

# We are IntechOpen, the world's leading publisher of Open Access books Built by scientists, for scientists

**4,800**

Open access books available

**122,000**

International authors and editors

**135M**

Downloads

Our authors are among the

**154**

Countries delivered to

**TOP 1%**

most cited scientists

**12.2%**

Contributors from top 500 universities



**WEB OF SCIENCE™**

Selection of our books indexed in the Book Citation Index  
in Web of Science™ Core Collection (BKCI)

Interested in publishing with us?  
Contact [book.department@intechopen.com](mailto:book.department@intechopen.com)

Numbers displayed above are based on latest data collected.

For more information visit [www.intechopen.com](http://www.intechopen.com)



---

## Ileoscopy; How and Why to Do It

---

Arjuna P. De Silva

Additional information is available at the end of the chapter

<http://dx.doi.org/10.5772/52628>

---

### 1. Introduction

Colonoscopy is a widely practiced procedure. Ileal intubation is widely regarded as the gold standard for evidence of complete colonoscopy<sup>[1]</sup>. However, this is not routinely attempted because of perceived technical difficulty, excess time thought to be added to the procedure or the low diagnostic yield that it was thought to provide<sup>[2]</sup>. However, there is mounting clinical evidence that ileoscopy is of clinical benefit<sup>[3]</sup>. It also important to remember that if ileoscopy is not routinely practiced, performing an ileoscopy may become difficult even when there is a definite clinical indication for doing so, such as, when Crohn's disease or ileal tuberculosis is suspected.

Currently the position employed to intubate ileum is with the patient in the left lateral position and entering the valve at the 6 o' clock position<sup>[4]</sup>. However, we have sometimes encountered difficulty when performing ileoscopy in this position leading to extra time being taken during busy endoscopy lists. During such difficult procedures we found that placing the patient in the prone position facilitated ileal intubation.

The available evidence for routine ileoscopy during colonoscopy is controversial. Some studies have demonstrated a benefit of ileoscopy in selected patients. These include patients with diarrhoea, inflammatory bowel disease (IBD), suspected ileocecal tuberculosis (TB), right lower quadrant pain and hematochezia<sup>[5,6,7,8,9,10]</sup>. Most studies on place of routine ileoscopy during colonoscopy were done in Western populations and only a few studies conducted among Asians<sup>[6, 8]</sup>.

Relatively low prevalence of Crohn's disease (CD)<sup>[8, 10]</sup> high prevalence of gastrointestinal infections including TB in our part of the world compared to the west make it even more worthwhile to study the place of routine ileoscopy in the tropical setting. This may have a significant impact on patient management in these settings.

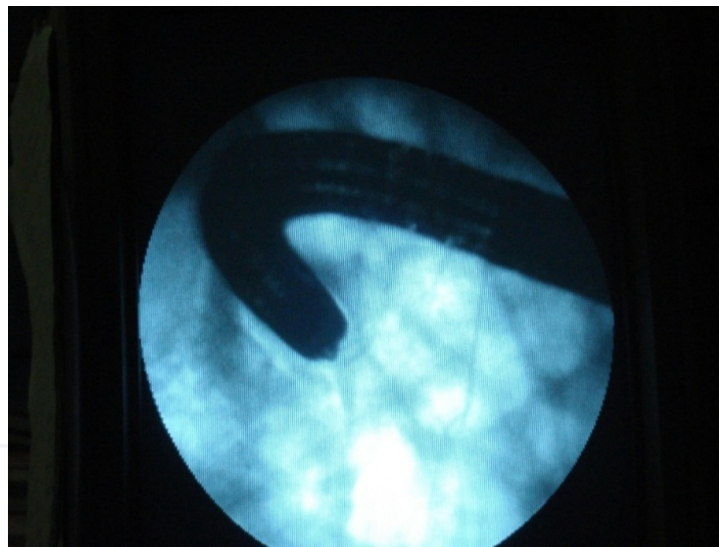
## 2. Aims

The aim of our first study was to test the hypothesis that the prone position made ileal intubation easier and quicker than the standard position that is currently used – the left lateral position.

The aim of the second study was to determine if routine ileoscopy was useful.

### 2.1. Methods [1]

We first performed a pilot study on ten patients undergoing routine colonoscopy using fluoroscopy to determine the best patient position for the most direct (end-on) approach to the ileo-caecal valve. Confirming our clinical impressions, the prone 12 o'clock position (patient prone and the tip of the colonoscope at the 12 o'clock position in relation to the ileocaecal valve) appeared to be the best position as this brought the tip of the colonoscope in line with the ileocaecal valve (figure 1). This was unlike in the 6 o'clock position (patient in left lateral position with tip of the colonoscope at the 6 o'clock position in relation to the ileocaecal valve) where the tip of the colonoscope was curved and not in the same axis (figure 2).

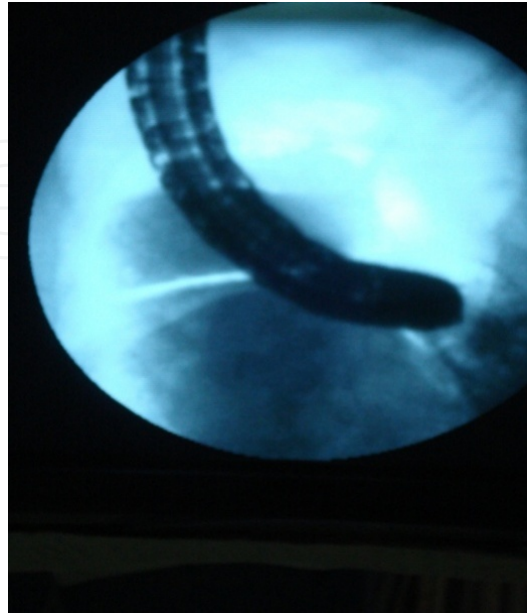

**Figure 1.** 6 o'clock position

We then randomized consecutive patients referred for colonoscopy to our unit between February 2009 and Jan 2010 using computer generated random numbers. Patients aged between 18-80 years and who were not pregnant were recruited after obtaining their written informed consent. They were then randomized to undergo ileoscopy either in the standard position or the prone 12 o'clock position.

All patients were given four packets of polyethylene glycol (PEG) for bowel cleansing prior to colonoscopy. All patients received pre-medication with medazolam 2.5 mg i.v. and pethidine 25 mg i.v. All patients had pulse oxymetry monitoring during the procedure. None of

the patients were given hyoscine-n-butyl bromide. The colonoscopes used were Olympus CF Q145L models.



**Figure 2.** 12 o'clock position

All colonoscopies were performed by experienced endoscopists (MAN and KVUK). After the ileo-caecal valve was identified during colonoscopy, ileal intubation time was standardized, and defined as the time taken for the tip of the colonoscope to be maneuvered from the mid-point of the caecum to entering the terminal ileum. This was timed by an independent observer (RSK).

#### *2.1.1. Ethical clearance*

Ethical clearance for the study was obtained from the Ethics Committee of the Faculty of Medicine, University of Kelaniya, Sri Lanka. Informed written consent was obtained from all patients.

#### *2.1.2. Statistics*

Sample size calculation was done on an assumption of 75% v 95% success at ileal intubation with the PP comp, and at 90% power this required a sample of 150 patients. The data was compared using Chi squared test and the statistical difference between the two groups will be compared using the program SPSS 16.

## **2.2. Methods [2]**

A retrospective study was conducted in the University Endoscopy Unit of the Colombo North Teaching Hospital, Ragama, Sri Lanka. As a policy in the University Medical Unit all patients undergoing colonoscopy had a routine ileoscopy and biopsy. All consenting pa-

tients who underwent colonoscopy from 01 January 2008 to 31 December 2012 were included in the study. Data was obtained from the endoscopy database and patient records using a preformed data extraction form. Details of the histopathological diagnoses were obtained from the data base of the Department of Pathology, Faculty of Medicine, University of Kelaniya, Ragama.

We hypothesized patients with right iliac fossa (RIF) pain, diarrhoea, anaemia, IBD and raised inflammatory markers have a higher incidence of ileal abnormality than the patients undergoing colonoscopy for other indications. Accordingly the macroscopic and microscopic abnormalities of the ileum were compared between these two groups.

### 2.2.1. Ethical clearance

Ethical clearance for this study was obtained from the Ethics Committee of the Faculty of Medicine, University of Kelaniya, Ragama, Sri Lanka.

### 2.2.2. Statistics

All statistical analysis was done using SPSS 16.

## 2.3. Results [1]

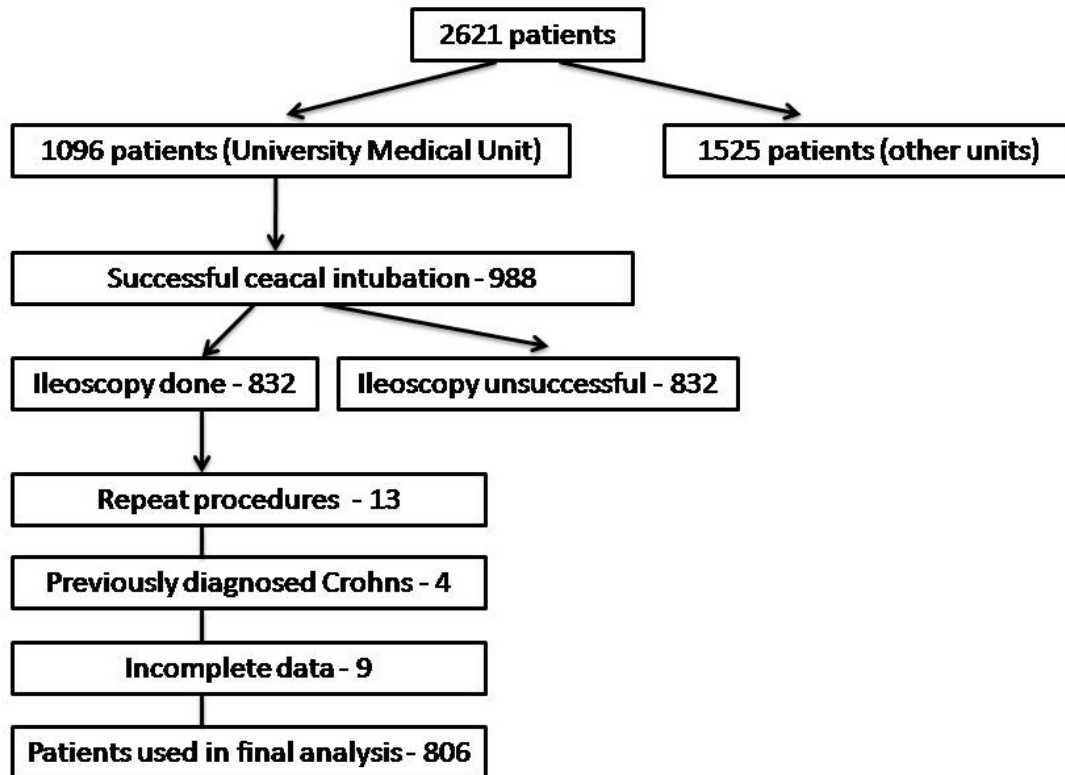
Colonoscopy was performed on 150 patients [82 females, mean (SD) age 53 (16) years]. 75 patients were randomized for ileal intubation in the PP and 75 patients in the LLP. The two groups were comparable for age, sex, indication for colonoscopy and abnormalities in the ileum (Table 1). Overall, the ileum was successfully intubated in 145 (96%) patients [74 (98.7%) in the PP and 71 (94.7%) in the LLP]. The median (Interquartile Range) ileal intubation time was 12 (10) seconds in the PP and 87 (82) seconds in the LLP ( $p < 0.0001$ ; Mann-Whitney U test). The ileum was abnormal in 11 (7.5%) patients: 6 in the PP group and 5 in the LLP group.

Indication for colonoscopy	Prone 12 (n=75)	Left lateral (n=75)
Diarrhoea	8	5
Constipation	8	12
Altered bowel habits	19	18
Abdominal pain	16	12
Iron deficiency Anaemia	9	10
Per rectal bleeding	3	6
IBD	6	8
Carcinoma of unknown primary	3	1
Loss of weight or& Loss of appetite	3	3
Number of patients with ileitis	6	5

**Table 1.** Indication for colonoscopy

## 2.4. Results [2]

A total of 2621 colonoscopies were done within the study period. Routine ileoscopy was practiced in 1096 patients who were evaluated by the University Medical Unit. Successful caecal intubation was achieved in 992 (90.51%) patients and the ileum was intubated in 832 (75.9%). 13 patients who underwent a repeat colonoscopy during the study period and 9 patients whose data records were incomplete were excluded from the final analysis Figure 3.



**Figure 3.** Trial profile

Indications for colonoscopy in patients who underwent ileal intubation were as follows (Table 2).

Four patients with Crohn disease were not analysed as they were any way expected to have ileal abnormalities. A total of 806 patients were taken in to final analysis.

These 806 patients were categorized as follows: presence of right iliac fossa (RIF) pain, diarrhoea, anaemia, ulcerative colitis (UC) and raised inflammatory markers considered as having a definite indication for ileoscopy (Group A); patients who underwent colonoscopy for any other reason as not having a definite indication for ileoscopy (Group B). Accordingly there were 593/806 (73.57%) patients with an indication for ileoscopy (Group A) and 213/806 (26.42%) patients did not have a definite indication for ileoscopy (Group B). Both groups were socio-demographically comparable to each other (Table 3).

Indication for Colonoscopy	Number of patients	Percentage (%)
RIF pain	126	15.55
Diarrhoea	238	29.38
Anaemia	80	9.88
Ulcerative colitis	89	10.98
Crohns disease	4	0.49
Polyps	7	0.86
IBS	29	3.58
Loss of weight	17	2.09
LIF pain	22	2.71
Constipation	61	7.53
Bleeding PR	47	5.80
RIF pain and Diarrhoea	18	2.22
Anaemia and Diarrhoea	6	0.74
Raised inflammatory markers	6	0.74
Bleeding PR and RIF pain	10	1.23
Bleeding PR and Diarrhoea	21	2.59
Other	29	3.58
Total	810	100.00

**Table 2.** Indications for colonoscopy

	Group A	Group B	P
Number	593	213	
Mean Age (SD) years	48.8 (16.5)	49.9 (15.4)	0.072
Male: Female ratio	1:1.08	1:1.05	0.818

**Table 3.** Demographic data of patients

137/806 patients (16.99%) studied had either macroscopic [48 (5.95%)] or microscopic [89 (11.04%)] abnormalities of the ileum. Ileum was considered macroscopically abnormal when it was described to have ulcers, strictures or evidence of inflammation by the endoscopist. Microscopic abnormalities described were Crohns disease, backwash ileitis of ulcerative colitis, tuberculosis (TB), ileitis due to resolving infection, drug induced ileitis and non specific-ileitis (Table 4,5)

Patients with macroscopic abnormalities of the ileum had significantly higher incidence of all histological abnormalities ( $p < 0.0001$ ,  $\chi^2 186$ ) as well as histopathological diagnoses which altered the management (Crohns disease, TB, Drug induced ileitis, Ileitis due to infection) ( $p < 0.0001$ ,  $\chi^2 119$ ) when compared with the patients whose ileum was macroscopically normal (Table 6).



	Group A	Group B	Total (%)
Macroscopically Abnormal	41	7	48 (5.95%)
Macroscopically Normal	552	206	758 (94.05%)
Total	593	213	806 (100%)

**Table 4.** Macroscopic abnormalities of the ileum

Histopathologica Diagnosis	Crohns	UC	TB	Drugs	Infection	Non-specific	Normal	Total
Macroscopy Abnormal	10 (20.83%)	8 (16.6%)	6 (12.5%)	01 (2.08%)	03 (6.25%)	06 (12.5%)	14 (29.16%)	48 (100%)
Macroscopy Normal	18 (2.37%)	6 (0.79%)	0	04 (0.52%)	05 (0.66%)	22 (2.9%)	703 (92.7%)	758 (100%)
Total	28 (3.47%)	14 (1.73%)	6 (0.74%)	5 (0.62%)	8 (0.99%)	28 (3.47%)	717 (88.95%)	806 (100%)

**Table 5.** Macroscopic and microscopic abnormalities

Histopathological Diagnosis	Group A	Group B	Total	Percentage (%)
Crohns disease	24	4	28	31.46
Tuberculosis	6	0	6	6.74
Ileitis- resolving infection	8	0	8	8.98
Drug induced ileitis	4	0	5	5.61
Back wash ileitis in UC	13	1	14	15.73
Non specific Ileitis	25	3	28	31.46
Total	80	9	89	100.00

**Table 6.** Histopathological abnormalities of the ileum

55 patients who had microscopic abnormalities in the ileum did not have a macroscopic abnormality of the ileum. Their histological diagnoses were Crohns disease (18), ileitis - resolving infection (5), drug induced (4), backwash ileitis in ulcerative colitis (6) and non-specific ileitis (22).

657 (81.5%) patients had no macroscopic mucosal abnormality in the colon, but 21(3.19%) of them had macroscopic ileal abnormalities. Furthermore 39(5.9%) patients with macroscopically normal colonic mucosa had histopathological abnormalities in the



ileum, namely Crohns disease (8), drug induced ileitis (2), resolving infection (2) and non specific ileitis (27).

47 (5.83%) of these microscopic abnormalities were considered to be significant ileal pathology which changed the management of the patient or provided clinically useful information, namely Crohn's disease (28), Tuberculosis(6), Ileitis due to resolving infection (8) or drug induced (5). ] Such ileal abnormalities were significantly higher among patients with right iliac fossa (RIF) pain, diarrhea, anemia, ulcerative colitis (UC) and raised inflammatory markers (Group A) [43/593] when compared to the others(Group B) [4/213]: ( $p=0.0032$ ,  $\chi^2$  8.23).

### 3. Conclusions

We have shown that during colonoscopy, the prone 12 o'clock position gives a more direct approach to the ileo-caecal valve and, although the ileum was intubated in more than 90% of cases in both positions, significantly reduces ileal intubation time when compared to the standard left lateral 6 o'clock position. The reason for this is that in the prone 12 o'clock position, the axis of the tip of the colonoscope is the same as the ileocaecal valve (as clearly demonstrated during fluoroscopy). This makes entry into the ileocaecal valve much easier. Since we use only light sedation (medazolam and pethidine) turning patients to the prone position is easy. The ileal abnormality rate was similar in both groups, and would therefore have not confounded our results.

The short coming of this study would probably be that we have not checked other positions of ileal intubation. However, we used the best position established by other studies and what is generally accepted as the best position(6 o'clock position) vs what we empirically thought was the best position (12o' clock). We also did a pilot study using fluoroscopy to establish the best possible position as well.

Although several previous studies have reported on the time taken for ileal intubation, such timings have not been standardized <sup>[5]</sup>. This has resulted in varying definitions of ileal intubation times which are not comparable, and the times reported range from seconds in some studies to more than ten minutes in some <sup>[6]</sup>. While no studies have clearly stated how to define ileal intubation time, it is assumed to be the time taken to maneuver the endoscope from the tip of the valve into the terminal ileum <sup>[4]</sup>. We felt that this does not give a true reflection of the difficulty of the procedure. We, therefore, defined it as the time taken for the tip of the colonoscope to be maneuvered from the mid-point of the caecum to entering the terminal ileum. Furthermore, we did not design our trial as a cross over study because once the ileum is intubated, the valve becomes patulous making the second intubation is easier <sup>[4]</sup>.

In conclusion, during colonoscopy the prone 12 o'clock position gives a more direct approach to the ileo-caecal valve than the left lateral 6 o'clock position and significantly reduces ileal intubation time. Incorporation of this observation into one's daily practice can be considered.

In our second study we found 16.9% of our study patients had either macroscopic or microscopic abnormality in the ileum. This is a much higher figure when compared to studies conducted in western countries<sup>[5,6,9]</sup>. Such studies have shown 2%-7.2% diagnostic yield in routine ileoscopy when performed in unselected patients<sup>[6]</sup>. In one study the diagnostic yield of ileoscopy had been only 0.3%<sup>5</sup>. Crohns ileitis had been the diagnosis made in most cases. However in most such studies, the ileum had been biopsied only when there was a macroscopic abnormality seen on endoscopy<sup>[5,6]</sup>. In our study an ileal biopsy was taken irrespective of the endoscopic findings of the ileum and we found that 55 patients with macroscopically normal ileum had microscopic abnormalities.

There were 657/806(81.5%) patients who did not have a mucosal abnormality of the colon on endoscopy. Out of this there were 21/657(3.19%) patients with macroscopic abnormalities and 39/657(5.9%) patients with histopathological abnormalities of the ileum. Among these there were 8 patients with Crohns disease who were diagnosed on ileoscopy and biopsy which would have been missed otherwise. One study conducted in India also has shown a high diagnostic yield of ileoscopy and 14 %( 8/57) study participants with ileal abnormalities were found to have a normal colonoscopy and barium enema<sup>7</sup>.

According to the literature it is clear that the yield of ileoscopy would depend on the clinical presentation of the patient. Therefore in our study we hypothesized that patients with Right iliac fossa pain (RIF pain), Diarrhea, Anemia, Inflammatory bowel disease (IBD) and Raised inflammatory markers would have a higher incidence of ileal abnormality than the patients undergoing colonoscopy for any other indication. Rationale behind this hypothesis was that it would include the patients with common conditions that would give rise to ileal abnormalities such as Crohns disease, tuberculosis and other chronic infections. Accordingly we have shown that the ileal abnormalities are significantly higher among patients with above features than those who don't have them.

Twenty eight patients were diagnosed to have Crohns disease on ileal biopsy and it is 3.4% of our total population. Even though there is no data available on population prevalence of Crohns disease in Sri Lanka, a hospital based survey carried out in two districts of Sri Lanka had found the prevalence of Crohns disease to be 1.2/100000 population<sup>11</sup>. This study was conducted in a tertiary referral centre with a special interest in inflammatory bowel disease. Therefore it is likely that the patients undergoing colonoscopy in our unit may have a higher prevalence of Crohns disease than the general population. Same bias in the sample may have contributed to the low prevalence of ileal tuberculosis and other gastrointestinal infections.

In conclusion, ileoscopy should be an integral part of any colonoscopy and especially so in the presence of right iliac fossa pain, inflammatory bowel disease, anaemia, diarrhoea and raised inflammatory markers. It improves the diagnostic yield of the colonoscopy by giving additional information, sometimes when the macroscopic appearances of the colon and the ileum are normal.

## Author details

Arjuna P. De Silva

Faculty of Medicine University of Kelaniya, Sri Lanka

## References

- [1] Borsh, G., & Schmidt, G. Endoscopy of the terminal ileum. Diagnostic yield in 400 consecutive examinations. *Dis Colon Rectum*. (1985). , 28, 499-501.
- [2] Harwood GC, Mattek NC, Holub JL et al. Variation in practice of ileal intubation among diverse endoscopy settings: results from a national endoscopic database. *Aliment Pharmacol Ther*. (2005). , 22, 571-8.
- [3] Seong, H. J., Kwang, J. L., & Yeong, B. K. Diagnostic value of terminal ileum intubation during colonoscopy. *J Gastroenterol and Hepatol*. (2008). , 23, 51-5.
- [4] Ansari A, Soon SY, Saunders BP, Sanderson JD. A Prospective Study Of The Feasibility of Ileoscopy at Colonoscopy. *Scand J Gastroenterol*. 2003; 38:1185-7.
- [5] Misra SP, Dwivedi M, Misra V. Ileoscopy in 39 hematochezia patients with normal colonoscopy. *World J Gastroenterol* 2006 May 21; 12(19): 3101-3104
- [6] Cherian, S., & Singh, P. Is routine Ileoscopy useful? An observational study of procedure times, diagnostic yield, and learning curve. *Am Journal of Gastroenterol* (2004). , 99, 2324-2329.
- [7] Bhasin, D. K., Goenka, M. K., Dhavan, S., Dass, K., & Singh, K. Diagnostic value of ileoscopy: a report from India. *J Clin Gastroenterol* (2000). , 31(2), 144-146.
- [8] Yoong, K. K. Y., & Heymann, T. It is not worthwhile to perform ileoscopy on all patients. *Surg Endosc* (2006). , 20, 809-811.
- [9] Kennedy, G., Larson, D., Wolff, B., Winter, D., Petersen, B., & Larson, M. Routine ileal intubation during screening colonoscopy: a useful maneuver?. *Surg Endosc* (2008). , 22, 2606-2608.
- [10] Jeong SH, Lee KJ, Kim YB, Kwon HC, Sin SJ, Chung JY. Diagnostic value of terminal ileum intubation during colonoscopy. *J. Gastroenterol. Hepatol*. (2008). Jan; , 23(1), 4-5.
- [11] Niriella, M. A., de Silva, A. P., Dayarathne, A. H. G. K., Ariyasinghe, M. H. A. D. P., Nawarathne, M. M. N., Pieriset, R. S. K., & al. . Prevalence of Inflammatory Bowel Disease in two districts of Sri Lanka: a hospital based survey. *BMC Gastroenterology* (2010).