

We are IntechOpen, the world's leading publisher of Open Access books Built by scientists, for scientists

4,800

Open access books available

122,000

International authors and editors

135M

Downloads

Our authors are among the

154

Countries delivered to

TOP 1%

most cited scientists

12.2%

Contributors from top 500 universities



WEB OF SCIENCE™

Selection of our books indexed in the Book Citation Index
in Web of Science™ Core Collection (BKCI)

Interested in publishing with us?
Contact book.department@intechopen.com

Numbers displayed above are based on latest data collected.

For more information visit www.intechopen.com



Optical Coherence Tomography in Neuro-Ophthalmology

Tony Garcia, Ghislain Bonnay, Ayman Tourbah and Carl Arndt

Additional information is available at the end of the chapter

<http://dx.doi.org/10.5772/53510>

1. Introduction

In optic nerve disease excluding glaucoma, mainly three ophthalmoscopic presentations of the optic disc can be encountered: an apparently normal optic disc, an atrophic or an edematous optic disc. Many documentation methods in optic neuropathy (ON) have been used: drawings; color, monochromatic and angiographic photographs.

The optical coherence tomography (OCT), based on interferometry analysis, is a major achievement particularly for documentation of quantitative changes in the optic nerve head: it allows a measure of the retinal nerve fiber layer thickness (RNFL). This retinal layer is composed of non myelinated axons (myelination is generally posterior to the cribriform lamina). OCT can quantify a decrease in thickness due to the atrophy by axonal loss or increase in thickness related to edema. This review aims to illustrate the usefulness of this RNFL quantification in the exploration of optic nerve and anterior visual pathway diseases.

2. Materials and methods

An extensive review of the literature on applications of OCT in optic neuropathy was performed. The PubMed search engine was applied to the keywords "optic neuropathy", "optical coherence tomography" and "retinal nerve fiber layer". Studies exploring the various diseases of the optic nerve were classified according to the OCT results obtained at the initial visit. Glaucomatous neuropathy was excluded from this review. Characteristic diseases are illustrated by clinical case reports.

3. Results

The average RNFL thickness is the most common parameter encountered in all publications. It represents the average of all measured thickness values in a predefined annular zone adjacent to the optic disc. In some publications, the macular volume has also been evaluated.

The change over time of the average RNFL thickness could be characterized by two different patterns:

- a normal RNFL thickness at the initial visit, followed by a gradual decrease: progressive RNFL decrease
- an increased RNFL thickness at the initial visit.

4. Progressive decrease of RNFL thickness (evolution towards atrophy)

4.1. Inflammatory diseases: Multiple sclerosis (case reports 1 et 2)

Multiple sclerosis (MS) is the most common cause of optic neuropathy, therefore the evaluation of RNFL thickness in MS was the subject of numerous publications [1,2]

At the initial stage of optic neuritis, RNFL thickness is within normal limits, after 2 months it decreases and stabilizes between 6 and 12 months [3,4] as highlighted in case report 1.

Case report 1:

A 35 year-old man was admitted for subacute left monocular impairment. Left orbital pain increased by ocular movements was reported. Visual acuity was 1.0 on the right eye and 0.4 in the left eye.

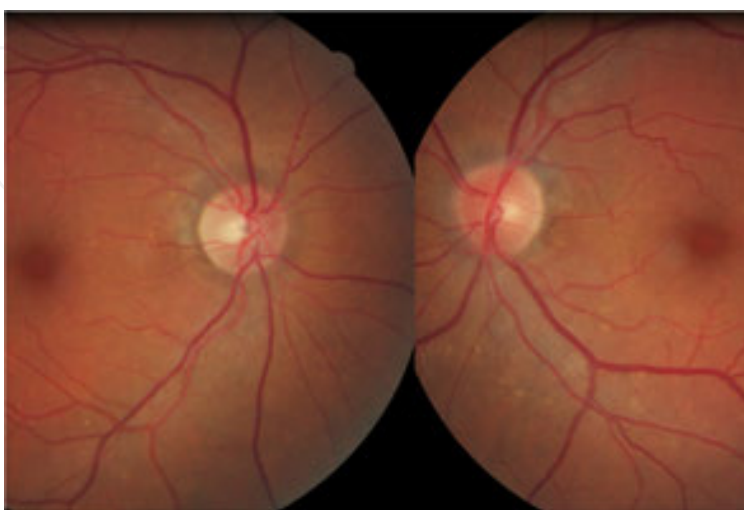


Figure 1. Retinal colour photography (case 1)

Ophthalmoscopy noted normal appearance of the right optic disc and slight left optic disc hyperemia (figure 1). Acute optic neuritis was suspected. On the OCT, there is a slight RNFL swelling in its nasal superior part, however the mean thickness remains within normal limits (figure 2).

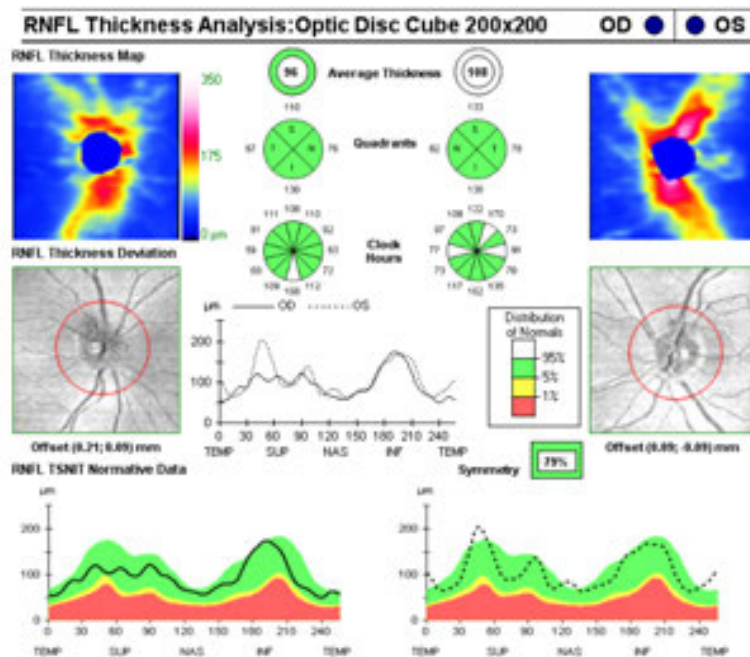


Figure 2. OCT slight RNFL swelling in the left eye (case 1)

The left visual field was abnormal with a nasal inferior defect, the right visual field was normal (figure 3).




Figure 3. Visual fields (case 1)

After stabilization of the affected eye following an episode of optic neuritis, average RNFL thickness is between 59.75 and 85.00 μm . In the contralateral eye, this parameter is between 82.73 and 99.80 μm (normal range: 102.90 - 111.10 μm) [5]. Thus, axonal loss is often present in both eyes even if symptomatic optic neuritis affects one eye only.

Case report 2

A 54-year-old woman suffered from multiple sclerosis and had already a left demyelinating optic neuritis a few years ago. Flair-weighted axial magnetic resonance image shows periventricular plaques (figure 4).

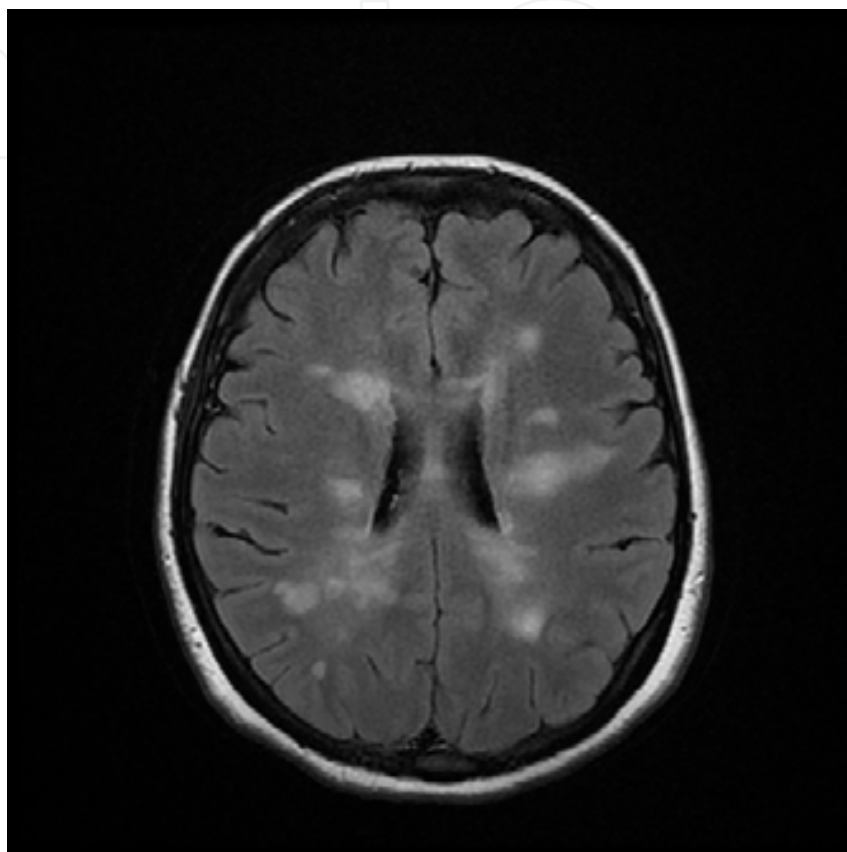


Figure 4. Brain MRI scan (case 2)

Visual acuity was 1.0 in both eyes. Left visual field displayed a small inferior central defect.




Figure 5. Visual field (case 2)

On ophthalmoscopy, a left temporal disc pallor indicative of previous optic neuritis was noted (figure 6).

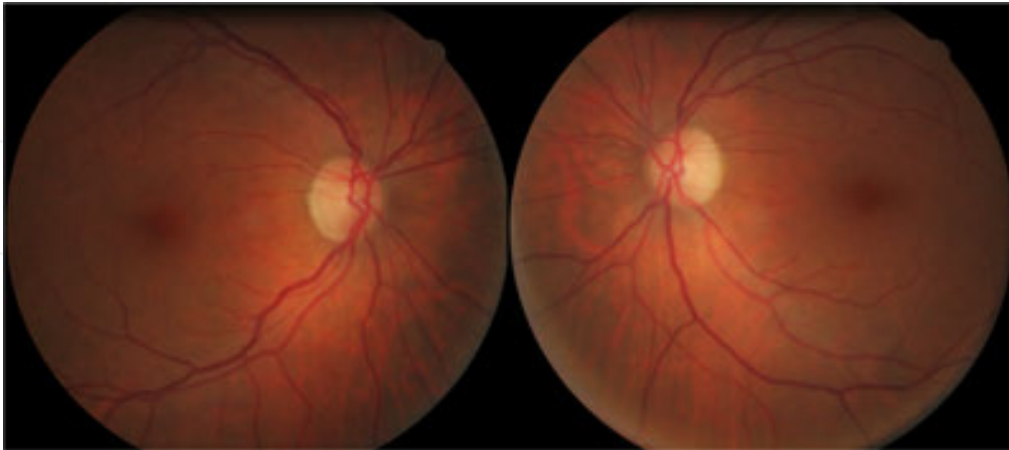


Figure 6. Retinal colour photography: left optic disc pallor (case 2)

OCT could confirm the decrease of the left temporal RNFL (figure 7).

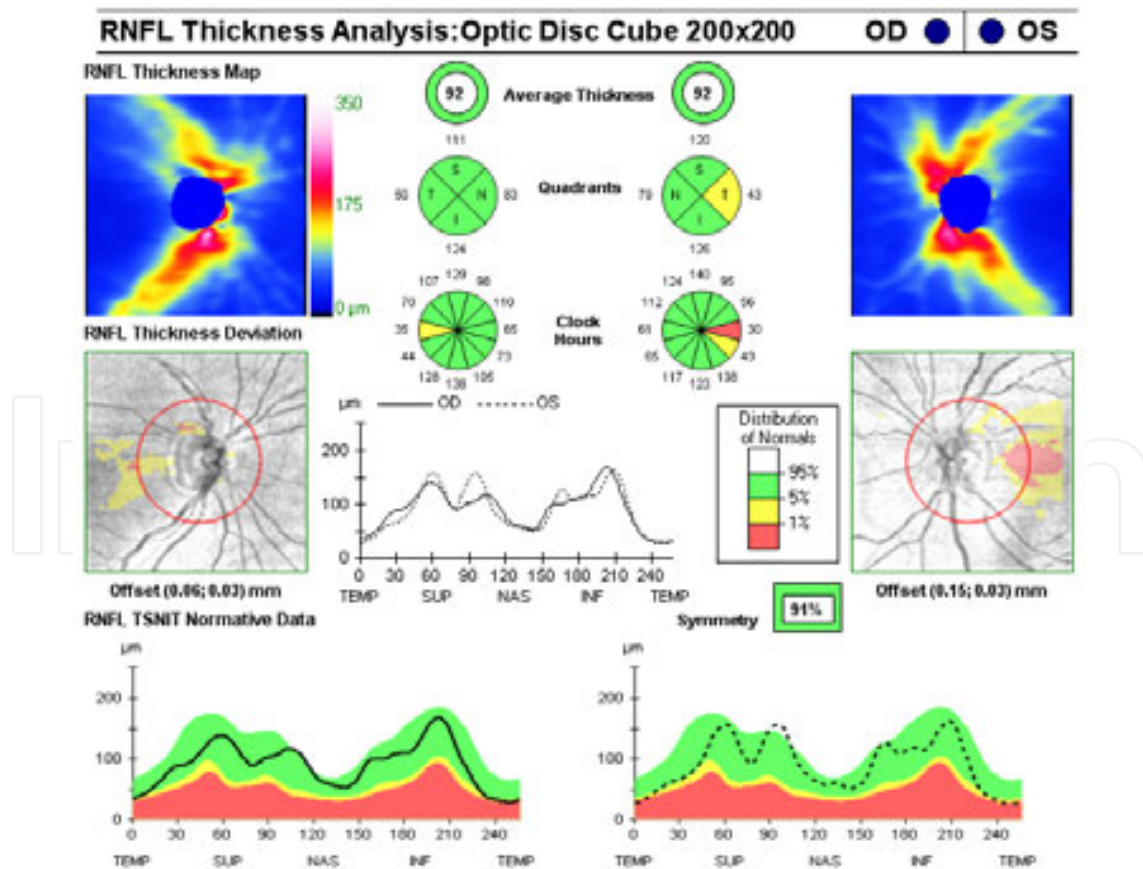


Figure 7. OCT: temporal RNFL thinning (case 2)

However, the importance of RNFL loss depends on the severity of MS in which optic neuritis occurs.

In the eye affected by inaugural optic neuritis, the RNFL thickness stabilizes at 58.10 microns, and at 101.20 microns in the contralateral eye.

If optic neuritis occurs in patients presenting with a relapsing form of MS, RNFL loss is greater in the affected eye, stabilizing at an average thickness of 48.20 μm whereas the contralateral eye remains unaffected, the thickness remains at a high average level of 103.70 μm .

In secondary progressive forms, characterized by a continuous evolution toward a severe neurological disability, axonal loss is even greater in the affected eye of optic neuritis (39.50 μm on average), but also affects the contralateral eye (83.40 μm on average) [6]. This RNFL loss predominates in the temporal quadrant [3] [7], a clinical model demonstrating the coexistence of axonal loss and demyelinating lesions in MS.

Other parameters have been evaluated with OCT in MS, especially a decrease in macular volume which is correlated with axonal loss [8] [9]. The relationship between central and peripheral macular thickness is an indicator of the evolution of the disease [10]. In addition, in MS, RNFL loss is considered to be a fairly accurate indicator of overall axonal loss, both ocular and extraocular. In the early course of the disease, there is a correlation between the decrease in RNFL thickness and neurological disability assessed by the Expanded Disability Status Scale (EDSS) [11] which represents the global axonal loss in MS. There is a relationship between RNFL loss and brain atrophy [12]. Thus RNFL thickness also appears as a reliable marker of disease severity.

Finally, some correlations between OCT parameters and morphological and functional data have been reported.

At the initial stage of optic neuritis: when RNFL thickness is often normal, visual evoked potentials (VEP) (and MRI when it is rapidly accessible) is more efficient to objectify the optic nerve lesions (eliminating a pithiatism when there is a doubt). Thus, at the early stages of MS, OCT is less sensitive than VEP for detecting clinical and subclinical optic neuropathy [13].

At distance of the initial attack of optic neuritis

- there is no correlation between RNFL thickness (a marker of axonal loss) and P100 latency (a marker of demyelination) [14]. In optic neuritis, the increase of cup/disc ratio is inversely proportional to the decrease in visual acuity and the decrease in RNFL thickness [15];
- there is a correlation between RNFL thickness (morphological marker of axonal loss) and visual acuity (a loss of one line of visual acuity corresponds to an average decrease of 5,40 μm in thickness) [16], pattern electroretinogram or pupillary reflex (functional markers of axonal loss) [17, 18].

4.2. Degenerative diseases: Neuromyelitis Optica (NMO) or Devic's disease (case report 3)

In Devic's syndrome, unlike MS, optic neuropathy is severe and is associated with spinal cord lesions without brain damage (figure 10). In OCT, the significant decrease in the thickness of

the layer of ganglion fibers reflects an atrophy more severe and diffuse than that observed in MS, mainly in the upper and lower quadrants [19,20]. As in MS, there is a correlation between the retinal nerve fiber layer thickness and the overall neurological disability assessed by the EDSS [21]. OCT can thus provide morphological arguments in the differential diagnosis of Devic's syndrome and MS. In a comparative study, the average thickness was 63.60 μm in Devic's syndrome, whereas it is 88.30 μm in MS (102.00 μm in the group of MS patients in an eye with no history of optic neuropathy) [22]. The average RNFL loss is 15 μm in a patient suffering from MS, whereas it is 39.00 μm in the case of Devic's syndrome [22].

Case 3

A 35-year-old woman had bilateral optic neuritis. Left visual acuity was 1.0. Despite anti-inflammatory treatment, right visual acuity had not recovered and remained very low (0.02).

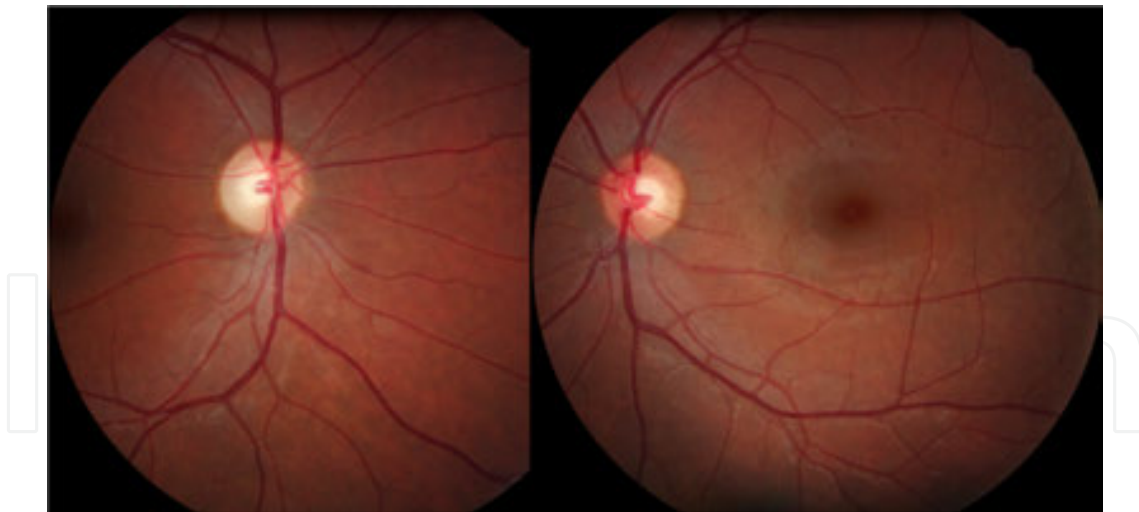


Figure 8. Retinal colour photography (case 3)

Optic atrophy is observed in the right eye, there is an optic disc pallor in the left eye (figure 8)

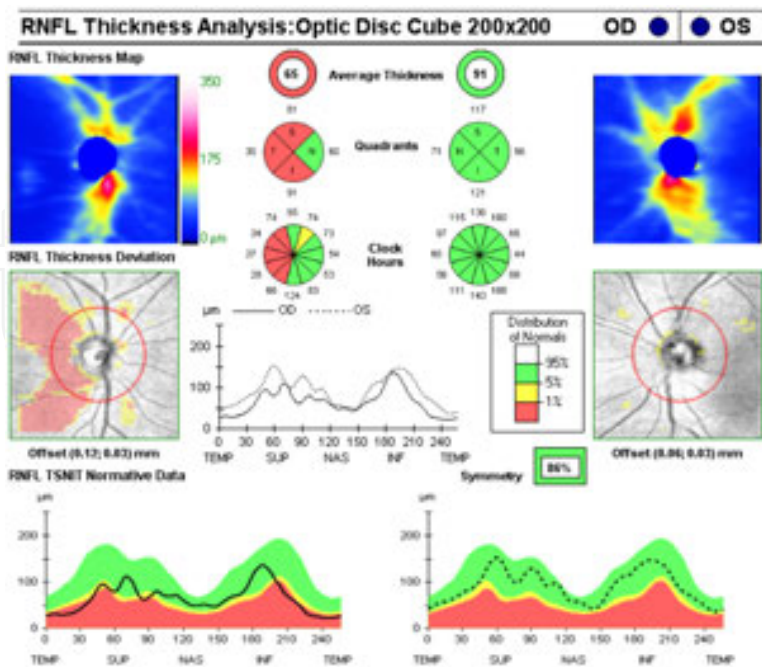


Figure 9. OCT RNFL: loss in the right eye (case 3)

Important decrease of retinal fiber layer was found on the right OCT with an average thickness of 65 μm (figure 9).

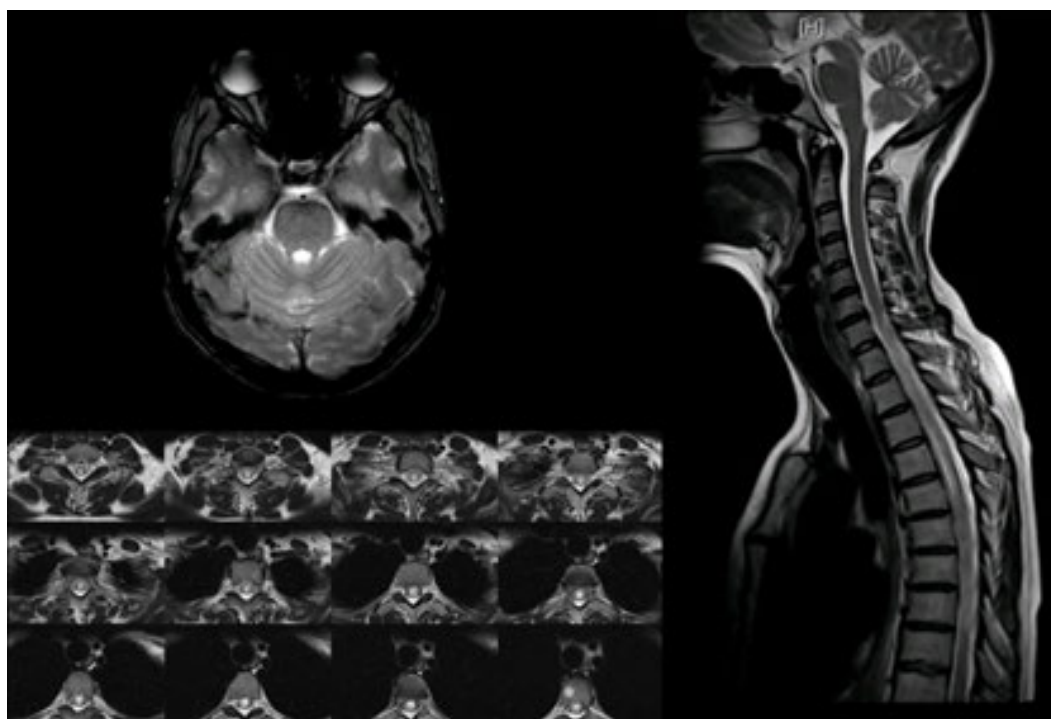


Figure 10. Brain and Medullar MRI scan (case 3)

Transverse myelitis was found on the MRI scan (Figure 10) as part of Devic's disease.

4.3. Compressive disease (case 4)

Compression of visual pathways caused by a pituitary adenoma induces axonal loss responsible for RNFL loss on time domain OCT. The importance of this axonal loss predicts visual acuity changes and visual field recovery after surgery for pituitary adenoma [23]. The postoperative recovery is significantly better if the preoperative thickness is greater than 85.00 μm [24].

Case 4

A 75 year-old man complained of chronic headache. Visual acuity was 0.8 on the right eye and 0.4 in the left one.

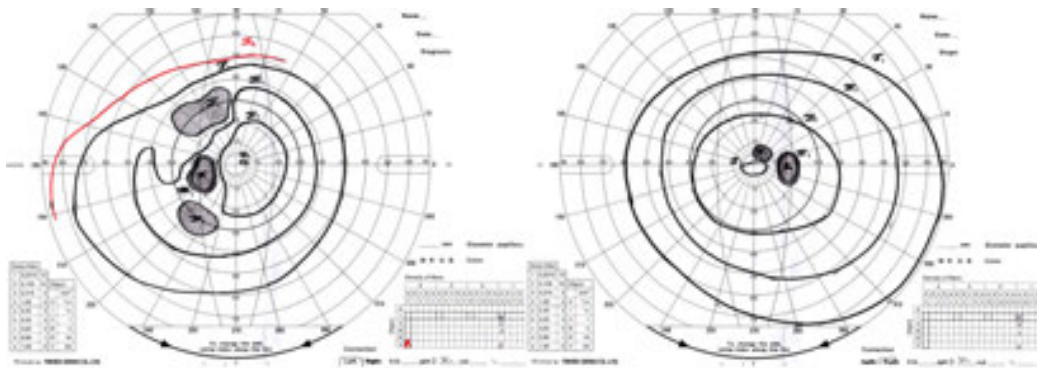


Figure 11. Visual field: temporal asymmetric defect in both eyes (case 4)

Visual fields showed temporal defects in particular in the left field (Figure 11).

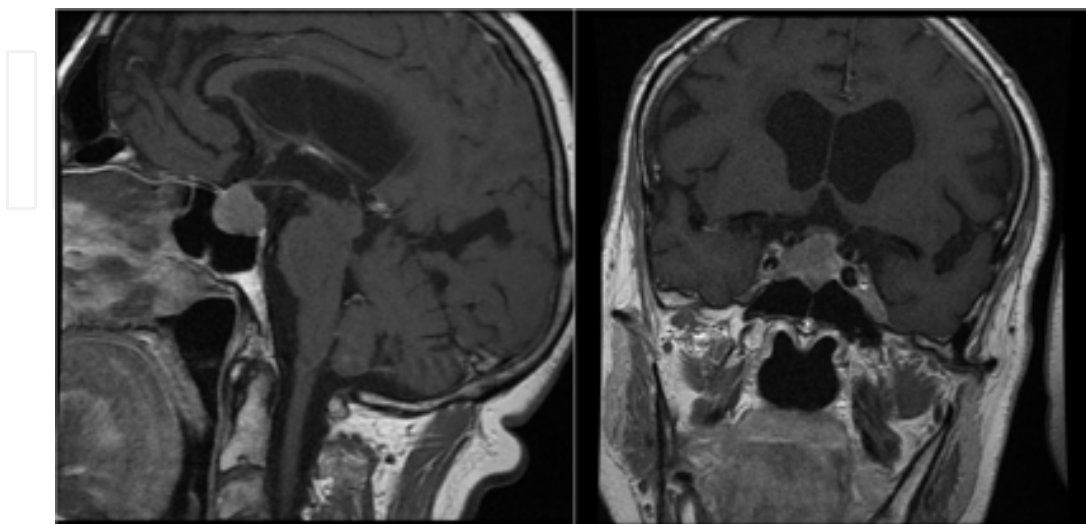


Figure 12. Brain MRI scan (case 4)

Magnetic resonance imaging discovered a large pituitary tumor with chiasm compression (figure 12).

Preoperative average RNFL thickness attests of significant axonal loss in the temporal area.

IntechOpen

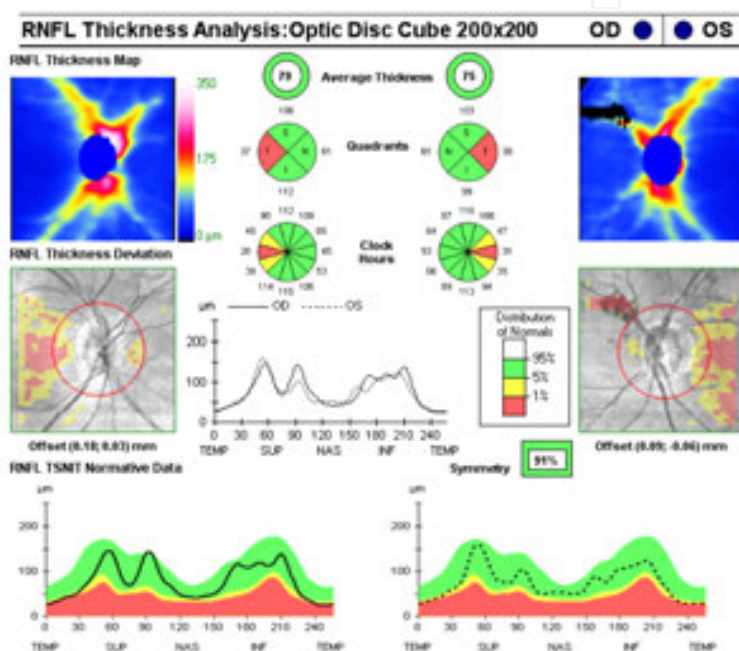


Figure 13. OCT: temporal RNFL thinning (case 4)

4.4. Hereditary disease

4.4.1. Dominant Optic Atrophy (DOA) or Kjer's disease (Case 5)

In dominant optic atrophy (DOA), there is bilateral symmetric optic nerve pallor (Case 5) related to retinal ganglion cell death. The decrease in the RNFL thickness in OCT is dominant in the temporal part [25].

Case 5

A seven year old girl is referred for poor visual acuity (RE 20/40, LE 20/50) associated with bilateral optic disc atrophy (Figure 14).

IntechOpen

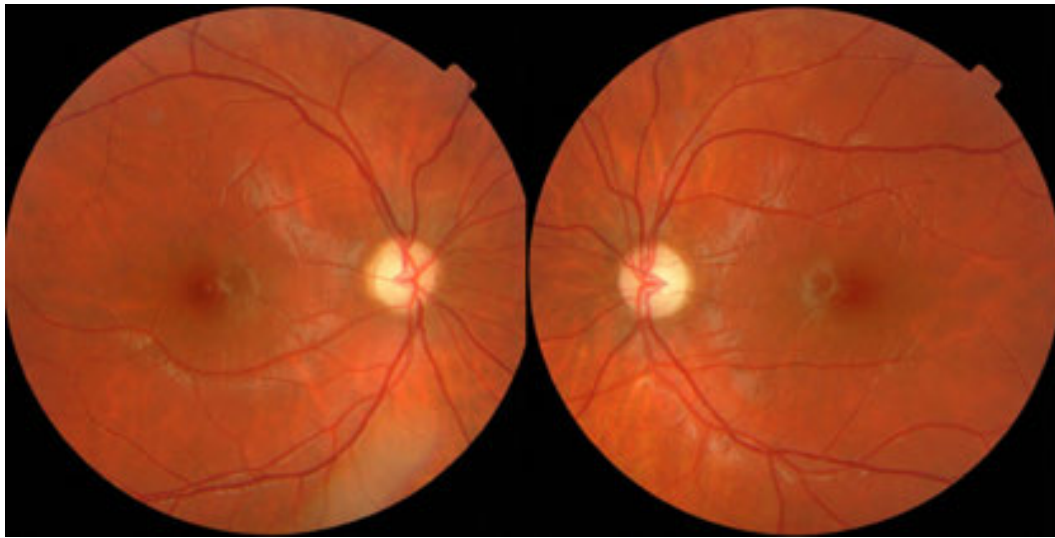


Figure 14. Retinal colour photography (case 5): bilateral optic atrophy

On color vision testing there is a blue-yellow confusion axis (Figure 15).

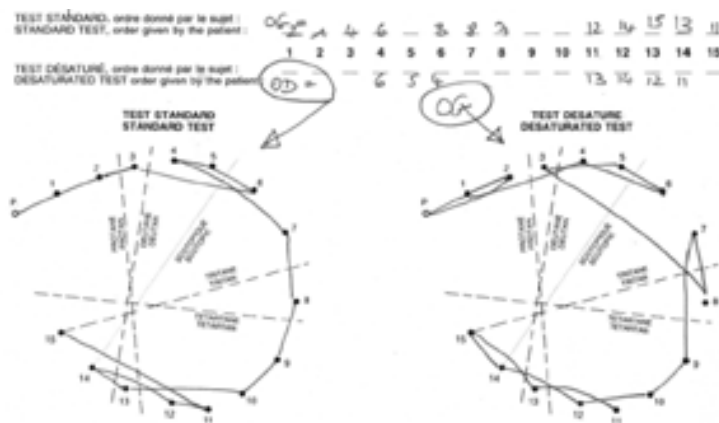


Figure 15. Farnsworth 15HUE (case 5): yellow blue defect

On the time domain OCT, a major bilateral RNFL loss is noted (Figure 16).

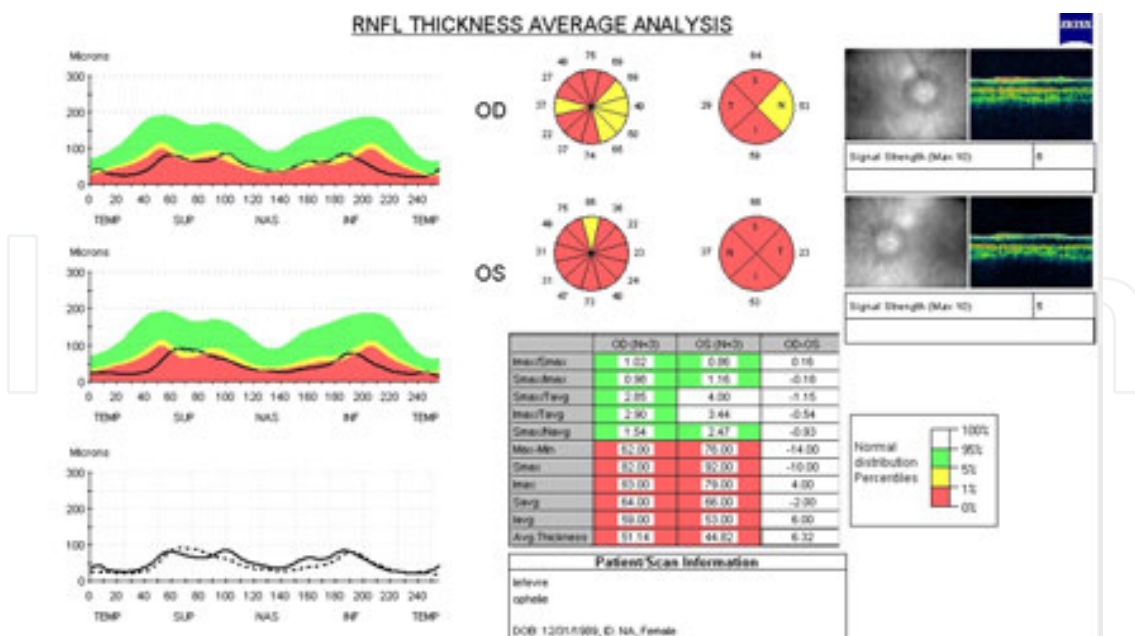


Figure 16. OCT: RNFL loss in both eyes (case 5)

There is no compressive process on the brain MRI which only displays atrophic optic nerves (figure 17).

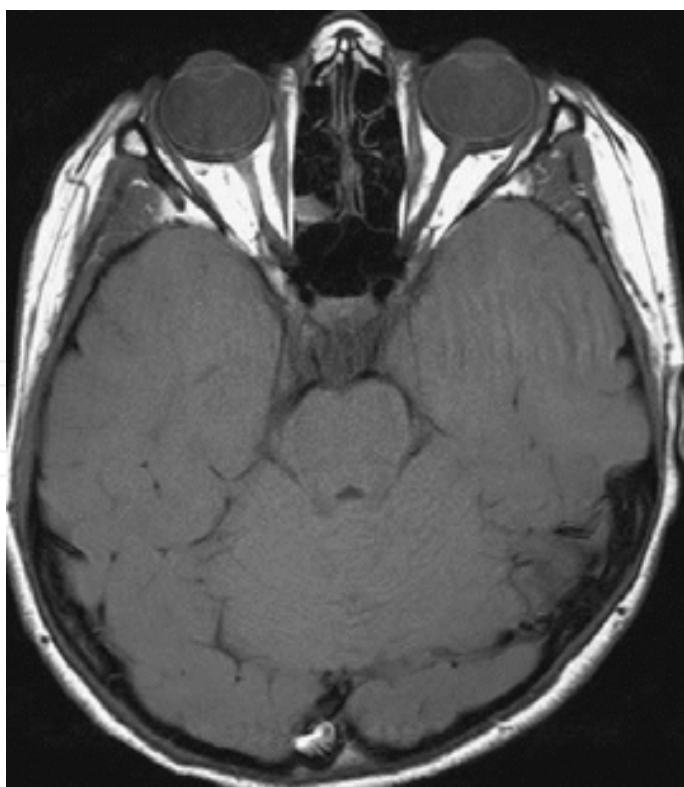


Figure 17. Brain MRI scan (case 5): bilateral thinning of the optic nerves

A dominant pattern was found upon family enquiry (Figure 18).

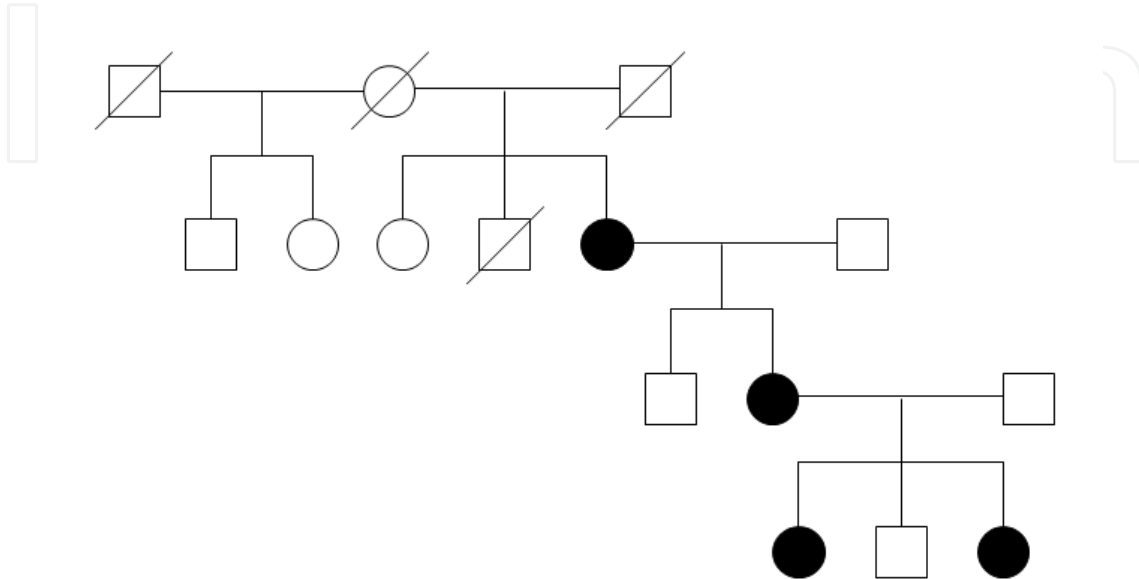


Figure 18. Family enquiry (case 5)

4.4.2. Other hereditary optic neuropathies

In the authors' clinical experience, OCT is also useful in the morphological evaluation of optic neuropathies encountered in other hereditary diseases such as recessive optic neuropathy and Wolfram's disease. However no reports on this subject could be found.

4.5. Toxic optic neuropathy

OCT can be useful for the follow-up of visual loss in patients with toxic optic neuropathy due to smoking, alcohol consumption or treatment for tuberculosis. In the early stages of toxic optic neuropathy, RNFL edema may be detected in some patients before permanent visual loss occurs. RNFL decrease consecutive to the withdrawal of the toxic agent can be monitored with OCT.

Case 6

A 48-year-old woman complained of progressive and painless visual loss. She had alcohol and tobacco addiction. She was deficient in B vitamins. Visual acuity was 0.3 in the right eye and 0.4 in the left eye. Color fundus photos showed pale optic discs without hemorrhage. Miliary drusens were also observed on macular areas (Figure 19).

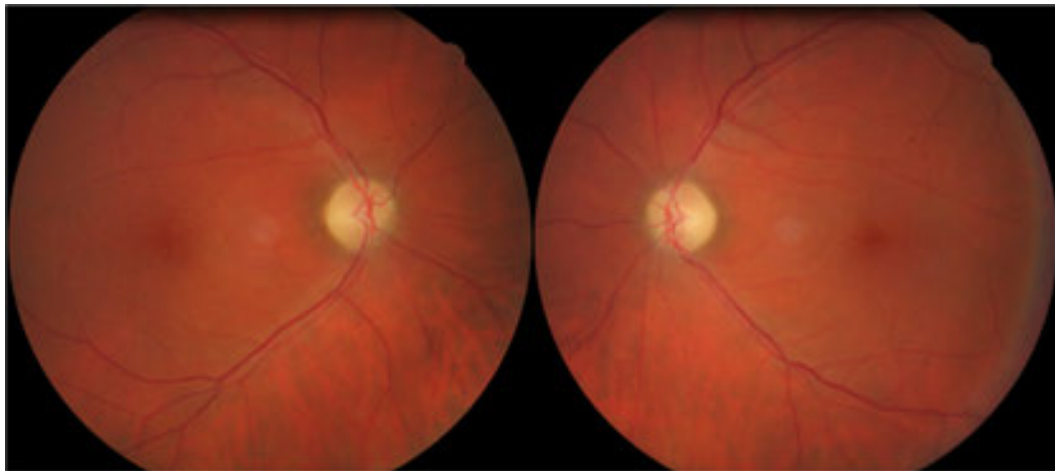


Figure 19. Retinal colour photography (case 6): bilateral optic atrophy

Centrocaecal scotomas were visible in both visual fields (Figure 20)

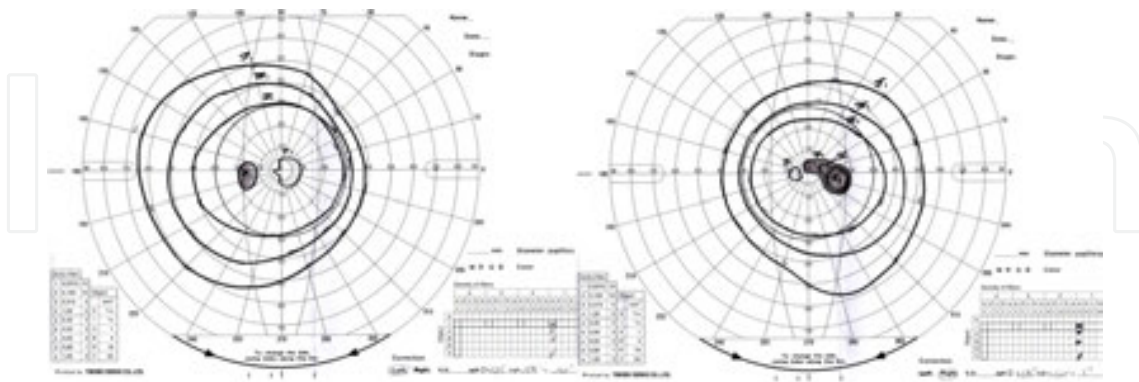


Figure 20. Visual fields (case 6)

OCT confirmed optic nerve atrophy demonstrating a global RNFL loss.

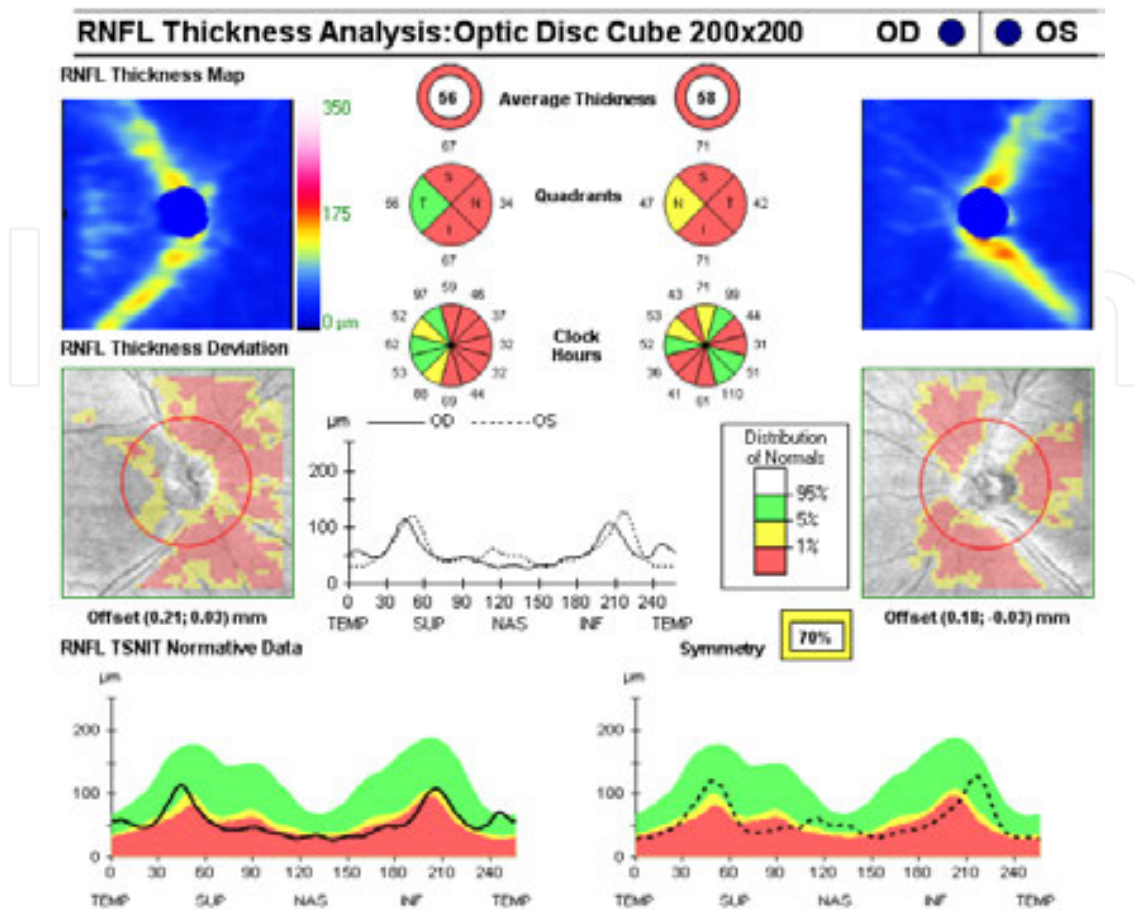


Figure 21. OCT RNFL: loss in both eyes (case 6)

5. Gradual RNFL reduction following initial increase of RNFL thickness

In optic disc swelling, an increase in the RNFL thickness can be quantified by OCT.

Depending on the underlying disease, the condition will either resolve with normalization or shift to optic atrophy with axonal loss. This evolution can be monitored with OCT.

5.1. Papilledema (case 7)

Optic disc swelling due to idiopathic intracranial hypertension is referred to as papilledema [26]. It may be responsible for the deterioration of visual function and progression to optic atrophy. Visual field and VEP are prognostic indicators for visual outcome [27]. This is not the case for RNFL thickness changes which only enable to monitor the progression of the disease.

Case 7

A 28-year-old woman suffered from headache and vomiting. On ophthalmologic examination, visual acuity was 0.9 on the right eye and 1.0 on the left eye without oculomotor paralysis. This

condition was due to intracranial hypertension. A bilateral papilloedema, venous engorgement, white exudates and superficial retinal folds was found (Figure 22).

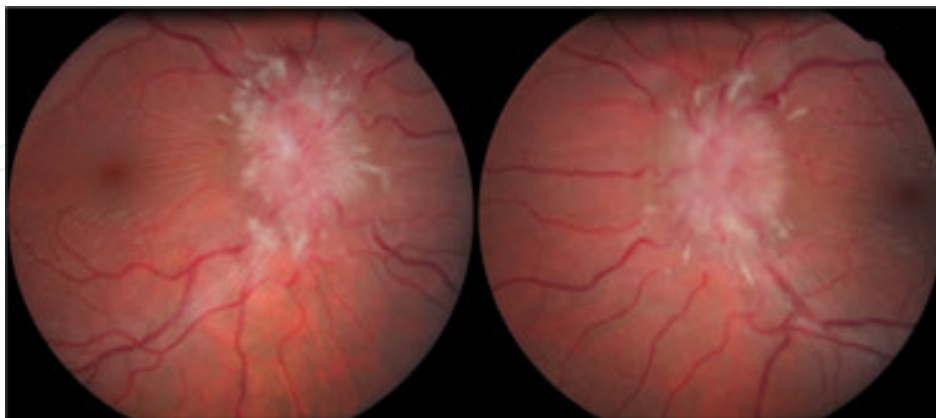


Figure 22. Retinal colour photography (case 7): bilateral optic nerve head swelling

Blind spots were enlarged on visual fields (figure 23).




Figure 23. Visual fields (case 7)

After spinal puncture and acetazolamide medication, she recovered normal visual acuity. OCT follow-up enabled to monitor the improvement with treatment (Figure 24).

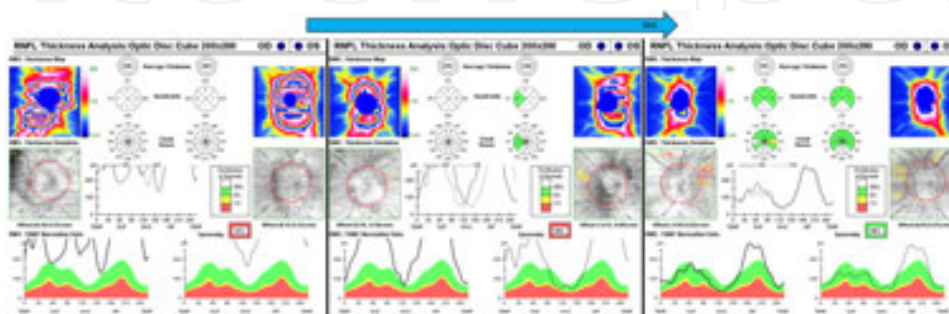


Figure 24. OCT RNFL follow-up (case 7)

5.2. Anterior Ischemic Optic Neuropathy (AION)

At the initial stage of an anterior ischemic optic neuropathy, there is most often a progressive optic disc swelling. Then, axonal loss is responsible for a gradual reduction of RNFL leading to a variable stage of optic atrophy stabilizing at six months of onset [28].

5.3. Leber's Hereditary Optic Neuropathy (LHON) (case 8)

At the acute phase, Leber's hereditary optic neuropathy associates peripapillary telangiectasia, tortuosity of retinal vessels and a peripapillary RNFL swelling with apparent optic disc swelling (figure 25-27). Within a few months (generally less than six months), diffuse optic atrophy occurs without excavation [29,30].

Case 8

An 11-year-old girl with no family history of Leber's disease suddenly presented with severe painless central vision loss in the right eye. Dilated capillaries in the retina adjacent to the optic nerve head were found in both eyes. Two months after onset, visual acuity in the left eye also decreased.

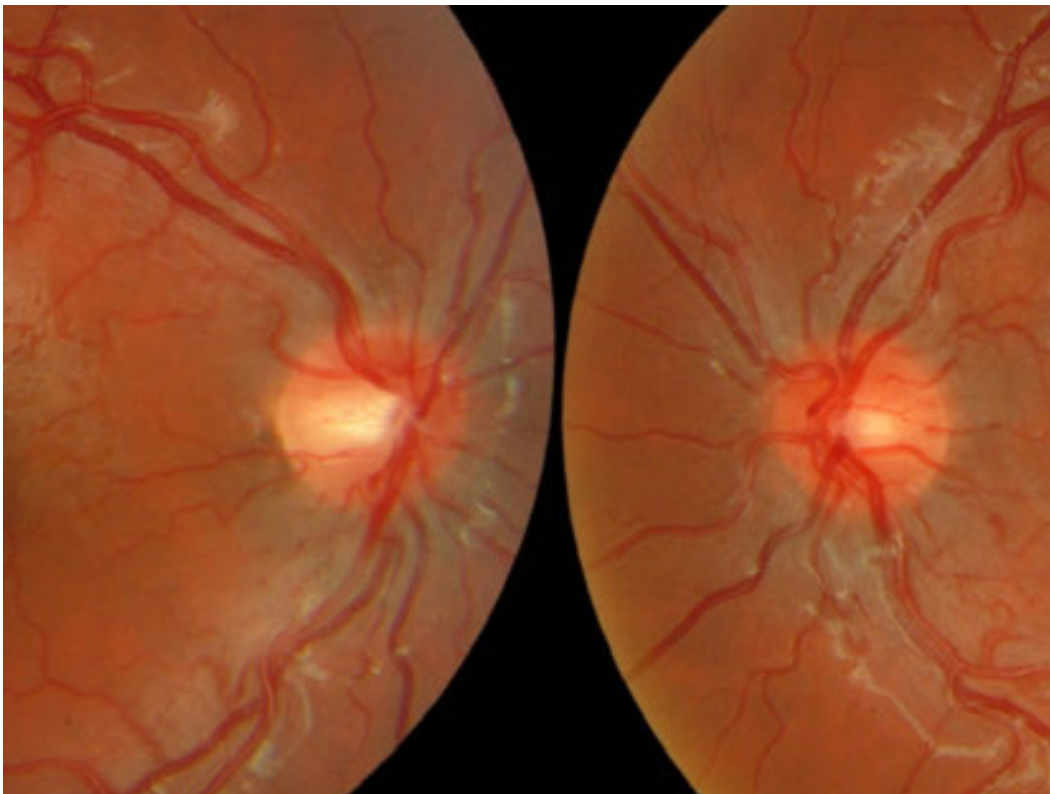


Figure 25. Retinal colour photography (case 8)

Average RNFL thickness was increased in both eyes on the initial examination and it then slowly decreased as optic atrophy developed.

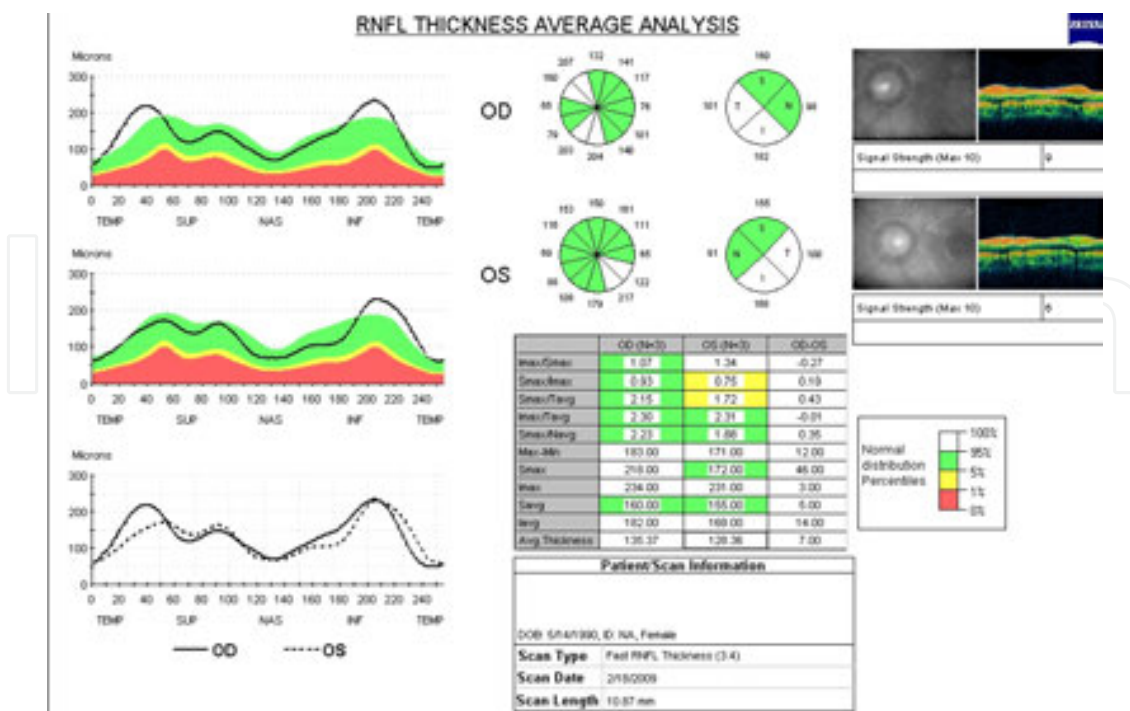


Figure 26. Initial OCT RNFL (case 8)

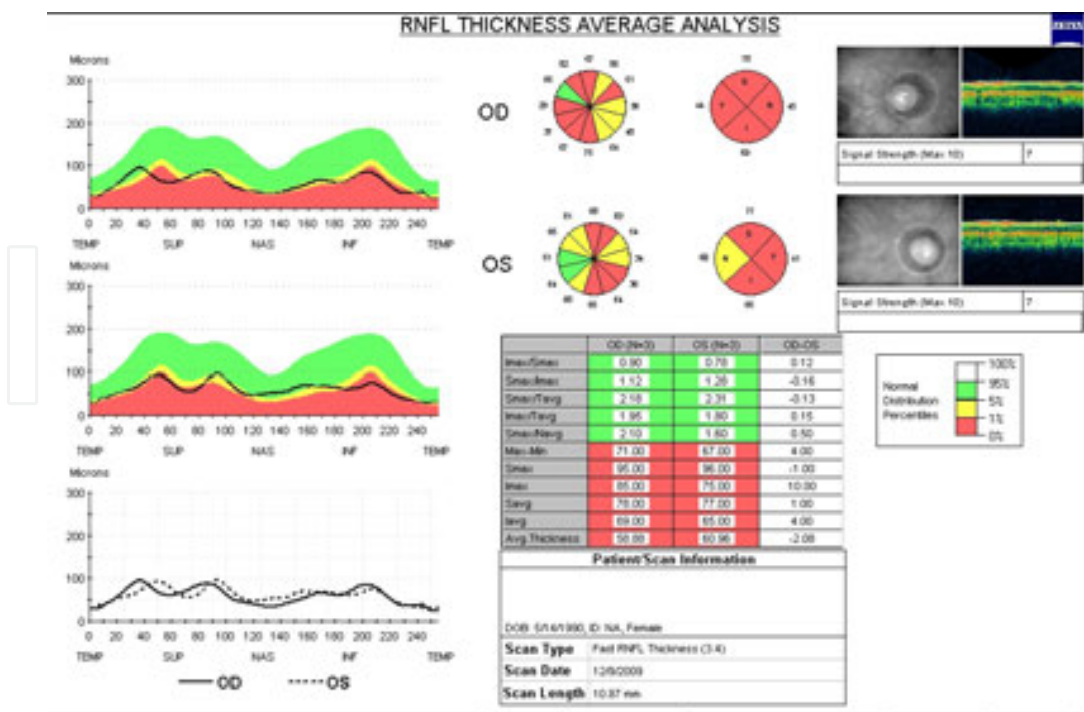


Figure 27. End stage OCT RNFL (case 8)

5.4. Secondary intracranial hypertension

Many different diseases can be responsible for increased intracranial pressure such as infectious meningitis (case 9). As in other diseases with initial optic disc swelling, OCT enables to monitor RNFL thickness reduction after causal treatment.

Case 9

A 47-year-old man was admitted for visual field disorders with papulosquamous eruption of the palms and soles within two weeks following a previous asymptomatic general skin eruption. Visual acuity was 0.8 in both eyes. Bilateral optic nerve head swelling was observed (figure 28).

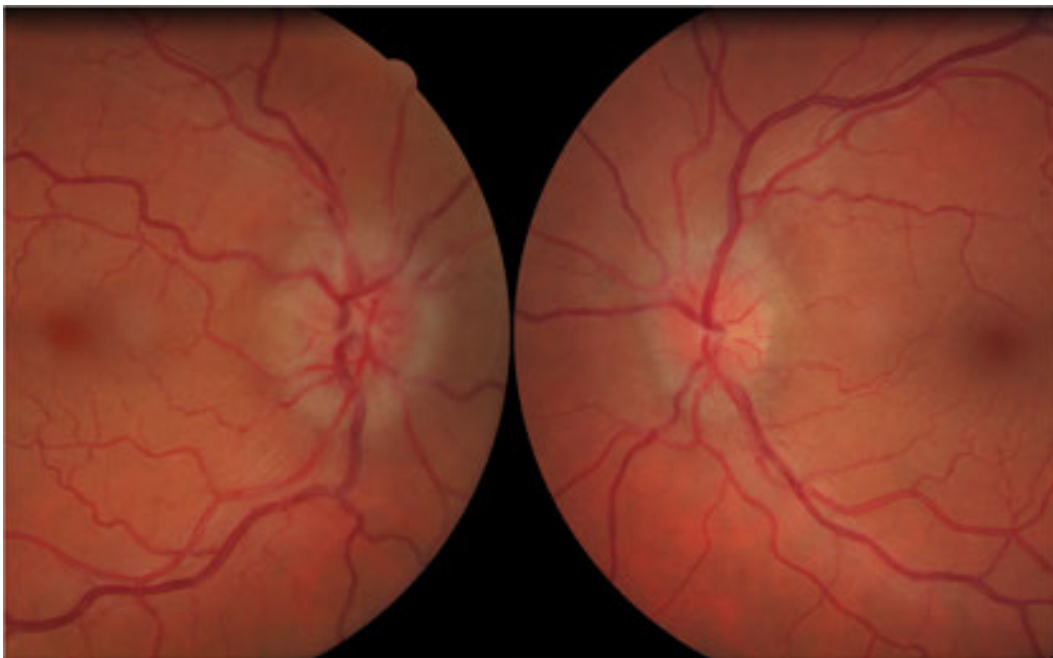


Figure 28. Retinal colour photography (case 9): Optic nerve head swelling

Goldmann visual fields displayed inferior altitudinal field defects (Figure 29).

Serological tests on blood and cerebrospinal fluid confirmed a syphilitic infection. After initial intravenous penicillin G, the patient was discharged with ceftriaxone injections (1 g/day) for three weeks. On the OCT scans, the decrease of optic nerve head swelling was replaced with superior optic atrophy (figure 30).

6. Limitations

Although OCT provides very useful quantitative information on RNFL thickness, there are several limitations inherent to the device which should be highlighted.

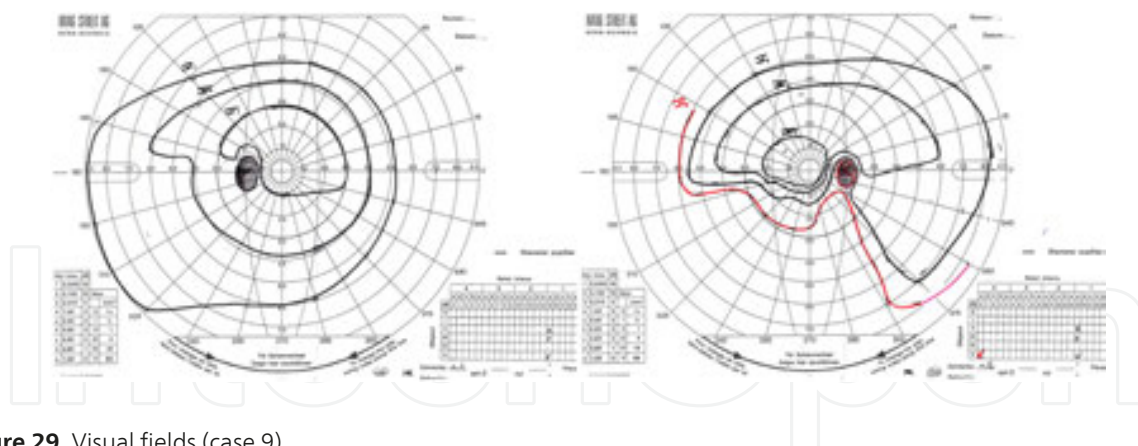


Figure 29. Visual fields (case 9)

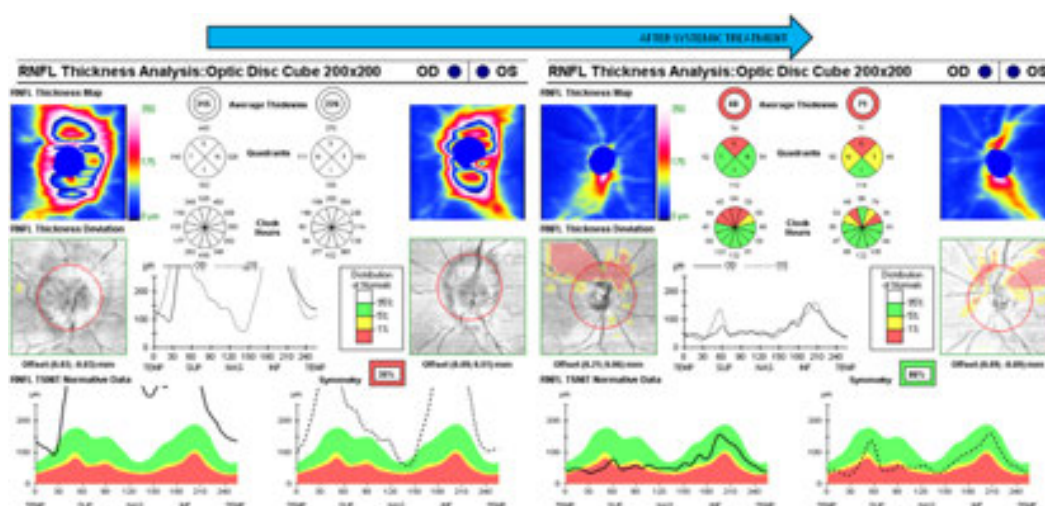


Figure 30. OCT RNFL follow-up (case 9)

6.1. Age

In the OCT database, normal values apply only to patients over 18 years. Evaluation of RNFL thickness is based on the assumption that there are no significant changes in normals from birth to the age of 18.

6.2. Morphological variations

RNFL thickness evaluation by OCT is not a reliable method in case of major morphologic changes of the optic nerve head such peripapillary atrophy in high myopia, staphyloma or optic pits.

6.3. Refractive media disorders

Ultra-red light has to pass through the transparent media of the eye to reach the retina. In case of corneal dystrophy, cataract, vitreous opacity, there is a signal decrease and RNFL thickness measurements become less reliable.

7. Discussion

As in macular disease, OCT has become a precious tool that contributes to improve management of optic nerve disease. This review illustrates the many indications in neuro-ophthalmology, although there are limitations to its use. OCT measures RNFL thickness to assess axonal loss [31]. Axonal loss may be masked in cases with optic nerve head swelling due to the inhibition of orthograde axoplasmic transport at the initial stage of the disease.

Despite the high utility of OCT in neuro-ophthalmology, exclusive RNFL thickness analysis is not sufficient for assessing optic nerve disease. OCT results should always be interpreted in the light of clinical ophthalmoscopy and visual function (visual acuity, perimetry, visual evoked potentials).

8. Declaration of interest

The authors hereby declare that they have no conflict of interest related to this article.

Author details

Tony Garcia¹, Ghislain Bonnay², Ayman Tourbah³ and Carl Arndt¹

1 Ophthalmologie, Hôpital Robert Debré, Reims University Hospital, Reims, France

2 Service d'Ophthalmologie, Troyes General Hospital, Troyes, France

3 Service de Neurologie, Hôpital Maison Blanche, Reims University Hospital, Reims, France

References

- [1] Garcia-martin, E, Pueyo, V, Martin, J, & Fernandez, F. J. Progressive changes in the retinal nerve fiber layer in patients with multiple sclerosis. *Eur J Ophthalmol* (2010). , 20, 167-173.
- [2] Beddiaf, A, & De Sèze, J. Névrite optique dans la sclérose en plaques : données diagnostiques et pronostiques. *Rev Neurol* (2009). SS147, 145.
- [3] Costello, F, Hodge, W, Pan, Y. I, Eggenberger, E, Coupland, S, & Kardon, R. H. Tracking retinal nerve fiber layer loss after optic neuritis: a prospective study using optical coherence tomography. *Mult Scler* (2008). , 14, 893-905.

- [4] Costello, F, Coupland, S, Hodge, W, Lorello, G. R, Koroluk, J, Pan, Y. I, et al. Quantifying axonal loss after optic neuritis with optical coherence tomography. *Ann Neurol* (2006). , 59, 963-969.
- [5] Kallenbach, K, & Frederiksen, J. Optical coherence tomography in optic neuritis and multiple sclerosis: a review. *Eur J Neurol* (2007). , 14, 841-849.
- [6] Costello, F, Hodge, W, Pan, Y. I, Freedman, M, & Demeulemeester, C. Differences in retinal nerve fiber layer atrophy between multiple sclerosis subtypes. *J Neurol Sci* (2009). , 281, 74-79.
- [7] Pro, M. J, Pons, M. E, Liebmann, J. M, Ritch, R, Zafar, S, Lefton, D, et al. Imaging of the optic disc and retinal nerve fiber layer in acute optic neuritis. *J Neurol Sci* (2006). , 250, 114-119.
- [8] Burkholder, B. M, Osborne, B, Loguidice, M. J, Bisker, E, Frohman, T. C, Conger, A, et al. Macular volume determined by optical coherence tomography as a measure of neuronal loss in multiple sclerosis. *Arch Neurol* (2009). , 66, 1366-1372.
- [9] Pulicken, M, Gordon-lipkin, E, Balcer, L. J, Frohman, E, Cutter, G, & Calabresi, P. A. Optical coherence tomography and disease subtype in multiple sclerosis. *Neurology* (2007). , 69, 2085-2092.
- [10] Gugleta, K, Mehling, M, Kochkorov, A, Grieshaber, M, Katamay, R, Flammer, J, et al. Pattern of macular thickness changes measured by ocular coherence tomography in patients with multiple sclerosis. *Klin Monatsbl Augenheilkd* (2008). , 225, 408-412.
- [11] Outteryck, O, Zephir, H, Defoort, S, Bouyon, M, Debruyne, P, Bouacha, I, et al. Optical coherence tomography in clinically isolated syndrome: no evidence of subclinical retinal axonal loss. *Arch Neurol* (2009). , 66, 1373-1377.
- [12] Siger, M, Dziegielewski, K, Jasek, L, Bieniek, M, Nicpan, A, Nawrocki, J, et al. Optical coherence tomography in multiple sclerosis: thickness of the retinal nerve fiber layer as a potential measure of axonal loss and brain atrophy. *J Neurol* (2008). , 255, 1555-1560.
- [13] Naismith, R. T, Tutlam, N. T, Xu, J, Shepherd, J. B, Klawiter, E. C, Song, S. K, et al. Optical coherence tomography is less sensitive than visual evoked potentials in optic neuritis. *Neurology* (2009). , 73, 46-52.
- [14] Gundogan, F. C, Demirkaya, S, & Sobaci, G. Is optical coherence tomography really a new biomarker candidate in multiple sclerosis? A structural and functional evaluation. *Invest Ophthalmol Vis Sci* (2007). , 48, 5773-5781.
- [15] Rebolleda, G, Noval, S, Contreras, I, Arnalich-montiel, F, García-perez, J. L, & Muñoz-negrete, F. J. Optic disc cupping after optic neuritis evaluated with optic coherence tomography. *Eye* (2009). , 23, 890-894.

- [16] Noval, S, Contreras, I, Rebolleda, G, & Muñoz-negrete, F. J. Optical coherence tomography versus automated perimetry for follow-up of optic neuritis. *Acta Ophthalmol Scand* (2006). , 84, 790-794.
- [17] Parisi, V, Manni, G, Spadaro, M, Colacino, G, Restuccia, R, Marchi, S, et al. Correlation between morphological and functional retinal impairment in multiple sclerosis patients. *Invest Ophthalmol Vis Sci* (1999). , 40, 2520-2527.
- [18] Salter, A. R, Conger, A, Frohman, T. C, Zivadinov, R, Eggenberger, E, Calabresi, P, et al. Retinal architecture predicts pupillary reflex metrics in MS. *Mult Scler* (2009). , 15, 479-486.
- [19] Green, A. J, & Cree, B. A. Distinctive retinal nerve fibre layer and vascular changes in neuromyelitis optica following optic neuritis. *J Neurol Neurosurg Psychiatry* (2009). , 80, 1002-1005.
- [20] Naismith, R. T, Tutlam, N. T, Xu, J, Klawiter, E. C, Shepherd, J, Trinkaus, K, et al. Optical coherence tomography differs in neuromyelitis optica compared with multiple sclerosis. *Neurology* (2009). , 72, 1077-1082.
- [21] De Seze, J, Blanc, F, Jeanjean, L, Zéphir, H, Labauge, P, Bouyon, M, et al. Optical coherence tomography in neuromyelitis optica. *Arch Neurol* (2008). , 65, 920-923.
- [22] Ratchford, J. N, Quigg, M. E, Conger, A, Frohman, T, Frohman, E, Balcer, L. J, et al. Optical coherence tomography helps differentiate neuromyelitis optica and MS optic neuropathies. *Neurology* (2009). , 73, 302-308.
- [23] Savino, P. J. Evaluation of the retinal nerve fiber layer: descriptive or predictive? *J Neuroophthalmol* (2009). , 29, 245-249.
- [24] Danesh-meyer, H. V, Papchenko, T, Savino, P. J, Law, A, Evans, J, & Gamble, G. D. In vivo retinal nerve fiber layer thickness measured by optical coherence tomography predicts visual recovery after surgery for parachiasmal tumors. *Invest Ophthalmol Vis Sci* (2008). , 49, 1879-1885.
- [25] Hamel, C, & Lenaers, G. Neuropathies optiques héréditaires. EMC (Elsevier Masson SAS, Paris), *Ophthalmologie*, 21-480-E-30, (2007).
- [26] Walsh and Hoyt's *Clinical Neuro-Ophthalmology* PhiladelphiaPA, USA: Lippincott Williams & Wilkins ((1998). , 487-548.
- [27] Biousse, V, & Newman, N. J. Management of optic nerve disorders: part II. Idiopathic intracranial hypertension. *Drugs Today* (1997). , 33, 19-24.
- [28] Contreras, I, Noval, S, Rebolleda, G, & Muñoz-negrete, F. J. Follow-up of nonarteritic anterior ischemic optic neuropathy with optical coherence tomography. *Ophthalmology* (2007). , 114, 2338-2344.
- [29] Votruba, M. Inherited optic neuropathies. *Pediatric Ophthalmology, Neuro-Ophthalmology, Genetics* Berlin: Ed. Springer ((2008). , 51-67.

- [30] Subei, A. M, & Eggenberger, E. R. Optical coherence tomography: another useful tool in a neuro-ophthalmologist's armamentarium. *Curr Opin Ophthalmol* (2009). , 20, 462-466.
- [31] Pula, J. H, & Reder, A. T. Multiple sclerosis. Part I: neuro-ophthalmic manifestations. *Curr Opin Ophthalmol* (2009). , 20, 467-475.

IntechOpen

IntechOpen