

We are IntechOpen, the world's leading publisher of Open Access books Built by scientists, for scientists

4,800

Open access books available

122,000

International authors and editors

135M

Downloads

Our authors are among the

154

Countries delivered to

TOP 1%

most cited scientists

12.2%

Contributors from top 500 universities



WEB OF SCIENCE™

Selection of our books indexed in the Book Citation Index
in Web of Science™ Core Collection (BKCI)

Interested in publishing with us?
Contact book.department@intechopen.com

Numbers displayed above are based on latest data collected.

For more information visit www.intechopen.com



Borderline Epithelial Tumors of the Ovary

Gennaro Cormio, Vera Loizzi, Maddalena Falagario,
Doriana Scardigno, Donatella Latorre and
Luigi E. Selvaggi

Additional information is available at the end of the chapter

<http://dx.doi.org/10.5772/54828>

1. Introduction

Borderline ovarian tumors (BOT) were first described in 1929 by Taylor, which, due to the characteristics of the tumor, called it “semi malignant” or “borderline” [1]; subsequently, this group of tumors of the ovary were classified in 1973 by the World Health Organization as “low malignant potential ovarian tumor” [2] and, finally, in 2003 WHO separates them from carcinomas and call them borderline tumors. [3]

Another term accepted to designate these independent ovarian neoplasms is “atypical proliferating (or atypical proliferative) tumor”. [4]

Borderline ovarian tumors represent 10-20% of epithelial ovarian neoplasm’s [5] with an incidence of 1.8-4.8 out of 100.000 women per year [6] and typically have an excellent prognosis.

Unlike the invasive carcinomas, borderline ovarian tumors are characterized by cytoplasmic and nuclear atypia, (element of differential diagnosis with benign tumors), absence of stromal invasion, (element of differential diagnosis with malignant tumors), unusual degree of proliferation of the epithelial cells with cellular stratification including remarkable architectural atypia and the formation of papillary protuberances. The absence of obvious stromal invasion is a principal diagnostic criterion for BOTs. Histologically, most of them are serous or mucinous, but endometrioid, clear cell, Brenner (transitional cell) or mixed histotypes can be also seen. [7]

To date, there are still no prospective randomized trials to clinical management, although they have an excellent prognosis, with a 5-year overall survival rate of almost 100% in early-stage disease (stage I-II) and between 86% and 92% in more advanced disease (stage III-IV). [8]

2. Classification, pathology and clinical behavior

Although they might occur in every age, most of the cases are diagnosed in pre-menopausal women between 34 and 40 years [9], while malignant ovarian cancer usually is diagnosed in patients between 50 and 70 years.

Risk factors for the development of BOTs are absolutely similar to those known for ovarian cancer, menarche, age at first pregnancy, age at first delivery, menstrual history, smoking history and family history of ovarian cancer, except that BOTs seem to have a lower frequency of BRCA mutations.

Borderline ovarian tumors are staged according to the FIGO classification of ovarian cancer. In 80% of cases patients with BOTs are in FIGO stage I at the time of diagnosis, about 30% of patients are in stage II-III in the same percentages each, while stage IV BOTs are very rare. [10]

2.1. Serous borderline tumors

They represent the 70% of BOTs, and 9-15% of all serous neoplasms [11,12] the mean age at presentation is 38 years old (range 17-77). [13] According to the FIGO staging system, [14] 68% are Stage I, 11% Stage II, 21% Stage III and less than 1% Stage IV. [15]

These neoplasms can be divided in two subtypes:

- APTs, Atypical proliferative serous tumors, behave in a benign way and show a papillary architecture with a hierarchical pattern
- Non-invasive MPSCs, micropapillary serous borderline tumors, with a non hierarchical pattern, characterized by the presence of micropapilla, they are more associated with invasive implants and a worse prognosis than APTs.

APTs in 25-30% of cases they are bilateral, macroscopically they appear as cysts with serous contents with friable and exuberant papillary projections. (Figure 1) These papillae are mostly observed on the inner surface of the cyst, but in 70% of cases also in the external one. Rarely these serous BOTs show solid components.

Histologically APTs show the presence of papillae with extensive epithelial stratification and budding, the epithelial cells have low or moderate atypias, in the fluid a detachment of single cells can be seen, there must not be any sign of invasion (Figure 2), but microinvasion (not more than 10 mm²) can be present in up to 15% of cases. F [13, 16, 17] Some patients with stage I microinvasive tumors have developed progressive disease and microinvasion for some authors can be considered as risk factor for patients with high-stage disease. [18]

The cells in APTs can show an epithelial and occasionally a mesothelial differentiation. The nuclei of these cells present more atypia than those seen in benign cystoadenomas, the nuclei are usually basally located and ovoid or rounded, the nucleoli are only occasionally prominent and the mitosis are not so common (usually less than four per ten high-power fields, HPF). [4]

APTs are occasionally also associated to the presence of endosalpingiosis or non invasive peritoneal implants, referred as the phenomenon of autoimplantation can be observed as the

presence of foci resembling non invasive desmoplastic peritoneal implants with a well-delineated border on the ovarian surface, this phenomenon does not have any clear known pathogenesis nor clinical significance. [13, 19, 20, 16, 17] Signs of necrosis are very rare. [4]

APTSs are usually positive for CK7, OC-125 and cytokeratin and express estrogen and progesterone receptors. [4]

Non-invasive MPSCs, are serous borderline tumors characterized by the presence of micropapillae arising from central papilla, when this specific pattern constitutes either a 5 mm or greater area or 10% or greater proportion.

In invasive MPSCs (synonymous of low-grade serous carcinoma) the stromal invasion must exceed 5 mm.

Non-invasive MPSCs represent 14% of all BOTs. The mean age at diagnosis is about 42 years, in 70% of cases they are bilateral and 50% of patients are in stage I at the time of diagnosis, while the other 50% are in stage II or III.

On gross appearance, non-invasive MPSCs look like cysts with papillae without or with little necrosis just like APSTs but in contrast to them they present mostly with peritoneal implant and bilaterality; the mean size is about 8 cm.

Histologically they are neoplasm with high degree of epithelial proliferation in a non hierarchical branching architecture, with micropapillary and cribriform patterns. [4]

The differential diagnosis should be done with serous cystadenomas, serous mucinous or endometrioid borderline tumors and with malignant neoplasm.

Survival in serous BOTs differs significantly from serous invasive ovarian cancer and is characterized by an excellent prognosis.

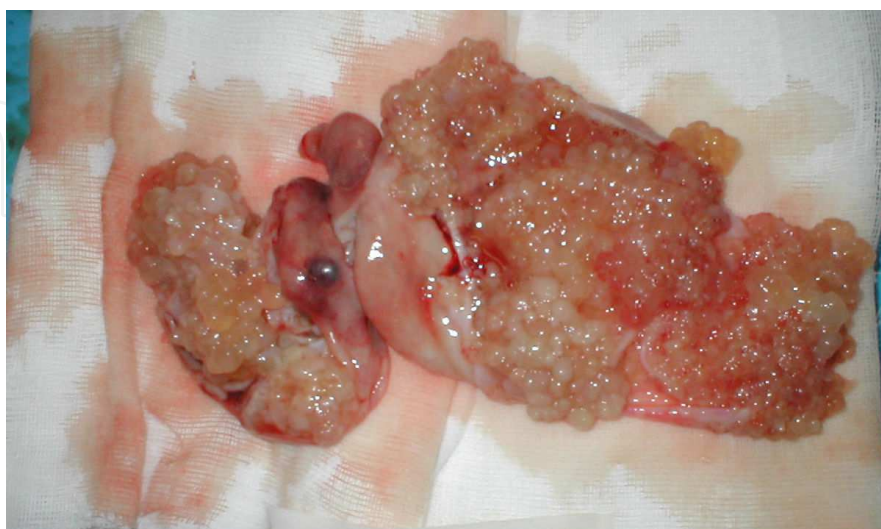


Figure 1. Serous borderline ovarian tumor

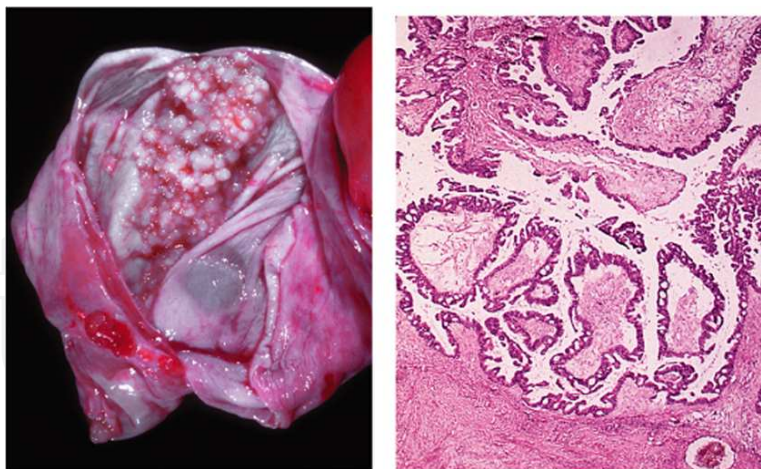


Figure 2. Serous borderline ovarian tumors

2.2. Mucinous borderline tumors

Mucinous BOTs are less common than their serous counterparts. They are also called “atypical proliferative mucinous tumor” (APMT) or “mucinous tumor of low malignant potential”. They are often associated to pseudomyxoma peritonei (PMP) a condition characterized by the presence of mucinous ascites and mucoid peritoneal implant

They can be divided into two subtypes:

- Gastrointestinal type
- Endocervical-like type (müllerian or seromucinous)

The first type in 95% of cases is unilateral and appears macroscopically as a multicystic large neoplasm (mean size of about 20 cm) with a smooth capsule.

The cysts contain inside a mucinous material and their surfaces very rarely show the presence of papillary projections.

Histologically, the stromal invasion is absent, the epithelium is stratified, mucinous gastrointestinal-type, with villoglandular or papillary intraglandular growth; the cells show moderate atypia in their nuclei. [4]

Their biological behaviour is very benign with a survival rate of nearly in early stages 100%. The tumors in advanced stage have a mortality of 50%, but mostly are associated with pseudomyxoma peritonei and probably all these case can be considered of primary gastrointestinal and not ovarian origin (usually appendix but also pancreas and biliary tract). For this reason is generally accepted that the true primary APMT in advanced stage do not really exist and that those cases with mucin or benign mucinous epithelium implant on the peritoneum can be explained by the rupture of the cyst and should not be classified as PMP or as APMT with peritoneal implants. [4]

Atypical proliferative mucinous tumors of endocervical-like type are more frequently bilateral, smaller and are often associated with endometriosis. Macroscopically and microscopically they resemble APTS with a combination of endocervical mucinous and serous epithelium. These neoplasms very rarely present with peritoneal implants or signs of microinvasion (defined as the presence of single or small cluster of cells within the stroma) and have a benign behaviour.

In some cases these tumors can show a severe atypia and epithelial overgrowth still without any sign of stromal invasion, these cases are referred to “non invasive or intraepithelial carcinoma” and have still an excellent prognosis in stage I. [4]

The immunohistochemistry pattern of mucinous BOTs is characterized by the expression of cytokeratin (CK) 7 and 20, but no positivity for estrogen and progesterone receptors and Ca125; in the differential diagnosis with intestinal tract tumors this can be very helpful (the neoplasms of intestinal tract origin express CK20 but not CK 7). [4]

The differential diagnosis should be done with metastatic mucinous carcinomas to the ovary and benign or invasive mucinous neoplasms of ovarian origin.

2.3. Endometrioid borderline tumors

Endometrioid tumors of the ovary are usually carcinomas, while borderline forms are very rare; they can arise from endometriosis and can also be associated to endometrial hyperplasia.

Endometrioid BOTs, also called Atypical Proliferative Endometrioid Tumors (APET), account for the 0,2% of ovarian epithelial neoplasms. [4]

Macroscopically they appear as cyst sometimes with solid compounds with hemorrhagic brown fluid inside, in about 60% of cases endometriotic foci are also associated. [4]

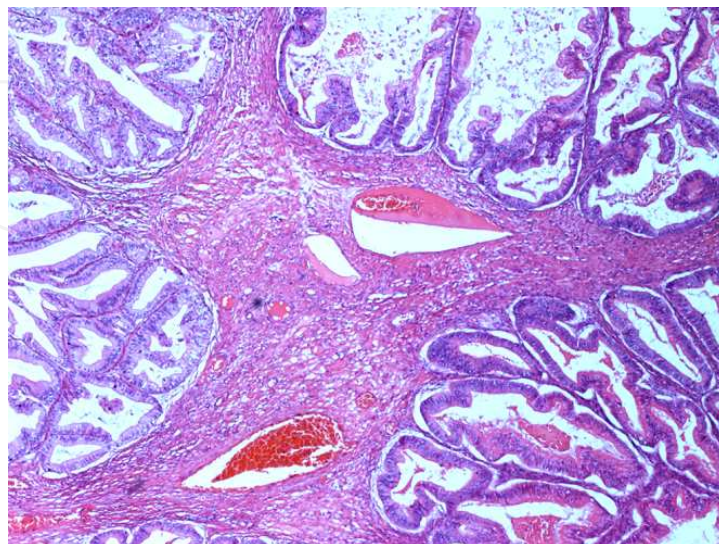


Figure 3. Endometrioid borderline ovarian tumor

Histologically they have glandular and papillary proliferation with different grade of complexity, with moderate or mild atypia in their cells, sometimes they show also squamous metaplasia and necrosis (Figure 3). A microinvasive APET can also be described if the glandular proliferation becomes confluent and the confluent area is less than 5 mm (otherwise it becomes a carcinoma) and this does not seem to be a negative prognostic factors.

Also in case of APET with intraepithelial carcinoma (referred to the presence of severely atypical cells, but without any sign of invasion) the prognosis remains benign.

The immunohistochemistry pattern of endometrioid BOTs is characterized by the expression of CK7, CK20 and p16 only focally. [4, 21]

2.4. Clear cell borderline tumors

Clear cell tumors of the ovary are usually carcinomas, while borderline forms are very rare; they are usually associated to endometriosis and sometimes to endometrial disorders.

Clear cell BOTs, also called Atypical Proliferative Clear Cell Tumors (APCCT), represent the 0,2% of ovarian epithelial neoplasm, their incidence is higher in elder people than other BOTs (mean age 60-70 years).

Macroscopically, they usually appear as cyst with a smooth lobulated surface, clear fluid inside and the cut surface has minute cyst in a rubbery stroma (honeycomb appearance). Microscopically, they are characterized by the presence of tubular glands lined by more layers of hobnail cells, with a more crowded architecture, more epithelial proliferation and more atypia in their cells, when compared to their benign counterparts (clear cell adenofibromas). [4]

As for other BOTs microinvasive APCCT or APCCT with intraepithelial carcinoma can be described, but they are actually very rare, while peritoneal implants have not been described.

The prognosis of these forms of BOTs in early stage is also very benign. [4, 22]

2.5. Borderline brenner (transitional cell) tumors

Transitional cell tumors of the ovary account for 10% of all the epithelial ovarian neoplasm, they are usually benign while malignant and borderline forms have been described but are very uncommon.

Borderline Brenner (Transitional cell) tumors are also called Atypical Proliferative Brenner (Transitional cell) tumors, the mean age at presentation is about 69 years; they are usually unilateral and in stage I at the moment of diagnosis.

Macroscopically, they are cystic, quite large (mean diameter of about 20 cm) with papillary projections in the inner surface.

Histologically, they are characterized by a transitional urothelial like epithelium, with benign areas and parts with proliferation and atypia. No cases of intraepithelial carcinoma or microinvasion have been described in literature.

In immunohistochemistry these neoplasms are usually positive for CEA, EGFR, Ras and negative for p16, p53 and cyclin d.

The prognosis is very good, with only one lethal case of recurrence occurred 50 months after the primary surgery reported in literature. [4, 23]

3. Diagnosis

The only certain diagnosis of BOT can be done by pathologists on the histological examinations, despite this, better understanding before surgery if an adnexal mass is benign, borderline or malignant is very important to decide if surgery is required and the surgical approach. The diagnosis of BOT can be suggested by the presence of certain symptoms, serum markers and image techniques patterns.

3.1. Symptoms

The range and type of symptoms claimed by BOT patients are similar to invasive cancer patients,

Most commonly [80%] patients with Borderline tumors of the ovary complain of abdominal symptoms like abdominal pain or increased abdominal size, discomfort, tense abdomen; 10-35% of these patients complain of gastrointestinal symptomatology like changes in bowel habits, nausea or constipation; 15% complain of gynaecological symptoms like abnormal vaginal bleeding and dyspareunia (more patients when compared with invasive cancer); 5-26% complain of urinary symptoms especially urinary frequency or urgency; 5-7% present with weight loss and malaise and increased urinary urgency or frequency, very few patients (around 3%) complain chest pain or breathing problems. Some studies demonstrated that patients with borderline ovarian tumour are more likely to have no symptoms than patient with invasive cancer. [24, 25, 26, 27, 28, 29, 30, 31]

Olsen et al compared symptoms of women with benign, borderline and invasive ovarian tumors, and demonstrated that patients with invasive cancer reported a greater number of symptoms (3.1 and 3.6 for Stages I-II and III-IV, respectively) than women with borderline or benign tumors. (2.8 and 2.2 respectively; $p < 0.0001$). [31]

3.2. Serum markers

Many studies tried to identify a serum marker that could distinguish BOT from invasive and benign ovarian tumors.

Ca-125 increases in BOT patients, less than in women with invasive cancer; anyway this marker is not so useful in the diagnosis especially because it can overlap between patients with stage I ovarian carcinoma or benign adnexal masses like endometriomas, abscesses or myomas and BOT patients. [27, 32, 33]

Ca-125 can instead, be used in the follow up and to primarily assess the severity of the disease because several studies demonstrated that it increases more in advanced stage BOT than early ones. [34, 35, 36, 37, 38]

Ca-19.9 increases in 18,8 – 48,8% of patients, probably more in serous hystotype, [35, 39], while Carcinoembryonic antigen (CEA) levels increases in 17% of patients and more in mucinous tumor. [35, 39, 40]

Ca 72-4 increases in BOT with no differences within the hystotypes, anyway the levels of this serum marker are similar in patients with ovarian cancer. [35, 41]

3.3. Ultrasound

Transvaginal ultrasound is well known to be an effective primary screening imaging technique in patients with adnexal masses to distinguish benign from malignant conditions.

Up to 63% of patients with BOT present on the ultrasound a cyst with papillae inside, but without solid patterns, septa or any other sign of complexity. [42, 43]

BOTs appears on ultrasound images usually as:

- unilocular cyst with solid papillary projections (defined as any projections with a height greater than or equal to 3 mm) arising from the inner wall and with a positive ovarian crescent sign (Figure 4, 5)
- cyst with a “honeycomb nodule”, defined as a multilocular nodule mostly with a solid pattern with cystic areas arising from the inner cyst wall. (Figure 6) [42, 43, 44, 45]

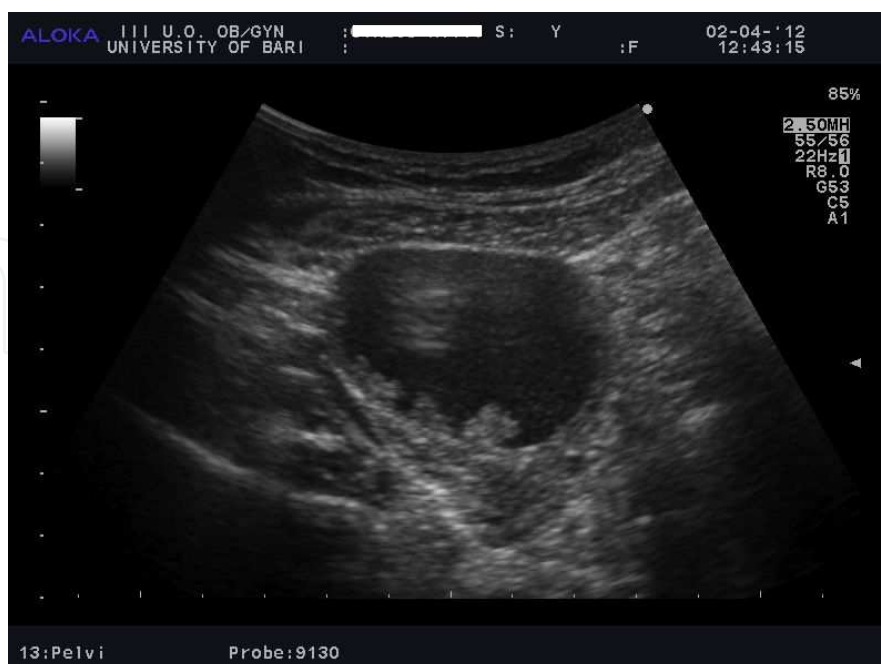

Figure 4. Unilocular cyst with solid papillary projections in BOTs

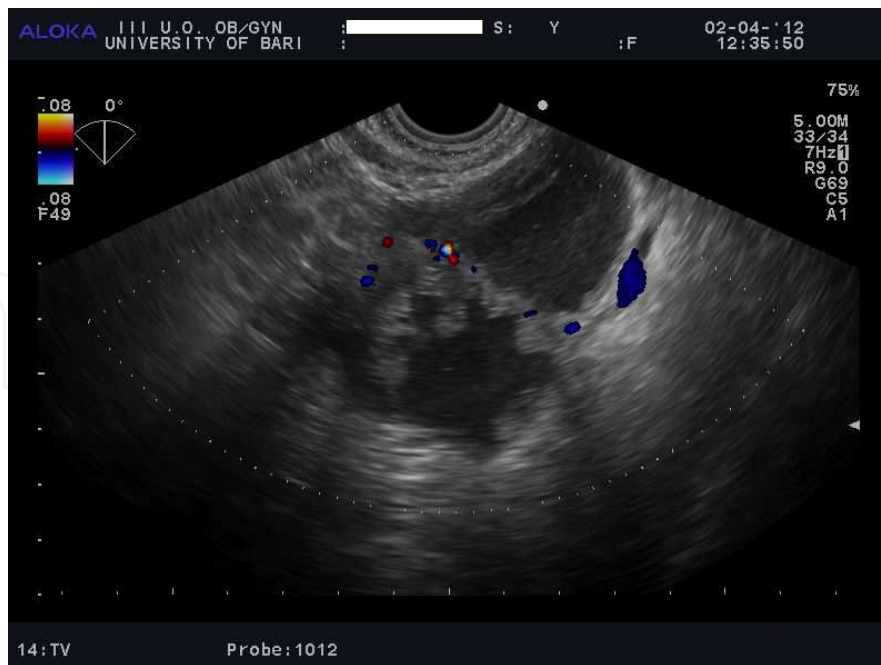


Figure 5. Papillary projections in BOTs

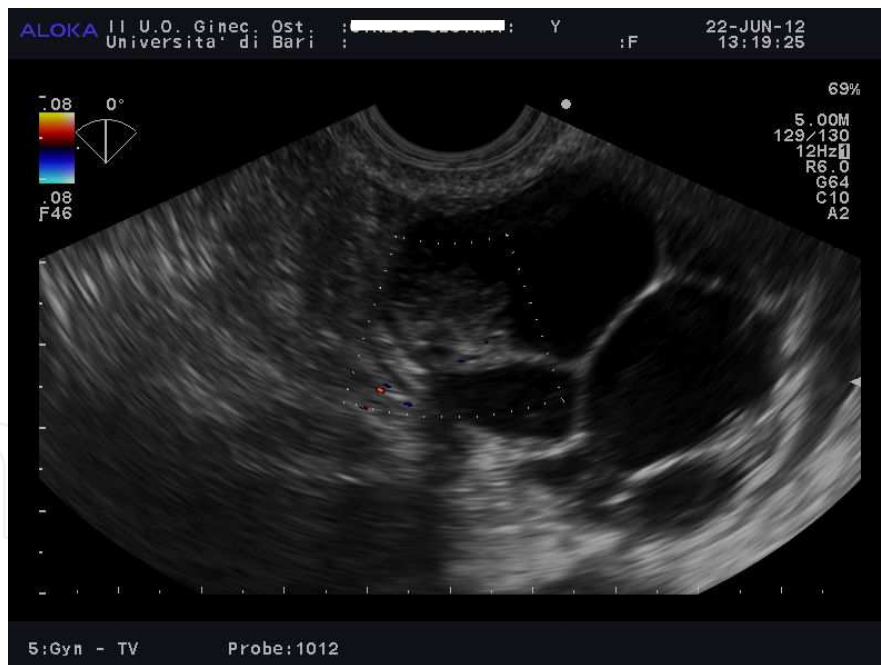

Figure 6. Honeycomb nodule in BOTs

11% of these tumors can appear as simple anechoic cysts without any papillae, and up to 30% as cysts with septa. (Figure 7) [42, 43, 45]. For these reasons, neither the presence of papillae nor septa can be considered as sensitive sonographic markers of borderline tumors, in fact it has been shown that also benign tumors can contain papillae or septa. [42, 46]

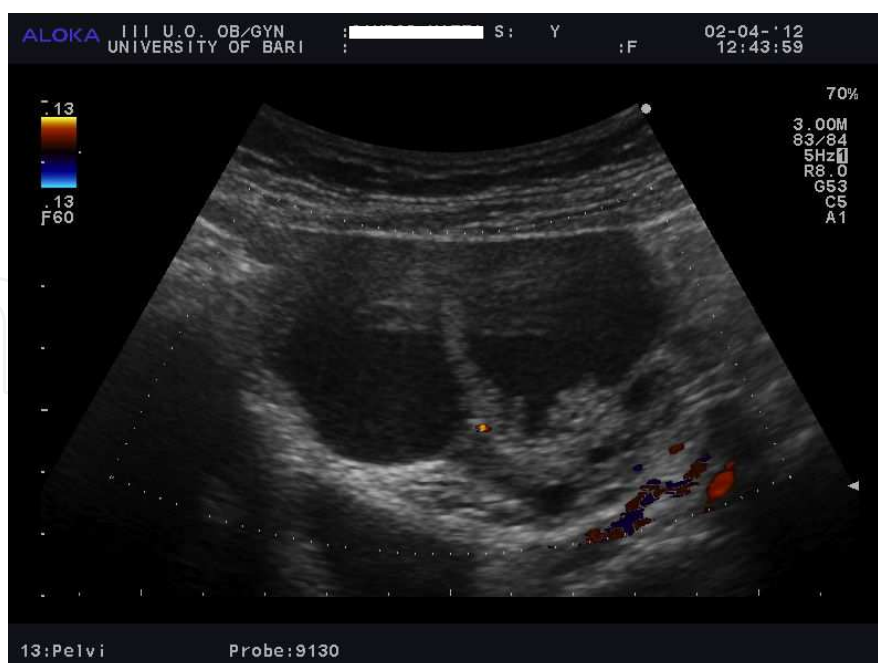

Figure 7. Cyst with septa in BOTs

The ovarian crescent sign is defined as the presence of healthy ovarian tissue adjacent to the cyst wall seen on the ultrasound images as an hypoechoic area with or without ovarian follicles that cannot be separated from the mass when applying pressure with the transvaginal probe; it has been shown that the presence of this sign can be used to exclude the diagnosis of invasive ovarian cancer. [47]

Yazbek et al demonstrated that the presence of papillae and crescent signs are suggestive of a serous or endocervical histotype while the presence of thick echogenic fluid and honeycomb nodules are suggestive of gastrointestinal histotype, moreover Exacoustos et al found that the serous types seem to be smaller than mucinous. [43, 45]

Yazbek et al conclude that the diagnosis of BOT with ultrasound can be achieved in 68.6%, more in serous or endocervical (75%) than in gastrointestinal histotype (60%). [45]

The role of Doppler ultrasound is still not clear in the diagnosis of BOTs, some authors found a difference in the resistance index and pulsatility index between BOT, benign tumors and invasive cancers, these indexes seem to gradually decrease with the grade of malignancy of the condition. [48, 49, 50]

Otherwise, Tekay et al found no statistically significant differences in the resistance and pulsatility indexes values between invasive, borderline and benign ovarian tumors. [51]

The vessel distribution within the tumor tissue has also been studied deeply but there are not still any clear conclusions, some authors demonstrated that BOT show similar vascular patterns to benign or malignant conditions. [42, 43, 49, 52]

Exacoustos et al found that the flow was present respectively in benign, borderline and malignant tumors in 80, 97 and 100% of cases and that usually a peripheral vascularization is

present mostly in benign masses, while intramural or intrapapillae flow is present mostly in borderline or malignant conditions. (Figure 8, 9) [43]

The study of the distribution of the flow or the resistance and pulsatility indexes cannot be considered effective neither in the differential diagnosis between the different histotypes. [53]

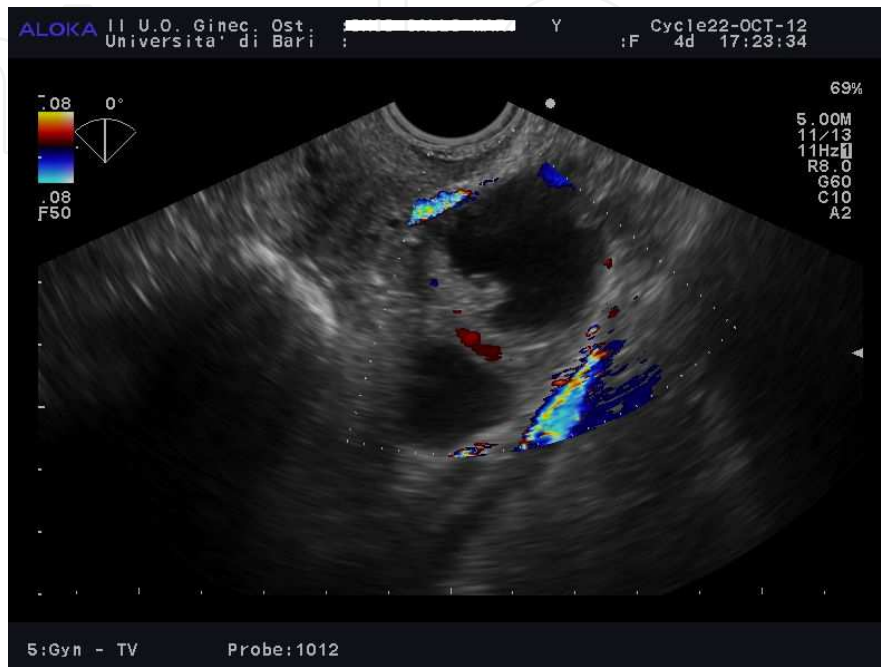


Figure 8. Flow distribution in BOTs

The use of contrast medium injected intravenously has been also suggested as a technique able to discriminate benign from borderline and malignant condition, a multicentre study including 10 cases of BOT and totally 89 patients with ovarian masses concluded that the use of second generation contrast agent like Sono Vue, Bracco, Netherland can be useful in the differential diagnosis between benign and malignant condition but not between borderline and benign ovarian masses. [54]

3.4. Computerized tomography, magnetic resonance and positron emission tomography

Computerized tomography seems not to discriminate BOT from malignant ovarian tumors, it can recognize the complex architecture of BOT, but the tissue contrast is limited so that it is not so clear the contrast between the solid and cystic components of these tumors; the role of CT scan is then mostly limited to detect the presence of metastases and to estimate the FIGO stage. [55, 56]

Magnetic Resonance is the best image technique to characterize borderline ovarian tumors. Bent et al described the appearance of BOT on MR images, and identified four morphological categories: unilocular cysts (19%), minimally septate cysts with papillae (19%), markedly septate lesions with plaque-like excrescences (45%) and predominantly solid with exophytic

papillary projections (16%); they also concluded that MRI can be helpful in the differential diagnosis of BOT and in surgical planning. [57]

In T1- and T2-weighted images BOTs solid tissues are usually intermediate in signal intensity and they demonstrate also enhancement after the administration of gadolinium-based contrast media. [57, 58, 59, 60] The enhancement pattern seems to be useful in the differential diagnosis between benign, borderline and invasive ovarian tumors. [61]

In a series of 168 ovarian masses (23 BOT) Bazot et al estimated that the sensitivity and specificity of MRI for the diagnosis of BOT are 45.5% and 96.1%, respectively. [62]

Positron emission tomography can increase the accuracy of other imaging techniques in the diagnosis of BOT.

Malignant cells use glucose to survive, for this reason invasive cancer are characterized on PET images by a higher uptake of 18F-fluorodeoxyglucose than both BOT and benign tumors that do not have a high glycolytic rate. [64, 65, 66, 67]

Nam et al investigated the role of combined 18F-fluorodeoxyglucose positron emission tomography/computerized tomography (FDG-PET/CT) and found that it can be more accurate than ultrasound, CT and MRI in the differential diagnosis between BOT, benign and malignant ovarian cancer. [68]

4. Treatment and follow up

Surgery represents the gold standard treatment and a complete surgical staging is mandatory and very important. Lin et al found out that only in 12% of cases the primary surgical stadiation is actually right. Moreover, BOTs are also difficult to diagnosed in frozen section, many apparent BOTs on frozen section are found to be frankly malignant in permanent sections (the correct diagnosis is achieved in 58-86%) of patients and it depends especially on the experience of the pathologists.

The surgical approach in the management of BOT is similar to the one used in the malignant forms and includes: total abdominal hysterectomy, bilateral salpingo-oophorectomy, omentectomy, peritoneal washings, and multiple biopsies, including pelvic and paraortic lymph nodes sampling for the stadiation.

In mucinous BOTs is strongly recommended to perform appendectomy and to carefully analyze the entire intestinal tract to exclude a gastrointestinal tumor.

Because of the excellent prognosis and the young age of these women the treatment is becoming always more conservative and fertility sparing surgery can be considered [69, 70], it consists in ovariectomy or simple cystectomy.

Because 15% of patients who undergone unilateral salpingo oophorectomy develop a primary tumor in the preserved ovary [13, 71] the conservative approach should be considered carefully. In all cases a carefully inspection of the capsule to find any sign of rupture should

be performed in case of fertility sparing surgery. Several reports suggest that the overall disease-specific survival rates between the radical and the fertility sparing surgical approaches are not different. [70, 72] Thus, it appears that young women who desire future fertility can be safely treated with fertility-sparing surgery without compromising their overall survival.

Barnhill DA et al suggested that a simple cystectomy should be performed only in selected cases if the tumor is in stage I, can be removed completely and is loosely attached. [73]

The contralateral ovary must be carefully macroscopically inspected, but performing a biopsy is not recommended in order to avoid the occurrence of adhesions that can affect the future fertility capacity of the patient. Some surgeon suggest to women with BOTs who had undergone fertility sparing surgery to complete the radical surgery after the completion of child-bearing.

BOTs in advanced stage should be treated with debulking surgery.

The role of adjuvant therapy is still not clear. At this time, there is no proven benefit from adjuvant therapy, even in advanced-stage disease and with the presence of invasive implants. [74]

Generally, in absence of invasive implants, watchful expectancy should be considered, while adjuvant chemotherapy (usually platin based chemotherapy) should be offered to patients with invasive implants, with the persistence of residual tumor after surgery and in clinically progressive disease.

The follow up of these patients must be performed for more than 10 years after the primary treatment since long term recurrence (even after 20 years) have been observed especially in women who underwent a conservative surgical approach. The follow up should include pelvic and gynecological examinations, ultrasound and measurement of serum markers.

5. Our experience: 55 cases

Fifty-five women with borderline ovarian tumors were identified at our institution from 1991 to 2011, median age at diagnosis was 40 years (range 13-79). The most common symptoms complained by patients at the moment of diagnosis were abdominal or pelvic pain and discomfort. The tumor diameter ranged between 0.5 and 10 cm and 5.4% of patients presented ascites at the time of diagnosis.

Only in the 47% patients, [26] tumor markers were evaluated before primary surgery, specifically CA125 was higher in 13 (23.6%), CA19.9 in 2 (3.6%) and 4 patients (7.3%) presented with both of these markers increased.

Our expert pathologist in Gynecological oncology pathology found 33 serous, 18 mucinous, 1 endometrioid and 3 mixed borderline ovarian tumors.

All women underwent surgery as primary treatment, 72.8% with laparotomic approach, whereas 13 women (23.6%) underwent a laparoscopic one; in particular 20 patients (36.4%) had a total abdominal hysterectomy with bilateral salpingo-oophorectomy, 2 patients (3.6%)

had a bilateral salpingo-oophorectomy with uterus sparing and the remaining 33 women [60%) performed a procedure strictly interested the ovary. Omentectomy was performed in 32 patients [58%) whereas para aortic lymph node dissection in only 1 patient and appendectomy in 17 patients (31%). Peritoneal biopsies were performed in 27 women (49%), peritoneal cytology in 29 cases (53%) and positive in only 2 (7%).

Forty-seven patients were in FIGO stage I (85.4%), most of these in IA stage (41 patients, 74.5%), 4 patients were in stage II (7.3%) and the last 4 patients in stage III (7.3%).

Fifty-four patients (98.2%) had no residual tumor after surgical procedure, while 1 patient (1.8%) had macroscopic residual tumor ≤ 2 cm in the ovary and peritoneal carcinomatosis.

After surgery only 2 patients (3.7%) were treated with adjuvant platinum-based combination chemotherapy for their stage IIC and IIIC; both patients achieved a complete response after treatment.

The other patients did not received any other treatment.

The median disease free survival and the 5-year survival rate of our patient population were 42 months (range 16-84) and 97%, respectively.

The statistical analysis performed with Kaplan Meier method and log rank test showed that the survival in patients who underwent fertility-sparing surgery did not differ from those who had a complete surgical staging ($p=0.08$). No significant differences were observed when comparing the different stages (Stage I-II vs Stage III; $p=0.7$), histological type (serous versus mucinous, endometrioid and mixed tumor; $p=0.15$), tumor size (> 10 cm vs < 10 cm; $p=0.39$), surgical approach (laparotomy vs laparoscopy; $p=0.56$), elevation of CA125 at diagnosis (positive vs negative marker; $p=0.55$).

Six patients developed a recurrence of the disease. All of them underwent a secondary laparotomy, four with a conservative approach and two with a complete surgical staging because of the presence of invasive implants. These two patients received then also chemotherapy. All the six women were alive with no evidence of disease with a median survival of 39 months.

We were able to obtain the fertility status of 16 patients who underwent a fertility-sparing surgery. Four of these women became pregnant and the rest of them had not a desire of childbearing at the time of their last follow up. One of these pregnancies was obtained by in vitro fertilization techniques, while the rest of them were spontaneous.

6. Conclusions

In conclusion, BOTs have an excellent prognosis of nearly 100% of survival rate.

Conservative fertility sparing surgery should be considered for women in the reproductive age group who desire preservation of fertility.

In any case, a long-term follow-up is highly recommended for these tumors because recurrences can occur several years after primary treatment.

Author details

Gennaro Cormio, Vera Loizzi, Maddalena Falagario*, Doriana Scardigno, Donatella Latorre and Luigi E. Selvaggi

*Address all correspondence to: mad.falagario@gmail.com

Department of Gynaecology, Obstetric and Neonatology, University of Bari, Italy

References

- [1] Taylor, H. Malignant and semi-malignant tumors of the ovary. *Surg Gynecol Obstet*, (1929). , 48, 204-230.
- [2] FIGO International Federation of Gynecology and Obstetrics. Classification and staging of malignant tumours in the female pelvis. *Acta Obstet Gynecol Scand* (1971). , 50, 1-7.
- [3] Tavassoli, F. A. Devilee P (eds). World Health Organization Classification of Tumours. Pathology and Genetics. Tumours of the Breast and Female Genital Organs. IARC Press: Lyon, (2003).
- [4] Russell, P. Surface epithelial-stromal tumors of the ovary. In: Kurman RJ (ed). *Blaustein's Pathology of the Female Genital Tract*, 4th edn. Springer-Verlag: New York, (1994). , 705-782.
- [5] Crispens, M. A. Borderline ovarian tumours: a review of the recent literature. *Curr Opin Obstet Gynecol*, (2003). , 15, 39-43.
- [6] Skirnisdottir, I, Garmo, H, Wilander, E, & Holmberg, L. Borderline ovarian tumors in Sweden 1960-2005: trends in incidence and age at diagnosis compared to ovarian cancer. *Int J Cancer*, (2008). , 123, 1897-1901.
- [7] Bostwick, D. G, Tazelaar, H. D, Ballon, S. C, Hendrickson, M. R, & Kempson, R. L. Ovarian epithelial tumors of borderline malignancy. A clinical and pathologic study of 109 cases. *Cancer*, (1986). , 58, 2052-2065.
- [8] Benedet, J. L, Bender, H, & Jones, H. rd, Ngan, H. Y., and Pecorelli, S. FIGO staging classifications and clinical practice guidelines in the management of gynecologic cancers. FIGO Committee on Gynecologic Oncology. *Int J Gynaecol Obstet*, (2000). , 70, 209-262.

- [9] Sherman, M. E, Mink, P. J, Curtis, R, Cote, T. R, Brooks, S, Hartge, P, & Devesa, S. Survival among women with borderline ovarian tumors and ovarian carcinoma: a population-based analysis. *Cancer*, (2004). , 100, 1045-1052.
- [10] DiSaia P, Creasman WT. The adnexal mass and early ovarian cancer. *Clinical Gynecologic Oncology*. Mosby Inc. 6th edn. Mosby Inc. USA, (2002). , 259-288.
- [11] Katzenstein, A. A, Mazur, M. T, Morgan, T. E, et al. Proliferative serous tumors of the ovary: histologic features and prognosis. *Am J Surg Pathol* (1978). , 2, 339-355.
- [12] Russell, P. The pathological assessment of ovarian neoplasms. I. Introduction to the common 'epithelial' tumours and analysis of benign 'epithelial' tumours. *Pathol* (1979). , 11, 5-26.
- [13] Kennedy, A. W, & Hart, W. R. Ovarian papillary serous tumors of low malignant potential (serous borderline tumors): a long term follow-up study, including patients with microinvasion, lymph node metastasis, and transformation to invasive serous carcinoma. *Cancer* (1996). , 78, 278-286.
- [14] Scully, R. E, Young, R. H, & Clement, P. B. Tumors of the ovary, maldeveloped gonads, fallopian tube, and broad ligament. In: Rosai J (ed). *Atlas of Tumor Pathology, Third Series, Fascicle 23*. Armed Forces Institute of Pathology: Washington, DC, (1998).
- [15] Hart, W. A. Borderline epithelial tumors of the ovary *Modern Pathology* ((2005). SS50. doi:10.1038/modpathol.3800307, 33.
- [16] Bell, D. A, & Scully, R. E. Ovarian serous borderline tumors with stromal microinvasion: a report of 21 cases. *Hum Pathol* (1990). , 21, 397-403.
- [17] Tavassoli, F. A. Serous tumor of low malignant potential with early stromal invasion (serous LMP with microinvasion). *Mod Pathol* (1988). , 1, 407-414.
- [18] Mckenney, J. K, Balzer, B. L, & Longacre, T. A. Ovarian serous tumors of low malignant potential with stromal microinvasion: a clinicopathologic study of 36 cases. *Mod Pathol* (2004). A-206A.
- [19] Prat, J, & De Nictolis, M. Serous borderline tumors of the ovary: a long-term follow-up study of 137 cases, including 18 with a micropapillary pattern and 20 with microinvasion. *Am J Surg Pathol* (2002). , 26, 1111-1128.
- [20] Eichhorn, J. H, Bell, D. A, Young, R. H, et al. Ovarian serous borderline tumors with micropapillary and cribriform patterns: a study of 40 cases and comparison with 44 cases without these patterns. *Am J Surg Pathol* (1999). , 23, 397-409.
- [21] Uzan, C, Berretta, R, Rolla, M, Gouy, S, Fauvet, R, Darai, E, & Duvillard, P. Morice P Management and prognosis of endometrioid borderline tumors of the ovary. *Surg Oncol*. (2012). Sep; 21(3), 178-84.
- [22] Uzan, C, Dufeu-lefevre, M, Fauvet, R, Gouy, S, Duvillard, P, Darai, E, & Morice, P. Management and prognosis of clear cell borderline ovarian tumor. *Int J Gynecol Cancer*. (2012). Jul; 22(6), 993-9.

- [23] Uzan, C, Dufeu-lefebvre, M, Fauvet, R, Gouy, S, Duvillard, P, Darai, E, & Morice, P. Management and prognosis of borderline ovarian brenner tumors. *Int J Gynecol Cancer*. (2012). Oct;; 22(8), 1332-6.
- [24] Goff, B. A, Mandel, L. S, Melancon, C. H, et al. (2004). Frequency of symptoms of ovarian cancer in women presenting to primary care clinics. *JAMA* , 291, 2705-2712.
- [25] Hamilton, W, Peters, T. J, Bankhead, C, et al. (2009). Risk of ovarian ancer in women with symptoms in primary care: population based case-control study. *BMJ* 339:b2998
- [26] Ranney, B, & Ahmad, M. I. (1979). Early identification, differentiation and treatment of ovarian neoplasia. *Int J Gynaecol Obstet* , 17, 209-218.
- [27] Eltabbakh, G. H, Yadav, P. R, & Morgan, A. (1999). Clinical picture of women with early stage ovarian cancer. *Gynecol Oncol* , 75, 476-479.
- [28] Vine, M. F, Ness, R. B, Calingaert, B, et al. (2001). Types and duration of symptoms prior to diagnosis of invasive or borderline ovarian tumor. *Gynecol Oncol Arch Gynecol Obstet* (2012) 285:1103-1112, 83, 466-471.
- [29] Webb, P. M, Purdie, D. M, Grover, S, et al. (2004). Symptoms and diagnosis of borderline, early and advanced epithelial ovarian cancer. *Gynecol Oncol* , 92, 232-239.
- [30] Olsen, C. M, Cnossen, J, Green, A. C, et al. (2007). Comparison of symptoms and presentation of women with benign, low malignant potential and invasive ovarian tumors. *Eur J Gynaecol Oncol* , 28, 376-380.
- [31] Lenhard, M. S, Nehring, S, Nagel, D, et al. (2009). Predictive value of CA 125 and CA 72-4 in ovarian borderline tumors. *Clin Chem Lab Med* , 47, 537-542.
- [32] Van Calster, B, Timmerman, D, Bourne, T, et al. (2007). Discrimination between benign and malignant adnexal masses by specialist ultrasound examination versus serum CA-125. *J Natl Cancer Inst* , 99, 1706-1714.
- [33] Rice, L. W, Lage, J. M, Berkowitz, R. S, et al. (1992). Preoperative serum CA-125 levels in borderline tumors of the ovary. *Gynecol Oncol* , 46, 226-229.
- [34] Tamakoshi, K, Kikkawa, F, Shibata, K, et al. (1996). Clinical value of CA125, CA19-9, CEA, CA72-4, and TPA in borderline ovarian tumor. *Gynecol Oncol* , 62, 67-72.
- [35] Gotlieb, W. H, Soriano, D, Achiron, R, et al. (2000). CA 125 measurement and ultrasonography in borderline tumors of the ovary. *Am J Obstet Gynecol* , 183, 541-546.
- [36] Kolwijck, E, Thomas, C. M, Bulten, J, et al. (2009). Preoperative CA-125 levels in 123 patients with borderline ovarian tumors: a retrospective analysis and review of the literature. *Int J Gynecol Cancer* , 19, 1335-1338.
- [37] Tempfer, C. B, Polterauer, S, Bentz, E. K, et al. (2007). Accuracy of intraoperative frozen section analysis in borderline tumors of the ovary: a retrospective analysis of 96 cases and review of the literature. *Gynecol Oncol* , 107, 248-252.

- [38] Darai, E, Teboul, J, Walker, F, et al. (1996). Epithelial ovarian carcinoma of low malignant potential. *Eur J Obstet Gynecol Reprod Biol* , 66, 141-145.
- [39] Engelen, M. J, De Bruijn, H. W, Hollema, H, et al. (2000). Serum CA125, carcinoembryonic antigen, and CA 19-9 as tumor markers in borderline ovarian tumors. *Gynecol Oncol* , 78, 16-2017.
- [40] Gotlieb, W. H, Soriano, D, Achiron, R, et al. (2000). CA 125 measurement and ultrasonography in borderline tumors of the ovary. *Am J Obstet Gynecol* , 183, 541-546.
- [41] Lenhard, M. S, Nehring, S, Nagel, D, et al. (2009). Predictive value of CA 125 and CA 72-4 in ovarian borderline tumors. *Clin Chem Lab Med* , 47, 537-542.
- [42] Pascual, M. A, Tresserra, F, Grases, P. J, et al. (2002). Borderline cystic tumors of the ovary: gray-scale and color Doppler sonographic findings. *J Clin Ultrasound* , 30, 76-82.
- [43] Exacoustos, C, Romanini, M. E, Rinaldo, D, et al. (2005). Preoperative sonographic features of borderline ovarian tumors. *Ultrasound Obstet Gynecol* , 25, 50-59.
- [44] Fruscella, E, Testa, A. C, Ferrandina, G, et al. (2005). Ultrasound features of different histopathological subtypes of borderline ovarian tumors. *Ultrasound Obstet Gynecol* , 26, 644-650.
- [45] Yazbek, J, Raju, K. S, Ben-nagi, J, et al. (2007). Accuracy of ultrasound subjective 'pattern recognition' for the diagnosis of borderline ovarian tumors. *Ultrasound Obstet Gynecol* , 29, 489-495.
- [46] Alca'zar JLerrasti T, Mi'nguez JA et al ((2001). Sonographic features of ovarian cystadenofibromas: spectrum of findings. *J Ultrasound Med* , 20, 915-919.
- [47] Yazbek, J, Aslam, N, Tailor, A, Hillaby, K, Raju, K. S, & Jurkovic, D. A comparative study of the risk of malignancy index and the ovarian crescent sign for the diagnosis of invasive ovarian cancer. *Ultrasound Obstet Gynecol* (2006). , 28, 320-324.
- [48] Wu, C. C, Lee, C. N, Chen, T. M, et al. (1994). Incremental angiogenesis assessed by color Doppler ultrasound in the tumorigenesis of ovarian neoplasms. *Cancer* , 73, 1251-1256.
- [49] Tepper, R, Lerner-geva, L, Altaras, M. M, et al. (1995). Transvaginal color flow imaging in the diagnosis of ovarian tumors. *J Ultrasound Med* , 14, 731-734.
- [50] Reles, A, Wein, U, & Lichtenegger, W. (1997). Transvaginal color Doppler sonography and conventional sonography in the preoperative assessment of adnexal masses. *J Clin Ultrasound* , 25, 217-225.
- [51] Zanetta, G, Lissoni, A, Cha, S, et al. (1995). Pre-operative morphological and colour Doppler features of borderline ovarian tumours. *Br J Obstet Gynaecol* , 102, 990-996.
- [52] Tekay, A, & Jouppila, P. (1992). Validity of pulsatility and resistance indices in classification of adnexal tumors with transvaginal color

- [53] Emoto, M, Udo, T, Obama, H, et al. (1998). The blood flow characteristics in borderline ovarian tumors based on both color Doppler ultrasound and histopathological analyses. *Gynecol Oncol* , 70, 351-357.
- [54] Testa, A. C, Timmerman, D, Van Belle, V, et al. (2009). Intravenous contrast ultrasound examination using contrast-tuned imaging(CnTI) and the contrast medium SonoVue for discrimination between benign and malignant adnexal masses with solid components. *Ultrasound Obstet Gynecol* , 34, 699-710.
- [55] Lalwani, N, Shanbhogue, A. K, Vikram, R, et al. (2010). Current update on borderline ovarian neoplasms. *AJR Am J Roentgenol* , 194, 330-336.
- [56] Buy, J. N, Ghossain, M. A, Sciote, C, et al. (1991). Epithelial tumors of the ovary: CT findings and correlation with US. *Radiology* , 178, 811-818.
- [57] Bent, C. L, Sahdev, A, Rockall, A. G, et al. (2009). MRI appearances of borderline ovarian tumours. *Clin Radiol* , 64, 430-438.
- [58] Desouza, N. M, Neill, O, & McIndoe, R. GA et al ((2005). Borderline tumors of the ovary: CT and MRI features and tumor markers in differentiation from stage I disease. *AJR Am J Roentgenol* , 184, 999-1003.
- [59] Bazot, M, Darai, E, Nassar-slaba, J, et al. (2008). Value of magnetic resonance imaging for the diagnosis of ovarian tumors: a review. *J Comput Assist Tomogr* , 32, 712-723.
- [60] Van Vierzen, P. B, Massuger, L. F, Ruys, S. H, et al. (1998). Borderline ovarian malignancy: ultrasound and fast dynamic MR findings. *Eur J Radiol* , 28, 136-142.
- [61] Thomassin-naggara, I, Bazot, M, Darai, E, et al. (2008). Epithelial ovarian tumors: value of dynamic contrast-enhanced MR imaging and correlation with tumor angiogenesis. *Radiology* , 248, 148-159.
- [62] Bazot, M, Nassar-slaba, J, Thomassin-naggara, I, et al. (2006). MR imaging compared with intraoperative frozen-section examination for the diagnosis of adnexal tumors; correlation with final histology. *Eur Radiol* , 16, 2687-2699.
- [63] Lapela, M, Leskinen-kallio, S, Varpula, M, et al. (1995). Metabolic imaging of ovarian tumors with carbon-11-methionine: a PET study. *J Nucl Med* , 36, 2196-2200.
- [64] Grab, D, & Flock, F. Stoehr I et al ((2000). Classification of asymptomatic adnexal masses by ultrasound, magnetic resonance imaging, and positron emission tomography. *Gynecol Oncol* , 77, 454-459.
- [65] Rieber, A, Nuessle K, Stoehr I et al ((2001). Preoperative diagnosis of ovarian tumors with MR imaging: comparison with transvaginal sonography, positron emission tomography, and histologic findings. *AJR Am J Roentgenol* , 177, 123-129.
- [66] Ju, W, & Kim, S. C. (2007). Discrepancy between magnetic resonance and ¹⁸F-fluorodeoxyglucose positron emission tomography imaging in a case of borderline ovarian tumor. *Int J Gynecol Cancer* , 17, 1031-1033.

- [67] Yamamoto, Y, Oguri, H, Yamada, R, et al. (2008). Preoperative evaluation of pelvic masses with combined 18F-fluorodeoxyglucose positron emission tomography and computed tomography. *Int J Gynaecol Obstet* , 102, 124-127.
- [68] Nam, E. J, Yun, M. J, Oh, Y. T, et al. (2010). Diagnosis and staging of primary ovarian cancer: correlation between PET/CT, Doppler US, and CT or MRI. *Gynecol Oncol* , 116, 389-394.
- [69] Morice, P, Camatte, S, El Hassan, J, Pautier, P, Duvillard, P, & Castaigne, D. Clinical outcomes and fertility after conservative treatment of ovarian borderline tumors. *Fertil Steril*, (2001). , 75, 92-96.
- [70] Morris, R. T, Gershenson, D. M, Silva, E. G, Follen, M, Morris, M, & Wharton, J. T. Outcome and reproductive function after conservative surgery for borderline ovarian tumors. *Obstet Gynecol*, (2000). , 95, 541-547.
- [71] Bostwick, D. G, Tazelaar, H. D, Ballon, S. C, et al. Ovarian epithelial tumors of borderline malignancy: a clinical and pathologic study of 109 cases. *Cancer* (1986). , 58, 2052-2065.
- [72] Tazelaar, H. D, Bostwick, D. G, Ballon, S. C, Hendrickson, M. R, & Kempson, R. L. Conservative treatment of borderline ovarian tumors. *Obstet Gynecol*, (1985). , 66, 417-422.
- [73] Barnhill, D. A, Kurman, R. J, Brady, M. F, et al. Preliminary analysis of the behavior of stage I ovarian serous tumors of low malignant potential: a Gynecologic Oncology Group study. *J Clin Oncol* (1995). , 13, 2752-2756.
- [74] Trope, C, Kaern, J, Vergote, I. B, Kristensen, G, & Abeler, V. Are borderline tumors of the ovary overtreated both surgically and systemically? A review of four prospective randomized trials including 253 patients with borderline tumors. *Gynecol Oncol*, (1993). , 51, 236-243.

IntechOpen