

# We are IntechOpen, the world's leading publisher of Open Access books Built by scientists, for scientists

4,800

Open access books available

122,000

International authors and editors

135M

Downloads

Our authors are among the

154

Countries delivered to

TOP 1%

most cited scientists

12.2%

Contributors from top 500 universities



WEB OF SCIENCE™

Selection of our books indexed in the Book Citation Index  
in Web of Science™ Core Collection (BKCI)

Interested in publishing with us?  
Contact [book.department@intechopen.com](mailto:book.department@intechopen.com)

Numbers displayed above are based on latest data collected.  
For more information visit [www.intechopen.com](http://www.intechopen.com)



---

# **Subtalar Arthroscopy and a Technical Note on Arthroscopic Interosseous Talocalcaneal Ligament Reconstruction**

---

Jiao Chen, Hu Yuelin and Guo Qinwei

Additional information is available at the end of the chapter

<http://dx.doi.org/10.5772/55112>

---

## **1. Introduction**

### **1.1. History of subtalar arthroscopy**

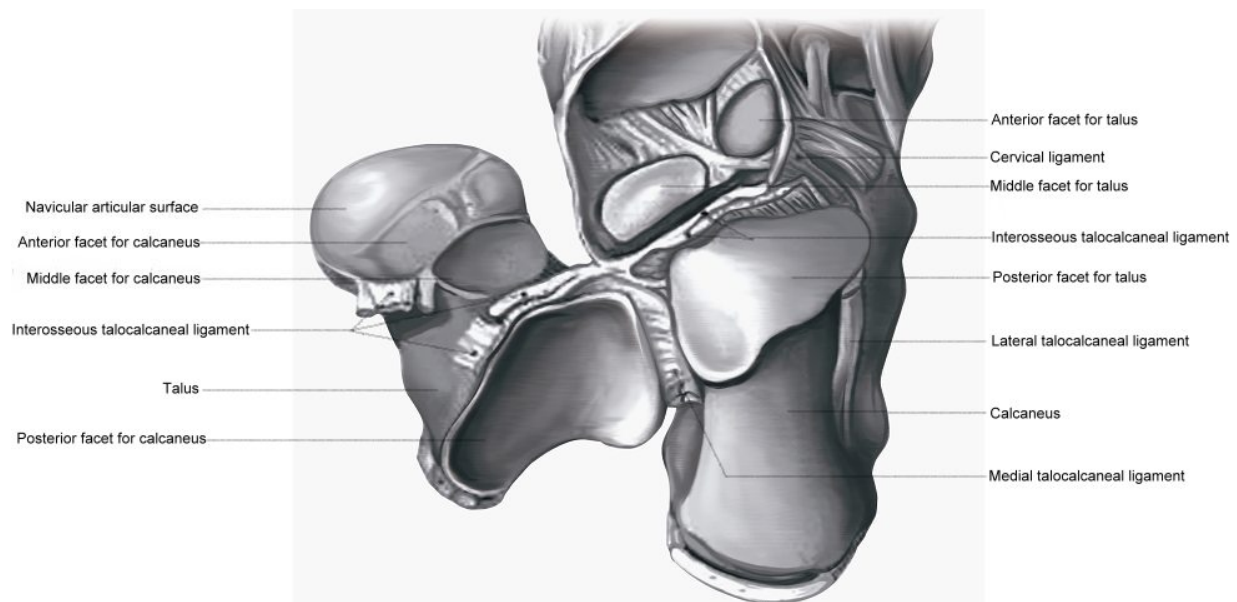
The history of arthroscopy can be traced back to 1912 when the Danish physician Severin Nordentoft reported on arthroscopies of the knee joint at the Proceedings of the 41st Congress of the German Society of Surgeons at Berlin [1]. Till seventy three years later was the first article on subtalar arthroscopy published in which Parisien did a cadaver study and introduced the arthroscopic approaches in detail[2]. Frey C compared three portals of subtalar arthroscopy on visualization area and safety in an article published in 1994[3]. Lundeen described ankle and subtalar joint fusion under arthroscopy in the same year[4]. Afterwards, as the advance of surgical technique many diseases can be treated under subtalar arthroscopy. However, to observe all structures in subtalar joint is still not easy and more efforts should be made to improve the subtalar arthroscopy technique.

## **2. Anatomy of subtalar joint**

The subtalar joint is comprised of two articulations: anterior subtalar joint and posterior subtalar joint divide by the sinus tarsi and tarsal canal. The anterior subtalar joint is formed by posterior facet of the navicular, convex head of the talus, oval and slightly convex middle talar facet, anterior and middle facets of the superior surface of os calcis. The floor of the joint is formed by the plantar surface of the talar head with the dorsal surface of the spring ligament. This articulation is also called the talocalcaneonavicular joint[5]. The posterior subtalar joint

is posterior talocalcaneal joint consisting of the inferior posterior facet of the talus and the superior posterior facet of the calcaneus, the axis of which runs obliquely forwards, downwards and outwards. The subtalar joint produces movement of supination which is composed of plantarflexion in the parasagittal plane, inversion in the frontal plane, and adduction in the transverse plane and pronation which is composed of eversion in the frontal plane, abduction in the transverse plane, and dorsiflexion in the parasagittal plane[6,7].

Between anterior and posterior subtalar articulations lies the sinus tarsi laterally and tarsal canal medially. Two separate groups of ligament structures lie in the sinus tarsi and tarsal canal. The lateral group of ligament structures in sinus tarsi includes lateral and intermediate root of the inferior extensor retinaculum. The medial group of ligament structures in tarsal canal consists of medial root of the inferior extensor retinaculum, cervical ligament and interosseous talocalcaneal ligament (ITCL). The ITCL originates from the sinus calcanei, orients proximally and medially and inserts into the sulcus of the talus. It is composed of two bands. The anterior band orients in an oblique direction from the sinus calcanei anteriorly to the inferior talar neck while the posterior band attached to the posterior sinus tali. This ligament contributes to the subtalar supination stability[5]. The cervical ligament inserts on the calcaneus anterior to the posterior talocalcaneal joint, goes posteromedially and ends on the talar external border of the tarsal canal. It also contributes to the subtalar stability. (Figure 1)



**Figure 1.** The subtalar joint

### 3. Indication and contraindication

The diagnostic indications of subtalar arthroscopy include persistent pain, swelling, catching, locking or instability resistant to conservative treatment. The therapeutic indications include chondromalacia, osteoarthritis, osteochondral lesions, synovitis, plica syndrome, loose body, ligament injury and posterior impingement syndrome of the hindfoot.

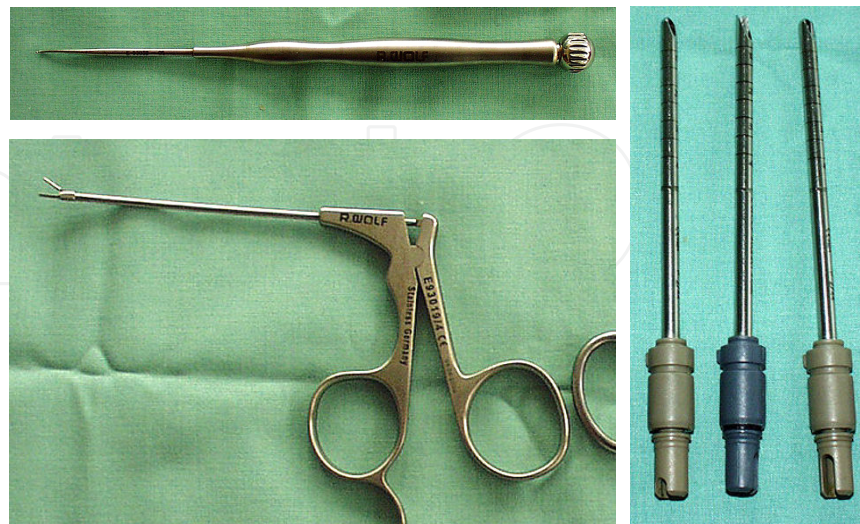
The absolute contraindications include localized infection, as well as severe degenerative joint disease or deformity. The relative contraindications include arthrofibrosis with severely narrow joint space, poorly vascularized extremity and neuropathic joint disease. Severe edema mentioned as a relative contraindication in previous literatures[8] has not been a contraindication yet since portals are not difficult to make by experienced arthroscopists even without obvious bony landmarks.

### 4. Surgical technique of subtalar arthroscopy

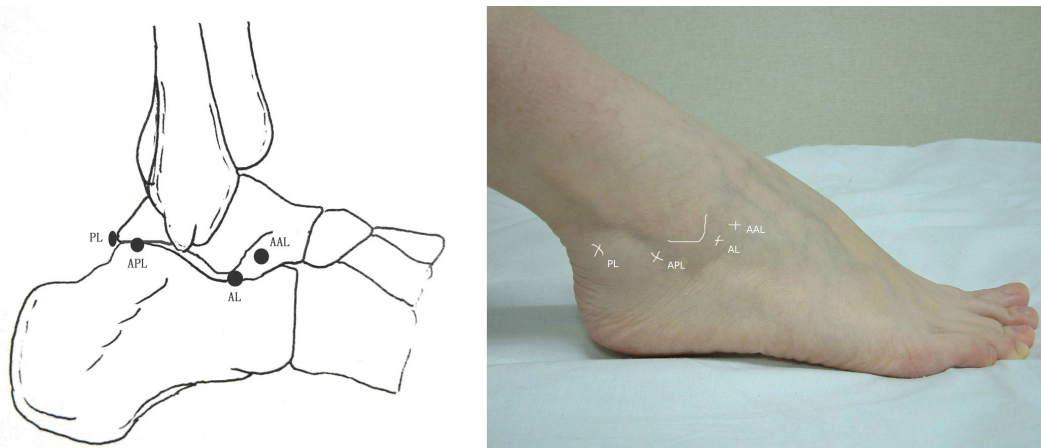
The instrument used for subtalar arthroscopy is similar to that used in ankle joint. Usually a 30° 2.7mm arthroscopy is used for subtalar joint. A 30° 1.9mm arthroscopy is used in some cases with tight joints and 4.0mm arthroscopy can be used in those with large joints. 2.9mm shaver and burr are routine instruments for subtalar arthroscopy. Small punch and probe should be also available. Other instruments such as small curette and microfracture device are optional. (Figure 2)

Supine position with elevation of pelvic region by a cushion and general or local anesthesia are usually used. The tourniquet is applied to the proximal thigh and inflated under pressure of 250mmHg to 350mmHg. Distraction belt is used in all patients. Bony distraction is seldom used except for small joints.

Initially the subtalar joint is distended by injection of normal saline in the subtalar joint using the anterolateral portal. Two anterolateral portals and two posterolateral portals are used for subtalar arthroscopy. The anterolateral (AL) portal is at 1cm distal and 2cm anterior to the fibular tip. The anterior anterolateral (AAL) portal is at 3cm anterior to the fibular tip. The posterolateral (PL) portal is at 0.5cm proximal to the fibular tip and just lateral to the Achilles tendon. The other portal is anterior posterolateral (APL) portal which is between the AL portal and the PL portal just behind peroneal tendons. After distending the joint the AL portal is firstly made for arthroscopic exploration with skin incision and subcutaneous separated bluntly. The AAL portal is then made for instrument placing. After exploring the joint from the AL portal arthroscopy is switched to the PL portal for further exploring the posterior part of the subtalar joint. Frey et al[3] reported that the best portal combination for access to the cartilaginous posterior facet of the subtalar joint involved placing the arthroscope through the AAL portal and the instrumentation through the PL portal. This allows directly visualization and instrumentation of nearly the entire surface of the posterior facet and involved contents. (Figure 3)



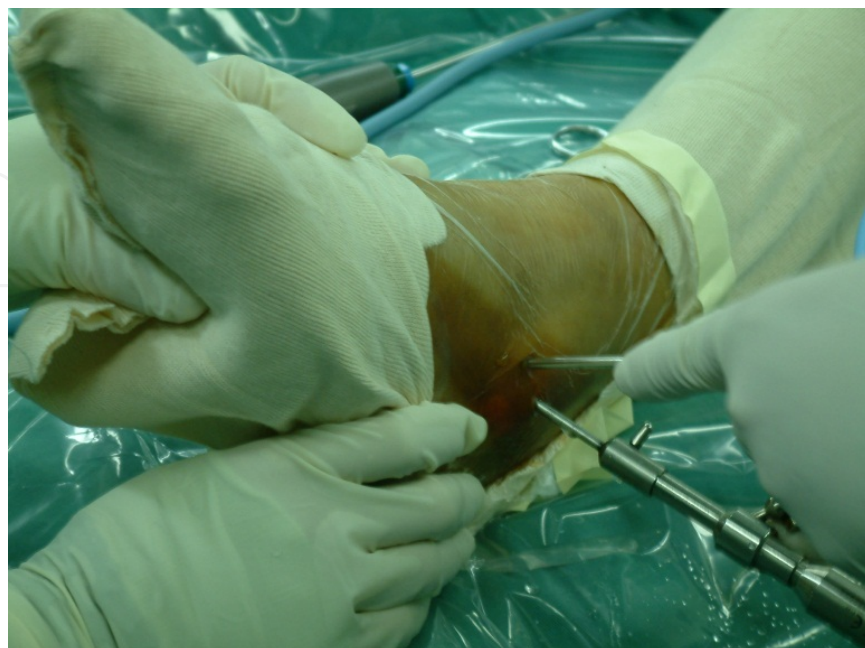**Figure 2.** Instruments for subtalar arthroscopy (small probe, punch, shaver & burr)



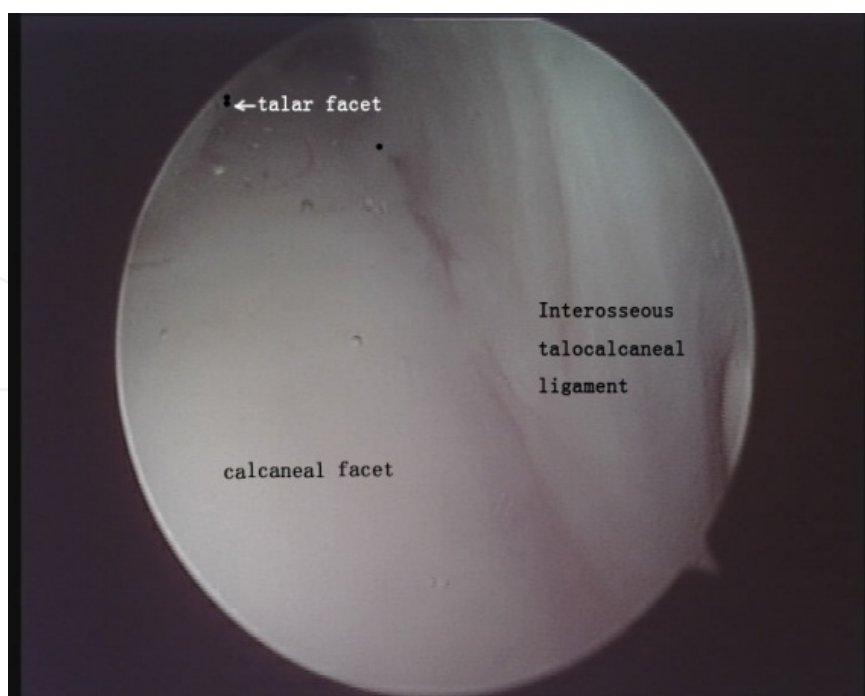**Figure 3.** Portals for subtalar arthroscopy

The exploration starts from insertion of arthroscope through the AAL portal and placing probe through the AL and PL portals. The posterior subtalar joint is explored in the order of deep interosseous ligament, superficial interosseous ligament, anterolateral corner, lateral gutter and the central articulation. Arthroscope is then switched to the PL portal and the probe is placed through the AL and AAL portals. Exploration is done in the order of interosseous talocalcaneal ligament anteriorly, anterolateral corner, lateral gutter, posterior gutter, posteromedial gutter, posteromedial corner and the posterior aspect of the talocalcaneal joint. (Figure 4~Figure 5)

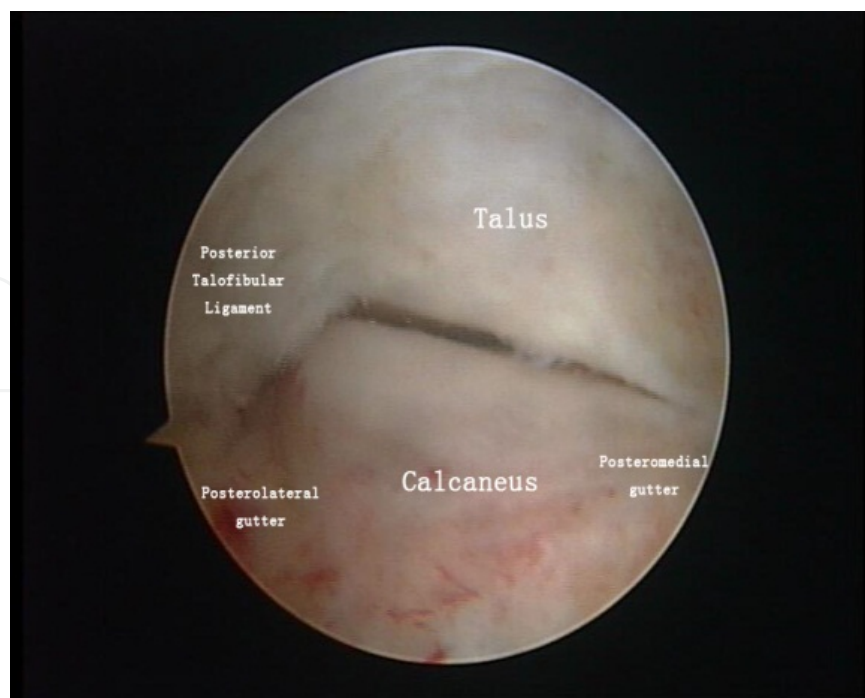




**Figure 4.** Insertion of arthroscopy



**Figure 5.** Subtalar joint under arthroscopy (View from the AL portal)



**Figure 6.** Subtalar joint under arthroscopy (View from the PL portal)

Therapeutic manipulation is done following exploration. Cartilage debridement, microfracture or loose body removal is performed for chondromalacia, osteoarthritis or osteochondral lesions. Synovectomy is performed for synovitis or plica syndrome. Os trigonum resection is done for posterior impingement syndrome of the hindfoot. The surgical technique refers to relative chapters on the knee and the ankle. The ligament reconstruction for subtalar instability (ITCL rupture) is described in detail below.

## 5. Surgical technique of Interosseous talocalcaneal ligament reconstruction

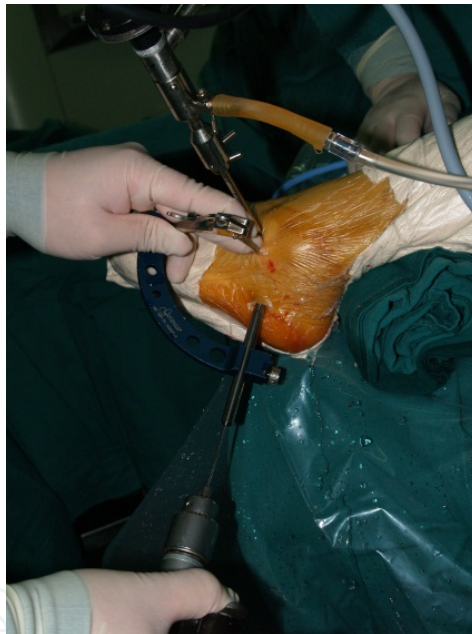
The ITCL is the main soft tissue stabilizer of the subtalar joint. Rupture of the ITCL can be associated with ankle sprains especially when combined with subtalar dislocation. Patients with chronic injury of the ITCL have symptoms of pain and swelling located in the tarsal sinus and instability of the hindfoot. Although relatively uncommon, and probably underreported in the literature, such problems were sometimes misdiagnosed as sinus tarsi syndrome. Now with an improved understanding of anatomy and function of the ITCL and the development of radiological diagnostic techniques, the differences between these two types of disease are apparent.

Physical examinations are critical for diagnosis of the ITCL injury. The anterior drawer test<sup>[9]</sup> of the subtalar joint was positive in patients with the ITCL injury when the affected foot was compared to the uninjured foot. We also designed calcaneal transverse slide test and calcaneal tilt test for diagnosis. The calcaneal transverse slide test is performed with one hand fixing the talus and the other hand pulling the calcaneus transversely to feel a slide between two bones.

The calcaneal tilt test is performed in the same way to feel inversion of the calcaneus “and opening up” on the lateral side of the subtalar joint.

The stress radiograph to measure the displacement of the calcaneus against the talus and subtalar tilt angle is more reliable<sup>[10,10,11]</sup>. However, the instrument used and standard for diagnosis differed among literatures. The ITCL can be clearly observed on MRI which is valuable for diagnosis and assessment in follow-up.

The surgical technique was designed in 2008<sup>[12]</sup>. The arthroscopy is performed with the patient in supine position and under general or spinal anaesthesia. The hip of affected side is lifted with internally rotation of the tibia. A thigh tourniquet was then inflated with pressure of 300mmHg. An AAL portal and an AL portal are established initially. The subtalar joint is then explored under arthroscopy. Rupture of ITCL and the remnant of the ligament can be observed. The calcaneal transverse slide test and the calcaneal tilt test are more obvious under arthroscopy. The articulation is explored under arthroscopy. Cartilage injury and synovitis can be treated simultaneously. The remnant of the ITCL is removed.

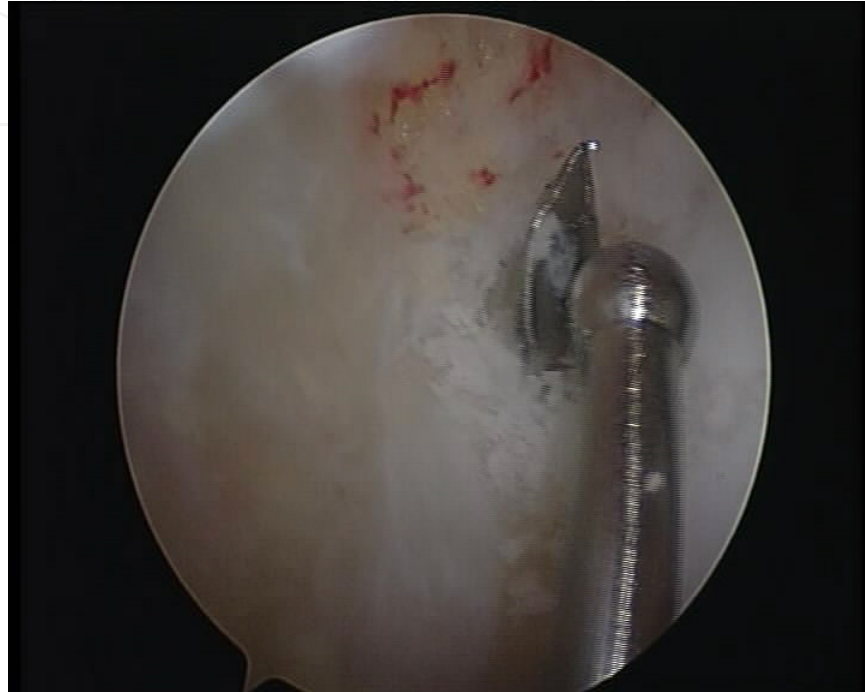


**Figure 7.** Making the calcaneal under arthroscopy

Before drilling the positions of bone tunnels are marked with radiofrequency. The anterolateral portal and the lower anteromedial portal are made in ankle for aiming of the outer exit of the bone tunnel of the talus. Two tunnels, 4.5 mm in diameter, are made in the talus and the calcaneus with the aimer (Figure 7 to Figure 10). The talar tunnel is located at the foot print of the ITCL medial to the anterior-lateral corner of the posterior facet and drilled toward the superomedial corner of the talar neck. The calcaneal tunnel is located at the remnant of the calcaneal root of the ITCL at a sulcus medial to the anterolateral corner of the posterior subtalar facet of the calcaneus and drilled toward the lateral side of calcaneus. A gracilis tendon is obtained from the ipsilateral knee. It is trimmed and sutured to double-bundle with 4mm to



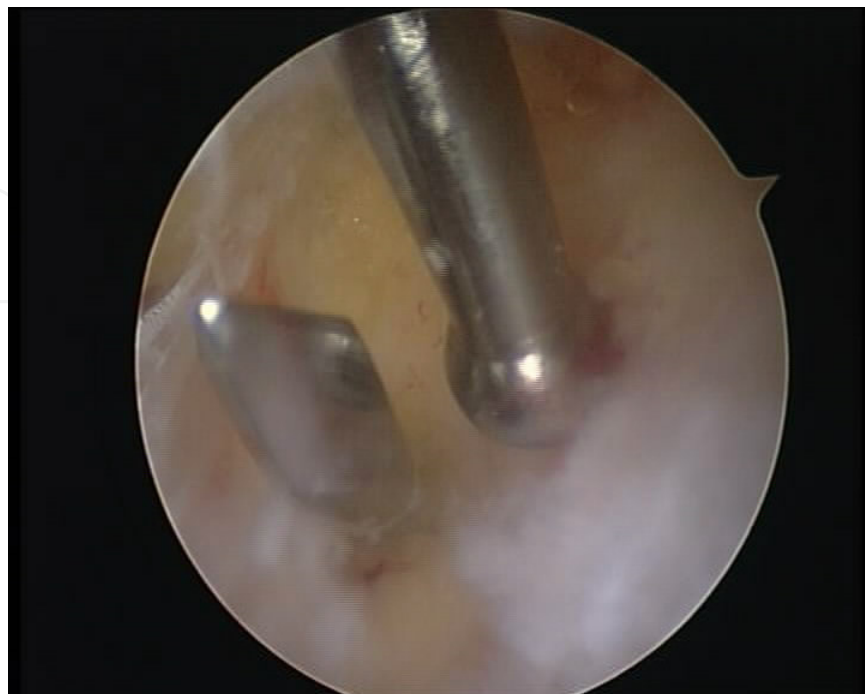
4.5mm in diameter and about 10 cm in length. No.2 polyester sutures were placed at each end. This double-strand ligament is passed through two bone tunnels and fixed with two 4.5mm Bio-Corkscrew suture anchors (Arthrex) in the bone tunnels as interference screws under arthroscopy while the foot is held in a neutral position (Figure 11 and Figure 12). The negative instability exams are performed at the end of operation under arthroscopy and manually.



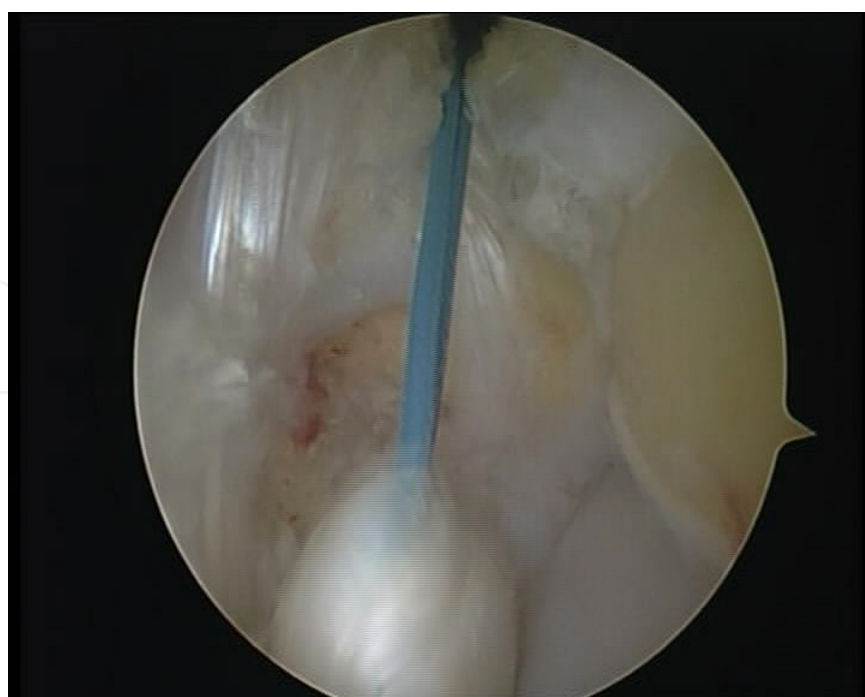
**Figure 8.** Making the calcaneal bone tunnel bone tunnel



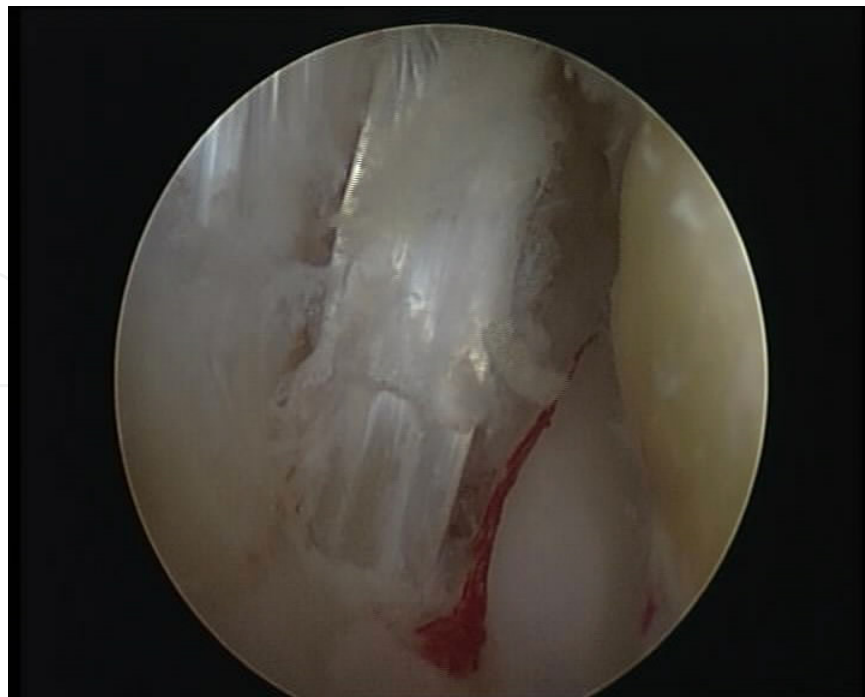**Figure 9.** Making the talar bone tunnel under arthroscopy



**Figure 10.** Making the talar bone tunnel



**Figure 11.** The gracilis tendon passing through bone tunnels



**Figure 12.** Reconstructed ITCL

## 6. Complication

The dorsal branches of superficial peroneal nerve, the third peroneus and the small saphenous vein located near the AAL portal can be injured when making the portal. The sural nerve and peroneal tendons can be injured when the APL portal is made. The Achilles tendon are probably injured when doing the PL portal. There is no severe complication for subtalar arthroscopy.

## 7. Postoperative rehabilitation

After subtalar arthroscopy the hindfoot is compressed with an elastic bandage or a cotton splint for two days. Then, half weight bearing and range of motion (ROM) exercise starts. Full weight bearing begins 2 weeks after surgery. The ROM exercise completes in four weeks. Patients return to daily life and sports 6 to 8 weeks after operation.

After the ITCL reconstruction the hindfoot is immobilized in a compressive cotton splint for 3 days. After removal of this dressing a hindfoot brace is applied with the foot in neutral position for 8 to 10 weeks. The ROM exercise is encouraged a week after surgery. Partial weight bearing begins 6 weeks after operation and full weight bearing is encouraged at 8 weeks. Patients return to normal ROM and walking 3 months after the operation and return to sports 6 to 9 months after the operation.

## Author details

Jiao Chen, Hu Yuelin and Guo Qinwei

Institute of Sports Medicine, Peking University Third Hospital, China

## References

- [1] Kieser, C. W, & Jackson, R. W. SeverinNordentoft: The first arthroscopist". *Arthroscopy* (2001). , 17(5), 532-535.
- [2] Parisien, J. S, & Vangsness, T. Arthroscopy of the subtalar joint- An experimental approach. *Arthroscopy* (1985). , 1(1), 53-57.
- [3] Frey, C, Gasser, S, & Feder, K. Arthroscopy of the subtalar joint. *Foot ankle int* (1994). , 15(8), 424-428.
- [4] Lundeen, R. O. Arthroscopic fusion of the ankle and subtalar joint.*ClinPodiatr Med Surg* (1994). , 11(3), 395-406.
- [5] Sizer, P. S. jr., Phelps P, James R, Matthijs O. Diagnosis and management of the painful ankle/foot part 1: Clinical anatomy and pathomechanics. *Pain Practice* (2003). , 3(3), 238-262.
- [6] Leardini, A, Stagni, R, & Conner, O. JJ. Mobility of the subtalar joint in the intact ankle complex. *J Biomech.*(2001). , 34(6), 805-809.
- [7] Astrom, M, & Arvidson, T. Alignment and joint motion in the normal foot. *J Orthop Sports PhysTher.* (1995). , 22(5), 216-222.
- [8] Williams, M. M, & Ferkel, R. D. Subtalar arthroscopy: indications, technique and results. *Arthroscopy* (1998). , 14(4), 373-381.
- [9] Kato T: The diagnosis and treatment of instability of the subtalar joint *J Bone Joint Surg Br.*(1995). , 77(3), 400-406.
- [10] Heilman, A. E, Braly, W. G, Bishop, J. O, et al. An anatomic study of subtalar instability. *Foot ankle.*(1990).
- [11] Yamamoto, H, Yagishita, K, Ogiuchi, T, et al. Subtalar instability following lateral ligament injuries of the ankle. *Injury.*(1998). , 29(4), 265-268.
- [12] Liu, C, Jiao, C, Hu, Y, et al. Interosseous talocalcaneal ligament reconstruction with hamstring autograft under subtalar arthroscopy: case report. *Foot Ankle Int* (2011). , 32(11), 1089-1094.

