

# We are IntechOpen, the world's leading publisher of Open Access books Built by scientists, for scientists

**4,800**

Open access books available

**122,000**

International authors and editors

**135M**

Downloads

Our authors are among the

**154**

Countries delivered to

**TOP 1%**

most cited scientists

**12.2%**

Contributors from top 500 universities



**WEB OF SCIENCE™**

Selection of our books indexed in the Book Citation Index  
in Web of Science™ Core Collection (BKCI)

Interested in publishing with us?  
Contact [book.department@intechopen.com](mailto:book.department@intechopen.com)

Numbers displayed above are based on latest data collected.

For more information visit [www.intechopen.com](http://www.intechopen.com)



---

# **Dermatology in Dogs and Cats**

---

Elisa Bourguignon, Luciana Diegues Guimarães,  
Tássia Sell Ferreira and Evandro Silva Favarato

Additional information is available at the end of the chapter

<http://dx.doi.org/10.5772/53660>

---

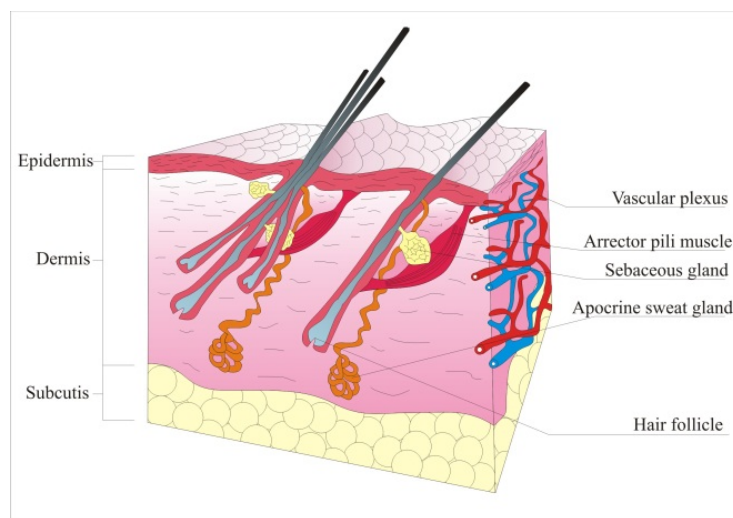
## **1. Introduction**

The skin is the largest organ of the body with many different functions as thermoregulation, immune protection, sensory perception, vitamin D production and it acts as a barrier between the animal and the environment. Besides all of these important functions and the diseases that affect directly the skin, it may also share or reflect pathologic processes from other tissues. Due to these characteristics, dermatologic problems are among the most commonly seen disorders in veterinary hospitals. It is important for the veterinarian to know and understand about the physiology of the skin and about the most common dermatologic disorders that affects dogs and cats, which will be addressed in this chapter.

## **2. Skin structure**

The skin is divided in three layers: epidermis, dermis and hypodermis (Figure 1). Epidermis, the outermost layer of the skin, is composed by keratinocytes, melanocytes and Langerhans cells. Keratinocytes are also disposed in layers in the epidermis. The deepest one, the stratum basale, is formed by a single row of germinative keratinocytes and also contains melanocytes. These germinative keratinocytes generate the other layers by cell division and differentiation. The next layer, stratum spinosum, differs from stratum basale by the presence of intercellular junctions. Langerhans cells are also present in this layer. Stratum granulosum is characterized by a large amount of keratohyaline granules inside keratinocytes which are important in the skin keratinization process. Stratum corneum, the outer epidermis layer, is composed by keratinocytes in their maximal differentiation degree (corneocytes), interspersed in lipid matrix [1].

Dermis, the layer under the epidermis, is composed by a conjunctive matrix where reticular, elastic and collagen fibers are found. Dermis cellular structure is composed by fibroblasts, mast cells and histiocytes. It also contains epidermal appendages (hair, nails, sebaceous and sweat glands), arrector pili muscles and blood and lymph vessels. Hypodermis or subcutaneous tissue provides support and cushioning against physical trauma. It is composed by a loose connective tissue and elastic fibers interspersed by adipocytes [1]. The hair follicles exhibit activity cycles that result in hair formation. Anagen is a period of active growth when a new hair is being formed. Catagen is when the hair growth stops and degenerative changes occur in the base of the follicle. Telogen represents a period of follicle inactivity, when the hair is shed so that a new one may start to grow [1]. Hair cycle activity, in some dog breeds, is strongly related to temperature variation and photoperiod, leading to decreased hair density in the warmer months, which helps the heat loss in these animals [2].



**Figure 1.** Structure of the skin.

### 3. Diagnosis techniques

Diagnosis approach for skin diseases depends on obtaining detailed history with thorough physical and dermatological examination. The evaluation offers precious information and guides the investigative process. Specific tests and, occasionally, therapeutic trials should be performed [3].

Skin scrapings, trichogram, fungal and bacterial culture, cytological evaluation and skin biopsy are important diagnosis techniques in dermatology. Skin scrapings are applied in mite detection, and it may be superficial or deep depending on the mite that is suspected. The sample obtained is evaluated under optical microscopy [3]. Fungal culture is recommended for patients that fungal diseases are suspected. Hair samples and skin scales should be collected from the lesion margin. Bacterial culture is not often performed and it is recommend-

ed in pyoderma refractory to initial therapy or when rods are observed in cytology [4]. The direct examination of the hairs, the trichogram, is performed by pulling the hairs from the affected area, followed by microscopic evaluation. With this technique it is possible to determine hair growth phase abnormalities and the presence of follicles parasites and dermatophytes [3]. Cytology is the analysis of tissue cells and it is a highly efficient and valuable exam to evaluate a lesion, after which it is possible to establish the next step in the diagnostic approach. The sample may be obtained by fine-needle aspiration, swab, skin scrapings or lesion imprint [5]. Histopathology associated with clinical findings usually leads to definitive diagnosis. Skin biopsy is recommended in unusual lesions, possibly neoplastic nodules, dermatosis with expensive therapy or when it represents a risk to the patient health, with poor response to previous therapy and to exclude differential diagnoses [4]. To perform the histopathological exam at least three representative samples should be obtained by punch or surgical resection [3].

#### 4. Bacterial skin diseases

Pyoderma is a bacterial skin infection and it is among the most common causes of skin diseases in dogs [6], however, it is less common in cats [7]. Lesions may be superficial and involve only the epidermis or they may affect deeper structures in the dermis or subcutaneous tissue, and it is therefore divided into surface, superficial and deep pyoderma [6]. *Staphylococcus pseudintermedius* is the most commonly isolated bacteria from dog's skin [8] and it is among the main reasons for antimicrobial use in these animals [9].

Surface pyodermas are characterized by superficial erosions of the stratum corneum. The presence of alopecia, erythema and pruritus are common findings [10]. Intertrigo is a surface pyoderma that affects the skin folds found in lips, face, vulva, tail and mammary glands of some breeds, and it may also affect the skin folds of obese animals. Acute moist dermatitis, also known as pyotraumatic dermatitis or hot spots, is of acute onset and rarely occurs as a primary disease in healthy skin, being usually secondary to other diseases [11]. Probably, local irritation due to an underlying cause leads to self-inflicted trauma, which quickly becomes extensive areas of skin damage [10].

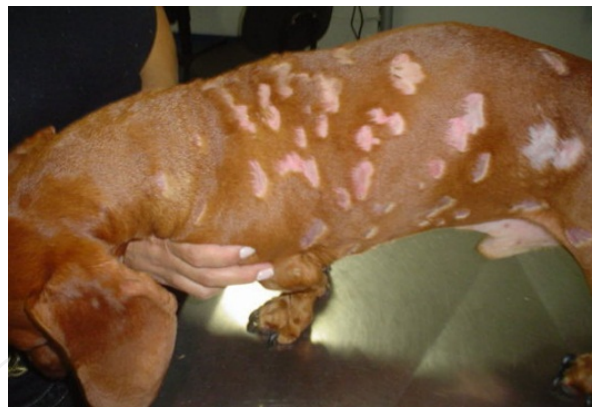Superficial pyodermas are the most common causes of cutaneous bacterial infection in dogs [6]. They affect the superficial portion of the hair follicles (bacterial folliculitis) or the epidermis (impetigo), causing pustules [10, 11]. The most common lesions are crusted papules due to the transient nature of canine pustules. Pruritus, epidermal collarettes, hyperpigmentation and alopecia are also common findings [6]. Impetigo affects sexually immature dogs that may present subcorneal pustules formed in inguinal and axillary areas [10]. Superficial bacterial folliculitis is the most common form of pyoderma in dogs [12]. Papules, pustules associated with hair follicles, epidermal collarettes, alopecia and hyperpigmentation are commonly found [10] (Figure 2).

Deep pyoderma does not occur spontaneously, often starting as superficial pyoderma [6]. Other organisms such as *Proteus* spp., *Pseudomonas* spp. and *E. coli* may be involved [12-14].

The bacterial infection affects the deepest portion of the hair follicle (deep folliculitis), that may lead to follicular wall rupture and to bacterial product release in the dermis (furunculosis), or it can also affect the deeper portion of the dermis and subcutaneous tissue (cellulitis) [10, 15]. The affected skin appears erythematous, hyperpigmented, with the presence of seropurulent debris from the ruptured pustules; variable pruritus, swelling, skin stiffness and evident pain are also noted [6].

Diagnosis is obtained through the evaluation of clinical signs, presence of characteristic skin lesions, elimination of other possible causes of folliculitis and by cytological evaluation of the intact pustules content, exudative lesions and skin debris. In the management of pyoderma, it is important to identify the possible underlying disorder, which may be done through skin scrapings, scabies therapeutic trial, allergy tests, endocrinopathies screenings, hypoallergenic diet trials, strict ectoparasites control and skin biopsies. [16].

The treatment varies depending on presented lesions. Local surface and superficial pyodermas may be treated only with topical antibiotics such as silver sulphadiazine, neomycin or 2% mupirocin ointments applied twice daily over the affected areas. Generalized lesions and deep pyodermas require a combination of oral and topical antibiotics. In patients with severe pruritus it is recommended to use anti-inflammatory doses of prednisone orally for up to two weeks [17]. The antibiotics of choice for oral use include cephalexin (22-33 mg / kg q12h) and amoxicillin associated with clavulanic acid (22 mg/kg q12h) [18]. Recurrent cases require culture and susceptibility testing to access resistance [16].



**Figure 2.** Superficial bacterial folliculitis in a Dachshund. Multiple areas of alopecia and erythema are seen in the trunk area.

## 5. Fungal diseases

### 5.1. Dermatophytosis

Dermatophytosis is a superficial mycosis caused by *Microsporum*, *Trichophyton* or *Epidermophyton* fungi genera. These fungi are isolated from hair, nails and skin surface since they



require keratin for their growth [19]. Dermatophytes are classified into three groups based on their habitat: zoophilic, mostly found in animals, occurring transmission to other animals or to humans; anthropophilic, mostly found in humans, transmitted between humans and rarely to animals and geophilic, dermatophytes, found in the soil, infects humans and animals [20]. *M. canis* is the most frequently isolated fungal species in dogs and cats [21].

Clinically, canine and feline fungal infections differ. Infections in dogs often produce lesions, while it is possible to isolate dermatophytes from clinically healthy cats, which can act as a conidia reservoir of the fungus [22]. The affected animals usually have alopecic, scaly, crusted, erythematous and papular lesions, especially in the face and limbs. Occasionally, dermatophytes may be presented in a nodular form known as kerions. This form of dermatophytosis is characterized by deep, inflammatory and suppurative lesions [23]. Pruritus may vary from absent to severe [24].

The direct microscopic examination of hairs and scales can reveal the presence of fungal hyphae or spores. The fungal culture is the diagnostic test of choice and the sample may be obtained by brushing the animal with a toothbrush or by skin scrapings [25].

The best strategy for the treatment of dermatophytes is the association of systemic and topical antifungal therapy. The aims of the treatment with topical products are the elimination of the fungi present at the epidermis and hair surface, while systemic treatment aims to eliminate infection within the hair shafts [26]. Lime sulfur rinse at 6.5 % twice a week showed good results in cats infected with *M. canis* [27, 28]. Systemic treatment options include itraconazole orally at 10 mg/kg once a day, griseofulvin 50 mg/kg once a day or terbinafine 5 mg/kg once a day [27-29]. The treatment must be extended over 2 to 4 weeks after clinical cure and after obtaining two or more negative fungal cultures [23].

## 5.2. *Malassezia dermatitis*

*Malassezia pachydermatis* is a commensal skin yeast, commonly isolated from lips, interdigital skin, anal mucosa and external auditory canal [30]. It is an opportunistic yeast, which usually manifests itself after the installation of other diseases. It is very common in dogs and least frequent in cats [31]. Previous antibiotic therapy is associated with the development of cutaneous *M. pachydermatis* over growth in dogs [32], as well as disorders of keratinization and hypersensitivity diseases [33]. Basset Hounds, Cocker Spaniels and West Highland White Terriers are more predisposed to this type of infection [32].

The most common clinical manifestation of *Malassezia dermatitis* is the presence of moderate to intense pruritus [34]. Erythema, lichenification, oily skin, malodor, alopecia and erosions are also common clinical findings [35] that can be generalized or localized [34].

Cytology is the diagnostic method of choice and allows microscopic identification of the increased number of yeasts. Samples can be obtained by skin scrapings, swabs, direct imprint or by tape preps. Fungal culture is not recommended as a diagnostic procedure because it is not a quantitative assessment [36].

Identification and correction of the predisposing diseases are essential for the successful treatment of *Malassezia* dermatitis [23]. Mild cases can be treated with miconazole, chlorhexidine, ketoconazole or acetic acid shampoos. Baths should be given, two times per week, for a minimum of six weeks [36]. Patients requiring systemic treatment should receive oral antifungals such as ketoconazole, itraconazole or fluconazole 5 mg/kg once a day for a minimum of 30 days [36]. Terbinafine 30 mg /kg every 24 hours on two consecutive days in a week, for six weeks, may also be an effective treatment [37]. In order to prevent recurrences of the disease, regular maintenance therapy may be needed in many dogs [23].

### 5.3. Sporotrichosis

Sporotrichosis is a subcutaneous mycosis caused by a dimorphic fungus, *Sporothrix schenckii*, which can infect animals and humans [39]. It is a zoonotic disease and transmission to humans occurs through bites or scratches, and contact with cats ulcers [40]. *S. schenckii* is present in the decaying vegetation and soil and animal contamination occurs by skin open lesions such as perforations, bites and scratches. Once in the host organism, the fungus may cause local lesions and possibly systemic signs [41].

Clinically, sporotrichosis has three forms: cutaneous, lymphocutaneous and generalized, and more than one form can occur simultaneously in the same animal. The cutaneous form is usually confined to the area of fungus inoculation and manifests after an incubation period of one month. If this lesion is not treated, the progression to lymphocutaneous form can occur. The lymphocutaneous form is characterized by the development of nodules that evolve into ulcers, affecting skin, subcutaneous tissue, lymph vessels and regional lymph nodes [41]. History of lethargy, anorexia, depression and fever on physical examination suggest the presence of the disseminated form [42].

The diagnosis is based on clinical history, physical examination, cytological evaluation, fungal culture and histopathological findings [43]. Cytological evaluation usually reveals oval to elongate yeast cells consistent with *S. schenckii* form and inflammatory cells may also be present [45]. On histopathology, the presence of deep pyogranulomatous dermatitis, cellular infiltration of polymorphonuclear and mononuclear cells, and the presence of PAS positive structures compatible with *S. schenckii* may be observed [44]. Oral administration of itraconazole 10 mg/kg every 24 hours is the treatment of choice [46].

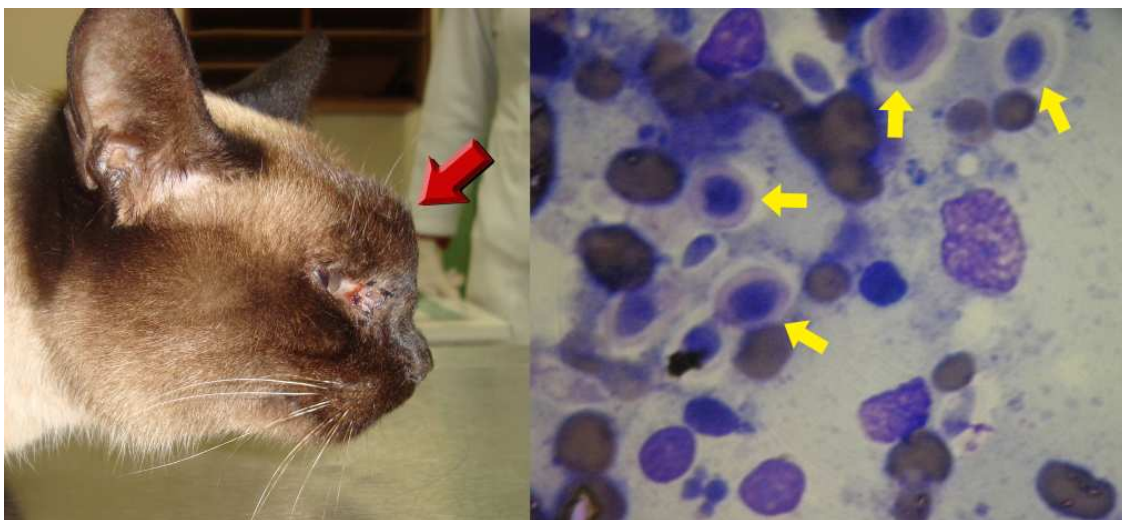
### 5.4. Cryptococcosis

*Cryptococcus* spp. is a saprophytic fungus present in the environment and in the feces of pigeons, capable of causing systemic infection in dogs and cats, with a higher incidence in felines. The species of interest in veterinary medicine are *C. neoformans*, which has a global distribution and *C. gattii* that has a limited distribution [47]. *C. neoformans* typically infects animals by inhalation and may cause ophthalmic, upper respiratory tract and central nervous system lesions. Ulcerative lesions in the nasal, oral or pharyngeal mucosae, or a nasal masse may be present (Figure 3) [31]. Mycotic rhinitis and cutaneous nasal bridge and nasal plan involvement are the most frequent findings. In cats with positive serology for feline im-

immunodeficiency virus (FIV) cryptococcosis tends to manifest itself in a disseminated or advanced form [48].

Cryptococcosis diagnosis is based on fungal culture, cytological, histological and serological exams [49]. Cytological examination may reveal the presence of leukocytes, macrophages and numerous encapsulated structures (yeast) of different sizes (Figure 3) [50, 51].

Drug therapy leads to patient healing in most cases [49] and it consists of oral antifungal use until complete remission of clinical signs, usually in 3 to 12 months. It is strongly recommended not to interrupt the treatment until the titers of antibodies against cryptococcosis are reduced to zero [52]. Drugs commonly used include fluconazole 50 mg/cat every 12 hours [48] and itraconazole 50-100 mg/cat every 24 hours [52], or 10mg/kg for dogs and cats every 24 hours [49]. Patients with nasopharyngeal masses benefit from surgical resection, for upper airway patency and reduction of infected tissue to be treated medically [52].



**Figure 3.** Feline cryptococcosis. Figure on the left: a cat presenting a nasal masse (red arrow). Figure on the right: Cytology by fine needle aspirate of the nasal masse showing several encapsulated structures (yellow arrows) compatible with *C. neoformans* (microscopic image viewed with a 100x oil objective).

## 6. Parasitic skin diseases

### 6.1. Demodicosis

Demodicosis is a very common skin disease in dogs but rare in cats [53]. It is an inflammatory disease, in which large amounts of *Demodex* mites are found in the skin [54]. Mites proliferate in the hair follicles and sebaceous glands causing the disease [55]. It is a common condition and it is often serious in dogs. Besides *Demodex canis*, two less common species were reported [54, 55], *Demodex sp. cornei* and *Demodex injai* [55]. Feline demodicosis may be caused by two different kinds of mites, *Demodex cati* and *Demodex gatoi* [53].



The mites are transferred from the mother to the offspring in the early life [56]. *D. canis* is considered a commensal in canine skin. It is believed that this disease is a consequence of a specific immunosuppression, which allows the proliferation of the mites [57]. Genetic factors are probably very important in the development of generalized disease and therefore, breeding of affected animals is contraindicated [54].

Erythema, comedones, scaling, partial or complete alopecia, papules, follicular casts, pustules, and in severe cases, furunculosis, crusting, exudation and ulceration with focal draining tracts can be clinical signs. Generally the lesions begin on the face and limbs, but they may become generalized. Demodicosis can be classified into generalized or localized. The involvement of one complete body region, five or more focal areas, or the involvement of the legs is considered generalized demodicosis. The diagnosis is made by deep skin scrapings or trichogram. In some rare cases, in the legs or certain breeds such as Shar-peis, these tests may be negative, requiring biopsies for mite detection [58].

In most dogs, localized demodicosis resolves spontaneously, thus mite-specific therapy is not necessary until the disease generalizes [53]. The treatment of generalized demodicosis involves several approaches. In addition to the acaricidal treatment, the concurrent secondary infections and underlying diseases should be also accessed [58]. As an acaricidal treatment, ivermectin is recommended at 0.3 to 0.6 mg/kg orally once a day, however, it is recommended to begin the treatment with a lower dose and gradually increase the amount of drug administered. The animal should be monitored for the appearance of adverse effects. Therapy with moxidectin 0.2-0.5 mg/kg orally once a day and doramectin 0.6 mg/kg orally or subcutaneously once a week were proven effective in the treatment of generalized demodicosis. The same careful institution of a gradual dose taken with ivermectin should be applied for these two other drugs. Milbemycin oxime can also be used at 1 to 2 mg/kg orally, once a day, with good results [58]. In cats weekly baths with 2% lime sulfur are indicated for the treatment of demodicosis. There is remote evidence to indicate weekly application of 0.025% amitraz and for the use of doramectin 0.6 mg/kg once a week subcutaneously [53]. Treatment should continue for one month after getting the third consecutive negative scraping [58].

## 6.2. Canine scabies

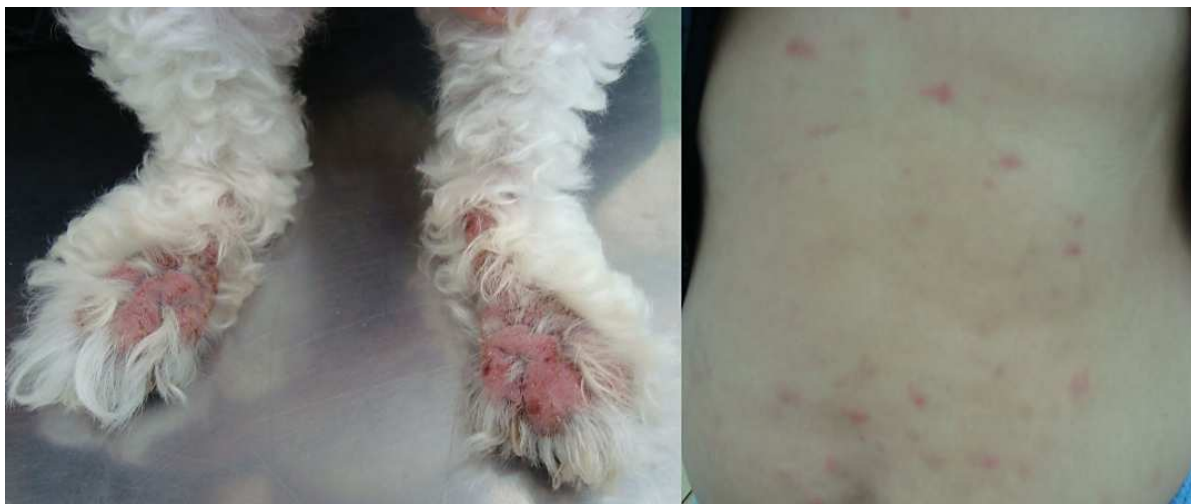Canine scabies is a common condition in dogs and humans, but rare in cats, in which the skin is colonized by *Sarcoptes scabiei* mite after contact with a donor host. The infestation with this mites results in intense pruritus [59, 60]. Female mites dig galleries in the stratum corneum in order to lay their eggs that hatch, releasing larvae forms that migrate to the skin surface, where they reach the adult stage [61].

Extremely irritating and pruritic papular eruption, skin thickening, erythema, alopecia, exudation with crust formation and secondary bacterial infection with pustules are common clinical findings (Figure 4). Chronic lesions are usually confined to the margins of the pinna, elbows and hocks that may present skin thickening, minimal crust formation and persistent pruritus [61].

Skin scraping with microscopic identification of *S. scabiei* is a valuable diagnostic method, although mites are hardly seen in many cases. Diagnosis is usually based on the animal's history, clinical signs and a positive pinnal-pedal reflex (pinna margins are gently scratched and the dog will reflexively use an ipsilateral hind limb to scratch the source of the irritation) [62, 63].

The treatment is recommended to the patient and other animals in their household. Bathing with 0.025% amitraz solution once weekly or twice weekly is recommended as an effective treatment. The therapy should be continued for two weeks after clinical signs remission. Adverse side effects should be monitored during the treatment [64]. Fipronil spray 0.25% can be applied three times with three weeks intervals on puppies [65]. Ivermectin can be administered at 0.2 to 0.4 mg/kg, orally every seven days, or subcutaneously every 14 days. The treatment usually takes four to six weeks [66]. This drug is contraindicated in Collies and their crosses [67]. An effective alternative treatment of scabies is a spot-on application of selamectin at 6-12 mg/kg every 15 to 30 days, for at least three applications and it is apparently, well tolerated in different breeds [67, 68]. Milbemycin oxime at 2mg/kg in a weekly dose, administered for up to five times has also a good efficacy [69].

NOTE: The permission for the use of macrocyclic lactones in the treatment of cats and dogs is different for each country. The rules concerning its use should be checked before treatment institution and the owners must be warned in order to authorize any extra-label use of these medications.



**Figure 4.** Scabies. Figure on the left: a dog with erythematous, alopecic and lichenified pruritic lesions in the distal aspect of the hind limbs. Figure on the right: the animal's owner presenting abdominal pruritic papular lesions, highlighting the zoonotic aspect of scabies.

## 7. Allergic diseases

### 7.1. Flea allergy dermatitis

*Ctenocephalides felis felis* is the most important ectoparasite in dogs and cats in several countries [70]. Its infestation may cause intense pruritus, self-inflicted trauma and even severe symptoms as anemia. Some animals will develop a severe condition known as flea allergy dermatitis (FAD). After the sensitization, the lesions may be initiated by only a few flea bites [71]. Flea allergy is one of the most frequent conditions in dogs, especially in humid and warm weather countries, where fleas are commonly found [72]. The most common clinical signs are erythema, excoriation, crusting, and pustules that usually affect the medial caudal aspect of forelegs and ventral abdomen; pyotraumatic dermatitis may also be observed [73].

Diagnosis is based on circumstantial evidence, such as clinical response to flea control. A successful treatment for FAD depends on eliminating the allergy source, the flea. Therapy goals are the total elimination of flea population in the patient's body and environment, as well as in contact animals. It is also important to prevent new infestation, what is not always simple, once fleas have a high reproductive capacity and a complex life cycle [71]. Flea control advances with modern insecticides and insect growth regulators markedly decreased the number of affected animals. Products as fipronil, imidacloprid, metaflumizone, nintempiram, selamectin e spinosad proved to be efficient to control fleas in animals with FAD [74]. These products are available in several presentations as shampoo, collars, spray, powder, spot on and oral medication [71].

### 7.2. Adverse food reaction

Adverse food reactions are described in veterinary medicine since 1920, reporting the occurrence of gastrointestinal signs and skin reactions in response to food allergens [75]. Adverse food reaction refers to any abnormal clinical response assigned to consumption of food or its additives [76]. This reaction is classified as food allergy (immune-mediated) or food intolerance (non-immune-mediated). The majority of reactions in animals are food intolerances and they can be of pharmacological or metabolic origin, poisoning, idiosyncrasy [76, 77], toxicity or anaphylactic reaction to the food [77]. There are some dogs with pruritic skin diseases or otitis which resolves with restrictive diet, but it remains unproved the immunologic cause or hypersensitivity (allergy) associated with cutaneous adverse food reactions (CAFR). Once the etiopathogenesis was not elucidated yet, the term food allergy should be avoided, and CAFR is more appropriate [76, 78]

There are no breed, sex or age predisposition to the occurrence of clinical signs. Pruritus is the most important sign reported and it affects mainly the face, perineum and ears (otitis externa). Gastrointestinal signs as vomiting and diarrhea can also be observed. The best diagnostic approach for CAFR in dogs and cats is feeding them with a diet, with only one source of protein that the animal has never been in contact before (novel protein). The diagnosis is obtained with the resolution of clinical signs after the diet trial and with the return of these signs when the previous diet is offered again. The diet trial should be implemented for at

least six weeks. Homemade diets are more appropriate for the CAFR trial described above, but there are also commercially available prescription and hydrolyzed diets [75].

Prescription diets, commercially available in some countries, are made of an unusual protein source and a non-allergenic carbohydrate source such as potato or oat meal. Lamb, duck, rabbit and Kangaroo meat are protein sources usually found in these diets [77]. Another option considered really hypoallergenic is the hydrolyzed diet. For humans it is known that most food allergens are glycoproteins with molecular weight higher than 12,000 d. The hydrolyzed food has smaller peptides what makes them potentially less allergenic [75]. However, a small percentage of allergic dogs show poor response to hydrolyzed food. The possibility of adverse food reaction to hydrolyzed food in sensitive dogs is rare but should be considered [79].

CAFR differential diagnoses are other hypersensitivities as FAD, atopic dermatitis, diseases caused by ectoparasites, and yeast or bacterial infections. These infections can also appear as complications of a pruritic process. Therapy should include secondary infections and otitis externa. Some cases also demand severe pruritus control while the diet trial is applied. Any drug therapy should be interrupted at least three weeks before the end of the diet trial, so that the clinician can access the animal response to the diet [75]. It is still unknown if animals develop tolerance to food allergens after a long period without contact, as reported in humans, however, natural hyposensitization is apparently rare [77].

### **7.3. Atopic dermatitis in dogs**

Canine atopic dermatitis (CAD) is an allergic, hereditary, inflammatory and pruritic skin disease, with characteristic clinical signs associated with immunoglobulin E (IgE) production against environmental allergens [80]. Atopic dermatitis also affects cats, but its incidence is lower than in dogs [81].

Most dogs with atopic dermatitis begin to manifest signs between six months and three years of age [82, 83]. There is no sex predisposition and clinical signs may or not be seasonal, depending on the allergen involved. Usually, patients have a history of pruritus with or without secondary skin or ear infections. Primary lesions include macules and papules, but frequently, patients are presented with secondary lesions from self-inflicted trauma as excoriations, alopecia, lichenification and hyperpigmentation. Lesions affect the face, concave part of the pinna, ventral aspect of the neck, axilla, groin, abdomen, perineum, ventral aspect of the tail, limbs joints, medial aspects of limb extremities, feet and ears [85].

In dog as in human beings there is no pathognomonic sign of atopic dermatitis that could provide a diagnosis based only in history and physical examination. Diagnosis depends on patient fitting in several criteria associated with the condition and on elimination of differential diagnoses. Following clinical diagnosis, laboratory or clinical tests as allergy tests and histopathology, reinforces the diagnosis. However, these tests should not be used to establish the diagnosis but to confirm it [82]. It is important to highlight the fact that some dogs with inflammatory and pruritic skin diseases, displaying clinical signs identical to those found in CAD, may have no IgE production in response to environmental allergens. This



condition is known as “canine atopic like dermatitis” [80]. Other dermatosis might share similar signs with canine atopic dermatitis or could be concurrent diseases and it is why they should be eliminated or controlled before the conclusive diagnose of CAD. Differential diagnoses for CAD are FAD, CAFR, pruritic parasitic diseases, bacterial pyoderma, *Malassezia* dermatitis and other allergic diseases [82, 83]. Allergy tests goals are to determinate allergens, to contact avoidance and to be included in the allergy specific immunotherapy [83]. No allergy test is completely sensitive or specific, therefore, clinically normal animals can have positive responses and animals with negative results can have clinical characteristics of the disease [82]. Allergens generally related to CAD pathogenesis are domestic dust mites, mold spores, trees and grasses pollens, antigens from insects and epidermis [84].

Atopic dermatitis is one of the most common skin diseases in dogs, however, its pathogenesis is not completely understood, so there is no curative therapy available yet [85]. Diverse topical and systemic therapies are currently available for CAD treatment such as specific allergy immunotherapy, corticosteroids, calcineurin inhibitors, anti-histamines and essential fatty acids. Unfortunately, these therapies are not effective in all cases or show adverse effects with long term use [86]. For most dogs with atopic dermatitis, the elimination or prevention of the contact with allergens is extremely difficult and drug therapy is not always satisfactory, in these cases the possibility to modulate the immune response to allergens is a good option. Specific allergy immunotherapy, also known as hyposensitization, desensitization or allergy vaccines [85], is defined as the act of administrating increasing amounts of allergen extracts to an allergic patient, in order to minimize the symptoms related to allergen exposure. Immunotherapy is not an option for patients that do not produce IgE against allergens with clinical relevance [87]. As a result, 50 to 100% of dogs submitted to immunotherapy may show improvement in clinical signs after four months of treatment, and some of these animals remain with no clinical sign for long periods [88]. Despite broadly applied in the treatment of human atopic dermatitis, there are just a few studies of the topical corticosteroids use in veterinary medicine. Triamcinolone 0.015% spray was used with good results during a month with minimal side effects [89]. Recently, hydrocortisone aceponate 0.0584% spray applied once daily in affected areas, in the dose of two sprays for each 100 cm<sup>2</sup>, during 84 days was markedly effective, showing results similar to those obtained with cyclosporine therapy, although with no adverse effects [90]. Frequently used oral glucocorticoids are prednisone, prednisolone and methylprednisolone, considered efficient and with rapid anti-allergic effect, at 0.5 to 1.0 mg/kg once or twice daily. Once desired effect is achieved, the dose may be decreased maintaining efficiency. Often observed adverse effects are related to dose and duration of the treatment [89]. Calcineurin inhibitors as tacrolimus 0.1% ointment applied twice daily on localized lesions is efficient in CAD treatment [91]. Good efficacy can also be observed with oral cyclosporine 5 mg/kg once daily during four to six weeks. When using cyclosporine the dose is usually reduced to half after obtaining improvement in clinical signs, maintaining the efficiency. Side effects as vomiting and transient diarrhea can occur. Oral anti-histamines has been used for decades in CAD treatment, however, there is no study showing conclusive evidences of its efficacy. Adverse effects of anti-histamines may be sedation and lethargy but this signs are uncommon. Omega 3 and 6 essential fatty acids from vegetal or from fishes source has been used for longer than 20 years in the



treatment of atopic dermatitis. They are commercially available in capsules, liquid or enriched diet. The benefits of fatty acids therapy for CAD, is not clear despite the many studies in the area, however, they might reduce the corticosteroids dose, after 8 weeks of concurrent therapy [89].

## 8. Immunologic skin diseases

### 8.1. Pemphigus complex

Pemphigus complex diseases result from the production of autoantibodies directed against epidermal intercellular content, resulting in cell separation with intraepidermal bullae formation. The deposition of antibodies promotes the physical separation of the cells; moreover, it is believed that the release of cell proteases occur, which digests the intercellular substance, further aggravating the condition. Among the forms observed in dogs and cats are pemphigus erythematosus, pemphigus vulgaris, pemphigus vegetans and pemphigus foliaceus, the latter being the most common autoimmune skin disorder in these species [92], which will be discussed in this chapter.

Pemphigus foliaceus is observed more frequently in middle-aged animals, especially in domestic short haired cats and in dogs of some predisposed breeds such as Bearded Collies, Japanese Akitas, Chow Chows, Doberman Pinschers and Newfoundlands [93, 94]. It is a vesiculobullous, erosive disorder, which produces evident footpad hyperkeratosis. The face, trunk and abdomen are also frequently affected [95, 96]. Pustules, crusted lesions, erythema, alopecia and secondary pyoderma may also be present [94, 96]. Cachexia and sepsis secondary to infection may be observed in severe cases [97].

When present, pustular lesions can be evaluated cytologically and can reveal non degenerated granulocytes and acanthocytes [94]. Histologically intraepidermal and intrafollicular pustules are observed, with the presence of superficial perivascular dermatitis and acanthocytes [92, 93, 98]. The histologic presence of acantholysis is the Hallmark of the pemphigus complex [98].

Therapy requires the use of immunosuppressant or immunomodulators. Prednisone, prednisolone and methylprednisolone are commonly used in the treatment of pemphigus. Initially it is recommended a dose of 2.2 to 4.4 mg/kg, every 24 hours, for all three drugs. If therapeutic response is seen in 14 days, the dosage should be reduced gradually over 30 to 40 days. After this, an alternate day dose should be implemented, reaching a final protocol of 1 mg/kg every 48 hours or less [98]. In resistant cases of canine pemphigus, the use of prednisolone can be combined with azathioprine (2.2 mg/kg q12h or q24h) or cyclophosphamide (50 mg/m<sup>2</sup> q48h). Feline pemphigus normally responds well to prednisolone, although resistant cases may benefit from a combination of prednisolone and chlorambucil (0.1-0.2 mg/kg every 24 hours or every other day) [94]. Topical glucocorticoids can be used as a single therapy, in localized forms of pemphigus or used for persistent lesions, as adjunctive therapy to the systemic treatment [98]. The occurrence of deaths in cases of pemphigus folia-

ceus are mainly from side effects of the drugs, secondary infections or in many cases, the pet owner requests euthanasia [97].

## 8.2. Discoid lupus erythematosus

Discoid lupus erythematosus (DLE) is an immune-mediated disease in which the lesions are similar to those of systemic lupus erythematosus (SLE), although, without the presence of the fluorescent antinuclear antibody and without the involvement of other body systems, as occurs in SLE [99]. The etiology is unknown, however, sunlight can precipitate or exacerbate the lesions. The most commonly affected regions of the body are the face and ears. Initially, there are depigmentation, erythema and desquamation. The lesions progress to scaly and swollen plaques. Definitive diagnosis is made by characteristic histopathology or immunofluorescence. Affected animals usually have a good response to systemic therapy with glucocorticoids, but topical presentations are also an option to the treatment [100]. Topical tacrolimus 0.1% can be an alternative therapy to the treatment with glucocorticoids, and was effective and safe for the treatment of DLE in dogs [101].

## 9. Metabolic and endocrine diseases

### 9.1. Hypothyroidism

Hypothyroidism is an endocrine disorder associated with a reduced production of T4 and T3 hormones by the thyroid gland [102]. Rarely affects cats [103], however, is the most common endocrinopathy in dogs [104]. The primary destruction of the thyroid gland occurs in more than 95% of adult dogs with hypothyroidism [104,105]. Thyroid hormones are extremely important in the maintenance of normal skin function, and dermatologic conditions are reported in 60 to 80% of hypothyroidism cases [106,107]. Usual findings are changes in coat quality and color, alopecia (in most cases, bilaterally symmetric and sparing head and limbs), superficial pyoderma, dry and desquamated skin, dry or oily seborrhea, brittle and easily pulled hairs, hyperkeratosis, hyperpigmentation, comedones, otitis, deficient healing of wounds, pruritus, myxedema and obesity [108].

Diagnosis is based on clinical signs, and on serum total TSH and free T4 [109]. Histopathology may show highly suggestive signs of hypothyroidism as follicle atrophy, hyperkeratosis, epidermal melanosis, many follicles in telogen phase [110], hypertrophy and vacuolization of arrector pili muscles, increased dermal mucine and thickened dermis [111].

Oral sodium levothyroxine (T4), 20 µg/kg twice daily, is the drug of choice for hypothyroidism [108]. The patient should receive appropriate treatment for dermatologic conditions presented, although they tend to disappear with the sodium levothyroxine administration.

### 9.2. Hyperadrenocorticism

Hyperadrenocorticism, also known as Cushing syndrome, results from chronic excessive cortisol secretion by the adrenal glands. It occurs iatrogenically, after synthetic glucocorti-

coids administration, or spontaneously, as a consequence of pituitary or adrenal gland primary hyper function. In dogs and cats, 80 to 85% of spontaneous hyperadrenocorticism are hypophysis-dependent [112]. Poodles, Dachshunds, Boston Terriers and Boxers are the more often affected dog breeds, and it rarely occurs in cats [113].

Symptoms as polyuria, polydipsia, polyphagia, hepatomegaly and abdominal swelling (pot-bellied appearance) are commonly observed. Dermatological signs include hypotrichosis, alopecia along the back tending to be symmetrical and bilateral, comedones, pyoderma and seborrhea [112]. Hyperpigmentation, thinner skin and calcinosis cutis occurs less frequently [114]. Clinical signs associated to laboratorial evaluation and diagnostic imaging findings, leads to the diagnosis. Plasma ACTH, low dexamethasone dose suppression test, ACTH stimulation test [113, 115] and urinary cortisol/creatinin ratio [116] confirms hyperadrenocorticism. It is also important to obtain the history of glucocorticoids use to eliminate iatrogenic cause [117].

Hyperadrenocorticism therapy depends on etiology, severity degree, tumor malignancy and availability of treatment options [118]. In hypophysis-dependent cases of adrenal dysfunction, surgical resection of the pituitary gland can be performed with low mortality rate. Adrenalectomy is recommended in cases of adrenal neoplasms. Drug therapy to control hypercortisolism involves the oral use of mitotane (o, p'-DDD), 50 mg/kg once a day [113] or oral trilostane, 2 to 3 mg/kg once a day. Some dogs may show a transient worsening of dermatological signs, especially with mitotane use. Complete resolution of dermatological signs usually takes months to be achieved [118].

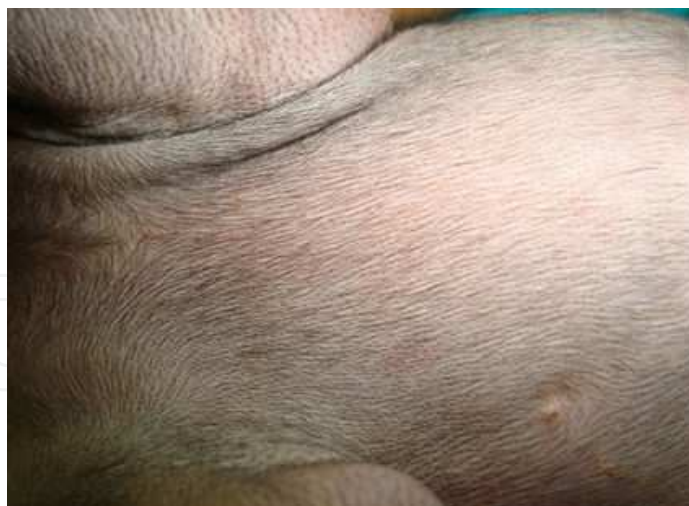## **10. Acquired alopecia**

### **10.1. Canine pattern baldness**

Canine pattern baldness is a common condition that affects short coated dog breeds with the development of acquired alopecia in specific body regions as, post-auricular, ventral cervical, chest, abdomen and caudomedial aspect of the thighs [119] (Figure 5). Canine pattern baldness is an aesthetic problem, with no consequences to patients health however, treatment may be required by the owners. Treatment may be tried with oral melatonin 5 mg (one capsule), once daily during 30 days to promote hair growth in alopecic regions [119,120].

### **10.2. Canine follicular dysplasia**

Follicular dysplasia is an inherited condition characterized by an abnormal development of the hair follicle, leading to hair structural abnormalities and alopecia [121]. Neck, back and hind limbs can be affected and secondary pyoderma and comedones are common clinical findings [122]. The diagnosis confirmation through histopathology reveal a great number of dysplastic follicles, dysplastic hair shafts and melanin aggregates within the hairs [123]. Patients can experiment spontaneous remission of follicle dysplasia, however, oral administration of 3 mg melatonin twice daily may help hair regrowth [124].



**Figure 5.** Canine pattern baldness. A Doberman pinscher with alopecia of the chest, which is characteristic of pattern alopecia (Veterinary Hospital of the Federal University of Viçosa).

### 10.3. Post clipping alopecia

Post clipping alopecia or post clipping hair follicles arrest [125] is a common but poorly understood syndrome in dogs, characterized by the absence of hair in consequence to a deficient growth in a previously clipped area [126]. In some cases the hair may take years to grow back. On clinical exam, the skin is normal with well delimited alopecic areas. Diagnosis is closed by the history of alopecia after clipping with no other dermatologic sign. If any systemic sign or other skin disorders are present, it is recommended to perform appropriate laboratory procedures to search for the endocrinopathies [125]. Usually no treatment is required [122]

### 10.4. Alopecia X

Alopecia X is a disease previously known as adrenal congenital hyperplasia, Cushing-like disease, dermatosis responsive to castration and adult-onset hyposomatotropism [127]. It is a condition associated with abnormalities on the hair cycle, affecting mainly the German Spitz breed. Affected animals display hairs in telogen phase what prevents new hair growth [128]. These animals are clinically healthy and show progressive hair loss, symmetric and non-pruritic, with variable degree of hyperpigmentation [129]. Histopathology findings are similar to those found in endocrinopathies, such as comedones, superficial and infundibulum hyperkeratinization, however, the presence of catagenization with flame follicle formation, confirms alopecia X diagnosis [127].

Therapies with sex hormones, growth hormone, mitotane and castration usually do not produce consistent results. Trilostane 10.5 mg/kg once a day, or twice a day, may produce complete hair growth in affected animals after four to eight weeks of treatment [129].

## 11. Keratinization disorders

### 11.1. Seborrhea

Seborrheic dermatitis is a skin keratinization disorder which can be primary or secondary. Primary keratinization disorders are inherited and exhibits breed predisposition. Usually, clinical signs appear before two years of age [130]. About 90% of the cases are secondary to an underlying disease [131,132] such as metabolic, hereditary or nutritional disorders [133] that causes excessive skin desquamation [131,132].

Seborrhea is classified in seborrhea sicca or oleosa according to hair and skin appearance [131,132]. In seborrhea sicca the coat is opaque and dry, containing aggregates of white to greyish scales, and in seborrhea oleosa there are adhesions of yellowish to brown lipid material, with greasy appearance [130]. Animals often exhibit pruritus, folliculitis, pyoderma, inflammation and hyperkeratosis plaques formation [131,132].

Diagnosis is based in history, clinical signs, physical examination findings and complementary exams to eliminate differential diagnosis or to determinate the primary disease. Frequently, it is necessary to perform skin scrapings, fungal and bacterial cultures, allergy tests, endocrine function evaluation, skin biopsy and evaluation of therapy response to close the diagnosis. Histopathology reveals abnormal keratinization of the epidermis and hair follicles, orthokeratotic and parakeratotic hyperkeratosis, follicular hyperkeratosis, dyskeratosis and perivascular superficial dermatitis [130].

Seborrhea treatment goals are scales and crusts removal and oil, pruritus and inflammation reduction [131,132]. Cases of primary idiopathic seborrhea could be treated with oral Vitamin A (600 to 800 UI/kg, twice daily) or with retinoids as isotretinoin and etretin (1 a 2 mg/kg a q12h) [134]. Salicylic acid and sulfur shampoos are recommended and might have positive results in moderate cases. Tar shampoos are recommended to severe cases of seborrhea oleosa in dogs, however, they are contraindicated in cats [135]. Secondary cases have an excellent prognosis when the underlying disease is eliminated, while primary keratinization disorders demand lifelong control and treatment [130].

### 11.2. Acne

Acne is a common disorder in cats and it may result from an idiopathic keratinization defect or a secondary reaction pattern to another disorder [136]. The most common skin changes are found in the chin and lip margin, and they include comedones, crusts, papules, erythema, alopecia and variable pruritus. Usually this disorder courses with secondary bacterial pyoderma and in some cases, with *M. pachydermatis* infections [137]. Papules, pustules, furunculosis and cellulitis might be signs of a secondary infection. Changes in hair follicle cycle, immunosuppression, stress, deficient grooming and concurrent viral infections are possible causes for this disorder [136]. Histology shows periductal linfoplasmocitary inflammation, sebaceous gland duct dilatation and follicular keratosis with obstruction and dilatation of the follicles [137]. Mild cases can be treated with anti-seborrheic shampoo; however, severe cases require association with systemic antimicrobial therapy or systemic corticoids



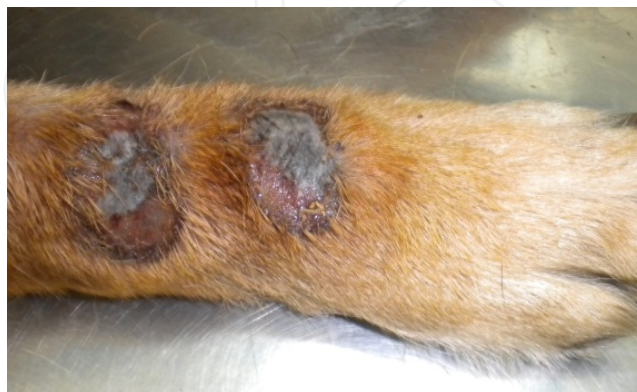[136]. Mupirocin 2% ointment is efficient when applied on lesions twice daily [138]. Topical tretinoin 0.01 to 0.025% (lotion or ointment) improves the clinical signs in chronic cases [139,140]. Proper recognition and treatment of secondary infections contribute to a successful therapy [137]. Feline acne has a good prognosis, however, symptomatic lifelong treatment is often necessary to control the condition [140].

## 12. Psychogenic diseases

### 12.1. Acral lick dermatitis

Acral lick dermatitis is characterized by ulcerated, proliferative, firm and alopecic plaques, derived from compulsive licking of the distal portion of the limbs [141] (Figure 6). Secondary bacterial infection is frequent and contributes to the sorely pruritic nature of the lesions [142]. This condition may originate from psychogenic (fear, and/or anxiety-based conditions), dermatologic (secondary to hypersensitivity, demodicosis, neoplasms and fungal or bacterial infections), traumatic, neuropathies or articular diseases [141,142].

Diagnosis requires complete clinical evaluation (anamnesis, physical, neurological and dermatological exams), complete blood cell count, serum biochemical profile and urinalysis. Only after the elimination of possible organic causes for acral lick dermatitis, it can be considered a behavioral disorder. In this case, the animal behavior should be evaluated, with the observation of its environmental and social stimuli and their motivational status. Treating acral lick dermatitis is notoriously challenging. The animal's environment should be modified to eliminate or minimize their exposure to stress factors [142], and the use of anti-depressives as fluoxetine 20 mg/day may help significantly in compulsion control which improves the lesions [143].



**Figure 6.** Acral lick dermatitis. Ulcerated plaques with tissue necrosis in the distal portion of a dog's forelimb.

## 13. Nutritional skin diseases

### 13.1. Vitamin A responsive dermatosis

Vitamin A is essential to the maintenance of epithelial tissue integrity and is especially important in the keratinization process [144]. Vitamin A responsive dermatosis is an uncommon condition, observed mainly in properly fed Cocker Spaniels [145] that may exhibit skin desquamation, pruritus, oily skin, characteristic hyperkeratotic plaques and secondary pyoderma [144]. Histopathology reveals follicular oriented exuberant hyperkeratosis [145].

Lesions do not improve with anti-seborrheic therapy, but oral supplementation of vitamin A (retinol), at 10,000 UI once a day, provides clinical improvement in 5 to 8 weeks of treatment. Lifelong treatment is usually necessary [144].

### 13.2. Zinc responsive dermatosis

Zinc is essential in the cellular metabolism and also in hair and skin health maintenance [144]. Zinc responsive dermatosis is an unusual disorder in dogs and it is characterized by scaling, focal erythema, crusts and alopecia, mainly over the head [146].

Two syndromes are recognized in dogs. Syndrome I affect young adult dogs fed with balanced diets, especially Siberian Huskies and Alaskan Malamutes, however, it was reported in other breeds [146,147]. Affected animals have a diminished ability to absorb zinc from the intestinal tract, due to some subclinical disease or to genetic factors [144]. Syndrome II is observed in rapidly growing puppies, especially of giant breeds, fed with zinc deficient diets or with excessive calcium phytate [144,146].

The diagnosis is based on history, clinical signs, characteristic lesions, breed, skin biopsy and response to zinc supplementation. The histopathological abnormalities found are papillary epidermal hyperplasia, confluent spongiotic parakeratosis and suppurative crusts [146].

Syndrome I control requires lifelong oral zinc supplementation with zinc methionine 1.7 mg/kg once a day, zinc gluconate 5 mg/kg once a day or zinc sulfate 10 mg/kg once a day [14]. Refractory cases to oral supplementation could receive intravenous administration of zinc sulfate at 10 to 15 mg/kg once a week, initially during four weeks and later each one, to six months [144]. Prognosis is good in most cases, although, lifelong supplementation may be required. Affected animals should be removed from breeding [147].

Syndrome II has an excellent prognosis and only requires food balancing to supply the zinc deficiency, however, signs remission occur faster with oral zinc supplementation [144].

### 13.3. External ear diseases

The external ear is divided in three parts: inner, middle and outer ear. External or outer ear comprises the pinna, vertical canal and horizontal canal, formed by auricular and annular cartilages. The diameter of the external ear canal varies according to the age, breed and size of the animal and it is separated from the middle ear by the tympanum, a thin semitranspar-

ent membrane with an elliptic shape [148]. External ear diseases are particularly important in veterinary dermatology, since the outer ear is formed in the embryo life through a skin invagination, being susceptible to a number of dermatologic conditions [149]. Otitis externa is the most frequent disorder of the outer ear canal in dogs and cats, consisting in the inflammation of its epithelium [150,151].

In order to achieve the correct diagnosis and a successful therapy, it is essential to recognize and understand the primary predisposing and perpetuating causes. Primary causes are factors or processes that trigger the inflammation in the outer canal [152]. The most frequent trigger factors are parasitic infestation (*Octodetes cynotis*, *Demodex canis*, *Sarcoptes scabiei*, *Notoedres cati*), foreign body, allergic diseases and hypersensitivities (atopic dermatitis, food allergy, contact allergic dermatitis), keratinization disorders (seborrhea, sebaceous adenitis), hormonal disorders and autoimmune diseases (pemphigus, lupus erythematosus). Predisposing causes are factors and process that increases the risk of otitis development, such as the ear conformation (narrow ear canal, excessive hair in the ear canal, long and pendulous ears), excessive humidity (baths, swimming habit), iatrogenic factors (use of cotton swab to clean the ear, use of irritant cleaning solutions) and the occurrence of obstructive ear diseases (polyps and neoplasms) [151].

Factors that help to perpetuate otitis are bacterial infection (*Staphylococcus pseudintermedius*, *Pseudomonas aeruginosa*), yeast infection (*M. pachydermatis*) and complications of otitis media, as ear canal narrowness due to hyperplasia and calcification of the cartilage structures [151,153,154].

The initial sign of otitis externa is erythema of the pinna and outer ear canal. Worsening of symptoms can lead to head shake, ear pruritus, malodorous purulent or ceruminous discharge, edema, pain and evidences of self-inflicted trauma as aural hematoma and acute moist dermatitis in the base of ears. Chronic or recurrent otitis can lead to soft tissue hyperplasia, ear canal stenosis and occlusion [151].

Diagnosis requires physical and dermatological examination, knowledge of the dermatological history and clinical signs development. Otoscopy is the first choice technique to evaluate the outer ear canal [155] and it should be performed in every patient with signs of otitis [156]. It is important to notice that a healthy ear canal might have small amounts of yellowish or brown cerumen [150]. Through otoscopy the clinician can access the presence of inflammation, exudate, hyperplasia, stenosis, foreign body, neoplasms and evaluate the tympanic membrane. Depending on the degree of pain, inflammation and stenosis, it might be necessary to use topical or systemic corticoids for two to three weeks before performing an otoscopic examination [156].

Cytological analysis is required for the diagnosis, and samples should be obtained from both pinna and the outer vertical and horizontal canal. Cytology can provide early information about the inflammatory response and microbial organisms or parasites involved in the process [150].

A successful therapy is based on: removing or controlling the primary cause and predisposing factors; eliminating bacterial and yeast infection, parasite infestation and foreign bodies

on ear canal; cleaning the pinna, vertical and horizontal canal; eliminating debris, exudates and cerumen. It is also extremely important to instruct the owner about cleaning techniques and administration methods for topical medications [150].

Gram positive bacterial infections can be treated with topical steroidal antibiotics (fusidic acid) and topical fluoroquinolones (marbofloxacin and orbifloxacin). Gram negative infections could also be treated with fluoroquinolones or with topical cationic polypeptides (polymyxin B) and aminoglycosides (neomycin, framycetin, gentamicin) [154]. Aminoglycosides are contraindicated in cases of tympanic membrane rupture due to their ototoxicity [150]. *Malassezia* species are usually susceptible to azoles (clotrimazol and myconazol) and polyene macrolides (nistatin) [154].

The use of topical drugs such as moxidectin 1% and imidacloprid 10% (0.1 mg/kg, two applications with two weeks interval) is effective for *Otodectes cynotis* infestation in cats [157].

Animals with acute otitis should be treated twice daily during 7 to 14 days. Chronic or recurrent cases should be treated for, at least 4 weeks, and systemic anti-inflammatory drugs are recommended in association to the topical therapy (prednisone or prednisolone 0.5 mg/kg q12h) [158]. Glucocorticoids efficiently control the inflammation and may prevent or reverse tissue hyperplasia and canal stenosis [154]. Therapy should be discontinued only when cytology is negative for microorganisms, if there is no ear canal edema and if the epithelium has a normal appearance [158].

## Author details

Elisa Bourguignon<sup>1</sup>, Luciana Diegues Guimarães<sup>2</sup>, Tássia Sell Ferreira<sup>3</sup> and Evandro Silva Favarato<sup>2</sup>

\*Address all correspondence to: dermatovet@gmail.com

1 Veterinary Department, Pontifical Catholic University of Minas Gerais, Betim, Brazil

2 Veterinary Department, Federal University of Viçosa, Viçosa, Brazil

3 General Practitioner, Juiz de For, Brazil

## References

- [1] Thomsett LR. Structure of Canine Skin. *The British Veterinary Journal* 1986; 142 (2) 116-23.
- [2] Favarato ES, Conceição LG. Hair Cycle in Dogs with Different Hair Types in a Tropical Region of Brazil. *Veterinary Dermatology* 2008; 19(1) 15-20.

- [3] Beale K. Dermatologic Diagnostic Techniques. In: Florida Veterinary Medical Association: proceedings of FVMA's 82<sup>nd</sup> Annual Conference, April 29-May 1, 2011, Orlando, EUA.
- [4] Mueller RS (Ed.). Specific Tests in Small Animal Dermatology. In: Dermatology for the Small Animal Practitioner. Ithaca: IVIS; 2006. <http://www.ivis.org/advances/Mueller/part1chap3/chapter.asp?LA=1> (accessed 01 August 2012).
- [5] Shelly SM. Cutaneous Lesions. *Veterinary Clinics of North America: Small Animal Practice* 2003; 33(1) 1-46.
- [6] Ihrke PJ. An Overview of Bacterial Skin Disease in the Dog. *British Veterinary Journal* 1987; 143(2) 112-8.
- [7] Moriello KA. Pyoderma. In: Kahn CM. (ed.) *The Merck Veterinary Manual*. Whitehouse Station: Merck Sharp & Dohme Corp.; 2011. Available from: <http://www.merckvetmanual.com/mvm/index.jsp?cfile=htm/bc/70900.htm> (accessed 12 August 2012).
- [8] Devriese LA, Vancanneyt M, Baele M et al. *Staphylococcus pseudintermedius* sp. nov., a coagulase-positive species from animals. *International Journal of Systematic and Evolutionary Microbiology* 2005; 55(4) 1569-73.
- [9] Guardabassi L, Loeber ME, Jacobson A. Transmission of Multiple Antimicrobial-resistant *Staphylococcus intermedius* Between Dogs Affected by Deep Pyoderma and their Owners. *Veterinary Microbiology* 2004; 98(1) 23-7.
- [10] Mason, I.S. Canine Pyoderma. *Journal of Small Animal Practice* 1991; 32(8) 381-6.
- [11] Cobb MA, Edwards HJ, Jagger TD, Marshall J, Bowker KE. Topical Fusidic Acid/Betamethasone-Containing Gel Compared to Systemic Therapy in the Treatment of Canine Acute Moist Dermatitis. *Veterinary Journal* 2005; 169(2) 276-80.
- [12] Ihrke, P.J. *Bacterial Skin Disease in the Dog: A Guide to Canine Pyoderma*. Newark: Bayer/Veterinary Learning Systems, 1996.
- [13] Hill PB, Moriello KA. Canine Pyoderma. *Journal of American Veterinary Medical Association* 1994; 204(3) 334-40.
- [14] Scott, D.W., Miller, W.H., Griffin, C.E. *Muller & Kirk's Small Animal Dermatology*. 6th edition. Philadelphia: W.B. Saunders; 2001.
- [15] Lloyd, D. Dealing with Cutaneous Staphylococcal Infection in Dogs. *In Practice* 1996;18(2) 223-31.
- [16] Coyner, KS. Challenges & New Developments in Canine Pyoderma - Disease Overview & Diagnosis. *Today's Veterinary Practice* 2012; 2(1) 31-38.
- [17] Coyner, KS. Challenges & New Developments in Canine Pyoderma - Topical & Systemic Treatment. *Today's Veterinary Practice* 2012; 2(2) 36-44.



- [18] May, E.R. Bacterial Skin Diseases: Current Thoughts on Pathogenesis and Management. *Veterinary Clinics of North America: Small Animal Practice* 2006; 36(1) 185-202.
- [19] Hainer BL. Dermatophyte Infections. *American Family Physician* 2003; 67(1) 101-8.
- [20] Georg LK. *Dermatophytes: New methods in classification*. Atlanta: Public Health Service; 1957.
- [21] Lewis DT, Foil CS, Hosgood, G. Epidemiology and Clinical Features of Dermatophytosis in Dogs and Cats at Louisiana State University: 1981–1990. *Veterinary Dermatology* 1991; 2(2) 53–8.
- [22] Sparkes AH, Werret G, Stokes CR, Gruffydd-Jones TJ. *Microsporum canis*: Innaparent Carriage by Cats and the Viability of Arthrospores. *Journal of Small Animal Practice* 1994; 35(8): 397-401.
- [23] Bond R. Superficial Veterinary Mycoses. *Clinics in Dermatology* 2010; 28(2) 226-36.
- [24] Moriello KA. Treatment of Dermatophytosis in Dogs and Cats: Review of Published Studies. *Veterinary Dermatology* 2004; 15(2) 99-107.
- [25] Moriello KA, Newbury S. Recommendations for the Management and Treatment of Dermatophytosis in Animal Shelters. *Veterinary Clinics of North America: Small Animal Practice* 2006; 36(1): 89-114.
- [26] Borgers M, Xhonneux B, Van Cutsem J. Oral Itraconazole Versus Topical Bifonazole Treatment in Experimental Dermatophytosis. *Mycoses* 1993; 36(3-4) 105-15.
- [27] Newbury S, Moriello KA, Verbrugge M, Thomas C. Use of Lime Sulphur and Itraconazole to Treat Shelter Cats Naturally Infected with *Microsporum canis* in an Annex Facility: an Open Field Trial. *Veterinary Dermatology* 2007; 18(5) 324-31.
- [28] Newbury S, Moriello KA, Kwochka KW, Verbrugge M, Thomas C. Use Of Itraconazole and Either Lime Sulphur or Malaseb Concentrate Rinse to Treat Shelter Cats Naturally Infected with *Microsporum canis*: an Open field Trial. *Veterinary Dermatology* 2010; 22(1) 75-9.
- [29] Balda AC, Otsuka M, Gambale W, Larsson CE. Comparative Study of Griseofulvin and Terbinafine Therapy in the Treatment of Canine and Feline Dermatophytosis. *Veterinary Dermatology* 2004; 15(Issue Supplement s1) 44.
- [30] Bond R, Saijonmaa-Koulumies LEM, Lloyd DH. Population Sizes and Frequency of *Malassezia pachydermatis* at Skin and Mucosal Sites on Healthy Dogs. *Journal of Small Animal Practice* 1995; 36 (4) 147–50.
- [31] Hirsh DC, Biberstein, EL. Yeasts - *Cryptococcus*, *Malassezia* and *Candida*. In: Hirsh DC, MacLachlan NJ, Walker RL (eds). *Veterinary Microbiology* 2nd ed. Ames: Blackwell Publishing; 2004. p265-72.

- [32] Plant JD, Rosenkrantz WS, Griffin CE. Factors Associated with and Prevalence of High *Malassezia pachydermatis* Numbers on Dog Skin. *Journal of the American Veterinary Medical Association* 1992; 201(6) 879-82.
- [33] Bond R, Ferguson EA, Curtis CF, Craig JM, Lloyd DH. Factors Associated with Elevated Cutaneous *Malassezia pachydermatis* Populations in Dogs with Pruritic Skin Disease. *Journal of Small Animal Practice* 1996; 37(3) 103-7.
- [34] Mason, K.V.: *Malassezia: Biology, associated diseases and treatment*. In: Annual Members' Meeting AAVD & ACVD, vol.12: proceedings of American Academy of Veterinary Dermatology/ American College of Veterinary Dermatology 1996, Las Vegas, EUA. Harrisburg: American Academy of Veterinary Dermatology; 1996.
- [35] Machado ML, Ferreiro L, Ferreira RR, Corbellini LG, Deville M, Berthelemy M, Guillot J. *Malassezia dermatitis in Dogs in Brazil: Diagnosis, Evaluation of Clinical Signs and Molecular Identification*. *Veterinary Dermatology* 2011; 22(1) 46-52.
- [36] Ihrke, PJ. *Malassezia dermatitis: diagnosis & management*. In: proceedings of 33rd World Small Animal Veterinary Association Congress, 20-24 August 2008, Dublin, Ireland.
- [37] Berger DJ, Lewis TP, Schick AE, Stone RT. Comparison of Once-Daily Versus Twice-Weekly Terbinafine Administration for the Treatment of Canine *Malassezia Dermatitis* - a Pilot Study. *Veterinary Dermatology* 2012; Early View (Online Version of Record published before inclusion in an issue).
- [38] Bond R, Guillot J, Cabañes FJ. *Malassezia Yeasts in Animal Disease*. In: Boekhout T, Guého-Kellermann E, Mayser P, Velegraki A (eds). *Malassezia and the Skin: Science and Clinical Practice*. Heidelberg: Springer; 2010. p.271-92.
- [39] Lacaz, C. S.; Porto, E.; Martins, J. E. C.; Heins-Vaccari, E. M.; Melo, N. T. *Esporotricose e Outras Micoses Gomosas*. In: Lacaz, C. S.; Porto, E.; Martins, J. E. C.; Heins-Vaccari, E. M.; Melo, N. T. (eds.). *Tratado de Micologia Médica Lacaz 9ª. ed.* São Paulo: Sarvier; 2002. p.479-97.
- [40] Kauffman CA. *Sporotrichosis*. *Clinical Infectious Diseases* 1999; 29(2) 231-6; quiz 237.
- [41] Welsh, RD. *Sporotrichosis*. *Journal of the American Veterinary Medical Association* 2003; 223(8) 1123-6.
- [42] Rosser EJ, Dunstan RW. *Sporotrichosis*. In: Greene C (ed.). *Infectious Diseases of the Dog and Cat 3rd ed.* Canada: Elsevier; 2006. p.609-27.
- [43] Larsson CE. *Esporotricose*. *Brazilian Journal of Veterinary Research and Animal Science* 2011; 48(3) 250-9.
- [44] Madrid, I. M.; Xavier, M. O.; Mattei, A. S.; Carapeto, L. P.; Antunes, T. A.; Júnior, R. S.; Nobre, M. O.; Meireles, M. C. A. *Esporotricose Óssea e Cutânea em Canino*. *Brazilian Journal of Veterinary Research and Animal Science*, 2007; 44(6) 441-3.

- [45] Cagnini DQ, Rodrigues MMP, Palumbo MIP, Heckler MCT, Peixoto AS, Amorim RL, Machado LHA. Cytologic Diagnosis and Treatment of Feline Sporotrichosis: Case Report. *Veterinária e Zootecnia* 2012; 19(2) 186-91.
- [46] Boothe DM, Herring I, Calvin J, Way N, Dvorak J. Itraconazole Disposition After Single Oral and Intravenous and Multiple Oral Dosing in Healthy Cats. *American Journal of Veterinary Research* 1997; 58(8) 872-7.
- [47] Grace SF. Cryptococcosis. Norsworthy GD, Grace SF, Crystal MA, Tilley LP (eds). *The feline patient* 4th. ed. Iowa: Blackwell Publishing; 2011. p.97-9.
- [48] Malik R, Wigney DI, Muir DB, Gregory DJ, Love DN. Cryptococcosis in Cats: Clinical and Mycological Assessment of 29 Cases And Evaluation of Treatment Using Orally Administered Fluconazole. *Journal of Medical and Veterinary Mycology* 1992; 30(2) 133-44.
- [49] Chiesa S. C., Castro R. C., Otsuka M., Michalany N. S., Larsson Jr C. E., Larsson C. E. Cryptococcosis in São Paulo (Brazil): Clinical and Epidemiological Features (1992–2003). *Veterinary Dermatology* 2004; 15(Supplement s1) 46.
- [50] Martins DB, Barbosa ALT, Cavalheiro A, Lopes STA, Santurio JM, Schossler JE, Mazzanti A. Diagnóstico De Criptococose Canina pela Citologia Aspirativa por Agulha Fina. *Ciência Rural* 2008; 38(3) 826-9.
- [51] Trivedi SR, Malik R, Sykes JE. Feline Cryptococcosis: Impact of Current Research on Clinical Management. *Journal of Feline Medical Surgery* 2011; 13 (3) 163-172.
- [52] Hunt GB, Foster SF. Nasopharyngeal Disorders. In: Bonagura JD, Twedt DC (eds). *Kirk's Current Veterinary Therapy XIV*. St. Louis: Saunders Elsevier, 2009; 624-25.
- [53] Mueller RS. Treatment Protocols for Demodicosis: an Evidence-Based Review. *Veterinary Dermatology* 2004; 15(2) 75-89.
- [54] Gortel, K. Update on Canine Demodicosis. *Veterinary Clinics of North America: Small Animal Practice* 2006; 36(1) 229-41.
- [55] Rojas M, Riazzo C, Callejón R, Guevara D, Cutillas C. Molecular Study on Three Morphotypes of Demodex Mites (Acarina: Demodicidae) from Dogs. *Parasitology Research* 2012, Online First™, 16 August 2012. <http://www.springerlink.com/content/h0357h6867775g66/fulltext.pdf> (accessed 20 August 2012).
- [56] Baker KP. The Histopathology and Pathogenesis of Demodecosis of the Dog. *Journal of Comparative Pathology* 1969; 79 321-7.
- [57] Mason I, Mason K, Lloyd D. A Review of the Biology of Canine Skin with Respect to the Commensals *Staphylococcus intermedius*, *Demodex canis* and *Malassezia pachydermatis*. *Veterinary Dermatology* 1996; 7(3)119-32.
- [58] Mueller, RS, Bensignor E, Ferrer L, Holm B, Lemarie S, Paradis M, Shipstone MA Treatment of Demodicosis in Dogs: 2011 Clinical Practice Guidelines. *Veterinary Dermatology* 2012; 23(2): 86-96, e20-1.

- [59] Arther RG. Mites and Lice: Biology and Control. *Veterinary Clinics of North America: Small Animal Practice* 2009; 39(6) 1159-71.
- [60] Currier RW, Walton SF, Currier BJ. Scabies in Animals and Humans: History, Evolutionary Perspectives, and Modern Clinical Management. In: *The Evolution of Infectious Agents in Relation to Sex: proceedings of Annals of the New York Academy of Science* 2011; New York, USA.
- [61] Thomsett LR. Structure of Canine Skin. *The British Veterinary Journal* 1986;142(2) 116-23.
- [62] Mueller RS, Bettenay SV, Shipstone M. Value of the Pinnal-Pedal Reflex in the Diagnosis of Canine Scabies. *Veterinary Record* 2001; 148(20) 621-3.
- [63] Greiner E. Diagnosis of Arthropod Parasites. In: Zajac AM, Conboy GA. *Veterinary Clinical Parasitology*. 8<sup>th</sup> ed. Hoboken: Wiley-Blackwell, 2012: 217-303.
- [64] Folz SD, Kratzer DD, Kakuk TJ, Rector DL. Evaluation of a Sponge-On Therapy for Canine Scabies. *Journal of Veterinary Pharmacology and Therapeutics* 1984; 7(1) 29–34.
- [65] Curtis, C.F. Use of 0.25 Per Cent fipronil Spray to Treat Sarcoptic Mange in a Litter of five-Week-Old Puppies. *Veterinary Record* 1996; 139(2) 43–44.
- [66] Paradis M. Ivermectin in Small Animal Dermatology. Part II. Extralabel Applications. *Compendium of Continuing Education for the Practicing Veterinarian* 1998; 20: 459–69.
- [67] Curtis CF. Current Trends in the Treatment of Sarcoptes, Cheyletiella and Otodectes Mite Infestations in Dogs and Cats. *Veterinary Dermatology* 2004; 15(2) 108-114.
- [68] Six RH, Clemence RG, Thomas CA, Behan S, Boy MG, Watson P, Benchaoui HA, Clements PJ, Rowan TG, Jernigan AD. Efficacy and Safety of Selamectin Against *Sarcoptes scabiei* on Dogs and *Otodectes cynotis* on dogs and Cats Presented as Veterinary Patients. *Veterinary Parasitology* 2000; 91(3-4) 291–309.
- [69] Miller Jr WH, Jaham C, Scott DW, Cayatte SM, Bagladi MS, Buerger RG. Treatment of Canine Scabies with Milbemycin Oxime. *Canadian Veterinary Journal* 1996; 37(4) 219–21.
- [70] Rust MK, Dryden MW. The Biology, Ecology, and Management of the Cat Flea. *Annual Review of Entomology* 1997; 42 451-473.
- [71] Carlotti DN, Jacobs DE. Therapy, Control and Prevention of Flea Allergy Dermatitis in Dogs and Cats. *Veterinary Dermatology* 2000; 11(2) 83-98.
- [72] Gross TL, Halliwell REW. Lesions of Experimental Flea Bite Hypersensitivity in the Dog. *Veterinary Pathology* 1985; 22(1) 78-81.

- [73] Wilkerson MJ, et al. The Immunopathogenesis of the Flea Allergy Dermatitis in Dogs, an Experimental Study. *Veterinary Immunology and Immunopathology* 2004; 99 (3-4) 179-92.
- [74] Dryden MW. Flea and Tick Control in the 21st Century: Challenges and Opportunities. *Veterinary Dermatology* 2009; 20 (5-6) 435-440.
- [75] Jackson HA. Diagnostic Techniques in Dermatology: The Investigation and Diagnosis of Adverse Food Reactions in Dogs and Cats. *Clinical Techniques in Small Animal Practice* 2001; 16(4) 233-235.
- [76] Hillier A, Griffin CE. The ACVD Task Force on Canine Atopic Dermatitis (X): Is There a Relationship Between Canine Atopic Dermatitis and Cutaneous Adverse Food Reactions? *Veterinary Immunology and Immunopathology* 2001; 81(3-4) 227-231.
- [77] Hensel P. Nutrition and Skin Diseases in Veterinary Medicine. *Clinics in Dermatology* 2010; 28(6) 686-693.
- [78] Bloom P. Cutaneous Adverse Food Reactions in Dogs: Something New to Chew On. *The Veterinary Journal* 2011; 187(3) 289.
- [79] Ricci R, et al. A Comparison of the Clinical Manifestations of Feeding Whole and Hydrolysed Chicken to Dogs with Hypersensitivity to the Native Protein. *Veterinary Dermatology* 2010; 21(4) 358-366.
- [80] Halliwell R. Revised Nomenclature for Veterinary Allergy. *Veterinary Immunology and Immunopathology* 2006; 114(3-4) 207-208.
- [81] Scott DW, Paradis M. A Survey of Canine and Feline Skin Disorders Seen in a University Practice: Small Animal Clinic, University of Montréal, Saint-Hyacinthe, Québec (1987-1988). *Canadian Veterinary Journal* 1990; 31(12) 830-835.
- [82] DeBoer DJ, Hillier A. The ACVD Task Force in Canine Atopic Dermatitis (XV): Fundamental Concepts in Clinical Diagnosis. *Veterinary Immunology and Immunopathology* 2001; 81(3-4) 271-276.
- [83] Olivry T, DeBoer DJ, Favrot C, Jackson HA, Mueller RS, Nuttall T, Prélaud P. Treatment of Canine Atopic Dermatitis: 2010 Clinical Practice Guidelines from the International Task Force on Canine Atopic Dermatitis. *Veterinary Dermatology* 2010; 21(3) 233-248.
- [84] Hill PB, DeBoer DJ. The ACVD Task Force in Canine Atopic Dermatitis (IV): Environmental Allergens. *Veterinary Immunology and Immunopathology* 2001; 81(3-4) 169-86.
- [85] Olivry T, Sousa CA. The ACVD Task Force in Canine Atopic Dermatitis (XIX): General Principles of Therapy. *Veterinary Immunology and Immunopathology* 2001; 81(3-4) 311-16.



- [86] Bloom P. Atopic Dermatitis in Dogs – Hitting the Moving Target. *The Veterinary Journal* 2006; 171(1) 16-7.
- [87] Bousquet J, et al. Allergen Immunotherapy: Therapeutic Vaccines for Allergic Diseases A WHO Position Paper. *Journal of Allergy and Clinical Immunology* 1998; 102(4) 558-62.
- [88] Griffin CE, Hillier A. The ACVD Task Force in Canine Atopic Dermatitis (XXIV): Allergen-specific Immunotherapy. *Veterinary Immunology and Immunopathology* 2001; 81(3-4) 363-83.
- [89] Olivry T, Foster AP, Mueller RS, McEwan NA, Chesney C, Williams HC. Interventions for Atopic Dermatitis in Dogs: a Systematic Review of Randomized Controlled Trials. *Veterinary Dermatology* 2010; 21(1) 4-22.
- [90] Nuttall TJ, McEwan NA, Bensignor E, Cornegliani L, Löwenstein C, Rème CA.. Comparable Efficacy of a Topical 0.0584% Hydrocortisone Aceponate Spray and Oral Ciclosporin in Treating Canine Atopic Dermatitis. *Veterinary Dermatology* 2011; 23(1) 4-e2.
- [91] Bensignor E, Olivry T. Treatment of Localized Lesions of Canine Atopic Dermatitis With Tacrolimus Ointment: a Blinded Randomized Controlled Trial. *Veterinary Dermatology* 2005; 16(1) 52-60.
- [92] Gorman NT, Werner LL. Immune-Mediated Diseases of the Dog And Cat. III. Immune-Mediated Diseases of the Integumentary, Urogenital, Endocrine and Vascular Systems. *British Veterinary Journal* 1986; 142(6) 491-7.
- [93] Day MJ, Hanlon L, Powell LM. Immune-Mediated Skin Disease in the Dog and Cat. *Journal of Comparative Pathology* 1993; 109(4) 395-407.
- [94] Day MJ, Shaw SE. Immune-Mediated Skin Disease. In: Day MJ. *Clinical Immunology of the Dog and Cat*. 2nd ed. London: Manson Publishing; 2008. p.148-55.
- [95] Scott DW, Manning TO, Smith CA, Lewis RM. Pemphigus and Pemphigoid in Dogs, Cats, and Horses. *Annals of the New York Academy of Sciences* 1983; 420 (Defined Immunofluorescence and Related Cytochemical Methods) 353-60.
- [96] Mueller RS, Krebs I, Power HT, Fieseler KV. Pemphigus Foliaceus in 91 Dogs. *Journal of the American Animal Hospital Association* 2006; 42(3) 189-196.
- [97] Tater KC, Olivry T. Canine and Feline Pemphigus Foliaceus: Improving Your Chances of a Successful Outcome. *Veterinary Medicine* 2010; 105(1) 18-30.
- [98] Rosenkrantz WS. Pemphigus: Current Therapy. *Veterinary Dermatology* 2004; 15(2) 90-98.
- [99] Gershwin LJ. Autoimmune Diseases in Small Animals. *Veterinary Clinics of North America: Small Animal Practice* 2010; 40(3) 439-457.

- [100] Griffin CE, Stannard AA, Ihrke PJ, Ardans AA, Cello RM, Bjorling DR. Canine Discoid Lupus Erythematosus. *Veterinary Immunology and Immunopathology* 1979; 1(1) 79-87.
- [101] Griffies JD, Mendelsohn CL, Rosenkrantz WS, Muse R, Boord MJ, Griffin CE. Topical 0.1% Tacrolimus for the Treatment of Discoid Lupus Erythematosus and Pemphigus Erythematosus in Dogs. *Journal of the American Animal Hospital Association* 2004; 40(1) 29-41.
- [102] Scott-Moncrieff JC, Guptill-Yoran L. Hipotireoidismo. In: Ettinger SJ, Feldman EC. *Tratado de Medicina Interna Veterinária*. 5.ed. Rio de Janeiro: Guanabara Koogan; 2004. p.1496-506.
- [103] Ferguson D.C. Update on Diagnosis of Canine Hypothyroidism. *Veterinary Clinics of North America: Small Animal Practice* 1994; 24(3) 515-39.
- [104] Meeking SA. Thyroid Disorders in the Geriatric Patient. *Veterinary Clinics of North America: Small Animal Practice* 2005; 35(3) 635-53.
- [105] Graham PA, Refsal KR, Nachreiner RF. Etiopatologic Findings of Canine Hypothyroidism.. *Veterinary Clinics of North America: Small Animal Practice* 2007; 37(4) 617-31.
- [106] Panciera DL. Hypothyroidism in Dogs: 66 Cases (1987–1992). *Journal of the American Veterinary Medical Association* 1994; 5 (204) 761-7.
- [107] Dixon RM, Reid SWJ, Mooney CT. Epidemiological, Clinical, Haematological and Biochemical Characteristics of Canine Hypothyroidism. *Veterinary Record* 1999; 145(17) 481–7.
- [108] Scott-Moncrieff JC. Clinical Signs and Concurrent Diseases of Hypothyroidism in Dogs and Cats. *Veterinary Clinics of North America: Small Animal Practice* 2007; 37(4) 709-22.
- [109] Lust E. Thyroid Disease in Canines and Felines. *US Pharmacist* 2005; 30(06) 41-9.
- [110] Arias PT. Hipotiroidismo canino. *Virbac al Día Animales Compañía*. 16: 1-6 <http://www.webveterinaria.com/virbac/news19/hipotiroidismo.pdf> (accessed 08 August 2012).
- [111] Panciera DL. Canine Hypothyroidism. Part II. Thyroid Function Tests and Treatment. *Continuing Education Article – The Compendium Small Animal* 1990; 12(6) 843-58.
- [112] Peterson M.E. Hyperadrenocorticism. *Veterinary Clinics of North America* 1984; 14: 731-49.
- [113] Kaufman J. Diseases of the Adrenal Cortex of Dogs and Cats. *Modern Veterinary Practice* 1984; 65(6) 429-34.

- [114] Peterson ME. Diagnosis of Hyperadrenocorticism in Dogs. *Clinical Techniques in Small Animal Practice* 2007; 22(1) 2-11.
- [115] Peterson, M.E. Diagnosis of hyperadrenocorticism in dogs. In: Cavender A, Davidson M, Gibbs S, Green C, Holley C, Johnston D, Kovacs S. *Proceedings of the 16th Annual North Carolina Veterinary Conference, 4-6 November 2011, Raleigh, USA.*
- [116] Goossens MMC, Meyer HP, Voorhout G, Sprang EP. Urinary Excretion of Glucocorticoids in the Diagnosis of Hyperadrenocorticism in Cats. *Domestic Animal Endocrinology* 1995; 12(4) 355-62.
- [117] Ghubash R, Marsella R, Kunkle G. Evaluation of Adrenal Function in Small-Breed Dogs Receiving Otic Glucocorticoids. *Veterinary Dermatology* 2004; 15(6) 363-68.
- [118] Peterson ME. Treatment of canine hyperadrenocorticism. In: Cavender A, Davidson M, Gibbs S, Green C, Holley C, Johnston D, Kovacs S. *Proceedings of the 16th Annual North Carolina Veterinary Conference, 4-6 November 2011, Raleigh, USA*
- [119] Paradis M. Melatonin Therapy for Canine Alopecia. In: *Kirk's Current Veterinary Therapy XIII Small Animal Practice*. Philadelphia: W.B. Saunders; 2000. p.546-9.
- [120] Paradis M. Melatonin Therapy in Canine Pattern Baldness. In: Kwochka KW, Willemse T, Von Tscharner C. *Advances in Veterinary Dermatology: proceedings of the Third World Congress of Veterinary Dermatology, 11-14 September 1996, Edinburgh, Scotland*. London: Elsevier Health Sciences; 1996.
- [121] Ferrer, L. Follicular dysplasias. In: 4th European Federation of European Companion Animal Veterinary Associations, Società Culturale Italiana Veterinari per Animali da Compagnia Congress: conference proceedings of the 4th European FECAVA SCI-VAC Congress, 18-21 June 1998, Bologna, Italy.
- [122] Cerundolo R. Symmetrical Alopecia in the Dog. *In Practice* 1999; 21(7) 350-9.
- [123] Rothstein E, Scott DW, Miller WH Jr, et al. A Retrospective Study of Dysplastic Hair Follicles and Abnormal Melanization in Dogs with Follicular Dysplasia Syndromes or Endocrine Skin Disease. *Veterinary Dermatology* 1998; 9(4) 235-41.
- [124] Rachid MA, Demaula CD, Scott DW, Miller WH, Senter DA, Myers S. Concurrent Follicular Dysplasia and Interface Dermatitis in Boxer Dogs. *Veterinary Dermatology* 2003; 14(3) 159-166.
- [125] Scott DW, Miller WH Jr. Retrospective Record Review of Canine Postclipping Hair Follicle Arrest. *Veterinary Dermatology* 2012; 23(3) 248-9.
- [126] Diaz SF, Torres SMF, Dunstan RW, Lekcharoensuk C. An Analysis of Canine Hair Re-Growth After Clipping for a Surgical Procedure. *Veterinary Dermatology* 2004; 15(1) 25-30.
- [127] Rest JR, Lloyd DH, Cerundolo R. Histopathology of Alopecia X. *Veterinary Dermatology* 2004; 15(Supplement s1) 23.

- [128] Frank LA. Growth Hormone-Responsive Alopecia in Dogs. *Journal of the American Veterinary Medical Association* 2005; 226(9) 1494–7.
- [129] Cerundolo R, Lloyd DH, Persechino A, Evans H, Cauvin A. Treatment of Canine Alopecia X with Trilostane. *Veterinary Dermatology* 2004; 15(5) 285-93.
- [130] Campbell KL. Seborrheic Skin Disorders and Their Treatment in Dogs. *Clinics in Dermatology* 1994; 12(4) 551-8.
- [131] Halliwell RE. Seborrhea in the Dog. *Compendium on Continuing Education for the Practicing Veterinarian* 1979; 1 227-36.
- [132] Ihrke PJ. Canine Seborrheic Disease Complex. *Veterinary Clinics of North America* 1979; 9 93-106.
- [133] Gross TL, Ihrke PJ, Walder EJ, Affolter, VK. Diseases with Abnormal Cornification. In: Gross TL, Ihrke PJ, Walder EJ, Affolter, VK. *Skin Diseases of the Dog and Cat: Clinical and Histopathologic Diagnosis, Second Edition*. Oxford: Blackwell Science; 2005. p.161-98.
- [134] Noli, C. Seborrhea: why and how does it happen? *World Small Animal Veterinary Association: proceedings of the 28th World Congress of the WSAVA 24-27 October 2003, Bangkok, Thailand*. Ontario: World Small Animal Veterinary Association, 2003.
- [135] Rosenkrantz, W. Practical Applications of Topical Therapy for Allergic, Infectious, and Seborrheic Disorders. *Clinical Techniques in Small Animal Practice* 2006; 21(3)106-16.
- [136] Rosenkrantz WS. The Pathogenesis, Diagnosis, and Management of Feline Acne. *Veterinary Medicine* 1991; 86(5) 504-12.
- [137] Jazic E, Coyner KS, Loeffler DG, Lewis TP. An Evaluation of the Clinical, Cytological, Infectious and Histopathological Features of Feline Acne. *European Society of Veterinary Dermatology* 2006; 17(2) 134-40.
- [138] White, S, Bordeau P, Blumstein P, Ibisch C, Re EG, Denerolle P, Carlotti DN, Scott KV. Feline Acne and Results of Treatment with Mupirocin in an Open Clinical Trial: 25 Cases (1994–96). *Veterinary Dermatology* 1997, 8(3): 157-64.
- [139] Werner AH, Power HT. Retinoids in Veterinary Dermatology. *Clinics in Dermatology* 1994; 12(4) 579-86.
- [140] Hnilica KA. Keratinization and Seborrheic Disorders. In: Hnilica KA. *Small Animal Dermatology: A Color Atlas and Therapeutic Guide, 3rd edition*. Canadá: Elsevier; 2011. p360-1.
- [141] MacDonald JM, Bradley DM. Acral Lick Dermatitis. In: Bonagura JD (ed). *Kirk's Current Veterinary Therapy XIV: Small Animal Practice*. St Louis: WB Saunders; 2009. P468–73.

- [142] Virga V. Behavioral Dermatology. *Veterinary Clinics of North America: Small Animal Practice* 2003; 33(2) 231-51.
- [143] Wynchank D, Berk M. Fluoxetine Treatment of Acral Lick Dermatitis in Dogs: a Placebo-Controlled Randomized Double Blind Trial. *Depression and Anxiety* 1998; 8(1) 21-3.
- [144] Watson TDG. Diet and Skin Diseases in Dogs and Cats. *Journal of Nutrition* 1998; 128(12) 2783S-2789S.
- [145] Dethioux F. Nutrition, Skin Health and Coat Quality. *Veterinary Focus* 2008; 18(1) 40-6.
- [146] Colombini S., Dunstan RW. Zinc-Responsive Dermatitis in Northern-Breed Dogs: 17 Cases (1990-1996). *Journal of the American Veterinary Medical Association* 1997; 211(4) 451-3.
- [147] Hall, J. Diagnostic Dermatology. Zinc Responsive Dermatitis. *Canadian Veterinary Journal* 2005; 46(6) 555-7.
- [148] Getty R, Foust HL, Prestley ET, Miller ME. Macroscopic Anatomy of the Ear of the Dog. *American Journal of Veterinary Research* 1956; 17(64) 364-75.
- [149] Goth GM. Doenças do Ouvido Externo no Cão e no Gato. *Veterinary Focus* 2011; 21(3) 2-9.
- [150] McKeever PJ. Otitis Externa. *Compendium on Continuing Education for the Practicing Veterinarian* 1996; 18(7) 759-73.
- [151] Rosser EJ Jr. Causes of Otitis Externa. *Veterinary Clinics of North America: Small Animal Practice* 2004; 34(2) 459-468.
- [152] August JR. Otitis Externa: a Disease of Multifactorial Etiology. *Veterinary Clinics of North America: Small Animal Practice* 1988; 18(4) 731-42.
- [153] Merchant SR. Medically Managing Chronic Otitis Externa and Media. *Veterinary Medicine* 1997; 92(6) 515-34.
- [154] Bond R. Selecting Ear Drops for Dogs with Otitis Externa. *In Practice* 2012; 34(7) 392-9.
- [155] Paterson S. Diagnostic Approach to Otitis in Dogs. *Today's Veterinary Practice* 2011; 1(2): 27-32.
- [156] Cole LK. Otoscopic Evaluation of the Ear Canal. *Veterinary Clinics of North America: Small Animal Practice* 2004; 34(2) 397-410.
- [157] Fourie LJ, Kok DJ, Heine J. Evaluation of the Efficacy of an Imidacloprid 10% / Moxidectin 1% Spot-on Against *Otodectes cynotis* in Cats. *Parasitology Research* 2003; 90(3) S112-S113.
- [158] Morris DO. Medical Therapy of Otitis Externa and Otitis Media. *Veterinary Clinics of North America: Small Animal Practice* 2004; 34(2) 541-55.