

We are IntechOpen, the world's leading publisher of Open Access books Built by scientists, for scientists

4,800

Open access books available

122,000

International authors and editors

135M

Downloads

Our authors are among the

154

Countries delivered to

TOP 1%

most cited scientists

12.2%

Contributors from top 500 universities



WEB OF SCIENCE™

Selection of our books indexed in the Book Citation Index
in Web of Science™ Core Collection (BKCI)

Interested in publishing with us?
Contact book.department@intechopen.com

Numbers displayed above are based on latest data collected.

For more information visit www.intechopen.com



Vascular Access for Hemodialysis - How to Maintain in Clinical Practice

Hossam Elwakeel and Khaled Elalfy

Additional information is available at the end of the chapter

<http://dx.doi.org/10.5772/54352>

1. Introduction

Establishing and maintaining hemodialysis access is a cornerstone of long term renal replacement therapy. As hemodialysis techniques have improved sufficiently to allow the survival of patients as long as dialysis access can be maintained so it is justified to say that vascular access is an access to life [1].

2. Historical background

Since 1944 when WJ Kolff designed the first practical dialysis machine, the search for vascular access for hemodialysis began and still continued until nowadays. At first, it was necessary to do repeated cutdowns on an artery and vein for each dialysis, following which the vessels were ligated, so dialysis was therefore limited to the treatment of acute renal failure [2].

Chronic access to the circulation became a reality in 1960 when Scribner, Dillard, and Quinton introduced the Teflon-Silastic arteriovenous (AV) shunt. The Scribner shunt rarely could be used for more than 3 months because of: interference of the external appliance with normal activity, infection, thrombosis, and bleeding [3]. These disadvantages were overcome by introduction of the subcutaneous AV fistula by Brescia, Cimino, Appel and Hurwich in 1966 which is a fistula between the artery above the wrist and the largest available vein in close proximity [4]. Their innovative approach remains the initial procedure of choice in patients who are candidates for long term hemodialysis.

Subsequent development of the bridge fistula, initially with reversed saphenous vein [5] and later with synthetic materials, further expanded the availability of hemodialysis to a larger

population. The introduction of polytetrafluoroethylene (PTFE) for bridge fistulae in 1976 [6] was another milestone in dialysis access surgery.

3. Haemodynamics of arteriovenous fistula (AVF)

The physiologic effects of AV fistulas can be separated into local haemodynamic effects and systemic cardiovascular effects [7].

- Local haemodynamic effects:

The effect of creating a fistula on the proximal artery is similar to making a hole in a dike. Flow in the proximal artery increases markedly in response to the sudden decrease in outflow pressure afforded by the fistula, so with forearm AV fistulas, brachial artery flow may increase 5 to 10 folds [8].

In the distal artery, the situation is not so simple. With small fistula, distal artery flow is maintained antegrade, away from the heart. With increasing fistula size, however, distal artery flow decreases until it reaches a standstill when the anastomotic length is equal to the proximal artery diameter. At this point, circus motion develops with antegrade flow during systole and retrograde flow during diastole through the fistula into the venous limbs. When the anastomotic length of the fistula communication increases, above the diameter of the proximal artery, reversed flow in the distal artery increases until it exceeds the antegrade flow [9].

- Systemic haemodynamic effects:

The immediate effect of opening a fistula is to divert blood flow away from the rest of the peripheral circulation and into a special low-resistance path directly connecting the left side to the right side of the heart. Cardiac output increases acutely via increased rate and stroke volume. Arterial pressure falls, and heart rate increases; these changes are minimal with low-flow fistulas and increase with increasing fistula flow. Cardiac work also increases [10].

4. Preoperative evaluation

4.1. Patient preparation for permanent hemodialysis access (modified from NKF, 2006 [11])

Good planning allows initiation of dialysis at the proper time with a permanent functioning access in place ready at the start of dialysis.

- Patients with a glomerular filtration rate (GFR) less than 30 mL/min/1.73 m² and chronic kidney disease (CKD) stage 4 should be educated about all modalities of kidney replacement therapy (KRT) options, including transplantation, so that timely referral can be made for the appropriate modality and placement of a permanent dialysis access, if necessary.
- In patients with CKD stage 4 or 5, the following policy of vein preservation should be adopted:

- Strict avoidance of cannulation of veins of both forearms proximal to the wrist.
- When unavoidable, venipuncture should be performed in the dominant arm to preserve the non-dominant arm for AVF; or alternatively, rotation of puncture sites and sides could be used.
- Phlebocatheters should not be threaded to central veins through cephalic or basilic veins at the elbow.
- Instead, central vein catheters should be inserted into jugular veins (preferably on the right side).
- Insertion via subclavian veins is to be avoided because of very frequent subsequent stenosis.
- In cases where vein diameter/flow is the critical factor influencing the use of central veins (as when concentrated potentially caustic/toxic solutions are to be infused), one should consider using femoral veins [12].
- Patients should have a functional permanent access at the initiation of dialysis therapy:
 - A fistula should be placed at least 6 months before the anticipated start of HD treatments. This timing allows for access evaluation and gives additional time for revision to ensure a working fistula is available at initiation of dialysis therapy.
 - A graft should, in most cases, be placed at least 3 to 6 weeks before the anticipated start of HD therapy. However, some newer graft materials may be cannulated immediately after placement.
- Evaluations that should be performed before placement of a permanent HD access include:
 - a. History and physical examination:
 - Arterial inflow evaluation by: pulse examination of the accessible sites in upper extremity and lower extremity when needed [13] and Allen's test for assessment of palmar arch efficacy [14].
 - Venous outflow evaluation by: placing the arm in a dependent position or by placing a tourniquet on the upper arm while the patient clenches and releases the ipsilateral hand several times.
 - b. Duplex ultrasound of the upper-extremity arteries and veins:
 - To determine the diameter of the artery as a preoperative radial artery diameter of less than 1.6 mm usually will lead to failure of the radial-cephalic wrist autogenous AV access [7].
 - To assess superficial veins and deep veins for stenosis or occlusion and diameter which should be at least 2.5 mm [7].
 - Conventional arteriography or magnetic resonance angiography: Used in selected cases [7].
 - Central vein evaluation in the appropriate patient known to have a previous catheter or pacemaker.

(Modified from NKF, 2006 [11])

5. Different modalities of AVF

The 2006 updated version of the National Kidney Foundation Kidney Disease Outcomes Quality Initiative (KDOQI) urges for an increase in autogenous arteriovenous fistula (AVF) use in hemodialysis patients to a minimum of 65%, which is almost the same as the current goal of 66% raised by the Fistula First Breakthrough Initiative (FFBI).

5.1. Autogenous AVF

5.1.1. Forearm options

- Cephalic vein

a. Radial-cephalic (anatomical snuffbox) AVF:

Construction of a radial-cephalic AVF at the anatomical snuffbox mandates proper patient selection. The advantages are: proximity of the vessels and preservation of additional length of vein for cannulation. However, the disadvantages are the smaller vessel size which leads to greater surgical challenges, lower flow rate and less long term patencies than more proximal constructions [15].

b. Radial-cephalic AVF (wrist, direct or transposed, straight):

The advantages are larger vessel size, simplicity of anastomosis and lower risk of ischemic complications. The fistula can be done via various construction configurations, the most common is side-to-side and end vein to side artery (figure 1). The end-to-end was assumed to avoid ischemic consequences, however, it has the lowest flow and scarifying the radial artery can later compromise hand perfusion especially in the case of an associated progressive distal arterial occlusive disease. The advantage of an end vein to side artery configuration is minimizing venous hypertension risk. Moreover, flow and pressure in the preferred antegrade direction through the vein is increased by ligation of the distal vein and nearby tributaries. If the cephalic vein is too deep for cannulation, the vein should be transposed to a superficial location [16]. It remains the gold standard AVF.

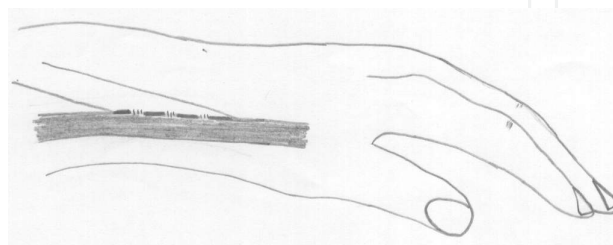


Figure 1. End to side radial-cephalic AVF

c. Proximal radial or brachial-cephalic AVF (transposed, loop):

When the distal radial artery is inadequate, the cephalic vein can be looped back to the antecubital region and anastomosed to the brachial or a branch artery preferably the proximal radial artery (PRA), as it lowers the risk of steal and ischemia. Transposed loop AVFs in the forearm are excellent alternatives when the distal radial or ulnar arteries are not suitable [17].

- Basilic vein

- a. Radial (or ulnar)-basilic AVF (transposed, straight):

If a radial-cephalic AVF in the forearm is not feasible, and the basilic vein is suitable, the vein can be anastomosed to either the ulnar or radial artery. It is recommended to transpose the vein to the volar aspect of the forearm because the anatomic location of the basilic vein makes it vulnerable to cannulation difficulties and complications, especially infiltrations from the patient resting the forearm on the needles [18].

- b. Brachial (or proximal radial)-basilic AVF (transposed, loop):

This transposed loop configuration is the same as that described for the cephalic vein above, except that the forearm basilic vein is used when the cephalic vein is unavailable [19].

- Antecubital vein

- a. Gracz perforator, median cubital veins:

The use of the antecubital veins in the creation of upper arm and reverse flow AVFs is ideal. The advantages are (i) the provision of multiple outflows, i.e., into the upper arm cephalic and basilic veins in antegrade fashion, as well as retrograde into the forearm veins by limited disruption of venous valves (when desired); (ii) preservation of continuity of the major AVF venous conduit for future use or revision of the AVF; and (iii) provision of an ischemic-resistant (flow-restricting) construction due to limited size of the anastomosis and lumen of the vein. In the operation described by Gracz et al. [20], the perforating vein connecting between the superficial system and the deep brachial system is transected and used for the anastomosis to create an upper arm AVF. The median cubital or other available nearby vein may be used, depending on the anatomy. Very high patency rates (80% at 3 years) have been reported for both constructions [21].

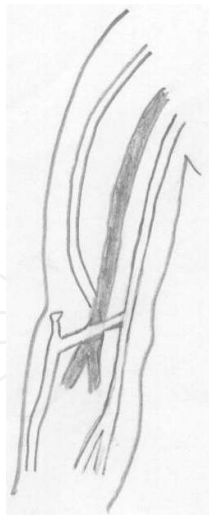


Figure 2. Brachial-cephalic AVF

5.1.2. Arm options

- **Cephalic vein**

- a. Brachial (or proximal radial)-cephalic AVF (direct or transposed):

The cephalic vein is ideally anastomosed to the artery just distal to the antecubital crease by using: an antecubital vein (as a first option), the cephalic vein itself (figure 2) or one of its tributaries all of them should be freed up distally into the forearm sufficiently to allow for a distal anastomosis into the proximal radial artery which is the inflow artery of choice or to the brachial artery (when used as inflow, the anastomosis should be limited to 4-5 mm to avoid ischemia or ischemic monomelic neuropathy). If the cephalic vein is too deep for safe cannulation, the vein should be transposed. During transpositions, it is critical to place the vein superficially and away from any incision or scars, thus allowing identification of the depth of the vein for easy cannulation. However, simple elevation and liposuction have been recently utilized when the vein is deep [22].

- **Brachial vein**

Brachial (or proximal radial)-basilic transposition AVF (1 or 2 stages):

The basilic vein is routinely transposed because there is only a short segment above the antecubital crease superficial enough for easy cannulation before the vein runs deep to the fascia. Even in very thin patients, where the vein can be seen and palpated, if the vein is not transposed, there is a danger of injuring the brachial artery during cannulation. The vein should be harvested from the axilla till below the antecubital crease for a short distance into the forearm (figure 3), in order to gain additional vein length. This additional vein length gives the advantages of: (i) having the tunnel in a lateral position without tension on the anastomosis which is very important especially in obese patients, (ii) allowing for anastomosing the vein distally to the proximal radial artery if it is suitable, (iii) important for easy cannulation as well

as any further revisions. Some surgeons use a single incision, while others use multiple incisions. Care is needed to (i) identify and protect the median brachial cutaneous nerve, which courses over the vein; (ii) to avoid torsion of the vein by marking it with dye before dissecting it from its bed; (iii) avoid tension on the vein or kinking in its tunnel; and (iv) limit the size of the anastomosis to reduce the risk of steal-induced ischemia if the brachial artery is used as inflow. The surgery can be performed in 1 or 2 stages. In the 2-stage approach, the basilic vein is simply anastomosed to the distal brachial artery, preferably in the antecubital region just distal to the crease. The distal anastomosis is necessary to ensure adequate length of vein for the second stage. After 4-8 weeks, a duplex ultrasound or fistulogram is performed to ensure that there are no anatomic problems. The second stage is then performed by either; transecting the vein close to the anastomosis, bringing the vein through a lateral tunnel and anastomosing the transposed vein to the vein cuff or the artery at a nearby location (preferably to the proximal radial artery), depending on the length of the available vein [23] or just by simply dividing the deep fascia and subcutaneous tissue with positioning of the vein in a more superficial plane [24]. The advantage of the 2-stage procedure is that the vein becomes arterialized, more durable and can be dissected and manipulated with very little risk of injury. Also, it affords protection against the development of stenosis by waiting for arterIALIZATION before transposition, especially with respect to the fairly common “swing-point” stenosis, where the vein turns down toward the axilla [23].

There are recent reports of endoscopic basilica vein transposition [25].

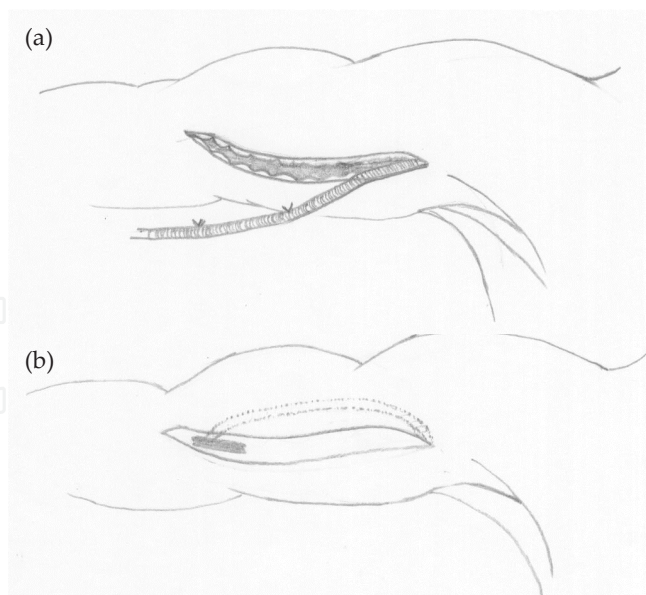


Figure 3. (a) Basilic vein harvest. (b) Transposed brachial-basilic AVF.

- Brachial vein

- a. Brachial-brachial transposition or elevation AVF (1 or 2 stages):

This procedure is rather recent and usually done in 2 stages. The 2-stage approach is essential, given the small and fragile characteristics of the brachial vein(s); delaying the second stage until 4-8 weeks or more provides additional maturation time to allow this small vein to be manipulated without injury. Elevation rather than transposition may be preferred because of the limited length of vein available for cannulation if transposed. The obese patient with a big arm is probably not a candidate for this procedure, as most of the elevated vein will be used to twice traverse the considerable distance between the fascia and skin [26, 27]

5.1.3. Lower extremity options

AVFs in the lower extremity are generally reserved for patients whom all upper extremity sites have been exhausted. Reasons are: higher rates of infection and ischemia, as well as the need to preserve the saphenous veins for coronary artery bypass and other bypass procedures [19].

- Saphenous vein

- a. Femoral-saphenous transposed loop AVF and superficial femoral (or popliteal)-saphenous transposed straight AVF:

The long saphenous vein can be used to either construct a thigh AVF (loop or straight configuration). In the thigh loop configuration, an incision is made below the inguinal crease. The vein is dissected through a single or multiple incisions to the level of the knee and looped back through a subcutaneous tunnel and anastomosed to the common or superficial femoral artery. In the straight configuration, the vein is anastomosed distally to the superficial femoral or popliteal artery [28].

- b. Translocation of saphenous vein to upper extremity:

In the 1970s, saphenous vein was usually translocated to the upper extremity as a forearm loop. The indications were patient preference, concern about a higher infection rate in the groin region and greater risk of vascular complications associated with lower limb access. Intimal hyperplasia and stenosis at the venous anastomosis was not known at the time a problem which is avoided by performing the procedure in the thigh [29].

- c. Posterior (or anterior) tibial-saphenous direct AVF:

An AVF constructed at the ankle is analogous to a wrist AVF, it is recommended to evaluate the patient with duplex ultrasound and with arteriogram and venogram in selected cases. The posterior tibial is preferred to the anterior tibial artery for inflow because this location provides more protection for the AVF and it is technically easier [19].

- Femoral vein

- a. Femoral-femoral transposed loop AVF and superficial femoral (or popliteal)-femoral transposed straight AVF:

AVF options and configurations utilizing the (superficial) femoral vein are the same as for the saphenous vein, whereby the superficial femoral vein is dissected from groin to knee and either brought through a subcutaneous tunnel in straight fashion and anastomosed to the distal

superficial femoral artery, or brought through as a loop back to the groin incision and anastomosed to the common or superficial femoral artery. Initially reported results were not always excellent and high access flow was an important cause of complications [30].

b. Translocation of femoral vein to upper extremity:

As with the saphenous vein, the femoral vein can be translocated to the upper extremity. The potential advantages are a less risk of infection and clinically significant ischemia, compared with lower extremity access. Translocating the femoral vein with its large-diameter and very low-resistance to the brachial artery is expected to have very high flow, so the diameter of the arterial anastomosis should not be more than 4-5 mm or it is better to use the PRA for inflow [31].

5.1.4. Reverse (retrograde)-flow AVF

With reverse-flow AVFs, venous valves must be destructed to permit retrograde flow with or without antegrade flow. The proximal vein may be ligated or not (antegrade flow maintained or not). The ideal patient for a reverse-flow AVF has exhausted forearm options but still has a suitable proximal segment of cephalic or basilic vein in the forearm, with or without a suitable upper arm vein for outflow. A side-to-side antecubital construction is usually made and 1 or 2 distal valves are carefully disrupted with the vein segment dissected and visualized as the probe is passed, to prevent tearing the vein. Valve disruption can be accomplished with a probe, coronary artery dilator or a valvulotome. The retrograde pressure and flow is expected to make progressive dilatation of venous tributaries. If these small veins do not mature adequately, endovascular balloon angioplasty may be used [32].

5.2. Arteriovenous graft (AVG) for hemodialysis

The ideal vascular graft for patients on HD should be easy to handle, closely mimicking the native vessels, nonthrombogenic, immunologically inert, resistant to infection and puncture trauma, able to retain tensile strength, and manufactured at a reasonable cost [33].

5.2.1. AVGs are either biological or synthetic

- Biological grafts
 - a. Autogenous greater saphenous vein should have been the first option in AV bridge graft construction but has generally given disappointing results with patency rates of 20% at 2 years [34, 35].
 - b. Denatured homologous vein allograft.
 - c. Cryopreserved saphenous vein
 - d. Bovine heterografts such as:
 - Bovine carotid artery

- SynerGraft Vascular Graft Model 100 (SGVG 100), a decellularized non-chemically cross linked bovine ureter vascular graft which provides a safe alternative for patients with a history of multiple failed synthetic grafts.
- Bovine mesenteric vein: obtained by a patented process of glutaraldehyde cross linking and gamma radiation has physiological properties similar to those of the human saphenous vein, due to its high elastin to collagen ratio [36] and is reported to have better survival than PTFE [37].
- e. Human umbilical vein.
- f. Sheep collagen grafts [36, 38-41].
- The Omniflow prosthesis is formed from glutaraldehyde-tanned bovine collagen, which is grown around a polyester mesh. This biosynthetic device obtained by inserting polyester mesh-covered mandrils beneath the cutaneous truncimuscle of Australian adult sheep for a period of 12–14 weeks, is stabilized using glutaraldehyde and may be prepared in straight or J- or U- curved configurations; this collagen encapsulated graft is easy to handle, with reduced thrombogenicity, low rates of infection, a low incidence of aneurysm formation and satisfactory long-term results. The current Omniflow II vascular graft has a more resistant mesh but requires delicate manipulation, avoiding cross clamping the graft with metal instruments and traction during the passage through the tunnel [42].
- g. Biohybrid and bioresorbable prostheses, graft pretreatment with endothelial cell culture, methods of affixing antibiotics, anticoagulants and growth factor to graft surfaces are under investigation to enhance the results of prosthetic vascular materials, as biologic materials facilitate cell repopulation and tissue remodeling [33].
- Synthetic grafts

The commonly used synthetic grafts include Dacron. The fibrillar structure of Dacron® was expected to encourage tissue ingrowth and provide greater durability for recurrent cannulation. However, this was not seen in practice and PTFE, a fluorocarbon polymer became the prosthetic graft of choice [43]. Stretch expanded PTFE (ePTFE) is preferable to standard PTFE. Available data supports PTFE over other biologic and synthetic materials (except bovine mesenteric vein) based on a lower risk of disintegration with infection, low thrombogenicity, low tissue reactivity, prolonged patency and improved surgical handling but this concept may change in the future with introduction of tissue engineered AVG or more recent biological grafts [44].

Other new graft materials include polyurethane grafts with their self-sealing properties and reported low complication rates. The polyetherurethaneurea (Vectra graft) is suitable for early needling [45, 46].

5.2.2. Upper extremity options

- Forearm
 - a. Straight AVG between the radial artery at the wrist and an antecubital vein should be avoided due to the risk of early thrombosis.

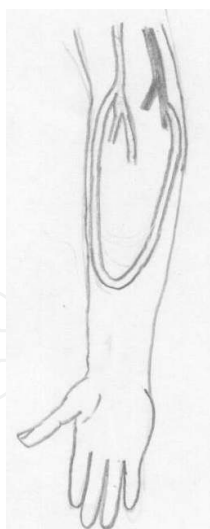


Figure 4. Forearm loop AVG

- b. The forearm loop between the brachial artery and one of the available veins in the antecubital fossa is far more better option (figure 4).
- c. One of the venae comitantes of the brachial artery should be used as outflow for both types rather than the superficial veins as outflow for a straight or looped forearm AVG graft, because if the basilic or cephalic veins are still available they should be used instead to construct an autogenous AVF with the brachial artery [47].
- d. Straight AVG in the upper arm between the brachial artery and the axillary vein (or the proximal brachial or basilic vein) is ideal and common (figure 5).
- e. Modern biological grafts are more suited for the 'O' shaped AVG with a narrow loop in the distal third of the upper arm between the brachial artery and its vena comitans or the basilic vein, because of their elasticity and compliance. This type of AVG preserve more proximal locations for potential future straight AVGs.
- f. The forearm loop between the brachial artery and one of the available veins in the antecubital fossa and the straight AVG in the upper arm between the brachial artery and the axillary vein (or the proximal brachial or basilic vein) are the most popular graft configurations [48].

5.2.3. Lower extremity options

AVGs in the lower limb have generally given less encouraging results than for the upper limb, because of increased rates of infection, ischaemia, and lower patency rates. However, groin access is a useful option when upper extremities are unavailable and peritoneal dialysis has failed [28].

When implanted in the thigh, the graft can be either a straight, looped or curved configuration (figure 6) between femoral artery and either stump of GSV or femoral vein. Anastomosing AV

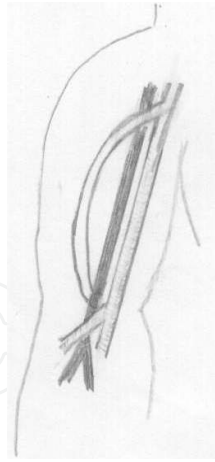


Figure 5. Straight brachial-axillary AVG.

graft to the common femoral vessels in close proximity to the groin has the disadvantage of a higher infection risk due to dissection through the dense lymphatic tissues. This has led to implantation of the AV graft more distal to the mid-superficial femoral vessels. This approach preserves the proximal vessels for future graft revision [49].

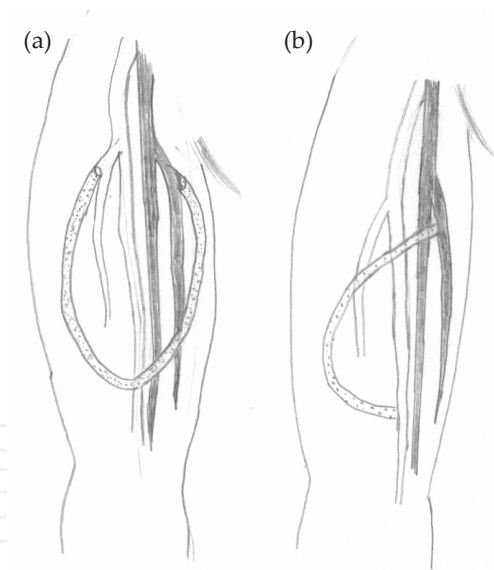


Figure 6. (a) Thigh loop AVG. (b) Straight thigh AVG.

5.3. Other less common prosthetic AV graft

- The axillary (or subclavian) artery can be used for a loop AVG, with the ipsilateral axillary or jugular vein as outflow, as well as for placing a straight AVG anastomosed to the contralateral axillary or jugular veins [50].

- Femro-femoral suprainguinal crossover AVG between the femoral artery and the contralateral femoral vein [51].
- Long axillo-femoral grafts are prone to repeated thromboses, especially in hypotensive patients. Moreover, when large vessels, such as the axillary artery and femoral veins, are employed severe venous or arterial problems may follow AVG thrombosis [52].
- Central vein occlusion, ischaemic steal syndrome and cardiac failure may be indications for creating arterio-arterial vascular access grafts running superficially in the lower limb, or on the chest wall [53, 54].
- More heroic access configurations, such as anastomosis to the right atrial appendage through a median sternotomy and to the renal vein to bypass central venous obstruction should be avoided if possible in favour of a permanent central venous catheter [55, 56].

5.4. Guidelines for selection and placement of hemodialysis access according to (KDOQI) [11]

A structured approach to the type and location of long-term HD accesses should optimize access survival and minimize complications.

The access should be placed distally and in the upper extremities whenever possible. Options for fistula placement should be considered first, followed by prosthetic grafts. Catheters should be avoided for HD and used only when other options listed are not available.

- The order of preference for placement of fistulae in patients with kidney failure who choose HD as their initial mode of KRT should be (in descending order of preference):
 - a. Autogenous AVF.
 1. A wrist (radiocephalic) primary fistula.
 2. An elbow (brachiocephalic) primary fistula.
 3. A transposed brachial basilic vein fistula
 - b. AVG of synthetic or biological material, such as:
 - A forearm loop graft, preferable to a straight configuration.
 - Upper-arm graft.
 - Chest wall or “necklace” prosthetic graft or lower extremity fistula or graft; all upper-arm sites should be exhausted first.
 - Patients should be considered for construction of a primary fistula after failure of every dialysis AV access.
- Enhanced maturation of fistulae can be accomplished by selective obliteration of major venous side branches in the absence of a downstream stenosis.
- Dialysis AVGs:

- a. The choice of synthetic or biological material should be based on the surgeon's experience and preference, technical details, and cost.
 - b. There is no convincing evidence to support tapered versus uniform tubes, externally supported versus unsupported grafts, thick versus thin-walled configurations, or elastic versus nonelastic material.
 - c. While the majority of past experience with prosthetic grafts has been with the use of PTFE, other prosthetics (eg, polyurethane [PU]) and biological conduits (bovine) have been used recently with similar outcomes.
- Rule of 6s:
 - a. A fistula in general must be a minimum of 6 mm in diameter with discernable margins when a tourniquet is in place, less than 6 mm deep, have a blood flow greater than 600 mL/min, and should be evaluated for nonmaturation if, after 6 weeks from surgical creation, it does not meet these criteria.

5.5. Detection of access dysfunction: monitoring, surveillance, and diagnostic testing [11]

- The surveillance program consists of:
 1. Physical examination (monitoring): to detect dysfunction in fistulae and grafts at least monthly by a qualified individual looking for: persistent swelling of the arm, presence of collateral veins, prolonged bleeding after needle withdrawal, or altered characteristics of pulse or thrill in a graft.
 2. Intra-access flow assessment by: Duplex Doppler Ultrasound (DDU), Magnetic Resonance Angiography (MRA), Variable flow Doppler ultrasound (VFDU), Ultrasound dilution (UDT), Glucose pump infusion technique (GPT) and Urea dilution (UreaD). Monthly in 1st 1.5 hr of treatment. The mean value of 2 separate determination (within 10% of each other) performed at a single treatment should be considered the access flow.
 3. Directly measured or derived static venous dialysis pressure.
 - Alarming findings deserving referral to vascular surgeon are:
 - a. An access flow rate less than 600 mL/min in grafts and less than 400 to 500 mL/min in fistulae.
 - b. If access flow 1,000 mL/min that had decreased by more than 25% over 4 months.
 - c. A venous segment static pressure (mean pressures) ratio greater than 0.5 in grafts or fistulae.
 - d. An arterial segment static pressure ratio greater than 0.75 in grafts.
 - e. Indicators of risk for graft rupture.
 - Poor eschar formation.
 - Evidence of spontaneous bleeding.

- Rapid expansion in the size of a pseudoaneurysm.
- Severe degenerative changes in the graft material.
- Patient Education Basics [11].

All patients should be taught how to:

1. Compress a bleeding access
2. Seal the site of a central venous catheter (CVC) with ointment to keep air embolus from entering
3. Wash skin over access with soap and water daily and before dialysis
4. Recognize signs and symptoms of infection
5. Select proper methods for exercising AV fistula arm with some resistance to venous flow
6. Palpate for thrill/pulse daily and after any episodes of hypotension, dizziness, or light-headedness
7. Listen for bruit with ear opposite access if cannot palpate for any reason

All patients should know to:

1. Avoid carrying heavy items draped over the access arm or wearing occlusive clothing
2. Avoid sleeping on the access arm
3. Insist that staff rotate cannulation sites daily
4. Insure that staff are using proper techniques in preparing skin prior to cannulation
5. Report any signs and symptoms of infection or absence of bruit/thrill to dialysis personnel immediately

6. Complications of vascular access

6.1. Failure of maturation of AVF

In general, two variables are required for AVF maturation. First, the AVF should have adequate blood flow to support dialysis; second, it should have enough size to allow for successful repetitive cannulation. Although flow and size may appear as two separate parameters, they are intricately related [57].

6.1.1. Interventions to salvage with early AVF failure

Studies demonstrated that the two most common problems observed in early AVF failure are the presence of stenosis and accessory veins. These studies have emphasized that a great majority of these failed fistulae can be salvaged using percutaneous techniques. Percutaneous balloon angioplasty and accessory vein obliteration using one of three techniques (percutane-

ous ligation using 3/0 nylon, venous cutdown, or coil insertion) were used to salvage the failed AVF. The single major complication consisted of a vein rupture with an expanding hematoma. It resulted in loss of the access. The minor complications all were hematomas that required no treatment and had no sequelae [58].

Reports have highlighted a newer technique (sequential dilation) to salvage an AVF that fails to develop because of diffuse stenosis [59, 60].

In this technique, the AVF is gradually dilated with a progressively increasing size of angioplasty balloon at 2- to 4-wk intervals until a size that is optimal for dialysis cannulation is achieved. In addition to endovascular techniques, surgical intervention has been used for AVF salvage [61].

There is a lack of prospective studies that have examined the role of surgical approach in the salvage of AVF with early failure only. The creation of a new anastomosis for a juxta-anastomotic lesion and superficialization procedures are some of the techniques that are available in this category. Inability to navigate the wire across a stenotic lesion during percutaneous approach and deep location of an AVF are some of the indications for surgical intervention [62].

6.2. Dialysis access infection

Dialysis-access-related infections are common, and often result in great cost and morbidity, may be mortality. It is the most important cause of loss of vascular catheter access and an important cause of failure of native and prosthetic arteriovenous grafts and fistula [63, 64, 65].

Diabetes seems to increase the risk of *S.aureus* bacteremia in dialysis patients [66].

Useful criteria for diagnosis of AV fistula infection includes, the presence of bacteremia associated with local tenderness or redness of the fistula site and no other obvious source of bacteremia, evidence of local infection at the fistula site with recovery of a pathogen by culture of draining pus or direct aspiration [67].

Prevention: The pillar of prevention is practicing meticulous aseptic technique and avoiding bleeding or hematoma when cannulating the graft. This is not only responsibility of the dialysis nurses and staff but also the patient. Avoidance of repeated needle insertion at one particular site on the graft is also critical to eliminate complications. The presence of foreign material makes synthetic conduit especially susceptible to infection [68].

Treatment [11]:

- *Infections of primary AVFs* are rare and should be treated as subacute bacterial endocarditis with 6 weeks of antibiotic therapy. Fistula surgical excision should be performed in cases of septic emboli.
- Infection of AVG:

Superficial infection of an AVG should be treated as follows:

Initial antibiotic treatment should cover both gram-negative and gram-positive microorganisms.

Subsequent antibiotic therapy should be based upon culture results.

- Incision and drainage may be beneficial.
- *Extensive infection of an AVG* should be treated with appropriate antibiotic therapy and resection of the infected graft material.

6.3. Thrombosis

This is the commonest cause of failure in the long term and is most often due to underlying stenosis, overdialysis leading to dehydration and hypotension, poor needling technique leading to haematoma and undue post-cannulation compression to control bleeding. The type of access and the site of thrombosis are important determinants of outcome.

Thrombosis may affect the anastomotic or post- anastomotic segments as a result of neointimal hyperplasia or may begin at a needling site. When radiocephalic or brachiocephalic AVFs thrombose at or close to anastomosis, the clot usually remains localized and run off remains patent as it has a number of natural tributaries which maintain some venous flow. This situation can be treated by a local refashioning of the AVF, anastomosing the arterialized vein to the artery at a more proximal site [69].

In contrast, thrombosis of AVFs involving transposed veins usually leads to thrombus propagation so that the entire AVF clots. This is a result of the fact that all the tributaries of the venous outflow had been ligated during the creation of this type of AVF. Successful salvage of such a clotted AVF must be attempted as soon as possible before the clot organizes. There are two choices for the treatment of the thrombosed graft: surgical and endovascular. The choice should be based on local expertise. Treatment must be timely, not delayed, and central venous catheters should be avoided. Angiography to detect venous stenotic lesions is mandatory. Venous stenosis must be corrected and all abnormal haemodynamic parameters present prior to thrombosis should return to normal [70].

Surgical correction:

The thrombectomy is usually performed with a small transverse incision at the nadir of a loop PTFE graft or at the venous anastomosis of straight PTFE grafts. The thrombectomy is then performed with a fogarty balloon catheter to extract the clot. Assessment of the presence of stenosis is made by the surgeon based on the resistance to passage of the fogarty balloon catheter or a similar dilators. More recently, intraoperative angiographic evaluation of the graft may be performed to better assess for the presence of stenoses [71].

Surgical correction of intimal hyperplasia at venous anastomosis is best managed by one of three methods depending on the extent of disease and adjacent venous anatomy:

1. Widening of the lumen with patch angioplasty.
2. Interposing a short segment of new graft material and constructing a more proximal venous anastomosis (jump graft).
3. Transferring the venous end of the graft to an adjacent vein, such as from an antecubital to the cephalic vein [72].

Endovascular therapy:

Endovascular therapy may be divided into two general categories: enzyme-mediated thrombolysis and endovascular thrombectomy [73, 74]. Enzyme-mediated thrombolysis can be subdivided into two categories:- pharmacological and pharmacomechanical.

Pharmacological thrombolysis: refers to thrombus dissolution using only the effects of a fibrinolytic enzyme. In large studies success has ranged from 58% to 68%. Complication rates have ranged from none to 85.7%. This complications included: bleeding at needle puncture sites, embolus to the peripheral artery [75] and systemic fibrinogen depletion has been routinely seen because of the large doses of enzyme used.

– Urokinase is administrated by crossed catheter technique in doses of 60,000 to > 500,000 u/hr with success rates of 75% to 93%. Urokinase offers the advantages over streptokinase of having shorter effective half-life and no antigenicity it can be readministered in cases of recurrent thrombosis [76].

– Recombinant tissue plasminogen activator has been used as thrombolytic agent for thrombosed grafts, administered at 10-20 minutes intervals with a maximum total dose of 30mg. The reported success rates have been 92% in 14 thrombosed grafts [77].

– **Pharmacomechanical thrombolysis** is composed of two phases. The first is pharmacological, consisting of enzymatic lysis. This is immediately followed by the second phase, mechanical maceration and removal of residual thrombus.

– **Endovascular thrombectomy** include pulse-spray delivery of saline [7 8], balloon thrombectomy [79, 80], thromboaspiration [81], and recently, thrombolysis using mechanical devices [82].

6.4. Vascular steal syndrome

Clinically significant distal extremity ischemia occurs in 1.6% to 8% of all individuals with a functioning dialysis shunt [83].

Risk factors include female sex, age greater than 60 years, diabetes, arteriosclerosis, multiple operations on the same limb, the construction of an autogenous fistula, and most commonly the use of the brachial artery as the donor vessel [83].

Theoretically, the presence of a large arteriovenous fistula always results in reduced perfusion to more peripheral tissues. This is evidenced by the fact that the perfusion pressure is always lower distal to an arteriovenous fistula [84].

Symptoms associated with the ischemic steal syndrome present over a broad spectrum, ranging from vague neurosensory deficits to ischaemic rest pain or tissue loss [85].

Recently, this classification was proposed [86]:

1. Stage I, pale/blue and/or cold hand without pain.
2. Stage II, pain during exercise and/or HD.

3. Stage III, pain at rest.
4. Stage IV, ulcers/necrosis/gangrene.

Definitive diagnostic testing can be performed non-invasively by comparing digital photoplethysmographic (PPG) waveforms with and without fistula compression [85].

Steal can be limited by reducing the anastomotic length to 75 percent or less of the proximal arterial diameter, which in most patients translates length of 5 mm. Of course this must be judged carefully as very small fistulas tend to clot because of inadequate flows of less than 200 ml/min. Steal syndromes following a radiocephalic fistula are relatively unusual. The cause is thought to be diversion of the ulnar arterial flow through the palmer arches to create retrograde distal radial artery flow into the fistula with a steal of blood flow away from the digital arteries. This can easily be treated by ligating the radial artery distal to the anastomosis which effectively creates an end-to-end fistula [69].

Treatment:

- Successful treatment mandates that the surgeon recognize the existing disparity between the resistances of the peripheral circulation and the fistula.
- For many years, the most commonly suggested procedures to treat steal syndrome were: excision of a portion of the vein or graft, interposition of 4 mm ePTFE graft, banding, plicating the fistula so as to increase fistula resistance and decrease fistula blood flow. To gauge the precise degree of narrowing such that adequate peripheral perfusion is restored, investigators have used digital PPG to reach digital-brachial index of ≥ 0.6 and digital pressure ≥ 60 mmHg and residual flow ≥ 300 ml/min [83, 87].
- Rerouting of arterial inflow:

Schanzer et al. in 1988 described a novel technique termed distal revascularization and interval ligation (DRIL) (figure 7b), which offers preservation of the access with physiologic restoration of flow to the hand. A DRIL procedure involves two parts: a bypass and interval ligation of the native artery. The bypass graft is connected to the artery proximal to the access anastomosis and its outflow directed to the native artery distal to the access anastomosis. The reversal of blood flow is eliminated by ligation of the artery distal to the AV access, providing the distal vascular bed with normal perfusion pressure and flow [88].

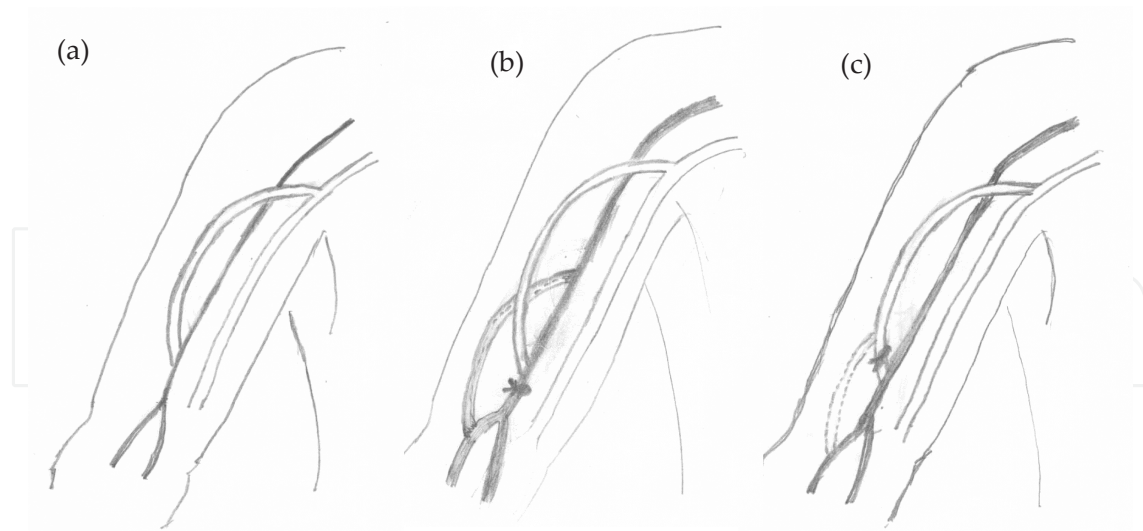


Figure 7. (a) Brachial-cephalic AVF with steal syndrome. (b) DRIL procedure. (c) RUDI procedure

Other novel solutions have focused on the basic concept of rerouting the arterial inflow. Recognizing that brachial arterial origin was a common feature of symptomatic steal, others have reported success with extending the arterial end of the access distally to smaller arteries with revision using distal inflow (RUDI)(figure 7c) and proximally to larger arteries with proximalization of arterial inflow (PAI). Each of these management solutions is based on small case series involving an uncommon but clinically significant complication of AV access. More experience is needed before an appropriate solution can be recommended [89, 90].

6.5. Haemorrhage

This occurs in the first 24 postoperative hours and may be from a specific bleeding point such as the anastomosis or from a slipped ligature. These are due to technical errors and should be avoidable. Generalized 'oozing' resulting in haematoma formation is probably more common and is a result of the functional platelet disorders and bleeding diathesis associated with uremia. This complication can be minimized by careful preoperative preparation including correction of anaemia with recombinant erythropoietin and adequate dialysis. late hemorrhage can complicate aneurysm formation and infection which controlled by firm pressure over the bleeding point and ligation may be required in the emergency situation [91].

6.6. Aneurysm formation

False aneurysms may occur at the anastomosis when there has been an error in surgical technique or more commonly at a needling site which has been over used. These can be treated by resection with either direct end-to-end anastomosis or by the placement of a short PTFE bridge graft. The incidence of false aneurysm formation is 10% for PTFE grafts compared to 2% for autogenous AVFs [92].

- Indications for revision/repair [11]:

AVGs with severe degenerative changes or pseudoaneurysm formation should be repaired in the following situations:

- a. The number of cannulation sites are limited by the presence of a large (or multiple) pseudoaneurysm(s).
 - b. The pseudoaneurysm threatens the viability of the overlying skin.
 - c. The pseudoaneurysm is symptomatic (pain, throbbing).
 - d. There is evidence of infection.
- Cannulation of the access through a pseudoaneurysm must be avoided if at all possible and particularly so if the pseudoaneurysm is increasing in size.

True aneurysmal dilatation of autogenous arterialized veins are common. Often no action is required but corrective surgery is indicated if the overlying skin becomes very thin or there is evidence of progressive expansion. In some patients the whole length of arterialized vein becomes very dilated and the AVF may have to be sacrificed by ligating it [69].

6.7. Stenosis

This may occur directly at the anastomosis, in the first few centimeters of the venous outflow from an AVF or at needling sites. Anastomotic stenosis results from either errors in surgical technique or from the development of neointimal hyperplasia. Radiocephalic AVFs can often be refashioned by creating a more proximal anastomotic site but this may not be possible for brachiocephalic or brachio basilic AVFs. In that case a "jump graft" can be created using a short segment of PTFE to bypass the stenosis. Post-anastomotic or needling site stenoses may be amenable to treatment by percutaneous transluminal angioplasty. The disadvantage is that recurrent stenosis is common and this may require surgical revision using a prosthetic interposition graft [69].

6.7.1. Indications for preemptive PTA in stenosed autogenous AVF or AVG [11]

A fistula with a greater than 50% stenosis in either the venous outflow or arterial inflow, in conjunction with clinical or physiological abnormalities such as: reduction in flow (< 600mL/min in AVG), increase in static pressures should be treated with percutaneous transluminal angioplasty (PTA) or surgical revision.

6.7.2. Central vein stenosis [11]

Patients with extremity edema that persists beyond 2 weeks after graft placement should undergo an imaging study (including dilute iodinated contrast) to evaluate patency of the central veins. The preferred treatment for central vein stenosis is PTA. Stent placement should be considered in the following situations:

- Acute elastic recoil of the vein (> 50% stenosis) after angioplasty.
- The stenosis recurs within a 3-month period.

6.8. Lymphocele

This occurs when the lymphatic channels have been divided or diathermed. It is particularly associated with brachio-basilic fistula formation and operation in the groin. Treatment by intermittent closed drainage under-sterile condition and antibiotics cover is usually successful. Recurrent and persistent lymphocele may require re exploration and open drainage [69].

6.9. Venous hypertension

A venous hypertension syndrome may develop in which the hand distal to the fistula becomes swollen and uncomfortable with thickening of the skin and hyperpigmentation [93, 94]. Hypertension may be avoided by forming an end-to-side or end-to-end anastomosis. Ligation of the enlarged venous tributaries causing the hypertension of the distal digits may relieve symptoms while preserving the fistula. The increasing use of subclavian lines for dialysis has led to an increased incidence of subclavian vein thrombosis or stenosis. The subsequent placement of a fistula may lead to massive arm edema caused by venous hypertension and, in women, breast enlargement [95]. Subclavian vein thrombolysis and angioplasty with stenting may allow continued use of the-fistula. This complication may also be lessened by using the internal jugular vein for central line placement [96].

6.10. Neuropathy

Ischemic neuropathy is unusual with the radiocephalic fistula and is seen mainly in diabetic patients with preexisting atherosclerotic disease and in patients with proximal site fistulas. It is characterized by the onset of severe, acute, painful weakness of the distal extremity, with wrist drop and minimal wrist flexion. This development is probably due peripheral nerve ischemia and if recognized early, fistula interception may preserve neurologic function [97].

Indeed definite thickening of the flexor synovium within the carpal tunnel is occasionally observed either in patients with a functioning shunt. The most prominent symptom of carpal tunnel syndrome in dialysis patients is painful nocturnal acroparesthession of the affected limb. The pain and numbness are in the distribution of the median nerve. In differentiating the carpal tunnel syndrome from painful uremic neuropathy, one should consider that the symptoms of uremic neuropathy are symmetric, often beginning as a burning sensation in the soles of the feet, with progressive involvement in the legs. The upper extremities are involved only after the presence of severe lower extremity disease. On examination of the median conduction velocity across the wrist it will be found to be delayed. Relief is achieved by median nerve decompression by division of the transverse carpal ligament. Some patients may achieve relief from symptoms by conservative measures such as simply moving the hand during dialysis. Using digital compression of the puncture site, rather than using a compression bandage avoids increased venous pressure [98].

6.11. Cardiovascular complications

High-output cardiac failure is a rare complication, which occurs particularly in patients who display a combination of low hematocrit and cardiomyopathy from diabetes, in the presence

of a high-flow fistula [99]. Treatment usually involves ligation of the fistula, although banding may be attempted [100].

7. Factors affecting access patency

Patient related factors:

1. **Age:** Increasing age has no effect on fistula patency [101].
2. **Gender:** The patency of distal forearm, wrist or snuffbox AVFs is poorer in women than in men. Since, this seems to apply also to more proximal AVFs it may be unrelated to the larger vessels of men and may have a hormonal basis [102, 103].
3. **Diabetes:** There is conflicting evidence as to whether diabetes is an adverse factor for fistula patency with some authors suggesting that flow rates and patency are poorer [103], whereas others have found no effect [104, 105].
4. **Obesity:** It is more difficult to create a suitable AV fistula in obese patients because the deeper veins are more difficult to cannulate but this does not affect patency [106].
5. **Smoking:** Smokers may have poorer fistula survival [107].
6. **Thrombotic tendencies and vasculitis:** Increased fibrinogen predisposes to access thrombosis and vasculitis is a strong predictor of access failure [108].

Access related factors:

1. **Vessel size:** Small vessels have higher initial failure rates, more frequent failure to mature and poorer long-term patency [7].
2. **Access position:** More proximal AV fistulae have improved blood flow and patency but leave fewer options for access in the event of failure [109, 110].
3. **Prosthetic AV grafts:** Prosthetic AV grafts have poorer primary patency, require more revisions and have higher infection rates than autogenous AVFs. However, their patency can be improved by using a wider diameter graft or adding a vein cuff to the venous anastomosis [111, 112, 113].
4. **Fistula flow rates:** The flow rate AV fistulae the day after surgery correlates inversely with the risk of thrombosis although intraoperative flow rates are less reliable [7].
5. **Anastomotic method:** Anastomosis using non-penetrating vascular clips, which give an interrupted anastomosis with excellent endothelial apposition and less bleeding, are quicker and may have improved patencies [109, 110].

Surgeon related factors:

Surgical experience: There can be little doubt that experienced surgeons with adequate training have good outcomes [103], but well supervised trainees can produce equivalent results [114].

Postoperative follow up related factors:

1. **Access surveillance:** The use of postoperative surveillance and pre-emptive repair of detected defects has been shown to improve access survival in a randomized controlled trial [115].
2. **Early cannulation:** This is not a risk factor for fistula failure [116].
3. **Drugs:** Antiplatelet agents such as aspirin and dipyridamole prolong fistula survival and are used routinely [117, 118] although a combination of aspirin and clopidogrel increased haemorrhagic complications without influencing patency in prosthetic AV grafts [119]. Anticoagulation with warfarin reduces AVF thrombosis in patients with hypercoagulable states [120], but routine use is best avoided because of the risk of haemorrhage [121].

8. Central venous catheter for hemodialysis

Another way to get access to the circulation to perform hemodialysis is the usage of the central venous catheters.

8.1. Indications and patient selection

Central venous catheter is the preferred method for short term hemodialysis and it is also used for emergent dialysis as temporary access while a permanent access is maturing. Central venous catheter is used as a permanent access in patients who have exhausted all other options for autogenous AVF or AVG. It is the method of choice in patients who are not candidate for AVF or AVG, like patients with limited cardiac reserve, children weighting less than 30 kg, and patients with extensive peripheral vascular disease.

8.2. Catheter types

There are many commercially available percutaneous hemodialysis catheters, all are grouped into two main types; the non-tunneled and the tunneled catheters (figure 8), both are usually provided with dual lumen; one for withdrawal and the other for return of blood, but in some cases they were of three lumens, with the third one for I.V. fluids, blood products, and drug administration, as well as blood sampling. The tunneled catheters have Dacron or Teflon cuff on their shaft near the distal end which promotes tissue ingrowth in order to fix the catheter to the subcutaneous tissue, some catheters have another antimicrobial cuff distal to the fixation cuff in order to limit microbial invasion through the subcutaneous tunnel, the antimicrobial cuff is formed of porous collagen incorporating an antimicrobial agent. The non-tunneled catheters are used in patients who are planned for short term catheter dependent hemodialysis (less than one month), while tunneled catheters are used in patients who are planned for long term catheter dependent hemodialysis. They are provided in different lengths, with the tunneled catheter having longer length than the non-tunneled one to accommodate the length of the subcutaneous tunnel, and also they are available in different diameters ranging from 9

Fr. in pediatric catheters up to 15 Fr. Most of hemodialysis catheters made of silicone or polyurethane.

The cuffed catheter is tunneled subcutaneously from the desired exit site to the site of vein entry. The non-cuffed double lumen catheters are placed by conventional Seldinger technique, while the cuffed one are flexible and required the use of rigid introducer or peel-apart sheath that is latter removed, leaving the catheter in place. The catheter is placed into one of the large central veins so the tip lies in the junction of superior vena cava with the right atrium.

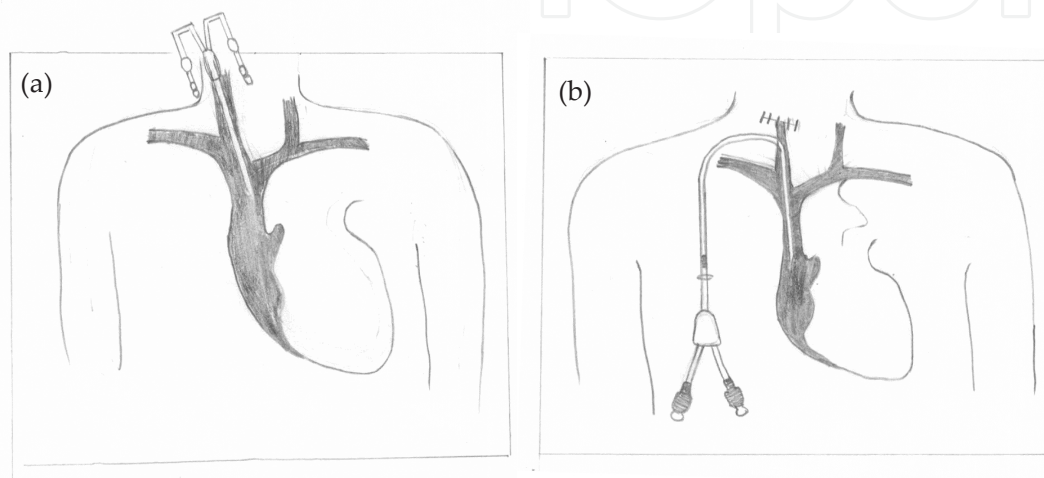


Figure 8. (a) Non-tunneled catheter in place. (b) Tunneled cuffed catheter.

Type and Location of Tunneled Cuffed Catheter Placement according to (KDOQI) guidelines [122]:

- a. Tunneled cuffed venous catheters are the method of choice for temporary access of longer than 3 weeks' duration. (They also are acceptable for access of shorter duration.) In addition, some patients who have exhausted all other access options require permanent access via tunneled cuffed catheters. For patients who have a primary AV fistula maturing but need immediate hemodialysis, tunneled cuffed catheters are the access of choice. Catheters capable of rapid flow rates are preferred.
- b. The preferred insertion site for tunneled cuffed venous dialysis catheters is the right internal jugular vein. Other options include: the right external jugular vein, the left internal and external jugular veins, subclavian veins, femoral veins, or translumbar access to the inferior vena cava. Subclavian access should be used only when jugular options are not available. Tunneled cuffed catheters should not be placed on the same side as a maturing AV access, if possible.
- c. Fluoroscopy is mandatory for insertion of all cuffed dialysis catheters. The catheter tip should be adjusted to the level of the caval atrial junction or into the right atrium to ensure optimal blood flow. (Atrial positioning is only recommended for catheters composed of soft compliant material, such as silicone).

- d. Real-time ultrasound-guided insertion is recommended to reduce insertion-related complications.
- e. There is currently no proven advantage of one cuffed catheter design over another. Catheters capable of a rapid blood flow rate are preferred. Catheter choice should be based on local experience, goals for use, and cost.

In updates of 2006 (NKF-K/DOQI) (11) stated that: Ultrasound should be used in the placement of catheters, and they recommend tunneled cuffed catheters for catheter dependent hemodialysis longer than one week.

8.3. Technique of insertion

Internal jugular vein is approached by inserting the needle about one inch above the clavicle between the two heads of the sternomastiod muscle directing it toward the ipsilateral nipple, another approach is achieved by inserting the needle about 1-2 inches above the clavicle under the lateral border of the sternomastiod muscle directing it toward the ipsilateral sternoclavicular joint, in both approaches the patient must be supine with the head extended and tilted to the other side, the carotid artery is felt and kept medially away from the needle puncture.

The subclavian vein is approached by inserting the needle under the clavicle at the junction of its lateral third with the medial two thirds directing the needle toward the sternoclavicular joint with the patient in supine position.

The femoral vein is approached by inserting the needle at the inguino-crural crease just medial to the femoral pulsation directing the needle toward the umbilicus with the patient in supine position.

8.4. Complications

Many complications may occur during catheter placement, but they could be prevented by adopting careful maneuver, using ultrasound and fluoroscopic guidance.

Complication list include hemothorax, pneumothorax, arterial puncture, hematoma and air embolism.

8.5. Catheter related problems

8.5.1. Catheter dysfunction

This is manifested by difficulty to withdraw and/or infuse blood, if this occurs in the first dialysis session after catheter placement it is usually due to malposition or kinking and it can be corrected under fluoroscopic guidance. If this occurs in a previously functioning catheter, catheter thrombosis should be suspected. The thrombus may be intraluminal, at the tip of the catheter or rarely the catheter induces thrombosis in the vein in which it is placed. Other cause of catheter malfunction is the fibrin flap, in this condition fibrin extends from the fibrin sheath to come in front of the catheter tip acting as a valve preventing withdrawal but allowing infusion of blood.

8.5.1.1. Prevention of catheter thrombosis

Routinely anticoagulant solution is infused inside the catheter lumen at the end of each dialysis session and it is adjusted to fill the catheter lumen (catheter lock) to prevent catheter thrombosis. The standard solution is heparin with concentrations ranging from 1000 to 10,000 u/ml, another solution is sodium citrate with concentrations ranging from 4% to 47%. In spite of the proper adjustment of the catheter lock solution to just fill the catheter lumen, some amount usually leak to the circulation [123], in case of citrate this causes no problem [124], but in case of heparin this may cause bleeding complications in susceptible patients [125]. Few studies have compared different heparin concentrations [126], and they found that lower concentration (1000 u/ml) is as effective as higher concentrations in preventing catheter thrombosis with less bleeding complications. Also studies comparing different concentrations of citrate solution [127, 128] found that concentrations of 4-5% is sufficient. Studies comparing heparin concentration of 1000 u/ml to citrate concentration of 4-5% solutions [129, 130, 131], showed that citrate is as effective as heparin in prevention of catheter thrombosis with the advantage of absence of liability to bleeding complications. Recently trials are going on to evaluate the use of small dose of tissue plasminogen activator as catheter lock solution aiming to obtain better results than those obtained with heparin and citrate [132, 133].

The use of oral anticoagulant in the form of warfarin in therapeutic dose with the INR (1.8-2.5) is supposed to be effective in decreasing the incidence of catheter thrombosis [134, 135].

8.5.1.2. Treatment of catheter dysfunction

In case of low catheter flow, simple measures may succeed in restoring adequate blood flow such as repeated aspiration and flushing with saline, passage of guide wire through the lumen of the catheter, changing the position of the patient, and reversal of the lines (withdrawal from the venous line and return the blood through the arterial line). In case of failure of the previous measures or if there is inability to withdraw and/or infuse from both ports, lytic therapy is indicated. The thrombolytic agent is injected inside the catheter lumen and left for 30-60 min before its withdrawal. The agent commonly used is either urokinase 5000 u/ml, or tissue plasminogen activator 1mg/ml, and it could be repeated. This procedure succeeded in restoring adequate flow in 70 to 90% of the cases but with high rate of recurrence [136-140]. Higher doses of urokinase were tried using infusion through the catheter rather than locking the catheter with higher success rate and less recurrence [141], provided that there were no contraindications to lytic therapy. If these methods failed to restore adequate blood flow, then catheter exchange over guide wire will be the appropriate option.

8.5.2. Catheter infection

Infection is the most common complication of hemodialysis catheter and it is one of the leading causes of morbidity and catheter removal in hemodialysis patients. The catheter infection rate is variable and is related to the duration of use. In a prospective study including 108 patients with tunneled dialysis catheter, the rate of catheter related bacteremia was 35% in the first 3 months and 48% within 6 months [142]. Catheter-related bacteremia may cause serious

metastatic infection in 5-10% of patients [143] (endocarditis, osteomyelitis, septic arthritis, epidural abscess, or death). Catheter infection may be exit-site infection, tunnel infection or catheter-related bacteremia. Catheter-related bacteremia is thought to be commonly originated from bacteria in the catheter biofilm. The biofilm is formed on the catheter lumen in the first 24 hours after catheter insertion. The bacteria in the biofilm are resistant to antibiotic at therapeutic plasma concentration, but are usually susceptible to higher concentrations [144].

8.6. Prophylactic measures to prevent catheter infection

Catheter Care and Accessing the Patient's Circulation according to (KDOQI) guidelines [122]:

- a. Hemodialysis catheter dressing changes and catheter manipulations that access the patient's bloodstream should only be performed by trained dialysis staff.
- b. The catheter exit site should be examined at each hemodialysis treatment for signs of infection.
- c. Catheter exit site dressings should be changed at each hemodialysis treatment.
- d. Use of dry gauze dressing combined with skin disinfection, using either chlorhexidine or povidone iodine solution, followed by povidone iodine ointment or mupirocin ointment at the catheter exit site are recommended after catheter placement and at the end of each dialysis session.
- e. Manipulating a catheter and accessing the patient's bloodstream should be performed in a manner that minimizes contamination.
- f. During catheter connect and disconnect procedures, nurses and patients should wear a surgical mask or face shield. Nurses should wear gloves during all connect and disconnect procedures.

Treatment of Infection of Tunneled Cuffed Catheters

Tunneled cuffed catheter infection is a serious problem. Appropriate treatment is dependent upon the nature of the infection:

1. Apply topical antibiotics, ensuring proper local exit site care; do not remove the catheter.
2. If there is tunnel drainage, treat with parenteral antibiotics (anti-staphylococcal, anti-streptococcal therapy pending exit site cultures) in addition to following appropriate local measures. Definitive therapy should be based on culture results. Do not remove the catheter unless the infection fails to respond to therapy. If the infection fails to respond to therapy, remove the catheter and replace it using a different tunnel and exit site.
 - a. Catheter-related bacteremia, with or without systemic signs or symptoms of illness, should be treated by initiating parenteral treatment with an antibiotic(s) appropriate for the organism(s) suspected, usually *Staphylococcus* and *Streptococcus*. Definitive therapy should be based on the organism(s) isolated. The catheter should be removed in all instances if the patient remains symptomatic more than 36 hours. The catheter should also

be removed in any clinically unstable patient. Preliminary reports suggest that after obtaining a bactericidal level of the antibiotic in the blood, in a stable asymptomatic patient without exit site or catheter tunnel tract involvement may be treated by changing the catheter over a guidewire plus a minimum of 3 weeks of systemic antibiotic therapy. Blood cultures should be repeated periodically during and immediately after this treatment to monitor its effectiveness.

A new permanent access should not be placed until blood cultures, performed after cessation of antibiotic treatment, have been negative for at least 48 hours.

In updates of 2006 [11]; the last recommendation has been changed: Catheters should be exchanged as soon as possible and within 72 hours of initiating antibiotic therapy in most instances, and such exchange does not require a negative blood culture result before the exchange. Follow-up cultures are needed 1 week after cessation of antibiotic therapy

Catheter-related bacteremia is diagnosed by the presence of fever in catheter- dependent patient with positive blood culture [141].

The empirical therapy should include antibiotic with broad-spectrum coverage against gram-negative organisms such as third generation cephalosporin and vancomycin in centers with frequent MRSA infection. Once the result of culture is obtained, the antibiotic is changed according to the results of the sensitivity tests, and the treatment should be continued for at least 3 weeks.

The antibiotic lock solution: Given that biofilm is the major source of catheter related bacteremia an antimicrobial catheter lock solution may reduce catheter-related bacteremia. The antibiotic lock is a concentrated antibiotic solution mixed with the anticoagulant solution and injected into the catheter lumen at the end of the dialysis session.

The antibiotic lock solutions may include the standard antibiotics or antimicrobial agents such as taurolidine and 30% citrate solution [144]. Many trials documented the efficacy of antibiotic locks in prophylaxis of catheter-related bacteremia [145, 146].

9. Portacath for hemodialysis

Portacath (totally implantable venous access system) is commonly used in oncology patients to deliver the chemotherapeutic agents and parenteral nutrition intravenously and recently it has been used for hemodialysis especially in children. The system used for hemodialysis consists of two separate or fused subcutaneously implantable reservoirs connected to double lumen catheter; one port is used for blood withdrawal and the other for blood return.

10. Translumbar inferior vena cava catheter for hemodialysis

This technique represents another option for challenging cases who did not have suitable patent central vein allowing creation of arteriovenous access or insertion of tunneled cuffed

catheter. In this technique a long tunneled cuffed catheter is inserted in the inferior vena cava percutaneous while the patient is in prone position with the aid of fluoroscopy.

Author details

Hossam Elwakeel and Khaled Elalfy

Mansoura University, Faculty of Medicine, Egypt

References

- [1] Punch JD, Merion RM (1995): External methods of angioaccess. In: Ernest CB, Stanley JC (eds). *Current Therapy in Vascular Surgery*. 3rd ed. Mosby Year Book, pp: 853.
- [2] Bennion RS, Williams RA, Wilson SE (1994): Principles of vascular access surgery. In Wilson SE, Veith FK, Hobson RW, Williams RA (eds): *Vascular Surgery: Principles and Practice*, 2nd ed. New York, McGraw-Hill.
- [3] Quinton WE, Dillard D, Scribner BH (1960): Cannulation of blood vessels for prolonged hemodialysis. *Trans Am Soc Artif Intern Organs*; 6: 104-13.
- [4] Brescia MJ, Cimino JE, Appel K, Hurwich BJ (1966): Chronic hemodialysis using venipuncture and a surgically created arteriovenous fistula. *N Engl J Med* 17; 275(20): 1089-1092.
- [5] May J, Tiller D, Johnson J, Stewart J, Sheila G (1969): Saphenous-vein arteriovenous fistula in regular dialysis treatment. *N Engl J Med*; 280(14): 770.
- [6] Baker LD, Johnson JM, Goldfarb D (1976): Expanded polytetrafluoroethylene (PTFE) subcutaneous arteriovenous conduit: An improved vascular access for chronic hemodialysis. *Trans Am Soc Artif Intern Organs* 22: 382-387.
- [7] Wong V, Ward R, Taylor J, Selvakumar S, How TV, Bakran A (1996): Factors associated with early failure of arteriovenous fistulae for haemodialysis access. *Eur J Vasc Endovasc Surg*; 12(2): 207-13.
- [8] Wedgwood KR, Wiggins PA, Guillou PJ (1984): A prospective study of end-to-side vs. side-to-side arteriovenous fistulas for haemodialysis. *Br J Surg*; 71(8): 640-2.
- [9] Reilly DT, Wood RF, Bell PR (1982): Prospective study of dialysis fistulas: problem patients and their treatment. *Br J Surg*; 69(9): 549-53.
- [10] Crowe CP, Schenk WG Jr (1963): Massive experimental arteriovenous fistulas. *J Trauma*; 3: 13-21.

- [11] National Kidney Foundation (2006): NKF-K/DOQI clinical practice guidelines for vascular access: update 2006. *Am J Kidney Dis*; 48 (Suppl 1): S176-S306.
- [12] Premru V (2002): Preservation of veins in predialysis patients and early referral. *Blood Purif*; 20(4): 409-440. indexed in the 5th European Basic Multidisciplinary Haemodialysis access course.
- [13] Silva MBJ, Hobson RW, Pappas PJ, Jamil Z, Araki CT, Goldberg MC, Gwertzman G, Padberg FT Jr (1998): A strategy for increasing use of autogenous hemodialysis access procedures: impact of preoperative noninvasive evaluation. *J Vasc Surg*; 27(2): 302-7.
- [14] Allen EV (1929): Thromboangitis obliterans: methods of chronic occlusive arterial lesions distal to the wrist with illustrative cases [abstract]. *Am J Med Sci*; 178: 237-244.
- [15] Wolowczyk L, Williams AJ, Donovan KL, Gibbons CP (2000): The snuffbox arteriovenous fistula for vascular access. *Eur J Vasc Endovasc Surg* 2000; 19: 70-6.
- [16] Chen Z, Wu W, Wu QH (2003): Operative outcome and experience in arteriovenous shunt at different sites. *Zhonghua Yi Xue Za Zhi*; 83(3): 2111-3.
- [17] Gefen JY, Fox D, Giangola G, Ewing DR, Meisels IS (2002): The transposed forearm loop arteriovenous fistula: a valuable option for primary hemodialysis access in diabetic patients. *Ann Vasc Surg*; 16: 89-94. Epub 2002 Jan 17.
- [18] Silva MB Jr, Simonian GT, Hobson RW 2nd (2000): Increasing use of autogenous fistulas: selection of dialysis access sites by duplex scanning and transposition of forearm veins. *Semin Vasc Surg*; 13(1): 44-8.
- [19] Spergel LM, Ravani P, Asif A, Roy Chaudhury P, Besarab A (2007): Autogenous arteriovenous fistula options. *J Nephrol*; 20(3): 288-298.
- [20] Gracz KC, Ing TS, Soung LS, Armbruster KF, Seim SK, Merkel FK (1977): Proximal forearm fistula for maintenance hemodialysis. *Kidney Int*; 11(1): 71-5.
- [21] Sparks SR, VanderLinden JL, Gnanadev DA, Smith JW, Bunt TJ (1997): Superior patency of perforating antecubital vein arteriovenous fistulae for hemodialysis. *Ann Vasc Surg*; 11(2): 165-7.
- [22] Oliver MJ, McCann RL, Indridason OS, Butterly DW, Schwab SJ (2001): Comparison of transposed brachio basilic fistulas to upper arm grafts and brachiocephalic fistulas. *Kidney Int*; 60(4): 1532-9.
- [23] Ravani P, Barrett B, Mandolfo S, Brunori G, Cancarini G, Imbasciati E, Malberti F (2005): Factors associated with unsuccessful utilization and early failure of the arterio-venous fistula for hemodialysis. *J Nephrol*; 18(2): 188-96.
- [24] EL-Mallah S (1998): Staged basilic vein transposition for dialysis angioaccess. *Int Angiol*; 17: 65-68.
- [25] Paul EM, Sideman MJ, Rhoden DH, Jennings WC (2010): Endoscopic basilic vein transposition for hemodialysis access. *J Vasc Surg*; 51(6): 1451-6.

- [26] Elwakeel HA, Saad EM, Elkiran YM, Awad I (2007): Unusual vascular access for hemodialysis: Transposed venae comitante of the brachial artery. *Ann Vasc Surg*. ; 21: 560-563
- [27] Dorobantu LF, Stiru O, Iliescu VA, Novelli E (2006): The brachio-brachial arteriovenous fistula: a new method in patients without a superficial venous system in the upper limb. *J Vasc Access*; 7(2): 87-9.
- [28] Pierre-Paul D, Williams S, Lee T, Gahtan V (2004): Saphenous vein loop to femoral artery arteriovenous fistula: a practical alternative. *Ann Vasc Surg*; 18(2): 223-7.
- [29] May J, Harris J, Fletcher J (1980): Long-term results of saphenous vein graft arteriovenous fistulas. *Am J Surg*; 140(3): 387-90.
- [30] Gradman WS, Cohen W, Haji-Aghaii M (2001): Arteriovenous fistula construction in the thigh with transposed superficial femoral vein: our initial experience. *J Vasc Surg*; 33(5): 968-75.
- [31] Huber TS, Hirneise CM, Lee WA, Flynn TC, Seeger JM (2004): Outcome after autogenous brachial-axillary translocated superficial femoropopliteal vein hemodialysis access. *J Vasc Surg*; 40(2): 311-8.
- [32] Jennings WC (2006): Creating arteriovenous fistulas in 132 consecutive patients: exploiting the proximal radial artery arteriovenous fistula: reliable, safe, and simple forearm and upper arm hemodialysis access. *Arch Surg* 2006; 141(1): 27-32.
- [33] Berardinelli L (2006): Grafts and graft materials as vascular substitutes for haemodialysis access construction. *Eur J Vasc Endovasc Surg*; 32(2): 203-211.
- [34] Bhandari S, Wilkinson A, Sellars L (1995): Saphenous vein forearm grafts and goretex thigh grafts as alternative forms of vascular access. *Clin Nephrol*; 44(5): 325-328.
- [35] Cimo-chowski GE, Rutherford WE, Blondin J, Harter H (1991): Use of the spiral vein graft as an arterial substitute for secondary access. *Am J Nephrol*; 11(1): 64-66.
- [36] Katzman HE, Glickman MH, Schild AF, Fujitani RM, Lawson JH (2005): Multicentre evaluation of the bovine mesenteric vein bioprotheses for hemodialysis access in patients with an earlier failed prosthetic graft. *J Am Coll Surg*; 201(2): 223-30.
- [37] Bacchini G, Del Vecchio L, Andrulli S, Pontoriero G, Locatelli F (2001): Survival of prosthetic grafts of different materials after impairment of a native arteriovenous fistula in hemodialysis patients. *ASAIO J*; 47(1): 30-3.
- [38] Baraldi A, Manenti A, Di Felice A, Grosoli M, Furci L, Leonelli M, Manca V, Roncaglia R, Lusvavghi E (1989): Absence of rejection in cryopreserved saphenous vein allografts for hemodialysis. *ASAIO Trans*; 35(3): 196-9.
- [39] Bolton WD, Cull DL, Taylor SM, Carsten CG 3rd, Snyder BA, Sullivan TM, Youkey JR, Langan EM 3rd, Gray BH (2002): The use of cryopreserved femoral vein grafts for hemodialysis access in patients at high risk for infection: a word of caution. *J Vasc Surg*; 36(3): 464-8.

- [40] Glickman MH, Lawson JH, Katzman HE, Schild AF, Fujitani RM (2003): Challenges of hemodialysis access for high risk patients: impact of mesenteric vein bioprosthetic graft. *J Vasc Access*; 4(2): 73-80.
- [41] Darby CR, Roy D, Deardon D, Cornall A (2006): Depopulated bovine ureteric xenograft for complex haemodialysis vascular access. *Eur J Vasc Endovasc Surg*; 31(2): 181-6.
- [42] Wang SS, Chu SH (1996): Clinical use of omniflow vascular graft as arteriovenous bridging graft for hemodialysis. *Artif Organs*; 20(12): 1278-1281.
- [43] Raju S (1987): PTFE grafts for hemodialysis access: techniques for insertion and management of complications. *Ann Surg*; 206(5): 666-73.
- [44] Almonacid PJ, Pallares EC, Rodriguez AQ, Valdes JS, Rueda Orgaz JA, Polo JR (2000): Comparative study of use of Diastat versus standard wall PTFE grafts in upper arm hemodialysis access. *Ann Vasc Surg*; 14(6): 659-62.
- [45] Peng CW, Tan SG (2003): Polyurethane grafts: a viable alternative for dialysis arteriovenous access? *Asian Cardiovasc Thorac Ann*; 11(4): 314-8.
- [46] Kakkos SK, Haddad R, Haddad GK, et al (2007): Results of aggressive graft surveillance and endovascular treatment on secondary patency rates of Vectra Vascular Access grafts. *J Vasc Surg*; 45(5): 974-80.
- [47] Greenstein S, Patel V, Kim D (1999): Surgical creation of fistulas and grafts. *Tech Vasc Intervent Radiol*; 2(4): 174-178.
- [48] Berardinelli L (2004): Arteriovenous fistulas: different types and surgical techniques. *Contrib Nephrol*; 142: 47-72.
- [49] Scott JD, Cull DL, Kalbaugh CA, Carsten CG, Blackhurst D, Taylor SM, Synder BA, Yaork JW, Langan EM (2006): The mid-thigh loop arteriovenous graft: patient selection, technique, and results. *Am Surg*; 72(9): 825-8.
- [50] McCann RL (1996): Axillary grafts for difficult hemodialysis access. *J Vasc Surg*; 24(3): 457-461.
- [51] Fee HJ Jr, Levisman JA, Dickmeyer JP, Golding AL (1976): Hemodynamic consequences of femoral arteriovenous bovine shunts. *Ann Surg*, 184(1): 103-6.
- [52] McLafferty RB, Taylor LM Jr, Moneta GL, Yeager RA, Edwards JM, Porter JM (1996): Upper extremity thromboembolism after axillary-axillary bypass grafting. *Cardiovasc Surg*; 4(1): 111-113.
- [53] Settmacher U, Heise M, Sholz H (1998): Das arterioarterielle Interponat als Dialysezugang. Arterioarterial grafts as vascular access for dialysis. *Gefasschirurgie*; 3(1): 11-13.
- [54] Bünger CM, Kröger J, Kock L, Henning A, Klar E, Schareck W (2005): Axillary-axillary interarterial chest loop conduit as an alternative for chronic hemodialysis access. *J Vasc Surg*; 42(2): 290-295.

- [55] El-Sabroun RA, Duncan JM (1999): Right atrial bypass grafting for central venous obstruction associated with dialysis access: another treatment option. *J Vasc Surg*; 29(3): 472-478.
- [56] Karb SJ, Hawxby A, Burdick JF (2004): Axillorenal arteriovenous graft: a new approach for dialysis access. *J Vasc Surg*; 40(2): 379-380.
- [57] Beathard GA, Arnold P, Jackson J, Litchfield T (2003): Aggressive treatment of early fistula failure. Physician operators forum of RMS lifeline. *Kidney Int*; 64(4): 1487-1494.
- [58] Faiyaz R, Abreo K, Zaman F, Pervez A, Zibari G, Work J (2002): Salvage of poorly developed arteriovenous fistulae with percutaneous ligation of accessory veins. *Am J Kidney Dis*; 39(4): 824-827.
- [59] Asif A, Gadalean, FN, Merrill, D, Cherla G, Cipleu CD, Epstein DL, Roth D (2005): Inflow stenosis in arteriovenous fistulas and grafts: A multicenter, prospective study. *Kidney Int*; 67(5): 1986-92.
- [60] Beathard GA (2005): An algorithm for the physical examination of early fistula failure. *Semin Dial*; 18(4): 331-5.
- [61] Mickley V, Cazzonelli M, Bossinger A (2003): The stenosed Brescia- Cimino fistula: Operation or intervention? *Zentralbl Chir*; 128(9): 757-761.
- [62] Asif A, Roy-Chaudhury P, Beathard GA (2006): Early Arteriovenous Fistula Failure: A Logical Proposal for When and How to Intervene. *Clin J Am Soc Nephrol*; 1(2): 332-339.
- [63] Keane M, Shapiro FL, Raj L (1977): Incidence and type of infections occurring in 445 chronic hemodialysis patients. *Trans. Am. Soc. Artif. Intern. Organs*, 23: 41-7.
- [64] Moss AH, Vasilakis C, Holley JL, Foulks CJ, Piljai K, McDowell DE (1990): Use of a silicone dual-lumen catheter with a dacron cuff as a long-term vascular access for hemodialysis patients. *Am J Kidney Dis*; 16(3): 211-215.
- [65] Fan PY, Schwab SJ (1992): Vascular access concepts for the 1990s. *J. Am. Soc. Nephrol*, 3(1): 1-11.
- [66] Quarles LD, Rutsky EA, Rostand SG (1985): Staphylococcus aureus bacteremia in patients on chronic hemodialysis. *Am J Kidney Dis*; 6(6): 412-19.
- [67] Fong IW, Capellan JM, Simbul M, Angel J (1993): Infection of arteriovenous fistulas created for chronic haemodialysis. *Scand J Infect Dis*; 25(2): 215-20.
- [68] Bhat DJ, Tellis VA, Kohlberg WI, Driscoll B, Veith FJ (1980): Management of sepsis involving expanded polytetrafluoroethylene grafts for hemodialysis access. *Surgery*; 87(4): 445-50.
- [69] Michael ML and Murphy GJ (2000): Surgical considerations in vascular access. In: Conlon, P.J, Schwab, S.J. and Nicholson, M.L. (eds.). *Hemodialysis Vascular Access: Practice and Problems*, 1st edition. Oxford, University Press Inc., pp. 101-119.

- [70] Kumpe DA and Cohen MA (1992): Angioplasty / thrombolytic treatment of failing and failed access sites: comparison with surgical treatment. *Prog Cardiovasc Dis*; 34(4): 263-78.
- [71] Krysl J, Kumpe DA (1997): Failing and failed hemodialysis access sites. *Semin Vasc Surg*; 10(3): 175-183.
- [72] Wilson YG, Davies AH, Southgate K, Currie IC, Knight D, Patton D, Baird RN, Lamont PM, Angelini GD (1996): Influence of angioscopic vein graft preparation on development of neointimal hyperplasia in an organ culture model of human saphenous vein. *J Endovasc Surg*; 3(4): 436-44.
- [73] Klimas VA, Denny KM, Paganini EP, Graor RA, Nakamoto S, Risius B, Young J (1984): Low dose streptokinase therapy for thrombosed arteriovenous fistulas. *Trans Am Soc Artif Intern Organs*; 30: 511-13.
- [74] McNamara TO and Fischer JR (1985): Thrombolysis of peripheral arterial and graft occlusions: improved results using high-dose urokinase. *AJR Am J Roentgenol*; 144(4): 769-75.
- [75] Cohen MAH, Kumpe DA, Durham JD and Zwerdinger SC (1994): Improved treatment of thrombosed hemodialysis access sites with thrombolysis and angioplasty. *Kidney International*; 46(5): 1375-80.
- [76] Berger MF, Aruny JE, Skibo LK (1994): Recurrent thrombosis of polytetrafluoroethylene dialysis fistulas after recent surgical thrombectomy: Salvage by means of thrombolysis and angioplasty. *JVIR*; 5(5): 725-730.
- [77] Rinast E, Weiss HD (1991): Regional angiography by application of recombinant tissue-type plasminogen activator followed by PTA and vascular endoprosthesis. *Acta Radial Suppl* 377: 29-34.
- [78] Bethard GA (1994): Mechanical versus pharmacomechanical thrombolysis for the treatment of thrombosed dialysis access graft. *Kidney Int*; 45(5): 1401-6.
- [79] Trerotola SO, Lund GB, Scheel PJ Jr, Savader SJ, Venbrux AC, Osterman FA Jr (1994): Thrombosed dialysis access grafts: percutaneous mechanical declotting without urokinase. *Radiology*; 191(3): 721-6.
- [80] Middlebrook MR, Amygdalos MA, Soulen MC, Haskal ZJ, Shlansky-Goldberg RD, Cope C, Pentecost MJ (1995): Thrombosed hemodialysis grafts: percutaneous mechanical balloon declotting versus thrombolysis. *Radiology*; 196(1): 73-7.
- [81] Uflacker R, Rajagopalan PR, Vujic I and Stutley JE (1996): Treatment of thrombosed dialysis -access grafts: randomized trial of surgical thrombectomy versus mechanical thrombectomy with the Amplatz device. *Journal of Vascular and International Radiology*; 7 (2): 185-92.

- [82] Vorwerk D, Konner K, Schurmann K and Gunther RW (1997): A simple trick to facilitate bleeding control after percutaneous hemodialysis fistula and graft interventions. *Cardiovascular and Interventional Radiology*; 20(2): 159-60.
- [83] DeCaprio JD, Valentine JR, Kakish MB, Awad R, Hagino RT, Clagett GP (1997): Steal syndrome complicating hemodialysis access. *Cardiovasc. Surg*; 5 (6): 648-653.
- [84] Lazarides MK, Staamos DN, Panagopoulos GN, Tzilalis VD, Eleftheriou GJ, Dayantas JN (1998): Indications for surgical treatment of angioaccess-induced arterial "steal". *J Am Coll Surg*; 187(4): 422-426.
- [85] Strandness DE, Gibbons GE, Bell JW (1962): Mercury strain gauge plethysmography: evaluation of patients with acquired arteriovenous fistulas. *Arch. Surg.*; 85(2): 215-219.
- [86] Tordoir JH, Dammers R, van der Sande FM (2004): Upper extremity ischemia and hemodialysis vascular access. *Eur J Vasc Endovasc Surg* 27(1): 1-5.
- [87] Shemesh, D, Mabweesh, NJ, Abramowitz, HB (1999): Management of dialysis access-associated steal syndrome: use of intra-operative duplex ultrasound scanning for optimal flow reduction. *J. Vasc. Surg*; 30(1): 193-195.
- [88] Schanzer H, Schwartz M, Harrington E, Haimov M (1988): Treatment of ischemia due to "steal" by arteriovenous fistula with distal artery ligation and revascularization. *J Vasc Surg*; 7(6): 770-3.
- [89] Minion DJ, Moore E, Endean E (2005): Revision using distal inflow: A novel approach to dialysis-associated steal syndrome. *Ann Vasc Surg*; 19(5): 625-8.
- [90] Zanol J, Kruger U, Scholz H (2006): Proximalization of the arterial inflow: a new technique to treat access-related ischemia. *J Vasc Surg*; 43(6): 1216-21.
- [91] Remuzzi G (1988): Bleeding in renal failure, *Lancet*. 28; 1(8596): 1205-8.
- [92] Zibari, GB, Rohr, MS: Landrenau, MD, bridges, RM, De Vault, GA, Petty, FH, Costley, KJ, Brown, ST, McDonald, JC (1988): Complications from permanent hemodialysis vascular access. *Surgery*; 104(4): 681-6.
- [93] Irvine C, Holt P (1989): Hand venous hypertension complicating arteriovenous fistulas construction for hemodialysis. *Clin Exper Dermatol*, 14(4): 289-90.
- [94] Deshmukh N, Reppert M (1993): Venous ulceration of the hand secondary to a Cimino fistula. *Mil Med*, 158(11): 752-3.
- [95] Gadallah MF, El-Shahawy MA, Campese VM (1993): Unilateral breast enlargement secondary to hemodialysis arteriovenous fistulas and subclavian vein occlusion. *Nephron*, 63(3): 351-3.
- [96] Bogaert AM, Vanholder R, De Roose J, Kint A, Mathys E, Ringoir R (1987): Pseudo-Kaposi's sarcoma as a complication of Brescia-Cimino arteriovenous fistulas in hemodialysis patients. *Nephron*, 46(2): 170-3.

- [97] Riggs E Jr, Moss AH, Labosky DA, Liput JH, Morgan JJ, Gutmann L (1989): Upper extremity ischemic monomelieneuropathy a complication of vascular access procedures in uremic diabetic patients. *Neurology*, 39(7): 997-8.
- [98] Wilson SE (1996): Complications of vascular access procedure. In: Wilson SE (ed). *Vascular access (principles and practice)* 3rd ed. Mosby St. Louis, PP: 212-274.
- [99] Lala MS (1985): Problems and prospect of internal arterio-venous fistula for hemodialysis. *Angiology*; 36(1): 27-32
- [100] Anderson CB, Groce MA (1975): Banding of arteriovenous dialysis fistulas to correct high-output cardiac failure. *Surgery*, 78(5): 552-554.
- [101] Ridao-Cano N, Polo JR, Polo J, Perez-Garcia R, Sanchez M, Gomez-Campdera FJ (2002): Vascular access for dialysis in the elderly. *Blood Purif*; 20(6): 563-8.
- [102] Rayner HC, Pisoni RL, Gillespie BW, Goodkin DA, Akiba T, Akizawa T, Saito A, Young EW, Port FK (2003): Creation, cannulation and survival of arteriovenous fistulae: data from the Dialysis Outcomes and Practice Patterns Study. *Kidney Int*; 63(1): 323-330.
- [103] Hernandez T, Saudan P, Berney T, Merminod T, Bednarkiewicz M, Martin PY (2005): Risk factors for early failure of native arteriovenous fistulas. *Nephron Clin Pract*; 101(1): c39-c44.
- [104] Murphy GJ, Nicholson ML (2002): Autogeneous elbow fistulas: the effect of diabetes mellitus on maturation, patency, and complication rates. *Eur J Vasc Endovasc Surg*; 23(5): 452-457.
- [105] Akoh JA, Sinha S, Dutta S, Opaluwa AS, Lawson H, Shaw JF, Walker AJ, Rowe PA, McGonigle RJ (2005): A 5-year audit of haemodialysis access. *Int J Clin Pract*; 59(7): 847-851.
- [106] Polkinghorne KR, Atkins RC, Kerr PG (2004): Determinants of native arteriovenous fistula blood flow. *Nephrology (Carlton)*; 9(4): 205-211.
- [107] Weitzig GA, Gough IR, Furnival CM (1985): One hundred cases of arteriovenous fistula for haemodialysis access: the effect of cigarette smoking on patency. *Aust N Z J Surg*; 55(6): 551-554.
- [108] Bumann M, Niebel W, Kribben A, Philipp T, Heemann U (2003): Primary failure of arteriovenous fistulae in auto-immune disease. *Kidney Blood Press Res*; 26(5-6): 362-367.
- [109] Lin PH, Bush RL, Nelson JC, Lam R, Paladugu R, Chen C, Quinn G, Lumsden AB (2003): A prospective evaluation of interrupted nitinol surgical clips in arteriovenous fistula for hemodialysis. *Am J Surg*; 186(6): 625- 630.
- [110] Schild AF, Pruett CS, Newman M, Raines J, Petersen F, Konkin T, Kim P, Dickson C, Kirsch WM (2001): The utility of the VCS clip for creation of vascular access for hemodialysis: long-term results and intraoperative benefits. *Cardiovasc Surg*; 9(6): 526-530.

- [111] Perera GB, Mueller MP, Kubaska SM, Wilson SE, Lawrence PF, Fujitani RM (2004): Superiority of autogenous arteriovenous hemodialysis access: maintenance of function with fewer secondary interventions. *Ann Vasc Surg*, 18(1): 66-73.
- [112] Garcia-Pajares R, Polo JR, Flores A, Gonzales-Tabares E, Solis JV (2003): Upper arm polytetrafluoroethylene grafts for dialysis access. Analysis of two different graft sizes: 6 mm and 6-8 mm. *Vasc Endovascular Surg*; 37(5): 335-343.
- [113] Lemson MS, Tordoir JH, van Det RJ, Welten RJ, Burger H, Estourgie RJ, Stroecken HJ, Leunissen KM (2000): Effects of a venous cuff at the venous anastomosis of polytetrafluoroethylene grafts for hemodialysis vascular access. *J Vasc Surg* 2000; 32(6): 1155-1163.
- [114] Weale AR, Barwell J, Chant H, Lear PA, Mitchell DC (2004): The impact of training on outcomes in primary vascular access surgery *Ann R Coll Surg Engl*; 86(4): 275-80.
- [115] Tessitore N, Lipari G, Poli A, Bedogna V, Baggio E, Loschiavo C, Mansueto G, Lupo A (2004): Can blood flow surveillance and pre-emptive repair of subclinical stenosis prolong the useful life of arteriovenous fistulae? A randomized controlled study. *Nephrol Dial Transplant*; 19(9): 2325-2333.
- [116] Saran R, Dykstra DM, Pisoni RL, Akiba T, Azikawa T, Canaud B, Chen K, Piera L, Saito A, Young EW (2004): Timing of first cannulation and vascular access failure in haemodialysis: an analysis of practice patterns at dialysis facilities in the DOPPS. *Nephrol Dial Transplant*; 19(9): 2334-2340.
- [117] Andrassy K, Malluche H, Bornefeld H, Comberg M, Ritz E, Jesdinsky H, Möhring K (1974): Prevention of p.o. clotting of AV. Cimino fistulae with acetylsalicyl acid: results of a prospective double blind study. *Klin Wochenschr*; 52(7): 348-349.
- [118] Saran R, Dykstra DM, Wolfe RA, Gillespie B, Held PJ, Young EW (2002): Association between vascular access failure and the use of specific drugs: the Dialysis Outcomes and Practice Patterns Study (DOPPS). *Am J Kidney Dis*; 40(6): 1255-1263.
- [119] Kaufman JS, O'Connor TZ, Zhang JH, Cronin JH, Flore LD, Ganz MB, Goldfarb DS, Peduzzi PN (2003): Randomised controlled trial of clopidogrel plus aspirin to prevent hemodialysis access graft thrombosis. *J Am Soc Nephrol*; 14(9): 2313-2321.
- [120] LeSar CJ, Merrick HW, Smith MR (1999): Thrombotic complications resulting from hypercoagulable states in chronic haemodialysis vascular access. *J Am Coll Surg*; 189(1): 73-79.
- [121] Biggers JA, Remmers AR Jr, Glassford DM, Sarles HE, Lindley JD, Fish JC (1977): The risk of anticoagulation in hemodialysis patients. *Nephron*, 18(2): 109-13.
- [122] NKF-DOQI (2001): Clinical practice guidelines for vascular access: Update 2000. *Am J Kidney Dis* 37[Suppl 1]: S137-S181.

- [123] Agharazii M, Plamondon I, Lebel M, Douville P, Desmeules S (2005): Estimation of heparin leak into the systemic circulation after central venous catheter heparin lock. *Nephrol Dial Transplant* 20: 1238-1240.
- [124] Rioux JP, De Bortoli B, Troyanov S, Madore F (2008): The effect of sodium citrate 4% locking solution for central venous dialysis catheter on the international normalized ratio (INR) value. *Nephrol Dial Transplant* 23: 1772-1773.
- [125] Karaaslan H, Peyronnet P, Benevent D, Lagarde C, Rince M, Leroux-Robert C (2001): Risk of heparin lock-related bleeding when using indwelling venous catheter in haemodialysis. *Nephrol Dial Transplant* 16: 2072-2074.
- [126] Thomas CM, Zhang J, Lim TH, Scott-Douglas N, Hons RB, Hemmelgarn BR (2007): Alberta Kidney Disease Network: Concentration of heparin-locking solution and risk of central venous hemodialysis catheter malfunction. *ASAIO J* 53: 485-488.
- [127] Kuypers DR, Claes K, Evenepoel P, Maes B, Vanrenterghem Y (2005): A prospective, randomized, double-blind crossover study on the use of 5% citrate lock versus 10% citrate lock in permanent hemodialysis catheters. *Blood Purif* 23: 101-105.
- [128] Dogra GK, Herson H, Hutchison B, Irish AB, Heath CH, Golledge C, Luxton G, Moody H (2002): Prevention of tunneled hemodialysis catheter-related infections using catheter-restricted filling with gentamicin and citrate: A randomized controlled study. *J Am Soc Nephrol* 13: 2133-2139.
- [129] Lok CE, Appleton D, Bhola C, Khoo B, Richardson RM (2007): Trisodium citrate 4%: An alternative to heparin capping of haemodialysis catheters. *Nephrol Dial Transplant* 22: 477-483.
- [130] Macrae JM, Dojcinovic I, Djurdjev O, Jung B, Shalansky S, Levin A, Kiaii M (2008): Citrate 4% versus heparin and the reduction of thrombosis study (CHARTS). *Clin J Am Soc Nephrol* 3: 369-374.
- [131] Grudzinski L, Quinan P, Kwok S, Pierratos A (2007): Sodium citrate 4% locking solution for central venous dialysis catheters: An effective, more cost-efficient alternative to heparin. *Nephrol Dial Transplant* 22: 471-476.
- [132] McGill RL, Spero JA, Sysak JC, Sandroni SE, Marcus RJ (2008): Tissue plasminogen activator as a hemodialysis catheter locking solution. *Haemodial Int*; 12: 348-351.
- [133] Gittins NS (2007): Comparison of alteplase and heparin in maintaining the patency of paediatric central venous haemodialysis lines: A randomised controlled trial. *Arch Intern Med* 92: 499-501.
- [134] Coli L, Donati G, Cianciolo G, Raimondi C, Comai G, Panicali L, Natasi V, Cannarile DC, Gozzetti F, Piccari M, Stefoni S (2006): Anticoagulation therapy for the prevention of hemodialysis tunneled catheters (TCC) thrombosis. *J Vasc Access* 7: 118-122.
- [135] Willms L, Vercaigne LM (2008): Does warfarin safely prevent clotting of hemodialysis catheters? *Semin Dial* 21: 71-77.

- [136] Suhocki PV, Conlon PJ, Knelson MH, Harland R, Schwab SJ (1996): Silastic cuffed catheters for hemodialysis vascular access: Thrombolytic and mechanical correction of malfunction. *Am J Kidney Dis* 28: 379-386.
- [137] Daeihagh P, Jordan J, Chen GJ, Rocco M (2000): Efficacy of tissue plasminogen activator administration on patency of hemodialysis access catheters. *Am J Kidney Dis* 36: 75-79.
- [138] Spry LA, Miller GA (2001): Low-dose tPA for hemodialysis catheter clearance. *Dial Transplant* 30: 10-12.
- [139] Moss AH, Vasilakis C, Holley JL, Foulks CJ, Pillai K, Mc-Dowell DE (1990): Use of a silicone dual-lumen catheter with a Dacron cuff as a long-term vascular access for hemodialysis patients. *Am J Kidney Dis* 16: 211-215.
- [140] Zacharias JM, Weatherston CP, Spewak CR, Vercaigne LM (2003): Alteplase versus urokinase for occluded hemodialysis catheters. *Ann Pharmacother*; 37: 27-33.
- [141] Twardowski ZJ (1998): High-dose intradialyticurokinase to restore the patency of permanent central vein hemodialysis catheters. *Am J Kidney Dis* 31: 841-847.
- [142] Lee T, Barker J, Allon M (2005): Tunneled catheters in hemodialysis patients: Reasons and subsequent outcomes. *Am J Kidney Dis* 46: 501-508.
- [143] Allon M (2004): Dialysis catheter-related bacteremia: Treatment and prophylaxis. *Am J Kidney Dis* 44: 779-791.
- [144] Shah CB, Mittelman MW, Costerton JW, Parenteau S, Pelak M, Arsenault R, Mermel LA (2002): Antimicrobial activity of a novel catheter lock solution. *Antimicrob Agents Chemother* 46: 1674-1679.
- [145] Dogra GK, Herson H, Hutchison B, Irish AB, Heath CH, Golledge C, Luxton G, Moody H (2002): Prevention of tunneled hemodialysis catheter-related infections using catheter-restricted filling with gentamicin and citrate: A randomized controlled study. *J Am SocNephrol* 13: 2133-2139.
- [146] Kim SH, Song KI, Chang JW, Kim SB, Sung SA, Jo SK, Cho WY, Kim HK (2006): Prevention of uncuffed hemodialysis catheter-related bacteremia using an antibiotic lock technique: A prospective randomized clinical trial. *Kidney Int* 69: 161-164.

IntechOpen

IntechOpen

