

# We are IntechOpen, the world's leading publisher of Open Access books Built by scientists, for scientists

## 4,800

Open access books available

## 122,000

International authors and editors

## 135M

Downloads

Our authors are among the

## 154

Countries delivered to

## TOP 1%

most cited scientists

## 12.2%

Contributors from top 500 universities

**WEB OF SCIENCE™**Selection of our books indexed in the Book Citation Index  
in Web of Science™ Core Collection (BKCI)

Interested in publishing with us?  
Contact [book.department@intechopen.com](mailto:book.department@intechopen.com)

Numbers displayed above are based on latest data collected.

For more information visit [www.intechopen.com](http://www.intechopen.com)

---

# Arteriovenous Fistula or Catheter: Creating an Optimal Vascular Access for Hemodialysis

---

Joëlle Cridlig, Michèle Kessler and Thanh Cao-Huu

Additional information is available at the end of the chapter

<http://dx.doi.org/10.5772/45929>

---

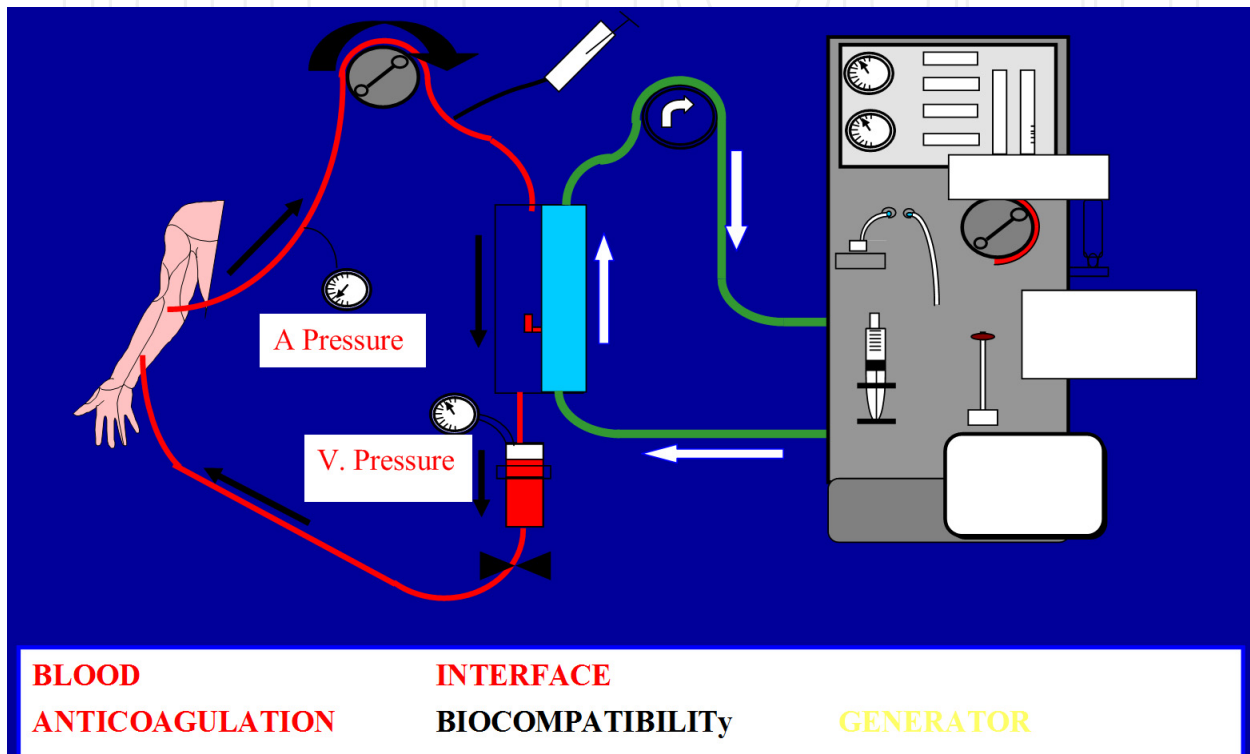
## 1. Introduction

Hemodialysis has been used for half a century and is often proposed as the first support treatment for patients developing end-stage renal disease, more frequently than peritoneal dialysis and kidney transplantation. For a large part, the success of hemodialysis depends on the success of the vascular access, whether achieved with an arteriovenous fistula or a central venous catheter. Survival of the vascular access often determines the patient's survival, emphasizing the importance of carefully preserving the often limited stock of available vascular tissue. The purpose of this chapter is to review the different possibilities for vascular access for hemodialysis, from planning to construction, including a discussion on the importance of complementary explorations for complex situations or complications. Clinical cases will be presented to illustrate how multidisciplinary management can meet the challenge of desperate "last chance" situations, providing lifesaving solutions for our patients.

## 2. Vascular access for hemodialysis: Background

Vascular access should enable obstacle-free blood flow for the extra corporeal hemodialysis circuit with appropriate inflow and outflow pressures (Figure 1). In addition, vascular access should not cause any deleterious consequences for the patient such as limb ischemia related to steal phenomena, stasis edema or compressive effects (for instance in the head and neck) due to a peripheral or central stenosis blocking venous backflow. An excessive flow rate can compromise cardiac function. Several types of vascular access are available, with two modalities: catheter and fistula. In the past, the first hemodialysis systems used an external shunt made by inserting canulas into an artery and a vein (lower or upper limbs), for

example the Thomas shunt [1], creating an extracorporeal circulation. In the sixties, improved techniques allowed the creation of the first arteriovenous fistula (AVF), an anastomotic bypass between an artery and a vein [2]. AVFs may be positioned on the upper limb or the lower limb, proximally or distally. Single or double-flow central venous catheters may also be inserted into the large veins of the neck or thigh, with or without tunnelization.



**Figure 1.** Hemodialysis circuit (From T. Cao-Huu with permission)

### 3. Catheter or arteriovenous fistula (AVF): The rationale

A central venous catheter may be used for vascular access in emergency situations in patients unprepared for hemodialysis or if an intercurrent event, for example thrombosis of the AVF, infection or any situation contraindicating the usual access, occurs in a patient already on hemodialysis. Insertion of a central catheter has the advantage of offering immediate high-flow vascular access but should, according to the guidelines issued by the National Kidney Foundation Kidney Disease Outcome Quality Initiative (KDOQI), be used in less than 10% of patients [3]. Data from the United States Renal Data System (USRDS) however revealed that in 2009 more than 80% of patients started dialysis with a central catheter. Practices in Europe and the United States differ as shown by the DOPPS study which, after adjustment for confounding factors, compared vascular access practices, focusing on particular

factors associated with use of a native AVF versus graft or catheter [4]. The prevalence of native AVF use was found to be 80% in Europe versus 24% in the US. At dialysis onset, 66% of European patients had an AVF (including 2% with a prosthetic graft) versus 15% in the US [24% prosthetic graft). Patient referral patterns, nephrological follow-up and the type of vascular access used are directly related: closely monitored patients are better prepared for dialysis. There is also an economic element, related to general population access to health-care [5].

It is argued that more complications occur with a catheter than with an AVF [6-10]. A review of the literature confirms the superiority of the native AVF over prosthetic material or catheters. Longer life, fewer mechanical complications (thrombosis, stenosis), and lower infectious risk are advantages of the native AVF. It is the recommended vascular access, and should be considered as the gold standard [3][10][11].

Quality-of-life [12] and morbidity-mortality risk, especially in the elderly [13], are directly related to the type of vascular access first used for dialysis. There is a real advantage if the first vascular access is a native or graft AVF [14]. Survival is also improved [15].

A central catheter may however be quite useful for temporary (or permanent) vascular access in particular situations: living-donor graft involvement; short life expectancy (cancer); waiting for an AVF to mature; permanent access despite a highly deteriorated vascular system; heart failure; severe arteriopathy with risk of steal phenomena [16]. For the congestive heart failure patient, preemptive construction of an AVF has been shown to be a source of decompensation[17].

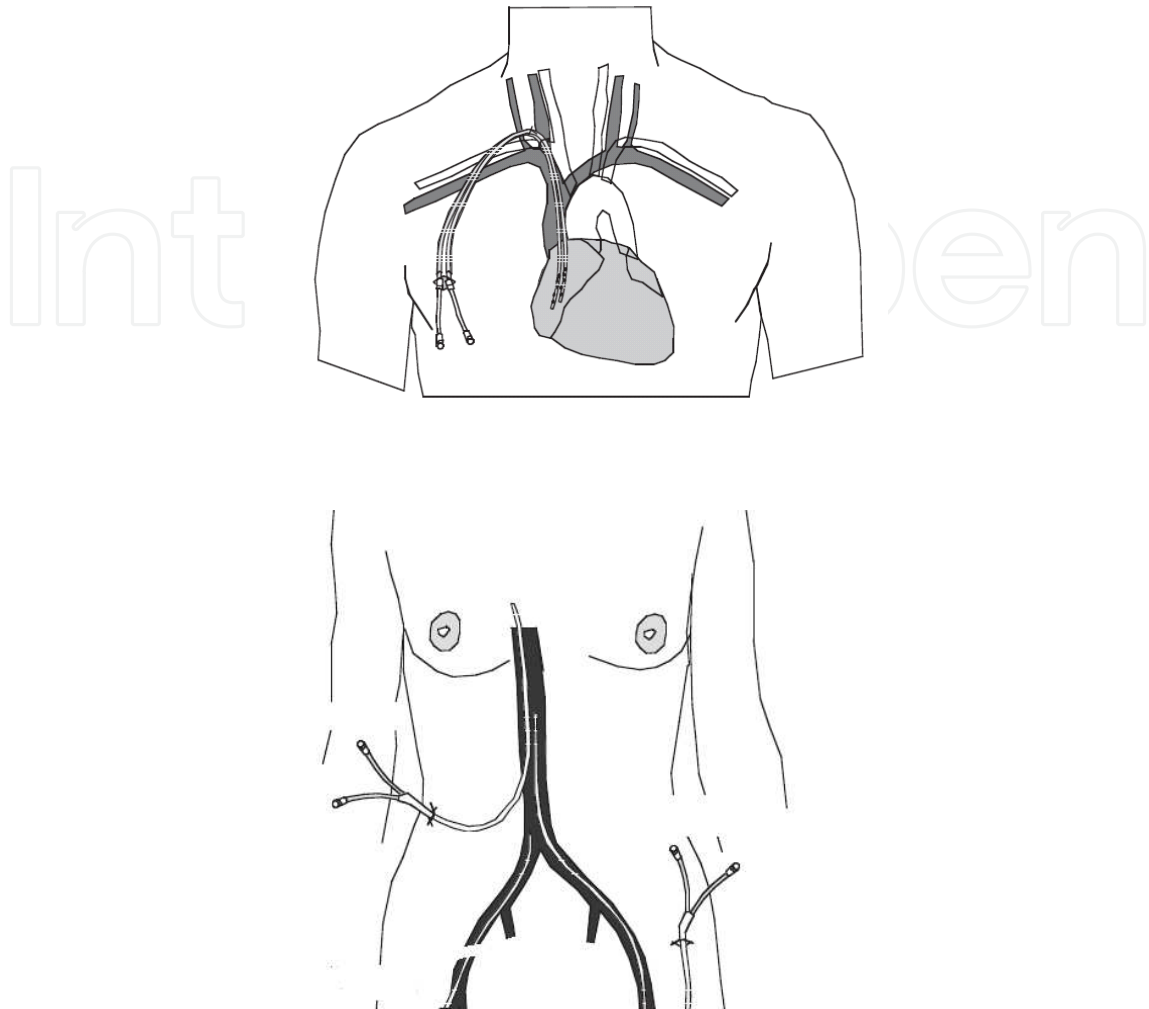
## 4. Choosing a vascular access for hemodialysis

### 4.1. Catheter

#### 4.1.1. Types used

Catheters have been carefully designed to respond to the needs of the dialysis patient. Prerequisites include appropriate flow rate and clearance quality (diameter, separate branches, multiperforated tip), physical resistance (flexibility/rigidity, composing material: silicone, polyurethane...), tolerance (internal medium, blood/material interactions, surfacing processes), and cosmetic acceptability. Portacaths and tunnelization have been used since 1987, greatly reducing the risk of infection by increasing the distance between the point of entry into the central vein and the point of exit through the skin [18] (Figure 2).

To access central veins, priority should be given to jugular (and secondarily infraclavicular) puncture to reach the superior vena cava, first on the right side, and secondarily on the left side. Access to the inferior vena cava, via a femoral or translumbar puncture, should always be a second-intention procedure.



**Figure 2.** Example of a cuffed catheter (From B. Canaud with permission)

#### 4.1.2. Technical modalities

There are a certain number of clinical prerequisites for catheter insertion. Attention must be given to the patient's history of vascular access and potential problems or anomalies, the risk of stricture often revealed by collateral circulation, and the presence of edema.

Ultrasound guidance has a proven impact on reducing the risk of complications [19]. The pitfalls of blind puncture (anatomic variations or unknown strictures or thrombi) may be avoided. This may be especially important in catheter-naïve patients or those with a past history of vascular access.

Hemostasis should be checked. Treatments (anticoagulants) and specific clinical features (hemodynamic situation, respiratory function, general status) should be noted before attempting to position a central catheter.

A chest X-ray may be useful during catheter insertion but in general is obtained in the radiology unit after completing the procedure. Local practices depend on available facilities (catheter insertion feasible in the radiology unit?).

Catheter maintenance is a multifactorial process. Rigorous aseptic manipulation is the rule. Different types of impregnated locks can be proposed depending on the objective [20]: anticoagulation, fibrinolysis, anti-infectious or anti-septic effect (tauludine, citrate). The debate continues concerning the longevity of non-tunnelized catheters: guidelines vary from 1 to 3 weeks. These catheters are however often used for much longer periods of time. It is also generally accepted that tunnelized catheters should be a temporary option while waiting for the maturation of an AVF, although clinical practice may dictate using them as the permanent vascular access (AVF unfeasible, frail elderly patient) [21].

#### *4.1.3. Acute complications*

Different types of acute intra-operative complications are noted: hemorrhage, traumatic arterial or venous puncture with vessel laceration, pneumothorax, hemothorax, air embolism, dysrhythmia, neurological injury, malposition [22-24].

#### *4.1.4. Long-term complications [25]*

Long-term complications are usually related to the duration of use and insertion [26] and in general affect the quality of dialysis. According to the KDOQI, catheter dysfunction is defined as blood flow <300ml/min and blood pressure >250 mmHg [3]. There are many causes related to mechanical problems or clot formation. Mechanical obstruction may arise if the catheter is folded or malpositioned (a catheter is considered to be too short or too long depending on the position of the tip in relation to the right atrium). Clotting may result from a blood-material interaction leading to progressive formation of a fibrin sheath around the catheter. Blood clots may also form at the tip of the catheter because of perturbed blood flow or microtrauma. This is the leading cause of catheter dysfunction [27].

Infection is another important complication. A venous catheter constitutes a portal with the inherent risk of colonization and dissemination. In the chronic hemodialysis patient, it is the leading source of infection [28], which in turn is the leading cause of morbidity and mortality [29].

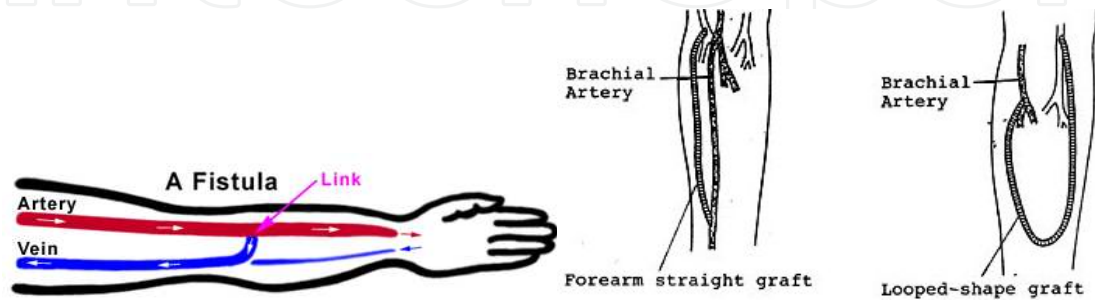
Central veins repeatedly exposed to catheters may develop zones of stenosis [30]. The hypothesized pathogenic mechanism would involve repeated microtrauma injuring the endothelium, turbulent blood flow, local uremic context related to the renal failure, chronic inflammation, and activation of the coagulation cascade. The use of the left side would have an impact since the catheter has to be longer and local anatomic conditions are less favorable (compression). Similarly, complications would be more common after infraclavicular puncture compared with jugular puncture due to the anatomic configuration.



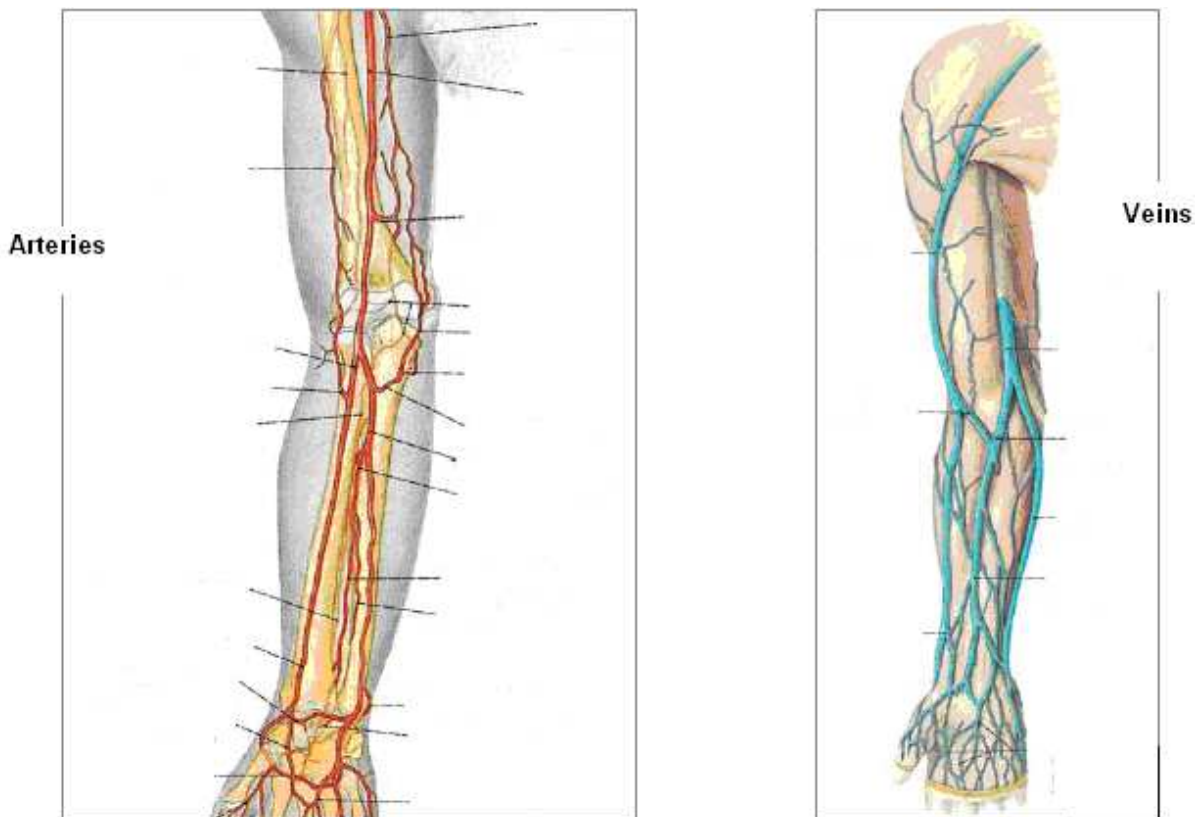
## 4.2. Arteriovenous fistula

### 4.2.1. Types used

Several types of AVF are proposed (Figure 3), using different upper or lower limb arteries and veins, with or without a graft (straight forearm graft, looped-shape graft). Beyond vessel quality and the patient's past history and clinical situation, the only limitation for fistula configuration appears to be the creativity of the nephrologist and surgeon [31] (Figure 4).



**Figure 3.** Native and prosthetic arteriovenous fistulas (from T Cao-Huu with permission)



**Figure 4.** Map of forearm vessels (from T Cao-Huu with permission)

One question often raised is whether the patient's endogenous vasculature or a prosthetic graft should be preferred. Most clinicians prefer to reserve prosthetic grafts as a second intention option after failure of one or more native AVF, or if the existing vascular network is unusable, as a first intention proposal. The advantage is that native AVFs mature more rapidly and offer easier more effective surgical access should a thrombotic event occur [32]. One retrospective study found that the risk of access failure is higher with a graft compared with a native AVF [33], both for first and second intention accesses. Greater longevity, better quality and fewer surgical revisions are all advantages of the native AVF over the graft [34]. If a native AVF is not feasible, a graft would be superior to a central catheter in terms of complications, although opinions have varied [36]. The Flixene graft composed of synthetic material (PTFE) is easy to puncture. To date, there has not been any clinical study comparing mechanical complications with Flixene and vascular grafts.

#### 4.2.2. Technical modalities

The construction of a vascular access for hemodialysis is a crucial event affecting the patient's quality-of-life and survival. European and American guidelines have been issued [37][38].

Several parameters and pre-operative explorations must be taken into account [38][39]:

- Patient characteristics: genetic background, age, dominant hand, spare vessels, co-morbid conditions (diabetes, arteriopathy), status of venous network, prior attempts to form an access, presence of a pacemaker, coagulation disorders, heart failure (risk of decompensation if the fistula flow rate is too high), possibility for anesthesia, patient education, future renal transplantation (waiting list, blood group, anti-HLA immunization, projected living-donor graft);
- Physical examination: vessel map and vessel characteristics [40], signs of collateral circulation or edema suggesting possible strictures, Allen maneuver to search for steal phenomena and other vascular functions [41];
- Imaging findings: ultrasound, computed tomography angiogram;
- Biochemical parameters would also have an impact although formal evidence is lacking [42];
- Physician experience and training (nephrologist and surgeon) also affect outcome [43].

A recent study showed that according to the responding nephrologists, selection criteria for AVF candidates are quite variable. No consensus has been reached concerning the appropriate indications and contraindications for creating an AVF [44].

#### 4.2.3. Acute complications

Early complications are mainly related to the operative procedure and include hematoma, operative site infection, defective wound healing, and neurological problems.



#### 4.2.4. Long-term complications [45]

Complications occurring late are also quite variable: retarded maturation requiring collateral ligation to favor development; need to change the site of anastomosis; a vein too deep for puncture (e.g. superficialization of a humerocephalic AVF); bleeding; ischemia related to steal phenomena; flow rate too high for cardiac output requiring a smaller caliber or a DRIL procedure); aneurismal or necrotic lesions related to puncture; thrombotic events and strictures of the AVF itself or of the central veins. No direct link between daily dialysis sessions and complication rate has been demonstrated [46]. Infection is also a serious complication, sometimes diffusing to multiple sites (endocarditis, spondylodiscitis).

#### 4.2.5. Good clinical practices for AVF [38][37]

As a rule, a good AVF will exhibit optimal development. This means avoiding complications and treating those which do develop early. It also means limiting the risk of thrombosis and stricture by avoiding the use of venous access in emergency situations. The site chosen for the AVF should be as distal as possible in order to facilitate puncture and spare more proximal veins for later use if needed. The AVF should be on the dominant side.

What is an ideal AVF? According to both the American [38] and European [37] guidelines, the first-intention AVF should be native and distal. Case-by-case decision making nevertheless determines the optimal configuration: e.g. a proximal fistula because of an insufficient distal network; a distal fistula to avoid high flow rate in a patient with heart failure; a synthetic graft or a central venous catheter in a patient with poor vessel quality.

When should the AVF be constructed? Considering past experience and available evidence, concerted action has been undertaken in several countries to increase the proportion of first-intention AVFs used for hemodialysis vascular access [47-49]. No consensus has been reached concerning the optimal position for the AVF in the end-stage renal disease dialysis patient. The decision depends on how fast the kidney disease progresses, and the availability of healthy arterial and venous tissue. In the emergency context, a temporary access may have to be created rapidly, followed by a final configuration determined later: position of the permanent vascular access, option for peritoneal dialysis, etc[37].

When can an AVF be punctured? According to the KDOQI [3], indicators of optimal maturation include flow rate >600 ml/m and 6-mm inner diameter. In clinical practice, operator skill greatly affects the decision to use an AVF or not, and consequently, its longevity. Good clinical practices focus on local hygiene and puncture technique (button-hole puncture, compression after needle withdrawal). Care must be taken to avoid infections, aneurysms or necrotic tissue and strictures. Several studies have compared the use of the button-hole option versus a rotation of the puncture points. Results have been discordant concerning the advantages and disadvantages of the two methods (pain, ease of puncture, infection rate) [50, 51]. There is also the question of the number of needles. Unipuncture can be useful if the fistula cannot be punctured readily or if it is too short to insert two needles. It can also be a solution if a bipuncture venous catheter cannot be inserted. Well performed, unipuncture can enable good quality dialysis, with equivalent morbidity and mortality compared to the bipuncture

technique. Data are lacking concerning a potential reduction in the complication rate with unipuncture.

How should the AVF be monitored? Various methods can be used to check vascular access function and detect the development of complications: physical examination, education of patients and nurses, venous pressure, blood recirculation and flow rate, clearance (kt/v), duplex Doppler, CTangiogram, or fistulography, which can be performed with or without compression, particularly to identify steal phenomena. Combining these explorations often provides complementary information. The KDOQI proposes a basic algorithm for monitoring these elements [38]. A software based on impedancemetry combined with tomography angiography is an innovative technology allowing study of flow rates and pressures within the AVF and thus early detection of potential complications [52].

## 5. Multidisciplinary management: Key to success

Nephrologists, radiologists, and vascular surgeons working together to find the most appropriate solution for each individual patient, before, during and after construction of the vascular access is the key to success. The goal is to achieve the best possible vascular access which will survive as long as possible.

In the following sections, we present a few examples of patients referred to our center with a failing vascular access. These 'desperate' cases illustrate how audacious solutions may be found for lifesaving vascular access.

### 5.1. Catheter failure

#### 5.1.1. General statement

Catheter failure generally occurs in patients who have had several catheters or when AVF is no longer feasible. Mechanical complications are however becoming less and less common because of the greater flexibility and longer stability provided by the new materials: polyurethane and silicone. Neither material has proven superiority over the other [18].

In the past, immediate withdrawal was the rule when infection developed in a catheter-bearing patient. This is still the basic attitude for non-tunnelized catheters. If however the catheter is tunnelized, most clinicians now consider that a probabilistic antibiotic regimen can be initiated in combination with aseptic wash-out (skin orifices, subcutaneous tunnel). An antibiotic lock is also useful. If the course is unfavorable (poor control of infection markers, secondary spread), the catheter must be withdrawn rapidly [53].

In general, for a non-tunnelized catheter, thrombus-related complications (clot formation within the catheter, fibrin sheath) are treated by withdrawal. For a tunnelized catheter, thrombolytic agents (urokinase) are often used. Short-term results have been satisfactory, but long-term results less so [54]. To prevent recurrence, thrombolysis may be associated with oral anticoagulants or antiplatelet agents, but to date no real indication has been identi-

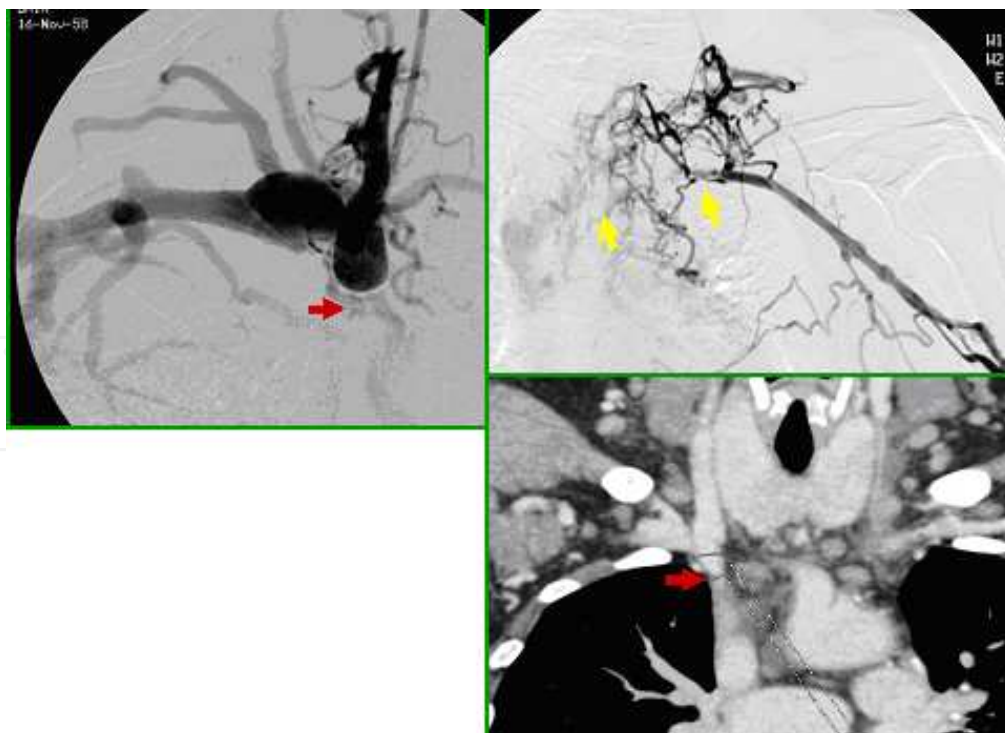
fied in this context and no consensus can be established from the currently available studies. There is no evidence supporting the efficacy of preventive treatment for AVF or central vein thrombotic events or strictures [55]. Salvage (mechanical extraction of a fibrin plug or blood clot) can be attempted with angioplasty equipment and balloons. Results have been promising [56, 57]. The KDOQI recommends extraction with catheter replacement [3].

For stenosis of the central veins, percutaneous angioplasty, with or without stenting, is preferred, especially for recurrent stenosis [58].

#### 5.1.2. Illustrative cases: Failing vascular access due to multiple strictures of the central veins and catheter dysfunction


Case n° 1: a large number of old thrombi obstructing the central veins and preventing catheter insertion. The problem was solved using a novel interventional radiology technique performed in cooperation with the vascular surgery team.

A 52-year-old obese woman with diabetes was referred for failing vascular access after loss of a kidney graft subsequent to non-compliance. Over the last five years, 12 central catheters (jugular and femoral access) had been used for dialysis. All attempts to fashion an AVF, on the right and on the left, had failed. The most recent central catheter was tunneled but failed due to thrombi in both brachiocephalic venous trunks (Figure 5). Several dilatation attempts had failed.

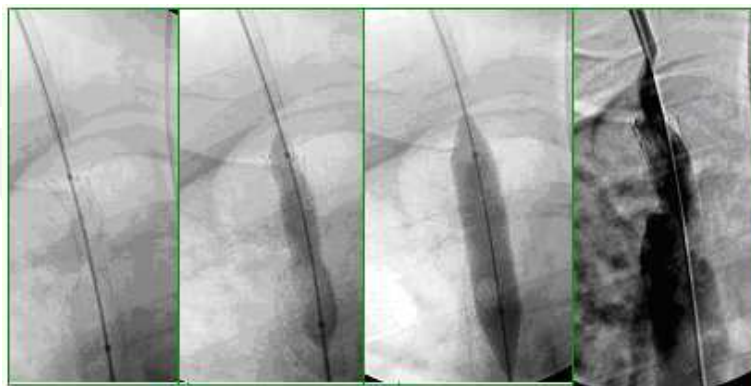


**Figure 5.** Thrombi in both brachiocephalic venous trunks; one was recent and long (yellow arrow); the older one was shorter (red arrow) (From T.Cao-Huu with permission)

The patient was referred with a tunnelized left femoral catheter complicated by a long thrombus in the right femoral vein. Imaging showed patent right subclavian and right cephalic veins so that a homolateral upper limb AVF would be feasible. In order to maintain the hemodialysis after constructing the AVF and waiting for it to mature, another angioplasty procedure was attempted to overcome the 1-cm obstruction in the right brachiocephalic trunk. Using an innovative “rendez-vous” technique, probes inserted via the femoral and jugular veins were passed through the obstruction and joined to dilate the stricture and insert a stent then a catheter. The procedure was performed under general anesthesia by a radiologist with a vascular surgeon back-up if necessary (Figure 6 and 7).



**Figure 6.** Dual access (10F) via the right common femoral vein and the right internal jugular vein. The right internal jugular probe was positioned on the superior aspect of the obstruction (green arrows). A lasso catheter was inserted via the femoral access up to the inferior aspect of the obstruction (blue arrows). Biplanar analysis showed the proximity of the two probes. A Chiba 23G needle (black arrows) was inserted via the jugular probe to puncture the thrombus. A 0.0014 In (yellow arrow) guidewire was fed through the Chiba needle and captured by the inferior lasso. (From T.Cao-Huu with permission)



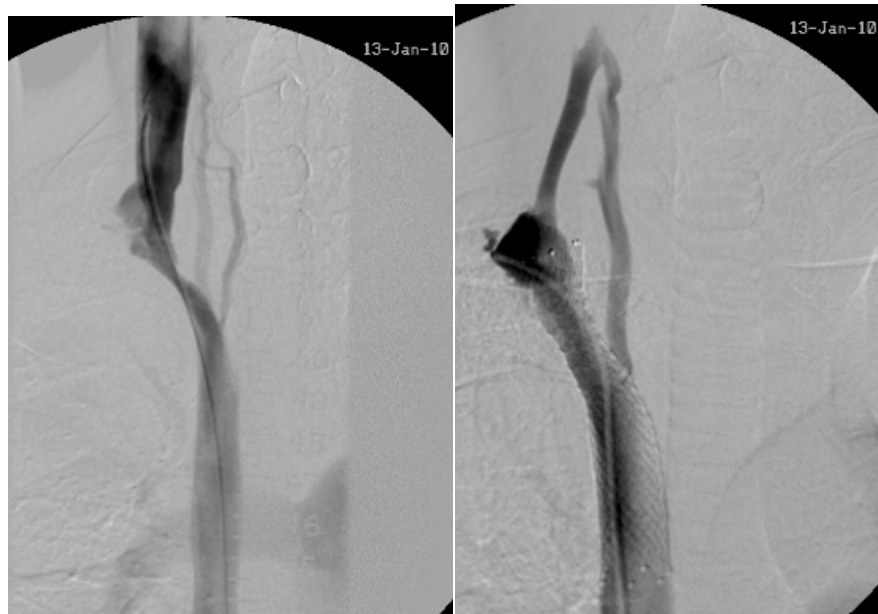
**Figure 7.** After 8, 10, and 12 mm balloon dilatations ⇒ 12-cm self-expansive stent completed with a 12-mm balloon. (From T.Cao-Huu with permission)

This patient was dialysed on her cuffed catheter and died about one year later, from a coronary disease.



Case n° 2: a problem of central venous stenosis solved by dilatation (and stenting) then secondary catheter insertion.

A 23-year-old patient who had developed cutaneous graft-versus-host disease after a bone marrow graft for leukemia was referred for calciphylaxia and very poor general status. At admission the work-up showed poor dialysis parameters and low flow rate from a left radial-radial native AVF. There were multiple arterial and venous strictures and a risk of hand ischemia. The angiogram visualized very frail calcified forearm arteries and thrombi in the left cubital artery, the left jugular vein, and the right brachiocephalic venous trunk. A multidisciplinary meeting with radiologists and vascular surgeons led to the decision to attempt stenting the right brachiocephalic venous trunk to insert two tunnelized catheters after dilatation (Figure 8).



**Figure 8.** Angioplasty and stenting of the stenosed right brachiocephalic venous trunk. (From T.Cao-Huu with permission)

The angioplasty was successful allowing intensified hemodialysis and associated treatment of the calciphylaxia (disodium thiosulfate) in preparation for renal transplantation, considered as an “emergency” procedure due to the failing vascular access and the calciphylaxia. Outcome was favorable, both for the kidney graft and the calciphylaxia.

## 5.2. Fistula failure: Multiple stenoses affecting the upper limb venous network and both central veins

Treatments for aneurismal complications, late fistula maturation, ischemia or high flow rate are well known and will not be discussed here. This chapter will focus on stenotic complications involving the fistula itself or the central veins and situations of failing vascular access

in patients who often have had a long history of successive attempts to create functional vascular accesses.

#### 5.2.1. General statement [59]

Evidence in the literature on patients prepared for hemodialysis with an AVF is formal: after adjustment for confounding factors, AVF survival is inversely proportional to the number of interventions needed to render it usable [60].

Two cases in our center have illustrated the negative impact of catheter-related stenosis of the central veins on vascular access. Treatment relies heavily on interventional radiology [61, 62].

In addition to the imaging explorations mentioned above, stenosis of the AVF can be detected clinically by measuring fistula flow rate during dialysis [63]. Patient and caregiver education is essential here. Invasive diagnostic procedures are not recommended per se and increase the cost of treatment, but if a stenosis is suspected clinically, further explorations should be undertaken to prevent the development of significant thrombosis [64]. To date, studies have been unable to demonstrate any difference in the long-term outcome of the fistula between surgery for thrombosis and pre-thrombotic treatment [65].

Angioplasty is the treatment of choice for fistula stenosis; stenting is optional. Various types of material have been tested. Ultra-high pressure balloons or cutting balloons can remove the atheroma from the vessel wall mechanically, but with the risk of vessel tears. Metallic stents can be coated with different surfacing agents to improve their longevity. Self-expandable stents are successful in only one-third of cases, but with no real impact on long-term AVF survival [66, 67].

A recent review [68] detailed the different phases of the interventions: angioplasty for stenosis of pre-thrombotic AVF and thrombectomy for thrombotic AVF (pressure or mechanical removal depending on the nature of the thrombus) followed by angioplasty if an associated stenosis is identified; systematic exploration of the central vascular network in order to avoid missing any stenosis-favoring stricture accessible to angioplasty. Short-term pharmacological treatment (anticoagulant, antiplatelet agents) may be useful.

#### 5.2.2. Illustrative cases: Steal syndrome and last chance access

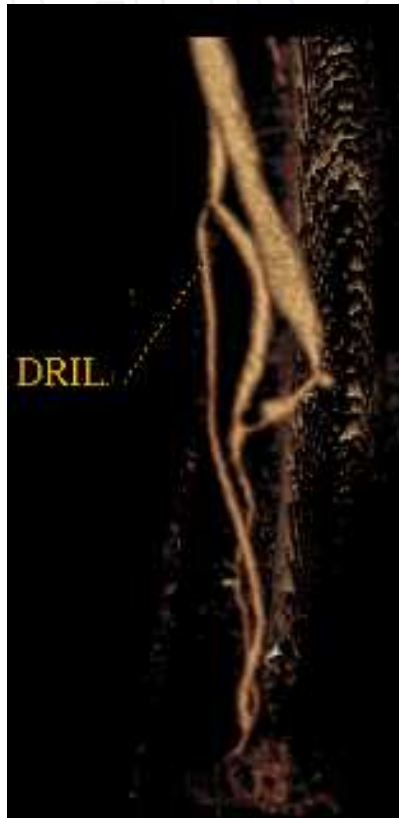
Case n°1: chronic hand ischemia in a 77-year-old patient with upper limb arteriopathy.

A Distal Revascularization Interval-Ligation (DRIL) (Figure 9) procedure was performed to reperfuse the distal arteries and save the fistula. Revascularization was achieved with a radial-radial bypass combined with ligation of the radial artery. It allowed a long term fistula, hand and patient survival. Other types of revascularization (e.g. prolongations) can also be proposed.

Case n° 2: extensive central venous stenosis involving the vena cava combined with intracardiac thrombotic formations treated with interventional radiology, avoiding thoracotomy for major heart surgery and preserving the vascular access.



This 56-year-old patient on chronic hemodialysis for uropathy subsequent to multiple trauma (traffic accident) had already had several central catheters and distal AVFs when he was referred to our unit for low flow rate in the right forearm gortex graft with central vein thrombus involving the superior vena cava. The final decision was to combine heparin with radiologic angioplasty because of the high risk of heart surgery. The successful intervention illustrates how the potentially serious consequences of a long history of vascular accesses can be resolved. This patient is still on hemodialysis, on his goretex graft that well work.



**Figure 9.** DRIL. (From T.Cao-Huu with permission)

Case n° 3: a young patient with recurrent fistula stenosis compromising the last dialysis access available.

This 26-year-old patient on hemodialysis since childhood for malformativeuropathy had had a kidney transplant before returning to hemodialysis due to non-compliance with drug regimen. He had a right tunnelized catheter for hemodialysis because successive attempts to fashion an AVF had failed. Thrombi developed bilaterally in the internal jugular vein, in the left brachiocephalic venous trunk and in the superior vena cava. Multiple episodes of catheter dysfunction occurred requiring successive replacements, complicated by repeated infections. Despite the very poor venous network and a very frail cubital vein, the vascular surgeon successfully created a right cubital AVF after repeated procedures to carefully dilate juxta-anastomotic strictures. Hemodialysis was continued for more than two years via this

fragile fistula while waiting for the progressive development of the basilic vein and subsequent construction and maturation of a humerobasilicgortex bypass. Despite recurrent stenosis with thrombus formation favored by a fold in the graft assembly at the elbow, the patient's hemodialysis protocol was conducted successfully until a second kidney graft could be implanted. This graft has a favorable outcome, but the patient has lost his fistula. This case illustrates the important contribution of an experienced vascular surgery team capable of creating a fistula with very little viable tissue.

The long term prognosis of these "difficult" patients is not easy to evaluate. With time these patients have also a high cardiovascular risk and even if an access for hemodialysis is successfully created, some of them died from a cardiovascular event. It reflects the links between the vascular deadlock and the global vascular risk.

## 6. Conclusion

Vascular access is vital for end-stage renal disease patients on hemodialysis. Many solutions are available, but careful decision making is crucial. A good vascular access could be defined as one avoiding serious complications and multiple surgical and radiological interventions. There is always a risk of complications, but with an adequate physical examination, appropriate imaging and multidisciplinary management involving the nephrologist, the interventional radiologist and the vascular surgeon, an optimal solution can be found to prolong the life of an existing access or fashion an ingenious new access, even for the most desperate "last chance" cases. A few cases observed in our center illustrate this need for a multidisciplinary approach to patient management, focusing not only on vascular access itself, but also its complications and their prevention.

It is clear that before opting for a central catheter, an arteriovenous fistula should be attempted whenever feasible, even for the most difficult cases. The optimal moment to create the arteriovenous fistula remains a difficult decision which can be made only after global assessment of all potential candidates, i.e. not only patients scheduled for prolonged hemodialysis but also those followed for kidney failure, keeping in mind the major objective of preserving the vascular network.

At the present time, the most innovating development remains the arteriovenous fistula conceived by Brescia in 1966. There has been no change in this gold standard, but there has been in our patients who have become older and frailer, a real challenge for multidisciplinary teams.

## Author details

Joëlle Cridlig, Michèle Kessler and Thanh Cao-Huu

University of Nancy, France

## References

- [1] Thomas GI. A large-vessel applique A-V shunt for hemodialysis. *Trans Am Soc Artif Intern Organs*. 1969;15:288-92.
- [2] Brescia MJ, Cimino JE, Appel K, Hurwicz BJ. Chronic hemodialysis using venipuncture and a surgically created arteriovenous fistula. *N Engl J Med*. 1966 Nov 17;275(20):1089-92.
- [3] Vascular Access Work Group. Clinical practice guidelines for vascular access. *Am J Kidney Dis*. 2006 Jul;48Suppl 1:S176-273.
- [4] Pisoni RL, Young EW, Dykstra DM, Greenwood RN, Hecking E, Gillespie B, Wolfe RA, Goodkin DA, Held PJ. Vascular access use in Europe and the United States: results from the DOPPS. *Kidney Int*. 2002 Jan;61(1):305-16.
- [5] Blosser CD, Ayehu G, Wu S, Lomagro RM, Malone E, Brunelli SM, Itkin M, Golden M, McCombs P, Lipschutz JH. High rate of fistula placement in a cohort of dialysis patients in a single payer system. *Hemodial Int*. 2010 Oct;14(4):393-7
- [6] Allon M, Daugirdas J, Depner TA, Greene T, Ornt D, Schwab SJ. Effect of change in vascular access on patient mortality in hemodialysis patients. *Am J Kidney Dis*. 2006 Mar;47(3):469-77.
- [7] Pastan S, Soucie JM, McClellan WM. Vascular access and increased risk of death among hemodialysis patients. *Kidney Int*. 2002 Aug;62(2):620-6.
- [8] Xue JL, Dahl D, Ebben JP, Collins AJ. The association of initial hemodialysis access type with mortality outcomes in elderly Medicare ESRD patients. *Am J Kidney Dis*. 2003 Nov;42(5):1013-9.
- [9] Oliver MJ, Rothwell DM, Fung K, Hux JE, Lok CE. Late creation of vascular access for hemodialysis and increased risk of sepsis. *J Am Soc Nephrol*. 2004 Jul;15(7):1936-42.
- [10] Astor BC, Eustace JA, Powe NR, Klag MJ, Fink NE, Coresh J. Type of vascular access and survival among incident hemodialysis patients: the Choices for Healthy Outcomes in Caring for ESRD (CHOICE) Study. *J Am Soc Nephrol*. 2005 May;16(5):1449-55
- [11] Rehman R, Schmidt RJ, Moss AH. Ethical and legal obligation to avoid long-term tunneled catheter access. *Clin J Am Soc Nephrol*. 2009 Feb;4(2):456-60
- [12] Wasse H, Kutner N, Zhang R, Huang Y. Association of initial hemodialysis vascular access with patient-reported health status and quality of life. *Clin J Am Soc Nephrol*. 2007 Jul;2(4):708-14
- [13] DeSilva RN, Sandhu GS, Garg J, Goldfarb-Rumyantzev AS. Association between initial type of hemodialysis access used in the elderly and mortality. *Hemodial Int*. 2012 Apr;16(2):233-41

- [14] Lacson E Jr, Wang W, Lazarus JM, Hakim RM. Change in vascular access and hospitalization risk in long-term hemodialysis patients. *Clin J Am SocNephrol*. 2010 Nov; 5(11):1996-2003
- [15] Lacson E Jr, Wang W, Lazarus JM, Hakim RM. Change in vascular access and mortality in maintenance hemodialysis patients. *Am J Kidney Dis*. 2009 Nov;54(5):912-21
- [16] Quarello F, Forneris G, Borca M, Pozzato M. Do central venous catheters have advantages over arteriovenous fistulas or grafts? *J Nephrol*. 2006 May-Jun;19(3):265-79.
- [17] Martínez-Gallardo R, Ferreira-Morong F, García-Pino G, Cerezo-Arias I, Hernández-Gallego R, Caravaca F. Congestive heart failure in patients with advanced chronic kidney disease: association with pre-emptive vascular access placement. *Nefrologia*. 2012;32(2):206-12
- [18] Canaud B, Chenine L, Formet C, Leray-Moragués H. Accès veineux pour hémodialyse: technique, indications, résultats et développement futur. *Actualités néphrologiques Jean Hamburger*, 2005;251-272
- [19] Rabindranath KS, Kumar E, Shail R, Vaux E. Use of real-time ultrasound guidance for the placement of hemodialysis catheters: a systematic review and meta-analysis of randomized controlled trials. *Am J Kidney Dis*. 2011 Dec;58(6):964-70.
- [20] Allon M. Dialysis catheter-related bacteremia: treatment and prophylaxis. *Am J Kidney Dis*. 2004 Nov;44(5):779-91.
- [21] Allon M. Current management of vascular access. *Clin J Am SocNephrol*. 2007 Jul; 2(4):786-800
- [22] Bhutta ST, Culp WC. Evaluation and management of central venous access complications. *Tech VascIntervRadiol*. 2011 Dec;14(4):217-24.
- [23] Fiaccadori E, Gonzi G, Zambrelli P, Tortorella G. Cardiac arrhythmias during central venous catheter procedures in acute renal failure: a prospective study. *J Am SocNephrol*. 1996 Jul;7(7):1079-84.
- [24] Bessereau J, Genotelle N, Chabbaut C, Huon A, Tabah A, Aboab J, Chevret S, Annane D. Long-term outcome of iatrogenic gas embolism. *Intensive Care Med*. 2010 Jul;36(7):1180-7
- [25] Vats HS. Complications of catheters: tunneled and nontunneled. *Adv Chronic Kidney Dis*. 2012 May;19(3):188-94.
- [26] Schwab SJ, Beathard G. The hemodialysis catheter conundrum: hate living with them, but can't live without them. *Kidney Int*. 1999 Jul;56(1):1-17.
- [27] Macrae JM, Dojcinovic I, Djurdjev O, Jung B, Shalansky S, Levin A, Kiaii M. Citrate 4% versus heparin and the reduction of thrombosis study (CHARTS). *Clin J Am SocNephrol*. 2008 Mar;3(2):369-74.

- [28] Hoen B, Paul-Dauphin A, Hestin D, Kessler M. EPIBACDIAL: a multicenter prospective study of risk factors for bacteremia in chronic hemodialysis patients. *J Am Soc Nephrol*. 1998 May;9(5):869-76.
- [29] Maya ID. Antibiotic lock for treatment of tunneled hemodialysis catheter bacteremia. *Semin Dial*. 2008 Nov-Dec;21(6):539-41
- [30] Yevzlin AS. Hemodialysis catheter-associated central venous stenosis. *Semin Dial*. 2008 Nov-Dec;21(6):522-7.
- [31] Astor BC, Eustace JA, Powe NR, Klag MJ, Sadler JH, Fink NE, Coresh J. Timing of nephrologist referral and arteriovenous access use: the CHOICE Study. *Am J Kidney Dis*. 2001 Sep;38(3):494-501.
- [32] Akoh JA. Prosthetic arteriovenous grafts for hemodialysis. *J Vasc Access*. 2009 Jul-Sep;10(3):137-47.
- [33] Gibson KD, Caps MT, Kohler TR, Hatsukami TS, Gillen DL, Aldassy M, Sherrard DJ, Stehman-Breen CO. Assessment of a policy to reduce placement of prosthetic hemodialysis access. *Kidney Int*. 2001 Jun;59(6):2335-45.
- [34] Kim DS, Kim SW, Kim JC, Cho JH, Kong JH, Park CR. Clinical analysis of hemodialysis vascular access: comparison of autogenous arteriovenous fistula & arteriovenous prosthetic graft. *Korean J Thorac Cardiovasc Surg*. 2011 Feb;44(1):25-31
- [35] Schild AF. Maintaining vascular access: the management of hemodialysis arteriovenous grafts. *J Vasc Access*. 2010 Apr-Jun;11(2):92-9.
- [36] James MT, Manns BJ, Hemmelgarn BR, Ravani P. What's next after fistula first: is an arteriovenous graft or central venous catheter preferable when an arteriovenous fistula is not possible? *Semin Dial*. 2009 Sep-Oct;22(5):539-44
- [37] Tordoir J, Canaud B, Haage P, Konner K, Basci A, Fouque D, Kooman J, Martin-Malo A, Pedrini L, Pizzarelli F, Tattersall J, Vennegoor M, Wanner C, ter Wee P, Vanholder R. EBPG on Vascular Access. *Nephrol Dial Transplant*. 2007 May;22Suppl 2:ii88-117.
- [38] III. NKF-K/DOQI Clinical Practice Guidelines for Vascular Access: update 2000. *Am J Kidney Dis*. 2001 Jan;37(1Suppl1):S137-81.
- [39] Abularrage CJ, Sidawy AN, Weiswasser JM, White PW, Arora S. Medical factors affecting patency of arteriovenous access. *Semin Vasc Surg*. 2004 Mar;17(1):25-31.
- [40] Malovrh M. Native arteriovenous fistula: preoperative evaluation. *Am J Kidney Dis*. 2002 Jun;39(6):1218-25.
- [41] Owens CD, Wake N, Kim JM, Hentschel D, Conte MS, Schanzer A. Endothelial function predicts positive arterial-venous fistula remodeling in subjects with stage IV and V chronic kidney disease. *J Vasc Access*. 2010 Oct-Dec;11(4):329-34.



- [42] Chan CY, Chen YS, Ma MC, Chen CF. Remodeling of experimental arteriovenous fistula with increased matrix metalloproteinase expression in rats. *J Vasc Surg.* 2007 Apr;45(4):804-11.
- [43] Weiswasser JM, Kellicut D, Arora S, Sidawy AN. Strategies of arteriovenous dialysis access. *Semin Vasc Surg.* 2004 Mar;17(1):10-18
- [44] Xi W, MacNab J, Lok CE, Lee TC, Maya ID, Mokrzycki MH, Moist LM. Who should be referred for a fistula? A survey of nephrologists. *Nephrol Dial Transplant.* 2010 Aug;25(8):2644-51
- [45] Kumbar L. Complications of arteriovenous fistulae: beyond venous stenosis. *Adv Chronic Kidney Dis.* 2012 May;19(3):195-201.
- [46] Shurraw S, Zimmerman D. Vascular access complications in daily dialysis: a systematic review of the literature. *Minerva UrolNefrol.* 2005 Sep;57(3):151-63.
- [47] Huijbregts HJ, Blankestijn PJ. Dialysis access--guidelines for current practice. *Eur J VascEndovasc Surg.* 2006 Mar;31(3):284-7.
- [48] Wish JB. Vascular access for dialysis in the United States: progress, hurdles, controversies, and the future. *Semin Dial.* 2010 Nov-Dec;23(6):614-8
- [49] Murray MA, Thomas A, Wald R, Marticorena R, Donnelly S, Jeffs L. Exploring the impact of a decision support intervention on vascular access decisions in chronic hemodialysis patients: study protocol. *BMC Nephrol.* 2011 Feb 3;12:7.
- [50] Verhallen AM, Kooistra MP, van Jaarsveld BC. Cannulating in haemodialysis: rope-ladder or buttonhole technique? *Nephrol Dial Transplant.* 2007 Sep;22(9):2601-4
- [51] van Loon MM, Goovaerts T, Kessels AG, van der Sande FM, Tordoir JH. Buttonhole needling of haemodialysisarteriovenous fistulae results in less complications and interventions compared to the rope-ladder technique. *Nephrol Dial Transplant.* 2010 Jan;25(1):225-30
- [52] 52. Kharboutly Z, Fenech M, Treutenaere JM, Claude I, Legallais C. Investigations into the relationship between hemodynamics and vascular alterations in an established arteriovenous fistula. *Med Eng Phys.* 2007 Nov;29(9):999-1007
- [53] Mermel LA, Allon M, Bouza E, Craven DE, Flynn P, O'Grady NP, Raad II, Rijnders BJ, Sherertz RJ, Warren DK. Clinical practice guidelines for the diagnosis and management of intravascular catheter-related infection: 2009 Update by the Infectious Diseases Society of America. *Clin Infect Dis.* 2009 Jul 1;49(1):1-45.
- [54] Gray RJ, Levitin A, Buck D, Brown LC, Sparling YH, Jablonski KA, Fessahaye A, Gupta AK. Percutaneous fibrin sheath stripping versus transcatheterurokinase infusion for malfunctioning well-positioned tunneled central venous dialysis catheters: a prospective, randomized trial. *J VascIntervRadiol.* 2000 Oct;11(9):1121-9.
- [55] Dixon BS, Beck GJ, Dember LM, Vazquez MA, Greenberg A, Delmez JA, Allon M, Himmelfarb J, Hu B, Greene T, Radeva MK, Davidson IJ, Ikizler TA, Braden GL,



- Lawson JH, Cotton JR Jr, Kusek JW, Feldman HI. *J Am SocNephrol*. 2011 Apr;22(4):773-81
- [56] Janned'Othée B, Tham JC, Sheiman RG. Restoration of patency in failing tunneled hemodialysis catheters: a comparison of catheter exchange, exchange and balloon disruption of the fibrin sheath, and femoral stripping. *J VascIntervRadiol*. 2006 Jun;17(6):1011-5.
- [57] Oliver MJ, Mendelssohn DC, Quinn RR, Richardson EP, Rajan DK, Pugash RA, Hiller JA, Kiss AJ, Lok CE. Catheter patency and function after catheter sheath disruption: a pilot study. *Clin J Am SocNephrol*. 2007 Nov;2(6):1201-6
- [58] Maya ID, Saddekni S, Allon M. Treatment of refractory central vein stenosis in hemodialysis patients with stents. *Semin Dial*. 2007 Jan-Feb;20(1):78-82.
- [59] Cao-Huu T. Les sténoses des veines centrales: revue de littérature de 1980 à 2000. *Néphrologie*. 2001;22(8):479-485
- [60] Lee T, Ullah A, Allon M, Succop P, El-Khatib M, Munda R, Roy-Chaudhury P. Decreased cumulative access survival in arteriovenous fistulas requiring interventions to promote maturation. *Clin J Am SocNephrol*. 2011 Mar;6(3):575-81
- [61] Cao-Huu T, Cridlig J, Boccaccini H, Mathias J, Dekeyser M, Bachelet C, Frimat L. Sténoses multiples des veines centrales (SMVC): à propos des 24 observations de cathéters d'hémodialyse exclusivement posés par voie jugulaire (KTJ). Oral communication. Société de Néphrologie et Société Francophone de Dialyse, Bruxelles 2010
- [62] Cridlig J, Dekeyser M, Peters N, Duchesne L, Lam Cham Kee H, Frimat L, Cao Huu T. Deadlock in hemodialysis angioaccess (DHDAA): reflections about 15 observations. *The Journal of Vascular Access*. 2010;11 (S3):13-41
- [63] Tessitore N, Bedogna V, Melilli E, Millardi D, Mansueto G, Lipari G, Mantovani W, Baggio E, Poli A, Lupo A. In search of an optimal bedside screening program for arteriovenous fistula stenosis. *Clin J Am SocNephrol*. 2011 Apr;6(4):819-26
- [64] Tessitore N, Bedogna V, Poli A, Mantovani W, Lipari G, Baggio E, Mansueto G, Lupo A. Adding access blood flow surveillance to clinical monitoring reduces thrombosis rates and costs, and improves fistula patency in the short term: a controlled cohort study. *Nephrol Dial Transplant*. 2008 Nov;23(11):3578-84
- [65] Dember LM, Holmberg EF, Kaufman JS. Randomized controlled trial of prophylactic repair of hemodialysis arteriovenous graft stenosis. *Kidney Int*. 2004 Jul;66(1):390-8.
- [66] Webb KM, Cull DL, Carsten CG 3rd, Johnson BL, Taylor SM. Outcome of the use of stent grafts to salvage failed arteriovenous accesses. *Ann Vasc Surg*. 2010 Jan;24(1):34-8

- [67] Sreenarasimhaiah VP, Margassery SK, Martin KJ, Bander SJ. Salvage of thrombosed dialysis access grafts with venous anastomosis stents. *Kidney Int.* 2005 Feb;67(2):678-84.
- [68] Bittl JA. Catheter interventions for hemodialysis fistulas and grafts. *JACC CardiovascInterv.* 2010 Jan;3(1):1-11.

IntechOpen

IntechOpen

