

We are IntechOpen, the world's leading publisher of Open Access books Built by scientists, for scientists

4,800

Open access books available

122,000

International authors and editors

135M

Downloads

Our authors are among the

154

Countries delivered to

TOP 1%

most cited scientists

12.2%

Contributors from top 500 universities



WEB OF SCIENCE™

Selection of our books indexed in the Book Citation Index
in Web of Science™ Core Collection (BKCI)

Interested in publishing with us?
Contact book.department@intechopen.com

Numbers displayed above are based on latest data collected.

For more information visit www.intechopen.com



History, Classification and Pathophysiology of Small Vessel Vasculitis

Mohamed Abdgawad

Additional information is available at the end of the chapter

<http://dx.doi.org/10.5772/55238>

1. Introduction

Systemic vasculitides are a heterogenous group of disorders characterized by destructive inflammation and fibrinoid necrosis of the blood vessel wall, blood vessel occlusion and ischemia of surrounding tissue. Typical clinical manifestations vary depending on the size of the affected blood vessels, and include fever, weight loss, malaise, arthralgias and arthritis. Vasculitides can be idiopathic, primary, secondary to another disease such as Systemic Lupus Erythematosus (SLE) and Rheumatoid Arthritis (RA), or associated with infections, such as infective endocarditis, pharmaceutical drug use, such as propylthiouracil and hydralazine, or other chemical exposures [1]. Vasculitis can be isolated to one organ or vessel and be relatively insignificant clinically or can present as a systemic life-threatening illness involving several organs and vessels [2].

ANCA-associated Systemic Vasculitis (AASV) is the most common primary systemic small-vessel vasculitis that occurs in adults. AASV is a small-vessel vasculitis affecting arterioles, venules, capillaries, and occasionally medium-sized arteries that commonly involves multiple organ systems. Although infrequent, the incidence of AASV is increasing. AASV is also called pauci-immune vasculitis, because no immunoglobulins or complement components are detected in the vasculitic lesions.

AASV is associated with significant morbidity and mortality, with almost all patients requiring aggressive immunosuppression. Without treatment, the mortality approaches 100% in 5 years [3]. Based upon the clinical presentation and the predominant organ involvement, AASV cases are classified as Wegener's granulomatosis (WG), microscopic polyangiitis (MPA), Churg-Strauss syndrome (CSS) and Renal Limited Vasculitis (RLV). ANCA are predominantly IgG

antibodies that were first described in the 1980s by Davies et al. in patients with necrotizing glomerulonephritis [4]. These antibodies are directed against antigenic components of neutrophilic granules or lysosomes. Indirect immunofluorescence (IIF) of ethanol-fixed neutrophils reveals cytoplasmic (cANCA) or perinuclear (pANCA) staining. cANCA staining correlates with proteinase-3 (PR3) reactivity, while pANCA staining correlates with reactivity towards myeloperoxidase (MPO) or other antigens.

PR3-ANCAs are mainly detected in patients with WG, whereas MPO-ANCAs are predominantly detected in patients with MPA and CSS. These diseases exhibit similar pathological focal necrotizing lesions, though WG and CSS also have granulomatous lesions [5].

Henoch-Schönlein purpura (HSP) is the most common systemic small-vessel vasculitis in children [6]. HSP is a systemic vasculitis affecting small vessels and capillaries. HSP is characterized by palpable purpura, edema, abdominal pain, joint pain and renal symptoms [7]. The prognosis is good as long as the patients have no renal symptoms. Renal symptoms vary from intermittent hematuria and proteinuria to rapidly progressive glomerulonephritis.

In this chapter, we shall discuss the pathophysiology of the most common primary small vessel vasculitis in adults, AASV, as well as the most common small vessel vasculitis in children, HSP.

2. History

Purpura was the first manifestation of vasculitis in vessels smaller than arteries. In 1808, Willan clearly distinguished purpura caused by infections from non-infectious purpura [8]. Over the next century, Henoch and his teacher, Schönlein, described a broad spectrum of signs and symptoms that were associated with purpura, and with small vessel vasculitis, including arthritis, peripheral neuropathy, abdominal pain, pulmonary hemorrhage, epistaxis, iritis, and nephritis [9].

In 1866, Kussmaul and Maier described a patient with general weakness caused by vasculitic neuropathy accompanied by tachycardia, abdominal pain, and the appearance of cutaneous nodules over the trunk. The patient's muscle paralysis progressed quickly causing death. At autopsy, visible nodules were present along the medium-sized arteries of the patient [10]. Kussmaul and Maier named this disease "periarteritis nodosa" because they observed inflammation in the perivascular sheaths and outer layers of the arterial walls and nodular thickening of the vessels. However, the name was later changed to "polyarteritis nodosa" because of the widespread involvement of vessels and the fact that it affects the entire thickness of the vessel wall [1].

A disorder of necrotizing vasculitis, granulomatous lesions of the entire respiratory tract, and glomerulonephritis was first described in 1897 by Peter McBride [11]. In 1931, Heinz Klinger described the pathological anatomical picture of this disease in two patients who died of

systemic vasculitis [12]. In 1936, Friedrich Wegener, a German pathologist, described three patients with necrotizing granuloma and later interpreted the pathological and clinical findings to represent a distinctive disease entity in 1939 [13]. Goodman and Churg in 1954 wrote a detailed description of the disease known as “Wegener’s granulomatosis” (WG) presenting definite criteria: necrotizing granulomata of the respiratory tract, generalized vasculitis and necrotizing glomerulonephritis [14]. DeRemee and colleagues in 1976 proposed the ELK classification (E= upper respiratory tract including paranasal sinuses; L= lung; K= kidney), allowing them to understand and manage cases that did not fit the strict criteria of Goodman and Churg [15]. In the early 1970s, Fauci and Wolff introduced treatment with cyclophosphamide and corticosteroids for WG, which resulted in a nearly complete and long-lasting remission of the disease [16]. In addition, DeRemee published in 1985 a report on the benefits of using cotrimoxazole (trimethoprim/ sulfamethoxazole) in WG with local disease [17]. In the same year, a major breakthrough was made by Van der Woude et al who reported autoantibodies sensitive and specific for the disease. These autoantibodies reacted with the cytoplasm of ethanol-fixed neutrophils, and monocytes and were called Anti-neutrophil Cytoplasmic Autoantibodies (ANCA) [18].

3. Classification

There are 20 recognized primary forms of vasculitis, which are classified according to the size of the affected blood vessels. The large vessel vasculitides, giant cell (temporal) arteritis and Takayasu arteritis, are caused by a granulomatous inflammation of the aorta and its major branches. In the case of giant cell arteritis, there is a particular predilection for the extracranial branches of the carotid artery, often with involvement of the temporal artery and frequent association with polymyalgia rheumatica. The age of the patient is helpful in distinguishing between the two conditions, because giant cell arteritis is rare in patients under the age of 50 and Takayasu’s disease is more common in younger patients [19].

Classical polyarteritis nodosa affects medium-sized vessels and therefore should not involve glomerulonephritis or vasculitis in arterioles, capillaries or venules. Kawasaki’s disease is a medium-sized vessel vasculitis that frequently involves the coronary arteries, is associated with the mucocutaneous lymph node syndrome and is most common in children [2].

Small vessel vasculitides include the immune-complex associated vasculitis of Henoch-Schoenlein purpura and essential cryoglobulinemic vasculitis. Henoch-Schönlein purpura has predominantly IgA immune complex deposition and involves the skin, gut and glomeruli with arthritis and arthralgia, while essential cryoglobulinemic vasculitis is caused by the deposition of cryoglobulins predominantly in the small vessels of the skin and glomeruli and is frequently associated with Hepatitis C infection. Another small vessel vasculitis category is cutaneous leucocytoclastic vasculitis, which is confined only to the skin, has no systemic involvement and has a better prognosis than vasculitides with systemic involvement [2].

Examples of different types of vasculitis are depicted in Table 1.

Dominant vessel involved	Primary	Secondary	
Large arteries	Giant cell arteritis	Aortitis associated with RA	
	Takayasu's arteritis	Infection (eg. Syphilis)	
Medium arteries	Classical PAN	Infection (eg. Hepatitis B)	
	Kawasaki disease		
Small vessels and medium arteries	Wegener's granulomatosis*	Vasculitis 2 to RA, SLE, Sjögren's syndrome	
	Churg-Strauss syndrome*		Drugs
	Microscopic polyangiitis*		Infection (e.g. HIV)
Small vessels (leukocytoclastic)	Henoch-Schönlein purpura	Drugs**	
	Essential mixed cryoglobulinaemia		Infection (e.g. Hepatitis B, C)
	Cutaneous leukocytoclastic vasculitis		

(*) Diseases most commonly associated with ANCA, pauci-immune crescentic glomerulonephritis and which are most responsive to immunosuppression with cyclophosphamide. (**) e.g. sulphonamides, penicillins, thiazide diuretics, and many others. PAN= Polyarteritis Nodosa. RA= Rheumatoid Arthritis. SLE= Systemic Lupus Erythematosus.

Table 1. Classification of systemic vasculitis.

ANCA-associated systemic vasculitis (AASV) are a group of diseases classified as small vessel vasculitides that are associated with anti-neutrophil cytoplasmic antibodies. AASV include microscopic polyangiitis, Wegener's granulomatosis, Churg-Struass syndrome and renal limited vasculitis. Together they are responsible for 5-6% of cases presenting with renal failure. They are characterized histologically by necrotizing vasculitis preferentially affecting small blood vessels and often associated with pauci-immune necrotizing crescentic glomerulonephritis. Serologically, these diseases present autoantibodies directed against constituents of neutrophil granules [20].

In 1990, three independent groups showed that azurophilic granule enzyme proteinase 3 was the target autoantigen recognized by ANCA (PR3-ANCA) [21,22,23]. Together with proteinase 3, another granule protein, myeloperoxidase (MPO) was also identified as a target autoantigen of ANCA (MPO-ANCA) [24]. The discovery of ANCA has been critical to understanding the pathogenesis of the disease, as well as providing a valuable diagnostic tool. The American College of Rheumatology published criteria for classifying vasculitides in 1990, leading to improved categorization of patients for clinical trials [25]. However, these criteria were not adequate for diagnosing patients with ANCA-associated vasculitides. An individual patient could simultaneously meet the criteria for WG, Churg Strauss Syndrome (CSS), Polyarteritis Nodosa (PAN), hypersensitivity vasculitis and Henoch-Schönlein pupura. In 1994 the Chapel Hill Consensus conference (CHCC) adopted standardized names and definitions of vasculitides, based on the size of the affected blood vessels [26].

Recently a group of physicians from multiple medical disciplines met at the European Medicines Agency (EMA) in London in September 2004 and January 2006 and developed a stepwise algorithm for classifying AASV and PAN for epidemiological studies. Their aim was to develop a consensus approach for applying CHCC definitions and ACR criteria to AASV and PAN, in order to facilitate comparison between epidemiological data for different vasculitides [27].

Without treatment, patients with AASV have a very poor prognosis with a median survival time of 5 months [28]. Current treatment regimens based on cyclophosphamide and corticosteroids have dramatically improved the prognosis for these patients and increased the median survival time to 21.7 years [29]. Although this regimen achieves long-lasting remission and prolonged survival of patients with AASV, it has its drawbacks; the worst being life-threatening infections early in the course of the disease and risk of malignancy in late stages of the disease [30,31]. Furthermore, the disease has a high relapse rate in spite of heavy immunosuppression. Improved understanding of the mechanisms underlying AASV may help in the search for better treatment modalities for this serious and devastating illness.

4. Pathophysiology of ANCA-Associated Systemic Vasculitis (AASV)

The pathophysiology of AASV remains largely unknown. Clinical and laboratory evidence suggest a multifactorial origin. Although the association between ANCA and pauci-immune small vessel vasculitides has been established, the exact role of ANCA in the pathogenesis of AASV is yet not fully elucidated. It is not known whether ANCA play a direct role in disease manifestations, or whether the antibodies are secondary markers of the disease process. Available data suggest that neutrophils, B- and T- lymphocytes play a key role in the pathophysiology of AASV.

4.1. Pathogenic B-cell response and production of ANCA

B-cells are the direct precursors of antibody producing plasma cells. B-cells also produce auto-antibodies and cytokines (Interleukin IL-6, Tumor Necrosis Factor alpha-TNF α , IL-10), act as antigen presenting cells, and differentiate into long lasting memory B-cells. Csernak et al. have shown that in WG patients, ANCA are produced following B-cell activation [32]. A polyclonal B-cell lymphoid infiltrate in the endonasal granulomatous lesion included PR3-ANCA-producing cells with copy number increase in three VH genes. The granulomatous lesions in WG consist of clusters of PR3 surrounded by an infiltrate consisting of maturing B-cells, antigen-presenting cells (APCs) and Th1-type CD4+CD28⁻ T cells. This suggests that endonasal B-cell maturation is antigen-driven, and that B-cells generate ANCA via contact with PR3 or an antigenic microbial epitope [33].

B-cells recognize soluble antigens via specific B-cell receptors (BCR) and co-receptor CD19 that augments BCR downstream signaling. CD19 dysregulation has been reported in patients with AASV. Culton et al. showed that CD19 expression is 20% lower in naive B-cells from patients with AASV than from normal controls [34]. In contrast, the memory B-cells from some patients with AASV express more CD19 than normal controls. This subset of B-cells shows evidence of antigenic selection, suggesting that in AASV, mechanisms of self-tolerance may be lost leading to production of auto-reactive B-cells [34]. Experiments in transgenic mice indicate that defective B-cell regulation, specifically in pathways responsible for deletion (central and peripheral) of auto-reactive B-cells, may also play a role in generating autoantibodies in AASV [35]. Interestingly, expression of B-cell activating factor of the TNF family (BAFF) is increased

in patients with WG [36]. It is postulated that BAFF may drive B-cell expansion, which then leads to ANCA production. B-cell depletion via rituximab in patients with AASV decreases ANCA levels and induces disease remission [37,38]. Conversely, clinical relapse correlates with increase levels of B cells [39]. These data support the conclusion that B cells play a central role in ANCA production and that ANCA play a significant role in the pathogenesis of AASV.

4.2. Pathogenic T-response, tissue damage, and granuloma formation

Under normal conditions, naïve T-cells are activated during an immune response to an antigen stimulus. Antigen-specific T-cells then differentiate into memory T-cells, while effector-T cells undergo apoptosis. Paucity of immunoglobulins in the vasculitic lesions, predominance of IgG1 and IgG4 subclasses of IgG, and the presence of granulomatous lesions indicate that T-cell-mediated immune responses play a role in the pathogenesis of AASV [40]. This is consistent with the fact that T cell-based treatment strategies produce clinically-relevant remission in AASV patients [41,42].

In patients with active WG, higher proportion of activated T-cells and higher concentration of soluble T cell activation markers (including soluble IL-2 receptor or CD30) are reported to correlate with disease activity [43]. High levels of activation markers also correlate with ANCA-positivity, which suggests persistent T cell activation, likely secondary to a persistent antigenic trigger, as an underlying pathogenic factor. This is consistent with reports of persistent expansion of CD4+ effector memory T-cells (Tem) combined with a decrease in naïve T-cells in patients with AASV [44,45]. A polarization of Th1 and Th2 response has also been reported in AASV. In particular, a Th2-type response is predominant in patients with active generalized WG or CSS, while a Th1 response is dominant in patients with localized WG or MPA, indicating that aberrant T cell response plays a role in the disease process [46,47]. CCR5 is also expressed on T-cells in early, localized WG, which might also favor recruitment of Th1-type cytokine secreting cells into inflammatory lesions in localized WG [48]. Conversion from Th1 to Th2 type response could underlie progression from localized to generalized WG. This shift could reflect B-cell expansion and T-cell-dependent PR3-ANCA production, secondary to interaction between neutrophils and auto-reactive T- and B-cells in inflammatory lesions, Figure 1.

The granulomas in AASV resemble a germinal centre, with a cluster of primed neutrophils surrounded by dendritic cells, T- and B-cells. CD4+ T cells are likely to play an important role in the granulomatous response in AASV. The decrease in CD4+CD28-- Tem subset of T-cells during active disease, in patients with WG, indicates an increased migration of these cells to sites of inflammation [44]. In an experimental model of autoimmune, anti-MPO-associated glomerulonephritis, it was noted that mice depleted of CD4+ T cells, at the time of administration of anti-mouse anti-GBM antibodies, developed significantly less crescent formation and cell response, compared to controls [49]. In patients with ANCA-associated glomerulonephritis, Tem cells are the predominant T-cell subtype in the glomerular infiltrate [50]. Together, these observations suggest that a cell mediated immune response contributes to the pathogenesis of renal lesions. Indeed, CD4+ Tem cells from WG patients lack NKG2A (inhibitory receptor) and demonstrate increased expression of NKG2D, which is a

member of the killer immunoglobulin-like receptor family [51]. A significant increase in the proportion of IL-17 producing CD4+ T cells (Th17 cells) in in vitro stimulated peripheral blood cells from WG patients has also been reported [52]. IL-17 induces secretion of neutrophil-attracting chemokines, and release of pro-inflammatory cytokines (IL-1 β , TNF- α) capable of increasing expression of PR3 on the surface of neutrophils. Patients with ANCA-positive WG are reported to have more PR3-specific Th17 cells than ANCA-negative WG patients and healthy controls [52]. It is, therefore, likely that a Th1 response plays an important role in antibody production and granuloma formation in AASV.

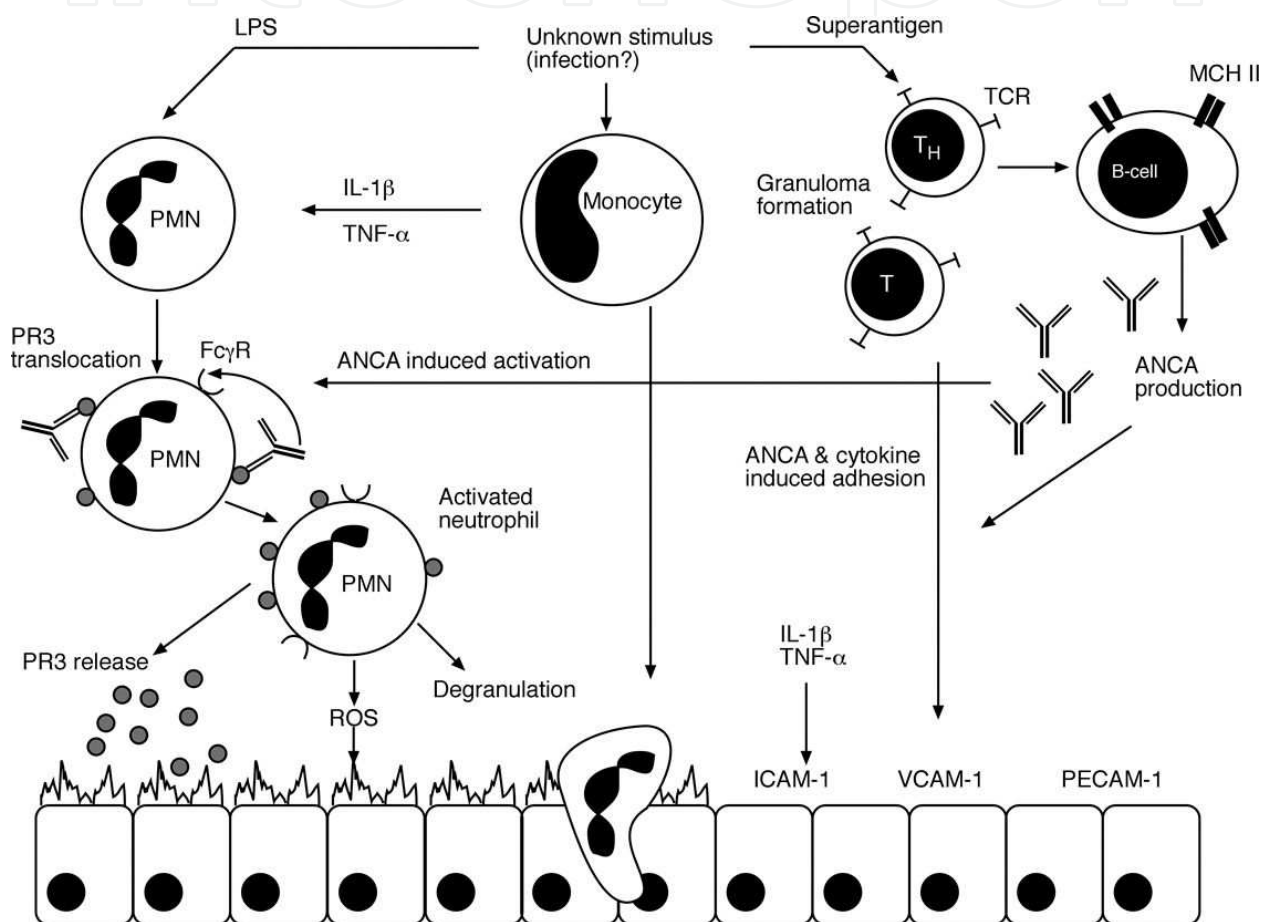


Figure 1. Pathophysiology of AASV. The stimulation of neutrophils by TNF- α or IL-1 β (priming), e.g. during a preceding infection, leads to the translocation of the ANCA-antigens, PR3 and MPO, from the cytoplasmic granules (specific granules and secretory vesicles) to the cell surface, where they are accessible for ANCA, which leads to a further activation of the cell. ANCA-induced neutrophil activation initiates production of ROS, neutrophil degranulation with release of inflammatory cytokines and granule contents (e.g., PR3 and HLE) from azurophilic granules, leading to endothelial cell detachment and lysis. Furthermore, neutrophil activation leads to leukocyte adhesion (via ICAM-1, VCAM-1) and transmigration through endothelium (via PECAM-1), and release of ROS and proteases into tissues. Superantigen (e.g., Staphylococcal exotoxins) or PR3 presented to the T-cells directly or via dendritic cells, are capable of stimulating the proliferation of T-cells, leading to granuloma formation and finally to maturation of PR3-specific autoreactive B-cells, culminating in ANCA production. ROS= Reactive oxygen species. PR3= Proteinase 3, MPO= Myeloperoxidase, HLE= Human Leukocyte elastase, ICAM= Intercellular adhesion molecule-1, VCAM-1=Vascular cell adhesion molecule-1, PECAM-1= Platelet endothelial cell adhesion molecule-1, TCR= T-cell receptor, MHC-II= Major Histocompatibility complex-II, TNF- α =Tumor necrosis factor-alpha, IL-1 β =Interleukin-1 Beta.

4.3. Monocyte activation and production of pro-inflammatory cytokines

Wickman et al compared monocytes and cytokine profiles in patients with acute anti-PR3 vasculitis and normal controls; monocytes from patients were reported to have a reduced capacity to produce oxygen radicals [53]. Ohlsson et al., from our group, reported a positive correlation between circulating levels of IL-8 and monocyte IL-8 mRNA in patients with AASV, suggesting prolonged immune activation [54]. Pathological analysis of renal tissue from patients with AASV revealed the presence of monocytes in the glomerular crescents and granulomas [55]. In-vitro studies demonstrated that ANCA are capable of stimulating monocytes, leading to release of cytokines including IL-8, MCP-1, TNF-, IL-1, IL-6 and thromboxane A2 [56,57]. On the other hand, membrane PR3 expression on monocytes does not correlate with disease activity. There are many possible explanations for the presence of activated monocytes in glomerular crescents. For example, it is possible that monocytes are activated by direct physical interaction with components of glomerular lesions once they reach site of lesion; alternatively, dysfunctional apoptosis may stimulate monocyte activation [58].

4.4. Endothelial cell activation and enhanced expression of adhesion molecules

Endothelial damage, neutrophil invasion and necrosis are histopathological features of AASV [59]. Activated endothelial cells express high levels of adhesion molecules. Increased circulating levels of endothelial proteins (thrombomodulin, vWF), and adhesion molecules (soluble intercellular adhesion molecule (sICAM)-1 and the soluble endothelial cell-leukocyte adhesion molecule (sELAM)-1) have been reported in vasculitis [60]. Woywodt et al. reported the presence of significant number of circulating endothelial cells and necrotic endothelial cell fragments in patients of active AASV [61]. A significant proportion of the circulating endothelial cells (EC) stain positive for tissue factor (TF), which links proinflammatory mechanisms with thrombosis [61]. Interestingly, TF expression can be induced in ECs by the release of PR3 and elastase from neutrophils; this may be mediated via PR3 receptors on the endothelial cell surface [62]. Endothelial cell necrosis, and release of TF, may play a role in development of vasculitic lesions. The mechanism of endothelial cell necrosis is not yet fully elucidated. Although anti-endothelial cell antibodies have been detected in AASV, their significance in this regard is not clear [63]. ANCA antigens, PR3 and MPO, can bind to endothelial cells via endothelial cell receptors [64,65]. ANCA can bind to endothelial cell bound antigens, leading to EC activation. It is possible that ANCA-induced neutrophil activation induces release of cytotoxic enzymes that damage endothelial cells. In AASV patients with renal involvement, the levels of circulating angiotensin-2 (Ang-2) correlate with the increased number of circulating ECs. In-vitro studies suggest that the endothelial-specific angiotensin (Ang)-Tie ligand-receptor system regulates endothelial cell detachment. By analogy, Ang-2 might regulate endothelial cell detachment in AASV [66].

4.5. Environmental factors

Clinical and epidemiological evidence demonstrate that environmental factors, including silica, asbestos, drugs (anti-thyroid medications), and various infections (bacterial endocarditis, hepatitis C virus), correlate with circulating ANCA and development of AASV [67,68].

Beaudreuil et al showed that exposure to silica is associated with a nearly seven-fold increased risk of being ANCA-positive [69]. ANCA, both PR3 and MPO, are detected in sera of patients with protracted infections; however, in most infections, ANCA are directed against a wide repertoire of antigens and tend to be dual [70]. Stegeman et al. described an association between nasal *S. aureus* and relapses of PR3-AAV [71]. Chronic infections may prime neutrophils, which can be further activated by PR3-ANCA, leading to vasculitis. It is also possible that some exogenous non-self proteins (i.e., bacterial, viral, fungal) mimic auto-antigens, which generates ANCA and an ANCA response. For example, PR3-ANCA has been detected in sera of patients with bacterial endocarditis [72]. Long standing exposure of the immune system to specific antigens, may set the stage for development of ANCA and subsequent AASV. Many theories have been made in line of this thought, including anti-complementary PR3 antibody theory [73] and Anti-LAMP (Lysosomal associated membrane protein) antibody theory [74], which are out of the scope of this study.

4.6. Genetic predisposition

In general, autoimmune diseases display familial inheritance, suggesting that affected individuals carry genetic variation that contributes to disease susceptibility. Case reports show clusters of WG in siblings and close relatives, and specific HLA associations (DR1-DQw1) in AASV patients also suggest the existence of genetic susceptibility loci [75,76,77]. In patients with WG, neutrophils with positive expression of membrane-PR3 (mPR3⁺) are more abundant than in healthy controls, leading to a skewed bimodal distribution of mPR3 towards a high mPR3⁺ phenotype in WG [78]. This phenomenon may be genetically determined, because the proportion of mPR3⁺neutrophils is a stable phenotype in the same individual over prolonged periods of time, it also runs in families and is similar between twins [79]. Furthermore, patients with WG carry a polymorphism that disrupts a putative transcription factor binding site in the PR3 promoter region [80]. This polymorphism may lead to increased expression of PR3 and explain the high mPR3⁺ phenotype. Additional polymorphisms involving CTLA-4 (affecting T cell activation), alpha-1 antitrypsin level (protease inhibitor of PR3), and other genes/proteins have been reported in AASV patients [81,82,83,84].

5. Are ANCA pathogenic?

The subject of pathogenicity of ANCA is controversial. ANCA are absent in some patients with small vessel vasculitis, while MPO-ANCA are detected in patients with rheumatoid arthritis and other disorders [85]. Also, a paucity of immune complexes at sites of pathological lesions argues against a direct role for ANCA. However, animal models of small vessel vasculitis provide convincing evidence that ANCA are pathogenic in AASV. Xiao et al demonstrated that Rag2^{-/-} mice, which are completely deficient in T- and B-lymphocytes with antigen receptors, developed a severe necrotizing glomerulonephritis and small vessel vasculitis when they were injected with anti-MPO splenocytes, while mice that received anti-BSA or normal splenocytes remained disease-free. Similarly, Rag2^{-/-} and WT B6-mice injected with anti-MPO IgG developed focal glomerular necrosis and crescent formation, clearly indicating that the

antibodies were pathogenic [86]. Neumann et al demonstrated excessive immune deposits in the early stages of life of SCG/Kinjoh mice (that spontaneously develop small vessel vasculitis and p-ANCA), and suggested that immune complex deposition leads to an inflammatory state, which when amplified by ANCA, likely lead to severe vasculitis [87]. In renal biopsies from AASV patients with renal involvement, Bajema et al showed that PR3, MPO, elastase and lactoferrin localized within or around fibrinoid necrotic lesions, and the lesions contained high levels of PR3 and elastase, which were also enriched inside the lesions [88]. Schlieben et al described a case of pulmonary renal syndrome in a newborn who received MPO-ANCA via passive transfer from the mother, supporting the idea that ANCA are pathogenic [89]. Animal models have not been developed to test the pathogenicity of PR3-ANCA, because human and murine PR3 share a low level of homology. However, an animal model of vasculitis and severe segmental and necrotizing glomerulonephritis, similar to WG, was recently developed in non-obese diabetic-severe combined immune deficiency (NOD-SCID) mice. In this model, splenocytes were isolated from NOD mice immunized with recombinant mouse PR3 and transferred into NOD-SCID mice, who developed disease pathology. These findings suggest that PR3-ANCA may play a direct role in PR3-ANCA-associated renal disease; however, in this model, a specific genetic background and autoimmune predisposition for kidney pathology are prerequisites for disease manifestation [90].

5.1. Role of neutrophil apoptosis in AASV

Increased neutrophil apoptosis has been observed in AASV. Pathological specimens from patients of WG show clear presence of apoptotic and necrotic neutrophils [91,92]. Leucocytes, with degraded nuclear material, undergoing disintegration and apoptotic cells have been observed in tissue specimens from ANCA-positive renal vasculitis [93]. Histologically, AASV is characterized by leukocytoclasia, with infiltration and accumulation of unscavenged apoptotic and necrotic neutrophils in tissues around blood vessels, and fibrinoid necrosis of the blood vessel walls [94]. E/M studies of the leukocytoclastic lesions, in patients with leukocytoclastic vasculitis, have suggested that there may be a defect in the clearance of apoptotic neutrophils. The minority of neutrophils in this study showed typical apoptotic changes of the condensed and marginated nuclei, while the majority showed intact nuclei with disintegrated cytoplasmic organelles and plasma membranes [95]. Apoptotic neutrophils may, in fact, be a source of immunologically exposed neutrophil antigens that promote the production of ANCAs. It has been speculated that the development of ANCA-positive vasculitis is a three-step pathological process. The first step involves an exogenous stimulus that increases neutrophil and macrophage apoptosis. An example is exposure to an inhaled substance like silica, which is known to induce apoptosis in human peripheral blood lymphocytes and to also induce Fas-ligand expression in lung macrophages (in *vitro* and in *vivo*), promoting Fas-dependent macrophage apoptosis in a murine model of silicosis [96,97]. Similarly, other postulated etiological agents for AASV (propylthiouracil, *Streptococcus Pneumoniae*) have also been shown to induce/accelerate apoptosis [98,99]. There is also pathological evidence of leucocytes with degraded nuclear material undergoing disintegration in tissues and apoptotic cells have been observed in AASV. Therefore, it seems logical to suggest that defective clearance/increased exposure to apoptotic neutrophils may be the initiating factor for ANCA

production and development of AASV (step two). Finally, environmental and genetic factors can also contribute to disease expression [100].

There are also experimental data that support this developmental model. There is evidence that in an inflammatory environment, autoantigens (nuclear/cytosolic) are presented by the opsonized cells, likely resulting in autoantibody formation. Kettritz et al used high doses of TNF- α to prime neutrophils, and demonstrated that caspase 3 dependent early neutrophil apoptosis was accompanied by increased surface expression of PR3 and MPO. In addition, these early apoptotic neutrophils showed a down-regulation of respiratory burst in response to ANCA [101].

Interestingly, Patry et al showed that injection of syngenic apoptotic neutrophils, but not freshly isolated neutrophils, into Brown Norway rats resulted in development of P-ANCA, with the majority being specific for elastase, again indicating that apoptotic neutrophils may boost an autoimmune response [102]. In another study, intraperitoneal infusion of live or apoptotic human neutrophils (but not formaline fixed or lysed neutrophils) into C57BL/6J mice resulted in development of ANCA specific for lactoferrin or myeloperoxidase. A second intravenous infusion of apoptotic neutrophils resulted in the development of PR3-specific ANCA. Again no vasculitic lesions were found in those mice developing ANCA [103].

As already known from general molecular biology knowledge, neutrophils migrating to inflamed sites undergo spontaneous apoptosis leading to their clearance without damage to the surrounding tissue. Macrophages in the blood recognize, among other surface membrane signals, the externalized Phosphatidyl Serine (PS) on the apoptotic neutrophils leading to their safe clearance. However, neutrophils that are not cleared in this manner progress to secondary necrosis, a process that triggers the release of pro-inflammatory cytokines. It appears that ANCAs dysregulate the process of neutrophil apoptosis. In an *in vitro* study conducted by Harper et al., ANCAs accelerated apoptosis of TNF--primed neutrophils by a mechanism dependent on NADPH oxidase and the generation of ROS. This was accompanied by uncoupling of the nuclear and cytoplasmic changes from the surface membrane changes. That is, while apoptosis progressed more rapidly, there was no corresponding change in the rate of externalization of PS following activation of neutrophils by ANCAs. This dysregulation created a 'reduced window of opportunity' for phagocyte clearance by macrophages, leading to a more pro-inflammatory environment [104]. It must be noted here that ANCAs were unable to accelerate apoptosis in unprimed neutrophils. Additionally, although there was increased expression of PR3 and MPO as apoptosis progressed, ANCAs were unable to activate these neutrophils. In fact, there was a time-dependent decrease in ROS generation as these neutrophils aged [104]. ANCA accelerates neutrophil apoptosis, in primed neutrophils, via generation of ROS that act as amplifying factors for apoptosis. ROS are critical since neutrophils isolated from patients with chronic granulomatous disease (having a defect in ROS production) do not show accelerated apoptosis after ANCA activation [104]. The same authors, in a later study, as well as another independent group showed that ANCA binding to apoptotic neutrophils enhanced phagocytosis by human monocyte-derived macrophages, but at the same time they increased the secretion of pro-inflammatory cytokines like IL-1, IL-8 and TNF- α [105,106]. IL-1 and IL-8 are capable of retarding apoptosis and are powerful chemo-attractants. The pro-inflammatory neutrophil clearance will result in further cell recruitment and perpetuation of inflammation. The autoimmune response may be promoted by aberrant

phagocytosis of apoptotic neutrophils by dendritic cells. In a recent study it has been shown that anti-PR3 antibody can also penetrate into human neutrophils (*in vitro*) and lead to enhancement of the apoptotic process [107].

Understanding the pathogenesis of neutrophil apoptosis and clearance in AASV can help to rationalize existing therapies and indicate new approaches to therapy [108].

5.2. The role of netting Neutrophils (NETs)

A novel form of PMN death named “NETosis”, characterized by the active release of chromatin, has been described recently [109]. Neutrophil extracellular traps (NETs) are extrusions of plasma membrane and nuclear material, containing granule components and histones. These structures bind gram-positive and negative bacteria, as well as fungi. *In vitro*, NETs have been shown to bind and kill extracellular microorganisms; *in vivo*, they have been documented in conditions, including appendicitis, sepsis, pre-eclampsia and experimental models of shigellosis [110]. The changes leading to NET formation follow a specific pattern, which is initiated by the loss of nuclear segregation into eu- and heterochromatin. Once the chromatin and granular components are mixed, NETs are released from the cell after cytoplasmic membrane rupture by a process distinct from necrosis or apoptosis, termed NETosis. NADPH oxidase plays a role in this process, via generation of ROS, which act as signaling molecules. Fuchs et al demonstrated that NET formation is a part of active cell death, and that NETs are released when the activated neutrophils dies [111].

Kessenbrock et al. demonstrated that ANCA-stimulated neutrophils release NETs, which contain PR3 and MPO in addition to chromatin and LL37 (an antimicrobial peptide with capabilities of activating dendritic cells) [112]. *In-vivo* presence of NETs was shown in tissues (kidney biopsies from patients with small vessel vasculitis), with maximal concentration in areas showing neutrophilic infiltration, which suggests that NET formation occurs predominantly during active disease [112]. In patients of AASV, increased levels of circulating nucleosomes has been reported [113]. It is likely that these may, in fact, be derived from and reflect NET formation in AASV. In short, NETs may incite production of ANCA, via presentation of antigen-chromatin complexes to the immune system, or ANCA may incite production of NETs, which then could aggravate the immune response, leading to perpetuation of the auto-immune response, Figure 2.

5.3. Recent updates

Experiments performed by our group, have shown that the plasma levels of mature PR3 as well as pro-PR3 are elevated in AASV [114,115,116]. It was also observed that mPR3⁺ neutrophils are more abundant in AASV compared to healthy donors, which agrees with previous studies suggesting that a high percentage of mPR3⁺ cells may be a risk factor for vasculitis [78,115]. Circulating neutrophils and monocytes from patients with AASV display upregulated transcription of the PR3 gene [117]. It is likely that aberrant PR3/mPR3 expression may reflect, or be a marker of a specific functional defect in neutrophils. A possible origin of high plasma levels of PR3 is shedding of membrane PR3.

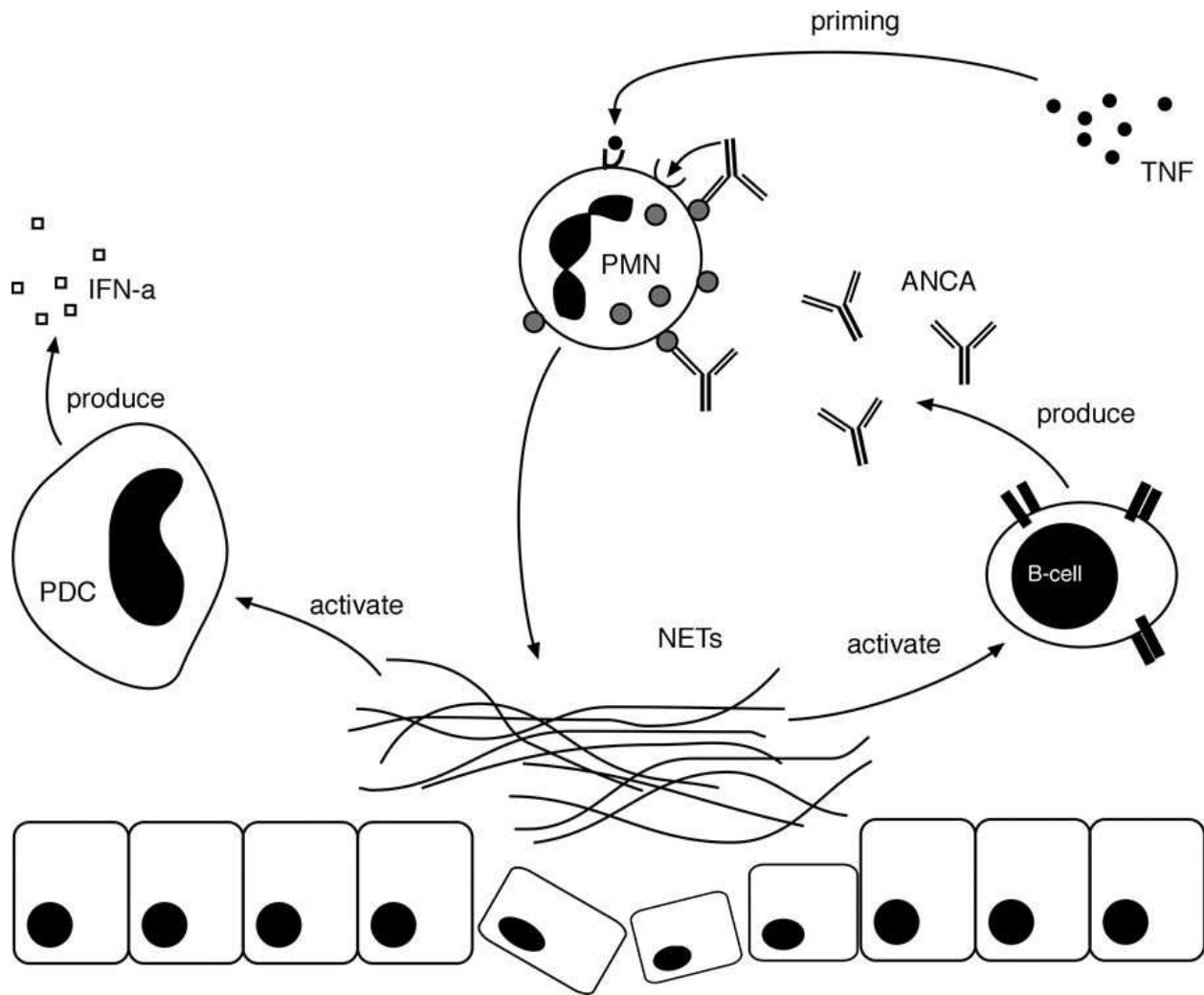


Figure 2. Pathophysiological model of neutrophil extracellular traps (NETs) in ANCA-associated vasculitis. ANCA can induce TNF- α -primed neutrophils to produce NETs. The deposition of NETs may activate plasmacytoid dendritic cells that produce large amounts of interferon- α driving the autoimmune response. In this context, NETs may activate autoreactive B cells to the production of ANCA, which results in a vicious circle of NET production that maintains the delivery of antigen–chromatin complexes to the immune system. Moreover, NETs may also stick to the endothelium and cause endothelial damage.

A significant recent finding is that mPR3 and CD177 are co-expressed on the same subset of circulating neutrophils in healthy subjects as well as in AASV patients [118,119]. Our group has demonstrated that the mPR3⁺/CD177⁺ neutrophil subpopulation was larger in AASV patients as compared to healthy controls, which suggests a distinct pathophysiological neutrophil phenotype in AASV [116]. Interestingly, higher CD177-mRNA, but not PR3-mRNA was found to correlate with a higher proportion of mPR3⁺/CD177⁺ cells, suggesting that overproduction of CD177 could lead to an increase in the proportion of mPR3⁺/CD177⁺ neutrophils [116].

It is likely that these two subpopulations have distinct functions, which may have a direct bearing on pathophysiological processes. Membrane CD177 helps neutrophils adhere to the endothelium, while m-PR3 helps this positive subpopulation to migrate through the endothe-

lium and interstitial tissues. It may be inferred that the mPR3⁺/CD177⁺ cells possess greater killing capabilities, including higher NET and ROS production, than the mPR3⁻/CD177⁻ sub-population. In simplistic terms, the mPR3⁺/CD177⁺ neutrophils may be the designated “fighting” neutrophils, designed to migrate from blood into tissues and promote pro-inflammatory, microbicidal functions, while mPR3-negative neutrophils are destined to stay in the intra-vascular compartment, and function as anti-inflammatory cells, until they are needed for resolution of inflammation to produce anti-inflammatory mediators or to phagocytose tissue debris and other dead neutrophils at the site of inflammation.

Our group is the first to demonstrate a lower rate of spontaneous apoptosis and *longer in vitro* survival in neutrophils from AASV patients in remission as compared to neutrophils from healthy blood donors [120].

Contrary to our results, Harper et al. showed that neutrophils from AASV patients, especially those with active disease, have an accelerated rate of apoptosis [106].

6. Pathophysiology of Henoch-Schönlein Purpura (HSP)

The etiology of HSP as well as its pathogenesis are largely unknown.

6.1. Genetic factors

Familial clustering of HSP has been described and suggests a genetic background to the disease [121,122]. In several countries and ethnic groups different HLA types have been associated with susceptibility for HSP [123,124]. The different HLA type associations may explain differences in manifestations between different ethnic groups, but, so far, no conclusions could be drawn from these studies to explain the pathogenesis of HSP. Positivity for HLAB35 was found to increase the risk for the development of HSP [125].

A polymorphism in the angiotensinogen gene (M235T) may confer risk for the development of Henoch-Schönlein Nephritis [126,127].

Polymorphisms in the gene for angiotensin 1-converting enzyme (ACE) may be involved in the pathogenesis of HSP or HSN, although data are conflicting. The insertion (I)/deletion (D) genotype of a polymorphism in ACE may confer susceptibility to HSP [126,127]. The DD polymorphism was related to persistent proteinuria in patients with HSP in one study [128], whereas in another study no correlation was found between the prognosis of HSP and the ACE genotype [129].

Variations in the complement C4 protein gene may confer susceptibility to the development of HSP. C4 null isotypes have been described to be prevalent in a significantly higher proportion of patients with HSP and HSN than controls [130,131,132]. A partial or complete deficiency of C4 could be related to impaired clearance of immune complexes and thus play a role in the pathogenesis of HSP [133]. Complement deficiency is, however, uncommon and transient in patients with HSP [134].

Investigations addressing polymorphisms in genes encoding for proinflammatory cytokines (TNF- α , IL-1b, IL-8, TGF- β and VEGF) have so far not revealed any predisposing factors for HSP [135,136].

Familial mediterranean fever (FMF) is an autoinflammatory disease caused by a mutation in the MEFV gene, which in 7 % of cases is associated with HSP [137]. There is a high prevalence of children with MEFV mutations among HSP patients in countries with relative abundance of FMF [138,139]. The implication this association has on the general pathogenesis of HSP is, if at all, unclear.

6.2. Infectious and non-infectious agents

HSP is usually preceded by infections, in up to 95 % of cases localized in the upper respiratory tract, and appears in clusters in families [140,141,142]. The incidence of HSP is highest during early childhood and shows distinct seasonal variations with a peak during autumn and winter [6]. Both early childhood and the autumn-winter season are periods with frequent infections. Thus, clinical observations suggest an important role of infections in the etiology and pathogenesis of HSP.

Several studies have shown a circumstantial relation of infections with group A streptococci and the development of HSP [143,144,145]. Others found serological evidence for an association with infections with other bacteria such as *Bartonella henselae* or viruses such as parvovirus B19 and hepatitis C virus [146,147,148].

Non-infectious agents have been found to be associated with the development of HSP especially in adults. These include certain drugs such as angiotensin-converting enzyme inhibitors, angiotensin II-receptor antagonists, antibiotics, and non-steroidal anti-inflammatory drugs as well as insect bites, vaccinations or food allergies [149].

6.3. IgA1 in HSP

IgA deposits in HSP are composed of immune-complexes mainly consisting of IgA1 [150].

Serum samples from HSN patients were found to have elevated levels of underglycosylated polymeric IgA1 compared to controls [151]. However, in children with HSP without renal involvement the levels were not higher than those of controls [152]. Underglycosylated polymeric IgA1 has been found to exhibit an inflammatory and proliferative effect on mesangial cells (see IgA1 in IgAN). Taken together, underglycosylated polymeric IgA1 seems to be involved in the development of HSN, but its role in the pathogenesis of HSP per se remains unclear.

6.4. Mediators of inflammation

The acute phase of systemic vasculitis is generally characterized by vascular leukocytic infiltration and activation of innate immunity. Elevated levels of inflammatory cytokines are usually detectable in the serum and affected tissues in these diseases.

IL-6, TNF- α , tumor necrosis factor-like weak inducer of apoptosis (TWEAK), IL-8, TGF- β , and VEGF have been found to be up-regulated during the acute stage of HSP [153,154].

Tissue samples of affected skin areas from patients with HSP show epidermal staining with IL-6 [155]. Serum levels of IL-6 were significantly higher in patients with HSP during the acute phase of disease than in controls and also higher in patients with HSN than HSP without renal affection [153]. IL-6 displays a wide variety of pro-inflammatory properties and promotes the secretion of IgA [153,156].

IL-6 displays, besides its various pro-inflammatory effects, even anti-inflammatory effects by inhibiting TNF- α and IL-1 and activating IL-1ra as well as IL-10 [157].

TNF- α is produced by macrophages and T cells in affected skin areas during HSP. Serum levels of TNF- α were higher in patients with HSN than HSP without renal engagement [153].

It stimulates the presentation of adhesion molecules and receptors on leukocytes and endothelial cells thereby directing inflammatory events. Furthermore, endothelial cells stimulated with TNF- α were shown to bind IgA with higher affinity [155]. These findings suggest, that TNF- α could be involved in the accumulation of granulocytes and endothelial sequestration of IgA as seen in affected tissues in HSP [153].

TWEAK, a member of the TNF superfamily, which binds to specific receptors on endothelial cells, is involved in the regulation of cell growth, angiogenesis, apoptosis, and inflammation.

In vitro evidence suggests that TWEAK may induce cytokine production by human microvascular endothelial cells via up-regulation of the production of IL-8 and CCL-5 leading to a leucocyte migration into affected vessels [158,159] which are common aspects of the HSP lesion.

Sera and IgA from patients with HSP induce the secretion of IL-8 from endothelial cells invitro [160,161].

IL-8 is a potent chemoattractant for polymorphonuclear neutrophilic granulocytes (PMNs). Levels of leukotriene B₄, also a potent chemo-attractant and activator of PMNs, are elevated both in serum and urine in patients with HSN compared to those with HSP.

Furthermore, the levels of leukotriene A₄, which counter-balance the effects of leukotriene B₄ and inhibit the synthesis of proinflammatory cytokines (e.g. IL-6, IL-8, TNF- α), are decreased in patients with HSN [162].

The role of VEGF in HSP is not clear-cut. Serum levels of VEGF were significantly higher during the acute phase of HSP than during remission. However tissue staining for VEGF showed more intense staining for VEGF in the epidermis and vascular bed during the resolution phase than during the acute phase of HSP [163]. High serum levels of VEGF could influence endothelial permeability, which may enhance capillary leakage and facilitate the extravasation and perivascular deposition of immune complexes. The increased tissue staining during the resolution phase, on the other hand, suggests a possible function of VEGF in the resolution of vascular damage.

T helper cells (Th) are a sub-population of lymphocytes, which have an important role in adaptive immune responses. Dependent on the surrounding cytokine environment naïve Th-cells differentiate into subtypes with different functions [164]. In patients with HSP an elevated number of Th2 and Th17 with increased synthesis of IL-5 and IL-13 have been found together with increased serum levels of IL-4, IL-6, and IL-17A [165]. The differentiation towards Th2 is stimulated by exposure to IL-4 and towards Th17 by TGF- β combined with IL-6. By secreting IL-4, Th2 exhibit a stimulatory effect on B cells and promote the generation of plasma cells. Further secretion of IL-5 or IL-13 from Th2 leads to an antibody switch in plasma cells towards the generation of IgA or IgE, respectively. Th17 secrete IL17, which in turn stimulates the expression of pro-inflammatory cytokines such as IL-1, IL-6, and cell adhesion factors and promotes leukocyte migration to the sites of inflammation. Th17 has been implicated in the pathogenesis of autoimmune diseases [164]. An imbalance of Th with Th2 and TH17 predominance, as seen in HSP, could explain elevated serum levels of IgA and IgE, the expression of pro-inflammatory cytokines and leukocyte infiltrations into affected tissues seen in HSP [166,167].

If the pieces of this puzzle are put together potential origins of cardinal symptoms of HSP emerge. Neutrophilic infiltration of the perivascular region may be mediated by TNF- α , TWEAK, IL-8, chemo-attractant leukotrienes, VEGF and/or Th17 and the extravasation and deposition of IgA by IL-6, TNF- α , VEGF, and Th2. The development of HSN could be related to the prevalence of underglycosylated polymeric IgA1, the effect of IL-6, TNF- α , and a disturbed balance between chemo-attractant and counteracting leukotrienes.

The contact system, which induces liberation of bradykinin or other vasoactive kinins from high-molecular kininogen, has been found to be activated in HSP, which could contribute to the development of clinical features such as inflammation, vasodilatation, edema and pain [168].

Increased reactive oxygen species, lipid and protein oxidation, and nitric oxide level detectable during the acute phase of HSP are believed to reflect secondary events and vascular damage [169,170,171].

Author details

Mohamed Abdgawad*

Address all correspondence to: mohamed.abdgawad@med.lu.se

The Department of Medicine, Blekinge Hospital, Karlshamn, Sweden

References

- [1] Firestein, G. S B. R. Harris Jr ED, McInnes IB, Ruddy S, Sargent JS ((2008). *Vasculitis. The classification and epidemiology of systemic vasculitis. Kelley's Tetbook of Rheumatology 8th edition Philadelphia, WB Saunders: Part 13, chapter 80.*
- [2] Watts, R S. D. (1995). *Vasculitis. Baillière's clinical rheumatology , 9, 529-554.*
- [3] Booth, A. D, Almond, M. K, Burns, A, Ellis, P, Gaskin, G, et al. (2003). *Outcome of ANCA-associated renal vasculitis: a 5-year retrospective study. Am J Kidney Dis , 41, 776-784.*
- [4] Davies, D. J, Moran, J. E, Niall, J. F, & Ryan, G. B. (1982). *Segmental necrotising glomerulonephritis with antineutrophil antibody: possible arbovirus aetiology? Br Med J (Clin Res Ed) 285: 606.*
- [5] Savage, C. O, Harper, L, & Adu, D. (1997). *Primary systemic vasculitis. Lancet , 349, 553-558.*
- [6] Gardner-medwin, J. M, Dolezalova, P, Cummins, C, & Southwood, T. R. (2002). *Incidence of Henoch-Schonlein purpura, Kawasaki disease, and rare vasculitides in children of different ethnic origins. Lancet , 360, 1197-1202.*
- [7] Niaudet, P, Murcia, I, Beaufils, H, Broyer, M, & Habib, R. (1993). *Primary IgA nephropathies in children: prognosis and treatment. Adv Nephrol Necker Hosp , 22, 121-140.*
- [8] Nunnelee, J. D. (2000). *Henoch-Schonlein purpura: a review of the literature. Clin Excell Nurse Pract , 4, 72-75.*
- [9] Iglesias-gamarra, A, Penaranda, E, & Espinoza, L. R. (2011). *Vasculitides throughout history and their clinical treatment today. Curr Rheumatol Rep , 13, 465-472.*
- [10] Kussmaul, A M. R. (1866). *Ueber eine bisher nicht beschriebene eigenthumliche arterienerkrankung (periarteritis nodosa), die mit morbus brightii und rapid fortschreitender allgemeiner muskellähmung einhergeht. Deutsche Arch Klin Med , 1, 484-518.*
- [11] McBride, P. (1991). *Photographs of a case of rapid destruction of the nose and face. 1897. J Laryngol Otol 105: 1120.*
- [12] Klinger, H. (1931). *Grenzformen der Periarteriitis nodosa.. Frankfurter Zeitschrift für Pathologie, Wiesbaden , 42, 455-480.*
- [13] Wegener, F. (1939). *Über eine eigenartige rhinogene Granulomatose mit besonderer Beteiligung des Arteriensystems und der Nieren. Beitr Pathol Anat , 102, 36-68.*
- [14] Godman, G. C C. J. (1954). *Wegener's granulomatosis: pathology and review of literature. AMA Arch Patholog , 58, 533-553.*

- [15] De Remeé RA MDTHarrison EJ Jr, et al ((1976). Wegener's granulomatosis, anatomic correlates, a proposed classification. *Mayo Clin Proc* , 51, 777-781.
- [16] Fauci, A. S W. S, & Johnson, J. S. (1971). Effect of cyclophosphamide upon the immune response in Wegener's granulomatosis. *N Engl J Med* 285.
- [17] Deremeé, R. A, Mcdonald, T. J, & Weiland, L. H. (1985). Wegener's granulomatosis: observations on treatment with antimicrobial agents. *Mayo Clin Proc* , 60, 27-32.
- [18] Van Der Woude, F. J, Rasmussen, N, Lobatto, S, Wiik, A, Permin, H, et al. (1985). Autoantibodies against neutrophils and monocytes: tool for diagnosis and marker of disease activity in Wegener's granulomatosis. *Lancet* , 1, 425-429.
- [19] Firestein, G. S B. R. Harris Jr ED, McInnes IB, Ruddy S, Sergent JS ((2008). *Vasculitis. Giant cell arteritis, polymyalgia rheumatica, and Takayasu's arteritis. Kelley's Textbook of Rheumatology 8th edition Philadelphia, WB Saunders: Part 13, chapter 81.*
- [20] Salama, A. D. (1999). Pathogenesis and treatment of ANCA-associated systemic vasculitis. *J R Soc Med* , 92, 456-461.
- [21] Goldschmeding, R, & Van Der Schoot, C. E. ten Bokkel Huinink D, Hack CE, van den Ende ME, et al. ((1989). Wegener's granulomatosis autoantibodies identify a novel diisopropylfluorophosphate-binding protein in the lysosomes of normal human neutrophils. *J Clin Invest* , 84, 1577-1587.
- [22] Niles, J. L, McCluskey, R. T, Ahmad, M. F, & Arnaout, M. A. (1989). Wegener's granulomatosis autoantigen is a novel neutrophil serine proteinase. *Blood* , 74, 1888-1893.
- [23] Ludemann, J, Csernok, E, Ulmer, M, Lemke, H, Utecht, B, et al. (1990). Anti-neutrophil cytoplasm antibodies in Wegener's granulomatosis: immunodiagnostic value, monoclonal antibodies and characterization of the target antigen. *Neth J Med* , 36, 157-162.
- [24] Falk, R. J, & Jennette, J. C. (1988). Anti-neutrophil cytoplasmic autoantibodies with specificity for myeloperoxidase in patients with systemic vasculitis and idiopathic necrotizing and crescentic glomerulonephritis. *N Engl J Med* , 318, 1651-1657.
- [25] Fries, J. F, Hunder, G. G, Bloch, D. A, Michel, B. A, Arend, W. P, et al. (1990). The American College of Rheumatology 1990 criteria for the classification of vasculitis. Summary. *Arthritis Rheum* , 33, 1135-1136.
- [26] Jennette, J. C, Falk, R. J, Andrassy, K, Bacon, P. A, Churg, J, et al. (1994). Nomenclature of systemic vasculitides. Proposal of an international consensus conference. *Arthritis Rheum* , 37, 187-192.
- [27] Watts, R, Lane, S, Hanslik, T, Hauser, T, Hellmich, B, et al. (2007). Development and validation of a consensus methodology for the classification of the ANCA-associated vasculitides and polyarteritis nodosa for epidemiological studies. *Ann Rheum Dis* , 66, 222-227.

- [28] Fauci, A. S, Haynes, B. F, Katz, P, & Wolff, S. M. (1983). Wegener's granulomatosis: prospective clinical and therapeutic experience with 85 patients for 21 years. *Ann Intern Med* , 98, 76-85.
- [29] Reinhold-keller, E, Beuge, N, Latza, U, De Groot, K, Rudert, H, et al. (2000). An interdisciplinary approach to the care of patients with Wegener's granulomatosis: long-term outcome in 155 patients. *Arthritis Rheum* , 43, 1021-1032.
- [30] Westman, K. W, Bygren, P. G, Olsson, H, Ranstam, J, & Wieslander, J. (1998). Relapse rate, renal survival, and cancer morbidity in patients with Wegener's granulomatosis or microscopic polyangiitis with renal involvement. *J Am Soc Nephrol* , 9, 842-852.
- [31] Gayraud, M, & Guillevin, L. le Toumelin P, Cohen P, Lhote F, et al. ((2001). Long-term followup of polyarteritis nodosa, microscopic polyangiitis, and Churg-Strauss syndrome: analysis of four prospective trials including 278 patients. *Arthritis Rheum* , 44, 666-675.
- [32] Csernok, E, Moosig, F, & Gross, W. L. (2008). Pathways to ANCA production: from differentiation of dendritic cells by proteinase 3 to B lymphocyte maturation in Wegener's granuloma. *Clin Rev Allergy Immunol* , 34, 300-306.
- [33] Voswinkel, J, Mueller, A, Kraemer, J. A, Lamprecht, P, Herlyn, K, et al. (2006). B lymphocyte maturation in Wegener's granulomatosis: a comparative analysis of VH genes from endonasal lesions. *Ann Rheum Dis* , 65, 859-864.
- [34] Culton, D. A, Nicholas, M. W, Bunch, D. O, Zhen, Q. L, Kepler, T. B, et al. (2007). Similar CD19 dysregulation in two autoantibody-associated autoimmune diseases suggests a shared mechanism of B-cell tolerance loss. *J Clin Immunol* , 27, 53-68.
- [35] Bunch, D. O, Silver, J. S, Majure, M. C, Sullivan, P, Alcorta, D. A, et al. (2008). Maintenance of tolerance by regulation of anti-myeloperoxidase B cells. *J Am Soc Nephrol* , 19, 1763-1773.
- [36] Krumbholz, M, Specks, U, Wick, M, Kalled, S. L, Jenne, D, et al. (2005). BAFF is elevated in serum of patients with Wegener's granulomatosis. *J Autoimmun* , 25, 298-302.
- [37] Keogh, K. A, Wylam, M. E, Stone, J. H, & Specks, U. (2005). Induction of remission by B lymphocyte depletion in eleven patients with refractory antineutrophil cytoplasmic antibody-associated vasculitis. *Arthritis Rheum* , 52, 262-268.
- [38] Keogh, K. A, Ytterberg, S. R, Fervenza, F. C, Carlson, K. A, Schroeder, D. R, et al. (2006). Rituximab for refractory Wegener's granulomatosis: report of a prospective, open-label pilot trial. *Am J Respir Crit Care Med* , 173, 180-187.
- [39] Ferraro, A. J, Day, C. J, Drayson, M. T, & Savage, C. O. (2005). Effective therapeutic use of rituximab in refractory Wegener's granulomatosis. *Nephrol Dial Transplant* , 20, 622-625.

- [40] Brouwer, E, Tervaert, J. W, Horst, G, Huitema, M. G, Van Der Giessen, M, et al. (1991). Predominance of IgG1 and IgG4 subclasses of anti-neutrophil cytoplasmic autoantibodies (ANCA) in patients with Wegener's granulomatosis and clinically related disorders. *Clin Exp Immunol* , 83, 379-386.
- [41] Lockwood, C. M, Thiru, S, Stewart, S, Hale, G, Isaacs, J, et al. (1996). Treatment of refractory Wegener's granulomatosis with humanized monoclonal antibodies. *Qjm* , 89, 903-912.
- [42] Hagen, E. C, De Keizer, R. J, Andrassy, K, Van Boven, W. P, Bruijn, J. A, et al. (1995). Compassionate treatment of Wegener's granulomatosis with rabbit anti-thymocyte globulin. *Clin Nephrol* , 43, 351-359.
- [43] Sanders, J. S, Huitma, M. G, Kallenberg, C. G, & Stegeman, C. A. (2006). Plasma levels of soluble interleukin 2 receptor, soluble CD30, interleukin 10 and B cell activator of the tumour necrosis factor family during follow-up in vasculitis associated with proteinase 3-antineutrophil cytoplasmic antibodies: associations with disease activity and relapse. *Ann Rheum Dis* , 65, 1484-1489.
- [44] Abdulahad, W. H, Van Der Geld, Y. M, Stegeman, C. A, & Kallenberg, C. G. (2006). Persistent expansion of CD4+ effector memory T cells in Wegener's granulomatosis. *Kidney Int* , 70, 938-947.
- [45] Marinaki, S, Kalsch, A. I, Grimminger, P, Breedijk, A, Birck, R, et al. (2006). Persistent T-cell activation and clinical correlations in patients with ANCA-associated systemic vasculitis. *Nephrol Dial Transplant* , 21, 1825-1832.
- [46] Schonermarck, U, Csernok, E, Trabandt, A, Hansen, H, & Gross, W. L. (2000). Circulating cytokines and soluble CD23, CD26 and CD30 in ANCA-associated vasculitides. *Clin Exp Rheumatol* , 18, 457-463.
- [47] Wang, G, Hansen, H, Tatsis, E, Csernok, E, Lemke, H, et al. (1997). High plasma levels of the soluble form of CD30 activation molecule reflect disease activity in patients with Wegener's granulomatosis. *Am J Med* , 102, 517-523.
- [48] Lamprecht, P, Bruhl, H, Erdmann, A, Holl-ulrich, K, Csernok, E, et al. (2003). Differences in CCR5 expression on peripheral blood CD4+CD28- T-cells and in granulomatous lesions between localized and generalized Wegener's granulomatosis. *Clin Immunol* , 108, 1-7.
- [49] Ruth, A. J, Kitching, A. R, Kwan, R. Y, Odobasic, D, Ooi, J. D, et al. (2006). Anti-neutrophil cytoplasmic antibodies and effector CD4+ cells play nonredundant roles in anti-myeloperoxidase crescentic glomerulonephritis. *J Am Soc Nephrol* , 17, 1940-1949.
- [50] Sakatsume, M, Xie, Y, Ueno, M, Obayashi, H, Goto, S, et al. (2001). Human glomerulonephritis accompanied by active cellular infiltrates shows effector T cells in urine. *J Am Soc Nephrol* , 12, 2636-2644.

- [51] Capraru, D, Muller, A, Csernok, E, Gross, W. L, Holl-ulrich, K, et al. (2008). Expansion of circulating NKG2D+ effector memory T-cells and expression of NKG2D-ligand MIC in granulomatous lesions in Wegener's granulomatosis. *Clin Immunol* , 127, 144-150.
- [52] Abdulahad, W. H, Stegeman, C. A, Limburg, P. C, & Kallenberg, C. G. (2008). Skewed distribution of Th17 lymphocytes in patients with Wegener's granulomatosis in remission. *Arthritis Rheum* , 58, 2196-2205.
- [53] Wikman, A, & Fagergren, A. Gunnar OJS, Lundahl J, Jacobson SH ((2003). Monocyte activation and relationship to anti-proteinase 3 in acute vasculitis. *Nephrol Dial Transplant* , 18, 1792-1799.
- [54] Ohlsson, S, Wieslander, J, & Segelmark, M. (2004). Circulating cytokine profile in anti-neutrophilic cytoplasmic autoantibody-associated vasculitis: prediction of outcome? *Mediators Inflamm* , 13, 275-283.
- [55] Ferrario, F, & Rastaldi, M. P. (1999). Necrotizing-crescentic glomerulonephritis in ANCA-associated vasculitis: the role of monocytes. *Nephrol Dial Transplant* , 14, 1627-1631.
- [56] Ralston, D. R, Marsh, C. B, Lowe, M. P, & Wewers, M. D. (1997). Antineutrophil cytoplasmic antibodies induce monocyte IL-8 release. Role of surface proteinase-3, alpha1-antitrypsin, and Fc gamma receptors. *J Clin Invest* , 100, 1416-1424.
- [57] Hattar, K, Bickenbach, A, Csernok, E, Rosseau, S, Grandel, U, et al. (2002). Wegener's granulomatosis: antiproteinase 3 antibodies induce monocyte cytokine and prostanoïd release-role of autocrine cell activation. *J Leukoc Biol* , 71, 996-1004.
- [58] Lan, H. Y, Mitsushashi, H, Ng, Y. Y, Nikolic-paterson, D. J, Yang, N, et al. (1997). Macrophage apoptosis in rat crescentic glomerulonephritis. *Am J Pathol* , 151, 531-538.
- [59] Jennette, J. C O. J, Schwart, M. M, & Silva, F. G. (1998). Renal involvement in small-vessel vasculitis. *Heptinstall's pathology of the kidney Philadelphia: Lippincott-Raven 5th Edition: 1059.*
- [60] Di Lorenzo GPacor ML, Mansueto P, Lo Bianco C, Di Natale E, et al. ((2004). Circulating levels of soluble adhesion molecules in patients with ANCA-associated vasculitis. *J Nephrol* , 17, 800-807.
- [61] Woywodt, A, Streiber, F, De Groot, K, Regelsberger, H, Haller, H, et al. (2003). Circulating endothelial cells as markers for ANCA-associated small-vessel vasculitis. *Lancet* , 361, 206-210.
- [62] Haubitz, M, Gerlach, M, Kruse, H. J, & Brunkhorst, R. (2001). Endothelial tissue factor stimulation by proteinase 3 and elastase. *Clin Exp Immunol* , 126, 584-588.

- [63] Gobel, U, Eichhorn, J, Kettritz, R, Briedigkeit, L, Sima, D, et al. (1996). Disease activity and autoantibodies to endothelial cells in patients with Wegener's granulomatosis. *Am J Kidney Dis* , 28, 186-194.
- [64] Ballieux, B. E, Zondervan, K. T, Kievit, P, Hagen, E. C, Van Es, L. A, et al. (1994). Binding of proteinase 3 and myeloperoxidase to endothelial cells: ANCA-mediated endothelial damage through ADCC? *Clin Exp Immunol* , 97, 52-60.
- [65] Taekema-roelvink, M. E, Van Kooten, C, Heemskerk, E, Schroeijs, W, & Daha, M. R. (2000). Proteinase 3 interacts with a 111-kD membrane molecule of human umbilical vein endothelial cells. *J Am Soc Nephrol* , 11, 640-648.
- [66] Kumpers, P, Hellpap, J, David, S, Horn, R, Leitolf, H, et al. (2009). Circulating angiotensin-2 is a marker and potential mediator of endothelial cell detachment in ANCA-associated vasculitis with renal involvement. *Nephrol Dial Transplant* , 24, 1845-1850.
- [67] Chen, M, & Kallenberg, C. G. (2010). The environment, geoepidemiology and ANCA-associated vasculitides. *Autoimmun Rev* 9: A, 293-298.
- [68] Pelclova, D, Bartunkova, J, Fenclova, Z, Lebedova, J, Hladikova, M, et al. (2003). Asbestos exposure and antineutrophil cytoplasmic Antibody (ANCA) positivity. *Arch Environ Health* , 58, 662-668.
- [69] Beaudreuil, S, Lasfargues, G, Laueriere, L, El Ghoul, Z, Fourquet, F, et al. (2005). Occupational exposure in ANCA-positive patients: a case-control study. *Kidney Int* , 67, 1961-1966.
- [70] Bonaci-nikolic, B, Andrejevic, S, Pavlovic, M, Dimcic, Z, Ivanovic, B, et al. (2010). Prolonged infections associated with antineutrophil cytoplasmic antibodies specific to proteinase 3 and myeloperoxidase: diagnostic and therapeutic challenge. *Clin Rheumatol* , 29, 893-904.
- [71] Stegeman, C. A, Tervaert, J. W, Sluiter, W. J, Manson, W. L, De Jong, P. E, et al. (1994). Association of chronic nasal carriage of *Staphylococcus aureus* and higher relapse rates in Wegener granulomatosis. *Ann Intern Med* , 120, 12-17.
- [72] Choi, H. K, Lamprecht, P, Niles, J. L, Gross, W. L, & Merkel, P. A. (2000). Subacute bacterial endocarditis with positive cytoplasmic antineutrophil cytoplasmic antibodies and anti-proteinase 3 antibodies. *Arthritis Rheum* , 43, 226-231.
- [73] Pendergraft, W. F. rd, Preston GA, Shah RR, Tropsha A, Carter CW, Jr., et al. ((2004). Autoimmunity is triggered by cPR-3(105-201), a protein complementary to human autoantigen proteinase-3. *Nat Med* , 10, 72-79.
- [74] Kain, R, Matsui, K, Exner, M, Binder, S, Schaffner, G, et al. (1995). A novel class of autoantigens of anti-neutrophil cytoplasmic antibodies in necrotizing and crescentic glomerulonephritis: the lysosomal membrane glycoprotein h-lamp-2 in neutrophil

- granulocytes and a related membrane protein in glomerular endothelial cells. *J Exp Med* , 181, 585-597.
- [75] Stoney, P. J, Davies, W, Ho, S. F, Paterson, I. C, & Griffith, I. P. (1991). Wegener's granulomatosis in two siblings: a family study. *J Laryngol Otol* , 105, 123-124.
- [76] Sewell, R. F, & Hamilton, D. V. (1992). Time-associated Wegener's granulomatosis in two members of a family. *Nephrol Dial Transplant* 7: 882.
- [77] Hay, E. M, Beaman, M, Ralston, A. J, Ackrill, P, Bernstein, R. M, et al. (1991). Wegener's granulomatosis occurring in siblings. *Br J Rheumatol* , 30, 144-145.
- [78] Witko-sarsat, V, Lesavre, P, Lopez, S, Bessou, G, Hieblot, C, et al. (1999). A large subset of neutrophils expressing membrane proteinase 3 is a risk factor for vasculitis and rheumatoid arthritis. *J Am Soc Nephrol* , 10, 1224-1233.
- [79] Schreiber, A, Busjahn, A, Luft, F. C, & Kettritz, R. (2003). Membrane expression of proteinase 3 is genetically determined. *J Am Soc Nephrol* , 14, 68-75.
- [80] Gencik, M, Meller, S, Borgmann, S, & Fricke, H. (2000). Proteinase 3 gene polymorphisms and Wegener's granulomatosis. *Kidney Int* , 58, 2473-2477.
- [81] Steiner, K, Moosig, F, Csernok, E, Selleng, K, Gross, W. L, et al. (2001). Increased expression of CTLA-4 (CD152) by T and B lymphocytes in Wegener's granulomatosis. *Clin Exp Immunol* , 126, 143-150.
- [82] Elzouki, A. N, Segelmark, M, Wieslander, J, & Eriksson, S. (1994). Strong link between the alpha 1-antitrypsin PiZ allele and Wegener's granulomatosis. *J Intern Med* , 236, 543-548.
- [83] Fiebeler, A, Borgmann, S, Woywodt, A, Haller, H, & Haubitz, M. (2004). No association of G-463A myeloperoxidase gene polymorphism with MPO-ANCA-associated vasculitis. *Nephrol Dial Transplant* , 19, 969-971.
- [84] Tse, W. Y, Abadeh, S, Jefferis, R, Savage, C. O, & Adu, D. (2000). Neutrophil Fcγ₃ allelic polymorphism in anti-neutrophil cytoplasmic antibody (ANCA)-positive systemic vasculitis. *Clin Exp Immunol* , 119, 574-577.
- [85] Hoffman, G. S, & Specks, U. (1998). Antineutrophil cytoplasmic antibodies. *Arthritis Rheum* , 41, 1521-1537.
- [86] Xiao, H, Heeringa, P, Hu, P, Liu, Z, Zhao, M, et al. (2002). Antineutrophil cytoplasmic autoantibodies specific for myeloperoxidase cause glomerulonephritis and vasculitis in mice. *J Clin Invest* , 110, 955-963.
- [87] Neumann, I, Birck, R, Newman, M, Schnulle, P, Kriz, W, et al. (2003). SCG/Kinjoh mice: a model of ANCA-associated crescentic glomerulonephritis with immune deposits. *Kidney Int* , 64, 140-148.

- [88] Bajema, I. M, Hagen, E. C, De Heer, E, Van Der Woude, F. J, & Bruijn, J. A. (2001). Colocalization of ANCA-antigens and fibrinoid necrosis in ANCA-associated vasculitis. *Kidney Int* , 60, 2025-2030.
- [89] Schlieben, D. J, Korbet, S. M, Kimura, R. E, Schwartz, M. M, & Lewis, E. J. (2005). Pulmonary-renal syndrome in a newborn with placental transmission of ANCA. *Am J Kidney Dis* , 45, 758-761.
- [90] Primo, V. C, Marusic, S, Franklin, C. C, Goldmann, W. H, Achaval, C. G, et al. (2010). Anti-PR3 immune responses induce segmental and necrotizing glomerulonephritis. *Clin Exp Immunol* , 159, 327-337.
- [91] Travis, W. D, Hoffman, G. S, Leavitt, R. Y, Pass, H. I, & Fauci, A. S. (1991). Surgical pathology of the lung in Wegener's granulomatosis. Review of 87 open lung biopsies from 67 patients. *Am J Surg Pathol* , 15, 315-333.
- [92] Leigh, J, Wang, H, Bonin, A, Peters, M, & Ruan, X. (1997). Silica-induced apoptosis in alveolar and granulomatous cells in vivo. *Environ Health Perspect* 105 Suppl , 5, 1241-1245.
- [93] Rastaldi, M. P, Ferrario, F, & Crippa, A. Dell'Antonio G, Casartelli D, et al. ((2000). Glomerular monocyte-macrophage features in ANCA-positive renal vasculitis and cryoglobulinemic nephritis. *J Am Soc Nephrol* , 11, 2036-2043.
- [94] Barksdale, S. K, Hallahan, C. W, Kerr, G. S, Fauci, A. S, Stern, J. B, et al. (1995). Cutaneous pathology in Wegener's granulomatosis. A clinicopathologic study of 75 biopsies in 46 patients. *Am J Surg Pathol* , 19, 161-172.
- [95] Yamamoto, T, Kaburagi, Y, Izaki, S, Tanaka, T, & Kitamura, K. (2000). Leukocytoclasia: ultrastructural in situ nick end labeling study in anaphylactoid purpura. *J Dermatol Sci* , 24, 158-165.
- [96] Aikoh, T, Tomokuni, A, Matsukii, T, Hyodoh, F, Ueki, H, et al. (1998). Activation-induced cell death in human peripheral blood lymphocytes after stimulation with silicate in vitro. *Int J Oncol* , 12, 1355-1359.
- [97] Borges, V. M, Falcao, H, Leite-junior, J. H, Alvim, L, Teixeira, G. P, et al. (2001). Fas ligand triggers pulmonary silicosis. *J Exp Med* , 194, 155-164.
- [98] Zysk, G, Bejo, L, Schneider-wald, B. K, Nau, R, & Heinz, H. (2000). Induction of necrosis and apoptosis of neutrophil granulocytes by *Streptococcus pneumoniae*. *Clin Exp Immunol* , 122, 61-66.
- [99] Kolaja, K. L, Hood, A. M, & Klaassen, C. D. (1999). The UDP-glucuronyltransferase inducers, phenobarbital and pregnenolone-16alpha-carbonitrile, enhance thyroid-follicular cell apoptosis: association with TGF-beta1 expression. *Toxicol Lett* , 106, 143-150.

- [100] Esnault, V. L. (2002). Apoptosis: the central actor in the three hits that trigger anti-neutrophil cytoplasmic antibody-related systemic vasculitis. *Nephrol Dial Transplant* , 17, 1725-1728.
- [101] Kettritz, R, Scheumann, J, Xu, Y, Luft, F. C, & Haller, H. (2002). TNF-alpha--accelerated apoptosis abrogates ANCA-mediated neutrophil respiratory burst by a caspase-dependent mechanism. *Kidney Int* , 61, 502-515.
- [102] Patry, Y. C, Trewick, D. C, Gregoire, M, Audrain, M. A, Moreau, A. M, et al. (2001). Rats injected with syngenic rat apoptotic neutrophils develop antineutrophil cytoplasmic antibodies. *J Am Soc Nephrol* , 12, 1764-1768.
- [103] Rauova, L, Gilburd, B, Zurgil, N, Blank, M, Guegas, L. L, et al. (2002). Induction of biologically active antineutrophil cytoplasmic antibodies by immunization with human apoptotic polymorphonuclear leukocytes. *Clin Immunol* , 103, 69-78.
- [104] Harper, L, Ren, Y, Savill, J, Adu, D, & Savage, C. O. (2000). Antineutrophil cytoplasmic antibodies induce reactive oxygen-dependent dysregulation of primed neutrophil apoptosis and clearance by macrophages. *Am J Pathol* , 157, 211-220.
- [105] Moosig, F, Csernok, E, Kumanovics, G, & Gross, W. L. (2000). Opsonization of apoptotic neutrophils by anti-neutrophil cytoplasmic antibodies (ANCA) leads to enhanced uptake by macrophages and increased release of tumour necrosis factor-alpha (TNF-alpha). *Clin Exp Immunol* , 122, 499-503.
- [106] Harper, L, Cockwell, P, Adu, D, & Savage, C. O. (2001). Neutrophil priming and apoptosis in anti-neutrophil cytoplasmic autoantibody-associated vasculitis. *Kidney Int* , 59, 1729-1738.
- [107] Deutsch, M, Guejes, L, Zurgil, N, Shovman, O, Gilburd, B, et al. (2004). Antineutrophil cytoplasmic autoantibodies penetrate into human polymorphonuclear leukocytes and modify their apoptosis. *Clin Exp Rheumatol* 22: S, 35-40.
- [108] Harper, L. (2006). ANCA-associated vasculitis: is there a role for neutrophil apoptosis in autoimmunity? *Expert Rev Clin Immunol* , 2, 237-244.
- [109] Brinkmann, V, Reichard, U, Goosmann, C, Fauler, B, Uhlemann, Y, et al. (2004). Neutrophil extracellular traps kill bacteria. *Science* , 303, 1532-1535.
- [110] Brinkmann, V, & Zychlinsky, A. (2007). Beneficial suicide: why neutrophils die to make NETs. *Nat Rev Microbiol* , 5, 577-582.
- [111] Fuchs, T. A, Abed, U, Goosmann, C, Hurwitz, R, Schulze, I, et al. (2007). Novel cell death program leads to neutrophil extracellular traps. *J Cell Biol* , 176, 231-241.
- [112] Kessenbrock, K, Krumbholz, M, Schonermarck, U, Back, W, Gross, W. L, et al. (2009). Netting neutrophils in autoimmune small-vessel vasculitis. *Nat Med* , 15, 623-625.

- [113] Holdenrieder, S, Eichhorn, P, Beuers, U, Samtleben, W, Schoenermarck, U, et al. (2006). Nucleosomal DNA fragments in autoimmune diseases. *Ann N Y Acad Sci* , 1075, 318-327.
- [114] Ohlsson, S, Wieslander, J, & Segelmark, M. (2003). Increased circulating levels of proteinase 3 in patients with anti-neutrophilic cytoplasmic autoantibodies-associated systemic vasculitis in remission. *Clin Exp Immunol* , 131, 528-535.
- [115] Abdgawad, M, Hellmark, T, Gunnarsson, L, Westman, K. W, & Segelmark, M. (2006). Increased neutrophil membrane expression and plasma level of proteinase 3 in systemic vasculitis are not a consequence of the -564 A/G promoter polymorphism. *Clin Exp Immunol* , 145, 63-70.
- [116] Abdgawad, M, Gunnarsson, L, Bengtsson, A. A, Geborek, P, Nilsson, L, et al. (2010). Elevated neutrophil membrane expression of proteinase 3 is dependent upon CD177 expression. *Clin Exp Immunol* , 161, 89-97.
- [117] Ohlsson, S, Hellmark, T, Pieters, K, Sturfelt, G, Wieslander, J, et al. (2005). Increased monocyte transcription of the proteinase 3 gene in small vessel vasculitis. *Clin Exp Immunol* , 141, 174-182.
- [118] Bauer, S, Abdgawad, M, Gunnarsson, L, Segelmark, M, Tapper, H, et al. (2007). Proteinase 3 and CD177 are expressed on the plasma membrane of the same subset of neutrophils. *J Leukoc Biol* , 81, 458-464.
- [119] Von Vietinghoff, S, Tunnemann, G, Eulenberg, C, & Wellner, M. Cristina Cardoso M, et al. ((2007). NB1 mediates surface expression of the ANCA antigen proteinase 3 on human neutrophils. *Blood* , 109, 4487-4493.
- [120] Abdgawad, M, Pettersson, A, Gunnarsson, L, Bengtsson, A. A, Geborek, P, et al. (2012). Decreased neutrophil apoptosis in quiescent ANCA-associated systemic vasculitis. *PLoS One* 7: e32439.
- [121] Levy, M. (2001). Familial cases of Berger's disease and anaphylactoid purpura. *Kidney Int* , 60, 1611-1612.
- [122] Motoyama, O, & Iitaka, K. (2005). Familial cases of Henoch-Schonlein purpura in eight families. *Pediatr Int* , 47, 612-615.
- [123] Saulsbury, F. T. (2010). Henoch-Schonlein purpura. *Curr Opin Rheumatol* , 22, 598-602.
- [124] Ren, S. M, Yang, G. L, Liu, C. Z, Zhang, C. X, Shou, Q. H, et al. (2012). Association between HLA-A and-B polymorphisms and susceptibility to Henoch-Schonlein purpura in Han and Mongolian children from Inner Mongolia. *Genet Mol Res* , 11, 221-228.

- [125] Amoli, M. M, Thomson, W, Hajeer, A. H, Calvino, M. C, Garcia-porrúa, C, et al. (2002). HLA-B35 association with nephritis in Henoch-Schonlein purpura. *J Rheumatol* , 29, 948-949.
- [126] Ozkaya, O, Soylemezoglu, O, Gonen, S, Misirlioglu, M, Tuncer, S, et al. (2006). Renin-angiotensin system gene polymorphisms: association with susceptibility to Henoch-Schonlein purpura and renal involvement. *Clin Rheumatol* , 25, 861-865.
- [127] Desong, L, Fang, L, Songhui, Z, Liu, W, Shi, M, et al. (2010). Renin-angiotensin system gene polymorphisms in children with Henoch-Schonlein purpura in West China. *J Renin Angiotensin Aldosterone Syst* , 11, 248-255.
- [128] Yoshioka, T, Xu, Y. X, Yoshida, H, Shiraga, H, Muraki, T, et al. (1998). Deletion polymorphism of the angiotensin converting enzyme gene predicts persistent proteinuria in Henoch-Schonlein purpura nephritis. *Arch Dis Child* , 79, 394-399.
- [129] Amoroso, A, Danek, G, Vatta, S, Crovella, S, Berrino, M, et al. (1998). Polymorphisms in angiotensin-converting enzyme gene and severity of renal disease in Henoch-Schoenlein patients. Italian Group of Renal Immunopathology. *Nephrol Dial Transplant* , 13, 3184-3188.
- [130] Ault, B. H, Stapleton, F. B, Rivas, M. L, Waldo, F. B, Roy, S, et al. (1990). Association of Henoch-Schonlein purpura glomerulonephritis with C4B deficiency. *J Pediatr* , 117, 753-755.
- [131] Mclean, R. H, Wyatt, R. J, & Julian, B. A. (1984). Complement phenotypes in glomerulonephritis: increased frequency of homozygous null C4 phenotypes in IgA nephropathy and Henoch-Schonlein purpura. *Kidney Int* , 26, 855-860.
- [132] Stefansson Thors V, Kolka R, Sigurdardottir SL, Edvardsson VO, Arason G, et al. ((2005). Increased frequency of C4B*Q0 alleles in patients with Henoch-Schonlein purpura. *Scand J Immunol* , 61, 274-278.
- [133] Atkinson, J. P. (1989). Complement deficiency: predisposing factor to autoimmune syndromes. *Clin Exp Rheumatol* 7 Suppl 3: S, 95-101.
- [134] Motoyama, O, & Iitaka, K. (2005). Henoch-Schonlein purpura with hypocomplementemia in children. *Pediatr Int* , 47, 39-42.
- [135] Brogan, P. A. (2007). What's new in the aetiopathogenesis of vasculitis? *Pediatr Nephrol* , 22, 1083-1094.
- [136] Yang, Y. H, Chuang, Y. H, Wang, L. C, Huang, H. Y, Gershwin, M. E, et al. (2008). The immunobiology of Henoch-Schonlein purpura. *Autoimmun Rev* , 7, 179-184.
- [137] Ozdogan, H, Arisoy, N, Kasapcapur, O, Sever, L, Caliskan, S, et al. (1997). Vasculitis in familial Mediterranean fever. *J Rheumatol* , 24, 323-327.

- [138] Gershoni-baruch, R, Broza, Y, & Brik, R. (2003). Prevalence and significance of mutations in the familial Mediterranean fever gene in Henoch-Schonlein purpura. *J Pediatr* , 143, 658-661.
- [139] Ozcakar, Z. B, Yalcinkaya, F, Cakar, N, Acar, B, Kasapcopur, O, et al. (2008). MEFV mutations modify the clinical presentation of Henoch-Schonlein purpura. *J Rheumatol* , 35, 2427-2429.
- [140] Farley, T. A, Gillespie, S, Rasoulpour, M, Tolentino, N, Hadler, J. L, et al. (1989). Epidemiology of a cluster of Henoch-Schonlein purpura. *Am J Dis Child* , 143, 798-803.
- [141] Allen, D. M, Diamond, L. K, & Howell, D. A. (1960). Anaphylactoid purpura in children (Schonlein-Henoch syndrome): review with a follow-up of the renal complications. *AMA J Dis Child* , 99, 833-854.
- [142] Levy-khademi, F, Korman, S. H, & Amitai, Y. (2000). Henoch-Schonlein purpura: simultaneous occurrence in two siblings. *Pediatr Dermatol* , 17, 139-140.
- [143] Al-sheyyab, M, Shanti, H, Ajlouni, S, Batieha, A, & Daoud, A. S. (1996). Henoch-Schonlein purpura: clinical experience and contemplations on a streptococcal association. *J Trop Pediatr* , 42, 200-203.
- [144] Al-sheyyab, M, Batieha, A, Shanti, H, & Daoud, A. (1999). Henoch-Schonlein purpura and streptococcal infection: a prospective case-control study. *Ann Trop Paediatr* , 19, 253-255.
- [145] Masuda, M, Nakanishi, K, Yoshizawa, N, Iijima, K, & Yoshikawa, N. (2003). Group A streptococcal antigen in the glomeruli of children with Henoch-Schonlein nephritis. *Am J Kidney Dis* , 41, 366-370.
- [146] Frankum, B, & Katelaris, C. H. (1995). Hepatitis C infection and Henoch-Schonlein purpura. *Aust N Z J Med* 25: 176.
- [147] Ayoub, E. M, McBride, J, Schmiederer, M, & Anderson, B. (2002). Role of Bartonella henselae in the etiology of Henoch-Schonlein purpura. *Pediatr Infect Dis J* , 21, 28-31.
- [148] Cioc, A. M, Sedmak, D. D, Nuovo, G. J, Dawood, M. R, Smart, G, et al. (2002). Parvovirus B19 associated adult Henoch Schonlein purpura. *J Cutan Pathol* , 29, 602-607.
- [149] Gonzalez, L. M, Janniger, C. K, & Schwartz, R. A. (2009). Pediatric Henoch-Schonlein purpura. *Int J Dermatol* , 48, 1157-1165.
- [150] Conley, M. E, Cooper, M. D, & Michael, A. F. (1980). Selective deposition of immunoglobulin A1 in immunoglobulin A nephropathy, anaphylactoid purpura nephritis, and systemic lupus erythematosus. *J Clin Invest* , 66, 1432-1436.
- [151] Lau, K. K, Wyatt, R. J, Moldoveanu, Z, Tomana, M, Julian, B. A, et al. (2007). Serum levels of galactose-deficient IgA in children with IgA nephropathy and Henoch-Schonlein purpura. *Pediatr Nephrol* , 22, 2067-2072.

- [152] Allen, A. C, Willis, F. R, Beattie, T. J, & Feehally, J. (1998). Abnormal IgA glycosylation in Henoch-Schonlein purpura restricted to patients with clinical nephritis. *Nephrol Dial Transplant* , 13, 930-934.
- [153] Besbas, N, Saatci, U, Ruacan, S, Ozen, S, Sungur, A, et al. (1997). The role of cytokines in Henoch Schonlein purpura. *Scand J Rheumatol* , 26, 456-460.
- [154] Tahan, F, Dursun, I, Poyrazoglu, H, Gurgoze, M, & Dusunsel, R. (2007). The role of chemokines in Henoch Schonlein Purpura. *Rheumatol Int* , 27, 955-960.
- [155] Yang, Y. H, Wang, S. J, Chuang, Y. H, Lin, Y. T, & Chiang, B. L. (2002). The level of IgA antibodies to human umbilical vein endothelial cells can be enhanced by TNF-alpha treatment in children with Henoch-Schonlein purpura. *Clin Exp Immunol* , 130, 352-357.
- [156] Kunimoto, D. Y, Nordan, R. P, & Strober, W. (1989). IL-6 is a potent cofactor of IL-1 in IgM synthesis and of IL-5 in IgA synthesis. *J Immunol* , 143, 2230-2235.
- [157] Petersen, A. M, & Pedersen, B. K. (2005). The anti-inflammatory effect of exercise. *J Appl Physiol* , 98, 1154-1162.
- [158] Chen, T, Guo, Z. P, Li, M. M, Li, J. Y, Jiao, X. Y, et al. (2011). Tumour necrosis factor-like weak inducer of apoptosis (TWEAK), an important mediator of endothelial inflammation, is associated with the pathogenesis of Henoch-Schonlein purpura. *Clin Exp Immunol* , 166, 64-71.
- [159] Sanchez-nino, M. D, Benito-martin, A, Goncalves, S, Sanz, A. B, Ucerro, A. C, et al. TNF superfamily: a growing saga of kidney injury modulators. *Mediators Inflamm* (2010).
- [160] Yang, Y. H, Lai, H. J, Huang, C. M, Wang, L. C, Lin, Y. T, et al. (2004). Sera from children with active Henoch-Schonlein purpura can enhance the production of interleukin 8 by human umbilical venous endothelial cells. *Ann Rheum Dis* , 63, 1511-1513.
- [161] Yang, Y. H, Huang, Y. H, Lin, Y. L, Wang, L. C, Chuang, Y. H, et al. (2006). Circulating IgA from acute stage of childhood Henoch-Schonlein purpura can enhance endothelial interleukin (IL)-8 production through MEK/ERK signalling pathway. *Clin Exp Immunol* , 144, 247-253.
- [162] Wu, S. H, Liao, P. Y, Yin, P. L, Zhang, Y. M, & Dong, L. (2009). Inverse temporal changes of lipoxin A4 and leukotrienes in children with Henoch-Schonlein purpura. *Prostaglandins Leukot Essent Fatty Acids* , 80, 177-183.
- [163] Topaloglu, R, Sungur, A, Baskin, E, Besbas, N, Saatci, U, et al. (2001). Vascular endothelial growth factor in Henoch-Schonlein purpura. *J Rheumatol* , 28, 2269-2273.
- [164] Afzali, B, Lombardi, G, Lechler, R. I, & Lord, G. M. (2007). The role of T helper 17 (Th17) and regulatory T cells (Treg) in human organ transplantation and autoimmune disease. *Clin Exp Immunol* , 148, 32-46.

- [165] Li, Y. Y, Li, C. R, Wang, G. B, & Yang, J. Zu Y Investigation of the change in CD4(+) T cell subset in children with Henoch-Schonlein purpura. *Rheumatol Int.*
- [166] Mccarthy, H. J, & Tizard, E. J. (2010). Clinical practice: Diagnosis and management of Henoch-Schonlein purpura. *Eur J Pediatr* , 169, 643-650.
- [167] Davin, J. C, Pierard, G, Dechenne, C, Grossman, D, Nagy, J, et al. (1994). Possible pathogenic role of IgE in Henoch-Schonlein purpura. *Pediatr Nephrol* , 8, 169-171.
- [168] Kahn, R, Herwald, H, Muller-esterl, W, Schmitt, R, Sjogren, A. C, et al. (2002). Contact-system activation in children with vasculitis. *Lancet* , 360, 535-541.
- [169] Demircin, G, Oner, A, Unver, Y, Bulbul, M, & Erdogan, O. (1998). Erythrocyte superoxide dismutase activity and plasma malondialdehyde levels in children with Henoch Schonlein purpura. *Acta Paediatr* , 87, 848-852.
- [170] Ece, A, Kelekci, S, Hekimoglu, A, Kocamaz, H, Balik, H, et al. (2007). Neutrophil activation, protein oxidation and ceruloplasmin levels in children with Henoch-Schonlein purpura. *Pediatr Nephrol* , 22, 1151-1157.
- [171] Soylemezoglu, O, Ozkaya, O, Erbas, D, Akkok, N, Buyan, N, et al. (2002). Nitric oxide in Henoch-Schonlein purpura. *Scand J Rheumatol* , 31, 271-274.

