

We are IntechOpen, the world's leading publisher of Open Access books Built by scientists, for scientists

4,800

Open access books available

122,000

International authors and editors

135M

Downloads

Our authors are among the

154

Countries delivered to

TOP 1%

most cited scientists

12.2%

Contributors from top 500 universities

**WEB OF SCIENCE™**Selection of our books indexed in the Book Citation Index
in Web of Science™ Core Collection (BKCI)

Interested in publishing with us? Contact book.department@intechopen.com

Numbers displayed above are based on latest data collected.

For more information visit www.intechopen.com

Proximal Interphalangeal Joint Arthrodesis with Tendon Transfer of the Flexor Digitorum Brevis

Ricardo Becerro de Bengoa Vallejo,
Marta Elena Losa Iglesias and
Miguel Fuentes Rodriguez

Additional information is available at the end of the chapter

<http://dx.doi.org/10.5772/52752>

1. Introduction

Hammer toe is a deformity characterized by dorsiflexion of the metatarsophalangeal (MTP) joint, plantarflexion of the proximal interphalangeal (PIP) joint, and dorsiflexion of the distal interphalangeal (DIP) joint. Claw toe is a similar deformity characterized by dorsiflexion of the MTP and plantarflexion of the PIP and DIP joints. These terms are often used interchangeably because both deformities involve the MTP joint. [1]

The causes of dorsiflexion of the metatarso- and interphalangeal joint have been described by various authors. [3], [4], [5], [6] Sandeman [2] reported that when the proximal phalanx is in the dorsal position at the expense of MTP dorsiflexion, the axis of the intrinsic musculature shifts. This causes a loss of competence of the intrinsic musculature of the foot, and the proximal phalanx can no longer be maintained in a plantar position. In the presence of concurrent flexor digitorum longus (FDL) contraction, the intrinsic musculature loses its ability to plantarflex the MTP joint. In a closed kinetic chain, this causes pathologic dorsiflexion of the MTP joint and places the proximal phalanx in a dorsal position. The result is claw or hammer deformity of the involved digits. Surgical correction of claw and hammer toe deformities utilize the action of the FDL tendon transferred to transform the deforming forces into corrective forces.

Correction of this flexible digital deformity by means of tendinous transposition of the flexor musculature to the extensor region of the toes has been described. [7], [8], [9], [10], [11], [12], [13] In each instance two cutaneous incisions have been utilized, one dorsal and another plantar. Only Barbari and Brevig [9] have described FDL tendon transfer to the dorsum of the

extensor digitorum longus (EDL) tendon through a single incision approach. In this approach the dorso-lateral incision over the MTP joint extends about 3 cm distally from the neck of the metatarsal bone when there is only a single involved digit. When the procedure is undertaken in multiple digits, a transverse incision at the level of the digit crease is performed and the FDL tendon is sutured end-to-side to the EDL tendon. The authors stated that care must be taken to avoid injuring the neurovascular axes which are retracted laterally. The authors also advocated, when indicated, performing plantar capsulotomies for the DIP and PIP joints as described by Pypers [12] and Taylor. [13] The additional incision, however, increases the risk for injuring the principal plantar vessels of the involved digits..

Thus far, it has been recommended that correction of claw and hammer toe deformities be performed by transferring the FDL tendon to the dorsum of the proximal phalanx. Transposition of the FDL tendon via the dorsal approach through a unique longitudinal dorsal cutaneous incision without performing plantar incisions for capsulotomies of the DIP and PIP joints has not been previously described. To determine the feasibility of transferring the FDL tendon as an approach to correct claw and hammer toe deformities with this approach, it is necessary to determine whether these fascicles are long enough to transpose to the plantar aspect of the EDL tendon in the dorsal area of the proximal phalanx, and directly to the dorsum of the proximal phalanx of the second and third toes. We hypothesized that the FDL tendon, when incised at the level of the PIP joint, has adequate anatomical length to be transferred to the dorsal aspect of the proximal phalanx via a single longitudinal dorsal cutaneous incision and it would not be necessary to perform plantar capsulotomies at the interphalangeal joints, thus decreasing the risk of injury to the principal plantar vessels of the digits.

2. Materials and methods

Sixty cadaveric foot specimens (Total N, 60; 30 right, 30 left) were used for study procedures, including fourteen fresh and forty-six embalmed specimens. Transfer of the FDL tendon to the dorsum of the proximal phalanx via dorsal approach was attempted in 120 toes (60 each second and third toes).

The surgical technique performed in this study was a modification of a previously described method to transfer the flexor digitorum brevis (FDB) tendon. [14] To perform the FDL transfer a central longitudinal incision was made on the dorsal aspect of the digit, preserving the medial and lateral vessels and nerves. The incision was along the dorsum of the proximal phalanx of the digit from the base to the PIP joint. Once the EDL tendon was exposed, it was tenotomized and released along with the transverse aponeurosis that shapes the digital extensor apparatus. Proximal phalanx arthroplasty and hood ligament and MTP joint release were then performed by means of a dorsal, medial, and lateral capsulotomy. Section of the collateral and suspensory ligaments was performed to reduce the fixed extension deformity of the MTP joint in the specimens with fixed claw or hammer toe deformities.

After arthroplasty of the proximal phalanx was completed the dorsal aspect of the distal tendon sheath of the FDL and FDB tendons was exposed (Fig. 1). The vincula from the plantar aspect

of the proximal phalanx to the dorsal aspect of the FDL and FDB tendons were released to further expose the flexor tendon sheath (Fig. 2). The tendon sheath was then incised and split longitudinally to the base of the middle phalanx (Fig. 3A), and the medial and lateral hemitendons of the FDB were exposed dorsally to the FDL (Fig. 3B). Plantar exposure of the FDB tendon was performed by inserting a curved hemostat by means of a blunt technique to identify and isolate the medial and lateral fascicles (Fig. 4 A, B). If the hemitendons of the FDB were not split adequately to permit passage of the FDL tendon, the FDB was divided longitudinally and proximally using a #15 blade (Fig. 5). The lateral and medial FDB hemitendons were then retracted to expose the FDL tendon (Fig. 6). Using a curved hemostat the FDL was collected dorsally between the medial and lateral FDB hemitendons (Fig. 7). Using a mini-osteotome, the FDL tendon was released from the plantar aspect of the distal middle phalanx to maximize the available tendon length (Fig. 8). This technique maximizes the length of the free distal tendinous stump to facilitate transfer to the dorsal aspect of the proximal phalanx (Fig. 9). The free proximal end of the tendon was clamped for later transfer (Fig 10). Next, using a #15 blade, the long flexor was split longitudinally in two portions, lateral and medial, proximal to distal (Fig. 11). Both free proximal FDL tendons were exposed between the plantar aspect of the proximal phalanx and the dorsal aspect of the FDB tendons (Fig 12).

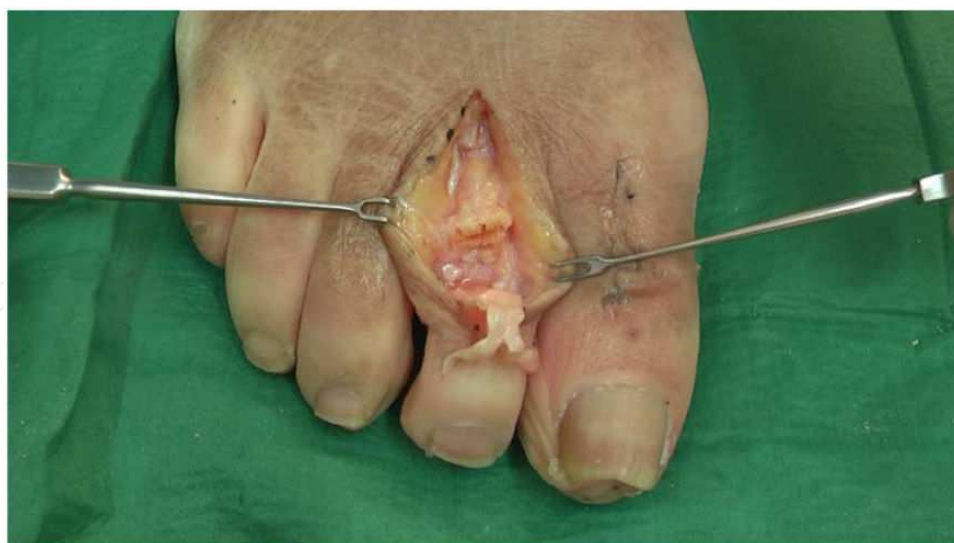

Figure 1. Dorsal aspect of the second digit after arthroplasty of the proximal phalanx and release of the metatarsophalangeal joint. The base of the middle phalanx is exposed. The proximal phalanx with the head resected is shown, and plantarly is the digital segment of the distal tendon sheath of the flexor digitorum longus and brevis tendons.

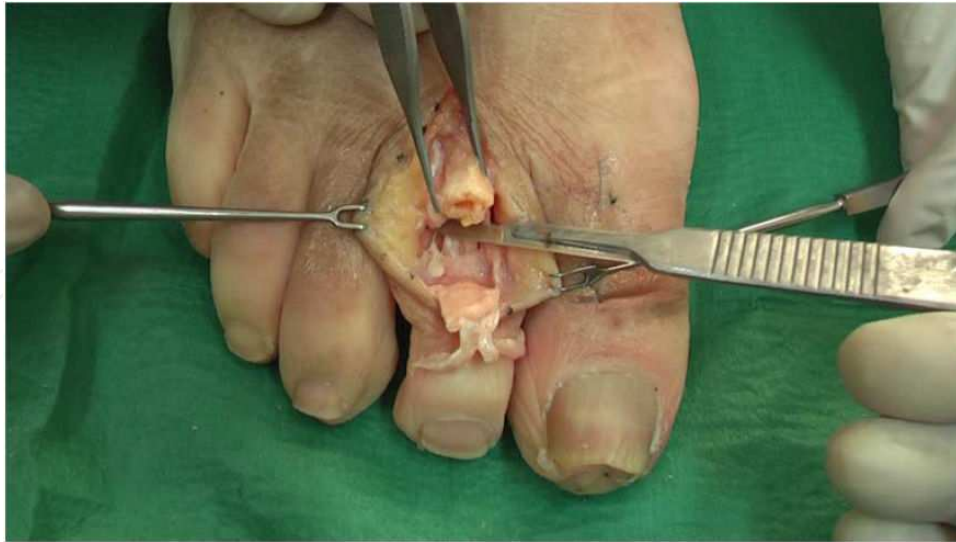
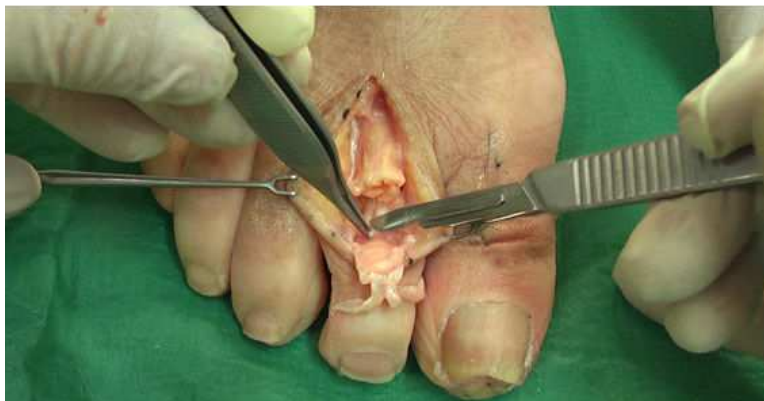
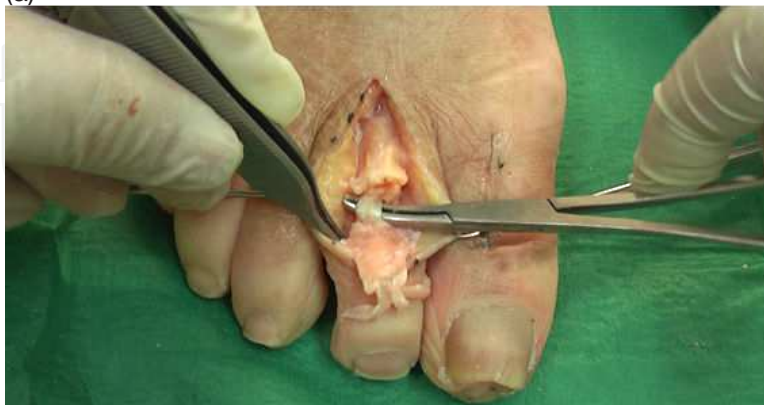Figure 2. The plantar vincula are sectioned to release the flexor tendon sheath at the plantar aspect of the proximal phalanx of the second digit.



(a)



(b)

Figure 3. (a) The tendinous sheath is cut longitudinally, proximally and distally to the base of the middle phalanx. **(b)** The tendinous sheath is opened, and the flexor digitorum brevis hemitendons, lateral and medial, are exposed over the curved hemostat.

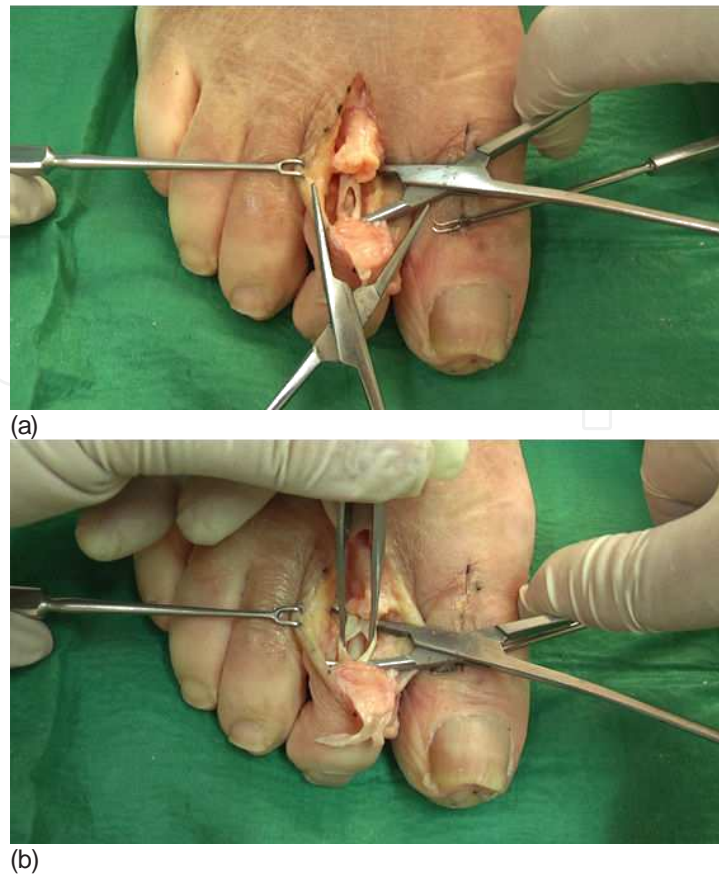


Figure 4. (a) The medial and lateral fascicles of the flexor digitorum brevis tendon are isolated using a curved hemostat. The flexor digitorum longus is localized plantarly. (b) Dorsal view of the hemitendons of flexor digitorum brevis with inadequate separation.

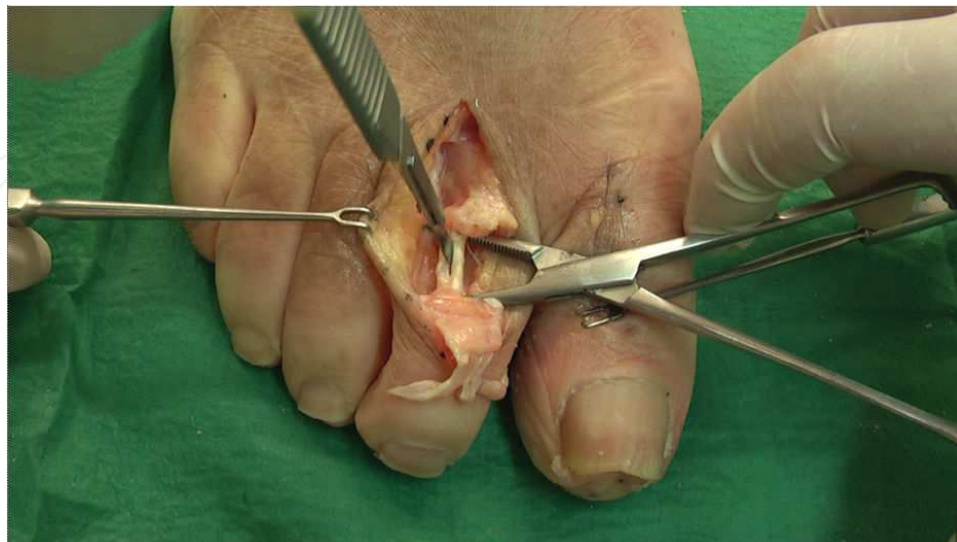

Figure 5. Flexor digitorum brevis is divided longitudinally and proximally using a blade #15 to permit passage of the flexor digitorum longus tendon.

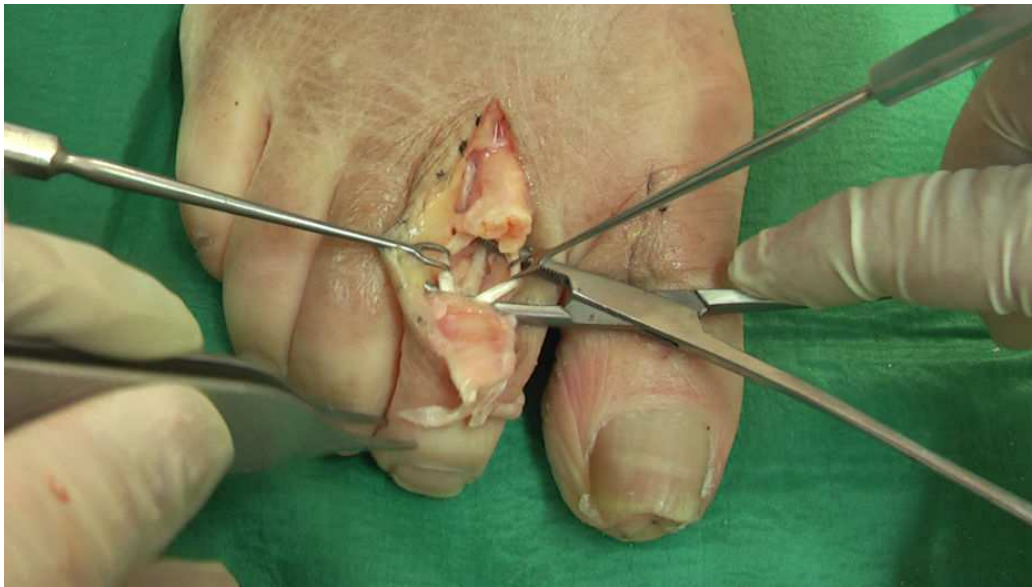

Figure 6. Medial and lateral hemitendon of the flexor digitorum brevis are retracted for plantar exposure of the flexor digitorum longus tendon.

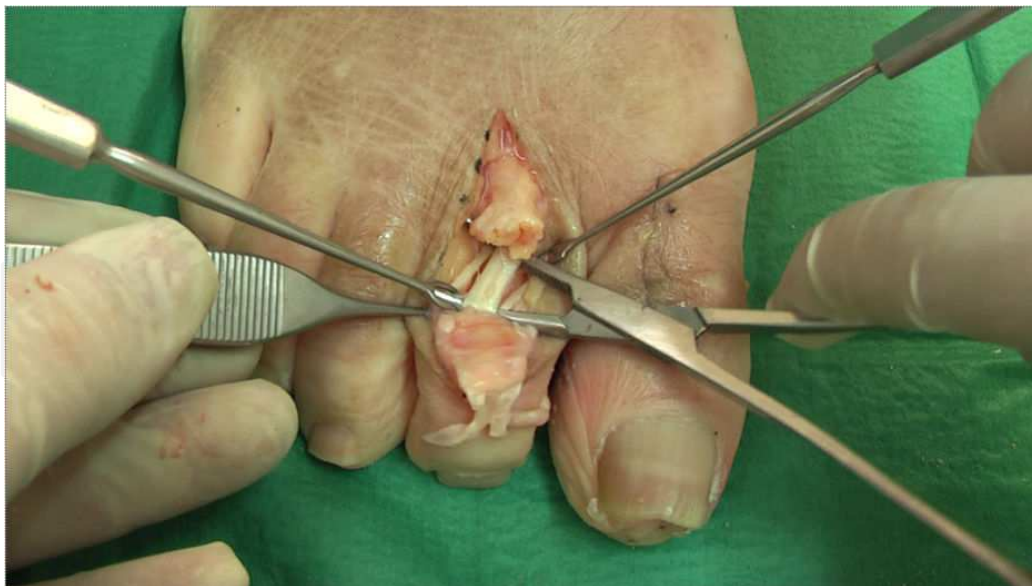

Figure 7. Using a curved hemostat and situating it plantar to the flexor digitorum longus is collocated dorsally between the medial and lateral hemitendons of flexor digitorum brevis.

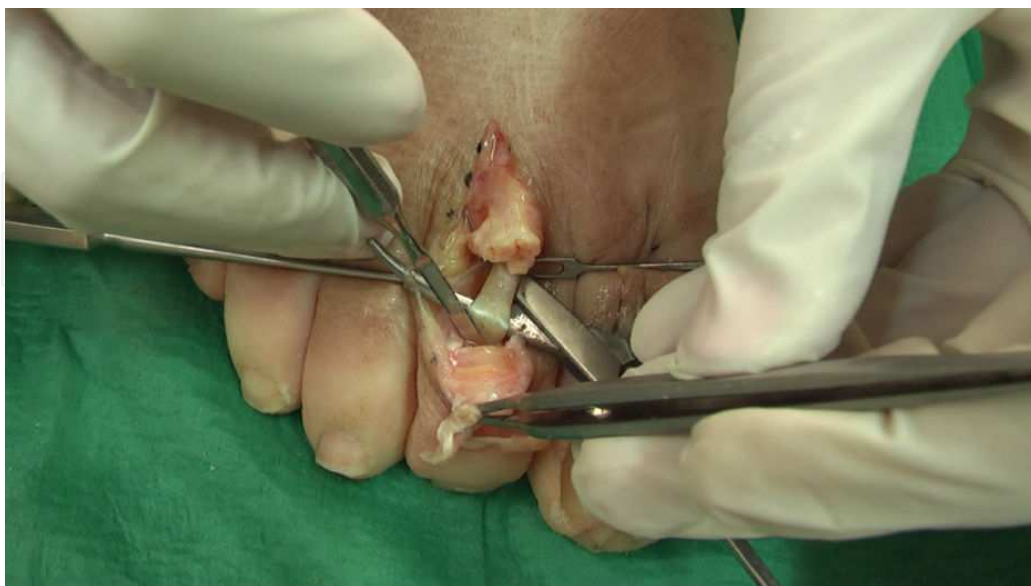

Figure 8. Using a mini-osteotome, the flexor digitorum longus tendon is released from the plantar aspect of the middle phalanx distally to obtain more tendon to facilitate the transfer.

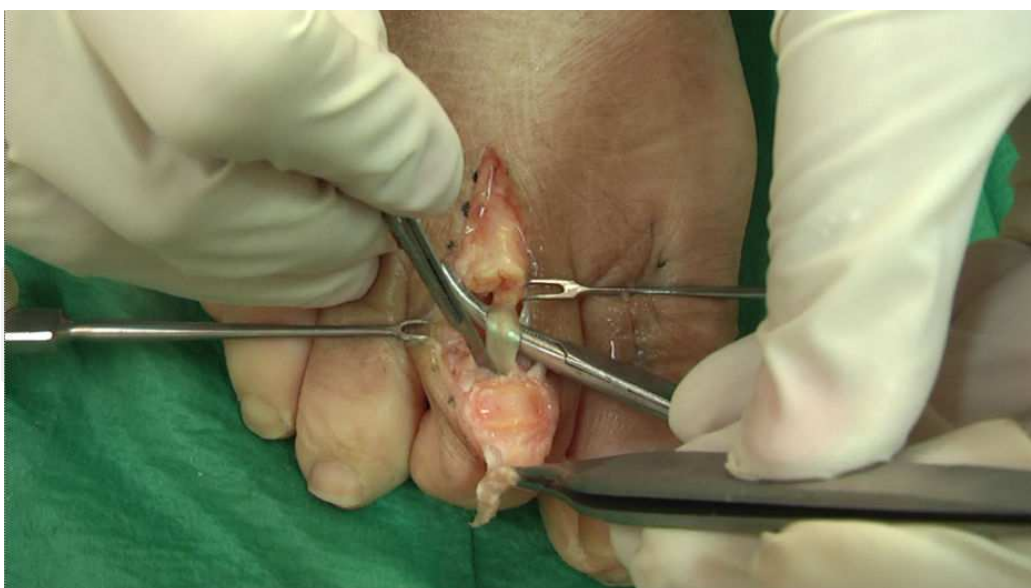

Figure 9. Flexor digitorum longus tendon is cut through its insertion point as distally as possible to the middle phalanx to maximize the length of the free distal tendinous stump.

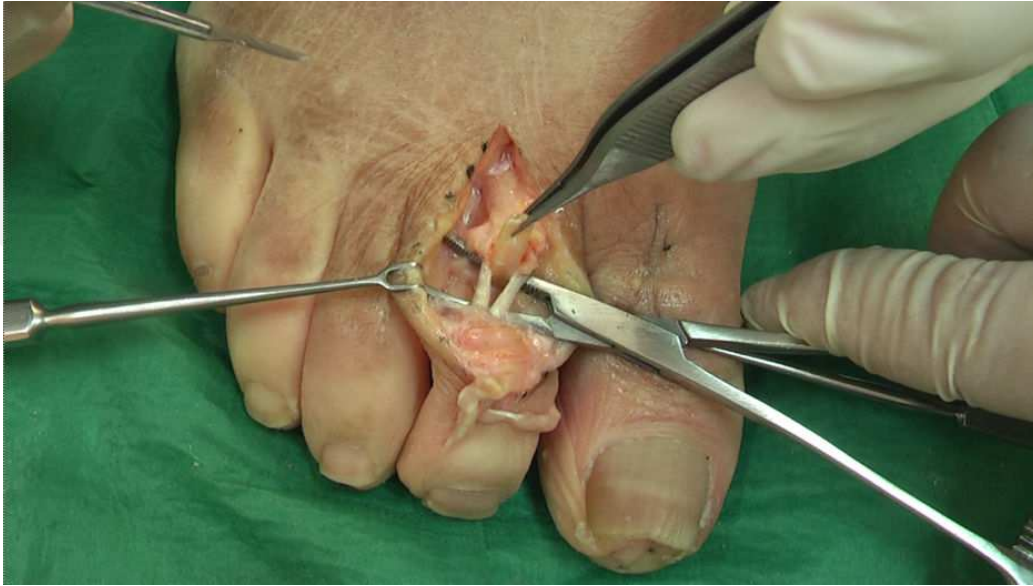

Figure 10. The stump of the proximal flexor digitorum longus tendon is clamped.

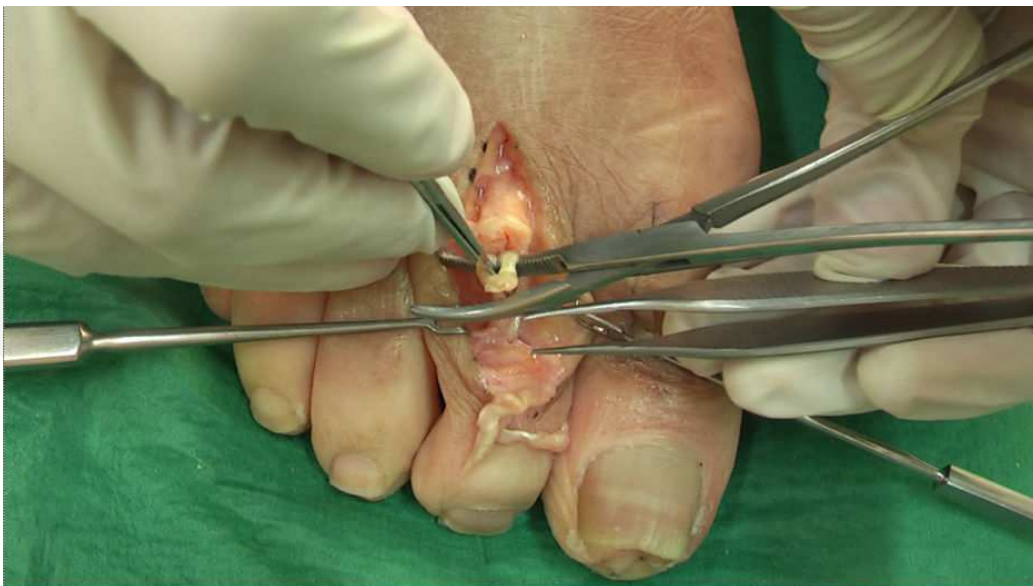
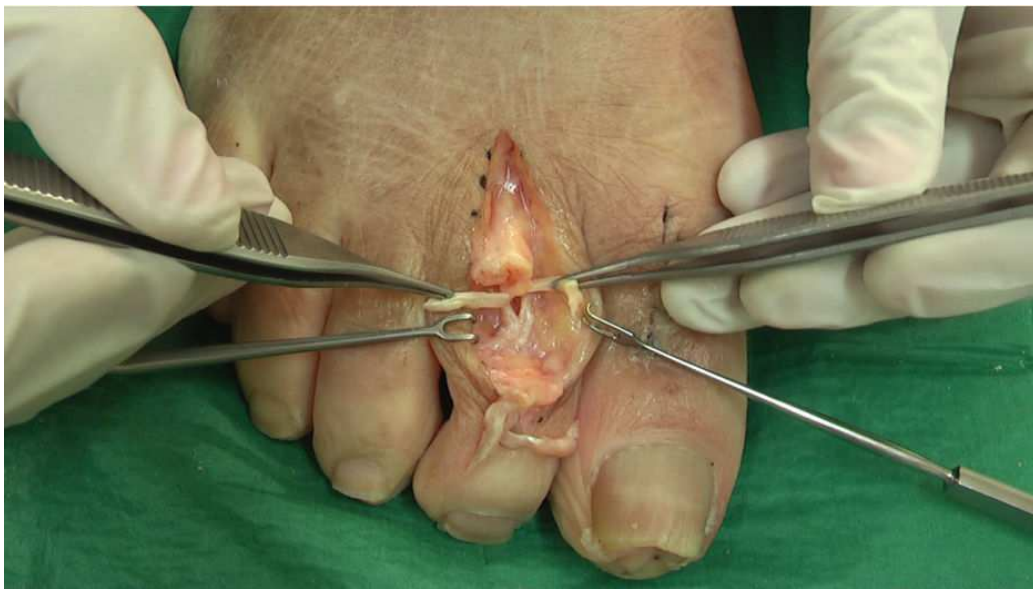
Figure 11. The long flexor is split longitudinally using a #15 blade.

IntechOpen



IntechOpen

Figure 12. The flexor digitorum longus tendon has been split longitudinally in two portions, lateral and medial.

Once the medial and lateral fascicles of the FDL tendon had been clamped they were transferred to the dorsal aspect of the medial and lateral proximal phalanx, respectively. During this procedure the length of the split tendinous fascicles of the FDL tendon were evaluated to ascertain whether the length was sufficient to permit transposition over the dorsal proximal phalanx. If the length was not adequate, a major incision was made in the proximal flexor tendon sheath. The medial and lateral FDL tendon stumps were sutured to itself in the dorsum of the proximal phalanx (Fig. 13 A,B,C,D).

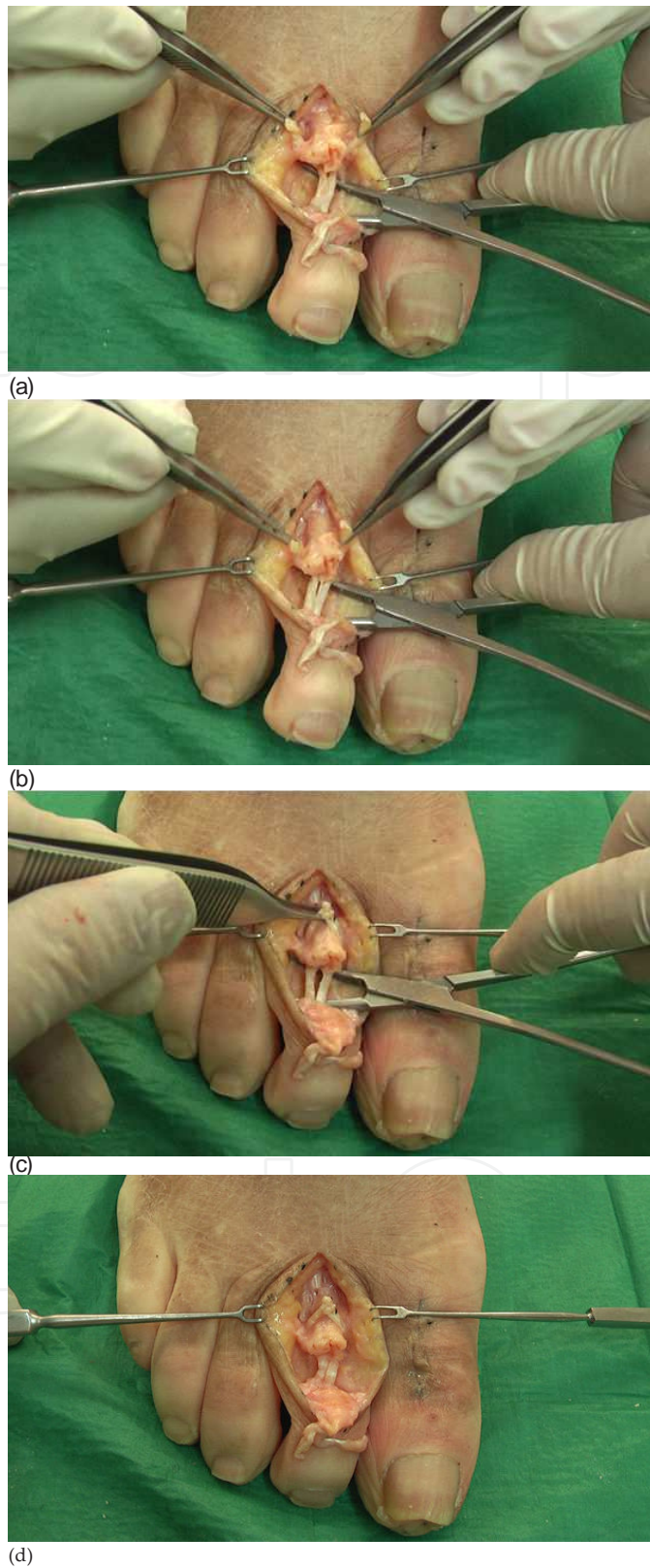


Figure 13. (a and b) The medial and lateral fascicles of the flexor digitorum longus tendon are transferred to the dorsal area of the proximal phalanx. The hemostat is showing the flexor digitorum brevis hemitendons. **(c)** Dorsal view of the medial and lateral stumps of the flexor digitorum longus tendon transferred to the medial and lateral aspects of

the proximal phalanx, respectively, and clamped with a pick up. The hemostat is showing the flexor digitorum brevis hemitendons intact. **(d)** Dorsal view of the flexor digitorum longus transferred to the dorsal aspect of the proximal phalanx

The toe was pinned using a double-pointed 0.54-mm Kirschner wire in a retrograde manner driven antegrade from the PIP joint, out the tip of the toe, and then retrograde into the proximal phalanx and the metatarsal head. The EDL stumps were sutured over the transferred FDL tendon (Fig. 14), and cutaneous suturing was performed in a usual manner.

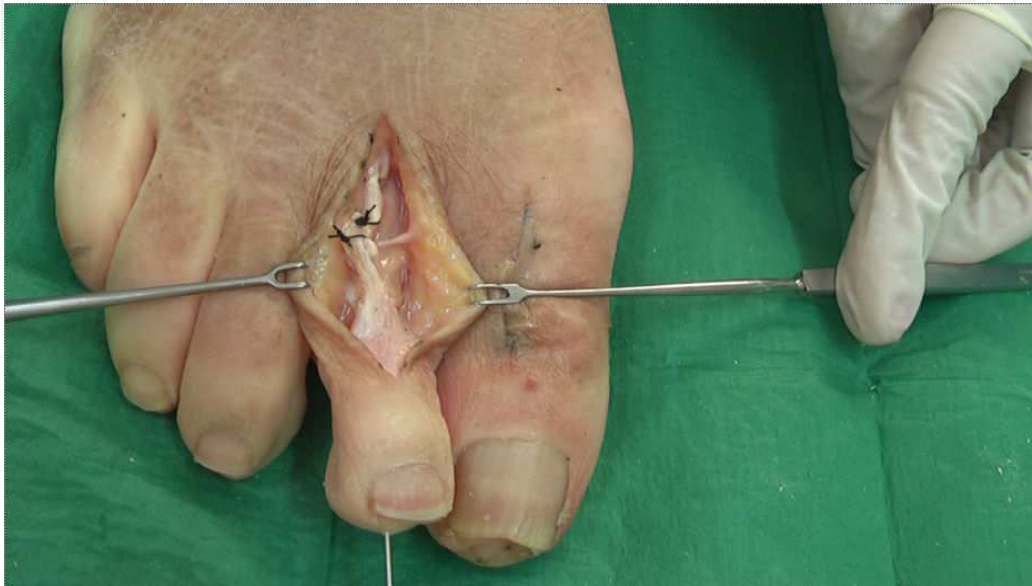

Figure 14. The extensor digitorum longus tendon stumps are sutured over the transferred flexor digitorum longus tendon.

3. Results

The FDL tendon transfer by the unique longitudinal dorsal approach attempted on 120 cadaveric toes (60 second toes and 30 third toes) was successful in 100% of the cases.

4. Discussion

The results of this study indicate that transfer of the FDL tendinous fascicles between the FDB hemitendons can be performed on second and third digits via a unique dorsal incision. Success of the procedure is predicated, in part, on an adequate longitudinal incision of the flexor tendon sheath that permits exposure and separation of the FDB hemitendons. We believe the indications for FDL tendon transfer between FDB hemitendons are the same as those for the FDL tendon transfer that other authors [28]- [36] are using for the correction of sagittal plane lesser MTP joint instability and loss of digital purchase. We do not, however, advocate this approach

when the fifth digit is involved. In the current investigation, the FDB tendon was absent in 3 cases (7%), thus the dorsal approach was not possible. Any hammer toe or claw toe deformity that is accompanied by a semi-rigid or rigid MTP joint requires accompanying correction. This correction may be accomplished via PIP joint fusion or FDL tendon transfer, which moves the lever arm to the MTP joint and holds the proximal phalanx in a plantarflexed position.

Based on the results of this investigation, we believe the surgical technique for FDL tendon transfer should utilize a dorsal approach to minimize the risk of compromising the principal blood supply to the involved digits. Chen et al [37] evaluated the vasculature of 20 foot specimens focusing on the second, third, and fourth toes. Findings from the study suggest that plantar circulation is predominant in the second, third, and fourth toes, while dorsal circulation predominated in the first digit. Chen et al [37] further stated that the plantar digital arteries of the lesser toes provide the predominant arterial supply of the PIP joints through a system of transverse and longitudinal arches. Thus, when a claw or hammer toe deformity correction is performed via FDL tendon transfer through a two-incision plantar approach, a decision must be made regarding whether to continue or discontinue surgery when there is a risk of vascular compromise to the digit due to two incisions. Emphasizing the potential deleterious consequences of multiple incisions, Coughlin [18] recommended that it is far better to offer a 2-stage repair of the deformity than to incur a vascular insult with excessive surgery on a digit.

Surgical correction of hammer and claw toe deformity has been described extensively. Transposition of the flexor tendon to the extensor musculature through a dorso-lateral cut, with FDL tendon transfer to the dorso-lateral area of the proximal phalanx, was originally performed by Girdlestone in 1947 and developed by Taylor. [13] In his study, Taylor included 68 patients with claw or hammer toe deformity treated with this technique and associated procedures, such as dorsal capsulotomy of the MTP joint. Taylor also performed plantar capsulotomy of the interphalangeal joints and stabilization of the proximal phalanx using an external splint. Several modifications of the procedure have subsequently been reported. In 1970, Sgarlato [16] reported 53 cases of FDL tendon transfer through 3 skin incisions. Pyper [12] performed the technique described by Taylor [13] on 45 feet in 23 patients. To correct the digital deformity, he combined it with lengthening of the EDL tendon and dorsal capsulotomy of the MTP joint. Subsequently, Parrish [11] modified this technique by detaching the FDL tendon and dividing the proximal tendinous stump longitudinally and repositioning its medial and lateral aspects in the extensor area. He performed FDL and FDB tendon transfer on the first 5 patients in his series but not on the remaining 18 patients, stating that "the FDB tendon had a smaller calibre and its length was insufficient for the transposition." [11]

Marcinko et al [17] described the FDL tendon transfer using two incisions in the toe, one plantar and another dorsal. Barbari and Brevig [9] performed 39 FDL transpositions to the extensor area in 31 patients; 11 of the 39 procedures were performed in accordance with the technique of Taylor, [13] with the remaining 28 following the modified technique described by Parrish. [11] The approach was through a dorso-lateral incision over the MTP joint extending approximately 3 cm distally from the neck of the metatarsal bone. Dissection was then performed on each side of the proximal phalanx. The sheath of the flexor tendons was located, and the long

flexor was then isolated, drawn out using a blunt hook, and divided near its distal insertion. It was then sutured end to end to the extensor tendon.

Coughlin [18], [19] performed an FDL tendon transfer by first making a transverse incision at the MTP joint, and then a second incision at the dorsal aspect of the digit. Kuwada [20] performed 81 procedures to transfer the FDL tendon via a dorsolateral incision along the digit beginning proximally at the MTP joint and extending distally to least the proximal PIP joint. Thompson and Deland [21] performed transfer of the FDL tendon in 13 digits following the indications of Coughlin [18] via the plantar and dorsal approach. Gazdag and Cracchiolo [22] in 11 feet performed an isolating tendon transfer of the FDL through the 2-cm longitudinal midline incision on the plantar side of the base of the proximal phalanx and performed another dorsal incision at the base of the proximal phalanx. Recently, Boyer and DeOrio [23] treated 70 toes with fixed or flexible hammer toes with a flexor-to-extensor tendon transfer making a longitudinal incision on the plantar aspect of the proximal phalanx and at the dorsal aspect of the toe.

The literature up to now reveals no attempts to discover why Parrish [11] found FDB tendon transfer to be a non-viable option. His findings, however, have been accepted by the scientific community without confirmation or challenge. Furthermore, many of the authors cited, except Barbari and Brevig, [9] performed the double plantar and dorsal incision approach as described by Girdlestone in 1947. [13]

In a cadaveric study we found [14] that it is possible to correct flexible claw and hammer toe deformity by transposing the FDB tendon to the extensor, or dorsal, area of the base of the proximal phalanx. This is a modification of the procedure used by Parrish [11] using a plantar and dorsal incision approach of the digit. We sought to transfer the FDB tendon to the dorsal aspect of the proximal phalanx via the dorsal approach through a unique incision, as described by Barbari and Brevig. [9] A search of the indexed literature found no previous reports of this procedure.

It is possible anatomical variations in the insertion of the FDB tendon may prohibit the popularity of this transfer approach. Three variations have been described: 1) absence of the tendon; 2) absence of the lateral and medial tendinous fascicles but presence of a single tendon running parallel to the FDL tendon; and 3) fusion of the FDB tendon to the FDL tendon. [24]-[27] LeDouble [24] and Nathan and Gloobe [25] found the FDB tendon to be absent in the fifth toe in 21.5% of cases. Testut [27] found the FDB tendon to be absent in the fourth and fifth toes in 3% of the dissections performed. In two separate studies [26], [27] Testut found that the FDB medial and lateral fascicles are not divided. Rather, the fascicles run parallel to the FDL tendon before inserting into a side of the intermediate phalanx of the fifth or fourth toe in 5% of patients. Although Testut [26], [27] did not specify individual percentages for variability in attachment for each of these digits, he established that the FDB tendon of the fifth toe is fused to the FDL tendon in 2% of cases. Thus, the anatomical variations found occur more frequently in the FDB tendon insertion of the fifth toe.

Anomalies or variations in the insertion of the FDB tendon in the third and second toes have not, however, been described. We reported [14] on transposition of the FDB tendon via the

plantar approach in 180 digits of cadaveric feet, including 45 second digits, 45 third digits, 45 fourth digits, and 45 fifth digits. We found no cases of variation in the insertion of the FDB tendon in the second, third, or fourth digits, and the FDB tendon was present in all 45 cases. There was variability in FDB tendon presentation in the fifth digit, including FDB tendon absence in 3 of 45 digits (7%), which is a recognized anatomical variation. Thus, we performed the dorsal FDL tendon transfer via the dorsal approach between the FDB hemitendons in only the second and third digits.

Another potential factor prohibiting the tendon transfer approach described in this study may be inadequate space for FDL passage through the FDB hemitendons. After arthroplasty the tendon sheath is exposed and opened longitudinally, and the hemitendons of the FDB are identified just over the FDL tendon. Once the hemitendons are identified they are carefully separated (Fig. 4). If there is not adequate room for FDL passage, the FDB hemitendons must be incised longitudinally (Fig. 5). We believe this additional surgical step is the primary challenge associated with this technique, and may potentially explain why this technique has not previously been described.

Available FDL tendon length may also impact the surgical approach. Once the FDL tendon is detached distally from the distal phalanx, it must be long enough to be transposed to the dorsal aspect of the proximal phalanx. When the MTP joint is rigidly dorsiflexed, it is necessary to perform a dorsal capsulotomy and MTP joint release as described by Barbari and Brevig, [9] thus relocating the proximal phalanx to its anatomical position. With this approach there is no need for plantar capsulotomies of the interphalangeal joints.

If there is difficulty in transferring the distal stumps of the longitudinally split FDL tendon to the dorsal aspect of the proximal phalanx of any digit, the clinician must cut the proximal flexor tendon sheath longitudinally for better FDL tendon exposure. We were able to transfer the FDL tendon via dorsal approach between the FDB hemitendons in 100% of second and third digits via a unique single longitudinal incision. We did find it difficult, however, to transfer the FDL "around" the lateral aspects of the FDB hemitendons. This transfer was unsuccessful in 83 (69,16%; N = 120) digits, including 45 (37,5%) second digits and 38 (31,66%) of the third digits. We believe this was a consequence of inadequate proximal tendon sheath dissection. When attempting transfer of the split FDL tendon lateral to the FDB hemitendons, it is difficult to obtain adequate proximal exposure secondary to the depth of the anatomical structures. A mini-osteotome may be used to release the FDL tendon from the plantar aspect of the distal middle phalanx to obtain more tendon and facilitate the transfer.

While passing the split FDL tendons between the hemitendons of the FDB is necessary to cut the flexor tendon sheath.

We also encountered difficulty in transposing the FDL tendon as a consequence of the transverse aponeurotic fibers originating from the EDL tendon. These fibers surround the MTP joint capsule and join in the plantar area with the glenoid plate, the deep MTP ligament, and the sheath of the flexor tendons to insert distally into the plantar base of the proximal phalanx. These aponeurotic fibers and the sheath of the flexor tendons must be cut to allow the split FDL tendon to be repositioned and sutured to the dorsal aspect of the proximal phalanx.

A final challenge associated with this novel surgical approach is ankle positioning while suturing FDL tendon stumps. If the ankle is in plantarflexion the tendon has adequate length to permit suturing to the dorsal aspect of the proximal phalanx without difficulty. When the patient is weight-bearing or walking, however, the ankle is in dorsiflexion, which shortens the FDL tendon and forces the MTP joint into plantarflexion. The FDL tendon should therefore be sutured in its anatomical position to avoid inappropriate flexion or extension positioning of any involved joint.

5. Conclusions

Transfer of the FDL tendon to the dorsum of the proximal phalanx can be performed for the correction of claw and hammer toe deformities in the second and third digits. The meticulous longitudinal incision of the flexor tendon sheath to expose the FDB tendon and its longitudinal incision are essential to the success of the procedure. Furthermore, this approach preserves the integrity of the primary plantar blood supply to the digits of interest.

Author details

Ricardo Becerro de Bengoa Vallejo^{1*}, Marta Elena Losa Iglesias² and Miguel Fuentes Rodriguez¹

*Address all correspondence to: ibebeva@enf.ucm.es

1 Escuela Universitaria de Enfermería, Fisioterapia y Podología, Universidad Complutense de Madrid, Madrid, Spain

2 Facultad de Ciencias de la Salud, Universidad Rey Juan Carlos, Madrid, Spain

References

- [1] Coughlin, M. J. Lesser-toe abnormalities. *J Bone Joint Surg Am* (2002). , 84, 1446-1469.
- [2] Sandeman, J. C. The role of soft tissue correction of claw toes. *Br J Clin Pract* (1967). , 21, 489-93.
- [3] Coughlin, M. J, & Mann, R. A. Lesser Toe Deformities. In: MJ Coughlin, RA Mann *Surgery of the Foot and Ankle*, 7th ed. Mosby, St Louis; (1999). , 328.
- [4] Richardson, E. G. Lesser Toe Abnormalities. In: AH Crenshaw. *Campbell's Operative Orthopaedics*, 8th ed. Mosby-Year Book, St Louis; (1992). , 99.

- [5] Scheck, M. Etiology of acquired hammertoe deformity. *Clin Orthop.* (1977). , 123, 63-9.
- [6] Engle, E. T, & Morton, D. J. Notes on foot disorders among natives of the Belgian Congo. *J Bone Joint Surg.* (1931).
- [7] Lutter, L. D. Toe Deformities. In: *Atlas of Adult Foot and Ankle Surgery*, Mosby-Year Book, St Louis; (1997). , 74.
- [8] Cyphers, S. M, & Feiwell, E. Review of the Girdlestone-Taylor procedure for clawtoes in myelodysplasia. *Foot Ankle.* (1988). , 8, 229-33.
- [9] Barbari, S. G, & Brevig, K. Correction of clawtoes by the Girdlestone-Taylor flexor-extensor transfer procedure. *Foot Ankle.* (1984). , 5, 67-73.
- [10] Newman, R. J, & Fitton, J. M. An evaluation of operative procedures in the treatment of hammertoe. *Acta Orthop Scand.* (1979). , 50, 709-12.
- [11] Parrish TF: Dynamic correction of clawtoes *Orthop Clin North Am.* (1973). , 4, 97-102.
- [12] Pyper, J. B. The flexor-extensor transplant operation for claw toes. *J Bone Joint Surg Br.* (1958). , 40, 528-33.
- [13] Taylor, R. G. The treatment of claw toes by multiple transfers of flexor into extensor tendons. *J Bone Joint Surg Br.* (1951). , 33, 539-42.
- [14] Becerro de Bengoa Vallejo R, Viejo Tirado F, Prados Frutos JC, Losa Iglesias ME, Jules KT. Transfer of the flexor digitorum brevis tendon. *JAPMA.* (2008). , 98, 27-35.
- [15] Sarrafian, S. K. *Anatomy of the Foot and Ankle.* JB Lippincott, Philadelphia, (1983). , 243.
- [16] Sgarlato, T. E. Transplantation of the flexor digitorum longus muscle tendon in hammertoes. *JAPA.* (1970). , 60, 383-8.
- [17] Marcinko, D. E, Lazerson, A, Dollard, M. D, et al. Flexor digitorum longus tendon transfer: a simplified technique. *JAPA.* (1984). , 74, 380-5.
- [18] Coughlin, M. J. Crossover second toe deformity. *Foot Ankle.* (1987). , 8, 29-39.
- [19] Coughlin, M. J. Subluxation and dislocation of the second metatarsophalangeal joint. *Orthop Clin North Am.* (1989). , 20, 535-51.
- [20] Kuwada, G. T. A retrospective analysis of modification of the flexor tendon transfer for correction of hammer toe. *J Foot Surg.* (1988). , 27, 57-9.
- [21] Thompson, F. M, & Deland, J. T. Flexor tendon transfer for metatarsophalangeal instability of the second toe. *Foot Ankle.* (1993). , 14, 385-8.
- [22] Gazdag, A, & Cracchiolo, A. Surgical treatment of patients with painful instability of the second metatarsophalangeal joint. *Foot Ankle Int.* (1998). , 19, 137-43.

- [23] Boyer, M. L, & Deorio, J. K. Transfer of the flexor digitorum longus for the correction of lesser-toe deformities. *Foot Ankle Int.* (2007). , 28, 422-30.
- [24] LeDouble AF *Traité des variations du système musculaire del l'homme et de leur signification au point de vue de l'anthropologie et zoologique*, Schleicher Frères, Paris, (1897). , 2, 327.
- [25] Nathan, H, & Gloobe, H. Flexor digitorum brevis: anatomical variations. *Anat Anz.* (1974). , 135, 295-301.
- [26] Testut, L. *Les anomalies musculaires chez l'homme expliquées par l'anatomie comparée: Leur importance en anthropologie*. Masson, Paris, (1884). , 588.
- [27] Testut, L. *Les anomalies musculaires considérées du point de vue de la ligature des artères*. Doin, Paris, (1892). , 38-40.
- [28] Thompson, F. M, & Deland, J. T. Flexor tendon transfer for metatarsophalangeal instability of the second toe. *Foot Ankle.* (1993).
- [29] Gazdag, A, & Cracchiolo, A. Surgical treatment of patients with painful instability of the second metatarsophalangeal joint. *Foot Ankle Int.* (1998).
- [30] Coughlin, M. J. Second metatarsophalangeal joint instability in the athlete. *Foot Ankle Int.* (1993).
- [31] Kuwada, G. T. A retrospective analysis of modification of the flexor tendon transfer for correction of hammertoe. *J Foot Surg.* (1988).
- [32] Coughlin, M. J. Subluxation and dislocation of the second metatarsophalangeal joint. *Orthop Clin North Am.* (1989).
- [33] Thompson, F. M, & Deland, J. T. Flexor tendon transfer for metatarsophalangeal instability of the second toe. *Foot Ankle Int.* (1993). , 14, 385-8.
- [34] Mendicino, R. W, Statler, T. K, Saltrick, K. R, & Catanzariti, A. R. Predislocation syndrome: a review and analysis of eight patients. *J Foot Ankle Surg.* (2001). , 40, 214-24.
- [35] Myerson, M. S, & Jung, H. G. The role of toe flexor-to-extensor transfer in correcting metatarsophalangeal joint instability of the second toe. *Foot Ankle Int.* (2005). , 29, 675-9.
- [36] Bouché, R. T, & Heit, E. J. Combined plantar plate and hammertoe repair with flexor digitorum longus tendon transfer for chronic, severe sagittal plane instability of the lesser metatarsophalangeal joints: preliminary observations. *J Foot Ankle Surg.* (2008). , 47, 125-37.
- [37] Chen, Y. G, Cook, P. A, McClinton, M. A, et al. Microarterial anatomy of the lesser toe proximal interphalangeal joints. *J Hand Surg [Am].* (1998). , 23, 256-60.
- [38] May JW Jr, Chait LA, Cohen BE, O'Brien BM. Free neurovascular flap from the first web space of the foot in hand reconstruction. *J Hand Surg.* (1977). , 2, 387-93.
- [39] Murakami T: On the position and course of the deep plantar arteries with special reference to the so-called plantar metatarsal arteries. *Okajimas Folia Anat Jpn.* (1971). , 48, 295-322.

