

We are IntechOpen, the world's leading publisher of Open Access books Built by scientists, for scientists

4,800

Open access books available

122,000

International authors and editors

135M

Downloads

Our authors are among the

154

Countries delivered to

TOP 1%

most cited scientists

12.2%

Contributors from top 500 universities



WEB OF SCIENCE™

Selection of our books indexed in the Book Citation Index
in Web of Science™ Core Collection (BKCI)

Interested in publishing with us?
Contact book.department@intechopen.com

Numbers displayed above are based on latest data collected.

For more information visit www.intechopen.com



Role of Fatty Acid Imaging with ^{123}I - β -methyl-p- ^{123}I -Iodophenyl-Pentadecanoic Acid (^{123}I -BMIPP) in Ischemic Heart Diseases

Junichi Taki, Ichiro Matsunari, Hiroshi Wakabayashi,
Anri Inaki and Seigo Kinuya

Additional information is available at the end of the chapter

<http://dx.doi.org/10.5772/53548>

1. Introduction

In nuclear cardiology, myocardial perfusion imaging has been widely and thoroughly investigated and used in various heart diseases, especially in ischemic heart diseases. However, beyond perfusion imaging, myocardial fatty acid metabolic imaging may yield valuable insight into the pathologic process of various heart diseases including ischemic heart diseases, cardiomyopathy, and diabetic heart etc [1, 2].

To run the contractile machinery and ion pumps to maintain rhythmic beating and integrity of the myocardium, the healthy heart derives its energy from a variety of oxidizable substrates such as fatty acids, glucose, lactate, amino acids etc. Approximately two-thirds or more of the total energy produced by myocardium is derived from fatty acid oxidation and the most of the remaining energy is covered by the glucose metabolism. Both fatty acid and glucose are catabolized to acetyl-COA through beta-oxidation and glycolysis and the metabolite is oxidized in the tricarboxylic acid (TCA) cycle (Fig 1). To respond the constantly changing environmental conditions and energy demands, the heart maintains the balance between its energetic supply and demands by shifting fluxes through existing various metabolic pathways. Short-term modulation of substrate switching is based on an effective interplay between various substrates, with metabolism of one substrate automatically suppressing the pathway of another substrate via rapid enzymatic changes. In the postprandial and under resting conditions, long-chain fatty acids are the predominant energy substrate for adult heart. On the other hand, during exercise or stress, predominant energy source shifts to carbohydrate [3] because the efficiency of glucose as substrate exceeds the

efficiency of fatty acids as substrate by as much as 40% [4]. In ischemia, oxidative metabolism of free fatty acid is decreased because β -oxidation of fatty acid in mitochondria requires a large amount of oxygen, and glucose becomes the preferred substrate for anaerobic glycolysis that requires less oxygen consumption [5,6]. This metabolic switch from predominant fatty acid use to predominant glucose use seems crucial in preserving myocardial viability. (Fig 2) Therefore, different imaging tracers that permit direct assessment of myocardial metabolism are desired to evaluate the pathophysiological changes in various heart disease. Current available tracers for metabolic imaging are several fatty acid tracers, ^{18}F -FDG for the evaluation of glucose metabolism, and ^{11}C -acetate for the assessment of oxygen consumption. Of these tracers, only ^{123}I -labeled fatty acid tracers are currently available for SPECT imaging. In this chapter, basic characteristics and clinical value of ^{123}I -labeled fatty acid agents, especially β -methyl-p- ^{123}I -iodophenyl-pentadecanoic acid (BMIPP) follows.

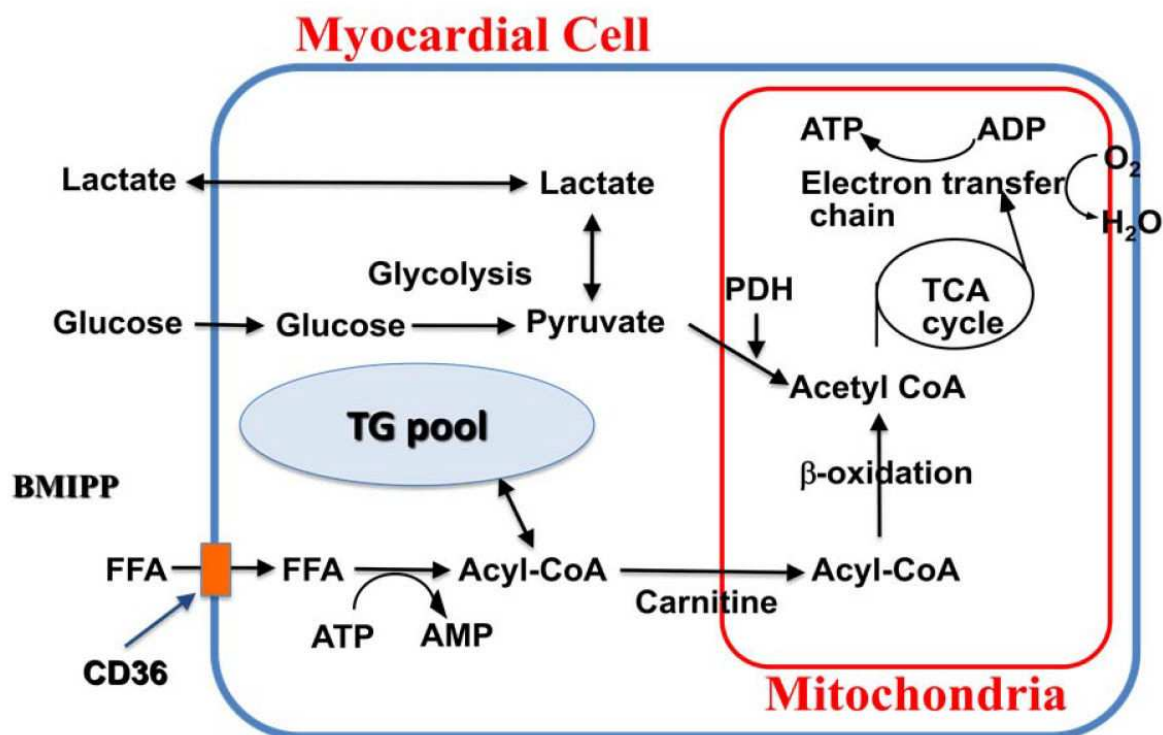


Figure 1. Schematic presentation of substrate metabolism in myocardium. ADP = adenosine diphosphate, AMP = adenosine monophosphate, ATP = adenosine triphosphate, BMIPP = β -methyl-iodophenyl-pentadecanoic acid, CoA = coenzyme A, FFA = free fatty acid, PDH = pyruvate dehydrogenase, TCA = tricarboxylic acid, TG = triglyceride

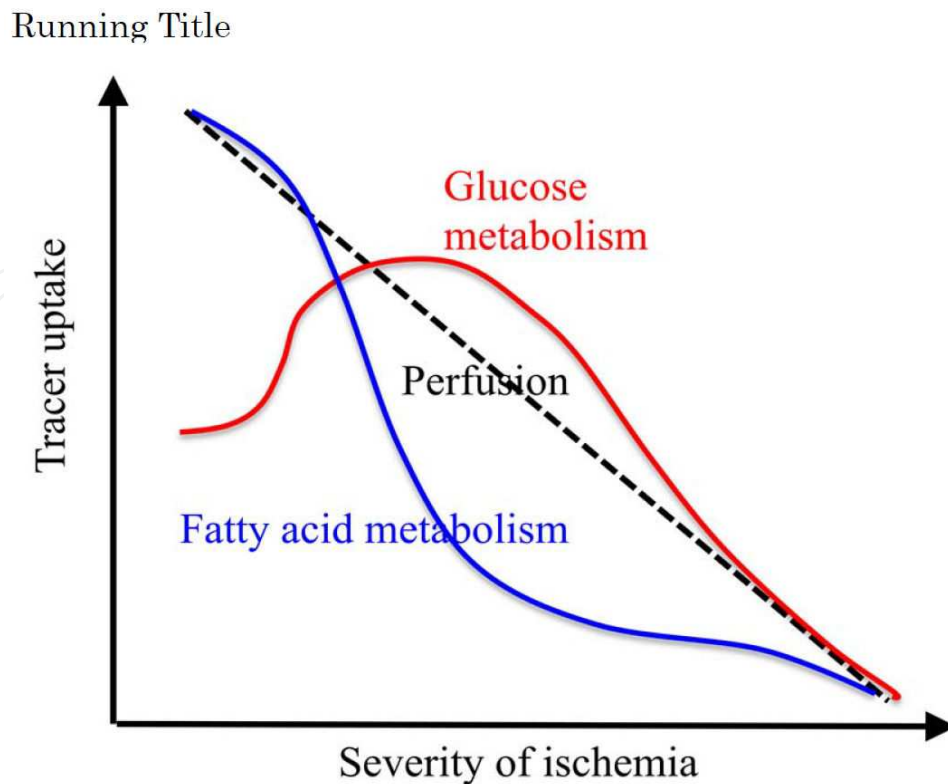


Figure 2. Relation between myocardial perfusion and fatty acid and glucose metabolism.

When myocardial perfusion decreases, fatty acid metabolism can not be maintained because β -oxidation of fatty acid in mitochondria requires a large amount of oxygen, and glucose becomes the preferred substrate for anaerobic glycolysis that requires less oxygen consumption. Therefore, the decrease in tracer uptake for fatty acid substrate analogue such as BMIPP becomes more prominent than the decrease of perfusion tracer. On the contrary, anaerobic glucose metabolism relatively increases, presenting increased or preserved FDG uptake in the area with reduced perfusion. When myocardial perfusion decreases further, glucose anaerobic metabolism also declines finally and myocardial viability will be lost eventually.

2. Myocardial fatty acid metabolism

Although the primary sources of energy are lactate and glucose for fetal heart, fatty acids comprise 60% to 80% of the energy source in adult heart to run the contractile machinery and ion pumps to maintain rhythmic beating and integrity of the myocardium [7].

Due to hydrophobic nature of fatty acids, they are delivered to the heart by binding to plasma albumin or lipoproteins. After dissociating from albumin or lipoprotein, fatty acids can pass through the sarcolemmal membrane by diffusion or a facilitated transport mechanism. The fatty acid translocase CD36 was suggested that it accounts for the key

uptake mechanism of long-chain fatty acid through the analysis of minority of patients with absent uptake of ^{123}I -BMIPP (15-(p-iodophenyl)-3(R, S)-methylpentadecanoic acid) even without significant cardiac abnormality [8,9]. The patients with deficient myocardial uptake of BMIPP has been proved to correspond to the patients with type I CD36 deficiency (neither platelets nor monocytes express CD36) [10-12] and biopsy specimen from the patients with absent myocardial BMIPP uptake and type I CD36 deficiency demonstrated no expression of CD36 on the myocardial capillary endothelial cells [13]. These patients without BMIPP cardiac uptake showed compensatory increased FDG uptake [14,15] and several gene abnormalities related to CD36 deficiency have been reported [16,17]. Based on these clinical data and other animal experiments, it has been proved that CD36 plays a crucial role in fatty acid transport into the cells [18].

Once the fatty acid is taken up by the myocyte, it undergoes adenosine triphosphate (ATP) dependent conversion to acyl-CoAs and are consequently trapped inside the cell. Then the acyl-CoAs are taken up by mitochondria via an acyl carnitine carrier system and is rapidly catabolized by β -oxidation into 2-carbon fragments, acetyl-CoAs, which enter the TCA cycle for further oxidation to become water and carbon dioxide. (Fig 1) The half-life of β -oxidation is fast and in the order of minutes, but is dependent on the adequate oxygen availability. The remainder of the total fatty acid entering the myocyte is incorporated into the lipid pool, mainly in the form of triglycerides and phospholipids, or into myocardial structural lipids and presents in the myocardium for a long time. Turnover in the lipid pool is much slower with the half-life of the order of hours.

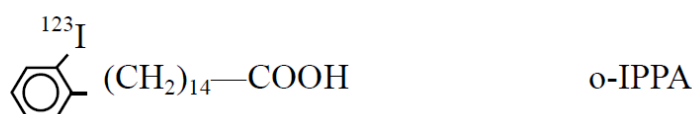
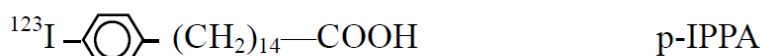
3. Tracers for fatty acid imaging for SPECT (Fig 3)

In mid 1970's, several iodinated long chain fatty acids were developed by introducing radioiodine to the terminal position of fatty acids without altering extraction efficiency compared with the natural compound [19-21]. These straight chain fatty acids, ^{123}I -hexadecanoic acid (IHXA) and ^{123}I -heptadecanoic acid (IHDA) were proved to be an indicator of myocardial perfusion in canine model and human [20,21]. After rapid initial myocardial extraction these tracers showed biexponential clearance similar to that of ^{11}C -palmitate with rapid and slow components, those were thought to represent β -oxidation of fatty acids and fatty acids storage in lipid pool, respectively. However, a canine study suggested that washout rate of radioactivity from the heart reflected the back diffusion of deiodinated free iodine not by β -oxidation [20]. A clinical study with IHDA demonstrated high image quality early after injection but it deteriorated rapidly because of rapid reduction of myocardial counts and increase in background counts by deiodinated radioiodine [23]. Accordingly, these characteristics of the tracers make IHDA and IHXA unattractive for clinical use, especially for SPECT study.

To overcome the problem of these alkyl fatty acids, the phenyl fatty acid was developed by attaching iodide to the para position of phenyl ring (IPPA) [24]. Because this agent demonstrates high myocardial uptake without essential release of free radioiodide into circulation,

the image quality is excellent. Animal experiment demonstrated that the IPPA accumulated rapidly to myocardium followed by a two-component tracer clearance similar to ^{14}C -palmitate, permitting estimation of metabolic rate [25]. The uptake of IPPA during exercise is related to myocardial perfusion and its catabolism follows the usual metabolic pathway for β -oxidation [26]. Through β -oxidation IPPA is metabolized to iodobenzoic acid and its metabolite iodohippurate, and these are rapidly excreted from the kidneys with the iodine still attached, resulting in high image quality with low background by preventing the build-up of free radioiodide [27]. Coronary occlusion and reperfusion blunted the uptake of IPPA and prolonged the clearance, but permanent coronary occlusion decreased the uptake significantly and accelerated the clearance, indicating that the IPPA can be used to localize the area of myocardial ischemia and infarction [28]. However, still relatively fast rate of metabolism and clearance of IPPA precludes the clinical SPECT imaging, even in a rotating multi-detector SPECT system. For initial IPPA uptake imaging, acquisition time should be shortened to prevent progressive undersampling due to rapid count decrease from the myocardium, resulting in the deterioration of image quality, and dynamic SPECT study may be necessary for kinetic analysis of β -oxidation. For this purpose, dynamic SPECT with cadmium zinc-telluride (CZT) multi-detector might be the choice of data acquisition and analysis because of its high sensitivity [29].

Straight chain fatty acids



Branched fatty acids

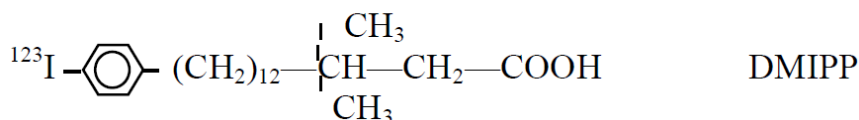
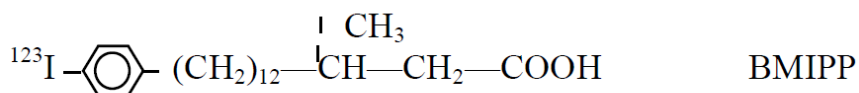


Figure 3. Iodinated fatty acids analogues for SPECT. BMIPP = β -methyl-iodophenyl pentadecanoic acid, DMIPP = di-methyl-iodophenyl pentadecanoic acid, IHDA = ^{123}I -heptadecanoic acid, IHXA = ^{123}I -hexadecanoic acid, IPPA = iodophenyl pentadecanoic acid,

Accordingly, a new fatty acid tracer with more prolonged cardiac retention has been developed to improve quantitative image quality. For this purpose methyl branching was introduced at β -carbon position to slow myocardial clearance by inhibiting β -oxidation. Two forms of iodine labeled modified fatty acids, 15-(*p*-iodophenyl)-3-*R*, 5-methylpentadecanoic acid (BMIPP) and 15-(*p*-iodophenyl)-3,3-dimethylpentadecanoic acid (DMIPP), has been developed [30,31]. In fasted rats, myocardial half-time of BMIPP and DMIPP are far longer, at 30-45 min and 6-7 hr, respectively, than that of IPPA (5-10 min) [31]. In human, DMIPP showed higher liver uptake than that of BMIPP (heart/liver ratio was 0.39 ± 0.05 and 1.00 ± 0.12 , respectively; $p < 0.001$), suggesting that BMIPP is more favorable cardiac SPECT agent [32]. Especially in Japan and some European countries, BMIPP has since been widely studied to investigate the clinical significance and basic properties. In Japan, ^{123}I -BMIPP has been used in daily clinical practice for nearly 2 decades since 1993.

4. Myocardial kinetic of ^{123}I -BMIPP (Fig 4)

After intravenous injection of ^{123}I -BMIPP, the tracer is delivered to myocardium depending on the regional flow and transported into myocardial cells via fatty acid translocase/CD36 involvement [10,11,13,16-18]. Once BMIPP is taken up by the myocyte, it will either back-diffuse to the plasma, accumulate in the lipid pool or undergo limited alpha and beta oxidation. Most of the BMIPP in the cytoplasm undergoes ATP dependent conversion to BMIPP-CoA and incorporated into triglyceride pool [31,33]. Canine study demonstrated that high first pass extraction (74%) within 30 sec of intracoronary BMIPP infusion, followed by a small fraction of washout (8.7% of infused BMIPP) for the next 30 min [34]. The washed out radioactivity consist of backdiffused BMIPP (24% of all washed out radioactivity), α oxidation metabolite (27%), intermediate metabolites (33%), and full metabolite (16%), suggesting only small amount of BMIPP-CoA transported into mitochondria is metabolized by α oxidation (because first β oxidation is blocked by β -methyl branching), followed by β oxidation. The high uptake and low washout of the tracer indicates that BMIPP can be substantially considered as a metabolically trapped tracer like FDG.

Thirty minutes coronary occlusion and reperfusion was found to increase early back diffusion of nonmetabolized BMIPP from 25.1% to 34.7%, and in mild ischemia with 10 minutes occlusion, back diffusion of BMIPP was closely correlated with lactate production (marker of ischemic severity) [35]. Pharmacological intervention with etomoxir, one of the carnitine palmitoyltransferase I inhibitor that inhibits the transport of long chain lipids into the mitochondria, enhanced early washout of radioactivity until 8 minutes after injection due to increased back diffusion of BMIPP [36]. Dynamic SPECT in patients with coronary artery disease demonstrated that the BMIPP washout was observed early after BMIPP injection (2-6 min after injection) in the segments with stress induced thallium defects but not in the segments with normal thallium uptake and fixed thallium defects [37]. In patients with acute coronary syndrome, early dynamic BMIPP SPECT showed similar

BMIPP and thallium uptake, whereas conventional BMIPP images at 30 min demonstrated the discordant BMIPP uptake less than thallium [38]. These findings suggest that, in ischemic myocardium, initial myocardial distribution of BMIPP may represent blood flow, followed by back diffusion of free BMIPP which is not incorporated into triglyceride pool after conversion to BMIPP-CoA, resulting in discordant BMIPP uptake less than thallium on static images obtained 20-30 min after BMIPP injection.

In the first step of the common pathway of fatty acid metabolism, BMIPP also underwent ATP dependent conversion to BMIPP-CoA. Once BMIPP-CoA is synthesized, it is hardly back-diffused out of the cell and is retained within it [39,40]. Therefore, BMIPP myocardial retention may relate to the ATP level of the cells. Both in mouse myocardium treated with an electron transport uncoupler, dinitrophenol, which reduced intracellular ATP level without affecting acyl-CoA synthetase activity or CoA level, and in acutely damaged canine myocardium by coronary occlusion and reperfusion, BMIPP uptake was found to correlate with the tissue ATP levels [41,42]. Therefore, myocardial BMIPP uptake most likely reflects activation of BMIPP by CoA and indirectly reflects cellular ATP production resulting from fatty acid metabolism.

During acute phase of ischemia, reduced availability of oxygen suppresses β -oxidation and increases the proportion of fatty acid in the triglyceride pool. At this moment BMIPP may enter into this enlarged triglyceride pool. Accordingly, BMIPP uptake may possibly be increased in acute ischemia. Canine experiments with occlusion and reperfusion model showed higher BMIPP uptake than thallium (reverse mismatch) which is an opposite finding observed in clinical studies [43,44]. However, BMIPP uptake may change as a function of time after ischemia. A rat study with 20 min coronary occlusion and reperfusion demonstrated higher BMIPP uptake than thallium at 1 day after reperfusion but showed similar to or lower than thallium uptake at 5 day after reperfusion [45]. Another rat study with 20 min coronary occlusion and reperfusion revealed that increased BMIPP uptake in area at risk at 20 min and 1 day after reperfusion, followed by reduction of uptake at 3 to 7 days, though, recovered to normal level at 30 days after reperfusion [46]. By contrast, thallium uptake did not change throughout the 30 days observation period. As a result, higher BMIPP uptake than thallium in acute phase was inverted in subacute phase (discordant or mismatch BMIPP uptake less than thallium) and recovered to the similar uptake to that of thallium. After a transient ischemic insult, recovery of myocardial perfusion, metabolism and function may be temporally different. Although, delayed recovery of function after transient ischemia is well documented in the experimental and clinical setting as stunned myocardium, delayed recovery of regional metabolism or *metabolic stunning* which provide imprint prior ischemic event has been recognized recently. This delayed recovery of metabolism after quick recovery of perfusion provides a concept of *ischemic memory* imaging [47-50]. Thus BMIPP imaging during or after an episode of myocardial ischemia might provide crucial insights into pathophysiology of coronary artery disease over perfusion imaging.

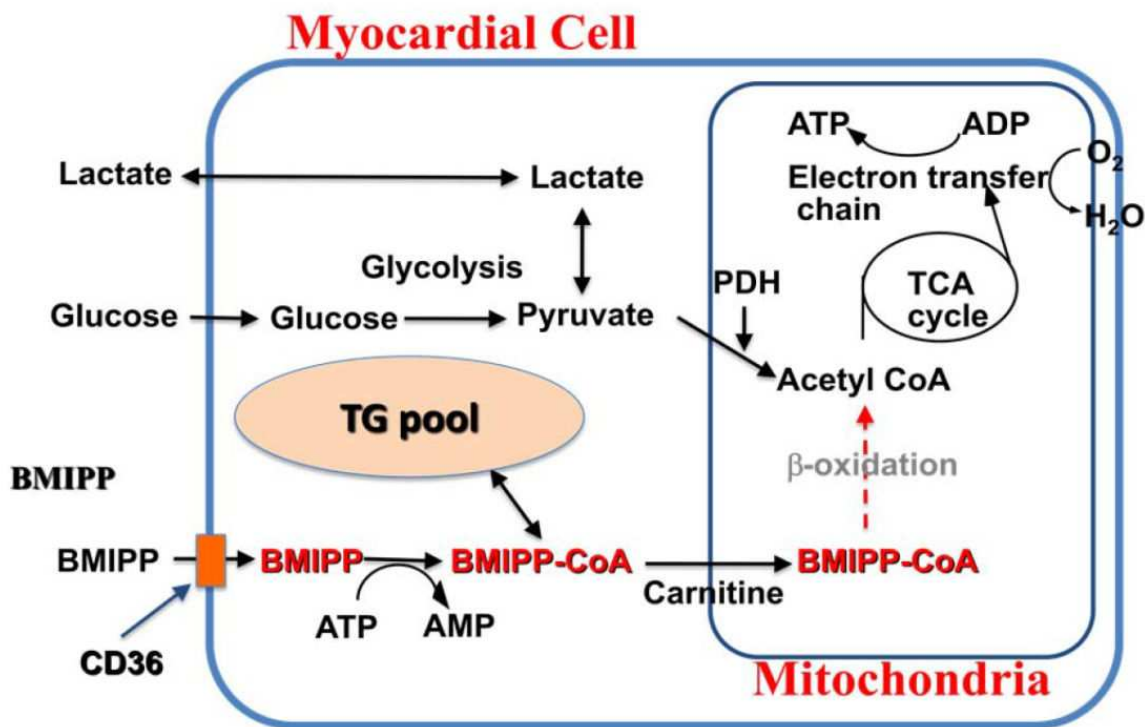


Figure 4. Schematic presentation of ^{123}I -BMIPP metabolism in myocardium. Abbreviations: see Figure 1.

5. ^{123}I -BMIPP imaging in ischemic heart diseases

5.1. Acute myocardial infarction

Discrepant BMIPP uptake less than thallium has been reported initially in 17 out of 28 patients with acute myocardial infarction. Such discordant BMIPP uptake was observed more often in areas of acute than chronic phase of myocardial infarction (59% at <4 week versus 31% at >4 week after onset), and more often in areas supplied with revascularized than non-revascularized arteries (74% versus 28%, respectively). In addition, regional wall motion was more severely impaired in such perfusion-metabolic mismatching area [51]. In patients with acute myocardial infarction, BMIPP and $^{99\text{m}}\text{Tc}$ -MIBI SPECT at 4 to 10 days after thrombolysis demonstrated that the segments with more reduced BMIPP uptake than MIBI uptake (mismatching) showed either normal wall motion or demonstrated inotropic reserve during dobutamine stimulation [52]. In addition, several studies had demonstrated that areas of discordant BMIPP uptake less than perfusion tracers in acute or subacute stages of myocardial infarction showed improvement of wall motion abnormality on the subsequent follow-up periods [47,53-59]. These findings suggested that mismatch or discordant BMIPP uptake less than perfusion is indicative of jeopardized but viable myocardium and may correspond to stunned myocardium where functional abnormality is prolonged in association with sustained metabolic abnormalities (metabolically stunned myocardium) after perfusion recovery by successful reperfusion

procedures. Accordingly, the finding of mismatched BMIPP uptake less than perfusion tracers may be a predictor of functional recovery in acute myocardial infarction. For the evaluation of area at risk in acute myocardial infarction, BMIPP imaging in subacute phase is valuable. BMIPP defect size in subacute phase of myocardial infarction correlated well with the risk area revealed by contrast ventriculography or echocardiography [47,60], and the area with BMIPP reduction 1 week after the onset of myocardial infarction corresponded well to the area with perfusion defect which was demonstrated before revascularization therapy at admission [61]. These observations holds the concept of “*ischemic memory imaging*” because BMIPP imaging obtained in subacute phase of myocardial infarction reflects prior ischemic damage or metabolically stunned myocardium even after the restoration of perfusion abnormality [47-49]. Therefore, BMIPP imaging may contribute to improving the detection of culprit lesion of the small amount of acute myocardial infarction. In patients with non ST elevated and non serum creatinine kinase-MB elevated but increased cTnT level, BMIPP SPECT at subacute phase can detect culprit coronary lesions more sensitively than thallium [62].

Mismatched uptake of BMIPP less than thallium is not also an uncommon finding in chronic phase of myocardial infarction. In 26 patients with prior myocardial infarction (>4 week after onset) without revascularization therapy, resting BMIPP and exercise-redistribution thallium scintigraphies were studied. Sixty-seven % of the segments with discordant BMIPP uptake less than redistribution thallium showed reversible thallium defects, 21% showed fixed thallium defects and 12% showed normal thallium uptake, indicating that the myocardium with discordant BMIPP uptake less than redistribution thallium uptake were mostly exposed to stress induced ischemia [37]. In subacute to chronic phase of infarction (>2 week after onset), similar findings were reported, with most of the mismatched segments (22/27) is associated with reversible thallium defect [63].

5.2. Acute coronary syndrome and unstable angina pectoris

Because oxygen extraction by the myocardium is nearly complete, reduction of coronary flow against the myocardial oxygen demand evoke the metabolic switch from fatty acid oxidation to anaerobic glucose metabolism. Thus the BMIPP uptake might be suppressed in ischemia. In a study of 111 consecutive patients with acute chest pain without myocardial infarction, BMIPP SPECT at 2 days after the onset of chest pain showed regional abnormality in 74% of coronary abnormalities, while only 38% showed perfusion abnormality demonstrated by tetrofosmin within 24 hr after the onset of chest pain [64]. Recently, multicenter trial to evaluate the performance of BMIPP to detect acute coronary syndromes in emergency department patients with chest pain was conducted in a total of 507 patients without history of prior myocardial infarction [65]. BMIPP imaging was performed within 30 hours of symptom cessation. Sensitivity of detecting acute coronary syndrome increased from 43% in clinical diagnosis to 73% in BMIPP imaging alone. Both negative and positive predictive values of a clinical diagnosis alone increased significantly when combined BMIPP imaging from 62% to 83% and 41% to 58%, respectively.

These findings indicate that BMIPP imaging can detect prolonged metabolic abnormality or stunning in patients with acute chest pain up to 2 days after cessation of symptom.

In patients with unstable angina, discordant BMIPP uptake less than thallium has also been observed frequently [66-69]. In patients with unstable angina without prior myocardial infarction, comparison of BMIPP image and stress thallium scan performed after stabilization of their condition demonstrated that BMIPP decrease was associated with stress perfusion abnormality in 44 of 57 (77%) segments and degree of BMIPP reduction correlated with the degree of perfusion abnormality at stress, degree of wall motion abnormality, and severity of coronary artery stenosis [66]. In another study in patients with unstable angina after medication and elimination of chest pain disclosed that patients with abnormal BMIPP uptake had more severe coronary artery stenosis and more collateral opacification than patients without BMIPP abnormality. In addition, revascularization was performed in 82% of patients with abnormal BMIPP images, while in only 22% of patients with normal BMIPP images, accordingly, BMIPP imaging may be helpful in decision-making regarding interventional treatment [68]. These findings indicate that reduced BMIPP uptake in patients with unstable angina may represent persistent metabolic abnormality reflecting prior severe ischemia or repetitive ischemic insults, thus the concept of ischemic memory imaging could be extended and applied to these patients population. In other words, BMIPP imaging could extend time window for detecting previous ischemic event after the resolution of perfusion abnormality.

5.3. Chronic stable coronary artery disease

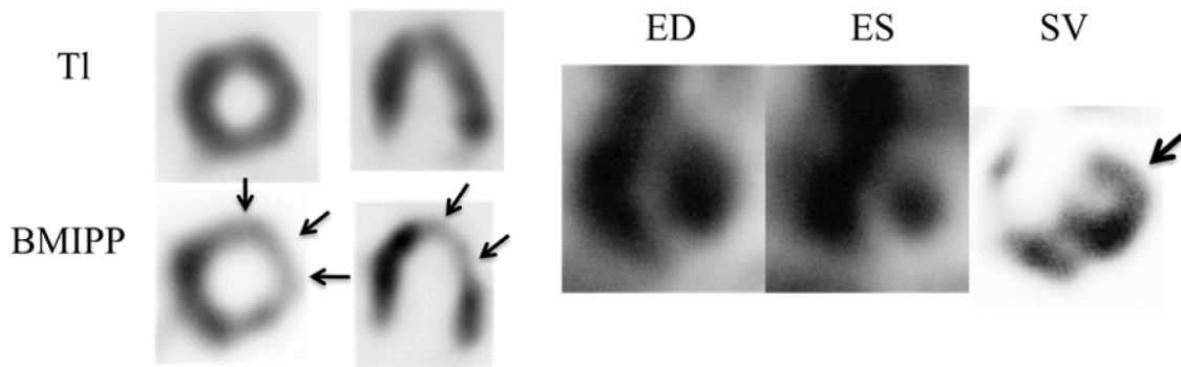
In chronic stable coronary artery disease even without history of myocardial infarction, discordant BMIPP uptake less than perfusion tracer is also a common finding. Comparison of BMIPP and stress-reinjection thallium SPECT in 45 patients with chronic coronary artery disease demonstrated that most of the segments (118/124) with discordant BMIPP uptake less than reinjection-thallium were associated with demand ischemia indicated by reversible thallium defects [70]. When reversible thallium defects were analyzed, approximately half of the segments evidenced discordant BMIPP uptake less than reinjection thallium. On the other hand, around 80% of the segments with fixed thallium defects demonstrated concordant reduction of both tracers, suggesting myocardium with reduced or poor viability has metabolic abnormality similar to the degree of resting perfusion abnormality. When reversible thallium defects were analyzed with respect to the evidence of discordant BMIPP uptake less than thallium and regional wall motion abnormality, wall motion was more severely impaired in the segments with discordant BMIPP uptake less than thallium than those without such discordance in both subset of patients with and without old myocardial infarction. However, severity of coronary artery stenosis was similar in the vascular territory with discordant BMIPP uptake less than reinjection thallium and those without such discordance. Comparison of BMIPP and stress-redistribution-reinjection thallium imaging in 55 patients with stable coronary artery disease revealed that discordant BMIPP uptake less than thallium was observed in only 37% of the segments with thallium redistribution after exercise, on the contrary, such dis-

cordance was observed in 82% of the segments with no redistribution but new fill-in after thallium reinjection [71]. In addition, such discordance was observed in only 19% of the segments with fixed defects. Previous studies with stress-redistribution-reinjection thallium demonstrated that the myocardium with new fill-in after thallium reinjection is characterized as severely ischemic but viable myocardium with frequent wall motion abnormalities that may recover after revascularization [72,73]. Accordingly, these observation may indicate that discordant BMIPP uptake less than thallium is suggestive of the myocardium jeopardized by more severe ischemia.

The concept of ischemic memory imaging of BMIPP has been tested in 32 patients with exercise-induced ischemia on thallium SPECT. BMIPP imaging at rest within 30 hrs of ischemia, which was induced and confirmed by exercise thallium SPECT, revealed reduction of BMIPP uptake corresponding to the ischemic area detected by stress thallium study in more than 90 % of patients [50]. Therefore, the authors concluded that BMIPP can identify sustained metabolic abnormality as a ischemic memory imaging at least until 30 hrs after stress induced ischemic episodes. This finding was complemented by the studies assessing glucose metabolism in patients undergoing exercise testing using FDG. Those have shown that a metabolic switch from fatty acid to glucose use occurs promptly when myocardial ischemia is induced during exercise and this metabolic switch to glucose may persist for 24hours, despite restoration of blood flow at rest [74,75].

Accumulated data in patients with chronic ischemic heart disease in Japan, however, demonstrated that reduced BMIPP uptake was frequently observed independent of prior radio-nuclide and ECG stress tests but related to severe ischemia and wall motion abnormality, raise the possibility that BMIPP reduction reflects the substrate shift from fatty acid to glucose as a results of repeated myocardial ischemia rather than reflecting the single episode of metabolic stunning. Myocardium exposed to repetitive ischemia or stunning is subsequently adapted metabolically (metabolic remodeling) into chronic ischemic myocardium, so called hibernation [76-78]. In hibernating myocardium, energy substrate is shifted from fatty acid to glucose, contractility is impaired but with recruitable inotropic reserve, and myocardial flow reserve is severely impaired. In relation to this issue, relationship between BMIPP uptake and absolute myocardial blood flow by PET was investigated in patients with chronic stable angina without previous myocardial infarction. The results demonstrated that rest myocardial blood flow was preserved independent of BMIPP uptake. However, hyperemic myocardial blood flow was decreased in the area with reduced BMIPP uptake, resulting in the severity of impaired myocardial flow reserve correlated to the reduction of BMIPP uptake [79]. Thus, reduced BMIPP uptake implies impaired myocardial flow reserve and may reflects adaptive substrate shifts or metabolic remodeling in hibernating myocardium. Representative case with stable angina pectoris who underwent BMIPP and thallium SPECT before and after coronary intervention (Fig 5).

Before PTCA



8 months after PTCA

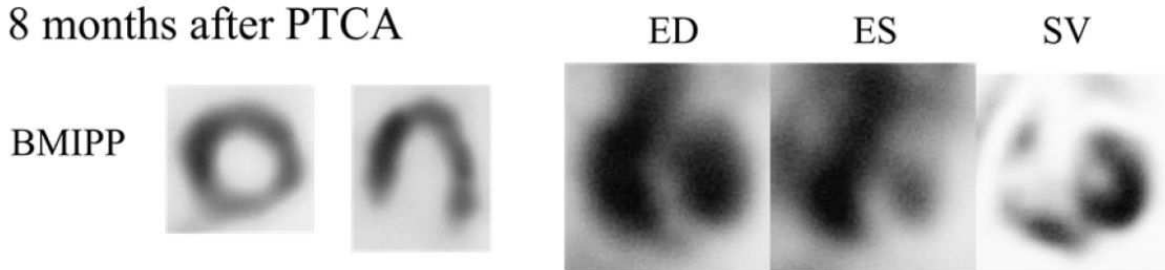


Figure 5. Short axis and horizontal long axis slices of ^{201}Tl , ^{123}I - BMIPP and gated blood pool images. The patient with angina pectoris underwent thallium and BMIPP SPECT. Discordant BMIPP uptake less than thallium in antero-lateral wall was observed (arrows). Gated blood pool scintigraphy demonstrated mild hypokinesia in antero-lateral wall. Stroke volume image showed reduced stroke volume in anterolateral wall (arrow). Coronary angiography showed severe stenosis of the first diagonal branch of the left anterior descending coronary artery. Coronary angioplasty was successfully performed and BMIPP uptake and wall motion abnormality improved 8 months later. The discordant BMIPP uptake less than thallium depicted the dysfunctional but viable myocardium or hibernating myocardium in anterolateral wall. ED = end-diastolic, ES = end-systolic, PTCA = percutaneous transluminal coronary angioplasty, SV = stroke volume

5.4. Detection of coronary artery disease

Meta-analysis for the assessment of diagnostic accuracy of BMIPP imaging for the detection of coronary artery disease was conducted with 7 studies between 1995 and 2004 [80]. A total of 528 patients with a high prevalence of coronary artery disease who underwent both BMIPP imaging and coronary angiography were analyzed using a random-effects model. The overall sensitivity and specificity were 78% (95% confidence interval, 73% to 81%) and 84% (95% confidence interval, 77% to 89%). The summary receiver operating characteristic curve analysis showed that the area under the curve was 0.91 (SE, 0.020), and the Q^* index was 0.84 (SE, 0.022), indicating excellent diagnostic accuracy. This diagnostic performance is comparable with stress myocardial perfusion SPECT reported by meta-analysis; a sensitivity and specificity of 88% and 73%, respectively [81]. Thus, stress SPECT imaging is a more sensitive test, whereas BMIPP imaging is a more specific test. Unlike stress myocardial perfusion imaging, BMIPP imaging is obtained without the use of exercise or pharmacologic agents. Therefore, BMIPP imaging at rest may be an alternative imaging modality for those

who are unable to perform adequate exercise testing or pharmacologic stress myocardial perfusion imaging, such as those presenting with acute chest pain and patients with end stage renal disease with hemodialysis.

5.5. Myocardial viability assessment and prediction of functional recovery

Improvement of regional or global systolic function can be achieved if revascularization of viable myocardium is successfully performed. Therefore, assessment of residual myocardial viability in the setting of dysfunctional myocardium due to significant coronary artery disease is a key issue in making clinical decisions with respect to revascularization procedures. In this respect, stress myocardial perfusion SPECT has been extensively investigated. The hallmarks of myocardial viability supplied by a stenosed or occluded coronary artery are the perfusion defect with thallium redistribution on stress-redistribution or rest-redistribution images, fill-in of thallium, sestamibi, and tetrofosmin after reinjection, or significant uptake on resting or reinjection images (usually more than 50-60% uptake of normal area). However, the ability of perfusion tracers to differentiate viable from non-viable myocardium is not completely satisfactory as evidenced by recent viability studies using perfusion tracers [82-84]. In terms of the hallmark of viability in BMIPP imaging, there are several substantial evidences that discordant BMIPP uptake less than perfusion tracers is a marker of viability; 1) as previously described, such mismatch is associated with ischemic myocardium as evidenced by stress perfusion studies, 2) increased FDG uptake was observed in areas with discordant BMIPP uptake less than thallium and higher oxidative metabolism by ^{11}C -acetate PET was observed in mismatched area than the area with concordant reduction of BMIPP and perfusion [85], 3) myocardial areas with BMIPP uptake less than sestamibi were more likely to have a positive response to dobutamine than areas with matched defect [86,87], 4) histologic examination in patients with bypass surgery demonstrated that BMIPP uptake reduction against % fibrosis looked biphasic, with steep reduction of BMIPP uptake within 20% of fibrosis, although, thallium uptake reduction correlated linearly to % fibrosis, implying the areas with discordant BMIPP uptake less than thallium had less than 20% fibrosis [88].

Functional recovery after revascularization has been investigated in relation to BMIPP uptake abnormality in patients with chronic coronary artery disease. Discordant BMIPP uptake less than thallium could predict functional recovery after revascularization more precisely than exercise-reinjection thallium study. In addition, the extent of discordance were a good predictor of global ejection fraction improvement after revascularization [89]. Similarly, area with discordant BMIPP uptake less than sestamibi measured by quantitative analysis was highly predictive of improvement of ejection fraction, wall motion and free fatty acid utilization after revascularization [87]. Interestingly, the comparison of FDG, BMIPP, and sestamibi uptake in patients with old myocardial infarction and stable ischemic regional wall motion abnormalities demonstrated that extent of discordant BMIPP uptake less than FDG uptake before revascularization highly correlated with ejection fraction improvement after revascularization ($r = 0.74$) and also the extent of discordant BMIPP uptake less than sestamibi correlated significantly with ejection fraction improvement ($r = 0.50$). However, no sig-

nificant correlation was observed between the area with discordant FDG uptake more than sestamib and ejection fraction recovery [90]. The results are quite intuitive because, in ischemic and viable myocardium, substrate shift from fatty acid to glucose would take place, hence, mismatch of FDG and BMIPP uptake should be prominent but mismatch between BMIPP and sestamibi might be modest. These data suggest that discordant BMIPP uptake less than perfusion may represent reversible ischemic myocardial injury or hibernating myocardium and that the regional and global dysfunction will improve after revascularization in patients with chronic stable coronary artery disease. Metabolic stunning is also a good marker of functional recovery. In acute myocardial infarction with emergency revascularization, BMIPP and tetrofosmin mismatch around 1 week after the revascularization predicted recovery of ejection fraction and wall motion 3 month later [91,92].

5.6. Risk stratification and prediction of the prognosis

Assessment of prognostic value of BMIPP imaging over perfusion tracers in patients with coronary artery disease is a matter of clinical importance. The initial study for the assessment of prognostic implications of BMIPP imaging was conducted in 50 consecutive patients with myocardial infarction with a mean follow up period of 23 months [93]. During the follow-up period, 9 patients had cardiac events; 8 of the 9 patients with cardiac events showed discordant BMIPP uptake less than reinjection thallium, whereas only 20 of 41 patients without cardiac events showed such mismatch. When all the clinical and radionuclide variables were analyzed by Cox regression analysis, presence of discordant BMIPP uptake was the best, and an independent, predictor of future cardiac events followed by the number of coronary artery stenosis. BMIPP and thallium imaging performed within 1 month of acute myocardial infarction demonstrated that impaired BMIPP uptake and mismatched BMIPP uptake less than thallium are related to a high probability of fatal and non-fatal cardiac events [94] and the defect score of BMIPP and mismatched BMIPP uptake less than thallium provided incremental predictive value for future cardiac events [95,96].

In the patients with chronic stage of myocardial infarction, clinical value of BMIPP imaging for predicting prognosis is also demonstrated. BMIPP imaging performed before revascularization in 76 patients with chronic stable ischemia (including 61 patients with myocardial infarction after at least 3 month of onset) with left ventricular dysfunction has been analyzed [97]. Patients with large amount of discordant BMIPP uptake less than thallium demonstrated greater ejection fraction improvement after revascularization and, interestingly, showed significantly better event free survival than patients with small amount or no perfusion and metabolic mismatch. These data indicate that patients with significant amount of discordant BMIPP uptake less than thallium may benefit from revascularization.

In chronic coronary artery disease without old myocardial infarction, value of BMIPP imaging for risk stratification has been also demonstrated. In 270 patients, BMIPP defect score was analyzed with respect to cardiac event during a median follow-up of 3.9 years [98]. Kaplan-Meier survival estimates revealed that patients with a summed BMIPP defect score lower than 5 showed a better prognosis than the patients with more defect of BMIPP (a hard event-free survival rate at 3 years: 98% vs 93% ($P = 0.03$), all event-free survival rate at 3

years: 92% vs 80% ($P = 0.0003$), respectively). More importantly, BMIPP was able to select a high-risk subgroup among patients with diabetes mellitus as well as non-diabetic patients, with 41% event rate in diabetic patients with BMIPP defect score 5 or more but only 4% event rate in non-diabetic patients with BMIPP defect score lower than 5.

One of the strength of BMIPP imaging in daily clinical use is its simplicity since it offers metabolic information without stress procedure. It is a matter of great interest whether resting BMIPP imaging offers complementary or additional prognostic information to that provided conventional stress perfusion imaging. One hundred and sixty-seven consecutive patients with angina pectoris but without prior myocardial infarction who had undergone both BMIPP and stress thallium imaging were followed up for 48 months [99]. For overall cardiac events (5 hard and 29 soft events), multivariate Cox's analysis revealed that reduced BMIPP uptake, stress perfusion score, diabetes, and left ventricular ejection fraction were the significant predictors. No hard event was observed with normal BMIPP uptake, whereas 2 patients with nearly normal stress perfusion with impaired BMIPP uptake had a hard event. The authors concluded that resting BMIPP imaging may provide significant prognostic information independent of stress myocardial perfusion imaging.

Recently meta-analysis on the prognostic value of BMIPP imaging in acute coronary syndrome, acute myocardial infarction, and stable coronary artery disease was reported [100]. In 3 studies involving 541 patients with suspected acute coronary syndrome who were excluded for acute myocardial infarction, an abnormal finding on BMIPP imaging significantly associated with future hard cardiac events, defined as cardiac death and non-fatal myocardial infarction. The negative predictive value of BMIPP imaging for future hard and soft events were 98.9% and 92.3% over 3.5 years, respectively. In 6 studies which comprised 607 patients with acute myocardial infarction, larger defect on BMIPP imaging was significantly associated with cardiac death and hard events with relative risk of 2.81 and 3.87, respectively. Two studies included 166 patients with stable coronary artery disease who underwent elective revascularization. Both studies evaluated the prognostic value of mismatched BMIPP uptake less than perfusion, and showed contrasting results depending on the timing of BMIPP imaging to relative to revascularization. The presence of mismatched myocardium before revascularization, which suggested a jeopardized but viable myocardium, is associated with fewer events if patients undergo successful revascularization. However, the mismatch occurs after revascularization, indicating residual ischemia, the more hard events occur.

5.7. Chronic kidney disease

In chronic kidney disease (CKD), cardiovascular disease accounts for most of the morbidity and mortality in both pre-dialysis and after the onset of end stage renal disease. Stress myocardial perfusion imaging has become increasingly recognized as a powerful prognostic tool for cardiovascular outcomes in patients with known or suspected coronary artery disease. Abnormal stress myocardial perfusion scan is more common in patients with CKD and stress perfusion imaging is confirmed as a powerful tool for predicting outcomes across entire spectrum of renal dysfunction. At the same time, pres-

ence of CKD itself added prognostic value to perfusion imaging [101]. While stress perfusion imaging is a valuable method to assess coronary artery disease, stress test may not be suitable for a substantial number of CKD patients, especially in end stage renal disease. Because of an inability to exercise enough due to multiple comorbidity including obesity, arthritis, and deconditioning etc, and suboptimal vasodilator stress testing due to an incomplete vasodilator response due to endothelial dysfunction. In this context, BMIPP imaging can be performed safely and effectively at rest to detect metabolic alteration due to ischemia without stress testing.

In addition to the high prevalence of coronary artery disease in patients with CKD, several sequelae of renal failure also contribute to left ventricular metabolic remodeling, so-called uremic cardiomyopathy. In this condition, myocyte capillary mismatch, with diminished vascular supply relative to the number and volume of functioning myocytes is observed [102,103]. These epicardial and microvascular disorders should induce ischemia when cardiac demand increases. For the detection of coronary artery disease in asymptomatic patients undergoing hemodialysis, dual isotope SPECT with thallium and BMIPP was investigated [104]. Significant coronary stenosis (>75%) was found in 72% of patients (93/130). When a BMIPP summed score of 6 or more was defined as abnormal, sensitivity, specificity, and accuracy for detecting coronary artery disease by BMIPP SPECT were 98.0%, 65.6%, and 90.0%, respectively. For the assessment of prognostic value of BMIPP in patients with hemodialysis, 318 asymptomatic patients without prior myocardial infarction underwent dual isotope SPECT with thallium and BMIPP [105]. During a mean follow up period of 3.6 ± 1.0 years, 50 died of cardiac event. Kaplan-Meier analysis showed that the cardiac death-free survival rates at 3 years were 61% and 98% in patients with BMIPP summed scores of >12 and <12, respectively. When the cutoff value of BMIPP-Tl mismatch score, a marker of ischemia, was determined to be 7, the sensitivity and specificity of BMIPP-Tl mismatch for predicting cardiac death were 86% and 88%, respectively. Kaplan-Meier survival estimates revealed that the event-free rates of cardiac death at 3 years were 53% in patients with BMIPP-Tl mismatch of > 7, whereas 96% in patients with BMIPP-Tl mismatch < 7. These findings suggested that significantly impaired myocardial fatty acid metabolism detected by BMIPP SPECT might predict the occurrence of cardiac death in asymptomatic hemodialysis patients. In addition, in patients with hemodialysis and complete coronary revascularization, BMIPP imaging abnormality and BMIPP thallium mismatch can also predict cardiac death [106]. Furthermore, prospectively enrolled 155 patients receiving hemodialysis after angiography had confirmed the absence of obstructive coronary lesions were examined by BMIPP SPECT [107]. During a mean follow-up of 5.1 years, 42 patients died of cardiac events. Stepwise Cox hazard analysis demonstrated that cardiac death associated with reduced BMIPP uptake and increased insulin resistance. Thus, impaired myocardial fatty acid metabolism and insulin resistance may be associated with cardiac death among hemodialysis patients without obstructive coronary artery disease.

Accordingly, in patients with high risk CKD, BMIPP imaging at rest is highly valuable in terms of the assessment of the myocardial metabolic abnormality, stratifying the patient's risk, and predicting cardiac death.

6. Summary and conclusions

In normal condition approximately two-thirds or more of the total energy produced by myocardium is derived from fatty acid oxidation and myocardial substrates may change significantly in various pathological conditions such as ischemia. Accordingly, many fatty acid tracers for SPECT imaging have been introduced. Until now, ^{123}I -BMIPP, one of the methyl branched fatty acid analogues, is the only approved fatty acid tracer for daily clinical use. The concept of BMIPP imaging is metabolic trapping, like FDG, by inhibiting β -oxidation by introducing methyl branching at β -carbon position. Myocardial BMIPP uptake more likely reflects activation of BMIPP into BMIPP-CoA with consumption of ATP, thus the uptake indirectly reflects cellular ATP production by fatty acid metabolism. Under the condition of ischemia, the reduction of BMIPP uptake is observed by reflecting the reduction of ATP production due to depressed oxidative fatty acid metabolism and substrate shift from fatty acids to glucose. Reduced uptake of BMIPP at rest is often observed in ischemic myocardium independent of the uptake of perfusion tracers, that is, discordant or mismatched BMIPP uptake less than perfusion tracers. Through comparison with perfusion, BMIPP image can detect previous myocardial ischemia as an ischemic memory imaging (stunned myocardium or status of metabolic stunning) and viable but chronically dysfunctional myocardium (hibernating myocardium or status of metabolic remodeling). In addition, BMIPP image may offer incremental prognostic information in ischemic heart diseases. Through the basic and clinical studies, it has become clear that BMIPP imaging has a high potential utility in the entire spectrum of ischemic heart diseases in evaluating the patients with acute chest pain, acute myocardial infarction, unstable angina pectoris, chronic stable coronary artery diseases, in terms of diagnosis, risk stratification, and also for the prediction of prognosis.

Author details

Junichi Taki¹, Ichiro Matsunari², Hiroshi Wakabayashi¹, Anri Inaki¹ and Seigo Kinuya¹

1 Department of Nuclear Medicine, Kanazawa University Hospital, Kanazawa, Japan

2 Medical & Pharmacological Research Center Foundation, Hakui, Japan

References

- [1] Taki J, Matsunari I. Metabolic imaging using SPECT. *Eur J Nucl Med Mol Imaging*. 2007 Jun;34 Suppl 1:S34-48.
- [2] Tamaki N, Morita K, Kawai Y. The Japanese experience with metabolic imaging in the clinical setting. *J Nucl Cardiol*. 2007;14(3 Suppl):S145-52.

- [3] Goodwin GW, Taegtmeier H. Improved energy homeostasis of the heart in the metabolic state of exercise. *Am J Physiol Heart Circ Physiol.* 2000;279:H1490–H1501.
- [4] Korvald C, Elvenes OP, Myrnes T. Myocardial substrate metabolism influences left ventricular energetics in vivo. *Am J Physiol Heart Circ Physiol.* 2000;278(4):H1345-51.
- [5] Liedtke AJ. Alterations of carbohydrate and lipid metabolism in the acutely ischemic heart. *Prog Cardiovasc Dis* 1981;23:321-36
- [6] Camici P, Ferrannini E and Opie LH. Myocardial metabolism in ischemic heart disease: basic principles and application to imaging by positron emission tomography. *Prog Cardiovasc Dis* 1989;32:217-38
- [7] Lopaschuk GD, Collins-Nakai RL, Itoi T. Developmental changes in energy substrate use by the heart. *Cardiovascular Research.* 1992;26(12):1172–80.
- [8] Hwang EH, Yamashita A, Takemori H, Taki J, Nakajima K, Bunko H, et al. Absent myocardial I-123 BMIPP uptake in a family. *Ann Nucl Med* 1996;10:445-8
- [9] Hashimoto J, Koseki S, Kinoshita F, Kubo A, Iwanaga S, Mitamura H, et al. Absent myocardial accumulation of two different radioiodinated pentadecanoic acids. *Ann Nucl Med* 1998;12:43-6
- [10] Tanaka T, Okamoto F, Sohmiya K and Kawamura K. Lack of myocardial iodine-123 15-(p-iodiphenyl)-3-R,S-methylpentadecanoic acid (BMIPP) uptake and CD36 abnormality--CD36 deficiency and hypertrophic cardiomyopathy. *Jpn Circ J* 1997;61:724-5
- [11] Hwang EH, Taki J, Yasue S, Fujimoto M, Taniguchi M, Matsunari I, et al. Absent myocardial iodine-123-BMIPP uptake and platelet/monocyte CD36 deficiency. *J Nucl Med* 1998;39:1681-4
- [12] Yoshizumi T, Nozaki S, Fukuchi K, Yamasaki K, Fukuchi T, Maruyama T, et al. Pharmacokinetics and metabolism of 123I-BMIPP fatty acid analog in healthy and CD36-deficient subjects. *J Nucl Med* 2000;41:1134-8
- [13] Watanabe K, Ohta Y, Toba K, Ogawa Y, Hanawa H, Hirokawa Y, et al. Myocardial CD36 expression and fatty acid accumulation in patients with type I and II CD36 deficiency. *Ann Nucl Med* 1998;12:261-6
- [14] Fukuchi K, Nozaki S, Yoshizumi T, Hasegawa S, Uehara T, Nakagawa T, et al. Enhanced myocardial glucose use in patients with a deficiency in long-chain fatty acid transport (CD36 deficiency). *J Nucl Med* 1999;40:239-43
- [15] Kudoh T, Tamaki N, Magata Y, Konishi J, Nohara R, Iwasaki A, et al. Metabolism substrate with negative myocardial uptake of iodine-123-BMIPP. *J Nucl Med* 1997;38:548-53
- [16] Nozaki S, Tanaka T, Yamashita S, Sohmiya K, Yoshizumi T, Okamoto F, et al. CD36 mediates long-chain fatty acid transport in human myocardium: complete myocar-

- dial accumulation defect of radiolabeled long-chain fatty acid analog in subjects with CD36 deficiency. *Mol Cell Biochem* 1999;192:129-35
- [17] Tanaka T, Nakata T, Oka T, Ogawa T, Okamoto F, Kusaka Y, et al. Defect in human myocardial long-chain fatty acid uptake is caused by FAT/CD36 mutations. *J Lipid Res* 2001;42:751-9
- [18] Brinkmann JF, Abumrad NA, Ibrahimi A, van der Vusse GJ and Glatz JF. New insights into long-chain fatty acid uptake by heart muscle: a crucial role for fatty acid translocase/CD36. *Biochem J* 2002;367:561-70
- [19] Robinson GD, Jr. and Lee AW. Radioiodinated fatty acids for heart imaging: iodine monochloride addition compared with iodide replacement labeling. *J Nucl Med* 1975;16:17-21
- [20] Poe ND, Robinson GD, Jr., Graham LS and MacDonald NS. Experimental basis of myocardial imaging with ¹²³I-labeled hexadecenoic acid. *J Nucl Med* 1976;17:1077-82
- [21] Poe ND, Robinson GD, Jr., Zielinski FW, Cabeen WR, Jr., Smith JW and Gomes AS. Myocardial imaging with ¹²³I-hexadecenoic acid. *Radiology* 1977;124:419-24
- [22] Visser FC, van Eenige MJ, Westera G, Den Hollander W, Duwel CM, van der Wall EE, et al. Metabolic fate of radioiodinated heptadecanoic acid in the normal canine heart. *Circulation* 1985;72:565-71
- [23] Freundlieb C, Hock A, Vyska K, Feinendegen LE, Machulla HJ and Stocklin G. Myocardial imaging and metabolic studies with [17-¹²³I]iodoheptadecanoic acid. *J Nucl Med* 1980;21:1043-50
- [24] Machulla HJ, Marsmann M and Dutschka K. Biochemical concept and synthesis of a radioiodinated phenylfatty acid for in vivo metabolic studies of the myocardium. *Eur J Nucl Med* 1980;5:171-3
- [25] Reske SN, Sauer W, Machulla HJ and Winkler C. 15(p-[¹²³I]iodophenyl)pentadecanoic acid as tracer of lipid metabolism: comparison with [1-¹⁴C]palmitic acid in murine tissues. *J Nucl Med* 1984;25:1335-42
- [26] Caldwell JH, Martin GV, Link JM, Krohn KA and Bassingthwaite JB. Iodophenyl-pentadecanoic acid-myocardial blood flow relationship during maximal exercise with coronary occlusion. *J Nucl Med* 1990;31:99-105
- [27] Ercan M, Senekowitsch R, Bauer R, Reidel G, Kriegel H and Pabst HW. In vivo and in vitro studies with omega-[rho-¹²³I-phenyl]-pentadecanoic acid in rats. *Int J Appl Radiat Isot* 1983;34:1519-24
- [28] Rellas JS, Corbett JR, Kulkarni P, Morgan C, Devous MD, Sr., Buja LM, et al. Iodine-123 phenylpentadecanoic acid: detection of acute myocardial infarction and injury in dogs using an iodinated fatty acid and single-photon emission tomography. *Am J Cardiol* 1983;52:1326-32

- [29] Garcia EV. Quantitative Nuclear Cardiology: we are almost there! *J Nucl Cardiol.* 2012 ;19(3):424-37.
- [30] Goodman MM, Kirsch G and Knapp FF, Jr. Synthesis and evaluation of radioiodinated terminal p-iodophenyl-substituted alpha- and beta-methyl-branched fatty acids. *J Med Chem* 1984;27:390-7
- [31] Knapp FF, Jr., Ambrose KR and Goodman MM. New radioiodinated methyl-branched fatty acids for cardiac studies. *Eur J Nucl Med* 1986;12 Suppl:S39-44
- [32] Sloof GW, Visser FC, van Lingen A, Bax JJ, Eersels J, Teule GJ, et al. Evaluation of heart-to-organ ratios of ¹²³I-BMIPP and the dimethyl-substituted ¹²³I-DMIPP fatty acid analogue in humans. *Nucl Med Commun* 1997;18:1065-70
- [33] Ambrose KR, Owen BA, Goodman MM and Knapp FF, Jr. Evaluation of the metabolism in rat hearts of two new radioiodinated 3-methyl-branched fatty acid myocardial imaging agents. *Eur J Nucl Med* 1987;12:486-91
- [34] Fujibayashi Y, Nohara R, Hosokawa R, Okuda K, Yonekura Y, Tamaki N, et al. Metabolism and kinetics of iodine-123-BMIPP in canine myocardium. *J Nucl Med* 1996;37:757-61
- [35] Hosokawa R, Nohara R, Fujibayashi Y, Okuda K, Ogino M, Hata T, et al. Myocardial kinetics of iodine-123-BMIPP in canine myocardium after regional ischemia and reperfusion: implications for clinical SPECT. *J Nucl Med* 1997;38:1857-63
- [36] Hosokawa R, Nohara R, Fujibayashi Y, Okuda K, Ogino M, Hata T, et al. Metabolic fate of iodine-123-BMIPP in canine myocardium after administration of etomoxir. *J Nucl Med* 1996;37:1836-40
- [37] Matsunari I, Saga T, Taki J, Akashi Y, Hirai J, Wakasugi T, et al. Kinetics of iodine-123-BMIPP in patients with prior myocardial infarction: assessment with dynamic rest and stress images compared with stress thallium-201 SPECT. *J Nucl Med* 1994;35:1279-85
- [38] Kobayashi H, Kusakabe K, Momose M, Okawa T, Inoue S, Iguchi N, et al. Evaluation of myocardial perfusion and fatty acid uptake using a single injection of iodine-123-BMIPP in patients with acute coronary syndromes. *J Nucl Med* 1998;39:1117-22
- [39] Fox KA, Abendschein DR, Ambos HD, Sobel BE and Bergmann SR. Efflux of metabolized and nonmetabolized fatty acid from canine myocardium. Implications for quantifying myocardial metabolism tomographically. *Circ Res* 1985;57:232-43
- [40] Duwel CM, Visser FC, van Eenige MJ and Roos JP. Variables of myocardial backdiffusion, determined with 17-iodo-¹³¹I heptadecanoic acid in the normal dog heart. *Mol Cell Biochem* 1989;88:191-4
- [41] Fujibayashi Y, Yonekura Y, Takemura Y, Wada K, Matsumoto K, Tamaki N, et al. Myocardial accumulation of iodinated beta-methyl-branched fatty acid analogue, io-

- dine-125-15-(p-iodophenyl)-3-(R,S)methylpentadecanoic acid (BMIPP), in relation to ATP concentration. *J Nucl Med* 1990;31:1818-22
- [42] Nohara R, Okuda K, Ogino M, Hosokawa R, Tamaki N, Konishi J, et al. Evaluation of myocardial viability with iodine-123-BMIPP in a canine model. *J Nucl Med* 1996;37:1403-7
- [43] Miller DD, Gill JB, Livni E, Elmaleh DR, Aretz T, Boucher CA, et al. Fatty acid analogue accumulation: a marker of myocyte viability in ischemic-reperfused myocardium. *Circ Res* 1988;63:681-92
- [44] Nishimura T, Sago M, Kihara K, Oka H, Shimonagata T, Katabuchi T, et al. Fatty acid myocardial imaging using ¹²³I-beta-methyl-iodophenyl pentadecanoic acid (BMIPP): comparison of myocardial perfusion and fatty acid utilization in canine myocardial infarction (occlusion and reperfusion model). *Eur J Nucl Med* 1989;15:341-5
- [45] Noriyasu K, Mabuchi M, Kuge Y, Morita K, Tsukamoto T, Kohya T, et al. Serial changes in BMIPP uptake in relation to thallium uptake in the rat myocardium after ischaemia. *Eur J Nucl Med Mol Imaging* 2003;30:1644-50
- [46] Higuchi T, Taki J, Nakajima K, Kinuya S, Namura M and Tonami N. Time course of discordant BMIPP and thallium uptake after ischemia and reperfusion in a rat model. *J Nucl Med* 2005;46:172-5
- [47] Naruse H, Arii T, Kondo T, Morita M, Ohyanagi M, Iwasaki T, et al. Clinical usefulness of iodine 123-labeled fatty acid imaging in patients with acute myocardial infarction. *J Nucl Cardiol* 1998;5:275-84
- [48] Mochizuki T, Murase K, Higashino H, Miyagawa M, Sugawara Y, Kikuchi T, et al. Ischemic "memory image" in acute myocardial infarction of ¹²³I-BMIPP after reperfusion therapy: a comparison with ^{99m}Tc-pyrophosphate and ²⁰¹Tl dual-isotope SPECT. *Ann Nucl Med* 2002;16:563-8
- [49] Tamaki N, Tadamura E, Kudoh T, Hattori N, Inubushi M and Konishi J. Recent advances in nuclear cardiology in the study of coronary artery disease. *Ann Nucl Med* 1997;11:55-66
- [50] Dilsizian V, Bateman TM, Bergmann SR, Des Prez R, Magram MY, Goodbody AE, et al. Metabolic imaging with beta-methyl-p-[(¹²³I)]-iodophenyl-pentadecanoic acid identifies ischemic memory after demand ischemia. *Circulation* 2005;112:2169-74
- [51] Tamaki N, Kawamoto M, Yonekura Y, Fujibayashi Y, Takahashi N, Konishi J, et al. Regional metabolic abnormality in relation to perfusion and wall motion in patients with myocardial infarction: assessment with emission tomography using an iodinated branched fatty acid analog. *J Nucl Med* 1992;33:659-67
- [52] Franken PR, De Geeter F, Dendale P, Demoor D, Block P and Bossuyt A. Abnormal free fatty acid uptake in subacute myocardial infarction after coronary thrombolysis: correlation with wall motion and inotropic reserve. *J Nucl Med* 1994;35:1758-65

- [53] Ito T, Tanouchi J, Kato J, Morioka T, Nishino M, Iwai K, et al. Recovery of impaired left ventricular function in patients with acute myocardial infarction is predicted by the discordance in defect size on 123I-BMIPP and 201Tl SPET images. *Eur J Nucl Med* 1996;23:917-23
- [54] Hashimoto A, Nakata T, Tsuchihashi K, Tanaka S, Fujimori K and Iimura O. Post-ischemic functional recovery and BMIPP uptake after primary percutaneous transluminal coronary angioplasty in acute myocardial infarction. *Am J Cardiol* 1996;77:25-30
- [55] Franken PR, Dendale P, De Geeter F, Demoor D, Bossuyt A and Block P. Prediction of functional outcome after myocardial infarction using BMIPP and sestamibi scintigraphy. *J Nucl Med* 1996;37:718-22
- [56] Nishimura T, Nishimura S, Kajiya T, Sugihara H, Kitahara K, Imai K, et al. Prediction of functional recovery and prognosis in patients with acute myocardial infarction by 123I-BMIPP and 201Tl myocardial single photon emission computed tomography: a multicenter trial. *Ann Nucl Med* 1998;12:237-48
- [57] Hambye AS, Vervaet A, Dobbeleir A, Dendale P and Franken P. Prediction of functional outcome by quantification of sestamibi and BMIPP after acute myocardial infarction. *Eur J Nucl Med* 2000;27:1494-500
- [58] Katsunuma E, Kurokawa S, Takahashi M, Fukuda N, Kurosawa T and Izumi T. Usefulness of BMIPP SPECT to evaluate myocardial viability, contractile reserve and coronary stenotic progression after reperfusion in acute myocardial infarction. *Jpn Heart J* 2001;42:435-49
- [59] Seki H, Toyama T, Higuchi K, Kasama S, Ueda T, Seki R, et al. Prediction of functional improvement of ischemic myocardium with (123I-BMIPP SPECT and 99mTc-tetrofosmin SPECT imaging: a study of patients with large acute myocardial infarction and receiving revascularization therapy. *Circ J* 2005;69:311-9
- [60] Furutani Y, Shiigi T, Nakamura Y, Nakamura H, Harada M, Yamamoto T, et al. Quantification of area at risk in acute myocardial infarction by tomographic imaging. *J Nucl Med* 1997;38:1875-82
- [61] Kawai Y, Tsukamoto E, Nozaki Y, Kishino K, Kohya T and Tamaki N. Use of 123I-BMIPP single-photon emission tomography to estimate areas at risk following successful revascularization in patients with acute myocardial infarction. *Eur J Nucl Med* 1998;25:1390-5
- [62] Fukushima Y, Toba M, Ishihara K, Mizumura S, Seino T, Tanaka K, et al. Usefulness of 201TlCl/ 123I-BMIPP dual-myocardial SPECT for patients with non-ST segment elevation myocardial infarction. *Ann Nucl Med*. 2008 ;22(5):363-9.
- [63] Kawamoto M, Tamaki N, Yonekura Y, Tadamura E, Fujibayashi Y, Magata Y, et al. Combined study with I-123 fatty acid and thallium-201 to assess ischemic myocardial

- um: comparison with thallium redistribution and glucose metabolism. *Ann Nucl Med* 1994;8:47-54
- [64] Kawai Y, Tsukamoto E, Nozaki Y, Morita K, Sakurai M and Tamaki N. Significance of reduced uptake of iodinated fatty acid analogue for the evaluation of patients with acute chest pain. *J Am Coll Cardiol* 2001;38:1888-94
- [65] Kontos MC, Dilsizian V, Weiland F, DePuey G, Mahmorian JJ, Iskandrian AE, et al. Iodofilic acid I 123 (BMIPP) fatty acid imaging improves initial diagnosis in emergency department patients with suspected acute coronary syndromes: a multicenter trial. *J Am Coll Cardiol*. 2010 ;56(4):290-9.
- [66] Tateno M, Tamaki N, Yukihiro M, Kudoh T, Hattori N, Tadamura E, et al. Assessment of fatty acid uptake in ischemic heart disease without myocardial infarction. *J Nucl Med* 1996;37:1981-5
- [67] Suzuki A, Takada Y, Nagasaka M, Kato R, Watanabe T, Shimokata K, et al. Comparison of resting beta-methyl-iodophenyl pentadecanoic acid (BMIPP) and thallium-201 tomography using quantitative polar maps in patients with unstable angina. *Jpn Circ J* 1997;61:133-8
- [68] Takeishi Y, Fujiwara S, Atsumi H, Takahashi K, Sukekawa H and Tomoike H. Iodine-123-BMIPP imaging in unstable angina: a guide for interventional strategy. *J Nucl Med* 1997;38:1407-11
- [69] Takeishi Y, Sukekawa H, Saito H, Nishimura S, Shibu T, Sasaki Y, et al. Impaired myocardial fatty acid metabolism detected by ^{123}I -BMIPP in patients with unstable angina pectoris: comparison with perfusion imaging by $^{99\text{m}}\text{Tc}$ -sestamibi. *Ann Nucl Med* 1995;9:125-30
- [70] Taki J, Nakajima K, Matsunari I, Bunko H, Takada S and Tonami N. Impairment of regional fatty acid uptake in relation to wall motion and thallium-201 uptake in ischemic but viable myocardium: assessment with iodine-123-labelled beta-methyl-branched fatty acid. *Eur J Nucl Med* 1995;22:1385-92
- [71] Matsunari I, Fujino S, Taki J, Senma J, Aoyama T, Wakasugi T, et al. Impaired fatty acid uptake in ischemic but viable myocardium identified by thallium-201 reinjection. *Am Heart J* 1996;131:458-65
- [72] Tamaki N, Ohtani H, Yonekura Y, Nohara R, Kambara H, Kawai C, et al. Significance of fill-in after thallium-201 reinjection following delayed imaging: comparison with regional wall motion and angiographic findings. *J Nucl Med* 1990;31:1617-23
- [73] Ohtani H, Tamaki N, Yonekura Y, Mohiuddin IH, Hirata K, Ban T, et al. Value of thallium-201 reinjection after delayed SPECT imaging for predicting reversible ischemia after coronary artery bypass grafting. *Am J Cardiol* 1990;66:394-9
- [74] He ZX, Shi RF, Wu YJ, Tian YQ, Liu XJ, Wang SW, et al. Direct imaging of exercise-induced myocardial ischemia with fluorine-18-labeled deoxyglucose and $^{99\text{m}}\text{Tc}$ -sestamibi in coronary artery disease. *Circulation*. 2003 ;108(10):1208-13.

- [75] Dou KF, Yang MF, Yang YJ, Jain D, He ZX. Myocardial ¹⁸F-FDG uptake after exercise-induced myocardial ischemia in patients with coronary artery disease. *J Nucl Med.* 2008 ;49(12):1986-91.
- [76] Kim SJ, Peppas A, Hong SK, Yang G, Huang Y, Diaz G, et al. Persistent stunning induces myocardial hibernation and protection: flow/function and metabolic mechanisms. *Circ Res* 2003;92:1233-9
- [77] Camici PG and Rimoldi OE. Myocardial blood flow in patients with hibernating myocardium. *Cardiovasc Res* 2003;57:302-11
- [78] Gerber BL, Vanoverschelde JL, Bol A, Michel C, Labar D, Wijns W, et al. Myocardial blood flow, glucose uptake, and recruitment of inotropic reserve in chronic left ventricular ischemic dysfunction. Implications for the pathophysiology of chronic myocardial hibernation. *Circulation* 1996;94:651-9
- [79] Kageyama H, Morita K, Katoh C, Tsukamoto T, Noriyasu K, Mabuchi M, et al. Reduced ¹²³I-BMIPP uptake implies decreased myocardial flow reserve in patients with chronic stable angina. *Eur J Nucl Med Mol Imaging* 2006;33:6-12
- [80] Inaba Y, Bergmann SR. Diagnostic accuracy of beta-methyl-p-[¹²³I]-iodophenyl-pentadecanoic acid (BMIPP) imaging: a meta-analysis. *J Nucl Cardiol.* 2008 May-Jun; 15(3):345-52.
- [81] Heijenbrok-Kal MH, Fleischmann KE, Hunink MG. Stress echocardiography, stress single-photon-emission computed tomography and electron beam computed tomography for the assessment of coronary artery disease: a meta-analysis of diagnostic performance. *Am Heart J.* 2007 ;154(3):415-23
- [82] Udelson JE, Bonow RO and Dilsizian V. The historical and conceptual evolution of radionuclide assessment of myocardial viability. *J Nucl Cardiol* 2004;11:318-34
- [83] Srinivasan G, Kitsiou AN, Bacharach SL, Bartlett ML, Miller-Davis C and Dilsizian V. [¹⁸F]fluorodeoxyglucose single photon emission computed tomography: can it replace PET and thallium SPECT for the assessment of myocardial viability? *Circulation* 1998;97:843-50
- [84] Bax JJ, Wijns W, Cornel JH, Visser FC, Boersma E, Fioretti PM. Accuracy of currently available techniques for prediction of functional recovery after revascularization in patients with left ventricular dysfunction due to chronic coronary artery disease: comparison of pooled data. *J Am Coll Cardiol.* 1997 ;30(6):1451-60
- [85] Tamaki N, Tadamura E, Kawamoto M, Magata Y, Yonekura Y, Fujibayashi Y, et al. Decreased uptake of iodinated branched fatty acid analog indicates metabolic alterations in ischemic myocardium. *J Nucl Med* 1995;36:1974-80
- [86] Hambye AS, Vaerenberg MM, Dobbeleir AA, Van den Heuvel PA and Franken PR. Abnormal BMIPP uptake in chronically dysfunctional myocardial segments: correlation with contractile response to low-dose dobutamine. *J Nucl Med* 1998;39:1845-50

- [87] Hambye AS, Dobbeleir AA, Vervaet AM, Van den Heuvel PA and Franken PR. BMIPP imaging to improve the value of sestamibi scintigraphy for predicting functional outcome in severe chronic ischemic left ventricular dysfunction. *J Nucl Med* 1999;40:1468-76
- [88] Kudoh T, Tadamura E, Tamaki N, Hattori N, Inubushi M, Kubo S, et al. Iodinated free fatty acid and 201Tl uptake in chronically hypoperfused myocardium: histologic correlation study. *J Nucl Med* 2000;41:293-6
- [89] Taki J, Nakajima K, Matsunari I, Bunko H, Takata S, Kawasuji M, et al. Assessment of improvement of myocardial fatty acid uptake and function after revascularization using iodine-123-BMIPP. *J Nucl Med* 1997;38:1503-10
- [90] Sato H, Iwasaki T, Toyama T, Kaneko Y, Inoue T, Endo K, et al. Prediction of functional recovery after revascularization in coronary artery disease using (18)F-FDG and (123)I-BMIPP SPECT. *Chest* 2000;117:65-72
- [91] Biswas SK, Sarai M, Toyama H, Yamada A, Motoyama S, Harigaya H, et al. (123)I-BMIPP and (99m)Tc-TF discordance on myocardial scintigraphy and its correlation with functional recovery following acute myocardial infarction: role of conventional echocardiography. *Int J Cardiovasc Imaging*. 2009 ;25(8):765-75.
- [92] Biswas SK, Sarai M, Yamada A, Motoyama S, Harigaya H, Hara T, et al. Fatty acid metabolism and myocardial perfusion imaging for the evaluation of global left ventricular dysfunction following acute myocardial infarction: comparisons with echocardiography. *Int J Cardiol*. 2010;138(3):290-9.
- [93] Tamaki N, Tadamura E, Kudoh T, Hattori N, Yonekura Y, Nohara R, et al. Prognostic value of iodine-123 labelled BMIPP fatty acid analogue imaging in patients with myocardial infarction. *Eur J Nucl Med* 1996;23:272-9
- [94] Nakata T, Kobayashi T, Tamaki N, Kobayashi H, Wakabayashi T, Shimoshige S, et al. Prognostic value of impaired myocardial fatty acid uptake in patients with acute myocardial infarction. *Nucl Med Commun* 2000;21:897-906
- [95] Nanasato M, Hirayama H, Ando A, Isobe S, Nonokawa M, Kinoshita Y, et al. Incremental predictive value of myocardial scintigraphy with ^{123}I -BMIPP in patients with acute myocardial infarction treated with primary percutaneous coronary intervention. *Eur J Nucl Med Mol Imaging* 2004;31:1512-21
- [96] Fukushima Y, Toba M, Ishihara K, Mizumura S, Seino T, Tanaka K, et al. Usefulness of $^{201}\text{TlCl}$ / ^{123}I -BMIPP dual-myocardial SPECT for patients with non-ST segment elevation myocardial infarction. *Ann Nucl Med*. 2008 ;22(5):363-9.
- [97] Fukuzawa S, Ozawa S, Shimada K, Sugioka J and Inagaki M. Prognostic values of perfusion-metabolic mismatch in Tl-201 and BMIPP scintigraphic imaging in patients with chronic coronary artery disease and left ventricular dysfunction undergoing revascularization. *Ann Nucl Med* 2002;16:109-15

- [98] Chikamori T, Fujita H, Nanasato M, Toba M and Nishimura T. Prognostic value of I-123 15-(p-iodophenyl)-3-(R,S) methylpentadecanoic acid myocardial imaging in patients with known or suspected coronary artery disease. *J Nucl Cardiol* 2005;12:172-8
- [99] Matsuki T, Tamaki N, Nakata T, Doi A, Takahashi H, Iwata M, et al. Prognostic value of fatty acid imaging in patients with angina pectoris without prior myocardial infarction: comparison with stress thallium imaging. *Eur J Nucl Med Mol Imaging* 2004;31:1585-91
- [100] Inaba Y, Bergmann SR. Prognostic value of myocardial metabolic imaging with BMIPP in the spectrum of coronary artery disease: a systematic review. *J Nucl Cardiol*. 2010 ;17(1):61-70.
- [101] Hakeem A, Bhatti S, Trevino AR, Samad Z, Chang SM. Non-invasive risk assessment in patients with chronic kidney disease. *J Nucl Cardiol*. 2011 ;18(3):472-85
- [102] Dilsizian V, Fink JC. Deleterious effect of altered myocardial fatty acid metabolism in kidney disease. *J Am Coll Cardiol*. 2008 ;51(2):146-8
- [103] Tyralla K, Amann K. Morphology of the heart and arteries in renal failure. *Kidney Int Suppl*. 2003 ;63(84):S80-3
- [104] Nishimura M, Hashimoto T, Kobayashi H, Fukuda T, Okino K, Yamamoto N, et al. Myocardial scintigraphy using a fatty acid analogue detects coronary artery disease in hemodialysis patients. *Kidney Int*. 2004;66(2):811-9.
- [105] Nishimura M, Tsukamoto K, Hasebe N, Tamaki N, Kikuchi K, Ono T. Prediction of cardiac death in hemodialysis patients by myocardial fatty acid imaging. *J Am Coll Cardiol*. 2008;51(2):139-45.
- [106] Nishimura M, Tokoro T, Nishida M, Hashimoto T, Kobayashi H, Yamazaki S, et al. Myocardial fatty acid imaging identifies a group of hemodialysis patients at high risk for cardiac death after coronary revascularization. *Kidney Int*. 2008 ;74(4):513-20.
- [107] Nishimura M, Tsukamoto K, Tamaki N, Kikuchi K, Iwamoto N, Ono T. Risk stratification for cardiac death in hemodialysis patients without obstructive coronary artery disease. *Kidney Int*. 2011;79(3):363-71.