

We are IntechOpen, the world's leading publisher of Open Access books Built by scientists, for scientists

4,800

Open access books available

122,000

International authors and editors

135M

Downloads

Our authors are among the

154

Countries delivered to

TOP 1%

most cited scientists

12.2%

Contributors from top 500 universities



WEB OF SCIENCE™

Selection of our books indexed in the Book Citation Index
in Web of Science™ Core Collection (BKCI)

Interested in publishing with us?
Contact book.department@intechopen.com

Numbers displayed above are based on latest data collected.
For more information visit www.intechopen.com



***Propionibacterium acnes* as a Cause of Sarcoidosis**

Yoshinobu Eishi

Additional information is available at the end of the chapter

<http://dx.doi.org/10.5772/55073>

1. Introduction

Sarcoidosis is one of the best-known systemic granulomatous diseases. Despite intensive investigation, however, the etiology of sarcoidosis has remained unresolved for more than 100 years [1]. Sarcoidosis seems to result from the exposure of a genetically susceptible subject to an environmental agent, and microbial etiologies of sarcoidosis have long been considered based on the clinical similarities to infectious granulomatous diseases [2]. Several epidemiologic mechanisms may underlie the association of an infective agent or agents with the etiology of sarcoidosis, including spatial, seasonal, and occupational clustering [3]. The results of the ACCESS (A Case Control Etiologic Study of Sarcoidosis) study support an association between selected microbially-rich environments and sarcoidosis [4].

Mycobacterial and propionibacterial organisms are the most commonly implicated etiologic agents based on studies indicating the detection by polymerase chain reaction (PCR) of microbial DNA from these organisms in tissues from sarcoid patients around the world [5-7]. Different studies have produced considerably varying results, however, with microbial DNA detected in 0% to 80% of sarcoidosis tissues and in 0% to more than 30% of control tissues [8, 9]. The failure to detect microbial DNA from these organisms in samples from some sarcoid patients suggests other causes of sarcoidosis in those patients, whereas detection of the microbial DNA in some control samples suggests latent infection of the bacterium.

Immune responses against microbial antigens from these organisms, such as ESAT-6 and KatG peptides from *Mycobacterium tuberculosis* and a recombinant trigger-factor protein from *Propionibacterium acnes*, have been examined in sarcoid patients and control subjects [10, 11]. Immune responses are frequently detected in sarcoid patients as well as in some non-sarcoid patients and healthy subjects. Latent infection by these organisms complicates the interpretation of the results of these immunologic studies. Unless microbial antigens that cause a specific immune response found only in sarcoid patients can be used to stimulate an immune response,

immunologic approaches will not be sufficient to unequivocally confirm that these organisms are causative.

Granuloma formation results from the persistence of a nondegradable product or a hypersensitivity response [12]. The two mechanisms overlap in most infectious diseases because microorganisms act as both foreign bodies and antigens to induce immunologic responses. Granulomas serve as protective mechanism to sequester and degrade the invading agent. The pathologic hallmark of sarcoidosis is an epithelioid cell granuloma, thus some etiologic agent of sarcoidosis must be present or have been present within the sarcoid granuloma. Histopathologic studies are therefore essential to demonstrate mycobacterial or propionibacterial organisms or antigens within sarcoid granulomas to demonstrate an etiologic link between sarcoidosis and these organisms.

P. acnes is so far the only microorganism isolated from sarcoid lesions by bacterial culture [13, 14]. *P. acnes* is an anaerobic, non-spore-forming, gram-positive rod bacterium indigenous to the skin and mucosal surfaces. A series of Japanese studies has provided accumulating evidence for a role of *P. acnes* in sarcoidosis. In this review, we propose mechanisms of granuloma formation in response to this indigenous bacterium in subjects with sarcoidosis based on our results obtained using histopathological and experimental approaches, and introduce a new concept of infectious disease in which endogenous infection is caused by indigenous bacteria.

2. Bacterial culture

The lung and its draining lymph nodes are the organs most commonly affected by sarcoidosis. As the lung constantly encounters airborne substances, including pathogens, many researchers have considered infection to trigger sarcoidosis and have thus tried to identify possible causative transmissible agents and their contribution to the mechanism of sarcoid granuloma formation [15, 16].

2.1. Bacterial culture from tissue samples affected by sarcoidosis

In the late 1970s, a large Japanese research project conducted by many clinicians and microbiologists with support by a grant from Japanese Ministry of Health was organized to seek the pathogens responsible for sarcoidosis. Extensive trials were performed to isolate microorganisms, including bacteria, viruses, and fungi, from tissue samples (especially biopsied lymph nodes) affected by sarcoidosis. Only *P. acnes*, and no other microorganism, was isolated from the large number of samples [13]. *P. acnes* was isolated in culture from biopsy samples of 31 (78%) of 40 lymph nodes from 40 patients with sarcoidosis [14], whereas this indigenous bacterium was also cultured from 20% of 141 control lymph nodes from patients with diseases other than sarcoidosis. The study was repeated twice to confirm that the initial samples had not been contaminated by cutaneous *P. acnes* during biopsy, and the results of both studies were the same.

2.2. Bacterial culture from tissue samples without sarcoidosis

Ishige *et al* cultured peripheral lung tissue and various lymph nodes obtained from patients with diseases other than sarcoidosis [17]. *P. acnes* was isolated from 24 of 43 lungs and 8 of 11 mediastinal lymph nodes, mostly in pure culture. *P. acnes* was isolated from 10 of 20 gastric and 3 of 12 intestinal lymph nodes; intestinal bacteria were also numerous. *P. acnes* was generally the only species isolated from these tissues. The number of *P. acnes* cells isolated was usually no more than 500 colony forming units (CFU)/g in the lungs and lymph nodes. Of 43 lungs from patients without sarcoidosis, only 4 (9%) had exceptionally high numbers of *P. acnes* cells. Random amplified polymorphic DNA analysis was used to compare the DNA of 45 isolates of *P. acnes* from these patients, 39 isolates from sarcoid lymph nodes, and 67 isolates from normal skin, conjunctiva, and intestine. The *P. acnes* strains in the lung and mediastinal lymph nodes differed genetically from those in the skin. Therefore, contamination from the skin during operative or culture procedures seems unlikely. These findings suggest that *P. acnes* normally resides in peripheral lung tissue and mediastinal lymph nodes.

2.3. Cell invasiveness of *P. acnes*

Studies of cell-invading *P. acnes* are essential for linking this indigenous bacterium to the cause of sarcoidosis because infectious granulomas are commonly caused by intracellular pathogens. Furukawa *et al* examined the cell invasiveness and serotype of *P. acnes* isolates from lymph nodes affected by sarcoidosis, together with isolates from non-sarcoid tissue obtained from the lymph nodes, lungs, prostate, skin, conjunctiva, and intestine [18]. The invasiveness of these *P. acnes* isolates into HEK293T cells was examined by cell-invasion assay according to the method described by Cue and Cleary [19] and intracellular localization of the invasive isolates was confirmed by electron microscopy (Figure 1). Cell invasiveness was found in 14 (40%) of 35 sarcoid isolates and 65 (51%) of 127 non-sarcoid isolates. The proportion of invasive isolates did not differ between isolates from sarcoid and non-sarcoid tissues. The whole-bacterium enzyme-linked immunosorbent assays with serotype-specific antibodies discriminated the serotype of all 162 isolates (112 strains of serotype I and 50 strains of serotype II). The proportion of the two serotypes did not differ between sarcoid and non-sarcoid tissues. Cell invasiveness was found in 79 (71%) of 112 serotype I isolates and in none of 50 serotype II isolates.

3. Polymerase chain reaction

Some investigators in Europe using PCR assays detected mycobacterial DNA in samples of affected tissue from patients with sarcoidosis [20-22], but others did not [23-25]. Quantification of the bacterial genomes detected in sarcoid lesions is essential for clarifying the etiologic correlation between lesions and bacteria detected therein because a tiny volume of bacteria or bacterial DNA can be detected even in conditions of latent infection or contamination with no etiologic correlation.

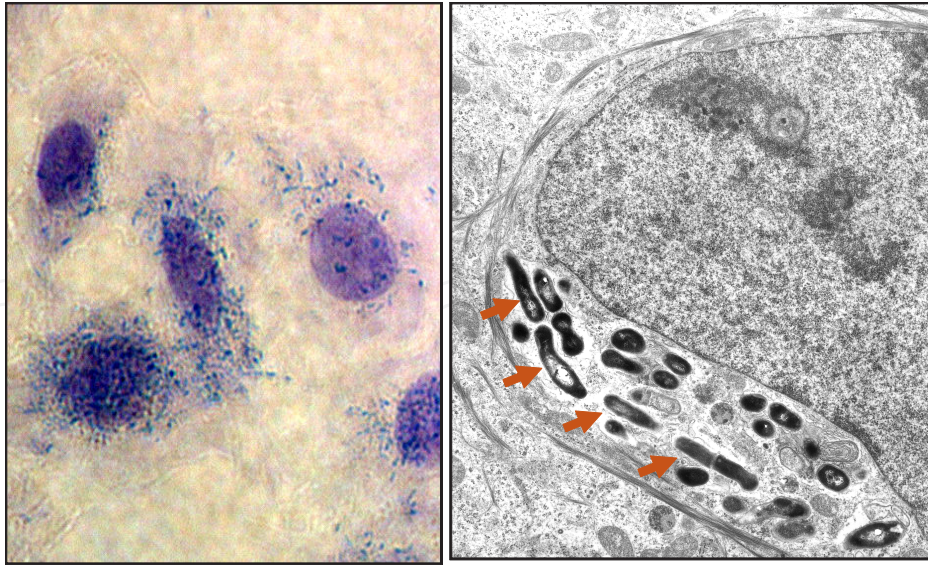


Figure 1. Invasiveness of *P. acnes* into epithelial cells. HEK293T cells infected with one of the serotype 1 *P. acnes* strains isolated from sarcoid lymph nodes were Giemsa-stained (left) and further examined by electron microscopy (right). The electron micrographs of the cells infected with an invasive isolate show intracellular localization of the bacterium (indicated by the red arrows).

3.1. Quantitative PCR for propionibacterial and mycobacterial DNA

Ishige *et al* used quantitative PCR to search for bacterial genomes of *P. acnes*, *P. granulosum*, and *M. tuberculosis* in histologic sections of lymph nodes from patients with sarcoidosis, tuberculosis, or gastric cancer [26]. They examined lymph node biopsy samples from 15 patients with sarcoidosis and 15 patients with tuberculosis lymphadenitis. As controls, they examined 15 lymph nodes without metastasis from 15 patients with gastric cancer undergoing surgery (Figure 2). Genomes of *M. tuberculosis* were found in samples from all 15 patients with tuberculosis, 3 patients with sarcoidosis, and 1 control sample. Genomes of *P. acnes* were found in 12 of 15 patients with sarcoidosis, 2 tuberculosis patients, and 3 controls. The difference in the estimated number of *P. acnes* genomes between individuals with and without sarcoidosis was similar to that in the number of *M. tuberculosis* between people with and without tuberculosis. Biopsy samples from the three patients with sarcoidosis but without *P. acnes* all contained many *P. granulosum* DNA. These findings suggest that propionibacteria resided in or proliferated ectopically in the sarcoid lesions, whether or not there was a connection with the disease. Propionibacteria are more likely than mycobacteria to cause sarcoidosis.

3.2. International collaborative study with quantitative real-time PCR

The international collaborative study evaluated the possible etiologic link between sarcoidosis and the suspected bacterial species [8]. Formalin-fixed and paraffin-embedded sections of biopsy samples of lymph nodes, 1 from each of 108 patients with sarcoidosis and 65 patients with tuberculosis, together with 86 control samples, were collected from 2 institutes in Japan and 3 institutes in Italy, Germany, and England (Figure 3). Genomes of *P. acnes*, *P. granulosum*, *M. tuberculosis*, *M. avium* subsp. *paratuberculosis*, and *Escherichia coli* (as the control) were estimated by quantitative real-time PCR. Either *P. acnes* or *P. granulosum* was found in all but

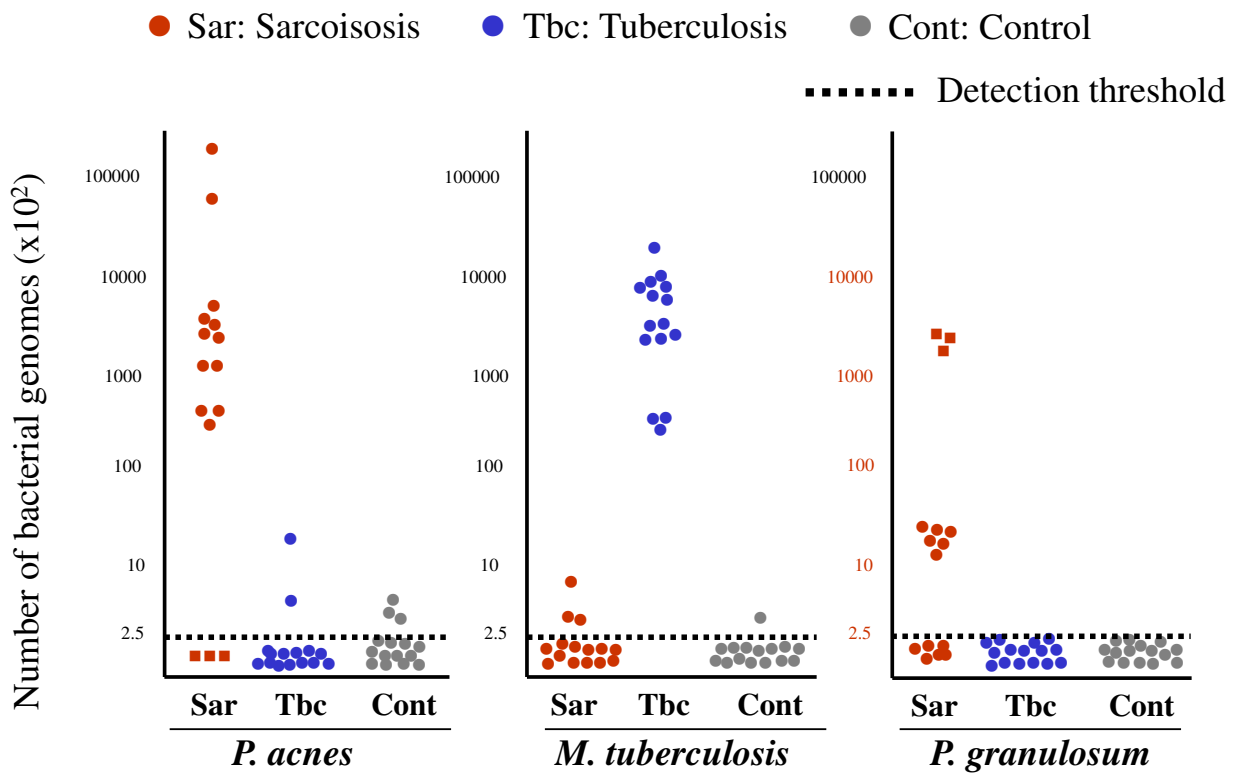


Figure 2. Quantitative PCR of bacterial DNA in lymph nodes from patients with sarcoidosis, tuberculosis, and gastric cancer. The horizontal dotted lines show the detection threshold and samples with results under this line were considered negative.

two of the sarcoid samples. *M. avium* subsp. *paratuberculosis* was not found in any sarcoid sample. *M. tuberculosis* was found in only 0% to 9% of the sarcoid samples, but in 65% to 100% of the tuberculosis samples. In sarcoid lymph nodes, the total numbers of genomes of *P. acnes* or *P. granulorum* far exceeded those of *M. tuberculosis*. *P. acnes* or *P. granulorum* was found in 0% to 60% of the tuberculosis and control samples, but the total numbers of genomes of *P. acnes* or *P. granulorum* in these samples were lower than those found in sarcoid samples. *Propionibacteria* spp. are more likely than *Mycobacteria* spp. to be involved in the etiology of sarcoidosis, not only in Japanese but also in European patients with sarcoidosis.

4. *In situ* hybridization

In situ localization of *P. acnes* genomes in sarcoid lymph nodes may help to elucidate an etiologic link between sarcoidosis and this indigenous bacterium. Formalin-fixed and paraffin-embedded biopsy samples of lymph nodes from nine patients with sarcoidosis, nine patients with tuberculosis, and nine patients with nonspecific lymphadenitis as controls were examined by quantitative real-time PCR (QPCR) for *P. acnes* and by *in situ* hybridization (ISH) using catalyzed reporter deposition (CARD) for signal amplification with digoxigenin-labeled oligonucleotide probes that complemented 16S rRNA of *P. acnes* [27]. The signals per 250 μm^2 of tissue sections from inside and outside sarcoidosis and tuberculosis granulomas and

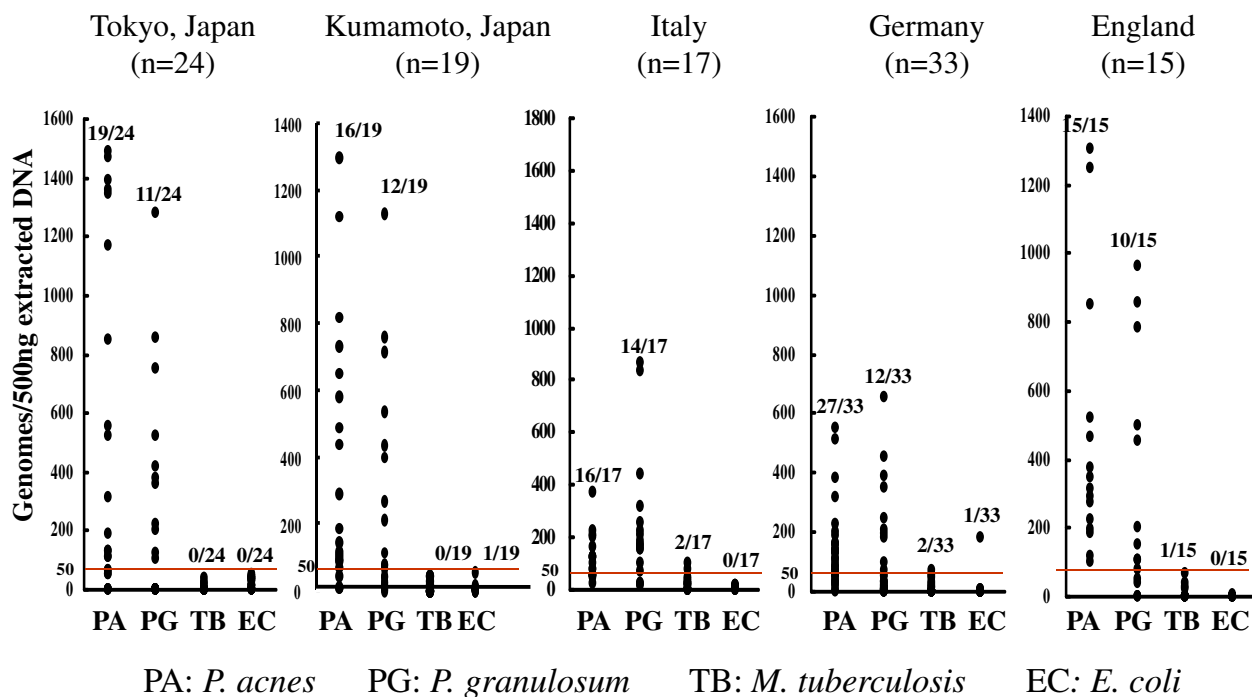


Figure 3. Quantitative real-time PCR of bacterial DNA in lymph node samples from Japanese and European patients with sarcoidosis. The horizontal red lines show the detection threshold and samples with results under this line were considered negative.

from control lymph nodes were counted. The number of genomes determined by QPCR was examined for correlation with the mean signal count by ISH with CARD. In sarcoid samples, one or several signals were detected in the cytoplasm of some epithelioid cells in granulomas (Figure 4). The mean signal counts were higher in granulomatous areas than in other areas of sarcoid lymph nodes. The correlation between the QPCR and ISH with CARD results was significant ($r = 0.86$, $p < 0.001$). The accumulation of *P. acnes* genomes in and around sarcoid granulomas suggests that this indigenous bacterium is related to the cause of granulomatous inflammation in sarcoidosis.

5. Immunohistochemistry

Granulomatous reactions are basically a defense mechanism that the body uses to fight off poorly degradable antigens. Granulomas begin as a small collection of lymphocytes and macrophages surrounding poorly degradable antigens. The aggregating macrophages, called an early focus of granuloma, then change to epithelioid cells and become organized into a cluster of cells, called an immature granuloma. Further progression results in ball-like clusters of cells and fusion of macrophages into giant cells, called a mature granuloma. The questions that must be asked in searching for the cause of sarcoidosis, therefore, are: "What is the antigen that the granulomas are fighting?" and "How is the antigen localized within the sarcoid lesion?" To evaluate the pathogenic role of *P. acnes*, Negi *et al* screened for this indigenous bacterium in sarcoid and non-sarcoid tissues using immunohistochemical methods with novel *P. acnes*-specific monoclonal antibodies that react with cell-membrane-bound lipoteichoic acid

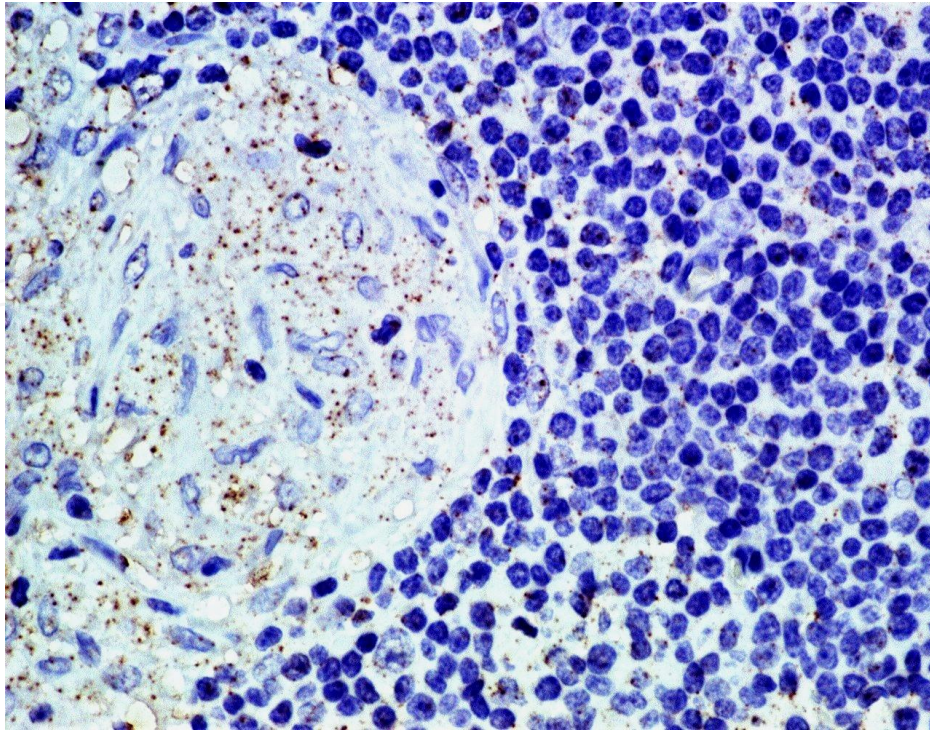


Figure 4. *In situ* hybridization using catalyzed reporter deposition for signal amplification with digoxigenin-labeled oligonucleotide probes that complemented 16S rRNA of *P. acnes*. Many signals were detected in the cytoplasm of sarcoid granuloma cells.

(PAB antibody) and ribosome-bound trigger factor protein (TIG antibody). They examined formalin-fixed and paraffin-embedded samples of lungs and lymph nodes from 196 patients with sarcoidosis, and corresponding control samples from 275 patients with non-sarcoidosis diseases. The samples were mostly from Japanese patients, with 64 lymph node samples from German patients [28].

5.1. Intracellular *P. acnes* detected within sarcoid granuloma

Immunohistochemistry with the PAB antibody revealed small round bodies within sarcoid granulomas in 20/27 (74%) video-assisted thoracic surgery lung samples, 24/50 (48%) trans-bronchial lung biopsy samples, 71/81 (88%) Japanese lymph node samples, and 34/38 (89%) German lymph node samples. The PAB antibody did not react with non-sarcoid granulomas in any of the 45 tuberculosis samples or the 34 samples with sarcoid reaction. The appearance of the small round bodies detected by the PAB antibody within sarcoid granulomas did not differ between lungs and lymph nodes. In sarcoid granulomas with many small round bodies, the cytoplasm of some granuloma cells was filled with small round bodies, consistent with the intracellular proliferation of the bacterium (Figure 5). In many sarcoid granulomas, a few small round bodies with occasional degraded or large-sized features were scattered among the granuloma cells. The amount of these small round bodies varied from each granuloma in identical sarcoid samples as well as from each sarcoid tissue sample (Figure 6). The appearance of the small round bodies detected by the PAB antibody within sarcoid granulomas did not differ between lungs and lymph nodes (Figure 7, 8).

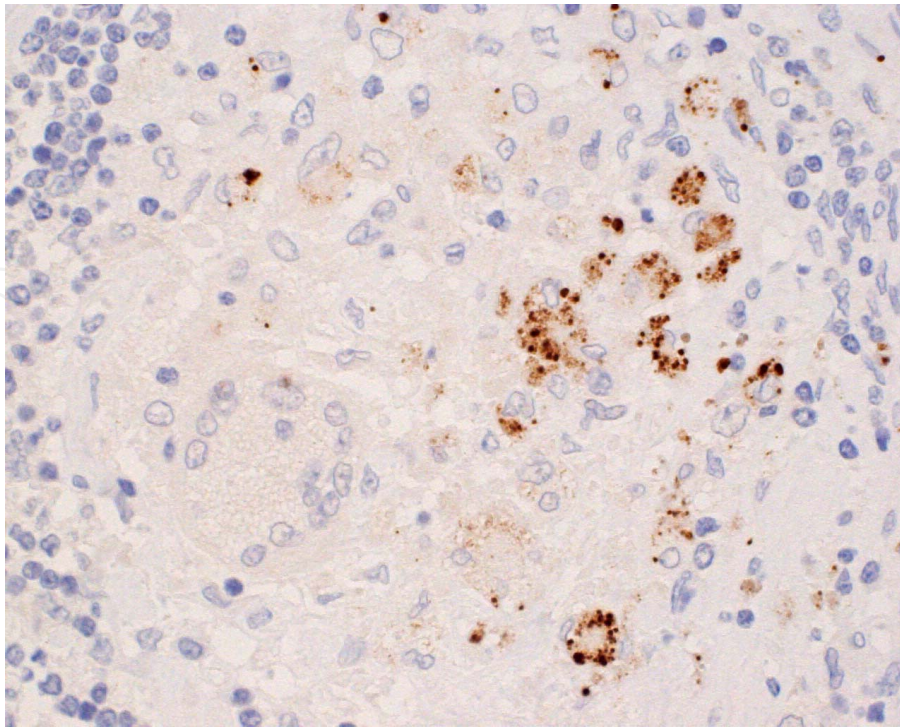


Figure 5. Immunohistochemistry with a *P. acnes*-specific monoclonal antibody (PAB antibody) that reacts with cell-membrane-bound lipoteichoic acid of the bacterium. Many small round bodies are shown within a non-caseating epithelioid cell granuloma of sarcoid lymph node.

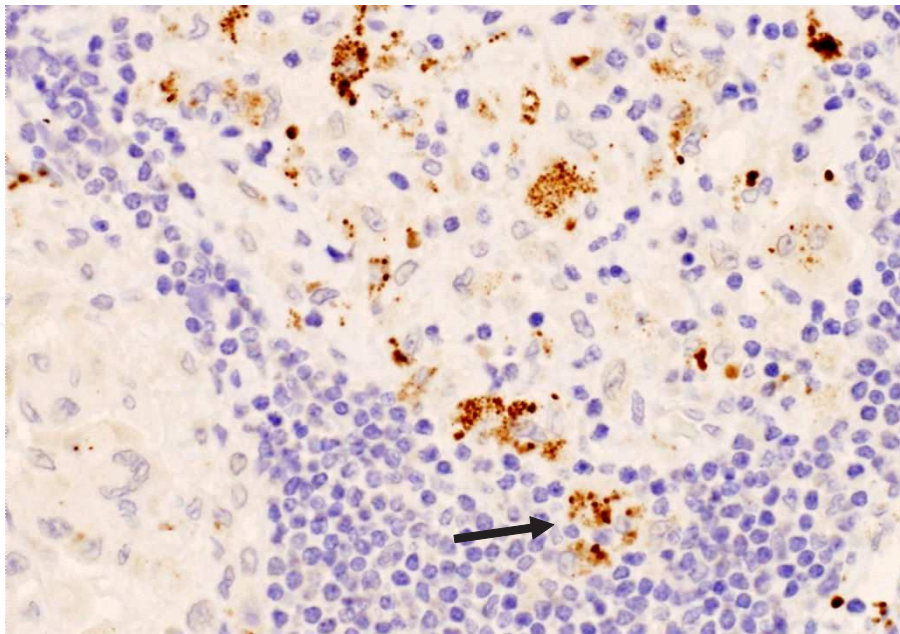


Figure 6. Many small round bodies detected by the PAB antibody are shown intermingled with many lymphocytes in one immature granuloma (right), but only a few are observed in the mature granuloma (left) of the sarcoid lymph node. Most of the *P. acnes* are present within the granuloma, but some are present outside of the granuloma (as indicated by the arrow).

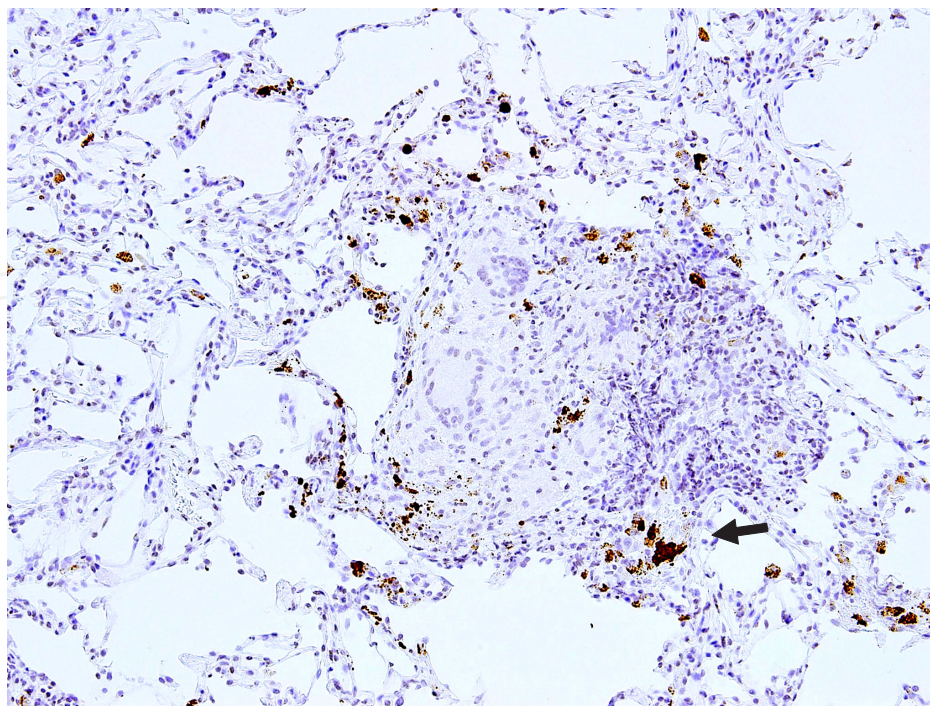


Figure 7. In the lung sarcoid granuloma lesion surrounded by prominent inflammatory cell infiltration, small round bodies are detected by the PAB antibody not only in the granuloma cells but also in some of the inflammatory cells. The arrow indicates the magnified region shown in Fig. 8.

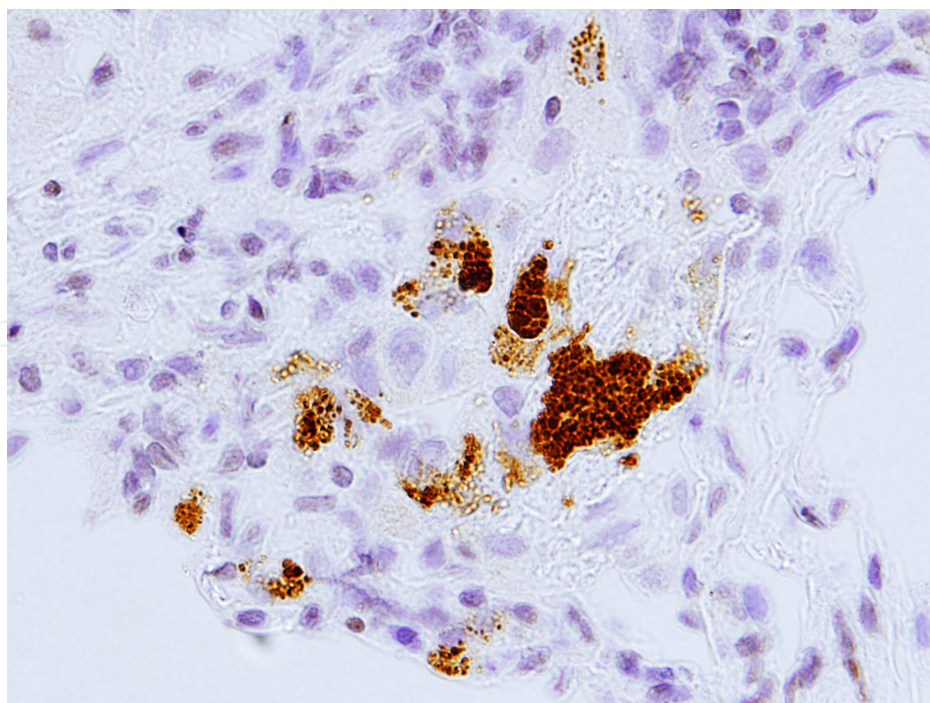


Figure 8. Higher magnification of the area indicated by the arrow in Figure 7. Some swollen macrophages of the immature granuloma are filled with many small round bodies detected by the PAB antibody.

5.2. Intracellular *P. acnes* in non-granulomatous areas

In non-granulomatous areas, small round bodies detected by the PAB antibody were found in alveolar macrophages of lungs and paracortical macrophages of lymph nodes from many sarcoid and some non-sarcoid patients. In the lymph nodes, paracortical macrophages with many small round bodies detected by the PAB antibody (Figure 9) were observed in 26 (22%) of 119 sarcoid samples and 18 (11%) of 165 non-sarcoid samples. The frequency was significantly higher in the sarcoid samples. Such small round bodies were observed in lymphatic endothelial cells in a few samples of sarcoid lymph nodes (Figure 10). In the lungs, alveolar macrophages with many small round bodies detected by the PAB antibody were found in 28 (36%) of 77 sarcoid samples and 18 (16%) of 110 non-sarcoid samples. The frequency was significantly higher in sarcoid samples. Such alveolar macrophages occasionally contained one or a few large spheroidal bodies detected by the PAB antibody that were acid-fast with Fite staining and also reacted with the TIG antibody.

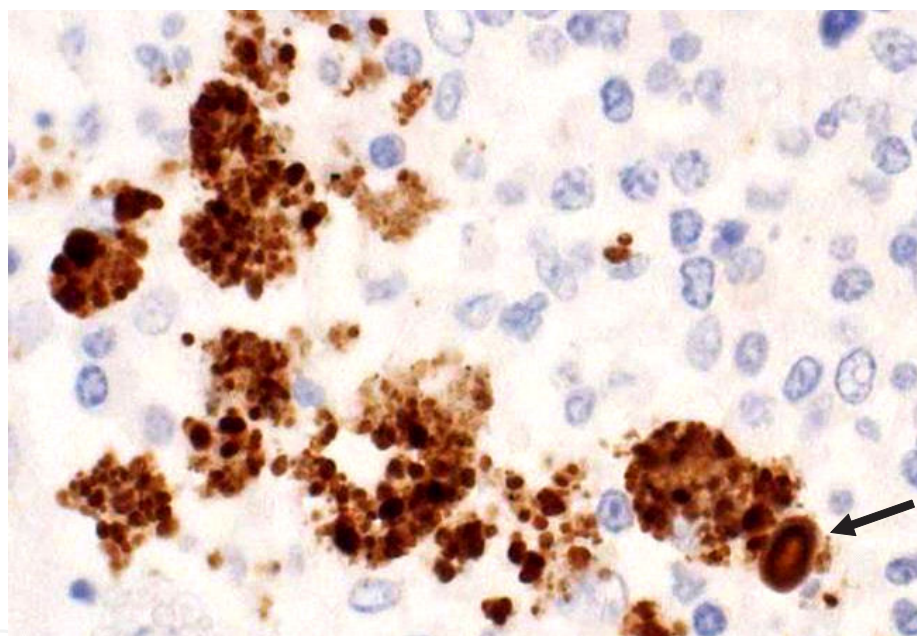


Figure 9. A cluster of some swollen macrophages filled with many small round bodies detected by the PAB antibody is occasionally found in paracortical areas of sarcoid lymph nodes. The arrow indicates a large-spheroidal body similar to Hamazaki-Wesenberg bodies.

5.3. Hamazaki-Wesenberg bodies

Hamazaki-Wesenberg (HW) bodies frequently appear in sarcoid lymph nodes although these bodies are not specific to sarcoidosis [29-31]. The large-spheroidal acid-fast bodies, HW bodies, which were found in 50% of sarcoid and 15% of non-sarcoid lymph node samples, reacted with both PAB and TIG antibodies. Electron microscopy revealed that these HW bodies had a single bacterial structure and lacked a cell wall with occasional protrusions from the body (Figure 11). Immunoelectron microscopy revealed that the immunoreactive products of the PAB

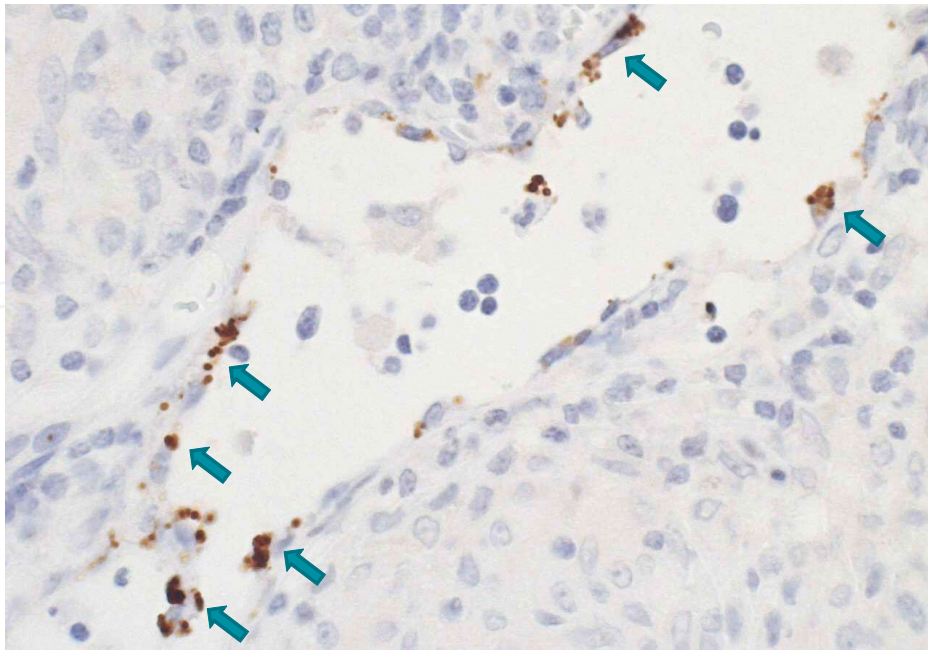


Figure 10. Some of the small round bodies detected by the PAB antibody (green arrows) were observed in lymphatic endothelial cells adjacent to sarcoid granulomas of the lymph node.

antibody and TIG antibody were differentially distributed in the outer and inner areas of the HW bodies, respectively (Figure 12). The localization of cell-membrane-bound lipoteichoic acid detected by the PAB antibody and ribosome-bound trigger factor detected by the TIG antibody suggests that HW might not be phagolysosomally-degraded products of *P. acnes*, but rather intact forms of intracellular bacteria because the original distribution pattern (plasma-lemmal and protoplasmic localization, respectively) of these bacterial components was preserved in terms of the morphologic structure of the bacterium. Furthermore, conventional electron microscopy revealed that these bodies lack a cell-wall structure and occasionally exhibit protrusions from the body that appear to be yeast-like proliferating features (not mitotic, but sprouting or branching), characteristic of cell-wall-deficient (L-form) bacteria (Figure 9). HW bodies may be cell-wall-deficient *P. acnes*.

5.4. Intracellular proliferation of *P. acnes*

Histopathologic analysis with the PAB antibody led us to formulate a hypothesis for the mechanism of granuloma formation in sarcoidosis (Figure 13). *P. acnes* causes latent infection and persists in macrophages. HW bodies are dormant and cell-wall-deficient *P. acnes*. This dormant form of *P. acnes* can be activated endogenously under certain environmental conditions and proliferate in cells at the sites of latent infection. Small round bodies proliferating in macrophages are infective forms of *P. acnes*. When these bodies spread out of macrophages, they infect other cells or organs via the lymph and blood streams. Sarcoid granulomas are formed as a host defense mechanism at the sites of activated bacteria proliferating intracellularly in patients with hypersensitive immune responses to *P. acnes* to prevent the spread of the infectious agent.

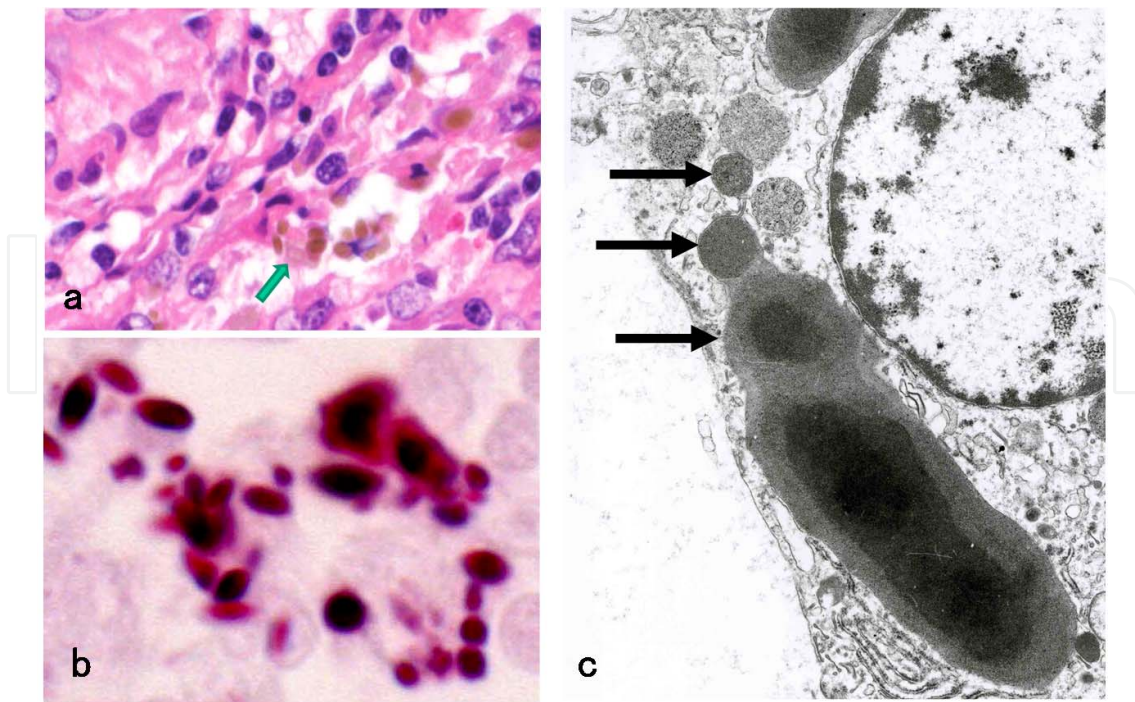


Figure 11. Hamazaki-Wesenberg (HW) bodies in sarcoid lymph nodes. HW bodies are large and spheroidal in shape with a yellow-brown color, as indicated by the green arrow, with hematoxylin and eosin staining (a). These bodies are strongly acid-fast with Fite staining (b). HW bodies with one-by-one protrusions (c), as indicated by black arrows, are rarely found in sinus macrophages of sarcoid lymph nodes.

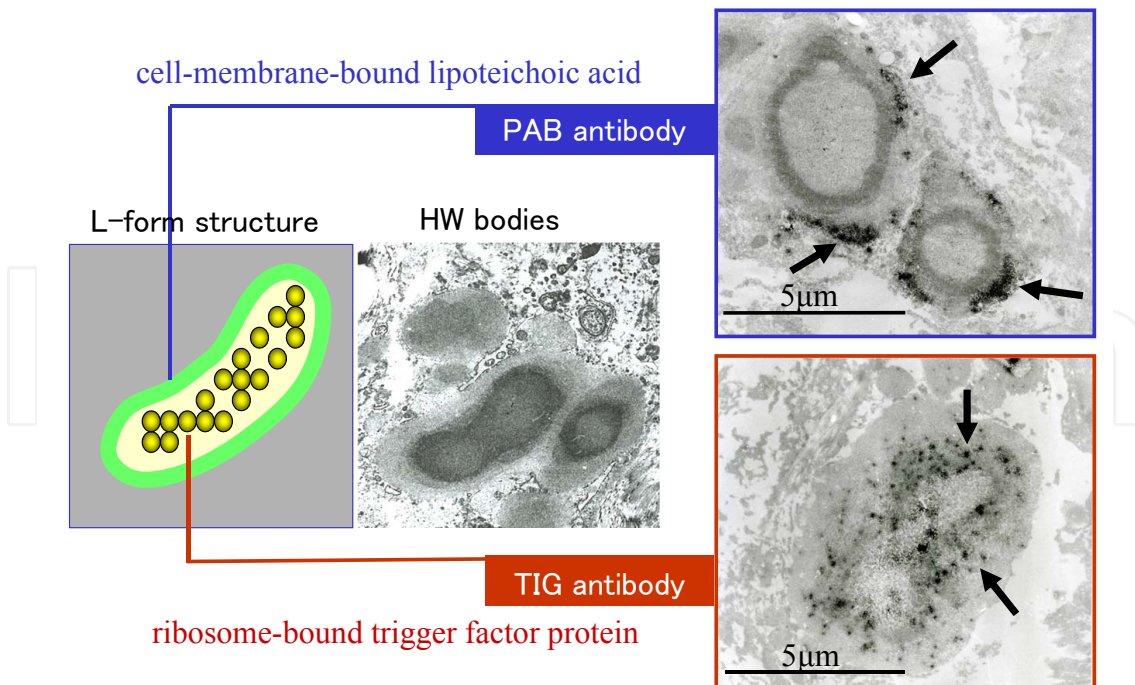


Figure 12. Immuno-electron-microscopic analysis with PAB and TIG antibodies suggests HW bodies may be cell-wall-deficient *P. acnes*.

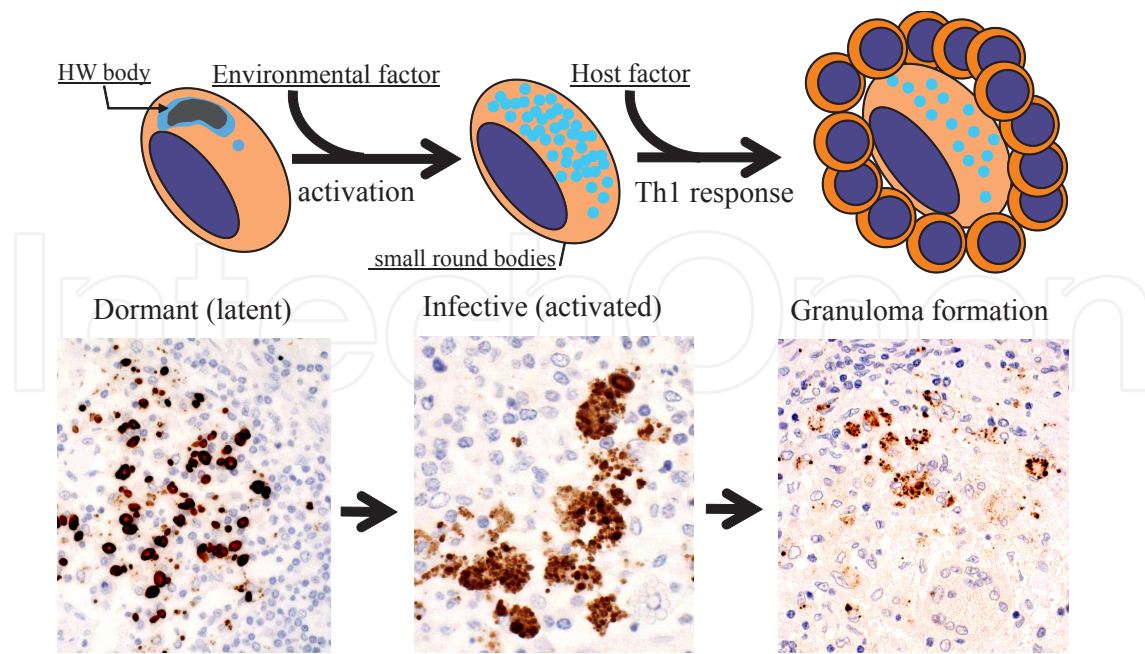


Figure 13. Hypothesized mechanism of sarcoid granuloma formation caused by *P. acnes*. Intracellular proliferation of *P. acnes* in macrophages triggers granuloma formation in patients with hypersensitivity to this indigenous bacterium.

5.5. Histopathological diagnosis of sarcoidosis by the PAB antibody

The PAB antibody seems to be appropriate for detecting cell-wall-deficient *P. acnes* because an epitope of lipoteichoic acid detected by this antibody is more exposed in cell-wall-deficient forms than in conventional forms of the bacterium. The high frequency and specificity of *P. acnes* detected by the PAB antibody within sarcoid granulomas suggests an etiologic link between sarcoidosis and this indigenous bacterium. The PAB antibody may be useful for diagnosing sarcoidosis caused by *P. acnes*, when the reactivity is detected in idiopathic granulomas (Figures 14, 15). The TIG antibody seems to be appropriate for detecting latent forms of *P. acnes* because increased expression of the trigger-factor protein is found only in the HW bodies. The trigger-factor protein is a molecular chaperone, like some heat-shock proteins, and either overproduction or depletion of the trigger-factor protein causes filamentation indicative of cell division defects. Increased expression of the trigger-factor protein in HW bodies might be necessary to sustain the latent phase of intracellular persistent bacterium.

6. Host factor

Host factors may be more critical than agent factors in the etiology of sarcoidosis, as suggested by the Kveim test phenomenon [32], in which an intracutaneously injected suspension of sarcoid tissue causes sarcoid granulomas in patients with sarcoidosis but not in healthy people or patients with other diseases. The inflammatory response in sarcoidosis involves many activated T cells and macrophages [33], with a pattern of cytokine production in the lungs

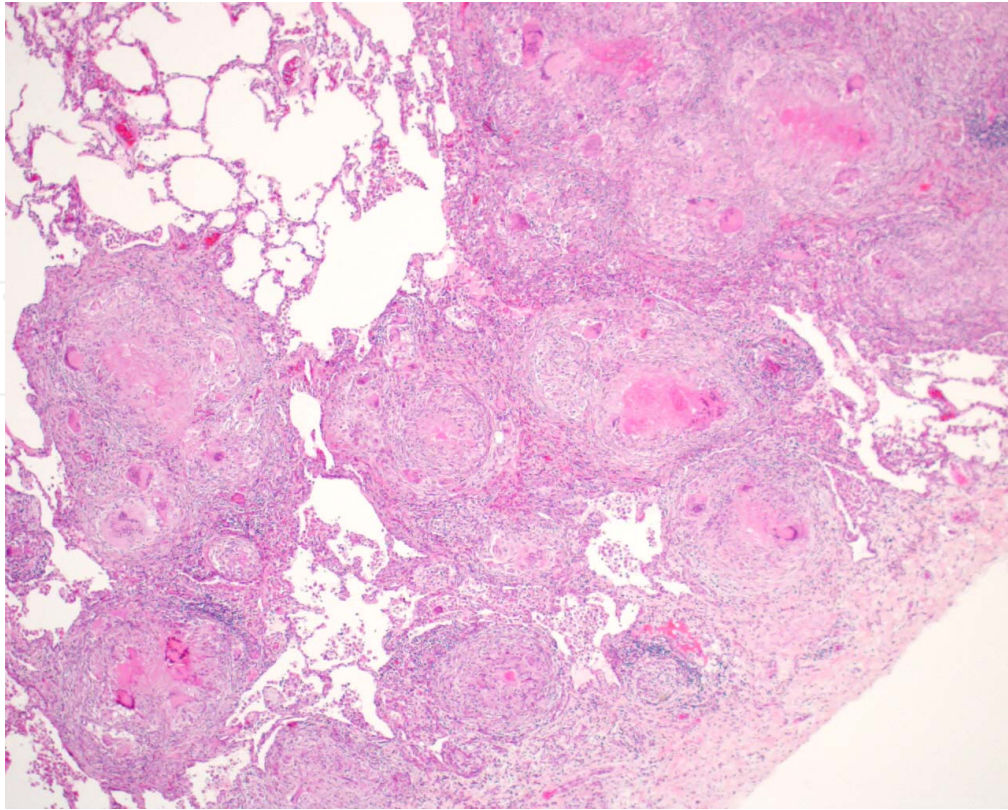


Figure 14. A lung sample with many epithelioid cell granulomas with central eosinophilic necrosis. This case required differential diagnosis from tuberculosis although the specimen contained no acid-fast bacilli and the clinical data of the patient suggested sarcoidosis.

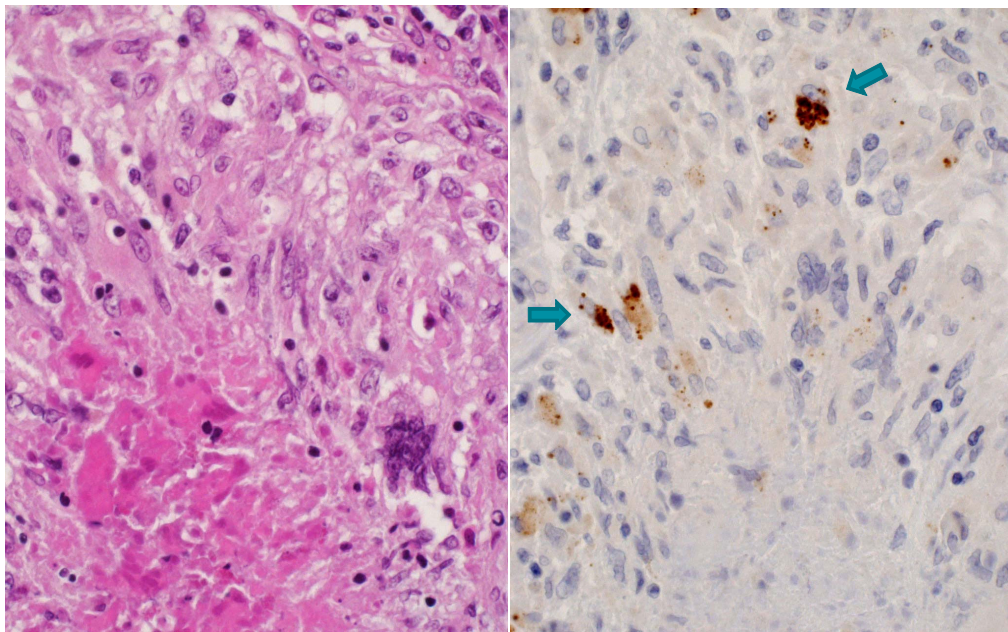


Figure 15. Immunohistochemistry with the PAB antibody for the specimen shown in Figure 14 revealed positive reaction products (green arrows) within granulomas accompanied by central eosinophilic necrosis.

consistent with a helper T-cell type 1 (Th1) immune response triggered by undefined antigen(s) [34]. If a propionibacterium caused a particular case of sarcoidosis, it is likely that an antigen arising from the bacterium gave rise to a Th1 immune response in the subject.

6.1. Hypersensitivity to *P. acnes* antigens

Ebe and colleagues searched for propionibacterial antigens that evoked cellular immune responses only in patients with sarcoidosis [11]. For this purpose, a λ gt11 genomic DNA library of *P. acnes* was screened with sera from patients with sarcoidosis, because high levels of serum antibodies against the antigen usually accompany such an immune response. Of 180,000 plaques screened, 2 clones coded for an identical recombinant protein, RP35, recognized by sera. RP35, a recombinant protein of 256 amino acid residues with a calculated molecular mass of 28,133 Da, is a fragment (the C-terminal region) of the *P. acnes* trigger factor, which has 529 amino acid residues and a calculated molecular mass of 57,614 Da. The C-terminal sequence (Asp-463 to Lys-529) seems to be unique to *P. acnes*, with no similarity to sequences of other bacterial proteins deposited in the Swiss-Prot database. Conformational analysis of the Ser-491 to Lys-529 region at the C terminus revealed it to be highly antigenic. RP35 caused sarcoidosis-specific proliferation of peripheral blood mononuclear cells (PBMCs) from 9 (18%) of 50 patients with sarcoidosis (Figure 16). The same study established that serum levels of IgG and IgA antibodies to RP35 are high in patients with sarcoidosis and other lung diseases. In bronchoalveolar lavage (BAL) fluid, IgG and IgA antibody levels were high in 7 (18%) and 15 (39%), respectively, of 38 patients with sarcoidosis, and in 2 (3%) and 2 (3%), respectively, of 63 patients with other lung diseases. The results of the study suggested that this antigen from *P. acnes* is responsible for the formation or maintenance of granulomas in some patients with sarcoidosis.

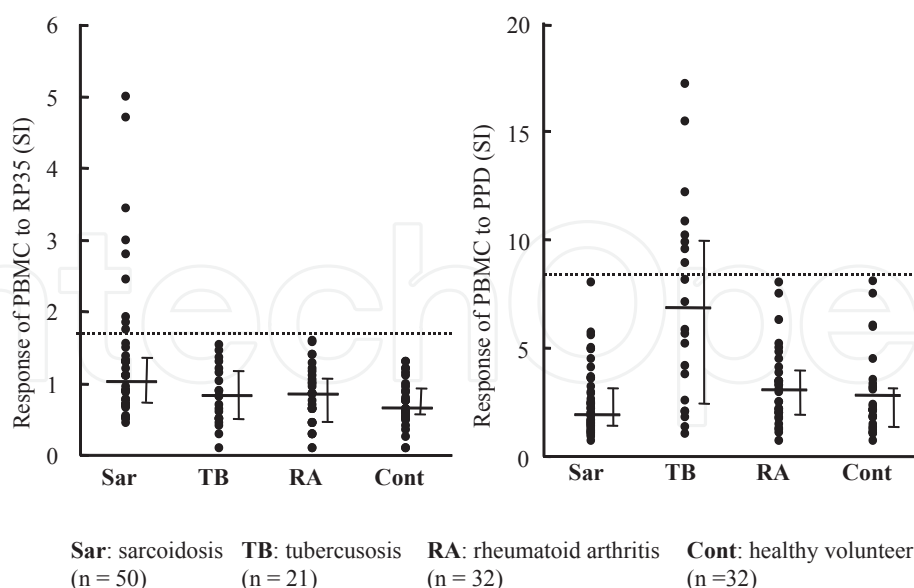


Figure 16. Response of peripheral blood mononuclear cells (PBMC) to recombinant trigger factor protein (RP35) from *P. acnes* and purified protein derivative (PPD) from *M. tuberculosis*. The horizontal bars show, from bottom to top, the 25th percentile, median, and 75th percentile, respectively. The dotted lines show the threshold, set at the mean + 3SD of the 32 control samples.

Recently, Furusawa *et al* [35] reported that interleukin-2 secretion from PBMCs after stimulation with viable *P. acnes* is higher in patients with sarcoidosis than in control subjects. Interleukin-2 and interleukin-12 mRNA expression of PBMCs after stimulation with *P. acnes* is also higher in patients with sarcoidosis than in control subjects. In contrast, interleukin-17 mRNA expression of PBMCs is lower in patients with sarcoidosis than in control subjects. The responses of the two groups to stimulation with *M. tuberculosis* antigens such as Bacille de Calmette et Guérin (BCG) or ESAT-6 recombinant protein were not significantly different. Sarcoidosis may arise from an imbalance of Th1/Th17 immune responses to viable *P. acnes*.

Additional evidence of the hypersensitivity of sarcoid patients to *P. acnes* was obtained in studies of BAL cells. When stimulated with a crude extract of *P. acnes* with pyridine, BAL cells from patients with sarcoidosis proliferated more than BAL cells from healthy subjects or from patients with lung cancer [36]. Interleukin-2 production and interleukin-2 receptor expression of BAL cells stimulated by the *P. acnes* antigen was greater in sarcoidosis patients than in healthy subjects or patients with other lung diseases [37]. *P. acnes* DNA was detected in BAL cells from 21 (70%) of 30 sarcoid patients and 7 (23%) of 30 control patients with other lung diseases [38]. In situ signals of *P. acnes* DNA were detected in the cytoplasm of a few alveolar macrophages among the BAL cells from sarcoid patients, but from no other kinds of BAL cells, including alveolar lymphocytes and neutrophils. Gallium-67 uptake by lung parenchyma was found in about half of the 30 sarcoid patients with *P. acnes* DNA, but in none of the other sarcoid patients [38].

6.2. NOD1 gene polymorphism

Mutations in the related NOD2 gene predispose patients to granulomatous diseases, including Crohn's disease [39], Blau syndrome [40], and early-onset sarcoidosis [41]. Although Blau syndrome and early-onset sarcoidosis are reported to share identical NOD2 mutations, no association has been reported between NOD2 and sarcoidosis [42]. NOD1 shares many structural and functional similarities with NOD2. Tanabe *et al* found that intracellular *P. acnes* activates NF- κ B in both an NOD1- and NOD2-dependent manner [43]. A systematic search for NOD1 gene polymorphisms in Japanese sarcoidosis patients identified two alleles, 796G-haplotype (156C, 483C, 796G, 1722G) and 796A-haplotype (156G, 483T, 796A, 1722A). Allelic discrimination of 73 sarcoidosis patients and 215 healthy individuals showed that the frequency of the 796A-type allele is significantly higher in sarcoidosis patients and the odds ratios (ORs) are significantly elevated in NOD1-796G/A and 796A/A genotypes (OR [95% CI] = 2.250 [1.084, 4.670] and 3.243 [1.402, 7.502], respectively) as compared to the G/G genotype, showing an increasing trend across the 3 genotypes ($P = 0.006$ for trend). Functional studies indicated that the NOD1 796A-allele is associated with reduced expression leading to diminished NF- κ B activation in response to intracellular *P. acnes* (Figure 17).

P. acnes has been studied for its role in immunomodulation with the conclusion that Toll-like receptor 2 (TLR2), TLR4, and TLR9 mediate the effects of *P. acnes* infection [44, 45]. These studies, however, only investigated non-invasive *P. acnes*. TLRs are likely to serve as first-line receptors for *P. acnes*, but NOD proteins might play a major role in a subsequent phase of intracellular infection. NOD1 was recently reported to be a critical regulator of beta-defensin-2

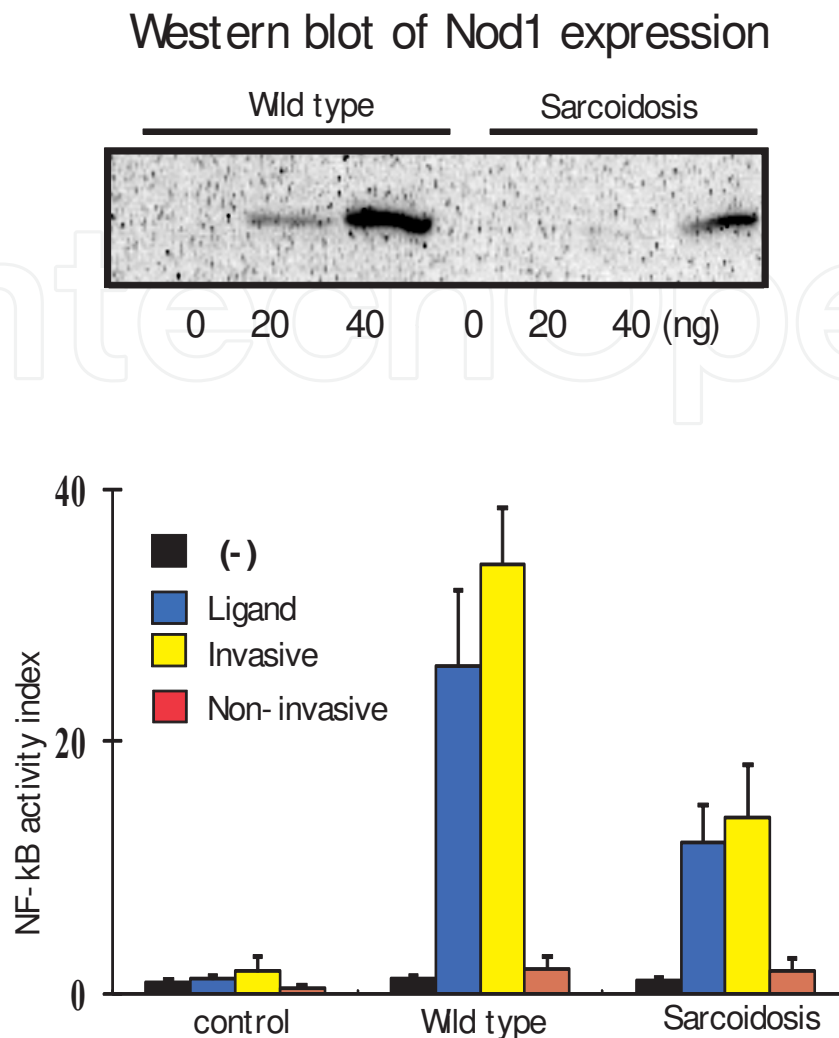


Figure 17. Functional studies (lower panel) revealed that intracellular *P. acnes* activates NF- κ B in a NOD1-dependent manner and the NOD1 796A-allele predominant in sarcoidosis patients causes diminished NF- κ B activation in response to intracellular *P. acnes*. Western blot analysis (upper panel) shows reduced expression of the NOD1 796A-allele.

during *Helicobacter pylori* infection [46]. It is possible that impaired expression of beta-defensin-2 through 796-A NOD1 due to a reduced ability to induce NF- κ B enables *P. acnes* to survive and persist intracellularly, leading to the pathogenesis of sarcoidosis.

7. Experimental models

In experimental animals, granulomatous lesions can be induced by *P. acnes*. A single intravenous injection of *P. acnes* into mice leads to the development of many granulomas in the liver [47-49], but not in the lungs. Pulmonary granulomas can be induced, however, by an intravenous injection of *P. acnes* into sensitized rats [50] and rabbits [51]. In these two studies of

experimental pulmonary granulomas, heat-killed *P. acnes* was used as a sensitizer, and a challenge by a single intravenous injection of the bacterium was essential for granulomas to form in the lungs.

7.1. Pulmonary granulomatosis caused by sensitization with *P. acnes* antigens

P. acnes trigger factor protein (RP35) or heat-killed *P. acnes* causes pulmonary granulomas in some (25%-57%) mice sensitized with the protein and complete Freund's adjuvant (CFA) [52]. An intravenous injection of *P. acnes* as a challenge was not essential for granulomas to form in the lungs. Granulomas were scattered throughout the lungs, especially in subpleural areas (Figure 18). The granulomas were composed of a core of epithelioid cells intermingled with a few and surrounded by many mononuclear cells. The detection frequency of pulmonary granulomas did not differ significantly between mice sensitized with the RP35 or heat-killed *P. acnes*.

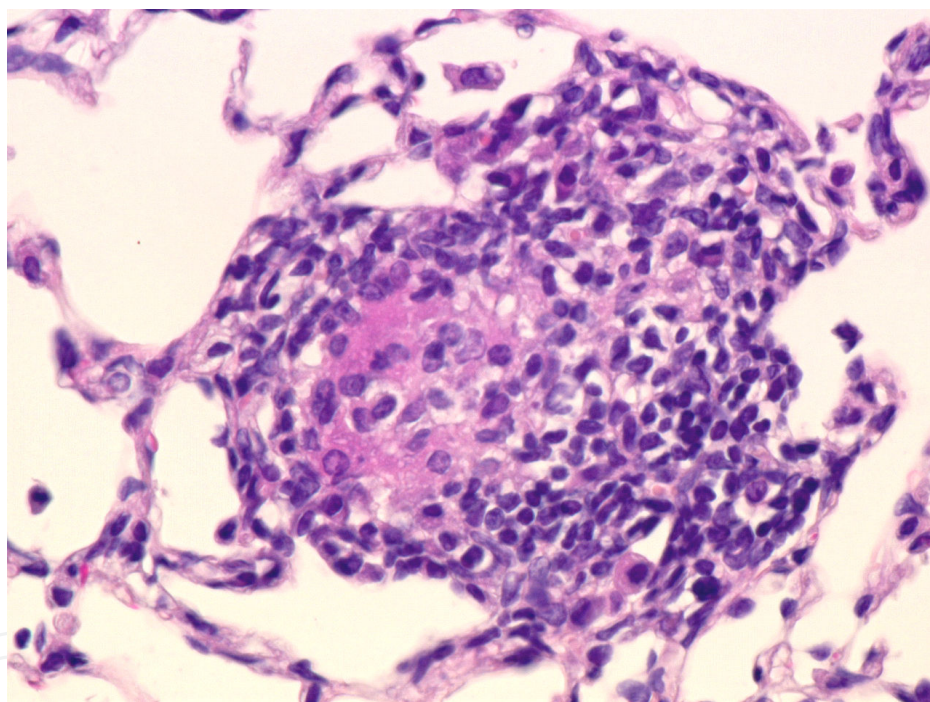


Figure 18. A non-caseating epithelioid cell granuloma observed in a mouse with experimental pulmonary granulomatosis induced by sensitization with *P. acnes* trigger factor protein and adjuvant.

This experimental protocol may provide a satisfactory model of sarcoidosis. First, hypersensitivity to *P. acnes* trigger factor, such as has been experimentally induced, has been reported in some patients with sarcoidosis. Second, situations resembling intravenous challenge with *P. acnes* are rare in humans, and sarcoidosis can start in asymptomatic persons without evidence of septicemia.

Experimental models of allergic diseases, such as encephalomyelitis [53], thyroiditis [54], and orchitis [55] have been produced by immunizing animals with self-antigens (myelin basic

protein, thyroglobulin, and testicular homogenate, respectively) emulsified in CFA, which is essential for the experiment. Autoimmune inflammatory lesions are induced in this way only in the organs from which the self-antigens used for the sensitization originated. In the animal model of sarcoidosis, sensitization of mice with *P. acnes* trigger factor protein or heat-killed *P. acnes* in CFA induces granulomatous inflammation confined to the lungs. This finding suggests that such antigens from *P. acnes* exist in the lungs of mice even before the experiment.

Similar to the results obtained by bacterial culture of human samples from lung and lymph nodes, *P. acnes* was cultured from the lungs, liver, and lymph nodes from some of the untreated normal mice, and culture was most often successful with the lungs. There was an unexpected concordance in the rate (33%) of culture from normal lungs and the frequency of detection of pulmonary granulomas in mice sensitized with the trigger factor protein. The concordance suggests that mice without granulomas may have been free from *P. acnes* in the normal indigenous flora of their lungs before and during the experiment.

Using the same experimental protocol with rabbits bred in a conventional environment, rabbits sensitized with the *P. acnes* trigger factor antigen developed more severe and diffuse pulmonary granulomatosis than did sensitized mice. In fact, the severe granulomatous inflammation that developed could even be identified macroscopically (Figure 19, 20). Th1 immune response to the *P. acnes* trigger factor protein might have caused pulmonary granulomas at the sites of *P. acnes* infection. Indeed, the administration of antibiotics (azithromycin in mice and minocycline in rabbits) before and during the experiments prevented granuloma formation in these experimental models (Figure 21).

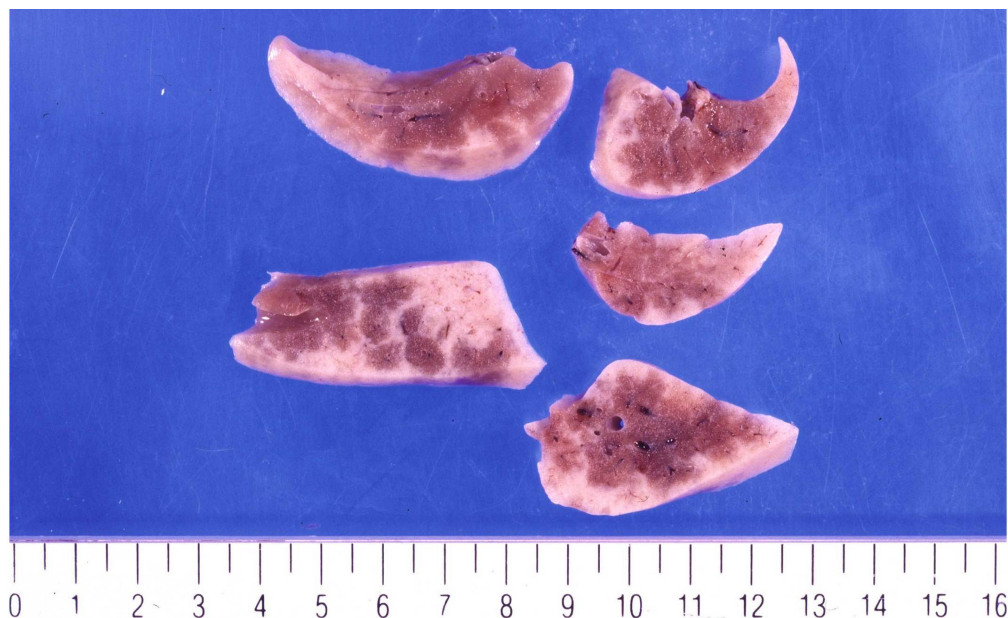


Figure 19. Cut sections of the lungs from a rabbit with experimental pulmonary granulomatosis induced by sensitization with *P. acnes* trigger factor protein and adjuvant. Whitish lesions are distributed throughout and are especially prominent in the subpleural and interlobular areas.

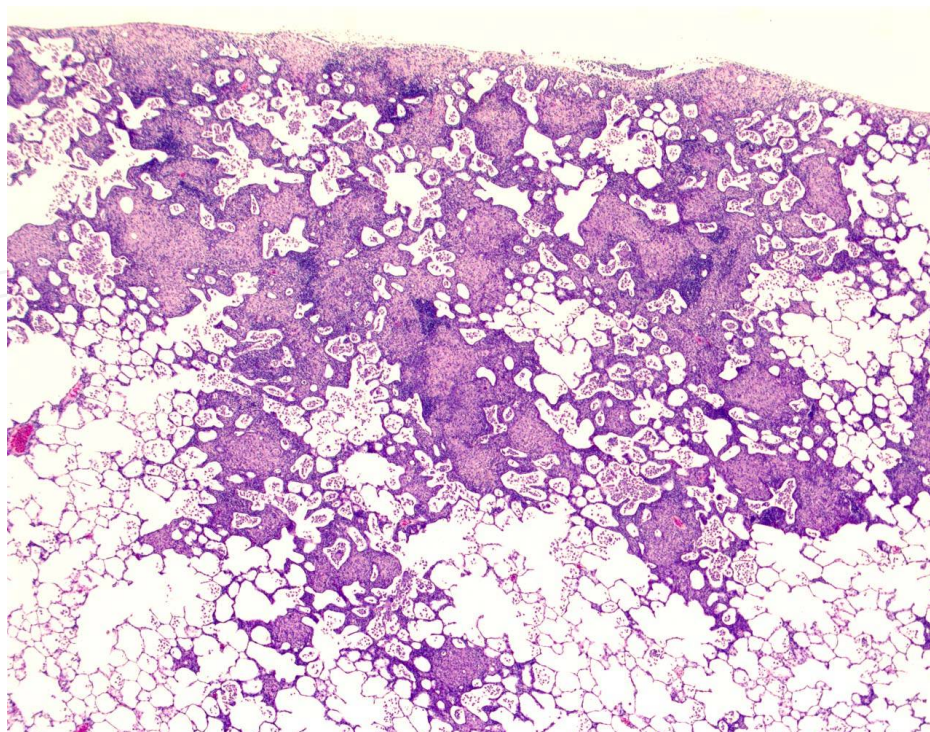


Figure 20. Histologic features of experimental pulmonary granulomatosis of the rabbit shown in Figure 19. Multiple non-caseating epithelioid cell granulomas are accompanied by surrounding lymphoid cell infiltration with alveolitis.

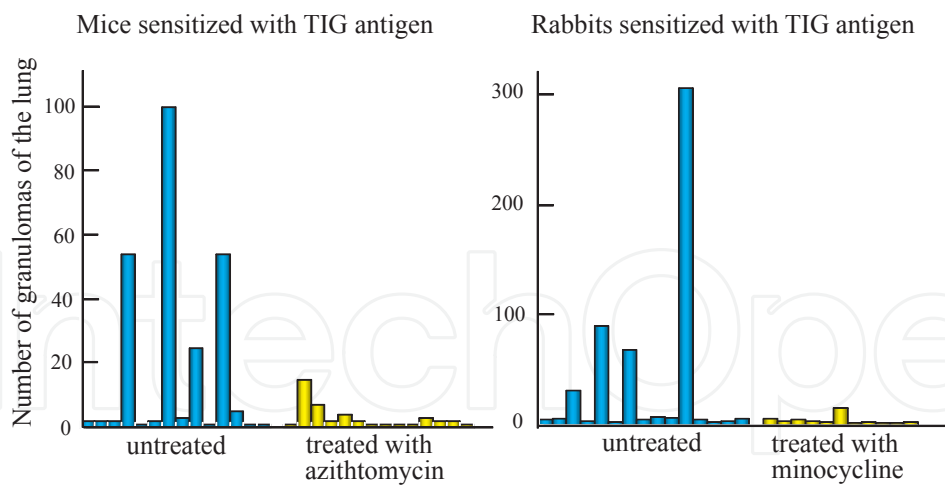


Figure 21. Prevention of pulmonary granulomatosis in mice and rabbits sensitized with *P. acnes* trigger factor (TIG) antigen by administration of antibiotics before and during the experiments.

7.2. Mechanism of granuloma formation in the experimental models

Nishiwaki *et al* further examined the mechanism of pulmonary granulomatosis caused by sensitization of heat-killed *P. acnes* [56], using a similar experimental protocol as used in a

previous study [52]. In the study, *P. acnes* was identified in normal murine alveolar cells by immunostaining with a *P. acnes*-specific monoclonal antibody (PAB antibody). *P. acnes* was taken up by lung cells, and the *P. acnes*-bearing cells expressed F4/80 rather than CD11c or DEC205, consistent with the ability of macrophages to phagocytose and deliver antigens to dendritic cells in the lung. As far away as the end of the airway, airborne organisms are impacted and eliminated by mechanical defenses, including mucociliary clearance and coughing. Nevertheless, a small number of *P. acnes* might escape this system and reside on the alveolar surface. *P. acnes* genomes were detected in normal pulmonary lymph nodes as well as the lungs, and lymphocytes from lymph nodes showed *P. acnes*-specific proliferation, suggesting that these cells had already been exposed to *P. acnes* by lung-derived antigen-presenting-cells and had established a memory response. Additionally, these results indicate that *P. acnes* were continuously transported to pulmonary regional lymph nodes in the steady state. Because of this constant delivery of antigens to the pulmonary lymph nodes for a long period, the small number of indigenous *P. acnes* in the normal lung would be enough to produce a specific immune response, but not for the formation of a steady-state granuloma. Although mycobacterial, atypical mycobacterial, and other propionibacterial antigens are potential candidate endogenous microorganisms that trigger pulmonary granuloma formation, genomic analyses revealed an absence of these organisms in the lungs of specific-pathogen-free C57BL/6 mice.

The adoptive transfer of *P. acnes*-sensitized lymph node CD4⁺ T cells into naïve mice resulted in granulomatous changes in the lung, indicating that extrapulmonary lymph node CD4⁺ T cells primed with *P. acnes* can interact with pulmonary resident cells via the circulation and induce granuloma formation in the normal lung. It was therefore hypothesized that a continuous supply of *P. acnes*-sensitized T cells should lead to chronic pulmonary granuloma formation, and consequently we performed continuous remote sensitization of normal mice with *P. acnes*. These mice exhibited distinct pulmonary granulomas, distributed in lymph-rich spaces such as the subpleural, peribronchial, and perivascular areas, and had typical cellular components of granuloma and preferential Th1 cytokine expression. These features are similar to those of pulmonary sarcoidosis. In addition, the ratio of CD4 to CD8 BAL lymphocytes was elevated in the group immunized twice, and serum calcium levels were also increased. Thus, the characteristics of this *P. acnes*-immunization model, without any direct exposure of antigen to the lung, showed several similarities to those of sarcoid patients.

That study also examined whether changes in the number of pre-existing *P. acnes* cells in the lung affected pulmonary granuloma formation. As expected, preloading of *P. acnes* exacerbated pulmonary disorders, whereas reduction of the *P. acnes* population by antimicrobial treatment reduced the pulmonary lesions. These findings suggest a pivotal role of normally localized *P. acnes* in the formation of pulmonary granuloma by extrapulmonary *P. acnes* sensitization, as well as the potential clinical usefulness of antimicrobial eradication targeting lung-indigenous *P. acnes* for the treatment of pulmonary granulomatosis induced by similar pathogenesis.

8. Etiology of sarcoidosis

In the past, once the germ theory of disease was accepted, microbes were considered to be pathogens if they met the stipulations of Koch's postulates. Although there are many microbes, however, most human infections are caused by only a few. Some microbes have been classified as pathogens although they do not cause disease in every host. In addition, some microbes have been classified as nonpathogenic although they cause disease in certain hosts. For these reasons, in a redefinition of the concepts of virulence and pathogenicity of microbes, Casadevall and Pirofski suggested a classification system for pathogens based on their ability to cause damage as a function of the host's immune response [57]. Koch's postulates for exogenous infection cannot be applied to diseases caused by endogenous bacteria. Endogenous infection is a disease caused by indigenous microorganisms. According to the classification system suggested by Casadevall and Pirofski, endogenous infection, which does not cause any lesions under normal immune conditions, can be classified into three major categories (Figure 22). Opportunistic infections, such as pneumocystis carinii pneumonia, are well known to be associated with immunodeficiency in AIDS patients. Combination type infections, such as Candida and Aspergillus, not only cause opportunistic infections, but may also cause hypersensitivity pneumonitis. The hypersensitivity type of endogenous infection does not cause any tissue damage until the hypersensitive immune response is triggered. *P. acnes* as a cause of sarcoidosis can therefore be classified within the group of endogenous diseases that results from hypersensitivity.

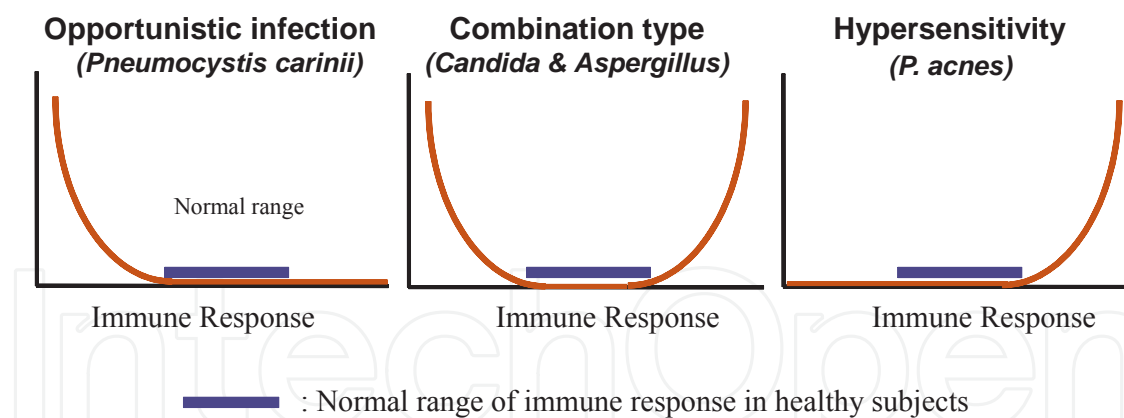


Figure 22. Three major categories of endogenous infection in the classification system of diseases caused by indigenous microorganisms.

8.1. Commensalism of *P. acnes* in the lungs and lymph nodes

P. acnes is the most common commensal bacterium in the lungs and lymph nodes from subjects without sarcoidosis [17]. Some *P. acnes* is found in 20% of non-sarcoid lymph nodes by bacterial culture [17], 15% of non-sarcoid lymph nodes by PCR [26], and 18% of non-sarcoid lung samples, and 22% of non-sarcoid lymph node samples by immunohistochemistry [28].

Occasional detection of intracellular *P. acnes* in non-granulomatous areas of the lungs and lymph nodes from non-sarcoid patients suggests that latent infection and endogenous reactivation of this indigenous bacterium occurs in these organs, even in patients without sarcoidosis. Sarcoidosis involves many organs, and the lungs and mediastinal lymph nodes are involved at the highest frequency [58]. Commensalism of *P. acnes* in these organs may explain why they are frequently involved in sarcoidosis.

8.2. Mechanism of granuloma formation in sarcoidosis

P. acnes, indigenous low-virulence bacterium, can cause latent infection in the lungs and lymph nodes and persist in a cell-wall-deficient form. This dormant form of *P. acnes* can be activated endogenously under certain environmental conditions and then proliferate in cells at the site of the latent infection. In patients hypersensitive to this endogenous bacterium, granulomatous inflammation is triggered by intracellular proliferation of the bacterium. Some proliferating bacteria may escape from isolation by the granuloma and spread to other organs via the lymph and blood streams. The spread of infective *P. acnes* might cause a new latent infection in systemic organs, such as eyes, skin, and heart. Latent infection established in certain systemic organs will be reactivated simultaneously by the next triggering event, resulting in the onset of systemic sarcoidosis (Figure 23).

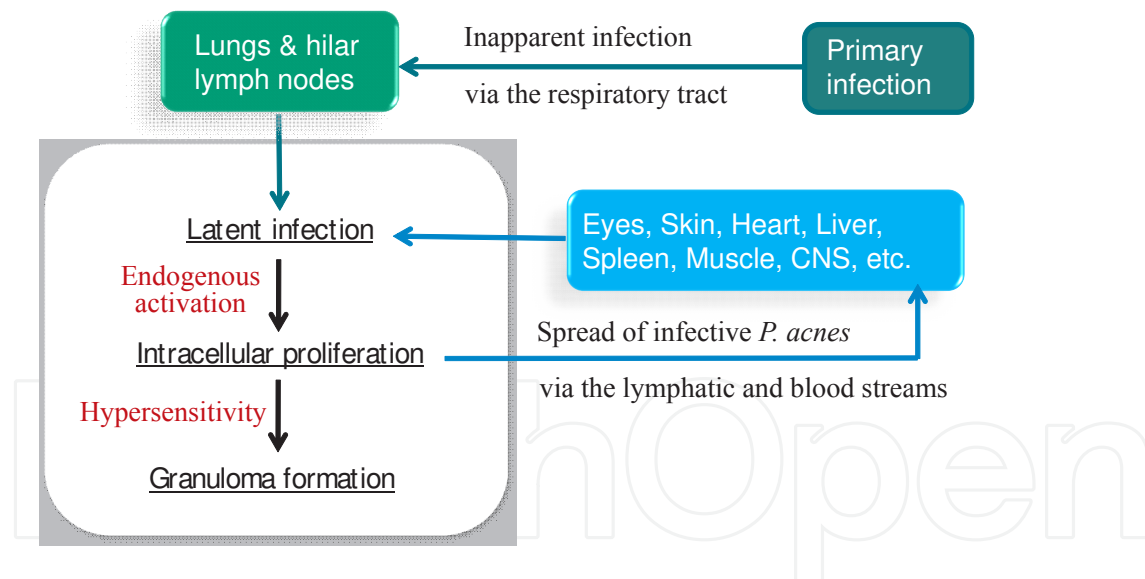


Figure 23. Hypothesized mechanism of systemic sarcoid granuloma formation caused by *P. acnes*.

Intracellular proliferation of *P. acnes* triggered by endogenous activation of latent infection might lead to the spread of the infectious *P. acnes*, giving rise to a new latent infection even within the same organ. As long as such latent infection is inadequately eradicated by the host defense mechanism of granuloma formation, the process will be repeated anytime reactivation occurs under the requisite environmental conditions. Relapsing sarcoidosis causes repetitive acute inflammation and post-inflammatory scars in the affected organs, which results in the progression of sarcoidosis through tissue damage and functional disorder in the affected organ.

Sarcoidosis is most likely the result of a complex interaction between infection, immunity, and allergic reaction (Figure 24). There are three conditions essential to the development of sarcoidosis caused by *P. acnes*: 1) latent infection with cell-wall-deficient *P. acnes*, 2) endogenous activation of dormant *P. acnes* triggered by certain environmental factors, and 3) a hypersensitive Th1 immune response towards the intracellular proliferation of *P. acnes*. The formation of sarcoid granulomas might be induced by a Th1 immune response to one or more antigens of *P. acnes* proliferating in the affected organ or tissue in an individual with a hereditary or acquired abnormality of the immune system.

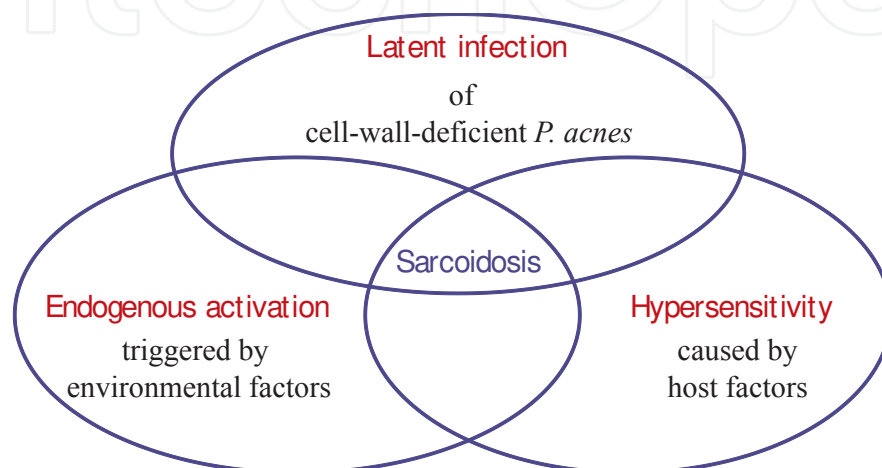


Figure 24. Sarcoidosis caused by *P. acnes* with a complex interaction of latent infection, endogenous activation, and host hypersensitivity.

8.3. Pathogenesis shared by sarcoidosis and tuberculosis

Tuberculosis shares many common features with sarcoidosis, not only their histopathologic features, but also aspects of their pathogenesis. Many tuberculosis cases arise from the endogenous activation of latent tuberculosis infection. Primary *M. tuberculosis* infection usually occurs in childhood and produces lesions termed the “primary complex”, which is a combination of lesions in the lung and lung hilar lymph nodes. Around 90% of subjects with primary infection by *M. tuberculosis* exhibit a so-called “unapparent infection”, i.e., they are asymptomatic. Latent infection by this pathogen is characterized by healed lesions comprising consolidated scar tissue or necrotic lesions that often becomes calcified. The persistent mycobacteria in this dormant phase are thought to be cell-wall-deficient. Active tuberculosis occurs when the latent mycobacterial infection is endogenously activated under certain environmental conditions, especially in older people. The risk for activation is also significantly increased by immunosuppressive triggers, such as HIV infection and diabetes. Recent immunologic data provide evidence of latent tuberculosis in about one-third of the global population, which corresponds to more than 2 billion individuals [59].

Endogenous reactivation of latent bacteria is well known to occur in tuberculosis, which shares many common features with sarcoidosis, not only the histopathologic features, but also the pathogenic features. Many cases of adult tuberculosis are caused by endogenous activation of

latent tuberculosis infection [59, 60]. Tuberculosis and sarcoidosis are side effects of the anti-tumor necrosis factor- α drugs administered to patients with rheumatoid arthritis [61, 62]. Anti-tumor necrosis factor- α treatment is thought to reactivate latent tuberculosis infection [63]. In the same manner, latent *P. acnes* might be reactivated by anti-tumor necrosis factor- α treatment, resulting in sarcoidosis in certain susceptible subjects among these patients.

9. Treatment of sarcoidosis

Immunosuppressive, mainly corticosteroidal, therapy has been used for sarcoidosis for more than 50 years, but the long-term effects of steroidal treatment in chronic sarcoidosis are still disputed [3]. Further, the high relapse rate after treatment and the side effects of long-term use are often a clinical challenge [64]. Steroids suppress the allergic reaction, thereby providing therapeutic effects. Interference of the inflammatory process by these immunosuppressive drugs, however, may impede the formation of granulomas, which function to curtail the spread of *P. acnes* infection.

9.1. Strategy for treating sarcoidosis caused by *P. acnes*

Antibiotics not only kill the bacteria proliferating in cells, but also prevent the endogenous activation of latent bacteria. Long-term administration of antibiotics may therefore be effective for patients with progressive sarcoidosis by preventing inflammatory relapses caused by reactivation of the latent bacteria (Figure 25). If latent bacterial infection persisting in organs can be eradicated by treatment with antibiotics, complete remission of sarcoidosis may be achieved. Complete eradication of latent bacteria might be difficult to achieve through the conventional use of antibiotics, however, as in the case of pulmonary tuberculosis.

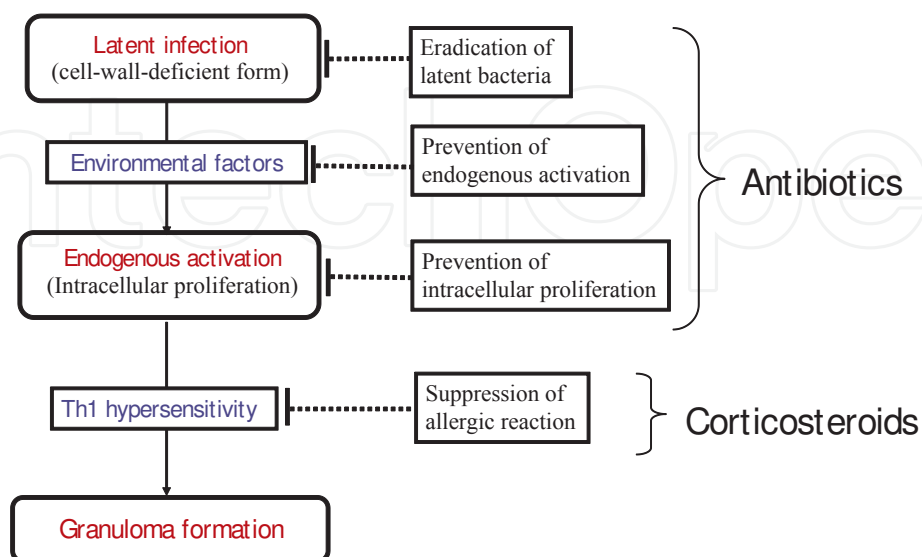


Figure 25. Strategy for treating sarcoidosis caused by *P. acnes*.

Another approach for treating sarcoidosis is specific suppression of the hypersensitivity to *P. acnes* antigens responsible for granuloma formation, such as the trigger factor protein. Recent advances in the modulation of epitope-specific immune responses by synthetic peptides might help to improve the treatment of sarcoidosis.

9.2. Tetracyclines for treating sarcoidosis

Minocycline is the first-choice antibiotic for patients with acne vulgaris caused by *P. acnes*. In an observational study, Bachelez and colleagues [65] reported the possible benefits of tetracyclines, to which *P. acnes* is sensitive, for the treatment of chronic forms of cutaneous sarcoidosis. The authors treated 12 patients with biopsy-proven cutaneous sarcoidosis with 200 mg daily minocycline over a median 12-month period. With a median follow-up of 26 months, the authors noted complete and partial responses to treatment in 8 and 2 patients, respectively. The mean time to reach a maximal response was 3.2 months. Of the 8 patients who had a complete response, minocycline could be withdrawn in 7 patients, 3 of whom experienced recurrent lesions and received further treatment with 200 mg daily doxycycline. Complete remission was maintained for a mean of 15.3 months. Regression of pulmonary infiltrates and mediastinal lymphadenopathy was noted in the 2 patients with concurrent pulmonary involvement.

The results of a nationwide questionnaire survey, performed by a Japanese research group in 2005 (reported in Japanese), indicated that antibiotic therapy was effective in 43% of 87 patients with sarcoidosis treated with many kinds of antibiotics, including minocycline, doxycycline, and clarithromycin. Baba and colleagues [66] used minocycline and clarithromycin for therapy against worsening of multiple endobronchial mass lesions, given the possible roles of *P. acnes* in the pathophysiology of sarcoidosis and the uncertainty of the long-term effects of corticosteroids. The lesions were worsening before the antibiotic therapy was initiated, so the improvements appeared to be due to the therapy. Park and colleagues [67] reported the first case of ocular and ocular adnexal sarcoidosis treated with minocycline. The patient in this report demonstrated a complete and recurrence-free response of lacrimal gland and choroidal lesions as well as parotid granulomas and pulmonary infiltrates after 3 months of minocycline therapy. Miyazaki and colleagues [68] reported the regression of nodular lesions of muscular sarcoidosis during minocycline treatment with decreased levels of angiotensin-converting enzyme, lysozyme, and soluble interleukin-2 receptor. The effectiveness of minocycline for muscular sarcoidosis in this case was confirmed when a prompt response to the minocycline therapy was repeatedly observed.

Based on the studies described in this section, the antimicrobial properties of tetracyclines are effective for treating sarcoidosis. Many researchers, have questioned the antimicrobial role of tetracyclines because tetracyclines also have anti-inflammatory properties, which were demonstrated by in vitro studies and corroborated by clinical trials. Tetracycline suppresses neutrophil migration and chemotaxis [69], and minocycline inhibits T-lymphocyte activation and proliferation [70]. Both minocycline and doxycycline obviate granuloma formation in vitro [71]. Although it remains controversial whether these antibiotics kill microbes or have only an anti-inflammatory effect, the mechanisms of sarcoid granuloma formation caused by *P.*

acnes proposed in this chapter suggest that these antibiotics have many roles in the process of granuloma formation, including the events triggering granuloma formation caused by intracellular proliferation of the bacterium.

9.3. Marshall protocol

The Marshall protocol [72] is an eradication therapy for intracellular bacteria established by Dr. Trevor Marshall. This therapeutic protocol is a combination of minocycline plus azithromycin or clindamycin, supported by the use of an angiotensin receptor blocker to prevent Herxheimer reactions. According to the results published by the Autoimmunity Research Foundation in 2006, this therapy is effective in 62% of patients with sarcoidosis. Information about the treatment can be found at the study site, marshallprotocol.com and also at autoimmunityresearch.org.

Author details

Yoshinobu Eishi*

Address all correspondence to: eishi.path@tmd.ac.jp

Department of Human Pathology, Division of Surgical Pathology, Tokyo Medical and Dental University, Japan

References

- [1] Newman LS, Rose CS, Maier LA. Sarcoidosis. *N Engl J Med* 1997;336:1224-34.
- [2] Hunninghake GW, Costabel U, Ando M, et al. ATS/ERS/WASOG statement on sarcoidosis. American Thoracic Society/European Respiratory Society/World Association of Sarcoidosis and other Granulomatous Disorders. *Sarcoidosis, vasculitis, and diffuse lung diseases : official journal of WASOG / World Association of Sarcoidosis and Other Granulomatous Disorders* 1999;16:149-73.
- [3] Baughman RP, Lower EE, du Bois RM. Sarcoidosis. *Lancet* 2003;361:1111-8.
- [4] Newman LS, Rose CS, Bresnitz EA, et al. A case control etiologic study of sarcoidosis: environmental and occupational risk factors. *Am J Respir Crit Care Med* 2004;170:1324-30.
- [5] McGrath DS, Goh N, Foley PJ, et al. Sarcoidosis: genes and microbes--soil or seed? *Sarcoidosis, vasculitis, and diffuse lung diseases : official journal of WASOG / World Association of Sarcoidosis and Other Granulomatous Disorders* 2001;18:149-64.

- [6] du Bois RM, Goh N, McGrath D, et al. Is there a role for microorganisms in the pathogenesis of sarcoidosis? *J Intern Med* 2003;253:4-17.
- [7] Drake WP, Newman LS. Mycobacterial antigens may be important in sarcoidosis pathogenesis. *Curr Opin Pulm Med* 2006;12:359-63.
- [8] Eishi Y, Suga M, Ishige I, et al. Quantitative analysis of mycobacterial and propionibacterial DNA in lymph nodes of Japanese and European patients with sarcoidosis. *J Clin Microbiol* 2002;40:198-204.
- [9] Brownell I, Ramírez-Valle F, Sanchez M, et al. Evidence for Mycobacteria in Sarcoidosis. *Am J Respir Cell Mol Biol* 2011.
- [10] Drake WP, Dhason MS, Nadaf M, et al. Cellular recognition of Mycobacterium tuberculosis ESAT-6 and KatG peptides in systemic sarcoidosis. *Infect Immun* 2007;75:527-30.
- [11] Ebe Y, Ikushima S, Yamaguchi T, et al. Proliferative response of peripheral blood mononuclear cells and levels of antibody to recombinant protein from Propionibacterium acnes DNA expression library in Japanese patients with sarcoidosis. *Sarcoidosis Vasc Diffuse Lung Dis* 2000;17:256-65.
- [12] Zumla A, James DG. Granulomatous infections: etiology and classification. *Clin Infect Dis* 1996;23:146-58.
- [13] Homma JY, Abe C, Chosa H, et al. Bacteriological investigation on biopsy specimens from patients with sarcoidosis. *Jpn J Exp Med* 1978;48:251-5.
- [14] Abe C, Iwai K, Mikami R, et al. Frequent isolation of Propionibacterium acnes from sarcoidosis lymph nodes. *Zentralbl Bakteriol Mikrobiol Hyg A* 1984;256:541-7.
- [15] Conron M, Du Bois RM. Immunological mechanisms in sarcoidosis. *Clin Exp Allergy* 2001;31:543-54.
- [16] Agostini C, Meneghin A, Semenzato G. T-lymphocytes and cytokines in sarcoidosis. *Curr Opin Pulm Med* 2002;8:435-40.
- [17] Ishige I, Eishi Y, Takemura T, et al. Propionibacterium acnes is the most common bacterium commensal in peripheral lung tissue and mediastinal lymph nodes from subjects without sarcoidosis. *Sarcoidosis Vasc Diffuse Lung Dis* 2005;22:33-42.
- [18] Furukawa A, Uchida K, Ishige Y, et al. Characterization of Propionibacterium acnes isolates from sarcoid and non-sarcoid tissues with special reference to cell invasiveness, serotype, and trigger factor gene polymorphism. *Microb Pathog* 2009;46:80-7.
- [19] Cue DR, Cleary PP. High-frequency invasion of epithelial cells by Streptococcus pyogenes can be activated by fibrinogen and peptides containing the sequence RGD. *Infect Immun* 1997;65:2759-64.

- [20] Fidler HM, Rook GA, Johnson NM, et al. Mycobacterium tuberculosis DNA in tissue affected by sarcoidosis. *BMJ* 1993;306:546-9.
- [21] Popper HH, Winter E, Höfler G. DNA of Mycobacterium tuberculosis in formalin-fixed, paraffin-embedded tissue in tuberculosis and sarcoidosis detected by polymerase chain reaction. *Am J Clin Pathol* 1994;101:738-41.
- [22] Saboor SA, Johnson NM, McFadden J. Detection of mycobacterial DNA in sarcoidosis and tuberculosis with polymerase chain reaction. *Lancet* 1992;339:1012-5.
- [23] Bocart D, Lecossier D, De Lassence A, et al. A search for mycobacterial DNA in granulomatous tissues from patients with sarcoidosis using the polymerase chain reaction. *Am Rev Respir Dis* 1992;145:1142-8.
- [24] Richter E, Greinert U, Kirsten D, et al. Assessment of mycobacterial DNA in cells and tissues of mycobacterial and sarcoid lesions. *Am J Respir Crit Care Med* 1996;153:375-80.
- [25] Vokurka M, Lecossier D, du Bois RM, et al. Absence of DNA from mycobacteria of the *M. tuberculosis* complex in sarcoidosis. *Am J Respir Crit Care Med* 1997;156:1000-3.
- [26] Ishige I, Usui Y, Takemura T, et al. Quantitative PCR of mycobacterial and propionibacterial DNA in lymph nodes of Japanese patients with sarcoidosis. *Lancet* 1999;354:120-3.
- [27] Yamada T, Eishi Y, Ikeda S, et al. In situ localization of *Propionibacterium acnes* DNA in lymph nodes from sarcoidosis patients by signal amplification with catalysed reporter deposition. *J Pathol* 2002;198:541-7.
- [28] Negi M, Takemura T, Guzman J, et al. Localization of *Propionibacterium acnes* in granulomas supports a possible etiologic link between sarcoidosis and the bacterium. *Mod Pathol* 2012;25:1287-97.
- [29] Boyd JF, Valentine JC. Unidentified yellow bodies in human lymph-nodes. *The Journal of pathology* 1970;102:58-60.
- [30] Doyle WF, Brahman HD, Burgess JH. The nature of yellow-brown bodies in peritoneal lymph nodes. *Archives of pathology* 1973;96:320-6.
- [31] Moscovic EA. Sarcoidosis and mycobacterial L-forms. A critical reappraisal of pleomorphic chromogenic bodies (Hamazaki corpuscles) in lymph nodes. *Pathology annual* 1978;13 Pt 2:69-164.
- [32] SILTZBACH LE. The Kveim test in sarcoidosis. A study of 750 patients. *JAMA* 1961;178:476-82.
- [33] Hunninghake GW, Crystal RG. Pulmonary sarcoidosis: a disorder mediated by excess helper T-lymphocyte activity at sites of disease activity. *N Engl J Med* 1981;305:429-34.

- [34] Moller DR, Forman JD, Liu MC, et al. Enhanced expression of IL-12 associated with Th1 cytokine profiles in active pulmonary sarcoidosis. *J Immunol* 1996;156:4952-60.
- [35] Furusawa H, Suzuki Y, Miyazaki Y, et al. Th1 and Th17 immune responses to viable *Propionibacterium acnes* in patients with sarcoidosis. *Respir Invest* 2012;50:104-9.
- [36] Nakata Y, Ejiri T, Kishi T, et al. Alveolar lymphocyte proliferation induced by *Propionibacterium acnes* in sarcoidosis patients. *Acta Med Okayama* 1986;40:257-64.
- [37] Mori Y, Nakata Y, Kataoka M, et al. [Interleukin-2 production and receptor expression of alveolar lymphocytes stimulated by *Propionibacterium acnes* in sarcoidosis]. *Nihon Kyobu Shikkan Gakkai Zasshi* 1989;27:42-50.
- [38] Hiramatsu J, Kataoka M, Nakata Y, et al. *Propionibacterium acnes* DNA detected in bronchoalveolar lavage cells from patients with sarcoidosis. *Sarcoidosis, vasculitis, and diffuse lung diseases : official journal of WASOG / World Association of Sarcoidosis and Other Granulomatous Disorders* 2003;20:197-203.
- [39] Ogura Y, Bonen DK, Inohara N, et al. A frameshift mutation in NOD2 associated with susceptibility to Crohn's disease. *Nature* 2001;411:603-6.
- [40] Miceli-Richard C, Lesage S, Rybojad M, et al. CARD15 mutations in Blau syndrome. *Nat Genet* 2001;29:19-20.
- [41] Kanazawa N, Okafuji I, Kambe N, et al. Early-onset sarcoidosis and CARD15 mutations with constitutive nuclear factor-kappaB activation: common genetic etiology with Blau syndrome. *Blood* 2005;105:1195-7.
- [42] Schürmann M, Valentonyte R, Hampe J, et al. CARD15 gene mutations in sarcoidosis. *Eur Respir J* 2003;22:748-54.
- [43] Tanabe T, Ishige I, Suzuki Y, et al. Sarcoidosis and NOD1 variation with impaired recognition of intracellular *Propionibacterium acnes*. *Biochim Biophys Acta* 2006;1762:794-801.
- [44] Nagy I, Pivarcsi A, Koreck A, et al. Distinct strains of *Propionibacterium acnes* induce selective human beta-defensin-2 and interleukin-8 expression in human keratinocytes through toll-like receptors. *J Invest Dermatol* 2005;124:931-8.
- [45] Kalis C, Gumenscheimer M, Freudenberg N, et al. Requirement for TLR9 in the immunomodulatory activity of *Propionibacterium acnes*. *J Immunol* 2005;174:4295-300.
- [46] Boughan PK, Argent RH, Body-Malapel M, et al. Nucleotide-binding oligomerization domain-1 and epidermal growth factor receptor: critical regulators of beta-defensins during *Helicobacter pylori* infection. *J Biol Chem* 2006;281:11637-48.
- [47] Senaldi G, Yin S, Shaklee CL, et al. *Corynebacterium parvum*- and *Mycobacterium bovis* bacillus Calmette-Guerin-induced granuloma formation is inhibited in TNF receptor I (TNF-RI) knockout mice and by treatment with soluble TNF-RI. *J Immunol* 1996;157:5022-6.

- [48] Tsuji H, Harada A, Mukaida N, et al. Tumor necrosis factor receptor p55 is essential for intrahepatic granuloma formation and hepatocellular apoptosis in a murine model of bacterium-induced fulminant hepatitis. *Infect Immun* 1997;65:1892-8.
- [49] Yoneyama H, Matsuno K, Zhang Y, et al. Regulation by chemokines of circulating dendritic cell precursors, and the formation of portal tract-associated lymphoid tissue, in a granulomatous liver disease. *J Exp Med* 2001;193:35-49.
- [50] Yi ES, Lee H, Suh YK, et al. Experimental extrinsic allergic alveolitis and pulmonary angiitis induced by intratracheal or intravenous challenge with *Corynebacterium parvum* in sensitized rats. *Am J Pathol* 1996;149:1303-12.
- [51] Ichiyasu H, Suga M, Iyonaga K, et al. Role of monocyte chemoattractant protein-1 in *Propionibacterium acnes*-induced pulmonary granulomatosis. *Microsc Res Tech* 2001;53:288-97.
- [52] Minami J, Eishi Y, Ishige Y, et al. Pulmonary granulomas caused experimentally in mice by a recombinant trigger-factor protein of *Propionibacterium acnes*. *J Med Dent Sci* 2003;50:265-74.
- [53] Swanborg RH. Experimental autoimmune encephalomyelitis in the rat: lessons in T-cell immunology and autoreactivity. *Immunol Rev* 2001;184:129-35.
- [54] Goulvestre C, Batteux F, Charreire J. Chemokines modulate experimental autoimmune thyroiditis through attraction of autoreactive or regulatory T cells. *Eur J Immunol* 2002;32:3435-42.
- [55] Teuscher C, Hickey WF, Grafer CM, et al. A common immunoregulatory locus controls susceptibility to actively induced experimental allergic encephalomyelitis and experimental allergic orchitis in BALB/c mice. *J Immunol* 1998;160:2751-6.
- [56] Nishiwaki T, Yoneyama H, Eishi Y, et al. Indigenous pulmonary *Propionibacterium acnes* primes the host in the development of sarcoid-like pulmonary granulomatosis in mice. *Am J Pathol* 2004;165:631-9.
- [57] Casadevall A, Pirofski LA. Host-pathogen interactions: redefining the basic concepts of virulence and pathogenicity. *Infect Immun* 1999;67:3703-13.
- [58] Iwai K, Takemura T, Kitaichi M, et al. Pathological studies on sarcoidosis autopsy. II. Early change, mode of progression and death pattern. *Acta Pathol Jpn* 1993;43:377-85.
- [59] Lin PL, Flynn JL. Understanding latent tuberculosis: a moving target. *J Immunol* 2010;185:15-22.
- [60] Tufariello JM, Chan J, Flynn JL. Latent tuberculosis: mechanisms of host and bacillus that contribute to persistent infection. *Lancet Infect Dis* 2003;3:578-90.
- [61] Keane J, Gershon S, Wise RP, et al. Tuberculosis associated with infliximab, a tumor necrosis factor alpha-neutralizing agent. *N Engl J Med* 2001;345:1098-104.

- [62] Gifre L, Ruiz-Esquide V, Xaubet A, et al. Lung sarcoidosis induced by TNF antagonists in rheumatoid arthritis: a case presentation and a literature review. *Arch Bronconeumol* 2011;47:208-12.
- [63] Keane J. TNF-blocking agents and tuberculosis: new drugs illuminate an old topic. *Rheumatology (Oxford)* 2005;44:714-20.
- [64] Gottlieb JE, Israel HL, Steiner RM, et al. Outcome in sarcoidosis. The relationship of relapse to corticosteroid therapy. *Chest* 1997;111:623-31.
- [65] Bachelez H, Senet P, Cadranet J, et al. The use of tetracyclines for the treatment of sarcoidosis. *Arch Dermatol* 2001;137:69-73.
- [66] Baba K, Yamaguchi E, Matsui S, et al. A case of sarcoidosis with multiple endobronchial mass lesions that disappeared with antibiotics. *Sarcoidosis, vasculitis, and diffuse lung diseases : official journal of WASOG / World Association of Sarcoidosis and Other Granulomatous Disorders* 2006;23:78-9.
- [67] Park DJ, Woog JJ, Pulido JS, et al. Minocycline for the treatment of ocular and ocular adnexal sarcoidosis. *Arch Ophthalmol* 2007;125:705-9.
- [68] Miyazaki E, Ando M, Fukami T, et al. Minocycline for the treatment of sarcoidosis: is the mechanism of action immunomodulating or antimicrobial effect? *Clin Rheumatol* 2008;27:1195-7.
- [69] Esterly NB, Koransky JS, Furey NL, et al. Neutrophil chemotaxis in patients with acne receiving oral tetracycline therapy. *Arch Dermatol* 1984;120:1308-13.
- [70] Kloppenburg M, Verweij CL, Miltenburg AM, et al. The influence of tetracyclines on T cell activation. *Clin Exp Immunol* 1995;102:635-41.
- [71] Webster GF, Toso SM, Hegemann L. Inhibition of a model of in vitro granuloma formation by tetracyclines and ciprofloxacin. Involvement of protein kinase C. *Arch Dermatol* 1994;130:748-52.
- [72] Marshall TG, Marshall FE. Sarcoidosis succumbs to antibiotics--implications for autoimmune disease. *Autoimmun Rev* 2004;3:295-300.