

We are IntechOpen, the world's leading publisher of Open Access books Built by scientists, for scientists

4,800

Open access books available

122,000

International authors and editors

135M

Downloads

Our authors are among the

154

Countries delivered to

TOP 1%

most cited scientists

12.2%

Contributors from top 500 universities



WEB OF SCIENCE™

Selection of our books indexed in the Book Citation Index
in Web of Science™ Core Collection (BKCI)

Interested in publishing with us?
Contact book.department@intechopen.com

Numbers displayed above are based on latest data collected.
For more information visit www.intechopen.com



Evolution and Strategy of Endoscopic Treatment for Colorectal Tumours

Koh Z.L. Sharon, H. Yamamoto and
Tsang B.S. Charles

Additional information is available at the end of the chapter

<http://dx.doi.org/10.5772/53342>

1. Introduction

1.1. History

Wolff and Shinya published their experience with *therapeutic* colonoscopy in September 1969 in JAMA [2], three months after they had commenced to perform diagnostic fiber colonoscopy. Since then, this has become an increasingly significant arm of minimally invasive colorectal surgery, complementing, even possibly replacing procedures that were once performed using “open” surgical techniques. [1-3]

Following the introduction of the fiber-optic colonoscopy for diagnostic evaluation of the lower gastrointestinal tract, enabling all parts of the colon to be assessed under direct vision and instrumentation as reported by Deyhle and Demling in 1971, and Sakai in 1972, [4-5] mastery of these techniques by Williams and colleagues have enabled therapeutic interventions to be performed endoscopically. [6]

Propelling this “endoscopic therapy” movement is the increasing evidence of the “adenoma-carcinoma” polyp-cancer sequence introduced by Morson and Bussey from 1968 to 1970. [7] This fundamental concept has enabled a form of prevention of colorectal cancer by endoscopic removal of precursor lesions and is the basis of colonoscopic screening for colorectal cancer, resulting in the effective cessation to their progression to cancer.

2. Polypectomy in the colon

Winawer and colleagues in 1993 provided strong evidence that the prevention of colorectal cancer can be achieved by colonoscopic polypectomy. [9] Data and statistics from the National

Polyp Study Workgroup demonstrated that the incidence of colorectal cancer is reduced by colonoscopic polypectomy and provided evidence for the adherence to the principle of searching and subsequent removal of adenomatous polyps in the colon and rectum. They reported on the 6-year follow-up of 1,418 patients after repeated colonoscopy to clear all polyps. While this study did not have a true control arm, the background age and sex specific incidence of colorectal cancer was used as a control group. The removal of all polyps seen during endoscopy prevented the development of 75% of carcinomas. The Veterans Affairs Study conducted by Muller and Sonnenberg published in 1995 found that only 50% of cancers were prevented, but the study was limited, for not all patients had received total colonoscopy in that study. [10] Hurlstone and colleagues postulate that one possible factor responsible for polyp surveillance failing to prevent all colorectal cancers within these studies may be due to the lack of Western experience of flat and depressed lesions within the colon. [11]

The evolution of colonoscopic polypectomies was between the 1950s and 1970s. As neither radiographic imaging via barium studies; nor macroscopic appearance of the polyps gave any definite information about its nature or behavior, histologic assessment was thereby deemed necessary to establish the diagnosis of these polyps and thereafter, their prognosis. Hellwig and Barbosa reported that forceps biopsy gave samples that were inadequate for the exclusion of the presence of malignancy. [12] Also there was no complete removal of the lesion, which is necessary for a full histological study.

In the 1970s, the largest series of colonoscopic polypectomies performed were reported by Wolff and Shinya in 1973. [13] They reported their undertaking of a program to remove colonic polyps endoscopically. Shinya was also responsible for the conception of "snare polypectomy" and with Hiroshi Ichikawa, developed various polypectomy techniques in the 1970s. This was performed after achieving 1600 uncomplicated diagnostic colonoscopies. They removed 303 polyps ranging from 0.5 to 5.0cm in diameter with minimal complication. Major bleeding requiring transfusion was encountered in one patient, and minor bleeding in four others. The other series published were much smaller and were descriptive, mainly by Friend and Ottenjahn in 1972, Dehyle, Demling, Fruhmorgen, Testas and Williams et al in 1973. Morgenthal et al thus concluded in a review published in 2007 that colonoscopic polypectomy may be the most significant of all developments in therapeutic endoscopy. [8]

Already in the early development of colonoscopic polypectomy, several problems were encountered and along with them, limitations with this technique. In 1974, Williams and colleagues reviewed their series of 300 polypectomies in 169 patients. Fundamental principles such as adequate bowel preparation to ensure minimally obstructed view of the polyp to be snared, and to ensure no residual fluid present to dissipate the energy current have been described right from the introduction of colonoscopic polypectomy and are still adhered to today.

2.1. Electrocautery in snare polypectomy and hot biopsy

Williams et al described the use of a diathermy snare loop technique for excision of polyps up to 4.5 cm in diameter. The "hot-biopsy" technique was also introduced and they reported their results in 107 smaller polyps. Their results compared favorably to surgical polypectomies.

They reported a single “closed” perforation that was managed conservatively, and 2 patients who experienced major hemorrhage. [14]

For small sessile polyps, the snare loop was passed over the head of the polyps and tightened at the base. For pedunculated polyps, the snare was closed halfway down the stalk. This was positioned “high” enough to minimize the risk of heat necrosis of the bowel wall, but “low” enough to include areas of mucosal changes suspicious of early malignant invasion of the stalk. [14]

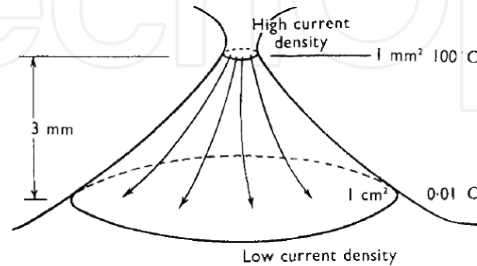


Figure 1. Principle of “current density” in diathermy electrocoagulation – heating effect in the stalk of the polyp (after Curtiss 1973)

The technique of diathermy snare polypectomy was based on the theory of diathermy currents described by Curtiss in 1973. The electrical precautions described then are also still observed today. These are to tighten the snare and elevate the polyp away from the bowel in the direction that the current passes into the smallest possible area of tissue within the stalk, enabling localized heating at the area of highest “current density” (Fig 1). [15] As this is applicable to pedunculated polyps with inherent stalks, Williams and colleagues [14] described the technique of creating a “pseudo-pedicle” in small sessile polyps by lifting the snared polyp forcible. Heat necrosis is avoided by ensuring that the polyp head, upon being lifted up, did not come into contact with the opposite bowel wall during the application of the current. These principles were extended for the same authors described the “hot-biopsy” techniques by which polyps up to 7mm were simultaneously biopsies and also destroyed by the application of a strong coagulating current down the closed jaws of the biopsy forceps. The tissue within the jaws is not heated and therefore preserved, as the current bypasses this area of conductive material.

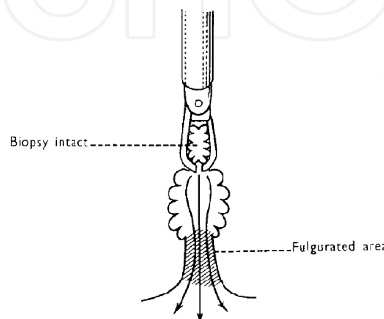


Figure 2. Technique of “hot biopsy” with the use of diathermy forceps – principle of selective coagulation necrosis at the base of the polyp.

Since then, the role of therapeutic colonoscopic polypectomy have grown exponentially as the technical problems of polypectomy and electrosurgery, in comparison to open surgical polypectomy, are more easily mastered and taught. More importantly, these techniques can be learnt not just by the surgeons, but also the gastroenterologists.

2.2. Impact of polypectomy – Review of the technique and histologic outcomes

In the 1980s to 1990s, Williams and Bedenne performed a literature review on what they called “the polyp problem” and carried out a critique of their current practice. They concluded that since the introduction of the adenoma-carcinoma sequence in 1973, there have been no evidence in the literature to disprove this concept that majority of colorectal cancers develop from previous adenomas. Even then, they concluded with the current management of colorectal polyps was “transparently worthwhile” for the ease of the removal of symptomatic or threatening polyps avoids the morbidity of surgery and unnecessary operation. [15]

The concept of the “flat adenoma” was also reviewed, and has been described as precursors of carcinomas especially in inherited colorectal cancers. Jass and colleagues [17] described that this may account for 10% of patients whose carcinoma develop in a “de novo” fashion. These are usually found in the right sided colon and characteristically present as a “firm pale button only 5-15mm in diameter” that could be missed at endoscopy, especially if bowel preparation of the caecal and right sided colon is inadequate. [18] During this time, colonoscopic techniques were reviewed. [19-20] It was reported that small polyps up to 5-6mm can be conveniently managed with the hot-biopsy technique. Combined with rapid electrocoagulation technique, the histological yield has been reported to be over 95%. There must be some visible electrocoagulation during this procedure to avoid recurrences of the polyp as simple “cold-biopsy” without electrocoagulation resulted in up to 29% remnant viable tissue. There is however, a significant incidence of complications, namely perforation when coagulation is overdone in the proximal colon. [21-23]

The use of a bipolar electrode, although initially demonstrated promise in localizing heat necrosis to the area within the jaws of the biopsy forceps, was not predictably effective in polyp destruction. This is because the tissue grasped between the jaws were heated and thereby destroyed by the electrical current passing between the jaws, resulting in inability to interpret the histology. [24] For polyps larger than 5-6mm in diameter, Williams et al concluded that it was safer to use conventional snare polypectomy. [16] Retrieval of the specimen was by aspiration into a filtered polyp suction trap commercially available since the late 1980s. [25]

For polyps larger than 1cm (medium to large sized), the principles of sclerotherapy injection with adrenaline in saline for short stalks prior to snaring or after bleeding have been widely practiced. Although some have reported that polyps 3cm or greater in size can be excised by snare polypectomy without employing the injection techniques. [26]

2.3. Advent of endoscopic mucosal resection & submucosa dissection

It is hence, of no surprise when the techniques of submucosal injection with various fluids (ranged from isotonic to hypertonic saline; 50% glucose with epinephrine +/- indigocarmine)

to enable a safer and more reliable removal of relatively large or flat lesions were popularized in the last twenty years as Endoscopic Mucosal Resection (EMR). [28] In general, for lesions larger than 2cm, several endoscopists recognize the challenge in performing an *en bloc* resection, hence piecemeal resection was routinely performed. These had then become accepted as a relatively quick and easy procedure to perform. [29-30] The disadvantages of the lack of a precise histological evaluation and risk of local recurrence were reported and widely accepted. The default staging of the resection automatically becomes Rx as compared to R0 if an adequate *en bloc* resection had been performed. Hence there was a challenge to perform a single step non piece-meal mucosectomy for large flat lesions. The first such successful procedure in the colorectum for a lesions larger than 2cm was performed by the co-author (H.Y.) and published in 1999. He performed single step resection of a 40mm flat-elevated tumor in the rectum using sodium hyaluronate which enabled a prominent and longer lasting mucosa protrusion. [79-80]

In a recent analysis of 58 lateral spreading tumours (>10 mm in diameter with a low vertical axis extending laterally along the luminal wall) 36 lesions required piecemeal resection due to their maximum diameter exceeding 20 mm, and the majority of recurrences (8/10) detected occurred in this group. These recurrences were successfully managed by further EMR. [11] Re-treatment of recurrent tumors after such piecemeal EMRs were postulated to have added difficulty as the local fibrosis prevented an adequate mucosal lift, hence increasing the risk of perforation and inadequate resection. Hurlstone and colleagues reported their method of addressing these issues. The problem of recurrence that piecemeal or incomplete resection poses may be tackled by utilizing endoscopic submucosal resection (ESD) which has recently been developed by Japanese groups for the endoluminal resection of Paris 0-II lesions of the stomach, gastro-esophageal junction and esophagus using a gastroscope with a distal transparent cap attachment. The technique allows *en bloc* knife dissection after sodium hyaluronic acid or glycerol submucosal infiltration for lesions > 20 mm in diameter. [11]

2.4. Endoscopic microsurgery

In 1987, Buess and colleagues extended the application of endoscopy in the arena of minimally invasive surgery, pushing back their boundaries by introducing the transanal endoscopic microsurgery (TEM) procedure. This enabled two-handed use of surgical instrumentation and suturing techniques via a jumbo proctoscope to enable air insufflation of the rectum and sigmoid colon. He reported the ability to resect large and full thickness lesions up to the distance of 25cm from the anal verge. However, large sessile tumours in the proximal colon will still require surgical management if endoscopic snaring is too risky or if it fails. [31] This eventually resulted in the evolution of the ESD technique, an amalgamation of both endoscopic and surgical principles.

2.5. Strategy of endoscopic treatment for colorectal tumours — Endoscopic submucosal dissection: Technique

ESD is a new endoluminal therapeutic technique involving the use of cutting devices to permit a larger resection of the tissue over the muscularis propria. The major advantages of the

technique in comparison with polypectomy and endoscopic mucosal resection are controllable resection size and shape, and en bloc resection of a large lesion or one with ulcerative features. [33-34] Naohisa Yahagi surmised this technique as a “fairly new arrival in the field of endoscopy”, but had redefined the whole concept of minimally invasive endoscopic resection for gastrointestinal neoplasms. [35] The technique of endoscopic submucosal dissection (ESD) has extended its applications for en bloc resection of large ulcerative lesions in the stomach for the treatment of early gastric cancer to that of resection of superficial neoplasms of the colon and the rectum for the treatment of early colorectal cancer. [36-39]

ESD has the advantage of permitting en bloc and histologically complete resection. On the other hand, ESD has some disadvantages such as a long operating time, a high frequency of complications, and the need for a high level of technical skill [39-41].

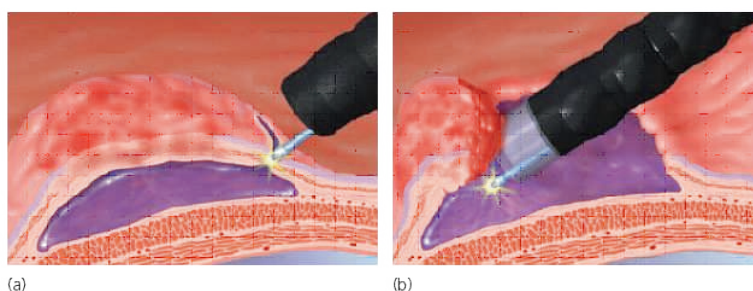


Figure 3. (a): mucosal incision made 3-5mm outside the tumour edge with Endocut mode. (b) Submucosal dissection performed using the ST hood as means of elevation and counter-traction.

The most important aspects of this technique are to incise the mucosa surrounding the lesion (Figure 3a), and to dissect completely the submucosa beneath that lesion (Figure 3b) to achieve reliable en bloc resection regardless of the size or location of the tumor

2.6. Principles of ESD

The technique of endoscopic resection is less invasive than surgical resection [34,39-40]. Its limitation lies in its inability to perform lymph node dissection, hence cure can only be achieved in localized tumors without metastases. [35,39] The risk of lymph node metastases strongly correlates with the depth of invasion of the tumor, the histopathologic type of the lesion and the presence of lymphovascular involvement. [42-46] Hence, the precise staging of the lesion pre-procedure with pit pattern diagnosis using the technique of magnifying endoscopy is strongly recommended for the appropriate selection of tumors for endoscopic resection [47-48].

Detailed pathological examination of the resected specimen is paramount to document the complete resection of the neoplasms, allowing appropriate decisions regarding the need for further surgical intervention. Curative endoscopic resection is defined by confirmation of negative resection margins, differentiated histopathologic type, depth of submucosal invasion to be $<1,000 \mu\text{m}$ and no lymphatic or vascular involvement. *En bloc* resection of the entire lesion is necessary to obtain such information.

ESD has demonstrated superiority to EMR for a more reliable en bloc resection of a targeted area of mucosa can be achieved. It has also shown to provide a higher complete resection rate with local recurrence rate as compared to piecemeal EMR. [32,49-51]. It enables the control of the size as well as the shape of the lesion to be resected, those with ulcerative findings can also be resected *en bloc*, leading to a potential cure of the target lesions without resection of that portion of the gastrointestinal tract or organ.

2.7. Indication for colorectal ESD

The characterization and endoscopic staging of each lesion is paramount in determining the suitability and thereby success of this procedure. In general, ESD can be applied to almost all lesions provided that they are within the mucosa and superficial submucosal layer of the colorectal wall. Absolute indications for ESD have been reported to be those that “cannot be resected en bloc by standard available procedures; those that require precise histological evaluation on account of a significant malignant potential. Hurlstone and colleagues describe these to be laterally spreading tumors of the nongranulating types (LST-NG). The use of the snare EMR technique for en bloc resection of larger lesions with features of LST-NG type, pseudo-depressed type and lesions with type Vi pit pattern with suspicion of carcinoma infiltrating into the submucosal layer (*sm*), or large elevated tumors are deemed difficult.

Other indications described in literature are those with biopsy-induced submucosal fibrotic scars, lesions located at challenging areas: on haustrae and difficult colonic angulations, and large lesions (>20mm), and small rectal carcinoid tumor when *en bloc* resection by conventional methods were deemed impossible. [52-53] Sporadic localized tumors occurring in the background of chronic inflammation such as those seen in inflammatory bowel disease namely ulcerative colitis; and residual early carcinoma post endoscopic resection are also indications for ESD. The success in such cases is dependent on the operability of endoscope, and the skill of the endoscopists - factors that should always be considered in the practice of ESD.

In the past decade, efforts to establish an East-West consensus on the clinicopathological importance of the macroscopic morphology of the colorectal polyp, incorporating the exophytic protruding polyps as well as those that are flat and depressed, have resulted in the introduction of multiple classifications. These are namely, the Paris classification and the modified Kudo criteria. The Cho criterion is used to differentiate tumor stage and nodal disease status by using high-frequency endoscopic ultrasonography. All are used to establish the *exclusion criteria* of ESD, which are: T2/N1 disease, transixed type IIC component (constant concavity of the lesion regardless of air insufflations or deflation as defined by Kudo). Presence of systemic disease (hepatic metastases) or local nodal metastasis at index computer tomography imaging of abdomen and pelvis excludes ESD as a curative procedure. [58-9]

More recently in Japan, the indications for colorectal ESD have been established by the Colorectal ESD Standardization Implementation Working Group (Table 1). The development of various devices, endoscopes, and accessories for colorectal ESD have increased the safety of colorectal ESD, established its procedures, and simplified its techniques. Consequently, colorectal ESD has been gradually introduced in many institutions, both within Japan and in Asian countries. [59]

Indications for Colorectal ESD - Standardization Implementation Working Group

Lesions larger than 20mm in diameter in which en bloc resection using snare EMR is difficult, although it is indicative for endoscopic treatment

Non granular LST, particularly those of pseudodepressed type

Lesions with V₁ type pit pattern

Carcinoma with submucosal infiltration

Large depressed type lesion

Large lesions with elevated type suspected to be cancer (including granular LST that consisted of large nodules)

Mucosal lesions with fibrosis caused by prolapse due to biopsy of peristalsis of the lesions

Sporadic localized tumors in chronic inflammation such as ulcerative colitis

Local residual early cancer after endoscopic resection

To determine the indication of ESD magnification is essential in addition to standard colonoscopic observation. In principle, a lesion with submucosal massive invasion is not indicative. LST-G should be treated with findings of both magnification and standard colonoscopy as follows:

1) Homogenous granular type: EPMR



2) Focal mixed nodular type: deliberated EPMR or ESD



3) Whole large nodular type: ESD or surgery



LST-G should not be cut at the large nodule or the V type pit pattern. The skill level of the colonoscopist should also be considered in selection of therapeutic methods (EPMR, ESD or surgery).

ESD, endoscopic submucosal dissection; EPMR, endoscopic piecemeal mucosal resection; LST-G, granular laterally spreading tumor.

Table 1. Indications of ESD for colorectal neoplasms. The Colorectal ESD Standardization Implementation Working Group, a subordinate organization of the Gastroenterological Endoscopy Promotion Liaison Conference has proposed the Indication Criteria for Colorectal ESD (Tanaka S, Oka S, Chayama K. Colorectal endoscopic submucosal dissection: present status and future perspective, including its differentiation from endoscopic mucosal resection. *J. Gastroenterol.* 2008; 43: 641–51 (Review).

2.8. Assessment of tumour extent

Mucosal neoplasms in the colon and rectum typically have clear margins, which become even more prominent after submucosal injection and/or with the assistance of chromo-endoscopy. Thus in most cases, placing marks around the tumour prior to dissection is not necessary. Chromo-endoscopy with indigo carmine spray with or without the use of crystal violet dye, is useful to enhance the borders of the tumors. Newer imaging techniques, such as narrow band imaging (NBI) and flexible spectral imaging color enhancement (FICE) or Fuji Intelligent Color Enhancement (FICE®) (Fujifilm Corp., Tokyo, Japan) are also useful to determine the borders of these tumors.

2.9. Preparation and set-up

This aspect of the procedure is important in ensuring optimal conditions during a technically challenging procedure. Optimal vision of the operating field is essential. A well-prepared bowel can also limit the contamination and degree of peritonitis should a perforation occur.

2.9.1. Endoscopes

Thinner endoscopes are preferred for precise control of the tip. Some authors select a single channel upper endoscope for ESD for rectosigmoid and distal left sided lesions. In our case

series performed in a local institution, we used a specifically designed colonoscope (EC-450RD5; Fujifilm Corp., Tokyo, Japan; Fig. 4) for ESD in the colon and rectum. It is a single-channel scope with tip size (9.8mm) with a regular shaft size (12.8mm). This enables the usage of the retroflexed approach in any part of the colon and rectum as the tip is thin and short with good angulation ability. A relatively large accessory channel of 3.2 mm and a water jet function with good targeting direction make this scope suitable for ESD. The water jet allows the operator to wash out blood or mucus at the target area from their tips. A mixture of water with simethicon is used as a standard preparation solution for there is marked reduction in adherent residue and enables easier luminal lavage during ESD.

It is paramount to understand that maneuverability of the endoscope is the key factor in successful ESD and this should not be compromised. Hence, some authors report that in the cases of colorectal neoplasms, the application of the upper GI endoscopes is preferable to that of a slim single-channel endoscope. This is especially so when retroflexed manipulation is necessary as an endoscope with a small diameter allows smoother maneuverability in the retroflexed position. Such a position is recommended for large-sized lesions with its oral edge straddling a fold.




Figure 4. Colonoscope for ESD (EC-450RD5; Fujifilm Corp.). a The bending section of the endoscope tip is thin and short with good angulation capability. b A large accessory channel and a water jet channel are situated close to each other. c Water jet function of the scope. d Good targeting direction of the water jet to the tip of an accessory device.

When a lesion for ESD is located in an unstable part of the colon and paradoxical movements with a standard colonoscope hamper the reliable performance of the ESD procedure, we select a double-balloon colonoscope (EC-450BI5, Fujifilm, Japan; Fig. 5). The double-balloon colonoscope provides precise control of the endoscope tip, even in this situation (Fig. 6). The principle of DBE is well described by the co-author (H.Y.), and this has enabled optimal maneuverability and stability of the endoscope tip especially in the colon with its inherent anatomic variability in comparison to the oesophagus or stomach. Ohya and colleagues [54] highlighted these in their brief article on the use of a balloon over-tube as an endoscopic

channel and platform for colorectal ESD in cases whereby access was difficult due to the colon being a longer tubular structure, with folds and formation of loops during intubation resulting in paradoxical movements. These authors report that the use of the balloon over-tube enabled optimal traction on the intestinal wall, and provided a shorter direct access to the lesion.

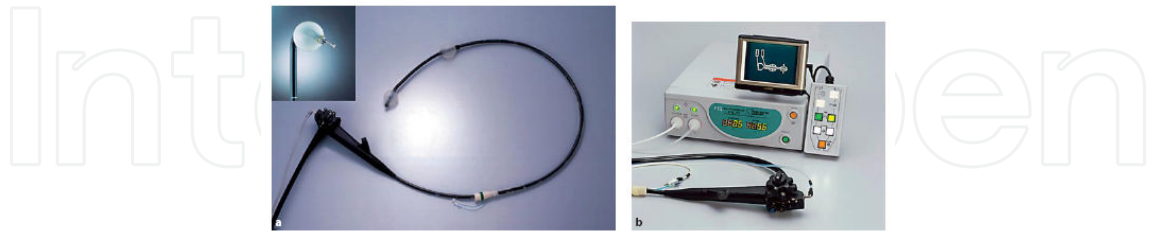


Figure 5. Double-balloon colonoscope (EC-450BI5, Fujifilm Corp.). a Soft balloons are equipped at the tip of the endoscope and the tip of the overtube. b A balloon controller to inflate or deflate the balloons.

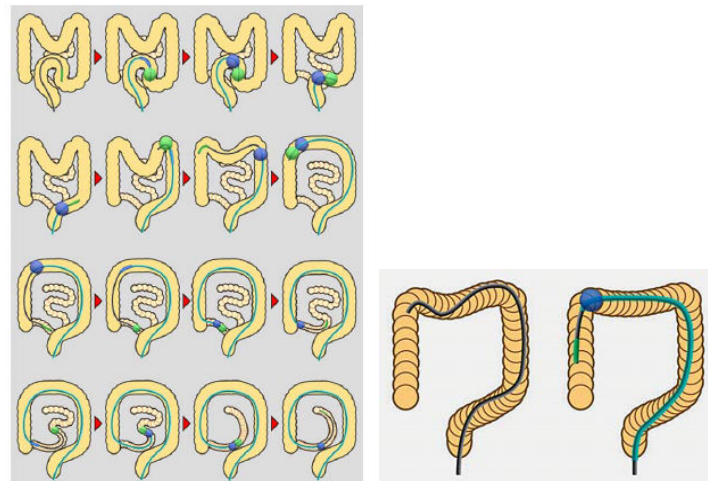


Figure 6. Illustrations demonstrating the sequential maneuvers of the instruments in the double-balloon method: (a) ante grade and (b) retrograde approach. Blue – paradoxical movements with standard colonoscope. Green – Precise control of endoscope tip provided by the double balloon (DB) colonoscope.

2.9.2. Accessories

Several kinds of electrosurgical knives have been developed for ESD. Among the currently available knives, we use a FlushKnife® (1.5mm; DK2618JN15; Fujifilm Corp., Tokyo, Japan) for ESD in the colon for our series. A FlushKnife® is a special needle knife featuring the water jet function through the knife sheath. The water jet function can be used to cleanse the surface of the mucosa and the needle itself. It can also be used for fluid injections directly into the submucosal layer through the FlushKnife® after mucosal incision. This improves its efficacy as it can be used for both injection and dissection. ESD can be performed immediately after the injection without changing the devices. The appropriate length of the needle can be selected from among 1, 1.5, 2, 2.5 and 3 mm sizes, based on the specific situation. (Fig 7)



Figure 7. Flush knife (DK2618JN10-30; Fujifilm Corp.). a The appropriate length of the needle can be selected from among 1, 1.5, 2, 2.5 and 3 mm sizes. b Water jet function through the knife sheath.

2.9.3. Hood

A transparent hood attached to the tip of the endoscope is useful to open the incised wound and to maintain a good endoscopic view during the procedure. It also allows precise control of the knife by stabilizing the target with its tip. Use of a hood is substituted for the triangulation used during surgical procedures, which is difficult to apply in endoscopic procedures. We mainly use a transparent hood with a small-caliber tip (ST hood; DH-15GR, DH-16CR; Fujifilm, Japan; Fig 8) for colonic ESD. The ST hood has an aperture small enough to make it easy to widen an incised wound using the edge of the hood, and to allow more accurate adjustment of the depth of incision by the knife point. Using the ST hood, it is easy to create a submucosal tunnel proceeding with submucosal dissection by inserting the tip of the hood into the submucosal layer, which is a useful strategy for effective ESD.




Figure 8. ST hood (DH-15GR, DH-16CR; Fujifilm Corp.). a Two sizes of the hood, DH-15GR for a thin endoscope tip and DH-16CR for a standard colonoscope tip) are available. b ST hood attached to the endoscope. c varying widths and heights for various locations and tissues

2.9.4. Electrosurgical current generator

The current and frequency of the electrosurgical current generator is of great importance to enable a reliable incision with effective control of bleeding and minimum tissue damage. We mainly use the ERBE VIO 300 D (Erbe, Tübingen, Germany). It is set to 'Endo Cut I' mode for mucosal incision, and to 'swift coagulation' or 'dry cut' mode for submucosal dissection. Table 2 is an example of the settings that was used in our case series.

	Device	Cut Mode	Coagulation Mode
Mucosal Incision	Flush knife	Endo Cut I	Dry Cut
		E1/D 4/11	E6 30 W
Submucosal Dissection	Flush knife	Dry Cut E6 30 W	Swift Coag E4 30 W
Hemostasis	Flush knife		Spray Coag E2 5 W
	Hemostatic Forceps		Soft Coag E6 80 W

Table 2. ERBE VIO 300D settings for ESD procedures (W: watts)

Minor bleeding and small blood vessels can be managed using the knife. However, more reliable hemostasis for a larger vessel can be achieved using hemostatic forceps (HDB2422W; Pentax, Tokyo, Japan). The generator is set to soft coagulation mode for the hemostatic forceps.

Effective control of bleeding during the procedure is a vital factor for successful ESD.

3. ESD technique

ESD for colorectal tumors has been considered more technically demanding as compared to that in the stomach. This can be attributed to these following reasons: (1) thinner and softer colonic wall, (2) endoscopic control is difficult in specific parts of the colon due to paradoxical movement; (3) limitations to the retroflexed approach due to the narrow caliber of the colon; (4) tumours located on or behind a prominent colonic folds, peristalsis, and (5) higher risk of diffuse peritonitis requiring emergency surgical intervention as compared to perforation of the upper gastrointestinal tract. [34]

Several devices have been applied to ESD in the colon and rectum with the principle to use a dissecting technique that allows direct visualization of the submucosal tissue, and to use long-lasting injecting fluid. [79-80]

3.1. Technical method

3.1.1. Approach strategy and technique for mucosal incisions and submucosal dissection

Success of the ESD procedure lies with the maneuverability and stability of the endoscope. Hence, the insertion must be done in a controlled manner to avoid loop formation if possible. Authors have reported that rotation is a key movement. Upon reaching the tumor, the lumen of the intestine is filled with a mixture of water and simethicon to ensure adequate visualization. Chromoendoscopy with indigo carmine is performed to characterize the surface details and extent of the lesion. The borders of the lesion should be clearly visualized. [34]

A good strategy with prior considerations to the angle of approach to the lesion, taking into account the direction of gravity in relation its location is recommended. This can be assessed by observing the direction of the course of the jet stream of water from the water-jet. The

position of the patient should be selected to locate the lesion at the top of the colonic lumen with regard to gravity. This enables sufficient opening of the mucosal incision and good visualization of the submucosal tissue during the procedure. Hence, minimal sedation for patient comfort is recommended if possible to allow patients to move positions more readily and report any undue discomfort during the procedure. In cases of unfavorable events such as bleeding and perforation, this positioning is beneficial to avoid or minimize further complications. In this position, bowel contents will not spill or leak into the intraperitoneal cavity and also, in situations of bleeding, blood will flow in the opposite direction (anti-gravity) to that of the lesion and not pool at the area of dissection. For example, if the bleeding point is at the top of the lumen, hemostasis can be performed reliably with accurate identification of the bleeding point because blood flows away from the bleeding point by gravity.

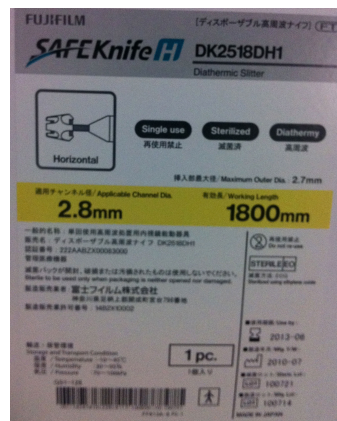Even in cases of perforation, if the perforation occurs at the top of the lumen with regard to gravity, identification and closing of the perforation is easier, maintaining a good view of the site of perforation. Air, not contaminated intestinal fluid, will flow out from the lumen to the abdominal cavity before closing the perforation, which is important to prevent diffuse peritonitis.

The mucosal incision is made only in the area to be dissected. This is made with a short FlushKnife (1.5 mm; DK2618JN15; Fujifilm Corp., Tokyo, Japan) after sufficient protrusion of the mucosa is obtained with injection of suitable fluid. The Endo Cut mode is used for the mucosal incision. ESD can be performed safely with a FlushKnife as long as adequate thickening of the submucosal layer is present. This maintains a safety margin away from the muscle layer. The dissection should be done parallel to the muscular layer, by sliding the knife from the centre of the tumor toward the mucosal incision on the side, while hooking submucosal fibers with the knife. There are several other types of knives available commercially and several other techniques have been described in literature but these are not described here.

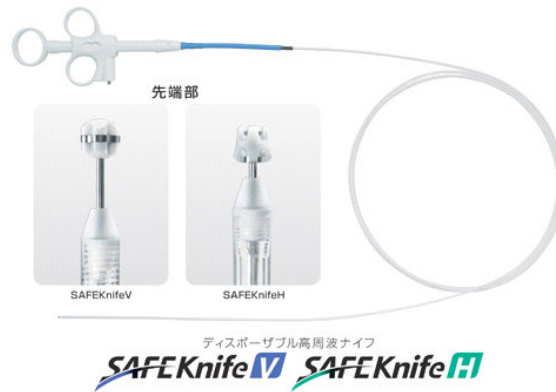Several newer strategies have been introduced over the last couple of years. As shown in Figure 9(a) [SAFEKnife Horizontal®. DK2518DH1 Fujifilm Corp, Tokyo Japan] newer knives have been designed to enable a different axis of cutting. These are introduced during the submucosal dissection itself during the procedure with the aim to achieve maximal safety and efficacy.

The mucosal incision is made only in the area to be dissected and then dissection of the submucosa from the incised part is promptly started. Circumferential marking around the tumor with the tip of the electrosurgical knife is recommended for lesions in the upper gastrointestinal tract but not for intestinal neoplasms as the colonic wall is thin enough to be perforated in the process.

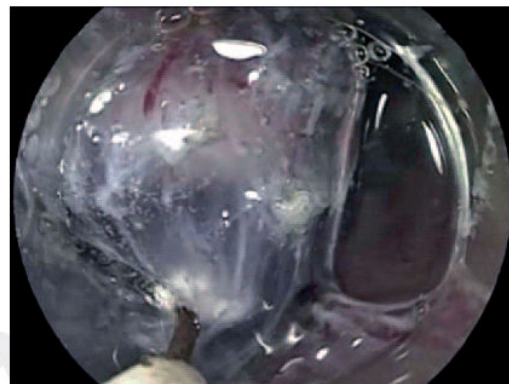
The development and subsequent maintenance of sufficient mucosal elevation is paramount for safe mucosal incisions and submucosal dissection. For these purposes, 0.4% sodium hyaluronate solution (MucoUp®; Seikagaku Corp, Tokyo, Japan) is the best injection fluid for ESD. [79-80]. The authors have found that the submucosal injection of sodium hyaluronate (0.4%) – commercially known as MucoUp®, (Johnson and Johnson Medical Co., Tokyo, Japan) enables the creation of a long-lasting mucosal protrusion that usually lasts more than 1 hour, providing the longest lasting fluid cushion, [49,79-80] and higher successful en-bloc resection



(a)



(b)



(c)

Figure 9. (a): SAFEKnife H[®] that cuts in the horizontal plane and (b) SAFEKnife V[®] that cuts in the vertical plane – invented by Dr H Yamamoto, manufactured by Fujifilm Corp Japan – 9(c) SAFEKnife V[®] has a sandwichlike structure with a central electrode plate placed between 2 insulated plates enabling a safe and effective diessction of the submucosal layers with a vertical approach

and lower perforation complication rates have been reported using HA, particularly for colorectal ESD [31,44,47,53-54]. However, in view of its high cost and unavailability locally (US \$49.50–128.00/mL in the United States), we have created our own solution using (Fig 10a-b) 4 vials of Optovisc Eyedrops[®] (Ashford, FP Marketing) (Fig 10a) to make up 40mls of solution. 0.4mls of 1:1000 Adrenaline with 4 drops of Indigo carmine solution (Fig 10b).

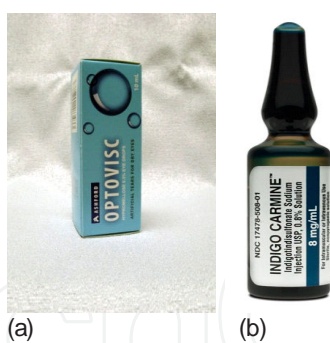


Figure 10. (a): one vial of Optovisc® (b): Indigo Carmine Solution

This solution is injected into the submucosal layer just outside where the mucosal incision is intended.

3.1.2. Mucosal incision

The mucosal incision is made with a short FlushKnife® (1.5 mm; DK2618JN15; Fujifilm Corp., Tokyo, Japan) after sufficient protrusion of the mucosa is obtained. Only the needle part should be used for the incision, keeping the tip of the sheath touching the surface of the mucosa without pushing the sheath into the submucosal layer. The Endo Cut mode is used for the mucosal incision, at 30 watts. (Table 2)

There is no need for complete marginal cutting of the mucosa before the submucosal dissection. Some authors report that after exposure of the submucosal layer, with the visualization of the blue-stained submucosal connective tissue, further submucosal injection from the exposed submucosal layers may be used to elevate the layer that is to be cut. If the blue submucosal layers is not seen, this may indicate that the muscularis mucosae layers is incompletely cut and the incising line should be traced again until the blue submucosal layer is seen.

3.1.3. Submucosal dissection

ESD can be performed safely with a FlushKnife® as long as adequate thickening of the submucosal layer is present. This maintains a safety margin away from the muscle layer. The dissection should be done parallel to the muscular layer, by sliding the knife from the centre of the tumor toward the mucosal incision on the side, while hooking submucosal fibers with the knife. The submucosal fibres stained blue (indigo-carmin) are very soft and dissected easily with gentle application of the FlushKnife® using the forced or swift coagulation mode. The knife length may be kept at the same length (<2mm) for both the mucosal incision and submucosal dissection.

A recent “tunneling” method has been introduced to dissect the submucosal layer, starting at the proximal edge of the colorectal tumour, followed by the distal edge.[34] Submucosal dissection is continued to make a tunnel in the submucosal layer by inserting the tip of the endoscope with a transparent hood under the mucosal tumor. This is continued to reach the mucosal incision at the proximal edge. After penetration of the tunnel, which began from both

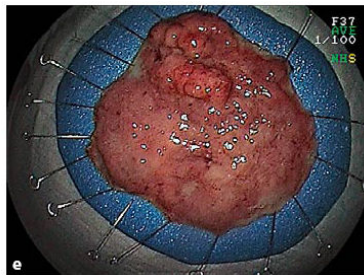


Figure 12. En bloc resection of the entire lesion (68 x 62 mm in diameter). Histopathologic examination confirmed complete curative resection (adenocarcinoma in adenoma, no invasion to submucosa, no lymphatic or vascular involvement); © Photographs courtesy of H Yamamoto 2010

ends, it is widened laterally. The mucosa on both sides of the tumour is then incised laterally and dissected submucosally to complete the dissection. (Fig.11). This tunneling technique enables the endoscope tip to be stabilized, hence a more precise control of the Flushknife® is achieved. This technique also enables a good safety margin for further dissection by stretching the submucosal tissue. Adjusting the approach angle of the knife to be tangential to the wall also is easy with this method because an adjusting force with the endoscope tip can be applied in either direction by pushing the mucosa up or pushing the muscle wall down with the tip of the hood (Fig 11b). This method is particularly useful for large lesions, lesions with fibrosis, and lesions located on a curved wall.

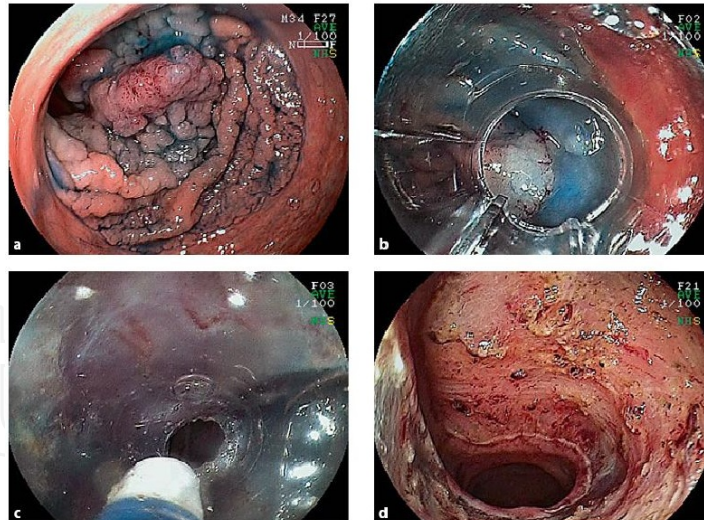


Figure 11. ESD using a tunneling method. a A large granular laterally spreading tumor (LST) in the rectum. b Distal edge of the tumor after submucosal injection of sodium hyaluronate solution. c Penetration of the tunnel in the submucosal layer. d Mucosal defect after the completion of ESD; © Photographs courtesy of H Yamamoto 2010

3.2. Handling of the resected specimen and histopathological assessment

The resected specimen is carefully retrieved per anally without tearing. A small specimen may be retrieved via suction into the soft hood/cap. A Roth net or other retrieval devices may be

used for moderate-sized lesions but with larger lesions, an over-tube may be required. The shape and orientation of the specimen is dutifully recorded, and the specimen pinned out on a Styrofoam or corkboard with the oral and anal sides indicated. The preservation of fresh material is ensured by freezing in liquid nitrogen, embedded in OCT prior to freezing, The slice is cut from the middle without warming up to allow a frozen section to be used for further analysis. We recommend the use of formalin soaked needles to fix the specimen, which should be tension-free as there is 20 to 50% shrinkage of the specimen soaked in formalin.

The ESD specimens are regarded as complex specimens and undergo a standardized processing during both macroscopic and microscopic assessment of the specimens. They are photographed with a styrofoam backing board, with the oral side of the specimen "O" at 12 o'clock position, and the anal side "A" at the 6 o'clock position to ensure that the orientation of the specimens are known. (Fig 12)

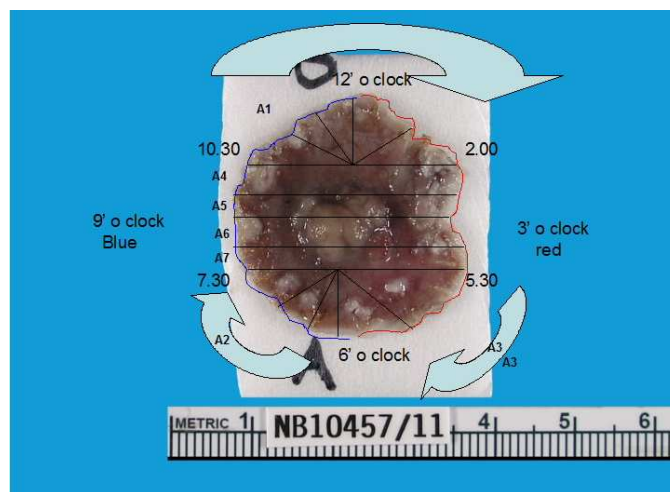


Figure 13. Mounting of a specimen on a Styrofoam board

Since 2009 to 2011, the specimen has been processed as shown below: The principle is to enable a fairly precise assessment of margin involvement. Currently, there are 2 methods of sectioning, each having their advantages and disadvantages. The first is described below whereby each transverse section should be submitted separately. The smaller fragments from the lateral edges should be submitted no more than 2 pieces per block. This has been performed since January 2009. The disadvantage of this method is that rounded irregular edges of such specimen are inadvertently shaved off during each 2mm sectioning and these margins cannot be assessed accurately when the sections happen to be tangential to the edge. The second method of sectioning aims to overcome the above problem. The axis of sectioning is perpendicular to the tangential line drawn at the edge. (Fig 14) This will enable more accurate margin assessment although tissue loss at the apex of each "segment" is inevitable. Inking of the margins is necessary and different colour should be used to represent the respective margins as required.

3.3. Standard operating procedures – Endoscopic Submucosal Dissections (ESD)

Currently all ESD specimens are regarded as complex specimens by the histopathology laboratory. They are photographed with the styrofoam backing board so that the orientation of the specimen is known. The principle of processing the ESD is to be able to tell the clinician fairly precisely where the margin is involved. An example of how the ESD specimen should be grossed and submitted is given below.

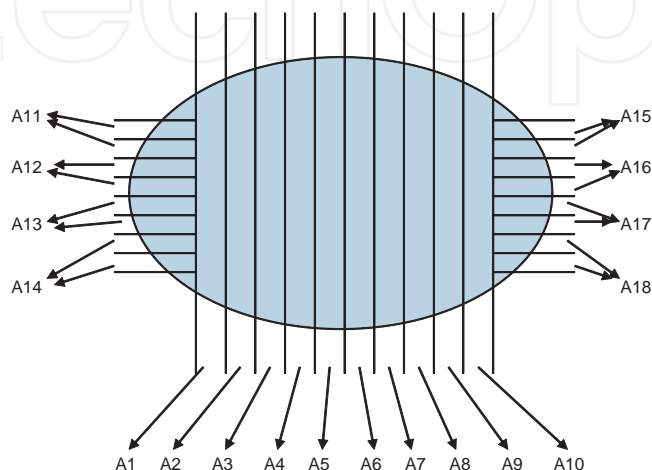


Figure 14. Pictorial diagram of how the specimen is sectioned and labeled

Each transverse section is submitted separately and the smaller fragments from the lateral edges should be submitted no more than 2 pieces per block. It is understood that some ESD specimen may have a rather irregular shape. In this situation, the pathologist or assistant trimmer should discuss with the consultant in charge how the specimen should best be processed so that the margins can be mapped back during microscopy.

An example of how the blocking should be represented in the photograph of the specimen is given below. This will be attached to the back of the report and filed. (Fig 14).

The completeness of the ESD is determined through precise histological evaluation. [56] Any intramucosal carcinoma for which the resection margins are free of tumor is considered radically curative. This is also true for cases where there is submucosal invasion that is limited to 1000 μm or less, or that the invasive front comprises of only highly or well-differentiated tumor. High risk factors for lymph node metastases are generally absent; hence further surgery is deemed unnecessary. [59]

Surgery is recommended for lesions with a high risk of local recurrence or lymph node metastases as seen in these following circumstances: lesions with 1) positive vertical (deep) margin; 2) those with submucosal invasion $>1000 \mu m$, 3) presence of vascular infiltration, 4) poorly or undifferentiated cancer front and 5) lesions with budding seen at the deepest part of invasion.




Figure 15. An example of how the trimming should be represented




Figure 16. Example of how the margins can be mapped in correlation with microscopy is given below to enable the clinician to be given appropriate information about the margins of concern.

The clinical course after a smooth and uneventful colorectal ESD is usually favorable. Soft food may be started a day after the treatment, presuming no symptoms, and oral intake is then gradually built up. These patients may be discharged from the hospital within 5 days of the treatment, irrespective of resection size. This is to allow identification of delayed complications such as bleeding or perforation. A few days of bowel rest and intravenous administration of antibiotics are recommended for patients who have had a perforation treated with immediate endoscopic closure; for the patient who complains of abdominal discomfort or develops fever.

Immediate surgical intervention is required for those who develop signs of general peritonitis. Patients who have localized peritonitis should be evaluated with radiologic investigation and clinical assessment, as this may be a result of post polypectomy syndrome. Patients who have had esophageal, gastric, or duodenal ESD, a follow-up endoscopic assessment is performed to check the healing process and identify exposed blood vessels with subsequent therapy. However, no such post-procedural examination is necessary after colorectal ESD, as the risk for delayed bleeding is relatively low. In such cases, patients are discharged from the ward within 1 week without checking ulcer healing. They will need to undergo follow-up endoscopies 2 months after the initial ESD to confirm healing and exclude recurrence.

In the recent years, various devices and peripheral equipment, as well as newer techniques, have been described by Japanese endoscopists. Colorectal ESD has henceforth become both safer and simpler. The Colorectal ESD Standardization Implementation Working Group in Japan reported the details and results of a nationwide questionnaire survey on the current situation of colorectal ESD in Japan. [61] They analyzed colorectal ESD performed from January 2000 to September 2008 by 194 of the 391 (28.8% of the total number of those institutions that responded). They reported the prevalence of colorectal ESD in Japan, the total number of colorectal ESD procedures performed during the stipulated period and compared it to the number performed in the last 1 year. They also investigated if those endoscopists that perform colorectal ESDs were performing gastric ESD; whether restrictions were placed upon those operators performing the ESD. Technical differences and equipment preferences were also analyzed.

Outcomes analysis was also performed. It was concluded that there was no observed relationship between the number of cases performed and the time required to complete an en bloc resection. However, operational difficulty was not documented in these comparisons.

The rate of complete en bloc resection of colorectal ESD for all the institutions was 83.8%. When stratified according to number of cases performed, the rate of complete en bloc resection of the institutions where 100 or more colorectal ESD had been performed was 90.2%; that of institutions where 50–99 colorectal ESD had been performed was 83.5%; that of those where 25–49 colorectal ESD had been performed was 85.3%; and that of those where 1–24 colorectal ESD had been performed was 82.2%.

Reported overall incidence of perforation as 4.8% from this survey, a value less than 5.9% reported by Tsuda et al in 2006. Reported rates from other series range from 4 to 10%, higher when compared with EMR (0.3 – 0.5%) [36,61-67]. Small perforations recognized during the procedure can be successfully sealed with endoscopic clips. [56,69,70], larger perforations require urgent salvage surgery to prevent peritonitis and its subsequent complications. [71] It can thus be postulated that the safety of colorectal ESD has increased over the recent years.

The overall incidence of hemorrhage was 1.9%. It is the most common complication of EMR and ESD, with rates reported ranging from 1% to 45%, with an average rate of 10% in larger series. [75-77] Most bleeding episodes are observed during the procedure or within the first 24 hours. [71] Delayed bleeding has been reported in up to 13.9% of patients. [72-73]

Hemostasis may be more difficult to achieve during the procedure as large elevated lesions, lesions that have been resected before and have developed fibrosis, and carcinomatous lesions develop strong neovascularization. Based on their survey, the authors recommended that to acquire a safe colorectal ESD technique, more than a certain number of cases should be performed. However, this “magic number” was not revealed. More importantly, there was no death occurring during this period of assessment in Japan. Table 3 demonstrates the safety and effectiveness of colorectal ESD and in these reports, ESD was performed on colorectal lesions with a median size of 29-37mm with an average procedure time of 90-120min. Niimi et al reports in a study of 310 consecutive patients who underwent ESD for colorectal epithelial neoplasms, overall survival rates were 97.1% at 3 years and 95.3% at 5 years during a median follow up of 38.7 months (range 12.8-104.2 months). Impressively, the disease specific survival rates were 100% at 3 years, leading the co-author (H.Y) to conclude that in expert hands, colorectal ESD is efficacious and safe.

Table 3 | Outcomes of colorectal endoscopic submucosal dissection

Study	Lesions (n)	Time (min)	Lesion size (mm)	Specimen size (mm)	En bloc resection (%)	Complete en bloc (%)	Bleeding (%)	Perforation (%)	Recurrence (%)
Niimi et al. (2010) ⁸⁵	310	NR	28.9 (6–100)	NR	90.3	74.5	1.6	4.8*	2
Nishiyama et al. (2010) ⁸⁶	300	NR	26.8	NR	89.2	79.1	0.7	8.1	0.3 [‡]
Saito et al. (2010) ²⁸	145	108±71	37±14	NR	84	NR	1.4	6.2	2
Saito et al. (2010) ⁸⁷	1,111	116±88	35±18	NR	88	NR	1.5	4.9 [§]	NR
Yoshida et al. (2010) ⁸⁸ Nonelderly	87	92 (20–270)	30.6 (12–80)	NR	93	NR	2.2	9.1	NR
Yoshida et al. (2010) ⁸⁸ Elderly	32	96 (40–290)	32.6 (15–70)	NR	81.2	NR	0	3.1	NR
Yamamoto (unpublished data)	467	60 (5–457)	NR	37 (21–170)	91.3	80.4	1.3	4.3	1.2

*Emergency surgery was required for one case of postoperative perforation. †One case of locally recurrent tumour with incomplete resection. ‡Two immediate perforations with ineffective endoscopic clipping and three delayed perforations required emergency surgery. Abbreviation: NR, not recorded.

Table 3. Summary of outcomes of colorectal ESD

4. Conclusion

ESD has emerged as an important therapeutic modality for superficial colorectal tumors, providing a high en bloc resection rate with lower morbidity as compared to surgical approaches. Both premalignant and early malignant tumors including depressed lesions and those with fibrosis can now be resected with adequate histological assessment. The nature of this procedure for colorectal lesions, with its inherent difficulties, must be recognized and hence a great degree of both skill and patience is required. Colorectal ESD has a higher risk of complication as compared to gastric or esophageal ESD and consequently, requires both a thorough knowledge and specific training to achieve satisfactory performance.

Acknowledgements

Dr Cheng Chee Leong & A/Prof Teh Ming. Department of Pathology, National University Hospital, Singapore

Author details

Koh Z.L. Sharon¹, H. Yamamoto² and Tsang B.S. Charles³

1 Division of Colorectal Surgery, National University Healthcare System, Singapore

2 Department of Medicine, Head of Division of Gastroenterology & Therapeutic Endoscopy, Jichi Medical University, Togichi, Japan

3 Colorectal Clinic Associates, Mt Elizabeth Novena Specialist Centre Singapore, National University of Singapore Yong Loo Lin School of Medicine, Singapore

References

- [1] Wolff, W. I. Colonoscopy: History and development. *Am. J. Gastroenterol.* 84:1017, (1989).
- [2] Wolff, W. I, & Shinya, H. Colonofiberscopy. *JAMA* (1971). , 217, 1509-562.
- [3] Shinya, H, & Wolff, W. I. Colonoscopic polypectomy: *Technique and safety. Hosp. Pract.* 24:71, (1975).
- [4] Deyhle, P, & Demling, L. Coloscopy: technique, results and indications. *Endoscopy* 3, (1971).
- [5] Sakai, Y. The technique of colonofiberoscopy. *Dis Colon Rectum* (1972). , 403-412.
- [6] Williams, B, & Teague, R. H. Progress report: colonoscopy. *Gut* (1973). , 14, 990-1003.
- [7] Morson, B. Bussey HJR. Predisposing causes of intestinal cancer *Current Problems in Surgery (February)*. (1970). Chicago Year Book Medical Publishers, , 3-50.
- [8] Morgenthal, C. B, Richards, W. O, Dunkin, B, et al. The role of the surgeon in the evolution of flexible endoscopy. *Surg Endoc* (2007). , 21, 838-853.
- [9] Winawer, S. J, Zauber, A. G, Ho, M. N, et al. Prevention of colorectal cancer by colonoscopic polypectomy. *N Engl J Med* (1993).

- [10] Muller, A. D, & Sonnenberg, A. (1995). Prevention of colorectal cancer by flexible endoscopy and polypectomy. A case-control study of 32,702 veterans. *Ann. Intern. Med.* 123904910
- [11] Hurlstone, D. P, Sanders, D. S, Cross, S. S, Adam, I, Shorthouse, A. J, Brown, S, Drew, K, & Lobo, A. J. Colonoscopic resection of lateral spreading tumours: a prospective analysis of endoscopic mucosal resection. *Gut* 5313341339(2004c).
- [12] Hellwig, A, & Barbosa, E. (1952). How reliable is biopsy of rectal polyps? *Cancer* 12, 620-624.
- [13] (1973a) Polypectomy via the fiberoptic colonoscope beyond the reach of the sigmoidoscopy. *New Engl. J. Med.* 1973; 288, 329-332
- [14] Christopher, B, Williams, R. H, Hunt, H, Loose, R. H, Riddell, Y, & Sakai, E. T. Swarbrick. Colonoscopy in the management of colon polyps. *Br. J. Surg.*(1974). , 61
- [15] Curtiss, L. E. High frequency currents in endoscopy: a review of principles and precautions. *Gastrointestinal Endoscopy* (1973).
- [16] Christopher, B. Williams and Laurent Bedenne. Management of colorectal polyps: Is all the effort worthwhile? *Journal of Gastroenterology and Hepatology Suppl.* 1, 1.(1990). , 14-165.
- [17] Jass, J. R. Do all colorectal carcinomas arise in preexisting adenomas? *WorldJ. Surg.* (1989). , 13, 45-51.
- [18] Lovli, R. R. Adenomas are precursor lesions for malignant growth in non-polyposis hereditary carcinoma of the colon and rectum. *Surg. Gynae Obst* (1986). , 162, 8-12.
- [19] Lee, Y. Early malignant lesions of the colorectum at autopsy. *Dis. Col. Rectum* (1988). , 31, 291-7.
- [20] Lynch, H. T, & Smyrr, T. Lansiw J Mak. Flat adenomas in a colon cancer-prone kindred. *J Natl Cancer Inst.* (1988). 27882, 80
- [21] Wayi, J. D. Techniques of polypectomy- hot biopsy forceps and snare polypectomy. *Amer. J Gastroenterol.* (1987). , 82, 615-8.
- [22] Vanagunas, A, Jacob, P, & Vakil, . . Adequacy of 'hot biopsy' for the treatment of diminutive polyps: a prospective randomised trial. *Amer. J Gastroenterol.* 1989; 84: 383-5.
- [23] Church, J. M, Fazio, V, & Jones, W. IT. Small colorectal polyps: are they worth treating? *Dis. Col. Rectum* (1988). , 31, 50-3.
- [24] Woods, A, Sanowski, R. A, & Wadas, D. Eradication of diminutive polyps: A prospective evaluation of bipolar coagulation versus conventional biopsy removal. *Gastrointest. Endosc.* (1989). , 35, 536-9.

- [25] Waye, J. D, Lewis, B, Atchison, M. A, & Talbott, M. The lost polyp: A guide to retrieval during colonoscopy. *Int J Colorect. Dis.* (1988). , 3, 229-31.
- [26] Gyorffy, J, & Amontree, S. . Large colorectal polyps: Colonoscopy, pathology and management. *Amer. J. Gastroenterol.* 1989; 84: 898-905.
- [27] Bertoni, G, & Ricci, E. Conigliarro. & Bedogni G. Endoscopic removal of large and giant colorectal polyps. *Coloproctology* (1987). , 4, 221-2.
- [28] Kudo, S, Tamegai, Y, & Yamano, H. Endoscopic mucosal resection of the colon: the Japanese technique. *Gastrointest Endosc Clin N Am* (2001). , 11, 519-35.
- [29] Iishi, H, Tatsuta, M, & Iseki, K. Endoscopic piecemeal resection with submucosal saline injection of large sessile colorectal polyps. *Gastrointest Endosc* (2000). , 51, 697-700.
- [30] Tamura, S, Nakajo, K, & Yokoyama, Y. Evaluation of endoscopic mucosal resection for laterally spreading rectal tumors. *Endoscopy* (2004). , 36, 306-12.
- [31] Buess, G, Kipfmuller, K, Hack, D, Grussner, R, & Heintz, A. Junginger T: Technique of transanal endoscopic microsurgery. *Surg Endosc* (1988).
- [32] Fujishiro, M. Endoscopic submucosal dissection for stomach neoplasms. *World J Gastroenterol* (2006). , 12, 5108-5112.
- [33] Kakushima, N, & Fujishiro, M. Endoscopic submucosal dissection for gastrointestinal neoplasms. *World J Gastroenterol* (2008). , 14, 2962-2967.
- [34] Yamamoto, H, et al. Endoscopic Submucosal Dissection for Colorectal Tumors. *Interventional and Therapeutic Gastrointestinal Endoscopy* (2010). , 27
- [35] Yahagi, N, Fujishiro, M, Kakushima, N, et al. Endoscopic submucosal dissection for lesions of the esophago-gastric junction and gastric cardia. *Gastrointest Endosc.* (2004).
- [36] Zhou et al Endoscopic Submucosal Dissection for Colorectal Epithelial Neoplasm. *Surg Endosc* (2009). , 2009, 23-1546.
- [37] Kato, M. (2005). Endoscopic submucosal dissection (ESD) is being accepted as a new procedure of endoscopic treatment of early gastric cancer. *Intern Med* , 44, 85-86.
- [38] Ono, H, Kondo, H, Gotoda, T, Shirao, K, Yamaguchi, H, Saito, D, Hosokawa, K, Shimoda, T, & Yoshida, S. (2001). Endoscopic mucosal resection for treatment of early gastric cancer. *Gut* , 48, 225-229.
- [39] Saito, Y, et al. Endoscopic Submucosal Dissection (ESD) for Colorectal Tumors. *Digestive Endoscopy* ((2009). supp) SS12, 7.
- [40] Hurlstone, D. P, et al. Achieving R0 resection in the colorectum using endoscopic submucosal dissection. *Br J Surgery* (2007). , 94, 1536-1542.

- [41] Yoshida, N, et al. Outcomes of endoscopic submucosal dissection for colorectal tumours in elderly people. *Int J Colorectal Dis* (2009).
- [42] Japanese Society for Cancer of the Colon and Rectum ((2005). Colorectal cancer treatment guidelines: the 2005 editionst edt. Kanahara-Shuppan, Tokyo
- [43] Tanaka, S, Oka, S, Tamura, T, et al. (2006). Molecular pathologic application as a predictor of lymph node metastasis in submucosal colorectal carcinoma: Implication of immunohistochemical alteration as the deepest invasive margin.
- [44] Muto, T, & Mochizuki, H. Masaki T (eds) Tumor budding in colorectal cancer: recent progress in colorectal cancer research. NOVA, Hauppauge, NY, , 171-180.
- [45] Tanaka, S, Haruma, K, Oka, S, et al. (2001). Clinicopathologic features and endoscopic treatment of superficially spreading colorectal neoplasms larger than 20 mm. *Gastrointest Endosc* , 54, 62-66.
- [46] Uraoka, T, Saito, Y, Matsuda, T, et al. (2006). Endoscopic indications for endoscopic mucosal resection of laterally spreading tumours in the colorectum. *Gut* , 55, 1592-1597.
- [47] Tanaka, S, et al. Strategy of Endoscopic Treatment for Colorectal Tumor. Recent Progress and Perspective.
- [48] Tanaka, S, et al. Colorectal Endoscopic Submucosal Dissection: present status and future perspective, including its differentiation from endoscopic mucosal resection. *J Gastroenterol* (2008).
- [49] Yamamoto, H, Kawata, H, Sunada, K, Sasaki, A, Nakazawa, K, Miyata, T, Sekine, Y, Yano, T, Satoh, K, Ido, K, & Sugano, K. (2003). Successful en bloc resection of large superficial tumors in the stomach and colon using sodium hyaluronate and small-caliber tip transparent hood. *Endoscopy* , 35, 690-694.
- [50] Gotoda, T. (2004). Endoscopic diagnosis and treatment for early gastric cancer. *Cancer Rev Asia Pacific* , 2, 17-37.
- [51] Saito et al Clinical outcome of endoscopic submucosal dissection versus endoscopic mucosal resection of large colorectal tumors as determined by curative resection. *Surg Endosc* (2009).
- [52] Hurlstone, D. P, Brown, S, & Cross, S. S. The role of flat and depressed colorectal lesions in colorectal carcinogenesis: new insights from clinicopathological findings in high-magnification chromoscopic colonoscopy. *Histopathology* (2003). , 43, 413-26.
- [53] Kudo, S, Shimoda, R, & Kashida, H. Laterally spreading tumor of colon: definition and history (in Japanese with English abstract). *Stomach and Intestine* (2005). , 40, 1721-5.

- [54] Tomohiko OhyaKen Ohata, Kazuki Sumiyama, Yousuke Tsuji, Ikuro Koba, Nobuyuki Matsushashi, Hisao Tajiri. Balloon overtube-guided colorectal endoscopic submucosal dissection. *World J Gastroenterol* (2009). December 28; , 15(48), 6086-6090.
- [55] Yamamoto, H, et al. Mucosectomy in the colon with endoscopic submucosal dissection. *Endoscopy* (2005). , 37, 764-768.
- [56] Fujishiro, M, Yahagi, N, Nakamura, M, Kakushima, N, Kodashima, S, Ono, S, et al. Successful outcomes of a novel endoscopic treatment for GI tumors: endoscopic submucosal dissection with a mixture of high-molecular-weight hyaluronic acid, glycerin, and sugar. *Gastrointest Endosc* (2006). , 63, 243-249.
- [57] Tamura, S, Nakajo, K, Yokoyama, Y, et al. Evaluation of endoscopic mucosal resection for laterally spreading rectal tumors. *Endoscopy* (2004). , 36, 306-12.
- [58] Japanese Society for Cancer of the Colon and Rectum Japanese Classification of Colorectal Carcinoma. Tokyo: Kanehara, (1997).
- [59] Kitajima, K, Fujimori, T, Fujii, S, et al. Correlations between lymph node metastasis and depth of submucosal invasion in submucosal invasive colorectal carcinoma: a Japanese collaborative study. *J Gastroenterol* (2004). , 39, 534-43.
- [60] Shinji TanakaYoshiro Tamegai, Sumio Tsuda, Yutaka Saito, Naohisa Yahagi and Hiro-o Yamano. Multicenter Questionnaire Survey of Colorectal Endoscopic Submucosal Dissection in Japan. *Digestive Endoscopy* ((2010). Suppl. 1), S8, 2.
- [61] Tanaka, S, Oka, S, Kaneko, I, et al. Endoscopic submucosal dissection for colorectal neoplasia: possibility of standardization. *Gastrointest Endosc* (2007). , 66, 100-7.
- [62] Oka, S, Tanaka, S, Kaneko, I, et al. Advantage of endoscopic submucosal dissection compared with EMR for early gastric cancer. *Gastrointest Endosc* (2006). , 64, 877-83.
- [63] Fujishiro, M, Yahagi, N, Kakushima, N, et al. Endoscopic submucosal dissection of esophageal squamous cell neoplasms. *Clin Gastroenterol Hepatol* (2006). , 4, 688-94.
- [64] Gotoda, T. A large endoscopic resection by endoscopic submucosal dissection procedure for early gastric cancer. *Clin Gastroenterol Hepatol* (2005). S, 71-3.
- [65] Ono, H. Early gastric cancer: diagnosis, pathology, treatment techniques and treatment outcomes. *Eur J Gastroenterol Hepatol* (2006). , 18, 863-6.
- [66] Fujishiro, M, Yahagi, N, Nakamura, M, et al. Endoscopic submucosal dissection for rectal epithelial neoplasia. *Endoscopy* (2006). , 38, 493-7.
- [67] Inoue, H. Endoscopic mucosal resection for esophageal and gastric mucosal cancers. *Can J Gastroenterol* (1998). , 12, 355-9.
- [68] Yokoi, C, Gotoda, T, Hamanaka, H, & Oda, I. Endoscopic submucosal dissection allows curative resection of locally recurrent early gastric cancer after prior endoscopic mucosal resection. *Gastrointest Endosc* (2006). , 64, 212-8.

- [69] Yoshikane, H, Hidano, H, Sakakibara, A, et al. Endoscopic repair by clipping of iatrogenic colonic perforation. *Gastrointest Endosc* (1997). , 46, 464-6.
- [70] Kim, H. S, Lee, D. K, Jeong, Y. S, et al. Successful endoscopic management of a perforated gastric dysplastic lesion after endoscopic mucosa l resection. *Gastrointest Endosc* (2000). , 51, 613-5.
- [71] Larghi, A, & Waxman, I. State of the art on endoscopic mucosal resection and endoscopic submucosal dissection. *Gastrointest Endosc Clin North Am* (2007). v., 17, 441-69.
- [72] Morales, T. G, Sampliner, R. E, Garewal, H. S, et al. The difference in colon polyp size before and after removal. *Gastrointest Endosc* (1996). , 43, 25-8.
- [73] Lee, S. H, & Park, J. H. Park do H, et al. Clinical efficacy of EMR with submucosal injection of a fibrinogen mixture: a prospective randomized trial. *Gastrointest Endosc* (2006). , 64, 691-6.
- [74] Binmoeller, K. F, Bohnacker, S, Seifert, H, et al. Endoscopic snare excision of "giant" colorectal polyps. *Gastrointest Endosc* (1996). , 43, 183-8.
- [75] Kodama, M, & Kakegawa, T. Treatment of superficial cancer of the esophagus: a summary of responses to a questionnaire on superficial cancer of the esophagus in Japan. *Surgery* (1998). , 123, 432-9.
- [76] Rembacken, B. J, Gotoda, T, Fujii, T, et al. Endoscopic mucosal resection. *Endoscopy* (2001). , 33, 709-18.
- [77] Iishi, H, Tatsuta, M, Iseki, K, et al. Endoscopic piecemeal resection with submucosal saline injection of large sessile colorectal polyps. *Gastrointest Endosc* (2000). , 51, 697-700.
- [78] Stergiou, N, Riphaus, A, Lange, P, et al. Endoscopic snare resection of large colonic polyps: how far can we go? *Int J Colorectal Dis* (2003). , 18, 131-5.
- [79] Yamamoto, H, Koiwai, H, et al. A successful single-step endoscopic resection of a 40 millimeter flat-elevated tumor in the rectum: endoscopic mucosal resection using sodium hyaluronate. *Gastrointestinal Endoscopy* 50:5: 701-4. (1999).
- [80] Yamamoto, H, Yube, T, Isoda, N, Sato, Y, Sekine, Y, et al. A novel method of endoscopic mucosal resection using sodium hyaluronate. *Gastrointest Endo* (1999). , 50, 251-6.

