

We are IntechOpen, the world's leading publisher of Open Access books Built by scientists, for scientists

4,800

Open access books available

122,000

International authors and editors

135M

Downloads

Our authors are among the

154

Countries delivered to

TOP 1%

most cited scientists

12.2%

Contributors from top 500 universities



WEB OF SCIENCE™

Selection of our books indexed in the Book Citation Index
in Web of Science™ Core Collection (BKCI)

Interested in publishing with us?
Contact book.department@intechopen.com

Numbers displayed above are based on latest data collected.

For more information visit www.intechopen.com



Pseudoexfoliation and Cataract

George K. Andrikopoulos and Sotirios P. Gartaganis
*Department of Ophthalmology, Medical School, University of Patras
Greece*

1. Introduction

Pseudoexfoliation (PXF) syndrome is a pathologic accumulation of abnormal fibrillar deposits on various ocular structures and extraocular tissues (Figure 1). It is an age-related disorder of the extracellular matrix that may affect up to 20% of people over the age of 60. Although the specific synthesis and pathogenesis of PXF syndrome are still unknown the concept of an elastotic process has recently been established by the finding of the lysyl oxidase-like 1 (LOXL 1) gene as a major risk factor for PXF syndrome and PXF glaucoma (Thorleifsson et al., 2007). It was first described by a Finnish ophthalmologist named John Lindberg, in 1917 in his doctoral thesis. With the aim of a newly developed slit-lamp, he defined the grayish flecks and the changes on the lens and the pupillary margin of the iris in 50% of patients with chronic glaucoma.

The reported prevalence rates vary extensively in different populations like: general population, persons over a certain age, patients with cataract or glaucoma, patients with severe glaucoma. The examiner and the method (mydriasis or not, early stages or not) also play an important role in the prevalence. Its prevalence varies considerably between countries and even within regions or between ethnic groups within many countries. Low rates have been found in Greenland Eskimos (0%), in India (4.2% in patients older than 70 years), in the eastern part of the United States (5% in patients between 75 and 85 years old), in Germany (1.5% in patients 70-79 years of age and 6.3% in those between 80 and 89) and in Britain (2% in 70-79 and 5.4% in 80-89) (Vesti & Kivela, 2000). Also in Australia (2.2% in older than 40), in Japan (1.24% in older than 40) (Ringvold, 1999) and in Austria (1.7%), in Denmark (2%) and in Switzerland (2%) in patients older than 60 years old (Forsius, 1988). On the other hand, high frequencies have been reported in Iceland (31.5%), Finland (>20%), Saudi Arabia (26.5%), Russia (21.4%), Tunisia (19.1%), all in patients older than 70 years old and in Greece (20.1% in ages 70-79 and 46.9% in patients older than 80) (Vesti & Kivela, 2000). Also, in Sweden (18% in ages 65-74), in Norway (16.9% in older than 65) (Ringvold, 1999) and in Turkey (18% in older than 60) (Forsius, 1988). In southwestern Greece in a cross-sectional study of patients admitted at the hospital for cataract surgery we found the prevalence of PXF syndrome to be 27.9% (Andrikopoulos et al., 2009).

Pseudoexfoliation syndrome has been associated with cataract progression, increased intraocular pressure and intraoperative complications like zonular or posterior capsule rupture, poorly dilating pupils, vitreous loss and postoperative fibrinoid reaction or luxation of intraocular lens implants. It is the most common identifiable cause of open-angle glaucoma, the pseudoexfoliation glaucoma. The later is characterized by worse prognosis

than primary open angle glaucoma, rapid progression and higher resistance to medical therapy.

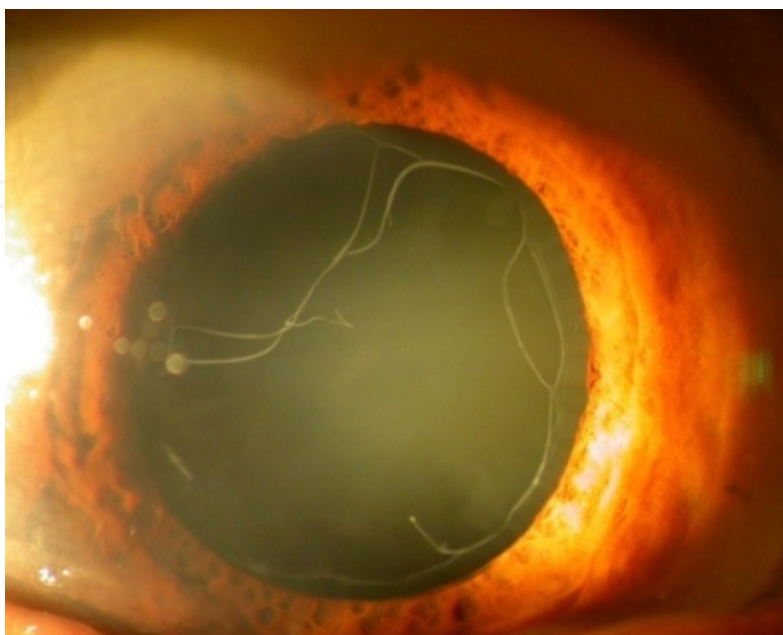


Fig. 1. Pseudoexfoliation material.

The definite clinical diagnosis of PXF deposits can be made only in the last stages of classic PXF (fibers in the two zones) and in the stage of mini-PXF (focal defects in the precapsular layer nasal superiorly). Next to the lens PXF deposits are most prominent to the pupillary border. Additional subtle clinical signs at the slit-lamp examination include loss of melanin from the peripupillary pigment epithelium of the iris, transillumination defects in the sphincter area, insufficient mydriasis, posterior synechiae, zonular instability, melanin deposition and melanin dispersion (on the structures of anterior segment) after pupillary dilation.

It appears that a variety of epithelial and mesenchymal cells may be associated with disordered synthesis of the extracellular fibrillar material in different sites. The intraocular material seems to be produced mainly in the pre-equatorial lens epithelium, the nonpigmented ciliary epithelium and the iris pigment epithelium and secondarily in the corneal endothelium, the trabecular endothelium and by almost all cell types of the iris stroma (Ritch & Schlötzer-Schrehardt, 2001). Secondary distribution by the aqueous humor is responsible for its passive deposition on the other structures of the anterior segment. The extraocular PXF material has been demonstrated electron microscopically in close proximity to fibroblasts, smooth and striated muscle cells, and heart muscle cells (Schlötzer-Schrehardt et al., 1992a; Streeten et al., 1992). These types of cells are probably involved in its production in various visceral organs.

There are two major theories on the pathogenesis of PXF syndrome. The first links the exfoliation fibers to the elastic microfibrils of the elastic system. It describes PXF syndrome as a type of elastosis, an elastic microfibrilopathy with excessive production of elastic fiber components (Garner & Alexander, 1984; Streeten et al., 1986). The second theory considers PXF syndrome to be a generalized disorder of the basement membranes (Dickson & Ramsay, 1975), with a variety of basement membrane components to have been recognized

in the PXF material (Eagle et al., 1979; Harnisch et al., 1981; Konstas et al., 1990; Kubota et al., 1998; Schlötzer-Schrehardt et al., 1992b; Tawara et al., 1996). Growth factors (GFs) and particularly Transforming Growth Factor- β 1 (TGF- β 1), impaired cellular protection system with increased cellular and oxidative stress, an imbalance between Matrix Metalloproteinases (MMPs) and Tissue Inhibitor of Metalloproteinases (TIMPs), ischemia/hypoxia, cross-linking process and aggregation of misfolded stressed proteins appear to be involved in the pathogenetic concept of this fibrotic disorder with accumulation of extracellular material (Gartaganis et al., 2001, 2002, 2005, 2007; Schlötzer-Schrehardt & Naumann, 2006; Schlötzer-Schrehardt, 2009).

The exact chemical composition of PXF material remains unknown. It seems to consist a complex of glycoprotein/proteoglycan with epitopes of the basement membrane and the elastic fiber system. The protein components of PXF material include non-collagenous basement membrane elements (such as laminin, nidogen, and fibronectin), epitopes of elastic fibers (such as elastin, tropoelastin, amyloid P, vitronectin) and components of elastic microfibrils such as fibrillin-1, emilin, microfibril-associated glycoprotein-1, and latent TGF- β binding proteins 1-2) (Ritch & Schlötzer-Schrehardt, 2001). Other proteins are cross-linking enzymes, chaperones, apolipoproteins, glycosaminoglycans, complement proteins, proteolytic enzymes and their inhibitors, and cytokines like TGF- β 1. The glycosaminoglycans and proteoglycans include heparan sulfate proteoglycan, chondroitin sulfate proteoglycan, dermatan sulfate proteoglycan, keratan sulfate proteoglycan, and hyaluronan (Fitzsimmons et al., 1997; Harnisch et al., 1981; Schlötzer-Schrehardt et al., 1992b; Tawara et al., 1996). The microfibrillar subunits seem to form a core surrounded by an amorphous matrix, which is suggested to represent glycosaminoglycans on the surface of the exfoliation fibrils.

2. Pseudoexfoliation syndrome and cataract formation

An association between PXF and cataract formation appears to exist. Nuclear cataract and secondarily subcapsular cataract are more frequently found in eyes with PXF than in eyes without PXF. And opposite, PXF has a higher prevalence in eyes with cataract (Hietanen et al., 1992). In a study conducted by the authors the prevalence of cataract in eyes with PXF was found 87.4% and in eyes without PXF 79.9%. And opposite, PXF prevalence in eyes with cataract was found 24.2% and in eyes without cataract 15.5% (Andrikopoulos, 2009). Eyes with PXF have been found with poorer visual acuity and more often lens opacification than clinically uninvolved fellow eyes (Puska, 1994). Cataract formation may be related to ocular ischemia, aqueous hypoxia, reduced protection against ultraviolet radiation, increased growth factor levels and oxidative stress. Ascorbic acid, that plays an important role in protecting the lens from ultraviolet irradiation, has been found reduced in the aqueous humor of patients with PXF deposits (Koliakos et al., 2003).

3. Pseudoexfoliation syndrome and cataract surgery

3.1 Intraocular manifestations of pseudoexfoliation syndrome that predispose to surgical complications

Lens In contrast to the characteristic changes in the anterior capsule which are relatively harmless, the pre-equatorial lens epithelium disorders may be associated with dangers for the intraocular surgeon. In the area corresponding to the proliferative zone of the epithelium

and the zone of zonular anchorage, deposits infiltrate and disrupt the lens capsule and the zonular lamella, resulting in separation of the zonules insertion on the capsule surface (Schlötzer-Schrehardt & Naumann, 1994). This peripheral region is the only area with active production of PXF material by the metabolically active epithelium. These changes are hidden behind the iris and thus clinically invisible, but responsible for the instability of the zonular attachment.

Zonules and ciliary body In cases associated with phacodonesis or lens luxation, degeneration of zonular attachment sites is usually observed (Schlötzer-Schrehardt & Naumann, 1994). Areas of weakness and zonular dehiscence include the zonular fibers themselves but also their anchorage sites to the defective basement membranes of the ciliary epithelium and lens. Proteolytic-lysosomal enzymes, that have been found within PXF material, may also be linked with the zonular disintegration. Zonular instability and subsequent laxity of the lens allows anterior lens movement resulting in pupillary or even ciliary block, that predispose to angle closure glaucoma. Attacks of angle closure glaucoma, because of inferior displacement of the lens, can occur, particularly under miotic therapy.

Iris Virtually all iris cell types are involved in PXF material production and deposition. Clinically PXF iris is characteristically rigid with reduced dilating properties. Dispersion of melanin granules, after pharmacological dilation, due to rupture of degenerative posterior pigment epithelial cells, may result in acute rise in IOP. Iris stromal vessels, because of deposition of fibers in the adventitia, may become obliterated resulting in hypoperfusion and iris microneovascularization. Neovascularization may result in microhyphema after pharmacologic dilation. PXF ocular ischemia may play a role in cataract formation too. Iris vasculopathy may be associated with a chronic breakdown in the aqueous barrier, that may manifest as pseudouveitis with posterior synechiae and elevated aqueous flare. Blood-aqueous barrier dysfunction is greater in eyes with PXF compared to eyes without PXF, after intraocular surgery, resulting in a transitory fibrinoid reaction. Posterior synechiae are common in PXF eyes due to adherence of the posterior pigment epithelium to the PXF coated anterior lens capsule or to miotics that inhibit iris movement. A combination of PXF fibers deposition in the stroma and muscle tissue with vascular disorders leads to hypoxia (Repo et al., 1995) and tissue degeneration that result in reduced dilating properties of iris (Asano et al., 1995). Even without mydriatics, the pupil in PXF eyes may be smaller (suggesting a defective dilator muscle or reduced sympathetic innervation).

Trabecular meshwork The deposits of PXF material and probably the melanin pigment throughout the trabeculum and the degenerating changes of the juxtacanalicular tissue beneath the inner wall of Schlemm's canal are the major mechanisms of PXF open-angle glaucoma (Ringvold & Vegge, 1971; Schlötzer-Schrehardt & Naumann, 1995). The pathologic alterations of Schlemm's canal include narrowing, fragmentation and obstruction in advanced cases. Apart from the obstruction to trabecular outflow, increased aqueous protein levels (due to persistent blood-aqueous barrier breakdown), an impaired ocular and retrobulbar perfusion and disorder of elastic tissue of the lamina cribrosa (Netland et al., 1995), have also been proposed. It is well known that PXF is the most common identifiable cause of open-angle glaucoma (Ritch, 1994a). It is also associated with a higher incidence of narrow angles (Herbst, 1976; Ritch, 1994b).

Cornea The corneal endothelium shows focal degeneration, phagocytosis of melanin granules and PXF fibers production. Central corneal thickness has been found greater in eyes with PXF. These changes together with a reduced endothelial cell density may lead to an irregular thickening of the Descemet membrane. The dysfunctional endothelium in PXF

eyes increases the risk of corneal endothelial decompensation with normal or after moderate rises in intraocular pressure (IOP), for example after mydriasis or after cataract surgery.

3.2 Preoperative considerations

Recognition of PXF material is critical for reducing operative complications. The classic pattern of three distinct zones of PXF material on the anterior lens surface represents a very late stage of the disease. In early stages a diffuse pre-capsular layer of microfibers ("early PXF") can be observed on the entire surface of the anterior lens capsule. Later focal defects in the midperipheral zone usually superonasally ("mini PXF") may alert the ophthalmologist. The importance of a dilated pupil and the comparison with the fellow eye have been emphasized by a number of authors. Iris changes like transillumination defects, melanin pigment liberation associated with pupil dilation, poor mydriasis or asymmetric pupil sizes and circular posterior synechiae are useful signs. Other early clinical signs are: PXF or melanin deposition on the anterior chamber structures (especially the trabecular meshwork), marked asymmetry of IOP or marked IOP rise after pupillary dilation, phacodonesis and atypical cornea guttata. In eyes with mature cataract it is mandatory to look carefully for PXF deposits as they may have the same colour with the grey-white cataract.

The complication rates of cataract extraction in PXF syndrome are higher compared to control. Phacoemulsification in PXF eyes is associated with increased rates of capsular and zonular tears and vitreous loss (Drolsum et al., 1993; Shingleton et al., 2003). On the other hand, recent studies around the world have shown no statistically significant difference in complication rates during phacoemulsification of PXF eyes (Akinci et al., 2008; Dosso et al., 1997; Hyams et al., 2005) than earlier studies that showed up to a 10-fold increase. Phacoemulsification performed by experienced surgeons, in combination with advanced technologies and devices, have decreased the risks. It is reported, in recent studies, that a thorough cataract consideration is important, in eyes with PXF syndrome, as it can minimize the risk for complications (Belovay et al., 2010; Drolsum et al., 2007; Shingleton et al., 2009; Tanhehco & Chen, 2010).

Zonule weakness The signs of zonular weakness include phacodonesis, lens subluxation, narrow iridocorneal angle, zonule dialysis and iridodonesis. Iridodonesis is best assessed prior to dilation, while phacodonesis, lens subluxation and zonule dialysis after maximum mydriasis. A shallow or hyper-deep anterior chamber may consist an indirect sign of zonule instability and lens displacement. A central anterior chamber depth less than 2.5 mm has been reported to increase the risk for surgical complications 5-fold in PXF eyes (Küchle et al., 2000). An asymmetry in anterior chamber depth or significant differences in refraction between the two eyes may be indicative of a subluxated lens. The increased cataract density, the increasing age and the reduced pupil size are indirect clinical predictors of zonule instability, while the amount of PXF material does not seem to be a predicting factor (Moreno et al., 1993). Ultrasound biomicroscopy can be useful to check the zonule status like infiltration of PXF fibrils, fragmentation or zonule loss. Zonular fragility has been associated with a 3 to 10-fold increased risk of zonular rupture and lens dislocation and a 5-fold increased risk of vitreous loss (Schlötzer-Schrehardt & Naumann, 2006).

Small pupil Poor pupil dilation may limit the size of the capsulorhexis. A small capsulorhexis often leads to increased and traumatic forces on the zonular apparatus and increased risk for capsular tear and postoperative capsule phimosis. The increased difficulty in extracting nuclear material from the capsular bag, due to a small pupil, can also lead to iris trauma and intraoperative bleeding.

It is also important to check carefully the corneal endothelial status, as reduced endothelial cell counts increases the risk of corneal endothelial dysfunction or decompensation.

3.3 Intraoperative considerations

Many surgical approaches have been used to avoid corneal failure and to manage a small pupil and zonular weakness.

Corneal endothelium Dispersive ophthalmic viscosurgical devices are helpful to adhere, coat and protect the cornea. Cohesive ophthalmic viscosurgical devices can help to dilate a small pupil and to maintain the anterior chamber (Shingleton et al., 2009). Overinflating the anterior chamber with viscoelastics should be avoided as it may cause undue stress on the zonules.

Small pupil In phacoemulsification it is not needed to extrude the nucleus through a full dilated pupil as in extracapsular cataract extraction. However, as PXF eyes respond poorly to mydriatics many strategies are frequently required intraoperatively. Pharmacologically, nonsteroid anti-inflammatory drops in combination with mydriatics can help to expand the pupil (Keates & McGowan, 1984). Mechanical enlargement of the pupil includes stretching, cohesive ophthalmic viscosurgical devices, release of posterior synechiae, sphincterotomy as well as iris hooks and pupil dilator rings. Special iris hooks (Figure 2a) can be used to allow visualization of the peripheral capsule and to release posterior synechiae. Bimanual stretching with Y-hooks, the Beehler pupil dilator, iris retractor hooks and pupil dilator polymethyl methacrylate rings have all been shown to be equally effective (Akman et al., 2004). Other pupil expansion devices like the Malyugin ring (Figure 2b), the Perfect pupil expansion device and the Graether pupil expander have also been used. However, pupil stretching and cutting should be avoided in patients predisposed to floppy-iris syndrome (Chang et al., 2008). Also, pupil mechanical dilation may lead to iris injury and hyphema, pigment release, postoperative inflammation and sometimes to a permanently dilated pupil.

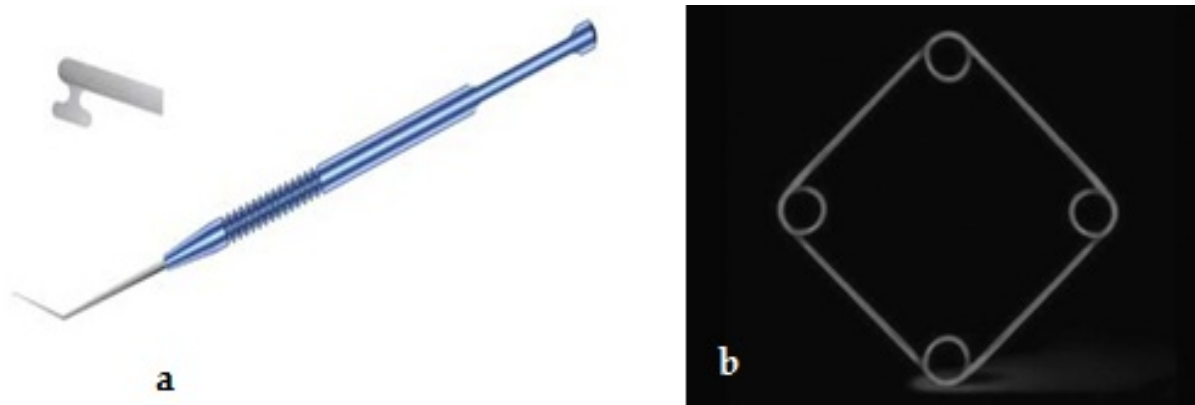


Fig. 2. a. Iris hook, b. Malyugin ring.

Zonule weakness When the zonules are loose a capsule tension ring (CTR) placed within an intact capsular bag may be useful (Figure 3a). It provides capsular bag expansion and supports the part of zonule instability, distributing the zonule tensions from the weakened zonules onto the remaining zonules. In this way it can provide buttress for the entire capsule-zonular apparatus (Menapace et al., 2000). It is reported that a CTR can center a mildly subluxed lens (equal or less than 4 hours zonulopathy and/or mild phacodonesis) (Hasanee & Ahmed, 2006) but does not prevent the progressive zonulopathy and the

following decentration in the presence of PXF material (Ahmed et al., 2005a). Also, it should not be used in cases of anterior or posterior capsular tear. Although a CTR can be implanted at any time after performing the capsulorhexis, most surgeons propose delaying implantation. It was found that CTR implantation before nucleus extraction gave increased capsular torque and displacement compared to implantation after the nucleus had been extracted (Ahmed et al., 2005b). Although some surgeons propose the use of a CTR in all PXF cases, regardless of whether zonule instability is present, the implantation can be hazardous and should better be performed only in cases of zonule instability, as it may create capsule and zonule trauma or entrapment of cortex behind it (Ahmed et al., 2005b). Regardless of these limitations, a CTR implantation has been found to reduce intraoperative complications in PXF cases and to decrease postoperative IOL decentration and tilt (D.-H. Lee et al., 2002). Lower rate of intraoperative zonular separation, posterior capsular rupture and increased rate of intraocular lens (IOL) fixation in the capsular bag have also been reported in PXF eyes with CTR implantation compared to controls (standard phacoemulsification) (Bayraktar et al., 2001).

In more advanced cases of profound zonule fragility a modified CTR, with a single or double eyelet for suture fixation to the sclera in areas of weakness, should be considered (Cionni & Osher, 1998) (Figure 3b). Capsule either iris retractors placed at the edge of capsulorhexis can be effective in holding capsulorhexis in place during phacoemulsification. They can also provide support for the capsulozonular complex (V. Lee & Bloom, 1999; Santoro et al., 2003). In advanced cases of profound zonule instability a capsule tension segment (CTS) can be useful (Figure 3c). The capsule tension segment serves as retracting apparatus and supporting stent for the capsular bag during phacoemulsification (Hasanee et al., 2006). It has an eyelet that can be used for suture fixation to the sclera in areas of weakness providing postoperative stability and good centration of the IOL/capsular bag complex. Unlike the larger CTR and modified CTR, the CTS can be positioned atraumatically and safely in the presence of an anterior or posterior capsule tear provided the CTS is not positioned within the tear itself. One or two CTR devices can be used simultaneously too.



Fig. 3. a. Capsule Tension Ring, b. modified Capsule Tension Ring, c. Capsule Tension Segment.

If despite the use of all the above devices intraoperative subluxation of lens fragment or capsular bag complex occur, the technique should be modified. In these cases most capsule tension devices are contraindicated and the available options include elevating the

remaining lens into the anterior chamber for anterior phacoemulsification or conversion to extracapsular or modified intracapsular cataract extraction. If there is a deep vitreous dislocation, pars plana vitrectomy and lensectomy are preferred. Posterior chamber lens may also be placed in the ciliary sulcus, even in the presence of small capsular tears providing sufficient support exists. Otherwise, an angle-supported IOL, an iris-claw IOL or an IOL fixed to the sclera wall may be mandatory (Dick & Augustin, 2001). An angle-supported anterior chamber IOL should probably be avoided in cases of eyes with glaucoma or corneal endothelial cell abnormalities (Drolsum, 2003).

Surgical technique In phacoemulsification the rate of intraoperative complications in PXF eyes is significantly lower than in extracapsular cataract extraction (ECCE) and seems to be related to zonular and not to capsule weakness (Shingleton et al., 2003). Small incision, less tension on the capsule and the zonules, less anterior chamber depth fluctuations are some of the advantages provided by the phacoemulsification, that have increased the safety of cataract surgery. On the other hand, the increased force needed to extrude the lens through a small pupil and the previous can-opener or envelope techniques with the increased risk of posterior capsule rupture may explain the higher frequency of intraoperative complications in ECCE.

When zonule instability is suspected, overinflating the anterior chamber with viscoelastics should be avoided. Also, avoidance of excessive fluctuations in anterior chamber pressure and gentle manipulation of the lens in phacoemulsification are recommended. Maintenance of anterior chamber avoids vitreous prolapse around the capsular bag. Small incision surgery, controlled paracentesis and adequate hydrodissection are some more useful strategies.

The continuous circular capsulorhexis (CCC) should be neither too small, nor too large. The ideal size is 5-5.5mm in diameter. A small CCC may lead to increased stress to a loose zonule during manipulation of the lens and to anterior capsular phimosis. A large CCC may preclude the use of capsule devices and may be suboptimal for IOL fixation. In PXF cases with zonule instability, CCC initiation and spread of the capsular tear may be difficult, as countertraction is decreased. A sharp needle puncture, a CCC forceps or a bimanual technique with a micrograsper and a sharp tipped instrument can help in CCC initiation. Hooks or capsule retractors at the cut edge of the CCC can help address the spread of the capsule tear (Shingleton et al., 2009). Capsule staining (trypan blue) may be helpful allowing for visualization of all capsular layers in cases of capsule-splitting phenomena in which multiple layers of a split capsule may be raised (Jacobs et al., 2006).

Adequate hydrodissection allows unimpeded rotation of the nucleus and facilitates cortex removal (Vasavada et al., 2002). The procedure has to be performed gently as an aggressive injection of fluid may lead to further downward stress and zonular weakness. Alternatively, the entire nucleus should be hydrodissected and luxated anteriorly for supracapsular phacoemulsification (Drolsum et al., 2007). The choice of IOL does not differ much between eyes with PXF and eyes without PXF. So, none of the common IOL materials seem to be superior to the others (Wagoner et al., 2003). Plate-haptic PC IOLs, accommodating IOLs, multifocal IOLs and aspheric IOLs are associated with a higher risk of subluxation or phimosis. Although most foldable PC IOLs are reasonable options in eyes with PXF, the slower unfolding acrylic PC IOLs may provide additional control and minimize zonule stress during insertion (Shingleton et al., 2009). Acrylic IOLs also seem to cause less anterior capsular opacification than silicone ones (Werner et al., 2000).

Despite the advances in phacoemulsification power modulation and fluidics, PXF eyes continue to have an increased risk of capsule injury particularly from the phacoemulsification tip and instruments. Signs of capsular bag collapse include infolding of the peripheral posterior capsule, collapse of the capsule equator or visualization of the capsule fornix (Belovay et al., 2010). Working in the safe central zone of the anterior chamber is proposed. Adequate hydrodissection as well as the use of viscodissection to separate cortex from the capsule facilitate cortex removal (Shingleton et al., 2009).

3.4 Postoperative considerations

After surgery frequent follow-up examinations are important as early and late postoperative complications may occur more frequently in eyes with PXF material. In the early period after cataract surgery the main complications include inflammation, keratopathy and IOP spikes while in the long term posterior capsule opacification, anterior capsule contraction (phimosis) and IOL decentration.

Inflammation On the basis of blood-aqueous barrier dysfunction intense and/or prolonged postoperative inflammation, increased aqueous flare, fibrinoid reaction, posterior synechiae, IOL deposits, anterior capsule contraction and macular edema are more frequent in eyes with PXF. However, advances in phacoemulsification have reduced dramatically the risk of an inflammatory response. PXF eyes with glaucoma have been reported to have increased risk for macular edema after phacoemulsification (Yüksel et al., 2008). Iris trauma, which is more common in PXF eyes, has been associated with higher rates of macular edema too (Gulkilik et al., 2006).

Intraocular pressure The presence of trabecular outflow and blood-aqueous barrier alterations results in an increased risk of early postoperative IOP elevation, particularly in patients with preexisting glaucoma (Pohjalainen et al., 2001; Shingleton et al., 2008). Postoperative IOP spikes should be prevented through careful aspiration of viscoelastic material at the end of the surgery procedure, and meticulous monitor IOP, and use prophylactic ocular hypotensive agents, at least in high-risk patients.

Several studies demonstrate a reduction of IOP in glaucomatous eyes after cataract surgery with IOL implantation (Handa et al., 1987; Shingleton et al., 1999). It has been reported that the IOP reduction is even greater in PXF eyes and it may be explained by a greater outflow improvement, as previously deposited PXF material is expeditiously cleared by the high flow states during phacoemulsification and irrigation/aspiration (Shingleton et al., 2003). Eyes with higher preoperative IOP and/or narrow angles tend to have greater IOP reduction after cataract surgery (Issa et al., 2005; Poley et al., 2008). However, these conclusions have been argued by another study that found no difference in IOP reduction after cataract surgery between non-glaucomatous eyes with and without PXF (Pohjalainen et al., 2001).

Keratopathy The endothelial cell count is reduced and mean endothelial cell area enlarged in exfoliative eyes, predisposing some of them to develop early corneal endothelial decompensation even with only moderate rises in IOP or after cataract surgery (Naumann & Schlötzer-Schrehardt, 2000). PXF is reported to have a negative influence on endothelial cell loss during cataract surgery (Kaljurand & Teesalu, 2007). Working in a safe distance from the cornea and adequate viscoelastic can help to protect the endothelial cells during surgical maneuvers.

Late intraocular lens problems Secondary cataract has been found increased significantly in PXF eyes than in controls (Küchle et al., 1997). This increase may be related to a persistent breakdown in the blood-aqueous barrier, hypoxia of the anterior chamber, cortical remnants and a compromised capsule-zonular complex leading to posterior capsular folds with subsequent facilitated migration of lens epithelial cells (Drolsum et al., 2007). Now that phacoemulsification is a standard procedure and IOL material is improved, postoperative posterior capsule opacification, corneal decompensation and inflammation, even in PXF eyes, are rare.

Even with uneventful phacoemulsification late in-the-bag IOL tilt or dislocation may occur many years postoperatively. Age, capsule contraction/phimosis, instability of the blood-aqueous barrier, surgical trauma to the zonules or postoperative trauma and progressive zonular disintegration have been proposed to contribute to the process (Gimbel et al., 2005; Gross et al., 2004; Jehan et al., 2001; Kato et al., 2002). PXF syndrome has been reported in >50% of all late in-the-bag IOL dislocations (Breyer et al., 1999). The mean time of the late subluxation of the IOL-capsular bag complex was 8+ years (range 9 months to 17 years) (Jehan et al., 2001). If the IOL optic remains in the pupillary area any intervention can be postponed. However, it is usually preferable to intervene surgically as long as an anterior approach is still possible. The options are to either reposition or exchange the IOL. We can reposition and suture the IOL to the sclera or to the iris. Otherwise, we have to exchange the IOL with an angle-supported anterior chamber (AC) IOL (Drolsum et al., 2007). If a dislocation far posteriorly of the IOL-capsule complex occurs, a vitreoretinal approach should be combined.

Anterior capsule contraction/phimosis can lead to postoperative IOL subluxation and dislocation (Hayashi et al., 1998). Age, blood-aqueous disorder, PXF material, retained cortex, IOL material, zonular weakness and a small CCC can lead to increased capsular shrinkage (Gimbel et al., 2005; Kato et al., 2002; Kimura et al., 1998; Werner et al., 2000). A neodymium: YAG laser radial anterior capsulotomy or a surgical release of the centripetal traction of the anterior capsule and zonules should be performed to treat phimosis.

We studied retrospectively nine patients (ten eyes) with PXF syndrome and late spontaneous dislocation of the bag-IOL complex. All patients had undergone uncomplicated cataract extraction with posterior chamber IOL implantation 4 to 17 years ago (mean 8.5) by the same surgeon (SPG). In one patient IOL dislocation occurred in both eyes approximately four months apart. Five surgeries had been performed by the extracapsular cataract extraction while in five cases a standardized surgical technique for phacoemulsification had been used. A CCC measuring approximately 5.0 to 5.5 mm in diameter had been made using forceps. In all cases surgical management included dislocated IOL removal and anterior chamber IOL implantation. Five cases underwent 3-port pars plana vitrectomy and five underwent anterior vitrectomy. Of the ten explanted IOLs, two were found to be one-piece polymethylmethacrylate (PMMA) posterior IOLs, one a three-piece PMMA IOL with polypropylene haptics, four were three-piece acrylic IOLs, two three-piece acrylic IOLs and one a silicone lens; the IOLs' overall length was 13.0 mm. The explanted IOLs underwent microscopic examination and were found to be intact, encased in the capsular bag. In six eyes visual acuity improved, in three eyes remained stable, and in one eye was found to be deteriorated after 24 months of follow-up, due to the development of age related macular disease. In our series, we observed that in five cases where an anterior CCC had been

performed, a circumferential anterior capsular overlap of the optic edge was found to be at least for 1 mm wide of the 6.0 mm optic zone of the dislocated IOL. Conversely, in cases where a can-opener capsulotomy had been made, the edge of the anterior capsule remnant was localized outside the edge of the optic part of the IOL. When comparing the cases of capsulorhexis to the cases of capsulotomy with regard to the interval between cataract surgery and IOL dislocation, we observed that in four cases of can-opener capsulotomy dislocation occurred much later (10-17 years) than in the cases of CCC (4-7 years). The earlier (4 years) IOL dislocation in an eye with a can-opener capsulotomy may be attributed to the co-existence of retinitis pigmentosa and PXF in the same patient that may accumulatively have contributed to zonular instability. In the can-opener capsulotomy patients both loops of the one-piece PMMA lenses may suggest that the retentive memory of the haptics provide stronger resistance to capsule contraction. The long-term dislocation in patients with one-piece PMMA IOLs could demonstrate that this type of IOL may also function as a capsular tension ring that stabilizes the capsular bag via a centrifugal tension on the capsular fornices.

The aforementioned considerations related to cataract surgery in PXF eyes are summarized in Table 1.

Intraoperative	Postoperative
Corneal endotheliopathy	Fibrinoid reaction
Small pupil	Aqueous flare
Zonule weakness	Posterior synechiae
Anterior chamber depth disorders	IOL deposits
Posterior capsule dehiscence	Macular edema
Vitreous prolapse	Postoperative pressure spikes
	Corneal edema
	Anterior capsule contraction (phimosis)
	Secondary cataract
	IOL subluxation/dislocation

Table 1. Intraoperative and postoperative considerations in cataract surgery in PXF eyes.

4. Conclusion

PXF syndrome may cause a spectrum of serious ocular and surgical complications. The problems related to cataract surgery are mainly initiated by zonular instability and, to some degree, by insufficient pupillary dilation. Awareness of the structural and functional features of this disorder may help avoid or minimize most of them. The early recognition of the syndrome in addition to advanced phacoemulsification techniques and associated surgical devices have increased the percentage of operative success. Through careful consideration with preoperative preparation, surgical awareness and postoperative follow up favorable outcomes can be achieved in cataract surgery.

5. References

- Ahmed, I.I.K., Chen, S.H., Kranemann, C., & Wong, D.T. (2005a). Surgical repositioning of dislocated capsular tension rings. *Ophthalmology*, Vol.112, No.10, (October 2005), pp. 1725-1733.
- Ahmed, I.I.K., Cionni, R.J., Kranemann, C., & Crandall, A.S. (2005b). Optimal timing of capsular tension ring implantation: Miyake-Apple video analysis. *Journal of Cataract & Refractive Surgery*, Vol.31, No.9, (September 2005), pp.1809-1813.
- Akinci, A., Batman, C., & Zilelioglu, O. (2008). Phacoemulsification in pseudoexfoliation syndrome. *Ophthalmologica*, Vol.222, No.2, (February 2008), pp. 112-116.
- Akman, A., Yilmaz, G., Oto, S., & Akova, Y.A. (2004). Comparison of various pupil dilatation methods for phacoemulsification in eyes with a small pupil secondary to pseudoexfoliation. *Ophthalmology*, Vol.111, No.9, (September 2004), pp. 1693-1698.
- Andrikopoulos, G.K., Mela, E.K., Georgakopoulos, C.D., Papadopoulos, G.E., Damelou, A.N., Alexopoulos, D.K., & Gartaganis, S.P. (2009). Pseudoexfoliation syndrome prevalence in Greek patients with cataract and its association to glaucoma and coronary artery disease. *Eye*, Vol.23, No.2, (February 2009), pp. 442-447.
- Andrikopoulos, G.K. (2009). *Pseudoexfoliation and coronary artery disease* [dissertation (in Greek)], University of Patras, Patras, Greece.
- Asano, N., Schlötzer-Schrehardt, U.M., & Naumann, G.O.H. (1995). A histopathologic study of iris changes in pseudoexfoliation syndrome. *Ophthalmology*, Vol.102, No.9, (September 1995), pp. 1279-1290.
- Bayraktar, S., Altan, T., Küçüksümer, Y., & Yılmaz, Ö.F. (2001). Capsular tension ring implantation after capsulorhexis in phacoemulsification of cataracts associated with pseudoexfoliation syndrome : intraoperative complications and early postoperative findings. *Journal of Cataract & Refractive Surgery*, Vol.27, No.10, (October 2001), pp. 1620-1628.
- Belovay, G.W., Varma, D.K., & Ahmed, I.I.K. (2010). Cataract surgery in pseudoexfoliation syndrome. *Current Opinion in Ophthalmology*, Vol.21, No.1, (January 2010), pp. 25-34.
- Breyer, D.R., Hermeking, H., & Gerke, E. (1999). Late dislocation of the capsular bag after phacoemulsification with endocapsular IOL in pseudoexfoliation syndrome. *Ophthalmology*, Vol.96, No.4, (April 1999), pp. 248-251.
- Chang, D.F., Braga-Mele, R., Mamalis, N., Masket, S., Miller, K.M., Nichamin, L.D., Packard, R.B., & Packer, M. (2008). ASCRS White Paper: Clinical review of intraoperative floppy-iris syndrome. *Journal of Cataract & Refractive Surgery*, Vol.34, No.12, (December 2008), pp. 2153-2162.
- Cionni, R.J., & Osher, R.H. (1998). Management of profound zonular dialysis or weakness with a new endocapsular ring designed for scleral fixation. *Journal of Cataract & Refractive Surgery*, Vol.24, No.10, (October 1998), pp. 1299-1306.
- Dick, H.B., & Augustin, A.J. (2001). Lens implant selection with absence of capsular support. *Current Opinion in Ophthalmology*, Vol.12, No.1, (February 2001), pp. 47-57.
- Dickson, D.H., & Ramsay, M.S. (1975). Fibrilloglucosaminopathy (pseudoexfoliation): a clinical and electron microscope study. *Canadian Journal of Ophthalmology*, Vol.10, No.2, (April 1975), pp. 148-161.

- Dosso, A.A., Bonvin, E.R., & Leuenberger, P.M. (1997). Exfoliation syndrome and phacoemulsification. *Journal of Cataract & Refractive Surgery*, Vol.23, No. 1, (January - February 1997), pp. 122-125.
- Drolsum, L., Haaskjold, E., & Davanger, M. (1993). Results and complications after extracapsular cataract extraction in eyes with pseudoexfoliation syndrome. *Acta Ophthalmologica*, Vol.71, No.6, (December 1993), pp. 771-776.
- Drolsum, L. (2003). Longterm follow-up of secondary flexible, open-loop, anterior chamber intraocular lenses. *Journal of Cataract & Refractive Surgery*, Vol.29, No.3, (March 2003), pp. 498-503.
- Drolsum, L., Ringvold, A., & Nicolaisen, B. (2007). Cataract and glaucoma surgery in pseudoexfoliation syndrome: a review. *Acta Ophthalmologica Scandinavica*, Vol.85, No.8, (December 2007), pp. 810-821.
- Eagle Jr., R.C., Font, R.L., & Fine, B.S. (1979). The basement membrane exfoliation syndrome. *Archives of Ophthalmology*, Vol.97, No.3, (March 1979), pp. 510-515.
- Fitzsimmons, T.D., Fagerholm, P., & Wallin, O. (1997). Hyaluronan in the exfoliation syndrome. *Acta Ophthalmologica Scandinavica*, Vol.75, No.3, (June 1997), pp. 257-260.
- Forsius, H. (1988). Exfoliation syndrome in various ethnic populations. *Acta Ophthalmologica*, Vol.66 (Suppl 184), (March 1988), pp. 71-85.
- Garner, A., & Alexander, R.A. (1984). Pseudoexfoliative disease: histochemical evidence of an affinity with zonular fibres. *British Journal of Ophthalmology*, Vol.68, No.8, (August 1984), pp. 574-580.
- Gartaganis, S.P., Georgakopoulos, C.D., Exarchou, A.M., Mela, E.K., Lamari, F., & Karamanos, N.K. (2001). Increased aqueous humor basic fibroblast growth factor and hyaluronan levels in relation to the exfoliation syndrome and exfoliative glaucoma. *Acta Ophthalmologica Scandinavica*, Vol.79, No.6, (December 2001), pp. 572-575.
- Gartaganis, S.P., Georgakopoulos, C.D., Mela, E.K., Exarchou, A., Ziouti, N., Assouti, M., & Vynios, D.H. (2002). Matrix metalloproteinases and their inhibitors in exfoliation syndrome. *Ophthalmic Research*, Vol.34, No.3, (May-June 2002), pp. 165-171.
- Gartaganis, S.P., Georgakopoulos, C.D., Patsoukis, N.E., Gotsis, S.S., Gartaganis, V.S., & Georgiou, C.D. (2005). Glutathione and lipid peroxide changes in pseudoexfoliation syndrome. *Current Eye Research*, Vol.30, No.8, (January 2005), pp. 647-651.
- Gartaganis, S.P., Patsoukis, N.E., Nikolopoulos, D.K., & Georgiou, C.D. (2007). Evidence for oxidative stress in lens epithelial cells in pseudoexfoliation syndrome. *Eye*, Vol.21, No.11, (November 2007), pp. 1406-1411.
- Gimbel, H.V., Condon, G.P., Kohnen, T., Olson, R.J., & Halkiadakis, I. (2005). Late in-the-bag intraocular lens dislocation: incidence, prevention, and management. *Journal of Cataract & Refractive Surgery*, Vol.31, No.11, (November 2005), pp. 2193-2204.
- Gross, J.G., Kokame, G.T., & Weinberg, D.V. (2004). In-the-bag intraocular lens dislocation. *American Journal of Ophthalmology*, Vol.137, No.4, (April 2004), pp. 630-635.
- Gulkilik, G., Kocabora, S., Taskapili, M., & Engin, G. (2006). Cystoid macular edema after phacoemulsification: risk factors and effect on visual acuity. *Canadian Journal of Ophthalmology*, Vol.41, No.6, (December 2006), pp. 699-703.

- Handa, J., Henry, J.C., Krupin, T., & Keates, E. (1987). Extracapsular cataract extraction with posterior chamber lens implantation in patients with glaucoma. *Archives of Ophthalmology*, Vol.105, No.6, (June 1987), pp. 765-769.
- Harnisch, J.P., Barrach, H.J., Hassell, J.R., & Sinha, P.K. (1981). Identification of a basement membrane proteoglycan in exfoliation material. *Graefe's Archives for Clinical and Experimental Ophthalmology*, Vol.215, No.4, (January 1981), pp. 273-278.
- Hasanee, K., & Ahmed, I.I.K. (2006). Capsular tension rings: update on endocapsular support devices. *Ophthalmology Clinics of North America*, Vol.19, No.4, (December 2006), pp. 507-519.
- Hasanee, K., Butler, M., & Ahmed, I.I.K. (2006). Capsular tension rings and related devices: current concepts. *Current Opinion in Ophthalmology*, Vol.17, No.1, (February 2006), pp. 31-41.
- Hayashi, H., Hayashi, K., Nakao, F., & Hayashi, F. (1998). Anterior capsule contraction and intraocular lens dislocation in eyes with pseudoexfoliation syndrome. *British Journal of Ophthalmology*, Vol.82, No.12, (December 1998), pp. 1429-1432.
- Herbst, R.W. (1976). Angle closure glaucoma in a patient with pseudoexfoliation of the lens capsule. *Annals of Ophthalmology*, Vol.8, No.7, (July 1976), pp. 853-856.
- Hietanen, J., Kivela, T., Vesti, E., & Tarkkanen, A. (1992). Exfoliation syndrome in patients scheduled for cataract surgery. *Acta Ophthalmologica (Copenh)*, Vol.70, No.4, (August 1992), pp. 440-446.
- Hyams, M., Mathalone, N., Herskovitz, M., Hod, Y., Israeli, D., & Geyer, O. (2005). Intraoperative complications of phacoemulsification in eyes with and without pseudoexfoliation. *Journal of Cataract & Refractive Surgery*, Vol.31, (May 2005), pp. 1002-1005.
- Issa, S.A., Pacheco, J., Mahmood, U., Nolan, J., & Beatty, S. (2005). A novel index for predicting intraocular pressure reduction following cataract surgery. *British Journal of Ophthalmology*, Vol.89, No.5, (May 2005), pp. 543-546.
- Jacobs, D.S., Cox, T.A., Wagoner, M.D., Ariyasu, R.G., & Karp, C.L. (2006). Capsule staining as an adjunct to cataract surgery; a report from the American Academy of Ophthalmology (Ophthalmic Technology Assessment). *Ophthalmology*, Vol.113, No.4, (April 2006), pp. 703-713.
- Jehan, F.S., Mamalis, N., & Crandall, A.S. (2001). Spontaneous late dislocation of intraocular lens within the capsular bag in pseudoexfoliation patients. *Ophthalmology*, Vol.108, No.10, (October 2001), pp. 1727-1731.
- Kaljurand, K., & Teesalu, P. (2007). Exfoliation syndrome as a risk factor for corneal endothelial cell loss in cataract surgery. *Annals of Ophthalmology*, Vol.39, No.4, (December 2007), pp. 327-333.
- Kato, S., Suzuki, T., Hayashi, Y., Numaga, J., Hattori, T., Yuguchi, T., Kaiya, T., & Oshika, T. (2002). Risk factors for contraction of the anterior capsule opening after cataract surgery. *Journal of Cataract & Refractive Surgery*, Vol.28, No.1, (January 2002), pp. 109-112.
- Keates, R.H., & McGowan, K.A. (1984). The effect of topical indomethacin ophthalmic solution in maintaining mydriasis during cataract surgery. *Annals of Ophthalmology*, Vol.16, No.12, (December 1984), pp. 1116-1121.

- Kimura, W., Yamanishi, S., Kimura, T., Sawada, T., & Ohte, A. (1998). Measuring the anterior capsule opening after cataract surgery to assess capsule shrinkage. *Journal of Cataract & Refractive Surgery*, Vol.24, No.9, (September 1998), pp. 1235-1238.
- Koliakos, G.G., Konstas, A.G.P., Schlötzer-Schrehardt, U., Hollo, G., Katsimbris, I.E., Georgiadis, N., & Ritch, R. (2003). 8-Isoprostaglandin F2a and ascorbic acid concentration in the aqueous humour of patients with exfoliation syndrome. *British Journal of Ophthalmology*, Vol.87, No.3, (March 2003), pp. 353-356.
- Konstas, A.G., Marshall, G.E., & Lee, W.R. (1990). Immunogold localisation of laminin in normal and exfoliative iris. *British Journal of Ophthalmology*, Vol.74, No.8, (August 1990), pp. 450-457.
- Kubota, T., Khalil, A., Tawara, A., Zhang, X., & Inomata, H. (1998). Double staining of proteoglycans and the HNK-1 carbohydrate epitope in pseudoexfoliation material. *Current Eye Research*, Vol.17, No.1, (January 1998), pp. 60-64.
- Küchle, M., Amberg, A., Martus, P., Nguyen, N.X., & Naumann, G.O.H. (1997). Pseudoexfoliation syndrome and secondary cataract. *British Journal of Ophthalmology*, Vol.81, No.10, (October 1997), pp.862-866.
- Küchle, M., Viestenz, A., Martus, P., Handel, A., Junemann, A., & Naumann, G.O.H. (2000). Anterior chamber depth and complications during cataract surgery in eyes with pseudoexfoliation syndrome. *American Journal of Ophthalmology*, Vol.129, No.3, (March 2000), pp. 281-285.
- Lee, V., & Bloom, P. (1999). Microhook capsule stabilization for phacoemulsification in eyes with pseudoexfoliation-syndrome-induced lens instability. *Journal of Cataract & Refractive Surgery*, Vol.25, No.12, (December 1999), pp. 1567-1570.
- Lee, D.-H., Shin, S.-C., & Joo, C.-K. (2002). Effect of a capsular tension ring on intraocular lens decentration and tilting after cataract surgery. *Journal of Cataract & Refractive Surgery*, Vol.28, No.5, (May 2002), pp. 843-846.
- Menapace, R., Findl, O., Georgopoulos, M., Rainer, G., Vass, C., & Schmetterer, K. (2000). The capsular tension ring: designs, applications, and techniques. *Journal of Cataract & Refractive Surgery*, Vol.26, No.6, (June 2000), pp. 898-912.
- Moreno, J., Duch, S., & Lajara, J. (1993). Pseudoexfoliation syndrome: clinical factors related to capsular rupture in cataract surgery. *Acta Ophthalmologica*, Vol.71, No.2, (April 1993), pp. 181-184.
- Naumann, G.O.H., & Schlötzer-Schrehardt, U. (2000). Keratopathy in pseudoexfoliation syndrome as a cause of corneal endothelial decompensation. A clinicopathologic study. *Ophthalmology*, Vol.107, No.6, (June 2000), pp. 1111-1124.
- Netland, P.A., Ye, H., Streeten, B.W., & Hernandez, M.R. (1995). Elastosis of the lamina cribrosa in pseudoexfoliation syndrome with glaucoma. *Ophthalmology*, Vol.102, No.6, (June 1995), pp. 878-886.
- Pohjalainen, T., Vesti, E., Uusitalo, R.J., & Laatikainen, L. (2001). Intraocular pressure after phacoemulsification and intraocular lens implantation in nonglaucomatous eyes with and without exfoliation. *Journal of Cataract & Refractive Surgery*, Vol.27, No.3, (March 2001), pp. 426-431.
- Poley, B.J., Lindstrom, R.L., & Samuelson, T.W. (2008). Long-term effects of phacoemulsification with intraocular lens implantation in normotensive and ocular

- hypertensive eyes. *Journal of Cataract & Refractive Surgery*, Vol.34, No.5, (May 2008), pp. 735-742.
- Puska, P. (1994). Lens opacity in unilateral exfoliation syndrome with or without glaucoma. *Acta Ophthalmologica*, Vol.72, No.3, (June 1994), pp. 290-296
- Repo, L.P., Suhonen, M.T., Terasvirta, M.E., & Koivisto, K.J. (1995). Color Doppler imaging of the ophthalmic artery blood flow spectra of patients who have had a transient ischemic attack: Correlations with generalized iris translucence and pseudoexfoliation syndrome. *Ophthalmology*, Vol.102, No.8, (August 1995), pp. 1199-1205.
- Ringvold, A., & Vegge, T. (1971). Electron microscopy of the trabecular meshwork in eyes with exfoliation syndrome (pseudoexfoliation of the lens capsule). *Virchows Archiv Abteilung A Pathologische Anatomie*, Vol.353, No.2, (June 1971), pp. 110-127.
- Ringvold, A. (1999). Epidemiology of the pseudoexfoliation syndrome. A review. *Acta Ophthalmologica Scandinavica*, Vol.77, No.4, (August 1999), pp. 371-375.
- Ritch, R. (1994a). Exfoliation syndrome – the most common identifiable cause of open-angle glaucoma. *Journal of Glaucoma*, Vol.3, No.2, (Summer 1994), pp. 176-178
- Ritch, R. (1994b). Exfoliation syndrome and occludable angles. *Transactions of the American Ophthalmological Society*, Vol.92, pp. 845-944.
- Ritch, R., & Schlötzer-Schrehardt, U. (2001). Exfoliation syndrome. *Survey of Ophthalmology*, Vol.45, No.4, (January 2001), pp. 265-315.
- Santoro, S., Sannace, C., Cascella, M.C., & Lavermicocca, N. (2003). Subluxated lens: phacoemulsification with iris hooks. *Journal of Cataract & Refractive Surgery*, Vol.29, No.12, (December 2003), pp. 2269-2273.
- Schlötzer-Schrehardt, U.M., Koca, M.R., Naumann, G.O.H., & Volkholz, H. (1992a). Pseudoexfoliation syndrome. Ocular manifestation of a systemic disorder? *Archives of Ophthalmology*, Vol.110, No.12, (December 1992), pp. 1752-1756.
- Schlötzer-Schrehardt, U., Dorfler, S., & Naumann, G.O.H. (1992b). Immunohistochemical localization of basement membrane components in pseudoexfoliation material of the lens capsule. *Current Eye Research*, Vol.11, No.4, (April 1992), pp. 343-355.
- Schlötzer-Schrehardt, U.M., & Naumann, G.O. (1994). A histopathologic study of zonular instability in pseudoexfoliation syndrome. *American Journal of Ophthalmology*, Vol.118, No.6, (December 1994), pp. 730-743.
- Schlötzer-Schrehardt, U.M., & Naumann, G.O.H. (1995). Trabecular meshwork in pseudoexfoliation syndrome with and without open-angle glaucoma. A morphometric, ultrastructural study. *Investigative Ophthalmology and Visual Science*, Vol.36, No.9, (August 1995), pp. 1750-1764.
- Schlötzer-Schrehardt, U.M., & Naumann, G.O.H. (2006). Ocular and systemic pseudoexfoliation syndrome. *American Journal of Ophthalmology*, Vol.141, No. 5 (May 2006), pp. 921-937.
- Schlötzer-Schrehardt, U. (2009). Molecular pathology of pseudoexfoliation syndrome/ glaucoma – New insights from LOXL1 gene associations. *Experimental Eye Research*, Vol.88, No.4, (April 2009), pp. 776-785.
- Shingleton, B.J., Gamell, L.S., O'Donoghue, M.W., Baylus, S.L., & King, R. (1999). Long-term changes in intraocular pressure after clear corneal phacoemulsification: normal

- patients versus glaucoma suspect and glaucoma patients. *Journal of Cataract & Refractive Surgery*, Vol.25, No.7, (July 1999), pp. 885–890.
- Shingleton, B.J., Heltzer, J., & O'Donoghue, M.W. (2003). Outcomes of phacoemulsification in patients with and without pseudoexfoliation syndrome. *Journal of Cataract & Refractive Surgery*, Vol.29, No.6, (June 2003), pp. 1080–1086.
- Shingleton, B.J., Laul, A., Nagao, K., Wolff, B., O'Donoghue, M., Eagan, E., Flattem, N., & Desai-Bartoli, S. (2008). Effect of phacoemulsification on intraocular pressure in eyes with pseudoexfoliation: single-surgeon series. *Journal of Cataract & Refractive Surgery*, Vol.34, No.11, (November 2008), pp. 1834–1841.
- Shingleton, B.J., Crandall, A.S., & Ahmed, I.I.K. (2009). Pseudoexfoliation and the cataract surgeon: Preoperative, intraoperative, and postoperative issues related to intraocular pressure, cataract, and intraocular lenses. *Journal of Cataract & Refractive Surgery*, Vol.35, No.6, (June 2009), pp. 1101–1120.
- Streeten, B.W., Gibson, S.A., & Dark, A.J. (1986). Pseudoexfoliative material contains an elastic microfibrillar-associated glycoprotein. *Transactions of the American Ophthalmological Society*, Vol.84, pp. 304–317.
- Streeten, B.W., Li, Z.Y., Wallace, R.N., Eagle, R.C., & Keshgegian, A.A. (1992). Pseudoexfoliative fibrilopathy in visceral organs of a patient with pseudoexfoliation syndrome. *Archives of Ophthalmology*, Vol.110, No.12, (December 1992), pp. 1757–1762.
- Tanhehco, T., & Chen, S.H. (2010). Pseudoexfoliation syndrome and cataract surgery. *International Ophthalmology Clinics*, Vol.50, No.1, (Winter 2010), pp. 81–93.
- Tawara, A., Fujisawa, K., Kiyosawa, R., & Inomata, H. (1996). Distribution and characterization of proteoglycans associated with exfoliation material. *Current Eye Research*, Vol.15, No.11, (November 1996), pp. 1101–1111.
- Thorleifsson, G., Magnusson, K.P., Sulem, P., Walters, G.B., Gudbjartsson, D.F., Stefansson, H., Jonsson, T., Jonasdottir, A., Jonasdottir, A., Stefansdottir, G., Masson, G., Hardarson, G.A., Petursson, H., Arnarsson, A., Motallebipour, M., Wallerman, O., Wadelius, C., Gulcher, J.R., Thorsteinsdottir, U., Kong, A., Jonasson, F., & Stefansson, K. (2007). Common sequence variants in the LOXL1 gene confer susceptibility to exfoliation glaucoma. *Science*, Vol.317, No.5843, (September 2007), pp. 1397–1400.
- Vasavada, A.R., Singh, R., Apple, D.J., Trivedi, R.H., Pandey, S.K., & Werner, L. (2002). Effect of hydrodissection on intraoperative performance: randomized study. *Journal of Cataract & Refractive Surgery*, Vol.28, No.9, (September 2002), pp. 1623–1628.
- Vesti, E., & Kivelä, T. (2000). Exfoliation syndrome and exfoliation glaucoma. *Progress in Retinal and Eye Research*, Vol.19, No.3, (May 2000), pp. 345–368.
- Wagoner, M.D., Cox, T.A., Ariyasu, R.G., Jacobs, D.S., & Karp, C.L. (2003). Intraocular lens implantation in the absence of capsular support; a report by the American Academy of Ophthalmology. *Ophthalmology*, Vol.110, No.4, (April 2003), pp. 840–859.
- Werner, L., Pandey, S.K., Escobar-Gomez, M., Visessook, N., Peng, Q., & Apple, D.J. (2000). Anterior capsule opacification: a histopathological study comparing different IOL styles. *Ophthalmology*, Vol.107, No.3, (March 2000), pp. 463–471.

Yüksel, N., Doğu, B., Karabaş, V.L., & Çağlar, Y. (2008). Foveal thickness after phacoemulsification in patients with pseudoexfoliation syndrome, pseudoexfoliation glaucoma, or primary open-angle glaucoma. *Journal of Cataract & Refractive Surgery*, Vol.34, No.11, (November 2008), pp. 1953–1957.

IntechOpen

IntechOpen