

# We are IntechOpen, the world's leading publisher of Open Access books Built by scientists, for scientists

4,800

Open access books available

122,000

International authors and editors

135M

Downloads

Our authors are among the

154

Countries delivered to

TOP 1%

most cited scientists

12.2%

Contributors from top 500 universities



WEB OF SCIENCE™

Selection of our books indexed in the Book Citation Index  
in Web of Science™ Core Collection (BKCI)

Interested in publishing with us?  
Contact [book.department@intechopen.com](mailto:book.department@intechopen.com)

Numbers displayed above are based on latest data collected.  
For more information visit [www.intechopen.com](http://www.intechopen.com)



# Combined Cataract and Glaucoma Surgery

Atilla Bayer

*Gulhane Medical Academy, Medical School  
Turkey*

## 1. Introduction

The association of cataract with glaucoma has become more frequent because of aging populations and the increased risk of cataract development in the patient with glaucoma. There is an increased risk of cataract in some forms of glaucoma, such as pseudoexfoliative glaucoma. In addition, glaucoma surgery increases the risk for the development of cataract (Hylton et al, 2003; AGIS investigators, 2001). With evolving techniques in both glaucoma and cataract surgery, the optimal management is ever changing in an effort to obtain a higher percentage of perfect results with fewer complications and shorter recovery times. It has been widely reported that modern cataract surgery results in a long-term reduction in intraocular pressure (IOP); however, the magnitude and clinical significance of this change continues to be debated. On the other hand, due to the growing armamentarium of medical antiglaucomatous therapy during the past decade, most of these patients are presenting for cataract surgery.

When a visually significant cataract is present and surgery is indicated, clinicians face several challenges. Some anatomical features such as a shallow anterior chamber and a shorter axial length may complicate cataract surgery in eyes with angle closure glaucoma. Conversely, how to successfully control the IOP while managing the cataract may complicate the decision making process in eyes with primary open angle glaucoma (POAG) (Table 1). Glaucoma surgery may be associated with an increased risk of cataract progression (AGIS investigators, 2001).

When glaucoma and cataract coexist, it is logical to think of a combined surgical procedure. This would help reduce surgical trauma and facilitate faster visual and functional recovery. Today's rapidly advancing phacoemulsification techniques, including small incisions and foldable lenses implanted in the bag, as well as the improvements in glaucoma techniques, facilitate safer and more efficient combined surgery. Combined surgery may avoid the occurrence of postoperative IOP spikes following cataract surgery in eyes with advanced glaucoma (Shingleton et al, 2007). In addition, subsequent cataract surgery may compromise the success of an earlier trabeculectomy (Seah et al, 1996).

Combined surgery for glaucoma and cataract is carried out in the presence of a cataract that disturbs function and either:

- a glaucomatous condition that fails to respond to maximally tolerated medical therapy;
- when there is appreciable visual field loss and optic disc damage independent of medical control; or
- when transient IOP elevations might cause further optic nerve damage.

<b>Trabeculectomy First; Cataract Extraction Later</b>	<b>Cataract Extraction First; Trabeculectomy Later if Needed</b>	<b>Combined Cataract and Glaucoma Surgery</b>
When large incision extracapsular cataract extraction is to be employed	Well controlled, mild glaucoma with additional medical options available	Advanced glaucoma
When marked inflammation is present	Ocular hypertension with additional medical options available	Patients on maximally tolerated medical therapy or intolerant to medications
When the risk of surgery is very high	Patients with shallow anterior chamber	Poor compliance to medications
		Low target intraocular pressure
		Patients with coincident glaucoma and cataract requiring two or more medications

Table 1. Options for Surgical Management of Coincident Cataract and Glaucoma

New surgical methods with the potential to significantly reduce IOP, such as ab-interno trabeculotomy and trabecular meshwork bypass stents have recently gained popularity (Godfrey et al, 2009). Many surgeons currently believe the collector system has a better chance to survive if intervention is undertaken earlier, before the distal collector system collapses or before years of topical drug therapy cause outflow scarring.

This chapter attempts to outline the current concepts in the management of cataract and glaucoma by evaluating the evidence in eyes with coincident cataract and glaucoma.

## 2. Physiopathologic factors: The glaucomatous eye

The glaucomatous eye for some of its characteristics is different from an eye without this pathologic condition. Factors related to glaucoma and other factors associated with its medical treatment are involved (Leske et al, 2002; Lichter et al, 2001; Collaborative Normal-Tension Glaucoma Study Group, 1998a; Collaborative Normal-Tension Glaucoma Study Group, 1998b; Kass et al, 2002). The Glaucoma Treatment Study showed, after 5 years of follow-up, twice the incidence of patients needed cataract surgery when medication was the initial treatment as in patients who underwent glaucoma surgery as the initial treatment (Lichter et al, 2001). The explanation for this finding is unknown. The process seemed to be related to the dynamics of the aqueous and the effect of hypotensive drugs (Lee & Gedde, 2004).

The corneal endothelium is more affected in patients with glaucoma, which explains their higher rate of corneal edema after cataract surgery (Tanihara et al, 1995). Patients with glaucoma have a tendency to have a poor response to pharmacologic pupil dilation and need additional surgical dilation to achieve correct visualization and to avoid the existing hidden cortex masses. Preoperative nonsteroidal anti-inflammatory medications (NSAIDs) in combination with mydriatics may improve intraoperative dilation (Stewart et al, 1999). Ophthalmic viscosurgical devices (OVDs) can be used to increase pupil size. Pupil

stretching maneuvers, or the use of iris hooks or rings for pupil dilation are recommended. Lens zonules may also become partially fragmented and disintegrated, especially in patients with pseudoexfoliation syndrome (PES). In advanced cases with PES, the zonular suspension of the lens is weakened to such an extent that phacodonesis occur. The zonular fibers may be separated from their attachments to the lens or ciliary body, causing inferior dislocation of the lens. Loosening of the zonules may induce anterior lens dislocation with an attack of secondary angle-closure glaucoma (ACG), especially with the patient in the prone position (Ritch, 1994). There are a number of methods that can be used to manage zonular weakness. A capsular tension ring (CTR), a circular polymethyl methacrylate (PMMA) device, can be inserted into the capsular bag to manage mild cases of zonular instability, defined as less than or equal to four clock hours of dialysis (Jacob et al, 2003). In cases with more severe zonular weakness, a modified capsular tension ring (mCTR) can be sutured to the sclera (Cionni et al, 2003). Lastly, iris hooks may be used to gently retract the anterior capsule during surgery. As the newer acrylic one-piece intraocular lenses (IOLs) unfold slower when inserted, there may be less trauma to the capsule and zonules. This may be an advantage of these IOLs over three-piece lenses. In glaucomatous eyes, we also see greater alteration of the blood aqueous barrier, indicating a greater incidence of postoperative inflammation.

### 3. Anesthesia

Combined cataract and glaucoma procedures are generally performed under retrobulbar, peribulbar, or sub-Tenon's anesthesia. Prior to the retrobulbar block, a combination of agents with short-acting sedative and amnesiac properties such as methohexital 20 to 30 mg, midazolam HCl 1mg, or alfentanil 250 $\mu$ g may be given intravenously to reduce anxiety and pain. The retrobulbar block consists of 2% xylocaine without epinephrine. During the procedure only light sedation or none will be required. The patient's systemic blood pressure must be controlled during the operation for many reasons, but primarily to reduce the risk of suprachoroidal hemorrhage.

In patients with markedly elevated IOP, preoperative administration of intravenous mannitol will minimize the abrupt change in IOP following the incision. Osmotic agents are preferred over aqueous suppressants because they dehydrate the vitreous, thereby reducing vitreous volume. Aqueous suppressants on the other hand, retard aqueous production during the early postoperative period.

### 4. Preoperative considerations

The preoperative clinical examination is extremely important. Lid position and orbital anatomy should be evaluated to consider superior tunnel incision versus temporal corneal selection. The conjunctiva should be examined carefully. Topical steroids should be administered if the conjunctiva is inflamed. Topical miotics should be discontinued 3 days before the surgery. Pupillary response to pharmacologic dilation should be recorded. If dilation is poor, the patient should be informed of the likely need for pupil stretch or iris manipulation, which may result in anisocoria or pupillary distortion. Patients should be informed preoperatively about the intense character of the postoperative period, which will require frequent visits and prolonged visual recovery, beyond that expected for standard cataract surgery. Finally, the eye should be carefully examined for the presence of pseudoexfoliative material, which can be associated with a more aggressive postoperative

inflammatory response, weakened zonular fibers, and poor pharmacologic pupil dilation (Küchle et al, 1996).

## 5. Intraocular lens choices for patients with glaucoma

Patients with glaucoma have unique functional and structural characteristics that should be considered prior to combined surgery. Decreased contrast sensitivity may be improved with aspheric IOLs; however, if these lenses decenter, they may induce more aberration than spherical IOLs. Patients with glaucoma may have smaller pupils and zonular weakness that may be managed intraoperatively by meticulous surgical technique as well as adjunctive devices including CTRs. In the setting of zonular/capsular instability, there are a number of surgical options to place an IOL in good position including anterior chamber IOLs, iris-sutured posterior chamber IOLs, sclera-sutured posterior chamber IOLs, and iris-claw IOLs, although some may exacerbate glaucoma and should be tailored to the individual patient. Posterior capsule opacification is a common postoperative problem and as it stands, surgical technique, IOL design and potentially IOL material may play a role in decreased incidence. Anterior chamber depth and axial length have been shown to change after glaucoma surgery and should be considered when calculating IOL power (Teichman & Ahmed., 2010). As both glaucoma and multifocal IOLs decrease contrast sensitivity, there has been much debate over whether multifocal IOL implantation into a glaucomatous eye is a reasonable practice (Ahmed & Teichman, 2008).

## 6. Antimetabolites

Adding pharmacologic adjuncts, such as 5-FU and mitomycin-C (MMC), to the combined procedure has become popular over the past decade. Both drugs act by inhibiting of proliferation of fibroblasts and probably also affect cell migration and extracellular matrix production. With rare exception, use of 5-FU with the procedure fails to demonstrate an advantage over the procedure when this antimetabolite is not used (Grady et al, 1993; Wong et al, 1994; Hurvitz, 1993).

The results with MMC, however, show a reduction in IOP despite appreciable variability in the way in which MMC is applied. Published studies report different MMC concentrations, durations of exposure and techniques of physical application to the eye (Munden & Alward, 1995; Lederer, 1996; Belyea et al, 1997; Carlson et al, 1997).

These data raise the question about whether MMC is required for eyes undergoing primary surgery or whether MMC should be reserved for eyes with failed filtering blebs, eyes that have had previous surgery or eyes with difficult-to-manage secondary glaucomas. As MMC is used so variably and both the short- and long-term consequences of its use in combined surgery are not clearly known, a prospective, randomized, multicentred study merits consideration.

A small piece can be cut from an edge of a triangular Weck-cel sponge using Mayo scissors and trimmed to 1 cm length. When wetted with an antimetabolite it expands to a thin porous layer that can be easily tucked beneath the conjunctiva on both sides and posteriorly (Fig. 1). Smooth forceps are used to hold the conjunctival edge away from the sponge during the contact period.

The choice of antimetabolite (if antimetabolite is to be used) and the duration of exposure are individualized, because there is no good evidence favoring any one technique either in

general or in specific patient situations. MMC is usually prepared as a solution containing 0.2 to 0.4 mg/ml and placed on the episclera for 2 to 5 minutes. The antimetabolite 5-FU is used in a concentration of 50 mg/ml and left in place for 3 to 5 minutes. Some surgeons apply antimetabolite under the scleral flap also. Contraindications for use of 5-FU and MMC are shown in Table 2.

Contraindications for Use of Antimetabolites
Corneal and conjunctival disorders
Lid function or position abnormalities
Pregnant or nursing women
Young children
Patient contemplating pregnancy

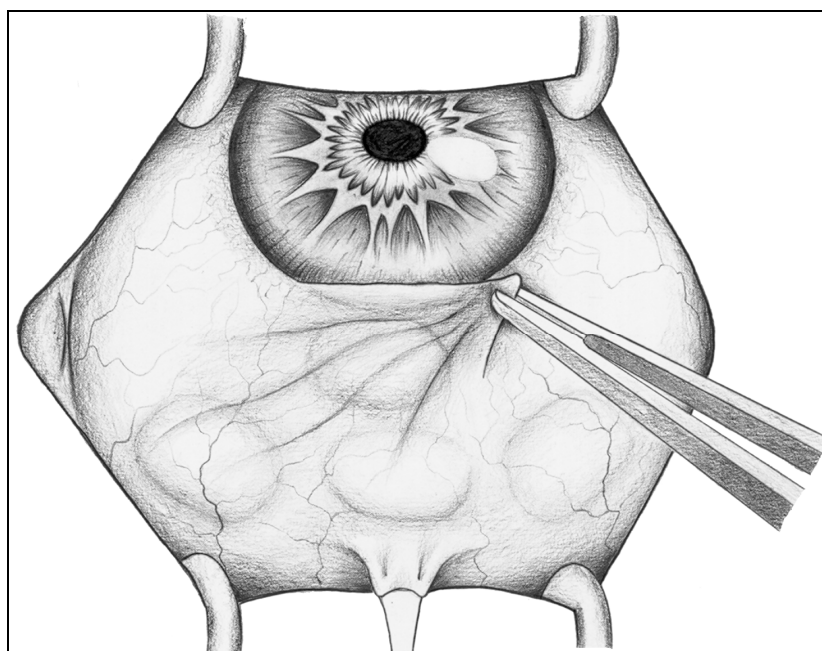


Fig. 1. Intraoperative application of 5-fluorouracil or mitomycin-C on sponge (From Bayer A ed. *Glokom Cerrahisi*, 1<sup>st</sup> edition. Ankara:MN Medikal & Nobel; with permission).

## 7. Pupil management

Glaucoma patients often present with pupils that do not dilate adequately for safe cataract surgery. Pupils may dilate poorly because:

- there are posterior synechiae;
- the iris sphincter is sclerotic;
- an inflammatory membrane involves the iris and anterior lens capsule;
- exfoliation syndrome is present with its consequent affect on the iris and lens capsule (Obstbaum, 2000).

We prefer manipulating the pupil to achieve a diameter of at least 5 mm before beginning cataract surgery. This may result in permanently dilated and poorly reactive pupil during the postoperative period. The basic principle in dealing with a pupil that dilates poorly is to remove the physical adhesions between the iris and lens, such as posterior synechiae or membranes. Synechiae are separated from the anterior lens capsule using a spatula.

Membranes can be peeled using fine forceps. Care is taken not to cause a traumatic iridodialysis. Injecting a high-viscosity viscoelastic agent aids in assessing the extent of pupil dilation (Obstbaum, 2000). If the amount of pupil dilation is not adequate, the pupil is stretched either using two instruments, such as Kuglen hooks (Dinsmore, 1996). The surgeon introduces one Kuglen iris hook through the tunnel incision or a paracentesis incision and a second Kuglen hook through a paracentesis incision. The inferior and superior pupillary borders near the 6 and 12 o'clock meridian engaged with the hooks that are oriented in opposite directions (Fig. 2). The surgeon slowly stretches the pupil by pushing each hook toward the anterior chamber angle. The same maneuver is repeated at the 3 and 9 o'clock meridians. After this maneuver, the anterior chamber is filled with additional viscoelastic material to further enlarge the pupil. Alternatively, a single instrument, such as the Beehler pupil dilator can be used (Fine & Hoffman, 1997). If this stretching does not result in adequate dilation, the surgeon may perform multiple 0.5 mm radial sphincterotomies using Vannas scissors (Fig. 3). Another option is to use iris retractors (Fig. 4) (Nichamin, 1993). Corneal stab incisions were made at the 1:00, 5:00, 7:00, and 11:00 positions to enlarge the pupil. The angle of the incisions adjacent to the phacoemulsification incision should be made parallel to the iris plane to minimize tenting of the peripheral iris toward the phacoemulsification hand piece entry site.

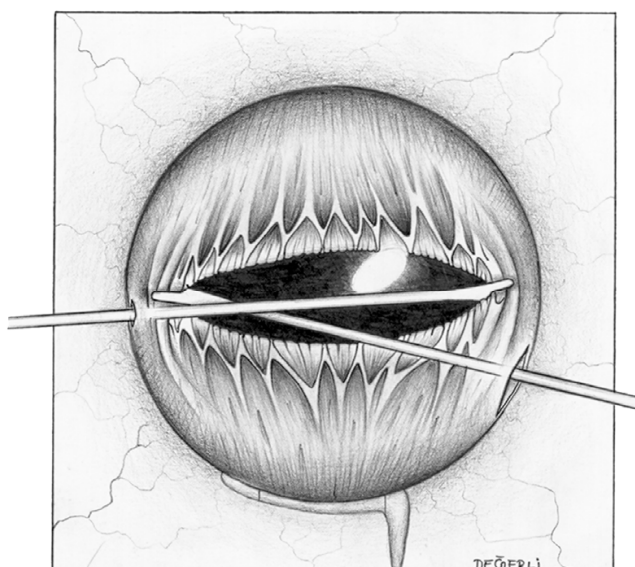


Fig. 2. Pupillary sphincter is stretched in the vertical and horizontal meridians using Kuglen hook (From Bayer A ed. *Glokom Cerrahisi*, 1<sup>st</sup> edition. Ankara:MN Medikal & Nobel; with permission).

## 8. Surgical techniques

Many techniques have been proposed to solve the conflicting problem of a watertight cataract incision and a patent filtering glaucoma procedure. The current combined surgical techniques for cataract and glaucoma include:

- phacoemulsification and trabeculectomy (phacotrabeulectomy);
- extracapsular cataract extraction and trabeculectomy;
- phacoemulsification and trabeculotomy;

- phacoemulsification and non-penetrating surgery;
- phacoemulsification and endocyclophotocoagulation;
- phacoemulsification and canaloplasty

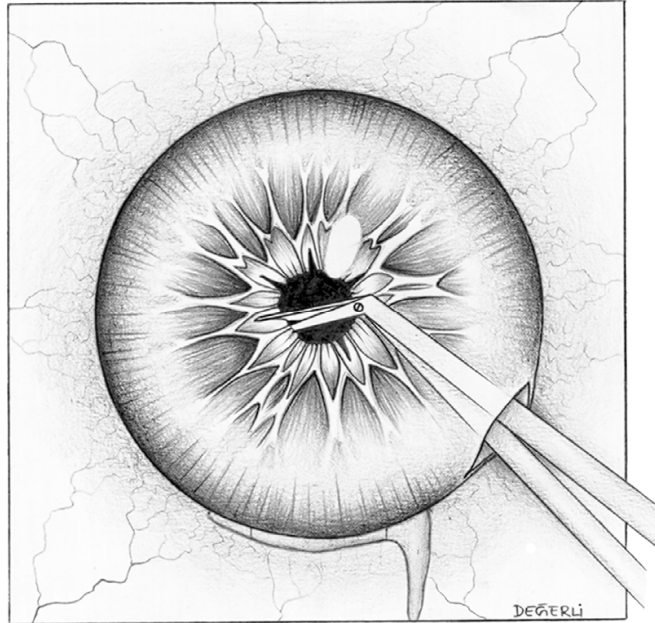


Fig. 3. Fine iris scissors such as Vannas make radial cuts 0.5 to 1 mm in iris sphincter at several locations (From Bayer A ed. *Glokom Cerrahisi*, 1<sup>st</sup> edition. Ankara:MN Medikal & Nobel; with permission).

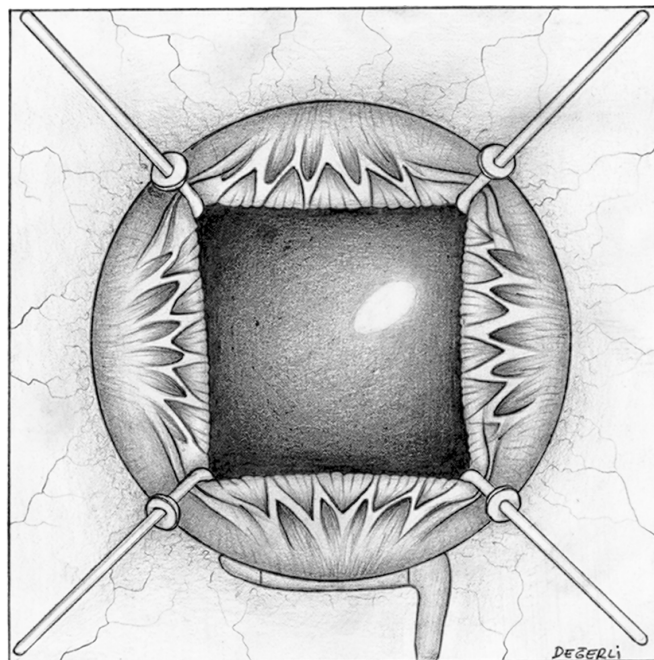


Fig. 4. Iris hooks are placed through paracentesis incisions. Pupil is engaged, and hooks are pulled toward periphery (From Bayer A ed. *Glokom Cerrahisi*, 1<sup>st</sup> edition. Ankara:MN Medikal & Nobel; with permission).



### 8.1 Extracapsular cataract extraction and trabeculectomy

Indications for combined extracapsular cataract extraction (ECCE) and trabeculectomy are similar to phacotrabeculectomy. Increased nucleus brunescence, reduced endothelial cell density, and Morgagni's cataracts are factors that favor extracapsular technique rather than phacoemulsification.

Fornix-based conjunctival peritomy is performed and conjunctiva is disinserted from the 10:00 to 2:00 meridian. Cauterization is performed for conjunctiva and episcleral hemostasis. The superficial scleral flap (rectangular, triangular, or circular) is outlined approximately 50% scleral thickness. It is usually placed in the center of the cataract incision, or at either end of it. A crescent knife is used to dissect the scleral flap. A groove is extended along the limbus on both sides at the base of the scleral flap. A stab incision is made to the anterior chamber adjacent to the anterior corner of the scleral flap, and the limbal groove. Anterior capsulotomy is performed using either envelope, or can opener technique. Continuous circular capsulorrhexis, slightly larger than that used for phacoemulsification can also be made. Multiple relaxing incisions may be made in the capsulotomy to facilitate nucleus removal. Cataract incision is extended to adequate width using corneoscleral scissors. After applying light pressure 2mm posteriorly to the incision with a forceps and additional force at the 6:00 meridian, the nucleus slides through the incision (Fig. 5). The lens cortex is removed in the usual fashion and posterior chamber IOL is implanted. The portion of the incision outside the scleral flap is closed with 10-0 nylon suture. The deep block of corneoscleral tissue is excised using either Vannas scissors or a Descemet's punch and peripheral iridectomy is performed. The scleral flap is closed with 2 to 6 interrupted 10-0 nylon sutures. The rate of aqueous outflow is checked by drying the flap area with a sponge as BSS is injected through the paracentesis. Additional sutures are placed as needed to ensure a formed anterior chamber and moderate aqueous outflow. Finally, the conjunctiva is sutured with interrupted 10-0 nylon sutures in watertight manner.

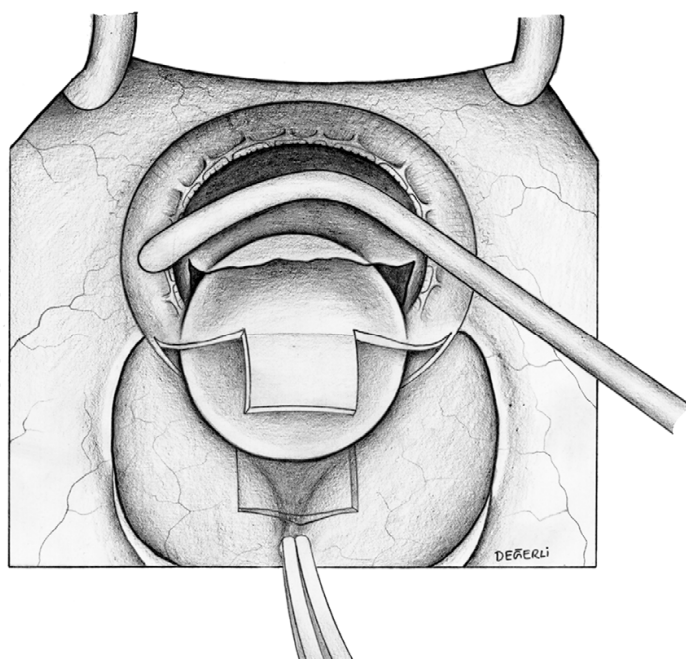


Fig. 5. Extracapsular cataract extraction combined with trabeculectomy. Nucleus removal using a forceps and hook (From Bayer A ed. *Glokom Cerrahisi*, 1<sup>st</sup> edition. Ankara:MN Medikal & Nobel; with permission).

## 8.2 Phacotrabeculectomy

A preferred technique for phacotrabeculectomy is to mimic a standard trabeculectomy procedure. The globe is immobilized with a 4-0 nylon suture beneath the tendon of the superior rectus muscle. Alternatively, corneal traction suture (6-0 or 7-0 silk) can be used. The suture in this case is placed over a length of 3mm through the cornea at 12 o'clock parallel to the limbus at a limbal distance of approximately 0.5 mm.

The conjunctiva is incised using scissors or a blade over a width sufficient to prepare a scleral flap. Either a fornix-based or limbus-based peritomy can be used. Fornix-based or limbus-based conjunctival flaps offer clinical advantages. Two retrospective studies in patients undergoing phacotrabeculectomy showed no difference in IOP control or visual acuity when either fornix-based or limbus-based conjunctival incisions were used (Tezel et al, 1997; Berestka & Brown, 1997). Some surgeons prefer the fornix-based flap is preferred because of better visualization during cataract surgery, but this flap has more leakage and therefore patient follow-up is more complex, especially when antimetabolites have been used (Hoskins & Migliazzo 1994; Cohen et al, 1996).

During 2-site phacotrabeculectomy, a limbus-based, 4X3mm rectangular, half-thickness scleral flap is dissected. The use of cautery should be limited so as to minimize postoperative inflammation. Some surgeons modify the shape and size of this scleral flap. Phacoemulsification is then performed through temporal corneal incision (Fig. 6), and intraocular lens is implanted into the capsular bag. Trabeculectomy opening (2X2 mm) is made using a Kelly Descemet's punch (Bausch & Lomb Surgical) or alternatively using scissors. This is followed by peripheral iridectomy. Scleral flap was closed with 2 to 6 10-0 nylon sutures. Black color is preferable because of the possible need for future suture lysis. The number of the sutures and their tightness should be adjusted during the operation. Injection of balanced salt solution into the anterior chamber permits intraoperative observation of pressure change and seepage of fluid at the edge of the scleral flap. The conjunctival-Tenon's capsule flap is closed with two wing sutures for a fornix-based flap or by a continuous running suture for a limbus-based flap. With the 1-site approach a scleral tunnel incision is made superiorly and the surgeon's preferred technique of phacoemulsification (Fig. 7) and IOL implantation is performed. Two radial incisions are made forward to the limbus and the tunnel incision is converted to a scleral flap. Trabeculectomy, iridectomy, scleral flap closure and conjunctiva closure is performed as mentioned above. Both 1-site and 2-site approaches to phacotrabeculectomy have yielded satisfactory results. In two studies comparing the results of these two techniques, patients who had the 1-site procedure required significantly more medication to maintain IOP control than did the group who had the 2-site procedure (Wyse et al, 1998; El-Sayyad et al, 1999).

Some surgeons have been eliminating the peripheral iridectomy step but there still remains the fear of incarceration and filtration failure. Kaplan-Messas et al randomized 36 patients to phacotrabeculectomy with and without iridectomy, 18 cases in each group. There were 11 additional patients having trabeculectomy alone. IOP lowering success was equal between the groups. There were more hyphemas in the trabeculectomy alone without iridectomy group (Kaplan-Messas et al, 1999). Our preference is to perform iridectomy in all the cases except neovascular glaucoma.

Newer technology has allowed cataract wounds to become smaller (Fig. 8). Whether an even less invasive cataract incision would translate into greater success and safety is unknown. We looked into the question of two-site phacotrabeculectomy compared to bimanual microincisional cataract surgery with trabeculectomy in 58 eyes and found very similar

success rates in regards of IOP. Complication rates were similar except for slightly more corneal edema in the two-site phacotrabeculectomy eyes (Bayer et al, 2009).

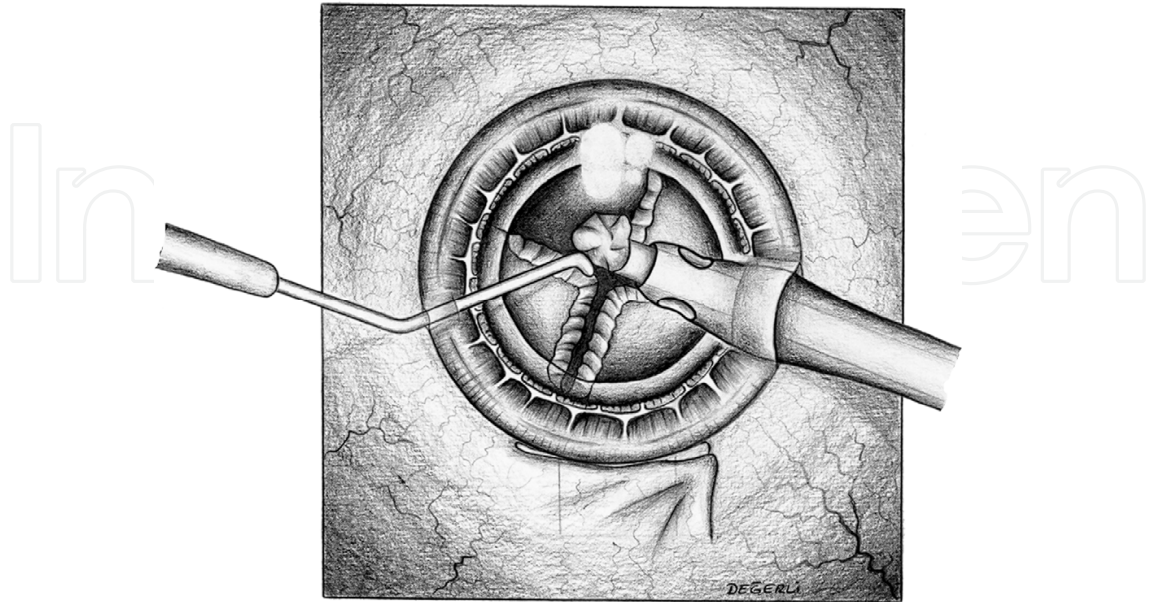


Fig. 6. Two-site phacotrabeculectomy. Phacoemulsification of each quadrant after nuclear cracking (From Bayer A ed. *Glokom Cerrahisi*, 1<sup>st</sup> edition. Ankara:MN Medikal & Nobel; with permission).

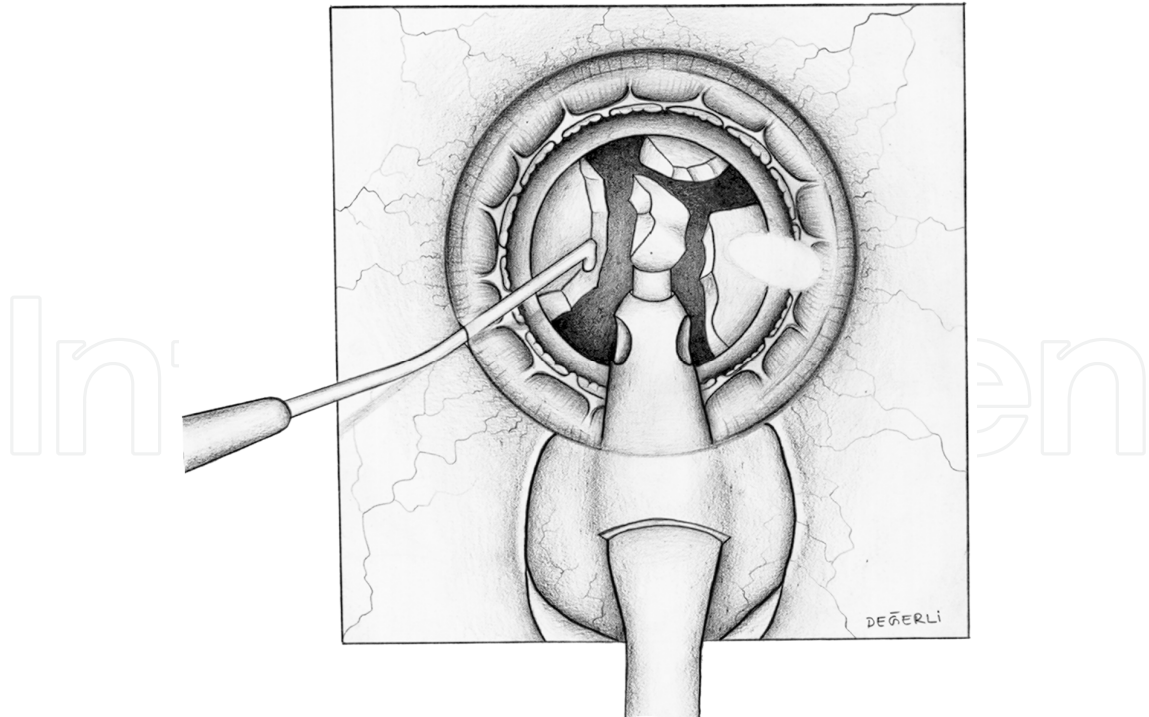


Fig. 7. One-site phacotrabeculectomy. Phacoemulsification of each quadrant after nuclear cracking (From Bayer A ed. *Glokom Cerrahisi*, 1<sup>st</sup> edition. Ankara:MN Medikal & Nobel; with permission).

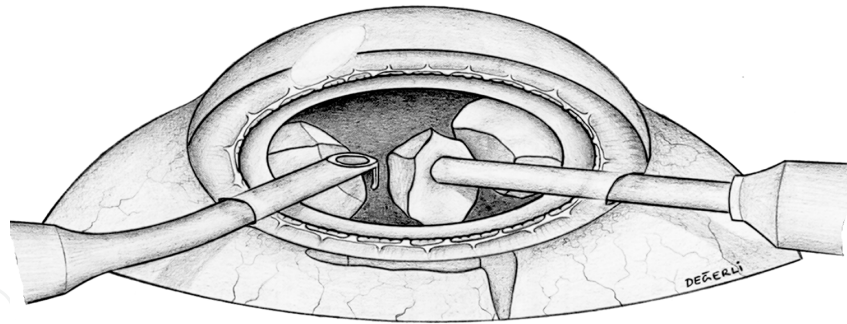


Fig. 8. Microincisional phacotrabeculectomy. Nucleus removal using an irrigating chopper and sleeveless phaco tip (From Bayer A ed. *Glokom Cerrahisi*, 1<sup>st</sup> edition. Ankara:MN Medikal & Nobel; with permission).

Careful postoperative follow up after any filtration surgery is vital to the success of the operation. Postoperative care will determine the outcome of surgery in many cases. All glaucoma medications should be discontinued. Aggressive topical steroid use, for example every 2 hours while awake, is recommended during the postoperative week. Topical antibiotics are instilled for 1 week. Topical steroid administration is continued for 2 months postoperatively. Tapering of the steroid dose is based on the amount of inflammation in and around the bleb. The early postoperative period is critical. It is during this time that procedures often fail and complications are most common. If the IOP is high, focal pressure is applied adjacent to the filtration site with a cotton-tip applicator to augment filtration (Traverso et al, 1984). This technique is preferred, because it encourages outflow through the sclerostomy site and can dislodge fibrin or other debris that may be limiting outflow. If the IOP is very low, one would expect to see a huge bleb. Any discrepancy between bleb appearance and IOP should warrant examination of a bleb leak. Once adequate aqueous production is established, by a deep anterior chamber and stable or rising IOP, the surgeon may augment filtration by performing suture lysis (Fig. 9) or release. Finally, part of the routine postoperative regimen should include discussion to educate patients of the potential hazards of blebs such as late leaks or late bleb infections.

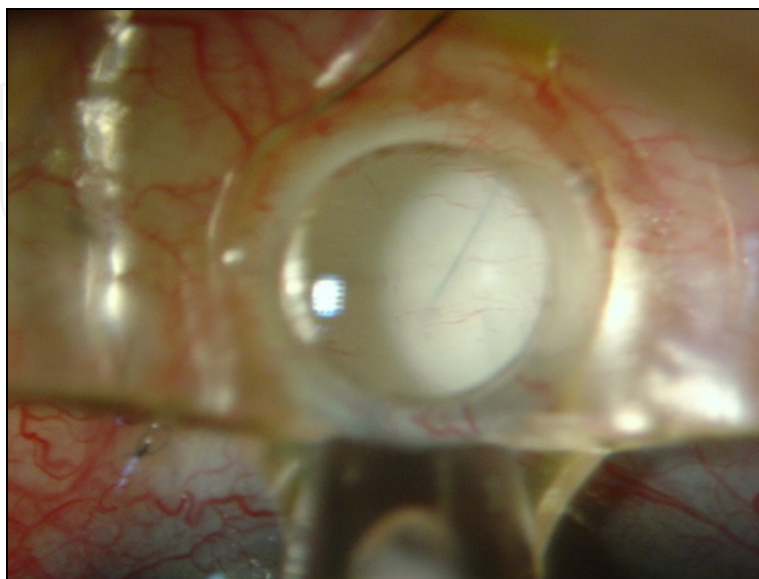


Fig. 9. View of the flap suture under the Hoskins lens during suture lysis.

### 8.3 Phacotrabeculotomy

Trabeculotomy has been reported to be effective in controlling IOP in eyes with POAG, pseudoexfoliation syndrome, and adult-onset glaucoma (Chihara et al, 1993; Tanihara et al, 1993; Wada et al, 1994).

Phacoemulsification and IOL implantation are performed as mentioned above, before the trabeculotomy ab externo. A clear corneal incision is made, and a corneoscleral incision after limbal peritomy is made in eyes to remove the cataract. After a continuous curvilinear capsulorrhexis, phacoemulsification and IOL implantation are performed. The trabeculotomy ab externo then is performed from a different site. The procedure begins with a limbal peritomy and radial conjunctival incision in the desired quadrant, and a fornix-based conjunctival flap is prepared. Conjunctiva and Tenon's tissue are retracted to expose the sclera. Apart from the site for cataract surgery, a 4 × 4-mm triangular area is marked, and the sclera is incised with a knife. A four-fifth thickness, limbal-based scleral flap is created. The outer wall of Schlemm's canal, which is identified as a dark brown band between the sclera and the scleral spur, is radially incised with a sharp razor blade and removed using modified Vannas scissors. Care is taken not to disrupt the inner wall of Schlemm's canal. Slow leakage of aqueous humor through the trabecular meshwork is confirmed under a surgical microscope. Semicircular trabeculotome probes (right and left) are inserted in both directions into Schlemm's canal, and rotated in to disrupt the inner wall of the canal and the juxtacanalicular tissue of the trabecular meshwork. The scleral flap then is sutured watertight with three 10-0 nylon sutures, and the conjunctival wound is closed with interrupted 10-0 nylon sutures.

Tanito et al. report that combined trabeculotomy and cataract surgery lowers IOP and has a low incidence of surgical complications (Tanito et al, 2001). A significant IOP reduction was observed in the trabeculotomy combined with phacoemulsification and IOL implantation (TPI group) and phacoemulsification and IOL implantation (PI) groups up to 3 years and up to 1 year and 6 months after surgery, respectively; the magnitude of the reduction was significantly larger in the TPI group. The success probabilities of TPI group for IOP control under 21, 17, and 15 mmHg were 95.8%, 58.7%, and 30.0%, respectively, 1 year after surgery. Tanito et al. suggests that trabeculotomy can be a better option for the older patients.

Lüke et al report that phacotrabeculotomy plus deep sclerectomy offered significant IOP reduction and a success rate that may be comparable with that of the current phacotrabeculectomy (Lüke et al, 2007). Intra- and postoperative complications specific to deep sclerectomy and trabeculotomy were seen in their series, although the overall rate of postoperative complications proved low.

The Trabectome is a surgical device that was cleared by the US Food and Drug Administration in January 2004 for the treatment of adult and juvenile open-angle glaucoma. The concept is similar in principle to ab interno trabeculotomy, the key difference being that a microelectrocautery device is used to ablate a strip of the trabecular meshwork and inner wall of Schlemm's canal, thus allowing direct access of aqueous to the collector channels. This theoretically bypasses the main site of resistance to aqueous outflow and reestablishes the natural drainage passageway out of the eye. Briefly, a 1.7-mm clear corneal incision is made temporally, through which the electrocautery handpiece is inserted and advanced to the nasal angle under gonioscopic visualization. The tip of the device is inserted into Schlemm's canal through the trabecular meshwork, and the cautery is then activated via a foot pedal. The handpiece is advanced while cautery is activated to ablate an arc of the meshwork, exposing the back wall of Schlemm's canal, usually for 90° to 120°. A

modified Swan-Jacob gonioscope (Ocular Instruments Inc, Bellevue, Washington) was developed for this procedure. The handpiece is then removed, and a single 10-0 suture is placed through the incision (Mosaed et al, 2009). This procedure has also been combined with microincisional phacoemulsification, and the IOP-lowering effect of the combined procedure has been previously reported to be 30% at 1 year in a study of 304 consecutive eyes (Francis et al, 2008; Minckler et al, 2008).

The main complication reported in the use of the Trabectome is transient hyphema (79% to 100%). There have been no reports of choroidal effusions, infections, or other permanent visual impairment. The potential advantages of this procedure are that it does not involve manipulation of the conjunctiva, the Tenon capsule, or sclera and therefore preserves the option for subsequent standard filtering surgery if necessary. There is also no risk of bleb-related complications such as leaks, blebitis, endophthalmitis, dellen, and dysesthesia, as there is no bleb formation. Hypotony has been rare, most likely if an inadvertent cyclodialysis occurs. The IOP-lowering effect after several months appears to stabilize in the mid-teens through 5 years of follow-up (n = 10).<sup>9</sup> After Trabectome, the majority of eyes require a reduced number of IOP-lowering medications. As a brief update on Trabectome, data now include IOP and medication outcomes on a total of 2,012 surgeries, including 1,228 Trabectome-only and 687 combined Trabectome-phacoemulsification surgeries continuing to demonstrate that clinically significant IOP and adjuvant medication reliance decrease follow these surgeries. Updated survival analyses for these two groups are also encouraging, especially for the combined cases.

#### **8.4 Phacoemulsification and non-penetrating surgery**

For many years ophthalmic surgeons have tried to find a way of surgically lowering the IOP without creating a filtering bleb and the associated complications. These are bleb dysesthesia, bleb leak, hypotony, blebitis, and bleb related endophthalmitis. One current trend in surgery for glaucoma is non-penetrating deep sclerectomy. Although we still do not have the same level of evidence for deep sclerectomy compared with trabeculectomy, some data support a similar efficacy of deep sclerectomy and trabeculectomy with a lower rate of complications. Because of these advantages, support for this technique has increased (Verges C et al, 2002; Gianoli F et al, 1999). By contrast, some reports show that the results of trabeculectomy are superior to those of deep sclerectomy (Chiselita D, 2001).

Deep sclerectomy is aimed at reducing IOP by allowing the filtration of aqueous humor into the subconjunctival space through the trabeculo-descemet membrane. The surgical technique varies; generally, after carrying out a fornix-based conjunctival peritomy, 5X5 mm superior scleral flap, approximately one-third of scleral thickness is dissected. At this stage, in all or in selected cases only, sponge soaked with 5-FU or MMC is applied over the sclera. A limbus based deep scleral flap is then prepared leaving a thin layer of sclera over the choroid and the ciliary body. The dissection is carried anteriorly until Schlemm's canal is deroofed and 1-2mm of Descemet's membrane is exposed. At this stage, aqueous humor should be seen percolating through the trabeculo-descemet membrane (Fig. 10). To increase percolation, some surgeons suggest removing the inner wall of Schlemm's canal. Deep scleral flap is removed and implants are used to avoid postoperative scarring. The superficial flap is sutured with two 10-0 nylon sutures. Conjunctiva is sutured with interrupted 10-0 nylon sutures.

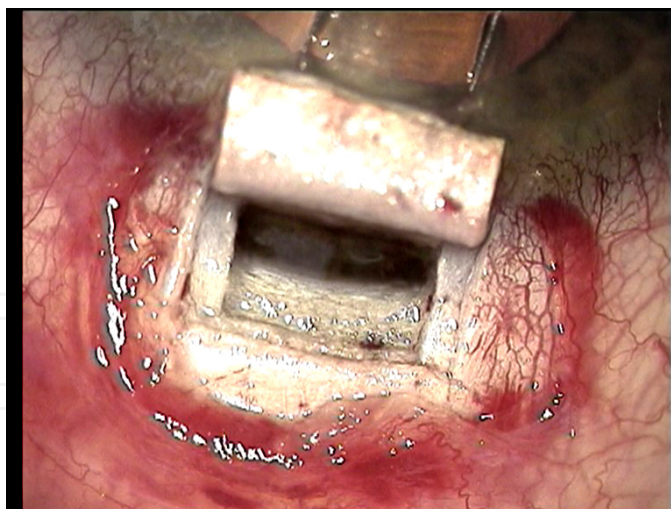


Fig. 10. Title of figure, left justified

Viscocanalostomy is similar to deep sclerectomy and Schlemm's canal is cannulated using a specifically designed 165 $\mu$ m cannula and high molecular weight sodium hyaluronate is slowly injected into the both ostia (Fig. 11). The injection of viscoelastic substance allows progressive atraumatic dilatation of Schlemm's canal.

One advantage of deep sclerectomy is its results in combination with phacoemulsification. D'Eliseo et al. in a randomized prospective work, compared a group of 21 eyes treated with deep sclerectomy with another group of 21 eyes treated with combined phacoemulsification and deep sclerectomy (D'Eliseo D et al, 2003). The IOP values in the group of eyes treated with combined surgery were better (13.1 mm Hg) than in the group treated with deep sclerectomy alone (15.2 mm Hg). The authors achieved IOPs lower than 21 mm Hg without medication in 90% of eyes undergoing combined surgery as opposed to 62% of eyes undergoing deep sclerectomy alone. Moreover, the incidence of postoperative hypotony was also reduced in the combined surgery group (20% vs 32%, respectively). Gianoli et al. however, reported similar results when they compared phacotrabeculectomy and phacoemulsification plus deep sclerectomy with a collagen implant, observing the same rate of pressure reduction after 1 year of follow-up (Gianoli F et al, 1999).

Rebolleda et al. analyzed Descemet membrane perforations necessary to convert the deep sclerectomy to a trabeculectomy, reporting that in deep sclerectomy cases it was necessary to convert 8.9% after 7 to 28 month follow-up (Rebolleda et al, 2004). IOP values were similar to those obtained in cases not needing perforation. However, their reported complications, although not serious, were significant, with hyphema, choroidal detachment, and fibrinous uveitis.

Viscocanalostomy obtained similar results to those of trabeculectomy during combined phacoemulsification. Park et al. observed IOP reduction and fewer glaucoma medications for IOP control (Park M et al, 2004). Whisart et al. also found similar results, with an IOP decrease of 37% in viscocanalostomy alone compared with 33% when combined with phacoemulsification (Park M et al, 2004). Uretmen et al. compared the safety and efficacy of viscocanalostomy and phacoviscocanalostomy in the management of medically uncontrolled open-angle glaucoma. In their study, 20 patients underwent phacoviscocanalostomy and 29 patients underwent viscocanalostomy alone. Significant reduction of IOP and medication occurred in both groups. The mean IOP reduction was 34%

in the eyes that underwent viscocanalostomy alone and 38% in the eyes that underwent phacoviscocanalostomy. The success rates of the two procedures were also comparable. In the combined surgery group, the best corrected visual acuity improved by two or more lines in 90% of the patients. Intraoperative complications did not occur in either group. The authors concluded that combining phacoemulsification with viscocanalostomy does not have a negative effect on the IOP control achieved by viscocanalostomy alone and does not increase the complication rate (Uretmen O et al, 2003).

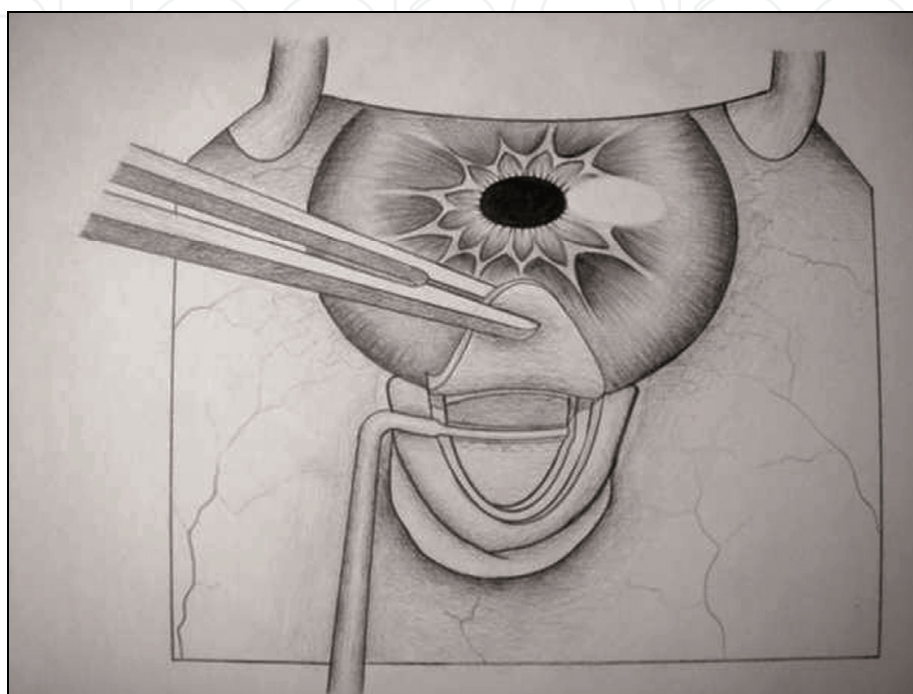


Fig. 11. Cannulation of Schlemm's canal during viscocanalostomy (From Bayer A ed. *Glokom Cerrahisi*, 1<sup>st</sup> edition. Ankara:MN Medikal & Nobel; with permission).

### 8.5 Phacoemulsification and endocyclophotocoagulation

Endoscopic cyclophotocoagulation (ECP) is a new surgical approach which targets the ciliary processes to decrease aqueous humor production thus leading to lower IOP. The use of ECP is becoming more accepted and is no longer reserved for end-stage cases. Previously developed methods targeting the ciliary processes, such as cyclocryotherapy and diode cycloablation, are procedures done without direct visualization of treated tissue and have been reserved for cases with endstage glaucoma after which other medical and surgical modalities have failed to control IOP. The experience with these less precise modalities has led to a degree of apprehension and skepticism about the use of ECP. Still, the use of ECP has increased with more cases performed earlier in the course of treatment (Gayton et al., 1999; Chen et al., 1997; Kahook et al., 2007).

ECP is carried out using a probe attached to a laser unit (Endo Optiks, Little Silver, NJ) which incorporates a diode laser. Pulsed continuous wave energy is emitted at 810 nm, using a 175 W variable xenon light source, a helium-neon laser aiming beam and video camera imaging. All elements are transmitted via fiberoptics within the probe. The 20 gauge probe provides a 70° field of view; the 18 gauge probe provides a 110° field. Power, duration, aiming beam intensity, and illumination are adjustable using controls on the



console. A foot pedal controls laser firing; the duration of treatment depends on how long the pedal is depressed. A retrobulbar or subtenons block with lidocaine and bupivacaine is preferred. After orientation of the probe image outside the eye, the probe is inserted intraocularly through a limbal incision. After visualization of the ciliary processes using the video monitor, treatment begins.

The safety and efficacy of ECP has been demonstrated in treating various forms of glaucoma when performed alone or in combination with phacoemulsification (Uram, 1995). ECP procedure is performed following phacoemulsification and IOL implantation and before the viscoelastic removal. Combined phacoemulsification and ECP is commonly practiced with ECP performed, in most cases, through a single clear cornea incision allowing approximately 240 to 300 degrees of treatment (Fig. 12). The remaining 60 to 120 degrees of ciliary processes under the corneal incision are often left untreated with the potential to eventually result in inadequate IOP lowering or frank failure of the procedure. Some surgeons, prefer to perform ECP to 360 degrees through two corneal incisions. Transvitreal approach can also be used for ECP, especially in vitrectomised eyes (Haller JA, 1996).

Complications of ECP include inflammation, hyphema, postoperative IOP spikes, choroidal detachment, choroidal hemorrhage, vitreous hemorrhage, hypotony, phtisis, and pregression to no light perception. ECP appears to be associated with a high rate of development of cataracts.

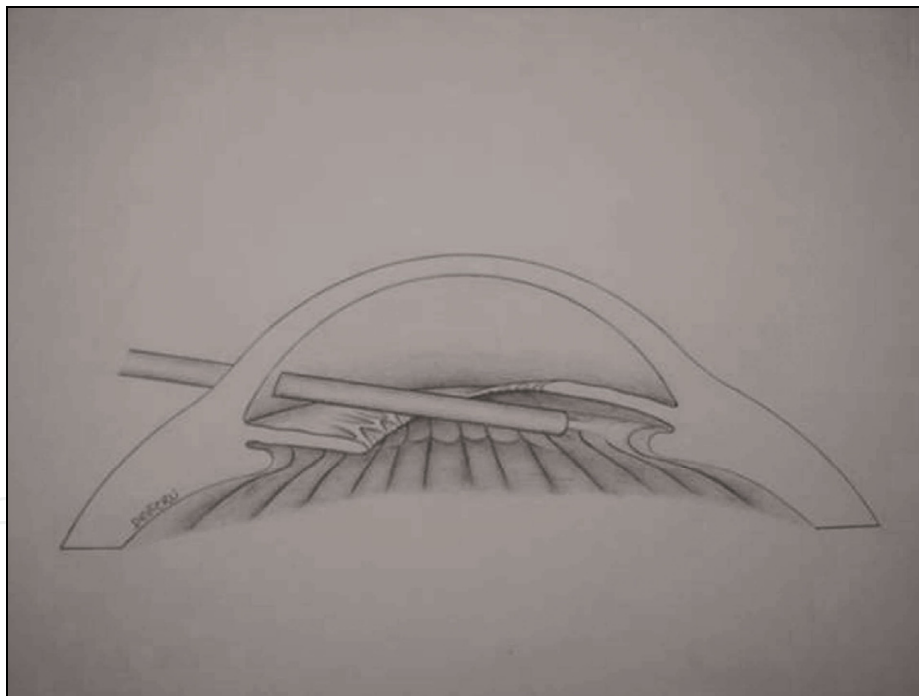


Fig. 12. Position of the probe during endoscopic cyclophotocoagulation from a clear corneal incision (From Bayer A ed. *Glokom Cerrahisi*, 1<sup>st</sup> edition. Ankara:MN Medikal & Nobel; with permission).

### 8.6 Phacocanaloplasty

Canaloplasty is a new angle surgical procedure that involves conjunctival incision, fashioning a trabeculectomy-like scleral flap and a smaller deeper flap (similar to non-penetrating surgery), which is excised to expose Schlemm's canal. A flexible microcatheter

with fiber optic illumination at the distal tip is introduced into the canal and advanced for 360° until visible opposite the entrance site. Viscoelastic is continually injected via the catheter lumen. A 10-0 Prolene suture is fastened to the distal catheter tip and then pulled back around the Schlemm's canal while the catheter is withdrawn (Fig. 13). The suture is then tensioned by hand to distend the canal inward. The superficial flap is then closed watertight, followed by secure closure of the conjunctiva. An ultrasound device can be used to verify tensioning and stretching of the canal, if desired.

Canaloplasty has also been successfully combined with phacoemulsification surgery (Lewis RA, 2011; Shingleton B, 2008). Lewis and colleagues have recently reported the 3 year results of combined phacoemulsification and canaloplasty. Eyes with combined cataract-canaloplasty surgery had a mean IOP of 13.6 mm Hg on  $0.3 \pm 0.5$  medications compared with a baseline IOP of 23.5 mm Hg on  $1.5 \pm 1.0$  medications. Intraocular pressure and medication use results in all eyes were significantly decreased from baseline at every time point (Lewis RA, 2011).

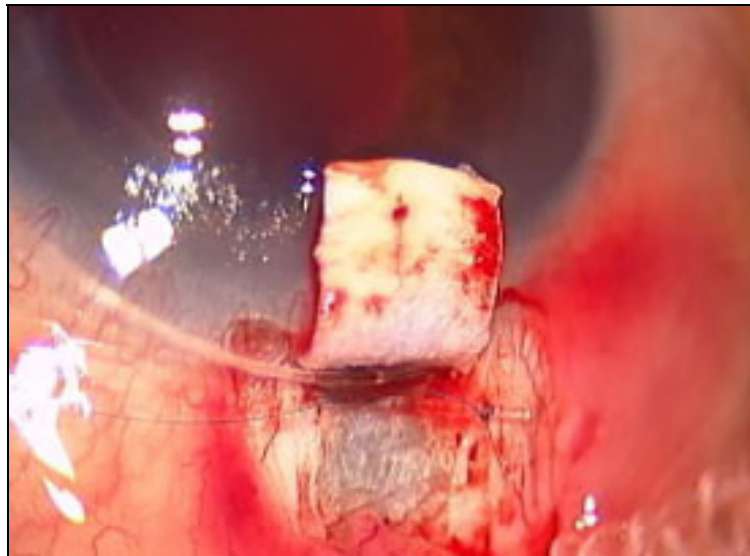


Fig. 13. Canaloplasty. Flexible microcatheter in Schlemm's canal with 10-0 prolene suture fastened to the distal end.

Benefits of this procedure over traditional glaucoma surgery include fewer complications, as it is not intended to create a bleb, therefore minimizing bleb-related complications. The most frequent early complication reported is hyphema. Late postoperative complications included cataract, transient IOP elevation, and partial suture extrusion through the trabecular meshwork. No bleb-related complications were reported so far.

## 9. Conclusion

Glaucoma surgery, as all the areas of ophthalmology, is changing rapidly. As the issue of cataract and glaucoma touches on two of the major and frequent problems, the choice of optimal care will certainly need to be re-evaluated. We now have new methods to benefit our patients and make a positive impact upon the quality of their lives. No uniform recommendations can be proposed for all cases. Clinicians have to consider a variety of factors before taking important surgical decisions. Greater safety can be provided by considering some of the newer glaucoma procedures. However, the ideal result has not yet

been realized. All of these new procedures have their own complications. We need to seek a better understanding of the variables in combined cataract and glaucoma surgery and to strengthen the evidence for adopting specific surgical techniques by designing multicentred, prospective, randomized trial.

## 10. References

- [1] AGIS Investigators (2001): The Advanced Glaucoma Intervention Study: 8. Risk of cataract formation after trabeculectomy. *Arch Ophthalmol* 2001; 119: 1771-1779.
- [2] Ahmed IK, Teichman JC. Multifocal IOLs and glaucoma: how much is too much? In: Chang D, editor. *Transitioning to refractive IOLs: the art and science*. Thorofare, NJ: Slack Incorporated; 2008, pp. 384-385.
- [3] Bayer A, Erdem U, Mumcuoglu T, et al. (2009). Two-site phacotrabeculectomy versus bimanual microincision cataract surgery combined with trabeculectomy. *Eur J Ophthalmol*, Vol.19, No.1, (January-February 2009), pp.46-54, PMID: 19123148.
- [4] Belyea DA, Dan JA, Lieberman MF, et al. (1997). Midterm follow-up results of combined phacoemulsification, lens implantation, and mitomycin-C trabeculectomy procedure. *J Glaucoma*, Vol.6, No.2, (April 1997), pp.90-8, PMID: 9098816.
- [5] Berestka JS, Brown SVL. (1996). Limbus- versus fornix-based conjunctival flaps in combined phacoemulsification and mitomycin C trabeculectomy surgery. *Ophthalmology*, Vol.104, No.7, (July 1997), pp.187-196, PMID: 9243657.
- [6] Carlson DW, Alward WL, Barad JP, et al. (1997). A randomized study of mitomycin augmentation in combined phacoemulsification and trabeculectomy. *Ophthalmology*, Vol.104, No.4, (April 1997), pp.719-24, PMID: 9111269.
- [7] Chen J, Cohn RA, Lin SC, et al. Endoscopic photocoagulation of the ciliary body for treatment of refractory glaucomas. *Am J Ophthalmol*, Vol.124, No.6, (December 1997), pp.787-796, PMID: 9402825.
- [8] Chihara E, Nishida A, Kodo M, et al. (1993). Trabeculectomy ab externo: an alternative treatment in adult patients with primary open-angle glaucoma. *Ophthalmic Surg*, Vol.24, No.11, (November 1993), pp.735-9, PMID:8290211.
- [9] Chiselita D.(2001) Non-penetrating deep sclerectomy in primary open angle glaucoma surgery. *Eye*, Vol.15, No.2, (April 2001), pp.197-201, PMID: 11339590.
- [10] Cionni RJ, Osher RH, Marques DMV, et al.2003. Modified capsular tension ring for patients with congenital loss of zonular support. *J Cataract Refract Surg*, Vol.29, No.9, (September 2003), pp.1668-1673, PMID: 14522284.
- [11] Cohen JS, Greff LJ, Novack G, et al. (1996). A placebo-controlled double-masked evaluation of mitomycin C in combined glaucoma and cataract procedures. *Ophthalmology*, Vol.103, No.11, (November 1996), pp.1934-42, PMID: 8942892.
- [12] Collaborative Normal-Tension Glaucoma Study Group (1998). The effectiveness of intraocular pressure reduction in the treatment of normal-tension glaucoma. *Am J Ophthalmol*. Vol.126, No.2, (October 1998), pp.498-505, PMID: 9780094.
- [13] Collaborative Normal-Tension Glaucoma Study Group. (1998). Comparison of glaucomatous progression between untreated patients with normal-tension glaucoma and patients with therapeutically reduced intraocular pressures. *Am J Ophthalmol*. Vol.126, No.2, (October 1998), pp.487-497, PMID: 9780094.

- [14] D'Eliseo D, Pastena B, Longanesi L, et al.(2003). Comparison of deep sclerectomy with implant and combined glaucoma surgery. *Ophthalmologica*, Vol.217, No.3, (May-June 2003), pp.208-11, PMID: 12660485.
- [15] Dinsmore SC. (1996). Modified stretch technique for small pupil phacoemulsification with topical anesthesia. *J Cataract Refract Surg*. Vol.22, No.1, (January-February 1996), pp.27-30, PMID: 8656356.
- [16] El-Sayyad F, Helal M, El-Maghraby A, et al.(1997). One-site versus 2-site phacoetabectomy: a randomized study. *J Cataract Refract Surg*, Vol.25, No.1, (January 1999), pp.77-82, PMID: 9888081.
- [17] Fine IH, Hoffman RS. (1997). Phacoemulsification in the presence of pseudoexfoliation: challenges and options. *J Cataract Refract Surg*, Vol.23, No.2, (March 1997), pp.160-5, PMID: 9113564.
- [18] Francis BA, Minckler D, Dustin L, et al. (2008). Trabectome Study Group Combined cataract extraction and trabeculotomy by the internal approach for coexisting cataract and open-angle glaucoma: initial results. *J Cataract Refract Surg*, Vol.34, No.7, (July 2008), pp.1096-1103, PMID: 18571075.
- [19] Gayton JL, Van Der Karr M, Sanders V. (1999). Combined cataract and glaucoma surgery: trabeculectomy versus endoscopic laser cycloablation. *J Cataract Refract Surg*, Vol.25, No.9, (September 1999), pp.1214-1219, PMID: 10476504.
- [20] Gianoli F, Schnyder CC, Bovey E, et al. (1999). Combined surgery for cataract and glaucoma: phacoemulsification and deep sclerectomy compared with phacoemulsification and trabeculectomy. *J Cataract Refract Surg*, Vol.25, No.3, (March 1999), pp.343-348, PMID: 10079438.
- [21] Godfrey DG, Fellman RL, Neelakantan A. (2009). Canal surgery in adult glaucomas. *Curr Opin Ophthalmol*, Vol.20, No.2, (March 2009), pp.116-21, PMID: 19240543.
- [22] Grady JM, Juzych MS, Shin DH, et al. (1993), Trabeculectomy, phacoemulsification, and posterior chamber lens implantation with and without 5-fluorouracil. *Am J Ophthalmol*. Vol.116, No.5, (November 1993), pp.594-9, PMID: 8238220.
- [23] Haller JA. (1996). Transvitreal endocyclophotocoagulation. *Trans Am Ophthalmol Soc*, Vol.94, (1996), pp.589-676, PMID: 8981713.
- [24] Hoskins HD, Migliazzo C. (1984). Management of failing filtering blebs with the argon laser. *Ophthalmic Surg*, Vol.15, No.9, (September 1984); pp.731-3, PMID: 6493678.
- [25] Hurvitz LM. (1993). 5-FU-supplemented phacoemulsification, posterior chamber intraocular lens implantation, and trabeculectomy. *Ophthalmic Surg*, Vol.24, No.10, (October 1993), pp.674-80 PMID: 8259245.
- [26] Hylton C, Congdon N, Friedman D, et al. (2003). Cataract after filtration surgery. *Am J Ophthalmol*, Vol.135, No. , pp. 231-232.
- [27] Jacob S, Agarwal A, Agarwal A, et al.(2003). Efficacy of a capsular tension ring for phacoemulsification in eyes with zonular dialysis. *J Cataract Refract Surg*, Vol.29, No.2, (February 2003), pp.315-321, PMID: 12648643.
- [28] Kahook MY, Lathrop KL, Noecker RJ. (2007). One-site versus two-site endoscopic cyclophotocoagulation. *J Glaucoma*, Vol.16, No.6, (September 2007), pp.527-30, PMID: 17873713.
- [29] Kaplan-Messas A, Cohen Y, Blumenthal E, et al.(2009). Trabeculectomy and phacotrabeculectomy with and without peripheral iridectomy. *Eur J Ophthalmol*, Vol.19, No.2, (March-April 2009), pp.231-234, PMID: 19253239.

- [30] Kass MA, Heuer DK, Higginbotham EJ, et al. (2002). The Ocular Hypertension Treatment Study: a randomized trial determines that topical ocular hypertensive medication delays or prevents the onset of primary open-angle glaucoma. *Arch Ophthalmol*. Vol.120, No.6, (June 2002), pp.701-713, PMID: 12049574.
- [31] Küchle M, Vinoses SA, Mahlow J, et al. (1996). Blood-aqueous barrier in pseudoexfoliation syndrome: evaluation by immunohistochemical staining of endogenous albumin. *Graefes Arch Clin Exp Ophthalmol*, Vol.234, No.1, (January 1996), pp.12-8, PMID: 8750845.
- [32] Lederer CM Jr.(1996). Combined cataract extraction with intraocular lens implant and mitomycin-augmented trabeculectomy. *Ophthalmology*. Vol.103, No.7, (July 1996), pp.1025-34, PMID: 8684790.
- [33] Lee RK, Gedde SJ. (2004): Surgical management of coexisting cataract and glaucoma. *Int Ophthalmol Clin*. Vol. 44, No.2, (Spring 2004), pp.151-166, PMID: 15087734.
- [34] Leske MC, Wu SY, Nemesure B, et al. (2002). Risk factors for incident nuclear opacities. *Ophthalmology*. Vol.109, No.7, (July 2002), pp.1303-8. PMID: 12093655.
- [35] Lewis RA, von Wolff K, Tetz M, et al. (2011). Canaloplasty: Three-year results of circumferential viscodilation and tensioning of Schlemm canal using a microcatheter to treat open-angle glaucoma. *J Cataract Refract Surg*, Vol.37, No.4, (April 2011), pp.682-90. PMID: 21420593.
- [36] Lichter PR, Musch DC, Gillespie BW, et al. (2001). Interim clinical outcomes in the Collaborative Initial Glaucoma Treatment Study comparing initial treatment randomized to medications or surgery. *Ophthalmology*, Vol.108, No.11, (November 2001), pp.1943-1953, PMID: 11713061.
- [37] Lüke C, Dietlein TS, Lüke M, et al. (2007). Phaco-trabeculectomy combined with deep sclerectomy, a new technique in combined cataract and glaucoma surgery: complication profile. *Acta Ophthalmol Scand*, Vol.85, No.2, (March 2007), pp.143-8, PMID: 17305727.
- [38] Minckler DS, Mosaed S, Dustin L, et al. (2008). Trabectome (trabeculectomy-internal approach): additional experience and extended follow-up. *Trans Am Ophthalmol Soc*. Vol.106, (2008), pp.1-12, PMID:19277230.
- [39] Mosaed S, Dustin L, Minckler DS. (2009). Comparative outcomes between newer and older surgeries for glaucoma. *Trans Am Ophthalmol Soc*, Vol.107, (December 2009), pp.127-33, PMID: 20126489.
- [40] Munden PM, Alward WL. (1995). Combined phacoemulsification, posterior chamber intraocular lens implantation, and trabeculectomy with mitomycin C. *Am J Ophthalmol*, Vol.119, No.1, (January 1995), pp.20-9, PMID: 7825686.
- [41] Nichamin LD. (1993). Enlarging the pupil for cataract extraction using flexible nylon iris retractors. *J Cataract Refract Surg*, Vol.19, No.6, (November 1993), pp.793-6, PMID:8271181.
- [42] Obstbaum SA. Cataract surgery in the glaucoma patient. In: Weinreb RN, Kitazawa Y, Krieglstein GK, editors. *Glaucoma in the 21<sup>st</sup> century*. London: Mosby International; 2000. pp. 259-265.
- [43] Park M, Tanito M, Nishikawa M, et al. (2004). Combined viscocanalostomy and cataract surgery compared with cataract surgery in Japanese patients with glaucoma. *J Glaucoma*, Vol.13, No.1, (February 2004), pp.55-61, PMID: 14704545.

- [44] Rebolleda G, Muñoz-Negrete FJ. (2004) Phacoemulsification-deep sclerotomy converted to phacotrabeculectomy. *J Cataract Refract Surg*, Vol.30, No.7, (July 2004), pp.1597-8, PMID:15210250.
- [45] Ritch R. (1994). Exfoliation syndrome and occludable angles. *Trans Am Ophthalmol Soc*. 1994;92:pp, 845-944, PubMed PMID: 7886885.
- [46] Seah SK, Jap A, Prata JA Jr, et al. (1996). Cataract surgery after trabeculectomy. *Ophthalmic Surg Lasers*. Vol.27, No.7, (July 1996), pp. 587-94, PMID: 9240775.
- [47] Shingleton BJ, Rosenberg RB, Teixeira R, et al. (2007). Evaluation of intraocular pressure in the immediate postoperative period after phacoemulsification. *J Cataract Refract Surg*. Vol.33, No.11, (November 2007), pp.1953-7, PMID: 17964404 .
- [48] Shingleton B, Tetz M, Korber N. (2008). Circumferential viscodilation and tensioning of Schlemm canal (canaloplasty) with temporal clear corneal phacoemulsification cataract surgery for open-angle glaucoma and visually significant cataract: one-year results. *J Cataract Refract Surg*, Vol.34, No.3, (March 2008), pp.433-40, PMID: 18299068.
- [49] Stewart R, Grosserode R, Cheetham JK, et al. (1999). Rosenthal A. Efficacy and safety profile of ketorolac 0.5% ophthalmic solution in the prevention of surgically induced miosis during cataract surgery. *Clin Ther*, Vol.21, No.4, (April 1999), pp.723-732, PMID :10363737.
- [50] Tanihara H, Negi A, Akimoto M, et al. (1993). Surgical effects of trabeculotomy ab externo on adult eyes with primary open angle glaucoma and pseudoexfoliation syndrome. *Arch Ophthalmol*, Vol.111, No.12, (December 1993), pp.1653-61, PMID: 8155036.
- [51] Tanihara H, Negi A, Akimoto M, et al. (1995). Long-term surgical results of combined trabeculectomy ab externo and cataract extraction. *Ophthalmic Surg*, Vol.26, No.4, (July-August 1995), pp.316-324, PMID: 8532283.
- [52] Tanito M, Ohira A, Chihara E. (2001). Surgical outcome of combined trabeculotomy and cataract surgery. *J Glaucoma*, Vol.10, No.4, (August 2001), pp.302-8, PMID: 11558815.
- [53] Teichman JC, Ahmed II. Intraocular lens choices for patients with glaucoma. (2010). *Curr Opin Ophthalmol*. Vol.21, No.2, (March 2010), pp.135-43, PMID: 20040877 .
- [54] Tezel G, Kolker AE, Kass MA, et al.: Comparative results of combined procedures for glaucoma and cataract: II: limbus-based versus fornix-based conjunctival flaps. *Ophthalmic Surg Lasers* 1997, 28:551-557.
- [55] Traverso CE, Greenidge KC, Spaeth GL, et al. (1984). Focal pressure: a new method to encourage filtration after trabeculectomy. *Ophthalmic Surg*, Vol.15, No.1, (January 1984), pp.62-5, PMID: 6700947.
- [56] Uram M. (1995). Combined phacoemulsification, endoscopic ciliary process photocoagulation, and intraocular lens implantation in glaucoma management. *Ophthalmic Surg*, Vol.26, No.4, (July-August 1995), pp.346-52, PMID: 8532289.
- [57] Uretmen O, Ateş H, Güven S, et al. (2003). Comparison of outcomes of viscocanalostomy and phacoviscocanalostomy. *Can J Ophthalmol*, Vol.38, No.7, (December 2003), pp.580-6, PMID: 14740800.
- [58] Verges C, Llevat E, Bardavio J.(2002). Laser-assisted deep sclerectomy. *J Cataract Refract Surg*, Vol.28, No.5, (May 2002), pp.758-765, PMID: 11978452.

- [59] Wada Y, Nakatsu A, Kondo T. (1994). Long-term results of trabeculotomy ab externo. *Ophthalmic Surg*, Vol.25, No.5, (May 1994), pp.317-20, PMID: 8058264.
- [60] Wishart MS, Shergill T, Porooshani H.(2002). Viscocanalostomy and phacoviscocanalostomy: long-term results. *J Cataract Refract Surg*, Vol.28, No.5, (May 2002), pp.745-51, PMID: 11978450.
- [61] Wong PC, Ruderman JM, Krupin T, et al. (1994). 5-Fluorouracil after primary combined filtration surgery. *Am J Ophthalmol*, Vol.117, No.2, (February 1994), pp.149-54, PMID: 8116741.
- [62] Wyse T, Meyer M, Ruderman JM, et al. (1998). Combined trabeculectomy and phacoemulsification: a one-site versus a two-site approach. *Am J Ophthalmol*, Vol.123, No.3, (March 1998), pp.334-339, PMID: 9512150.