

We are IntechOpen, the world's leading publisher of Open Access books Built by scientists, for scientists

4,800

Open access books available

122,000

International authors and editors

135M

Downloads

Our authors are among the

154

Countries delivered to

TOP 1%

most cited scientists

12.2%

Contributors from top 500 universities



WEB OF SCIENCE™

Selection of our books indexed in the Book Citation Index
in Web of Science™ Core Collection (BKCI)

Interested in publishing with us?
Contact book.department@intechopen.com

Numbers displayed above are based on latest data collected.

For more information visit www.intechopen.com



Useful Tips for Skin Grafts

Rei Ogawa and Hiko Hyakusoku

Additional information is available at the end of the chapter

<http://dx.doi.org/10.5772/55084>

1. Introduction

Skin grafting is a common operative procedure that is widely used in plastic, reconstructive, and aesthetic surgery. Beyond mere graft survival, however, the goals of surgery include good matching of texture and color and minimizing donor morbidity. These factors and optimal donor sites require careful consideration in each patient. We have found that the recommendations offered below can help achieve these goals.

2. Skin-graft harvesting on the basis of a high-cut bathing suit

When harvesting full-thickness skin grafts, it is important to consider each patient's age and sex to select the appropriate donor sites [1]. The correct color and texture is of paramount importance, but also important is minimal donor-site morbidity. The favored donor sites usually include the postauricular and subclavicular regions, the medial side of the upper arm, and the inguinal region. Of these sites, the inguinal region is often preferred because of its inconspicuous position and the facility of primary closure (Fig1a, b). However, a wound on the crease of inguinal region is much more objectionable than we had expected, especially for young female patients, because of the current vogue for swimsuits and short pants with high-cut leg openings. An example of such a case is that of a young woman in whom we selected the inguinal region as the donor site. Moreover, the crease of the inguinal region is often pigmented because of chronic inflammation due to sweat or sebum. It is, therefore, best to focus on the high-cut leg region rather than the inguinal crease (Fig1c, d). Another benefit of this approach is that the patient can be permitted to walk immediately after the operation, because when the legs are moved a wound in the high-cut leg region is subjected to less tension than is a wound in the inguinal region. This method should be indicated in female infant patients for the future.

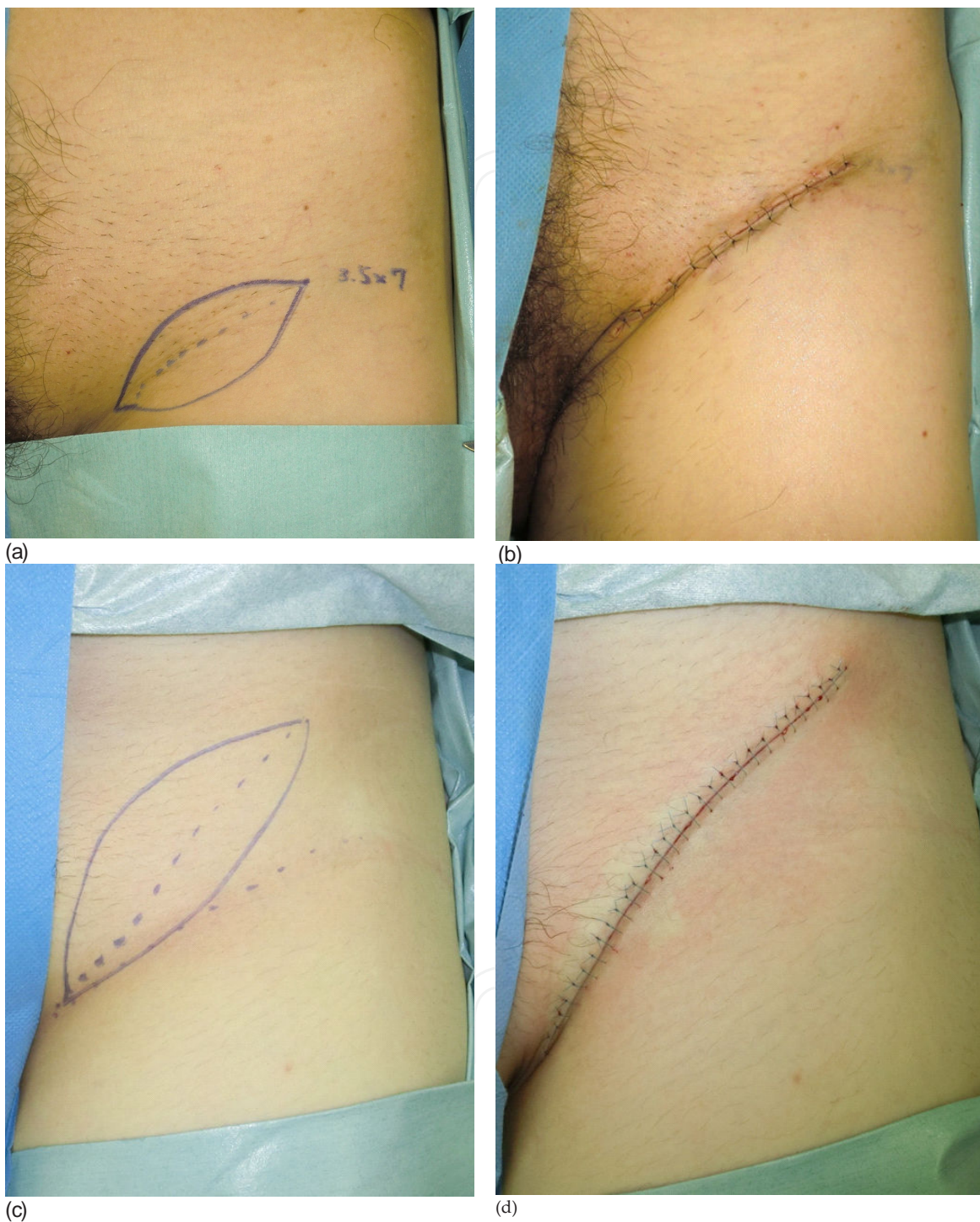

Figure 1. (a) Design of harvesting a skin graft on the conventional inguinal region (b) The sutured wound on the inguinal crease (c) Design of harvesting a skin graft on the our on the high-cut leg region (d) The sutured wound on the high-cut leg region

3. Use of a flower holder for making drainage holes

The success of a skin graft depends on [1] appropriate debridement of the recipient site down to the layer providing the blood supply; [2] adequate hemostasis of the recipient site to prevent the development of a hematoma; and [3] sufficient compression and securing of skin grafts from corner to corner, using a tie-over dressing or bandages. Hemostasis is especially important in blood-rich regions such as the scalp, face, and hand. In such cases, drainage holes — which are also useful for the drainage of bacteria and exudates — should be made on the skin grafts. However, large drainage holes will leave scars; therefore, numerous small holes are preferred. To make such holes, a Japanese *kenzan* flower holder (Fig. 2a) is far more effective than surgical knives or needles. The graft, held by a rubber sheet, is turned onto a flower holder. It is then beaten (against the rubber sheet) with a hammer (Fig. 2b). In this way, numerous small holes can be made in a matter of minutes (Fig. 2c). These holes suffice for drainage and become epithelialized after about 10 days (Fig. 2d, e). When using a flower holder for making drainage holes, split-thickness skin grafting is a good indication. When harvesting split-thickness skin grafts, it is important to select the non-outstanding donor sites. The favored donor sites usually include the thigh, the abdomen, and the dorsal region.

One established drainage method involves creating holes in the graft, typically with a No. 11 surgical knife. However, such holes can cause scars, so this method is undesirable when skin grafting is performed in exposed areas such as the face and dorsum of the hand. Before developing the method described here, we had used to create holes using an 18-gauge injection needle. However, uniformly creating numerous small holes took considerable time with large skin grafts. Non-expanded mesh skin grafts are also an option for treating actively bleeding wounds, but they are of limited use for cosmetic purposes.

4. Use of a tie-over dressing with external wire-frame fixation

We have used external wire-frame fixation for skin grafts since 1986. In 1991, we reported this method and described two advantages: [1] the technique is useful for securing grafts to wound beds and [2] preventing the graft edges from lifting [2]. Moreover, we confirmed the usefulness of this technique for skin grafting to regions with free borders, such as the lips and eyelids [3]. Particularly for eyelid grafts, external wire-frame fixation overcomes the disadvantages of tarsorrhaphy [3]. Moreover, this method can also be used for digital skin grafting [4]. Three-dimensional external wire frames are useful for fixing digital joints as well as skin grafts. If this method is used for digital skin grafts, the fixing of digital joints by pinning is not necessary, particularly for grafting the palmar surface of a finger.

During surgery, the skin graft is fixed with sutures by the usual method. At the same time, the wire frame, shaped like the graft itself, is made of 1.2-mm-diameter Kirschner wire. Then, one part of each suture is bound up (Fig. 3a, b), and the wire frame is applied to the graft. Next, the wire frame is attached with the same sutures already used for stitching the graft. Finally, tie-over fixation is performed in the usual way (Fig. 3c). The skin graft is then

taken from corner to corner even if it involves application on a free edge. This method is helpful to secure the skin graft after operation, and the post operative course will be uneventful (Fig.3d).

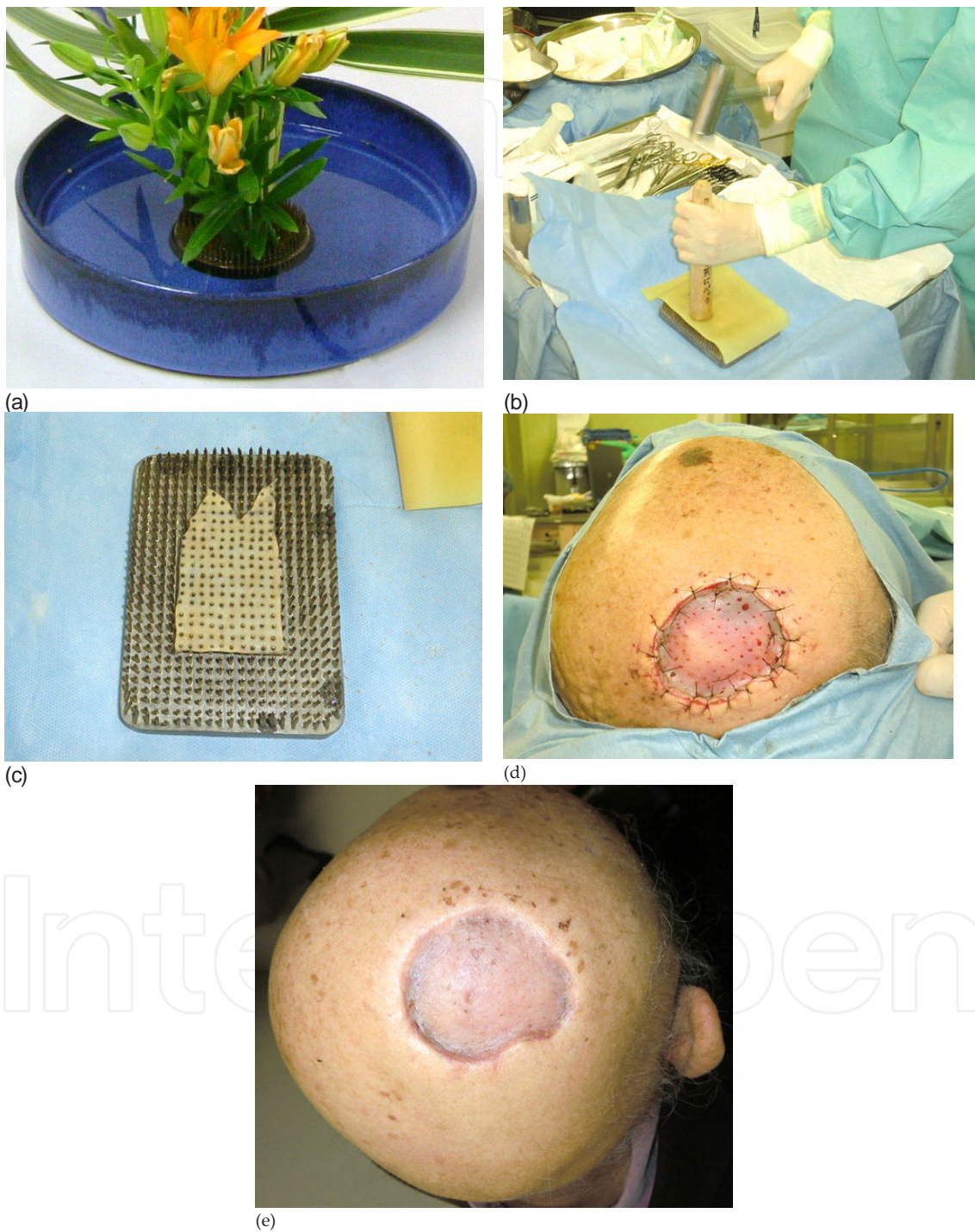


Figure 2. (a) A Japanese Kenzan flower holder (b) Making holes by beaten with a hammer (c) Numerous small holes (d) Immediately after skin grafting: blood is drained from holes (e) A month after operation: there are no scars of drainage holes

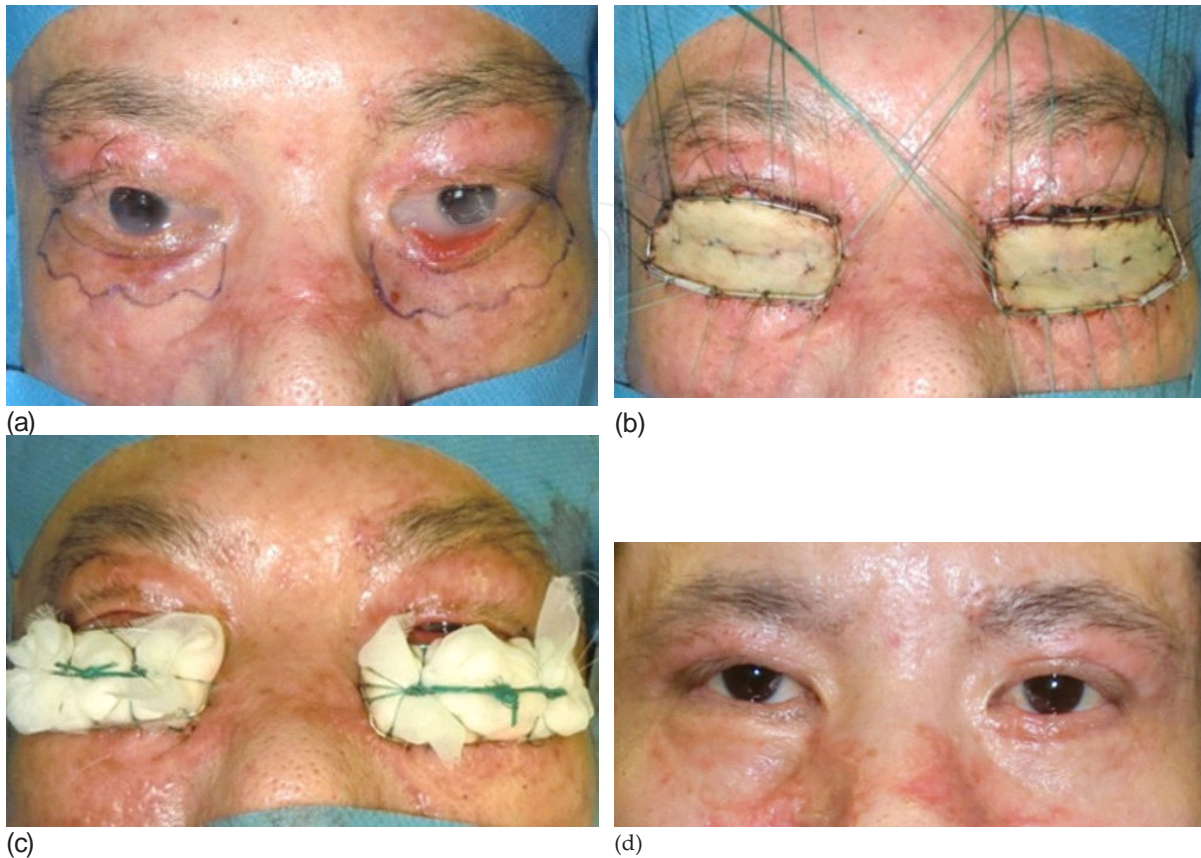

Figure 3. (a) Preoperative view of scar contractures on the bilateral lower eyelids (b) After applying skin grafts and external wire frames (c) Tie-over fixation (d) 6 months post operative view: scar contracture is completely released

5. Conclusions

We have presented three techniques that we have found to reduce complications and surgical invasiveness. [1] Skin grafts should be harvested on the basis of a swimsuit with high-cut leg openings. [2] A flower holder is recommended for making drainage holes. [3] A tie-over dressing using external wire-frame fixation is recommended. As mentioned, the success of a skin graft depends on: [1] appropriate debridement of the recipient site down to the layer providing the blood supply; [2] adequate hemostasis of the recipient site to prevent the development of a hematoma; and [3] sufficient compression and securing of skin grafts from corner to corner, using a tie-over dressing or bandages. However, most important is the surgeon's determination to reduce complications and surgical invasiveness. With this attitude, we have developed these recommendations. We hope that they will become widely known among the many physicians working with patients who require surgery of this kind.

Author details

Rei Ogawa and Hiko Hyakusoku

*Address all correspondence to: r.ogawa@nms.ac.jp

Department of Plastic, Reconstructive and Aesthetic Surgery, Nippon Medical School, Tokyo, Japan

References

- [1] Rigg, B. M. Importance of donor site selection in skin grafting. *Can Med Assoc J* (1977). , 117, 1028-29.
- [2] Hirai, T, Hyakusoku, H, & Fumiiri, M. The use of a wire frame to fix grafts externally. *Br J Plast Surg* (1991). , 44, 69-70.
- [3] Murakami, M, Hyakusoku, H, & Ishimaru, S. External wire frame fixation of eyelid graft. *Br J Plast Surg* (2003). , 56, 312-13.
- [4] Ogawa, R, Aoki, S, Aoki, M, Oki, K, & Hyakusoku, H. Three-dimensional external skin graft fixation of digital skin graft. *Plast Reconstr Surg* (2007). IN PRESS.