

We are IntechOpen, the world's leading publisher of Open Access books Built by scientists, for scientists

4,800

Open access books available

122,000

International authors and editors

135M

Downloads

Our authors are among the

154

Countries delivered to

TOP 1%

most cited scientists

12.2%

Contributors from top 500 universities



WEB OF SCIENCE™

Selection of our books indexed in the Book Citation Index
in Web of Science™ Core Collection (BKCI)

Interested in publishing with us?
Contact book.department@intechopen.com

Numbers displayed above are based on latest data collected.
For more information visit www.intechopen.com



Dyschromatosis Symmetrica Hereditaria and RNA Editing Enzyme

Michihiro Kono and Masashi Akiyama

Additional information is available at the end of the chapter

<http://dx.doi.org/10.5772/55203>

1. Introduction

Dyschromatosis symmetrica hereditaria (DSH) is a highly penetrant autosomal-dominant skin disease. It is characterized by a mixture of hyper- and hypo-pigmented macules on the dorsal aspects of the hands and feet (Figure 1). The disorder typically has its onset during infancy or early childhood, stops spreading before adolescence and lasts for life. It was clarified in 2003 that a heterozygous mutation in the adenosine deaminase acting on RNA1 gene (*ADAR1*) causes DSH [1].

The *ADAR1* protein catalyzes the deamination of adenosine to inosine in double-stranded RNA [2, 3]. This modification is called RNA editing, more specifically A-I editing (Figure 2).

RNA editing is a post-transcriptional modification, and A-I editing is widely conserved in species ranging from roundworm to mammals. A-I editing had been considered a rare phenomenon in the coding region and this editing is known to create alterations of the codon or alternative splice sites that lead to different proteins in the target substrate. Representative substrate genes are the ionotropic AMPA glutamate receptor subunit 2 [4] and the 5-HT_{2c} serotonin receptor [5], which are both expressed in the brain and are associated with the some neurologic diseases [6].

However, the substrate gene for *ADAR1* in the skin and the pathogenic mechanisms whereby mutation in *ADAR1* causes DSH remain unknown.

This chapter addresses DSH. First, we introduce the clinical and pathological features of DSH. Next, we introduce how *ADAR1* was identified as the causative gene of DSH. I mention *ADAR1* and A-I editing, *ADAR1* isoforms and DSH, the absence of a correlation between the DSH phenotype and mutation in *ADAR1*, and murine models of DSH.

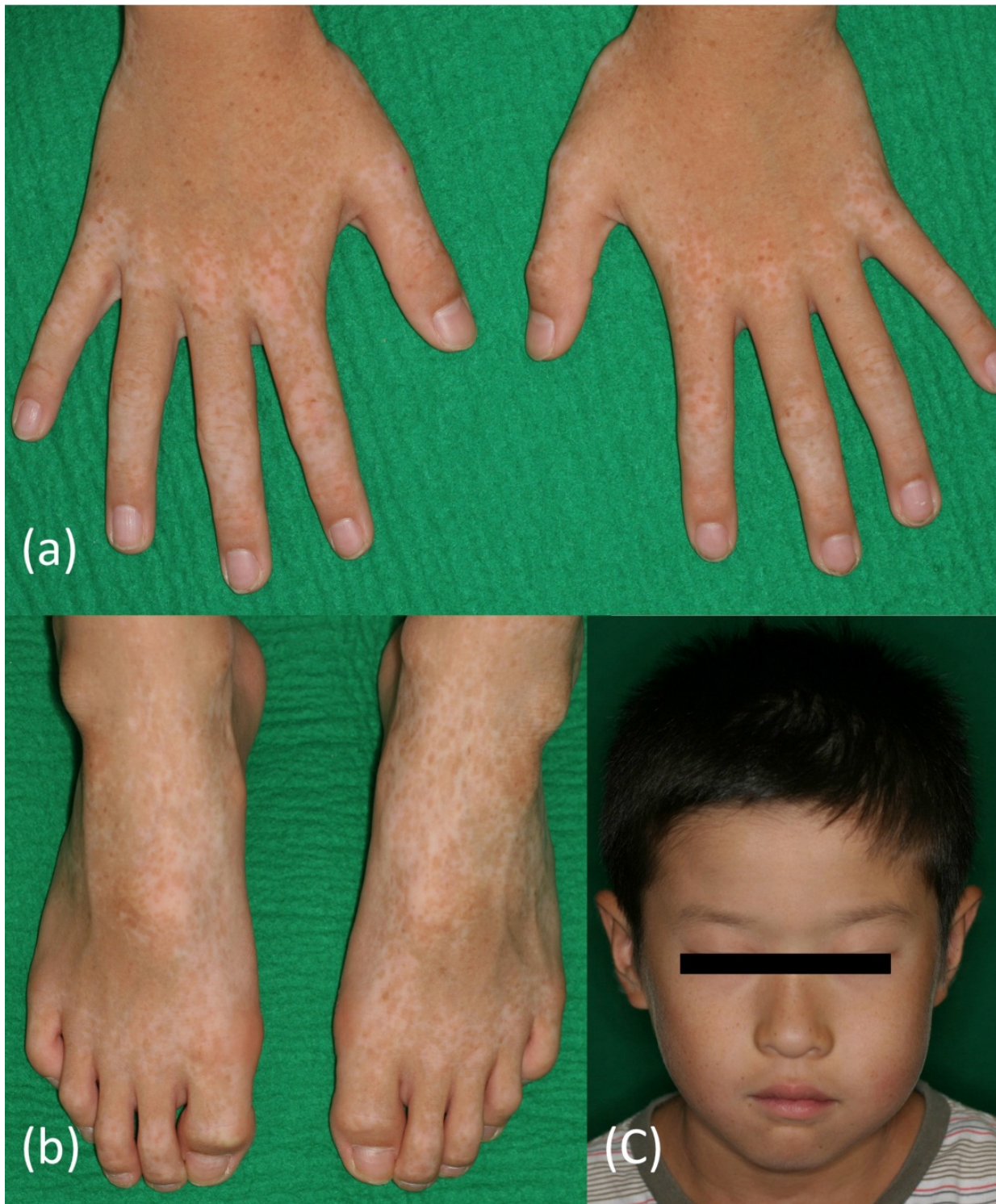


Figure 1. Clinical features of dyschromatosis symmetrica hereditaria. The patient is an 8-year-old boy. His hands and feet show hyper- and hypopigmented macules (a, b). On the face, he has small freckle-like, light-brown macules (c).

2. DSH, ADAR1 and RNA editing

2.1. Epidemiology and clinical features of DSH

Dyschromatosis symmetrica hereditaria (DSH; OMIM#127400; also called reticulate acropigmentation of Dohi) is an autosomal-dominant pigmentary genodermatosis with almost full penetrance. DSH was first described by Toyama [7, 8].

Clinically, the disorder is characterized by areas several millimeters in diameter of mixed hypopigmented and hyperpigmented macules distributed predominantly on the dorsal aspects of the hands and feet but sometimes extending to the dorsal aspects of the limbs (Figure 1). The lesions on the face are described as freckle-like macules with no hypopigmentation [9, 10]; some cases have been reported in which mixed areas of hypopigmented and hyperpigmented macules on the cheek were similar to those on the hands and feet [11]. Patients who have strong skin manifestations on the limbs also tend to have lesions on face. The skin lesions do not show telangiectasia, atrophy or scaling. Skin manifestations are not observed on the palm, sole or mucosa.

DSH has been reported mainly from Japan and China; however, patients in South Korea [12], Taiwan [13], Thailand [11], India [14], Turkey [15] and Europe [16, 17] and patients of Hispanic ethnicity [18] have been reported.

The disorder typically develops during infancy or early childhood [19]. Lesions first appear before the age of 6 years in 73% of cases, and the first appearance is usually on the limbs (83%) [20], particularly the hands and feet. This point can be useful in differentiating the disorder from dyschromatosis universalis symmetrica (DUH). The macules enlarge progressively [16], stop spreading before adolescence and last for life [19, 21]. The onset of lesions during adolescence has been reported in some patients [22].

The skin findings are more pronounced after sun exposure, although patients do not show photosensitivity [10, 20]. This differentiates the disorder from xeroderma pigmentosum (XP).

Interfamilial and intrafamilial variation has been reported. The clinical features are not always similar among patients in a pedigree [23]. We have encountered a family in which the patient has only faint hypopigmented macules on the backs of the fingers and the patient's children have mixtures of hyper- and hypopigmented macules in all the limbs.

The characteristic clinical features of typical DSH can be clearly differentially diagnosed from similar hereditary pigmentary disorders as follows [9]. Acropigmentatio reticularis (Kitamura) (ARK) is characterized by atrophic pigmented macules on the dorsum of the hands and feet, and palmoplantar pits and pigmentation. It is autosomal dominant, as is DSH.

DUH shows hypo- and hyper-pigmented macules that are similar to those of DSH on the trunk as well as the extremities. It has been reported to be autosomal dominant and autosomal recessive.

It had been thought that those two diseases were related to DSH. However, when mutation of the *ADAR1* gene was identified as causing DSH, it was clarified that the two diseases are genetically distinct from DSH, because patients with ARK and DUH do not have that mutation [9].

Mild cases or the early stages of child DSH are sometimes difficult to differentiate from xeroderma pigmentosum (XP) [24]. In such cases, the diagnosis of XP can usually be obtained by following up on skin lesions such as xerosis, atrophy, telangiectasia and skin tumors of sun-exposed areas as they grow up, photosensitivity test, and ultimately gene analysis [24, 25].

2.2. Histopathology of DSH

Histological studies have showed increased melanin pigmentation in the basal layer of hyperpigmented lesions, along with pigmentary incontinence and largely absent melanin in the hypopigmented macule [13, 23].

According to precise histochemical studies, Masson-Fontana stain reveals a remarkable decrease or total absence of melanin in the hypochromic-achromic epidermis [13, 23]. Split-dopa preparations were reported to show an obvious decrease in melanocyte number in the hypomelanotic area (45-167 cells/mm²) and the surrounding pigmented skin (119-204 cells/mm²), as compared with the 16 normal control persons (1,217+/-282 cells/mm² on the dorsal hands and 821-1,154 cells/mm² on the dorsal feet) [13]. There was an increase in melanocyte size but not number in the hyperchromic area, and the dendrites were very elongated and numerous, suggesting that melanosome transfer from melanocytes to keratinocytes was active [13]. Another study also indicated a lower density of dopa-positive melanocytes in the hypo-pigmented macules of DSH patients than in normal skin at same site from normal pigmented controls [26]. Electron microscopy showed melanocytic abnormalities in the hypomelanotic skin, i.e., a numerical decrease, fatty degeneration, swollen mitochondria, vacuolization of the cytoplasm, large cytoplasmic vacuole formation and condensed irregularly shaped nuclei [13, 23]. The keratinocytes located in the vicinity of the melanocytes contained few melanosomes. In some keratinocytes, the melanosome complex containing more than 15 melanosomes were recognized [13]. The hyperpigmented area showed a lot of slight larger melanosomes in the melanocytes, and the adjacent keratinocytes showed many singly dispersed melanosomes [13]. The aggregated melanosomes were also found in the keratinocyte in hyperpigmented macules [23]. In the hyperpigmented macules, the number of melanosomes in the melanocytes was somewhat smaller than in adjacent keratinocytes, which suggests that the melanosome transfer from melanocytes to keratinocytes is more active than melanosome production in the melanocyte [23].

2.3. Identifying the causative gene of DSH

In 2003, Miyamura et al. determined that a heterozygous mutation of the adenosine deaminase acting on RNA1 gene (*ADAR1*) caused DSH [1]. As there was no clue to predict

the pathogenesis of DSH at that time, they used a technique called positional cloning to identify the causative gene. Positional cloning locates the position of a disease-associated gene along the chromosome by a collection of methods including linkage analysis, haplotype analysis, genomic mapping and sequencing. This approach works even when little or no information is available about the biochemical basis of the disease.

In identifying the causative gene of DSH [1], whole-genome-wide scan (linkage analysis) using 343 microsatellite markers in three pedigrees of DSH (88 people, including 41 patients) was done at first. The results of linkage analysis indicated that the DSH locus was on the long arm of chromosome 1. Next, to narrow the interval of the region containing the DSH locus, haplotype analysis was carried out, and the results suggested that the DSH gene lay between two microsatellite markers, D1S2715 and D1S2777. Haplotype analysis using novel single-nucleotide polymorphisms showed a final DSH genetic interval of approximately 500 kbp. There were 9 genes in this interval, including the *ADAR1* gene. Finally, it was clarified that all of the patients with DSH had mutations in the *ADAR1* gene. Thus it was concluded that the *ADAR1* gene was the causative gene of DSH [1].

The *ADAR1* protein catalyzes the deamination of adenosine to inosine in double-stranded RNA [2, 3]. *ADAR1* is in the *ADAR* protein family, which includes *ADAR1* [6], *ADAR2* [27] and *ADAR3* [28]. As RNA editing enzymes, all *ADAR* family members contain several double-stranded RNA-binding domains (dsRBDs) and a conserved catalytic deaminase domain in the C-terminal region [29]. Differences in the number and spacing of the dsRBDs, nuclear localization signals and the presence of additional domains create the variants (Figure 2A).

The *ADAR1* gene spans 30 kbp and contains 15 exons. The encoded 1226 amino acid protein includes three dsRBDs and one dsRNA adenosine deaminase catalytic domain [30].

ADAR1 has two isoforms of different sizes: interferon-inducible *ADAR1*-p150 (150kDa) and constitutively expressed *ADAR1*-p110 (110kDa) (Figure 2B) [30]. Both contain three dsRBDs, but they differ in that the p150 variant contains two Z-DNA binding domains and a nuclear export signal, whereas the p110 variant contains only a single Z-DNA binding domain and no export signal. Consequently, *ADAR1*-p110 localizes mainly to the nucleus, whereas *ADAR1*-p150 is found in both the cytoplasm and the nucleus. Resulting from alternative promoters, the two variants may play different cellular roles. Although the *ADAR1*-p110 promoter is constitutively active, the *ADAR1*-p150 promoter is interferon-inducible, suggesting a role in response to cellular stresses such as viral infection [31].

ADAR1 catalyzes the deamination of adenosine to inosine in double-stranded RNA substrates in the step of post-transcription processing [2] (Figure 3). Inosine acts as guanine during translation, which results in codon alterations or alternative splicing sites [32] and thus leads to functional changes in proteins. It is expressed ubiquitously, including in the skin [29], but only a few known target genes for *ADAR1* are expressed in specific tissues, including ionotropic glutamate receptor [33] [34] and the serotonin receptor 2C subtype in the brain [5], and hepatitis δ virus antigen in the liver [35]. Fifteen sites of amino acid substitution by A-I editing have been identified to date [36]. The substrate gene edited by

ADAR1 in the skin is still unknown, and it remains to clarify how ADAR1 causes DSH. The structure and function of ADAR1 are detailed later.

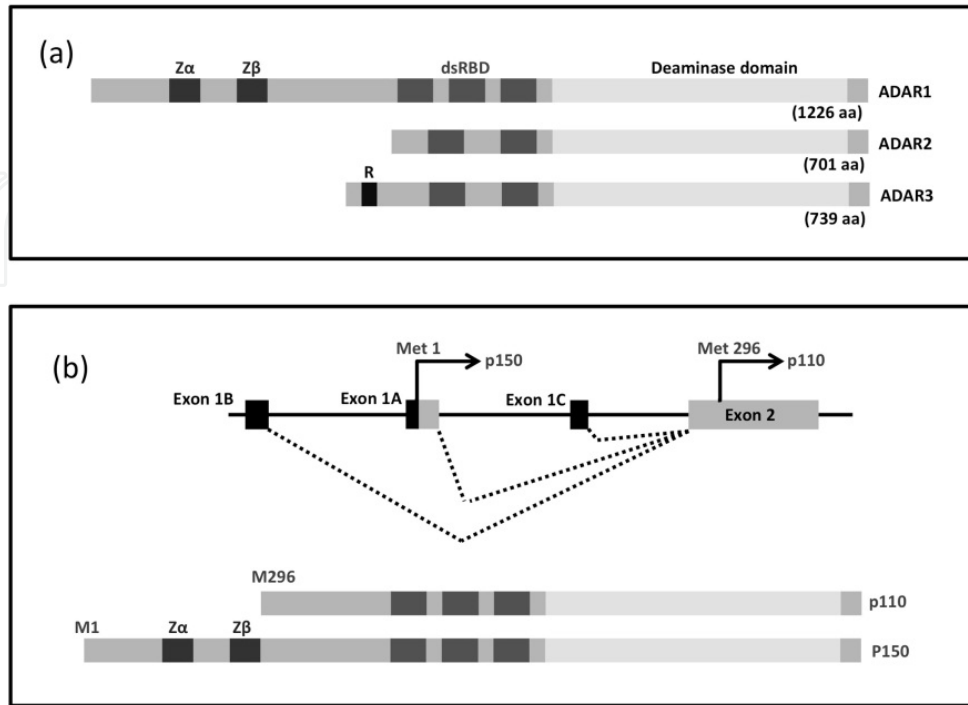


Figure 2. The human ADAR gene family. (a) The structure of the human ADAR gene family: ADAR1, ADAR2 and ADAR3. The dsRNA binding domains (dsRBDs) and the deaminase domain exist in all three ADARs. Two Z-DNA binding domains ($Z\alpha$ and $Z\beta$) exist in ADAR1. ADAR3 includes an arginine-rich domain (the R-domain) and an ssRNA binding domain, but the function of those two domains is still unknown. (b) Two isoforms of ADAR1. Exon 1A, exon 1B and exon1C are spliced to exon 2 at precisely the same junction. Exon1A contains the Met initiation codon for the p150 isoform (1226 aa) and follows the interferon-inducible promoter. Exon 1B and exon1C do not contain an AUG initiation codon. Those exons follow a constitutive promoter. The second AUG at 296aa from the first AUG located in exon 2 initiates translation of the other isoform, p110, which is constitutively expressed.

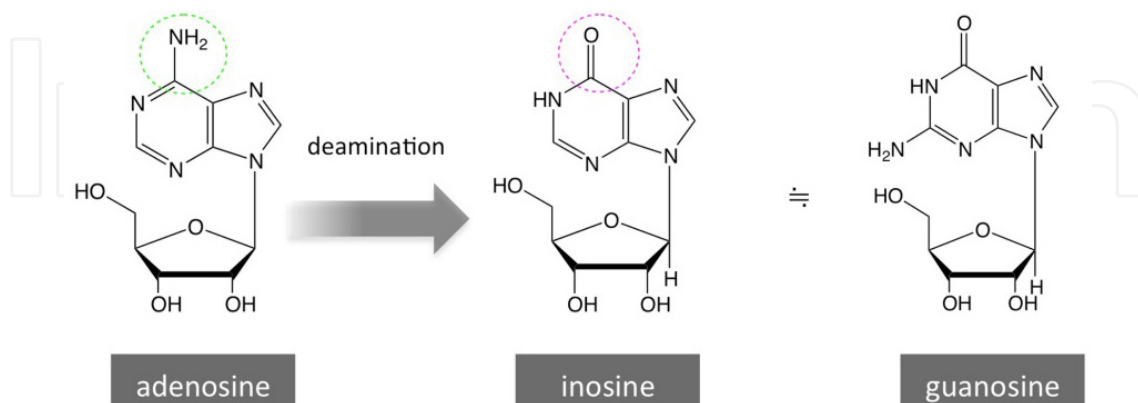


Figure 3. Adenosine deamination by ADARs. ADARs convert adenosines to inosines of double-stranded RNA by catalyzing a hydrolytic deamination at C6 of the adenine base. This modification is called RNA editing, more specifically, A-I editing. Inosine is recognized as guanosine at translation, and this editing produces codon change. Also, it creates alternative splice sites. These both lead to different proteins in the target substrate. Recently a lot of non-coding RNA has also been found to be substrates of ADARs.

2.4. Gene analysis of the *ADAR1* in DSH patients

Since identification of the *ADAR1* gene, more than 115 mutations in the gene have been reported in patients with DSH [37]. The distribution of mutations shows no hotspots, with the mutations distributed equally in coding regions. Every type of mutation—nonsense, missense, insertion, deletion and splice-site—has been identified in the gene. No founder effect has been recognized [9]. Major part of mutations have been identified in Japanese and Chinese, and some reports show mutations in *ADAR1* for DSH patients of other races. Characteristically, all the missense mutations are in the adenosine deaminase catalytic domain. Thus it is thought that this domain is a very critical one. Functional analysis of the adenosine deaminase catalytic domain has indicated different mutant *ADAR1* enzymes in which the missense mutation on the deaminase domain has caused complete abolishment of the deaminase activity, though there were some exceptions [38]. Notably, mutations that leave some enzyme activity intact are not found in DSH patients. The result of this experiment does not mean that DSH patient loses *ADAR1* activity completely because DSH is autosomal dominant and half of *ADAR1* protein are intact.

The two mutations p.Q102fs and p.H216fs [9, 39] that were found in the *ADAR1* gene of DSH patients were previously reported, and they are on the 5' side upstream of codon 296 in exon 2, which is the translation initiation codon for h*ADAR1*-p110 (Fig. 2B). Therefore, it is possible that they cause a frameshift change in the synthesis of h*ADAR1*-p150 but have no influence on that of *ADAR1*-p110. This suggests that only the p150 protein and the interferon-inducible (IFN) mechanism are responsible for the etiology of DSH.

2.5. Homodimerization of *ADAR1*

Homodimerization was demonstrated to be essential for the enzyme activity of *ADAR1* [40]. Having one monomer defective for the deaminase domain (E396A) halves the dimer function. Taken together, these data indicate that a deaminase mutant chimeric dimer (E396A/WT) is able to bind dsRNA but that only one functional active site is formed and the result is, therefore, only partial activity [40]. This result may indicate that *ADAR1* mutation in the deaminase domain generates haploinsufficiency. However, site-selective RNA editing activity of 5HT_{2c}R RNA by heterodimer was found to be decreased to 30% [40]. These results may indicate a complex effect at each site by this enzyme.

In contrast, the A-I editing activity of the dsRNA binding mutant chimeric dimer (Mut/WT) is completely lost [41]. This is because of the defective dsRBDs of one monomer, and it suggests that cooperative interactions of functional dsRBDs in both *ADAR* dimer subunits are required for dsRNA binding. When one monomer in the dimer complex is unable to bind the dsRNA, then the dimer complex is excluded from binding the substrate. It shows activity. As previously indicated, in DSH patients, a disproportionately high number of mutations are identified in the deaminase domain relative to the dsRBDs of *ADAR1*. It may be that mutations identified in the deaminase domain are less severe, because the chimeric dimers that are expected to form still retain some editing activity [41].

The likely ratio of monomer subunits in a dimer is 1:2:1 for (WT/WT), (Mut/WT) and (Mut/Mut), suggesting that a heterozygous deaminase mutation would not have as strong an effect due to the dimer's ability to maintain partial activity. In contrast, mutations are rarely found in the dsRBDs, because these alterations would have a more dominant effect when paired with a wild-type partner, thus greatly reducing ADAR function. Under this assumption, the reduced activity for ADAR could be as low as one-quarter with only (WT/WT) dimers having editing activity, and this may be below a threshold for survival and may possibly be selected out naturally during development. ADAR dimerization can be a potential source of modulation for RNA editing activity, and these ADAR (EAA) mutants may prove interesting for future studies *in vivo* [41]. So, DSH can be regarded as being induced by haploinsufficiency of ADAR1. Three DSH cases with neurological complications have been reported [16, 21, 42]. Two of these cases were confirmed by gene analysis [21, 42], and the *ADAR1* gene mutation that they have is common and is thought to show a dominant negative effect. The next section describes those cases.

2.6. Neurological complications

In 1994, Patrizi *et al.* reported a 9-year-old Caucasian girl who developed DSH at the age of 2 years and torsion dystonia at the age of 7 years [16]. Her clinical symptoms were very similar to the latter 2 cases, but mental deterioration and brain calcification were not described in their report [16]. The causative gene of DSH had not been clarified, and no information on *ADAR1* gene analysis of the patient was reported.

Tojo *et al.* reported a 27-year-old Japanese woman who had dystonia, mental deterioration, brain calcification and DSH with a p.G1007R mutation of the *ADAR* gene [42]. Kondo *et al.* reported an 11-year-old Japanese boy who also had mental deterioration, brain calcification and dystonia and DSH with a p.G1007R mutation of the *ADAR* gene [21]. It is noteworthy that the two patients had the same *ADAR1* mutation, p.G1007R, and it suggests that this mutation probably influences the development of neurological symptoms [21].

On the basis of the known crystal structure [43], it was predicted that ADAR1 G1007R would introduce an additional positively charged arginine residue on the RNA-binding face of the deaminase domain very close to the active site [44]. In fact, the ADAR1 G1007R mutant has efficient RNA-binding ability, similar in level to that of wild-type ADAR1, but it does not edit dsRNA; however, other mutant ADAR1 partially edit. So, the dominant negative effect gives these additional neurological symptoms of DSH [44, 45].

The ionotropic glutamate receptor [33, 34] is a known target gene for ADAR1. Glutamate receptors are expressed at high levels in the brain, including in the basal ganglia [46], and glutamatergic overactivity has been suggested to contribute to the occurrence of dystonia [47, 48]. ADAR1 catalyzes RNA editing at the Q/R sites of the glutamate receptor subunits GluR5 and GluR6, and reduces the Ca²⁺ permeability of glutamate receptors [49]. Therefore, mutation in *ADAR1* could reduce the efficiency of RNA editing at the Q/R sites of GluR5 and GluR6, inducing glutamatergic overactivity.

Furthermore, increased Ca^{2+} influx through glutamate receptors is known to be toxic to neurons, and that toxicity may induce various neurological abnormalities [50]. Increases in intracellular Ca^{2+} levels have also been reported to be the underlying mechanism of tissue calcification [51]. Therefore, mutations in *ADAR1* could conceivably cause neurological dysfunction, such as dystonia and mental deterioration, by means of brain calcification [51], but only the p.G1007R mutation has so far been suggested to be related to such symptoms, and the pathomechanism remains unknown.

The patient's mother had the same mutation in p.G1007R as her son, but she showed no neurological problems, which suggests that some unknown mechanism is involved in the development of dystonia, mental deterioration and brain calcification [52]. It will be necessary to observe whether she develops neurological symptoms later. This mechanism, as well as the unknown molecular pathogenesis of the skin lesion, should be clarified.

2.7. More ADAR functions than A-I editing of the coding region of mRNA

Only a few sites of A-I editing by *ADAR1* had been found in the coding region. Recently it was reported that 85% of all the transcripts are edited by A-I editing [53], and A-I editing regulated gene expression much more than had been thought.

New A-I editing sites have been found by next-generation sequencing [54]. Also, *ADAR1* is now known to frequently target 5' and 3' untranslated regions (UTRs) and intronic retrotransposon elements, such as Alu and long interspersed elements (LINE/SINEs). Further, several primary microRNA (miRNA) intermediates undergo A-I editing [55-58]. 99% of the identified A-I editing sites are in non-coding RNA [53]. It was reported that *ADARs* regulate the expression of microRNA and redirect silencing targets by A-I editing of miRNA [55, 57, 58]. There is extensive interaction between the RNA editing and RNA interference (RNAi) pathways [59]. However, the overview of physiologic significance of non-coding RNA editing still remains to be clarified, including whether those non-coding RNA editing is involved in the pathogenesis of DSH.

Additionally, in these miRNA/siRNA pathways, an editing-independent effect of inhibition of RNAi by *ADARs* was reported [44].

2.8. DSH murine models

Wang et al. generated an *Adar1* knockout (KO) murine model [60] that lacks exons 12-15, corresponding to the catalytic RNA-editing domain. Hartner et al. [61] created a KO mouse that has the homozygous deletion of exons 7-9 or exons 2-13.

In the *Adar*^{-/-} mouse with homozygous deletion exons 7-9 or exons 2-13, the liver sizes in fatal mice were the same as in wild-type mice until E11.0 - 11.25, and they did not increase further, whereas wild-type and *Adar*^{+/-} embryo livers enlarged by up to 50% between E11.5 and 12.5 [61]. Reduced cell density and blood accumulation were observed by microscopy in *Adar*^{-/-} fatal livers, perhaps resulting from massive cell death. Embryonic hematopoietic

tissues were significantly reduced in the yolk sac, fetal liver and peripheral blood compared with wild-type and *Adar*^{+/-} embryos. There were no morphological abnormalities in other tissues [61].

In KO mice with the homozygous deletions of exons 12-15, widespread apoptosis was detected in many tissues of the *Adar*^{-/-} mouse embryos collected live from E10.5 to E11.5, particularly in the heart, liver and vertebra, despite their normal gross appearance [60]. Fibroblasts derived from *Adar*^{-/-} embryos were also prone to apoptosis induced by serum deprivation. Those results demonstrated that ADAR1 is essential to embryogenesis and suggested that it functions to promote the survival of numerous tissues by editing one or more double-stranded RNAs required for protection against stress-induced apoptosis [60]].

KO mice with different mutant alleles showed the same result of fatal lethality at E11.5–12.5 [60, 61].

Interestingly nonsense mutations that encode proteins similar to those in the knockout mice have been reported in DSH patients, such as R328X [10] or Y989X [62]. Notably, DSH patients are heterozygous for the *ADAR1* gene mutation that is inherited as a dominant trait. Unlike DSH patients, the *Adar*^{+/-} mouse, which is heterozygous for *Adar1* deletion, does not manifest any clinical abnormalities of the skin, including the face or dorsal sites of the extremities, which are the most noticeable sites of DSH in humans [60, 61]. The effect of ADAR1 gene mutation on skin might be milder in heterozygous mice than in heterozygous humans.

The previously described KO mice had disruptions of both the p110 and p150 isoforms [60, 61]. To circumvent the embryonic lethality associated with simultaneous disruption of p110 and p150, a selective p150-isoform-disrupted mouse was generated in which the promoter and exon 1A region of the p150 isoform of *Adar1* were specifically targeted, while the expression of p110 was left intact [63]. Selective disruption of p150 alone resulted in embryonic lethality from E11-E12 [63], similar to the time point of embryonic lethality seen previously with disruption of p110 and p150 [60, 61]. These results indicate that the p150 isoform of ADAR1 plays a critically important role in embryogenesis. Furthermore, they raise the possibility that the embryonic lethality seen in the previously described *Adar1* gene disruptions may have resulted primarily from ablation of p150 expression. This p150-isoform-specific heterozygous KO mouse shows no skin manifestations clinically [63].

To investigate in more depth the role of ADAR1 in skin, an epidermis-specific *Adar1* knockout murine model was established [64]. In this model, *Adar1* gene deletion was induced by tamoxifen exposure. First we administrated tamoxifen orally to ten K14-*Adar1* mice (FVB background) at the age of 6 weeks old for 5 consecutive days. Eight of these treated mice died within three weeks after treatment, developing a phenotype that included dramatically decreased aggressiveness, thin body shape, fur loss, poor skin resiliency, skin rash and bleeding [64]. In the FVB mice, H–E stained sections revealed massive necrosis in the epidermis and few remaining hair follicles in the dermis. Thickening of the interfollicular epidermis (IFE) and the stratum corneum were observed, while skin ulcers

were observed in some other areas [64]. In the B6 mice, epidermal necrosis was not observed but increased keratinocytes and thickened stratum corneum were evident. p150-specific Adar1-deleted newborn B6 mouse showed death in a subset of the hair follicles. These results support an essential role for ADAR1 in the epidermis during the first hair follicle developmental cycle [64].

3. Conclusion

The RNA editing mechanism has been gaining much attention. A-I editing has been shown to affect a wide variety of RNA transcripts, both protein coding and noncoding sequences. Its relationship with some neurological diseases, e.g., amyotrophic lateral sclerosis [50, 65-67], epilepsy [68], depression [69] and schizophrenia [70], has been clarified. In the skin, although the expression of ADAR1 is recognized, its function remains unknown. Various functions of ADAR have been successively clarified. In DSH patients, if a new function of ADAR1 or a new target gene of ADAR1 were to be identified, it would not only help to elucidate the pathogenesis of DSH, but also be one step toward clarifying RNA editing in the skin. For dermatologists, it is also very interesting how this characteristic skin manifestation, a mixture of pigmented and depigmented macules with a unique distribution of eruptions in the extremities, develops.

Author details

Michihiro Kono and Masashi Akiyama

Department of Dermatology, Nagoya University Graduate School of Medicine, Nagoya, Japan

4. References

- [1] Miyamura Y, Suzuki T, Kono M, Inagaki K, Ito S, Suzuki N, et al. Mutations of the RNA-specific adenosine deaminase gene (DSRAD) are involved in dyschromatosis symmetrica hereditaria. *Am J Hum Genet.* 2003 Sep;73(3):693-9.
- [2] Bass BL, Weintraub H. An unwinding activity that covalently modifies its double-stranded RNA substrate. *Cell.* 1988 Dec 23;55(6):1089-98.
- [3] Wagner RW, Smith JE, Cooperman BS, Nishikura K. A double-stranded RNA unwinding activity introduces structural alterations by means of adenosine to inosine conversions in mammalian cells and *Xenopus* eggs. *Proc Natl Acad Sci U S A.* 1989 Apr;86(8):2647-51.
- [4] Sommer B, Kohler M, Sprengel R, Seeburg PH. RNA editing in brain controls a determinant of ion flow in glutamate-gated channels. *Cell.* 1991 Oct 4;67(1):11-9.
- [5] Burns CM, Chu H, Rueter SM, Hutchinson LK, Canton H, Sanders-Bush E, et al. Regulation of serotonin-2C receptor G-protein coupling by RNA editing. *Nature.* 1997 May 15;387(6630):303-8.
- [6] Nishikura K. Functions and regulation of RNA editing by ADAR deaminases. *Annu Rev Biochem.* 2010;79:321-49.

- [7] Toyama I. An unknown disorder of hyperpigmentation (in Japanese). *Jpn J Dermatol Urol.* 1910;10:644.
- [8] Toyama I. Dyschromatosis symmetrica hereditaria (in Japanese). *Jpn J Dermatol Urol.* 1929;29:95–6.
- [9] Suzuki N, Suzuki T, Inagaki K, Ito S, Kono M, Fukai K, et al. Mutation analysis of the ADAR1 gene in dyschromatosis symmetrica hereditaria and genetic differentiation from both dyschromatosis universalis hereditaria and acropigmentatio reticularis. *J Invest Dermatol.* 2005 Jun;124(6):1186-92.
- [10] Hou Y, Chen J, Gao M, Zhou F, Du W, Shen Y, et al. Five novel mutations of RNA-specific adenosine deaminase gene with dyschromatosis symmetrica hereditaria. *Acta Derm Venereol.* 2007;87(1):18-21.
- [11] Kantaputra PN, Chinadet W, Ohazama A, Kono M. Dyschromatosis symmetrica hereditaria with long hair on the forearms, hypo/hyperpigmented hair, and dental anomalies: Report of a novel ADAR1 mutation. *Am J Med Genet A.* 2012 Sep;158A(9):2258-65.
- [12] Kim NI, Park SA, Youn JI. Dyschromatosis symmetrica hereditaria affecting two families. *Korean J Dermatol.* 1980;18:585-9.
- [13] Sheu HM, Yu HS. Dyschromatosis symmetrica hereditaria--a histochemical and ultrastructural study. *Taiwan Yi Xue Hui Za Zhi.* 1985 Feb;84(2):238-49.
- [14] Dhar S, Malakar S. Acropigmentation of Dohi in a 12-year-old boy. *Pediatr Dermatol.* 1998 May-Jun;15(3):242.
- [15] Bilen N, Akturk AS, Kawaguchi M, Salman S, Ercin C, Hozumi Y, et al. Dyschromatosis symmetrica hereditaria: A case report from Turkey, a new association and a novel gene mutation. *J Dermatol.* 2012 Oct;39(10):857-8.
- [16] Patrizi A, Manneschi V, Pini A, Baioni E, Ghetti P. Dyschromatosis symmetrica hereditaria associated with idiopathic torsion dystonia. A case report. *Acta Derm Venereol.* 1994 Mar;74(2):135-7.
- [17] Ostlere LS, Ratnavel RC, Lawlor F, Black MM, Griffiths WA. Reticulate acropigmentation of Dohi. *Clin Exp Dermatol.* 1995 Nov;20(6):477-9.
- [18] Kono M, Akiyama M, Sukanuma M, Tomita Y. Dyschromatosis symmetrica hereditaria by ADAR1 mutations and viral encephalitis: a hidden link? *International Journal of Dermatology.* in press.
- [19] Tomita Y, Suzuki T. Genetics of pigmentary disorders. *Am J Med Genet C Semin Med Genet.* 2004 Nov 15;131C(1):75-81.
- [20] Oyama M, Shimizu H, Ohata Y, Tajima S, Nishikawa T. Dyschromatosis symmetrica hereditaria (reticulate acropigmentation of Dohi): report of a Japanese family with the condition and a literature review of 185 cases. *Br J Dermatol.* 1999 Mar;140(3):491-6.
- [21] Kondo T, Suzuki T, Ito S, Kono M, Negoro T, Tomita Y. Dyschromatosis symmetrica hereditaria associated with neurological disorders. *J Dermatol.* 2008 Oct;35(10):662-6.
- [22] Liu Q, Jiang L, Liu WL, Kang XJ, Ao Y, Sun M, et al. Two novel mutations and evidence for haploinsufficiency of the ADAR gene in dyschromatosis symmetrica hereditaria. *Br J Dermatol.* 2006 Apr;154(4):636-42.

- [23] Kondo T, Suzuki T, Mitsushashi Y, Ito S, Kono M, Komine M, et al. Six novel mutations of the ADAR1 gene in patients with dyschromatosis symmetrica hereditaria: histological observation and comparison of genotypes and clinical phenotypes. *J Dermatol*. 2008 Jul;35(7):395-406.
- [24] Nishigori C, Miyachi Y, Takebe H, Imamura S. A case of xeroderma pigmentosum with clinical appearance of dyschromatosis symmetrica hereditaria. *Pediatr Dermatol*. 1986 Nov;3(5):410-3.
- [25] Satoh Y, Yoshida M. Clinical and photobiological differences between dyschromatosis symmetrica hereditaria and xeroderma pigmentosum. *J Dermatol*. 1980 Oct;7(5):317-22.
- [26] Hata S, Yokomi I. Density of dopa-positive melanocytes in dyschromatosis symmetrica hereditaria. *Dermatologica*. 1985;171(1):27-9.
- [27] Melcher T, Maas S, Herb A, Sprengel R, Seeburg PH, Higuchi M. A mammalian RNA editing enzyme. *Nature*. 1996 Feb 1;379(6564):460-4.
- [28] Chen CX, Cho DS, Wang Q, Lai F, Carter KC, Nishikura K. A third member of the RNA-specific adenosine deaminase gene family, ADAR3, contains both single- and double-stranded RNA binding domains. *Rna*. 2000 May;6(5):755-67.
- [29] Kim U, Wang Y, Sanford T, Zeng Y, Nishikura K. Molecular cloning of cDNA for double-stranded RNA adenosine deaminase, a candidate enzyme for nuclear RNA editing. *Proc Natl Acad Sci U S A*. 1994 Nov 22;91(24):11457-61.
- [30] Patterson JB, Samuel CE. Expression and regulation by interferon of a double-stranded-RNA-specific adenosine deaminase from human cells: evidence for two forms of the deaminase. *Mol Cell Biol*. 1995 Oct;15(10):5376-88.
- [31] Patterson JB, Thomis DC, Hans SL, Samuel CE. Mechanism of interferon action: double-stranded RNA-specific adenosine deaminase from human cells is inducible by alpha and gamma interferons. *Virology*. 1995 Jul 10;210(2):508-11.
- [32] Rueter SM, Dawson TR, Emeson RB. Regulation of alternative splicing by RNA editing. *Nature*. 1999 May 6;399(6731):75-80.
- [33] Higuchi M, Single FN, Kohler M, Sommer B, Sprengel R, Seeburg PH. RNA editing of AMPA receptor subunit GluR-B: a base-paired intron-exon structure determines position and efficiency. *Cell*. 1993 Dec 31;75(7):1361-70.
- [34] Lomeli H, Mosbacher J, Melcher T, Hoyer T, Geiger JR, Kuner T, et al. Control of kinetic properties of AMPA receptor channels by nuclear RNA editing. *Science*. 1994 Dec 9;266(5191):1709-13.
- [35] Polson AG, Bass BL, Casey JL. RNA editing of hepatitis delta virus antigenome by dsRNA-adenosine deaminase. *Nature*. 1996 Apr 4;380(6573):454-6.
- [36] Li JB, Levanon EY, Yoon JK, Aach J, Xie B, Leproust E, et al. Genome-wide identification of human RNA editing sites by parallel DNA capturing and sequencing. *Science*. 2009 May 29;324(5931):1210-3.
- [37] Kono M, Akiyama M, Kondo T, Suzuki T, Suganuma M, Wataya-Kaneda M, et al. Four novel ADAR1 gene mutations in patients with dyschromatosis symmetrica hereditaria. *J Dermatol*. 2012;39(9):819-21.

- [38] Lai F, Drakas R, Nishikura K. Mutagenic analysis of double-stranded RNA adenosine deaminase, a candidate enzyme for RNA editing of glutamate-gated ion channel transcripts. *J Biol Chem*. 1995 Jul 21;270(29):17098-105.
- [39] Suzuki N, Suzuki T, Inagaki K, Ito S, Kono M, Horikawa T, et al. Ten novel mutations of the ADAR1 gene in Japanese patients with dyschromatosis symmetrica hereditaria. *J Invest Dermatol*. 2007 Feb;127(2):309-11.
- [40] Cho DS, Yang W, Lee JT, Shiekhattar R, Murray JM, Nishikura K. Requirement of dimerization for RNA editing activity of adenosine deaminases acting on RNA. *J Biol Chem*. 2003 May 9;278(19):17093-102.
- [41] Valente L, Nishikura K. RNA binding-independent dimerization of adenosine deaminases acting on RNA and dominant negative effects of nonfunctional subunits on dimer functions. *J Biol Chem*. 2007 Jun 1;282(22):16054-61.
- [42] Tojo K, Sekijima Y, Suzuki T, Suzuki N, Tomita Y, Yoshida K, et al. Dystonia, mental deterioration, and dyschromatosis symmetrica hereditaria in a family with ADAR1 mutation. *Mov Disord*. 2006 Sep;21(9):1510-3.
- [43] Macbeth MR, Schubert HL, Vandemark AP, Lingam AT, Hill CP, Bass BL. Inositol hexakisphosphate is bound in the ADAR2 core and required for RNA editing. *Science*. 2005 Sep 2;309(5740):1534-9.
- [44] Heale BS, Keegan LP, McGurk L, Michlewski G, Brindle J, Stanton CM, et al. Editing independent effects of ADARs on the miRNA/siRNA pathways. *Embo J*. 2009 Oct 21;28(20):3145-56.
- [45] Heale BS, Keegan LP, O'Connell MA. ADARs have effects beyond RNA editing. *Cell Cycle*. 2009 Dec 15;8(24):4011-2.
- [46] Bischoff S, Barhanin J, Bettler B, Mülle C, Heinemann S. Spatial distribution of kainate receptor subunit mRNA in the mouse basal ganglia and ventral mesencephalon. *J Comp Neurol*. 1997 Mar 24;379(4):541-62.
- [47] Nobrega JN, Raymond R, Barlow K, Hamann M, Richter A. Changes in AMPA receptor binding in an animal model of inborn paroxysmal dystonia. *Exp Neurol*. 2002 Aug;176(2):371-6.
- [48] Richter A, Loscher W, Loschmann PA. The AMPA receptor antagonist NBQX exerts antidystonic effects in an animal model of idiopathic dystonia. *Eur J Pharmacol*. 1993 Feb 9;231(2):287-91.
- [49] Wang Q, Khillan J, Gadue P, Nishikura K. Requirement of the RNA editing deaminase ADAR1 gene for embryonic erythropoiesis. *Science*. 2000 Dec 1;290(5497):1765-8.
- [50] Kwak S, Kawahara Y. Deficient RNA editing of GluR2 and neuronal death in amyotrophic lateral sclerosis. *J Mol Med (Berl)*. 2005 Feb;83(2):110-20.
- [51] Kim KM, Herrera GA, Battarbee HD. Role of glutaraldehyde in calcification of porcine aortic valve fibroblasts. *Am J Pathol*. 1999 Mar;154(3):843-52.
- [52] Manyam BV, Walters AS, Narla KR. Bilateral striopallidodentate calcinosis: clinical characteristics of patients seen in a registry. *Mov Disord*. 2001 Mar;16(2):258-64.
- [53] Athanasiadis A, Rich A, Maas S. Widespread A-to-I RNA editing of Alu-containing mRNAs in the human transcriptome. *PLoS Biol*. 2004 Dec;2(12):e391.

- [54] Eggington JM, Greene T, Bass BL. Predicting sites of ADAR editing in double-stranded RNA. *Nat Commun.* 2011;2:319.
- [55] Yang W, Chendrimada TP, Wang Q, Higuchi M, Seeburg PH, Shiekhatter R, et al. Modulation of microRNA processing and expression through RNA editing by ADAR deaminases. *Nat Struct Mol Biol.* 2006 Jan;13(1):13-21.
- [56] Kawahara Y, Nishikura K. Extensive adenosine-to-inosine editing detected in Alu repeats of antisense RNAs reveals scarcity of sense-antisense duplex formation. *FEBS Lett.* 2006 Apr 17;580(9):2301-5.
- [57] Kawahara Y, Zinshteyn B, Sethupathy P, Iizasa H, Hatzigeorgiou AG, Nishikura K. Redirection of silencing targets by adenosine-to-inosine editing of miRNAs. *Science.* 2007 Feb 23;315(5815):1137-40.
- [58] Kawahara Y, Zinshteyn B, Chendrimada TP, Shiekhatter R, Nishikura K. RNA editing of the microRNA-151 precursor blocks cleavage by the Dicer-TRBP complex. *EMBO Rep.* 2007 Aug;8(8):763-9.
- [59] Nishikura K. Editor meets silencer: crosstalk between RNA editing and RNA interference. *Nat Rev Mol Cell Biol.* 2006 Dec;7(12):919-31.
- [60] Wang Q, Miyakoda M, Yang W, Khillan J, Stachura DL, Weiss MJ, et al. Stress-induced apoptosis associated with null mutation of ADAR1 RNA editing deaminase gene. *J Biol Chem.* 2004 Feb 6;279(6):4952-61.
- [61] Hartner JC, Schmittwolf C, Kispert A, Muller AM, Higuchi M, Seeburg PH. Liver disintegration in the mouse embryo caused by deficiency in the RNA-editing enzyme ADAR1. *J Biol Chem.* 2004 Feb 6;279(6):4894-902.
- [62] Murata I, Hozumi Y, Kawaguchi M, Katagiri Y, Yasumoto S, Kubo Y, et al. Four novel mutations of the ADAR1 gene in dyschromatosis symmetrica hereditaria. *J Dermatol Sci.* 2009 Jan;53(1):76-7.
- [63] Ward SV, George CX, Welch MJ, Liou LY, Hahm B, Lewicki H, et al. RNA editing enzyme adenosine deaminase is a restriction factor for controlling measles virus replication that also is required for embryogenesis. *Proc Natl Acad Sci U S A.* 2011 Jan 4;108(1):331-6.
- [64] Sharma R, Wang Y, Zhou P, Steinman RA, Wang Q. An essential role of RNA editing enzyme ADAR1 in mouse skin. *J Dermatol Sci.* 2011 Oct;64(1):70-2.
- [65] Kawahara Y, Kwak S, Sun H, Ito K, Hashida H, Aizawa H, et al. Human spinal motoneurons express low relative abundance of GluR2 mRNA: an implication for excitotoxicity in ALS. *J Neurochem.* 2003 May;85(3):680-9.
- [66] Kawahara Y, Ito K, Sun H, Aizawa H, Kanazawa I, Kwak S. Glutamate receptors: RNA editing and death of motor neurons. *Nature.* 2004 Feb 26;427(6977):801.
- [67] Kawahara Y, Kwak S. Excitotoxicity and ALS: what is unique about the AMPA receptors expressed on spinal motor neurons? *Amyotroph Lateral Scler Other Motor Neuron Disord.* 2005 Sep;6(3):131-44.
- [68] Delorenzo RJ, Sun DA, Deshpande LS. Cellular mechanisms underlying acquired epilepsy: the calcium hypothesis of the induction and maintenance of epilepsy. *Pharmacol Ther.* 2005 Mar;105(3):229-66.

- [69] Iwamoto K, Nakatani N, Bundo M, Yoshikawa T, Kato T. Altered RNA editing of serotonin 2C receptor in a rat model of depression. *Neurosci Res.* 2005 Sep;53(1):69-76.
- [70] Dracheva S, Elhakem SL, Marcus SM, Siever LJ, McGurk SR, Haroutunian V. RNA editing and alternative splicing of human serotonin 2C receptor in schizophrenia. *J Neurochem.* 2003 Dec;87(6):1402-12.

IntechOpen

IntechOpen