

We are IntechOpen, the world's leading publisher of Open Access books Built by scientists, for scientists

4,800

Open access books available

122,000

International authors and editors

135M

Downloads

Our authors are among the

154

Countries delivered to

TOP 1%

most cited scientists

12.2%

Contributors from top 500 universities



WEB OF SCIENCE™

Selection of our books indexed in the Book Citation Index
in Web of Science™ Core Collection (BKCI)

Interested in publishing with us?
Contact book.department@intechopen.com

Numbers displayed above are based on latest data collected.

For more information visit www.intechopen.com



Maffucci Syndrome

Miki Tanioka

Additional information is available at the end of the chapter

<http://dx.doi.org/10.5772/54570>

1. Introduction

Maffucci syndrome is characterized by the presence of multiple enchondromas associated with multiple hemangiomas (figure 1). Enchondromas are common benign cartilage tumors of bone. They can occur as solitary lesions or as multiple lesions in enchondromatosis (Schwartz 1987, Kaplan 1993). When hemangiomas are associated, the condition is known as Maffucci syndrome (figure 2). The patients are normal at birth and the syndrome manifests during childhood and puberty. The enchondromas affect the extremities and their distribution is asymmetrical. The most common sites of enchondromas are the metacarpal bones and phalanges of the hands. The feet are less commonly afflicted. Clinical problems caused by enchondromas include skeletal deformity and the potential for malignant change to osteosarcoma (figure 3). The risk for sarcomatous degeneration of enchondromas, hemangiomas, or lymphangiomas is 15-30%. Maffucci syndrome is also associated with a higher risk of CNS, pancreatic, and ovarian malignancies (Ono 2012) (figure 4).

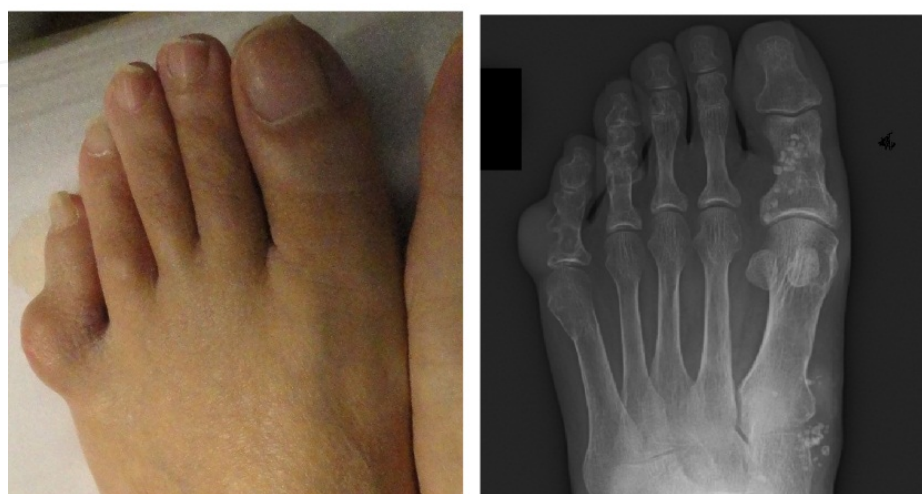


Figure 1. Multiple enchondromas

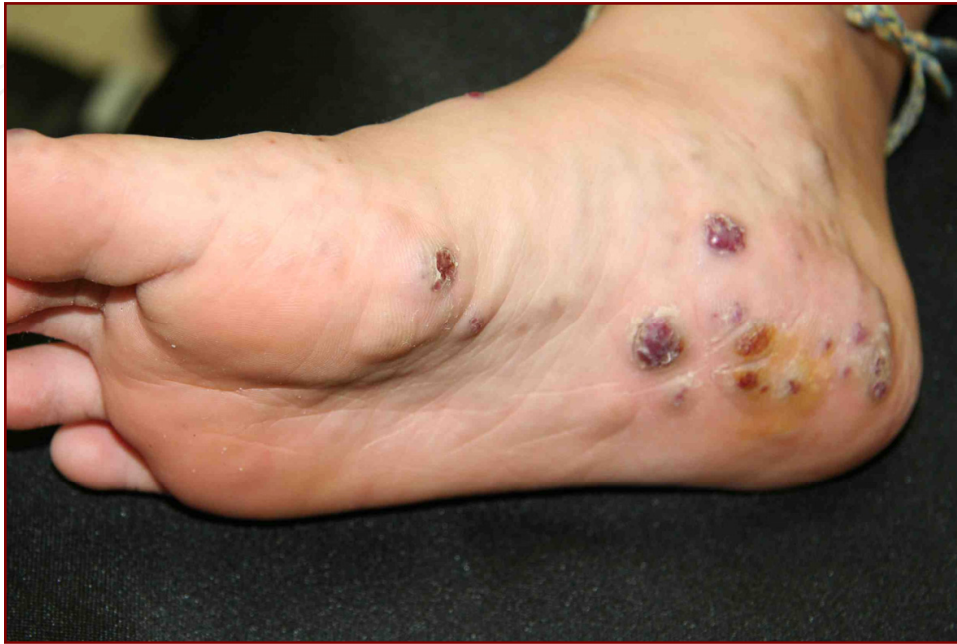

Figure 2. Multiple hemangioma on the sole

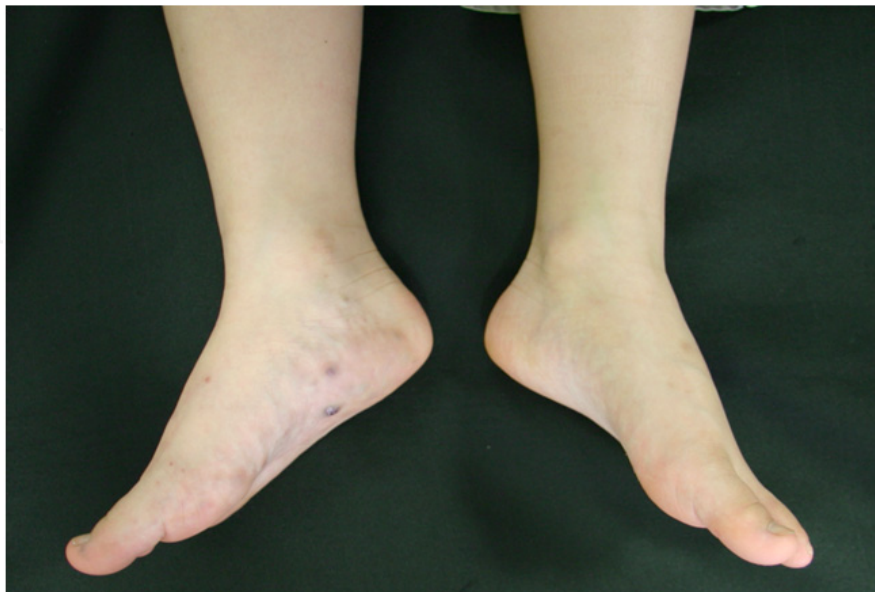

Figure 3. The differences of length and size of the legs are noted.

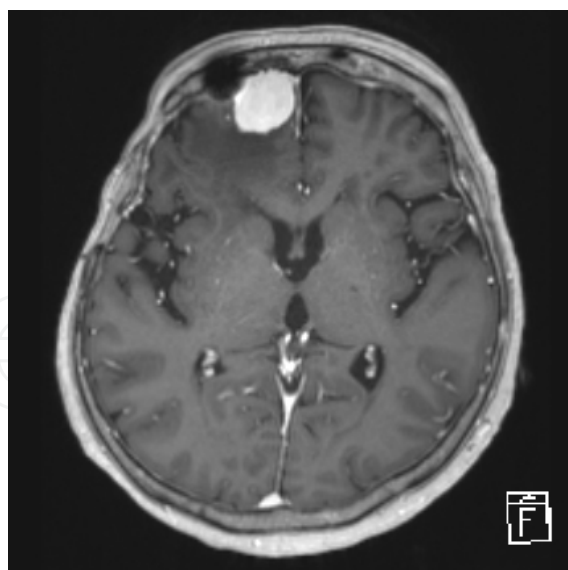


Figure 4. Brain tumor in a patient with Maffucci syndrome

2. Inheritance

Most cases of Maffucci syndrome have been sporadic and no specific hereditary form has been proven (Hakak and Azouz 1991).

It occurs in all races, and occurs in both sexes equally.

3. Cutaneous presentation of Maffucci syndrome

Multiple hemangiomas are presented as multiple nodules on the skin of the extremities, which looks like grapes (figure 2). However, the sites of hamangiomas are reported to be the colon and brain (Lee 1999). Multiple enchondromas present as a subcutaneous nodules fix to the underlining bones. Bleeding from the hemangiomas is clinically important and difficult to manage. Complete resection is usually impossible. Compression therapy is recommended.

4. Molecular genetics of Maffucci syndrome

The responsible genes for Maffucci syndrome have not been found. However, some studies were reported for multiple enchondromatosis.

In enchondromas and chondrosarcomas, mutations of the *PTH1* gene was reported to be a candidate gene, however, subsequent studies could not confirm it (Hopyan 2002, Rozeman 2004).

Somatic heterozygous mutations in *IDH1* or *IDH2* were reported in enchondromas and spindle cell hemangiomas (Pansuriya 2011). Ten cases of 13 (77%) with Maffucci syndrome carried *IDH1* or *IDH2* mutations in their tumors. *IDH1* mutations in cartilage tumors were associated with hypermethylation and downregulated expression of several genes (Amary

2011). Mutations were absent in DNA isolated from the blood, muscle, or saliva of the subjects. Therefore, these mutations are believed to be somatic.

5. Management of Maffucci syndrome

Management entails careful examination and monitoring for malignant degenerations. Surgical interventions can correct or minimize deformities.

Compression therapy may be useful to control hemangiomas.

Author details

Miki Tanioka

Department of Dermatology, Graduate School of Medicine, Kyoto University, Shogoin-Kawara-cho, Sakyo-ku, Kyoto, Japan

6. References

- Schwartz, H. S., Zimmerman, N. B., Simon, M. A., Wroble, R. R., Millar, E. A., Bonfiglio, M. The malignant potential of enchondromatosis. *J. Bone Joint Surg. Am.* 69: 269-274, 1987.
- Kaplan, R. P., Wang, J. T., Amron, D. M., Kaplan, L. Maffucci's syndrome: two case reports with a literature review. *J. Am. Acad. Derm.* 29: 894-899, 1993.
- Ono S, Tanizaki H, Fujisawa A, Tanioka M, Miyachi Y. Maffucci syndrome complicated with meningioma and pituitary adenoma. *Eur J Dermatol* 22(1):130-1, 2012.
- Halal, F., Azouz, E. M. Generalized enchondromatosis in a boy with only platyspondyly in the father. *Am. J. Med. Genet.* 38: 588-592, 1991.
- Lee, N. H., Choi, E. H., Choi, W. K., Lee, S. H., Ahn, S. K. Maffucci's syndrome with oral and intestinal haemangioma. (Letter) *Brit. J. Derm.* 140: 968-969, 1999.
- Hopyan, S., Gokgoz, N., Poon, R., Gensure, R. C., Yu, C., Cole, W. G., Bell, R. S., Juppner, H., Andrulis, I. L., Wunder, J. S., Alman, B. A. A mutant PTH/PTHrP type I receptor in enchondromatosis. *Nature Genet.* 30: 306-310, 2002.
- Rozeman, L. B., Sangiorgi, L., Briaire-de Bruijn, I. H., Mainil-Varlet, P., Bertoni, F., Cleton-Jansen, A. M., Hogendoorn, P. C. W., Bovee, J. V. M. G. Enchondromatosis (Ollier disease, Maffucci syndrome) is not caused by the PTHR1 mutation p.R150C. *Hum. Mutat.* 24: 466-473, 2004
- Pansuriya, T. C., van Eijk, R., d'Adamo, P., van Ruler, M. A. J. H., Kuijjer, M. L., Oosting, J., Cleton-Jansen, A.-M., van Oosterwijk, J. G., Verbeke, S. L. J., Meijer, D., van Wezel, T., Nord, K. H., and 15 others. Somatic mosaic IDH1 and IDH2 mutations are associated with enchondroma and spindle cell hemangioma in Ollier disease and Maffucci syndrome. *Nature Genet.* 43: 1256-1261, 2011.
- Amary, M. F., Damato, S., Halai, D., Eskandarpour, M., Berisha, F., Bonar, F., McCarthy, S., Fantin, V. R., Straley, K. S., Lobo, S., Aston, W., Green, C. L., Gale, R. E., Tirabosco, R., Futreal, A., Campbell, P., Presneau, N., Flanagan, A. M. Ollier disease and Maffucci syndrome are caused by somatic mosaic mutations of IDH1 and IDH2. *Nature Genet.* 43: 1262-1265, 2011.