

# We are IntechOpen, the world's leading publisher of Open Access books Built by scientists, for scientists

4,800

Open access books available

122,000

International authors and editors

135M

Downloads

Our authors are among the

154

Countries delivered to

TOP 1%

most cited scientists

12.2%

Contributors from top 500 universities



WEB OF SCIENCE™

Selection of our books indexed in the Book Citation Index  
in Web of Science™ Core Collection (BKCI)

Interested in publishing with us?  
Contact [book.department@intechopen.com](mailto:book.department@intechopen.com)

Numbers displayed above are based on latest data collected.  
For more information visit [www.intechopen.com](http://www.intechopen.com)



---

# Discovery and Delineation of Dermatan 4-O-Sulfotransferase-1 (D4ST1)-Deficient Ehlers-Danlos Syndrome

---

Tomoki Kosho

Additional information is available at the end of the chapter

<http://dx.doi.org/10.5772/55026>

---

## 1. Introduction

The Ehlers-Danlos syndrome (EDS) is a heterogeneous group of heritable connective tissue disorders affecting as many as 1 in 5000 individuals, characterized by joint and skin laxity, and tissue fragility [1]. The fundamental mechanisms of EDS are known to consist of dominant-negative effects or haploinsufficiency of mutant procollagen  $\alpha$ -chains and deficiency of collagen-processing-enzymes [2]. In a revised nosology established in the nomenclature conference held in June 1997 at Villefranche-sur-Mer, France, Beighton et al. [3] classified EDS into six major types (Table 1): classical type (OMIM#130000), hypermobility type (OMIM#130020), vascular type (OMIM#130050), kyphoscoliosis type (OMIM#225400), arthrochalasia type (OMIM#130060), and dermatosparaxis type (OMIM#225410). Additional minor variants of EDS have been identified with molecular and biochemical abnormalities: dermatan 4-O-sulfotransferase-1 (D4ST1)-deficient type/musculocontractural type (OMIM#601776), Brittle cornea syndrome (OMIM#229200), EDS-like syndrome due to tenascin-XB deficiency (OMIM#606408), EDS with progressive kyphoscoliosis, myopathy, and hearing loss (OMIM#614557); the spondylocheiro dysplastic form (OMIM#612350), cardiac valvular form (OMIM#225320), and progeroid form (OMIM#130070) [4] (Table 1). This chapter focuses on a recent breakthrough in EDS: discovery and delineation of D4ST1-deficient EDS (DD-EDS).

## 2. History of D4ST1-deficient EDS

DD-EDS, caused by loss-of-function mutations in the carbohydrate sulfotransferase 14 (*CHST14*) gene coding D4ST1, has been identified independently as a rare type of arthrogyrosis syndrome, “adducted thumb–clubfoot syndrome (ATCS)” [5]; as a specific

form of EDS, “EDS, Kosho Type” (EDSKT) [6]; and as a subset of kyphoscoliosis type EDS without evidence of lysyl hydroxylase deficiency, “Musculocontractural EDS” (MCEDS) [7].

	Prevalence §	Inheritance	Causative gene(s)
<b>Major types</b>			
Classical type	1/20,000	AD	<i>COL5A1, COL5A2</i>
Hypermobility type	1/5,000-20,000	AD	<i>TNXB</i> <sup>#</sup>
Vascular type	1/50,000-250,000	AD	<i>COL3A1</i>
Kyphoscoliosis type	1/100,000	AR	<i>PLOD</i>
Arthrochalacia type	30	AD	<i>COL1A1*</i> , <i>COL1A2*</i>
Dermatosparaxis type	8	AR	<i>ADAMTS-2</i>
<b>Other variants</b>			
D4ST1-deficient type	26	AR	<i>CHST14</i>
Brittle cornea syndrome	11	AR	<i>ZNF469</i>
EDS-like syndrome due to tenascin-XB deficiency	10	AR	<i>TNXB</i>
EDS with progressive kyphoscoliosis myopathy, and hearing loss	7	AR	<i>FKBP14</i>
Spondylocheiro dysplastic form	8	AR	<i>SLC39A13</i>
Cardiac valvular form	4	AR	<i>COL1A2</i>
Progeroid form	3	AR	<i>B4GALT7</i>

§, a fraction number represents the prevalence such as “one affected person in 20,000 individuals” for “1/20,000” and an integral number represents the sum of previously reported patients; AD, autosomal dominant; AR, autosomal recessive; *COL5A1* or *COL5A2*,  $\alpha 1(V)$  or  $\alpha 2(V)$  procollagen; *TNXB*, tenascin-X; #, in a small subset of cases; *COL3A1*,  $\alpha 1(III)$  procollagen; *PLOD*; lysyl hydroxylase; *COL1A1* or *COL1A2*,  $\alpha 1(I)$  or  $\alpha 2(I)$  procollagen; \*, splice-site mutations of the genes; *ADAMTS2*; procollagen I N-proteinase; *CHST14*, carbohydrate sulfotransferase 14; *ZNF469*, zinc finger protein 469; *FKBP14*, FK506-binding protein 14; *SLC39A13*, a membrane-bound zinc transporter; *B4GALT7*; xylosylprotein 4-beta-galactosyltransferase

**Table 1.** Classification of Ehlers-Danlos Syndromes

## 2.1. Adducted thumb–Clubfoot syndrome

The original report of ATCS was written by Dündar et al. [8] from Erciyes University, Turkey, presenting two cousins, a boy aged 3.5 years and a girl aged 1.5 years, from a consanguineous Turkish family. In common, they had moderate to severe psychomotor developmental delay, ocular anterior chamber abnormality, facial characteristics, generalized joint laxity, arachnodactyly, camptodactyly, and distal arthrogyriposis with adducted thumbs and clubfeet. They reported another patient with ATCS, a boy aged 3 months, from a consanguineous Turkish family including three affected siblings who died of unknown etiology between the ages of 1 and 4 months [9]. The patient also had bilateral nephrolithiasis, a unilateral inguinal hernia, and bilateral cryptorchidism. The authors

suggested that two brothers, aged 22 months and 7 months, from a Japanese consanguineous family reported by Sonoda and Kouno [10] would also fit the diagnosis of ATCS. The brothers had multiple distal arthrogyriposis, characteristic facial features, cleft palates, short stature, hydronephrosis, cryptorchidism, and normal intelligence. Dündar et al. [9] also showed follow-up observations of the original patients: the intelligence quotient (IQ) was roughly 90 in one subject at age 7 years and 2 months and the other died of unknown cause at 5 years of age. Janecke et al. [11] from Innsbruck Medical University, Austria, reported two brothers with ATCS from a consanguineous Austrian family, one of whom died shortly after birth because of respiratory failure. The authors concluded that all these patients represented a new type of arthrogyriposis with central nervous system involvement, congenital heart defects, urogenital defects, myopathy, connective tissue involvement (generalized joint laxity), and normal or subnormal mental development. In 2009, Dündar et al. reported that *CHST14* was the causal gene for ATCS through homozygosity mapping using samples from four previously published consanguineous families. The authors mentioned some follow-up clinical findings including generalized joint laxity, delayed wound healing, ecchymoses, hematomas, and osteopenia/osteoporosis; and categorized ATCS as a generalized connective tissue disorder [5].

## 2.2. EDS, Kosho type

We encountered the first patient with a specific type of EDS in 2000 and the second with parental consanguinity in 2003. They were Japanese girls with strikingly similar symptoms: characteristic craniofacial features; skeletal features including multiple congenital contractures, malfanoid habitus, pectus excavatum, generalized joint laxity, recurrent dislocations, and progressive talipes and spinal deformity; skin hyperextensibility, bruisability, and fragility with atrophic scars; recurrent hematomas; and hypotonia with mild motor developmental delay [12]. These symptoms overlapped those in the kyphoscoliosis type EDS (previously known as EDS type VI), which is typically associated with deficiency of lysyl hydroxylase (EDS type VIA) [13]. A rare condition with the clinical phenotype of the kyphoscoliosis type EDS but with normal lysyl hydroxylase activity were reported and named as EDS type VIB [13]. Therefore, we tentatively proposed that the two patients represented a clinically recognizable subgroup of EDS type VIB [12]. Through their long-term clinical evaluation as well as four additional unrelated Japanese patients including one with parental consanguinity and another reported by Yasui et al. [14], we concluded that they—four female patients and two male patients aged 4–32 years, represented a new clinically recognized type of EDS with distinct craniofacial characteristics, multiple congenital contractures, progressive joint and skin laxity, and multisystem fragility-related manifestations [15]. The disorder has been registered as EDS Kosho Type (EDSKT) in the London Dysmorphology Database (<http://www.lmdatabases.com/index.html>) and in POSSUM (<http://www.possun.net.au/>). In 2009, we identified *CHST14* as causal for the disorder through homozygosity mapping using samples from two consanguineous families and all the other patients were also found to have compound heterozygous *CHST14* mutations [6].

### 2.3. Musculocontractural EDS

Malfait et al. [7] from Ghent University, Belgium have found mutations in *CHST14* through homozygosity mapping of two Turkish sisters and an Indian girl both presenting clinically with EDS VIB and with parental consanguinity. They had distinct craniofacial features, joint contractures, and wrinkled palms in addition to common features of kyphoscoliosis type EDS including kyphoscoliosis, muscular hypotonia, hyperextensible, thin, and bruisable skin, atrophic scarring, joint hypermobility, and variable ocular involvement. Malfait et al. [7] concluded that their series and ATCS, as well as EDSKT, formed a phenotypic continuum based on their clinical observations and identification of an identical mutation in both conditions; and proposed to coin the disorder as “musculocontractural EDS” (MCEDS).

## 3. Pathophysiology of D4ST1-deficient EDS

### 3.1. Glycobiological abnormalities in D4ST1-deficient EDS

D4ST1 is a regulatory enzyme in the glycosaminoglycan (GAG) biosynthesis that transfers active sulfate to position 4 of the N-acetyl-D-galactosamine residues of dermatan sulfate (DS) (Fig. 1) [16, 17]. DS, together with chondroitin sulfate (CS) and heparan sulfate, constitutes GAG chains of proteoglycans and is implicated in cardiovascular disease, tumorigenesis, infection, wound repair, and fibrosis via DS-containing proteoglycans such as decorin and biglycan [18].

Sulfotransferase activity toward dermatan in the skin fibroblasts derived from the patients was significantly decreased to 6.7% (patient 1 with a compound heterozygous mutation: P281L/Y293C) and 14.5% (patient 3 with a homozygous mutation: P281L) of each age- and sex-matched control) (Fig. 2A). Disaccharide composition analysis of CS/DS chains isolated from the skin fibroblasts showed a negligible amount of DS and a slight excess of CS (Fig. 2B). Subsequently, we focused on a major DS proteoglycan in the skin, decorin, consisting of core protein and one GAG chain and playing an important role in assembly of collagen fibrils (Nomura, 2006). No DS disaccharides were detected in the GAG chains of decorin from the patients, whereas the GAG chains of decorin from the controls were mainly composed of DS disaccharides (approximately 95%) (Fig. 2C) [6].

### 3.2. Pathological abnormalities in D4ST1-deficient EDS

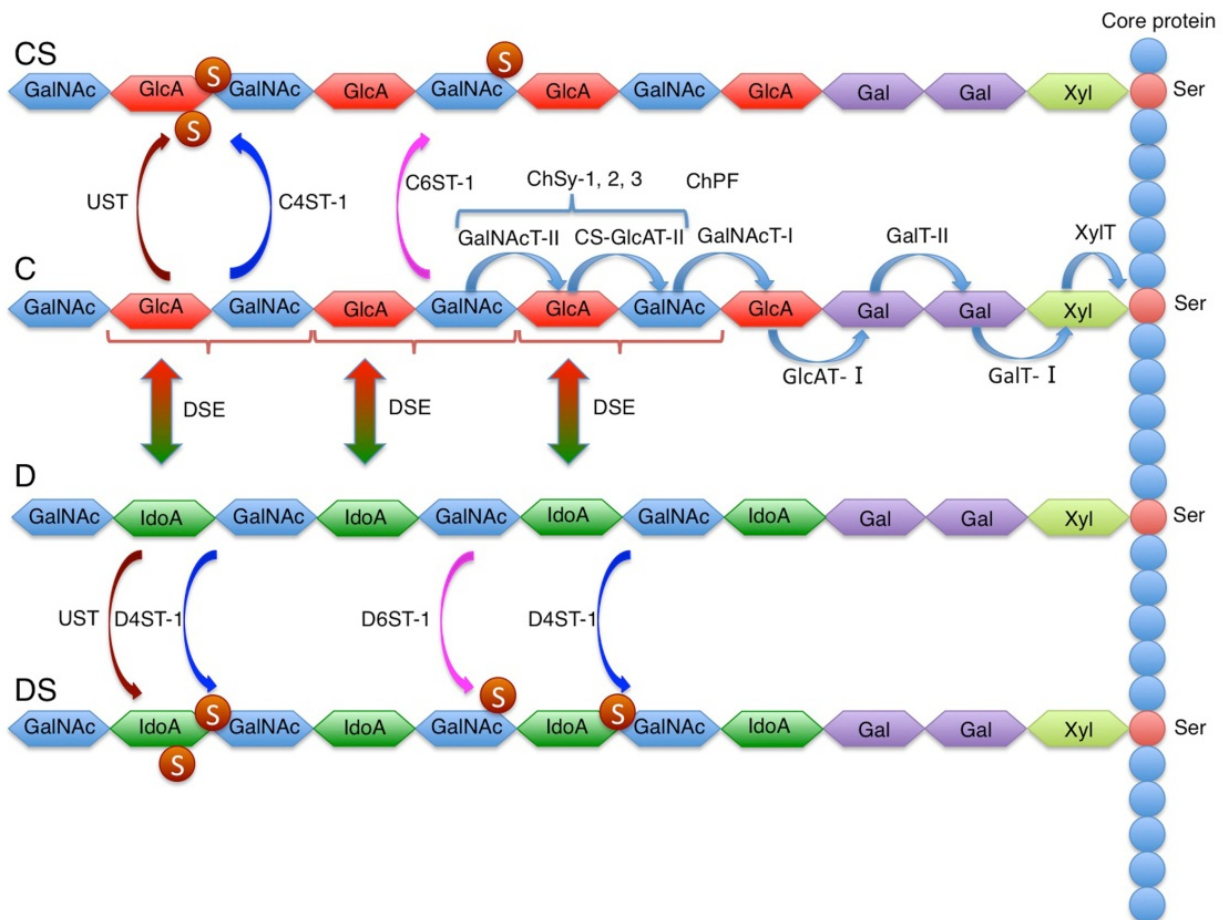
Hematoxylin and eosin (H&E)-stained light microscopy on patients' skin specimens showed that fine collagen fibers were present predominantly in the reticular to papillary dermis with marked reduction of normally thick collagen bundles (Fig. 3a, b). Electron microscopy showed that collagen fibrils were dispersed in the reticular dermis, compared with the regularly and tightly assembled ones observed in the control; whereas each collagen fibril was smooth and round, not varying in size and shape, similar to each fibril of the control (Fig. 3c, d) [6].

Patient	Family	Origin	<i>CHST14</i> mutations	Sex	Age at initial publication	References
1	1	Turkish	V49X homo	F	3.5y	[8]
2				M	1.5y	
3				F	6y	
4	2	Japanese	Y293C homo	M	4y	[10]
5				M	7m	
6	3	Austrian	R213P homo	M	0d†	[11]
7				M	12m	
8	4	Turkish	[R135G;L137Q] homo	F	1–4m†	[9]
9				M	1–4m†	
10				M	1–4m†	
11				M	3m	
12	5	Japanese	P281L/Y293C	F	11y	[12]
13	6	Japanese	P281L homo	F	14y	[12]
14	7	Japanese	P281L homo	M	32y	[15]
15	8	Japanese	K69X/P281L	M	32y	[14,15]
16	9	Japanese	P281L/C289S	F	20y	[15]
17	10	Japanese	P281L/Y293C	F	4y	[15]
18	11	Turkish	V49X homo	F	22y	[7]
19				F	21y	
20	12	Indian	E334Gfs*107 homo	F	12y	[7]
21	13	Japanese	P281L/Y293C	M	2y	[21]
22	14	Japanese	F209S/P281L	M	6y	[21]
23	15	Dutch	V48X homo	F	20y	[23]
24	16	Afghani	R274P homo	F	11y	[24]
25				F	0y	
26	17	Miccosukee	G228Lfs*13	F	16y	[25]

homo, homozygous mutation; /, compound heterozygous mutation; F, female; M, male; y, years old; m, months old; †, dead at the time of publication

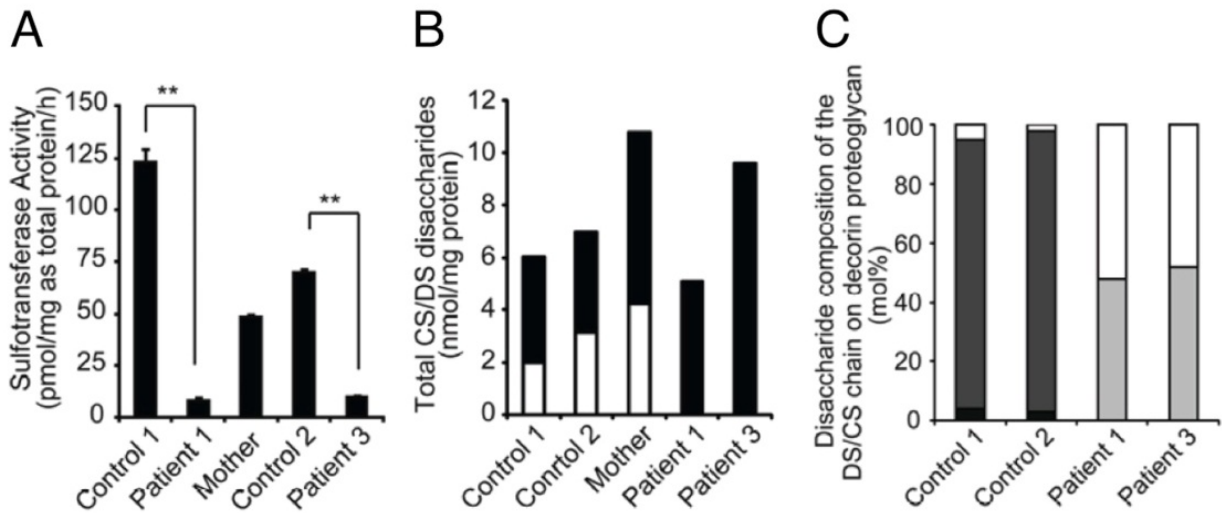
**Table 2.** Reported patients with D4ST1-deficient EDS





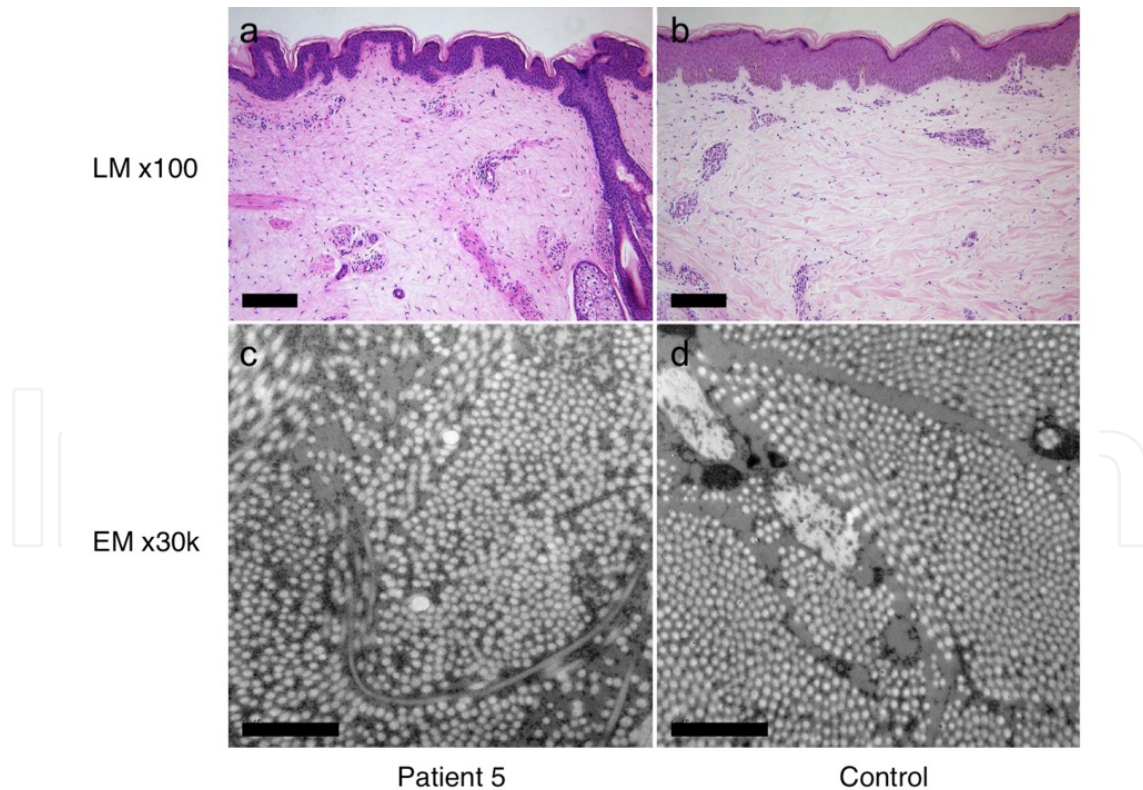
Biosynthesis of chondroitin sulfate (CS) and dermatan sulfate (DS) starts with binding a tetrasaccharide linker region, glucuronic acid $\beta$ 1-3galactose $\beta$ 1-3galactose $\beta$ 1-4xylose $\beta$ 1-O- (GlcA-Gal-Gal-Xyl-), onto serine (Ser) residues of specific core proteins of proteoglycans, by  $\beta$ -xylosyltransferase (XylT),  $\beta$ 1,4-galactosyltransferase-I (GalT-I),  $\beta$ 1,3-galactosyltransferase-II (GalT-II), and  $\beta$ 1,3-glucuronosyltransferase-I (GlcAT-I), respectively. Subsequently, a disaccharide chain of chondroitin (C[N-acetyl-D-galactosamine(GalNAc)-GlcA]<sub>n</sub>) is synthesized by N-acetyl-D-galactosaminyltransferase-I (GalNAcT-I), N-acetyl-D-galactosaminyltransferase-II (GalNAcT-II), and CS-glucuronosyltransferase-II (CS-GlcAT-II) encoded by chondroitin synthase-1, 2, 3 (ChSy-1, 2, 3); and chondroitin polymerizing factor (ChPF). CS chains are matured through sulfation by chondroitin 4-O-sulfotransferase-1 (C4ST-1), chondroitin 6-O-sulfotransferase-1 (C6ST-1), and uronyl 2-O-sulfotransferase (UST). A disaccharide chain of dermatan (D) is synthesized through epimerization of a carboxyl group at C5 from GlcA to L-iduronic acid (IdoA) by dermatan sulfate epimease (DSE). DS chains are matured through sulfation by dermatan 4-O-sulfotransferase-1 (D4ST-1), dermatan 6-O-sulfotransferase-1 (D6ST-1), and UST. D4ST-1 deficiency, resulting in impaired 4-O-sulfation lock, probably allows back epimerization from IdoA to GlcA and finally leads to loss of DS and excess of CS.

**Figure 1.** Biosynthesis of dermatan sulfate and chondroitin sulfate.



A. Sulfotransferase activity of skin fibroblasts: A patient (a compound heterozygous mutation, P281L/Y293C; patient 1), her heterozygous mother, and her age-matched control (control 1); another patient (a homozygous mutation, P281L; patient 3) and his age-matched control (control 2). B. The total amounts of CS and DS derived from skin fibroblasts. The total disaccharide contents of CS and DS are shown in a black box and a white box, respectively. C. Proportion of the disaccharide units in the CS/DS hybrid chains in decorin secreted by the fibroblasts. A white box and a light gray box indicate GlcUA-GalNAc (4S) and GlcUA-GalNAc (6S), respectively, both composing CS. A dark gray box and a black box indicate IdoUA-GalNAc(4S) and IdoUA-GalNAc (6S), respectively, both composing DS.

**Figure 2.** Glycobiological studies [6].

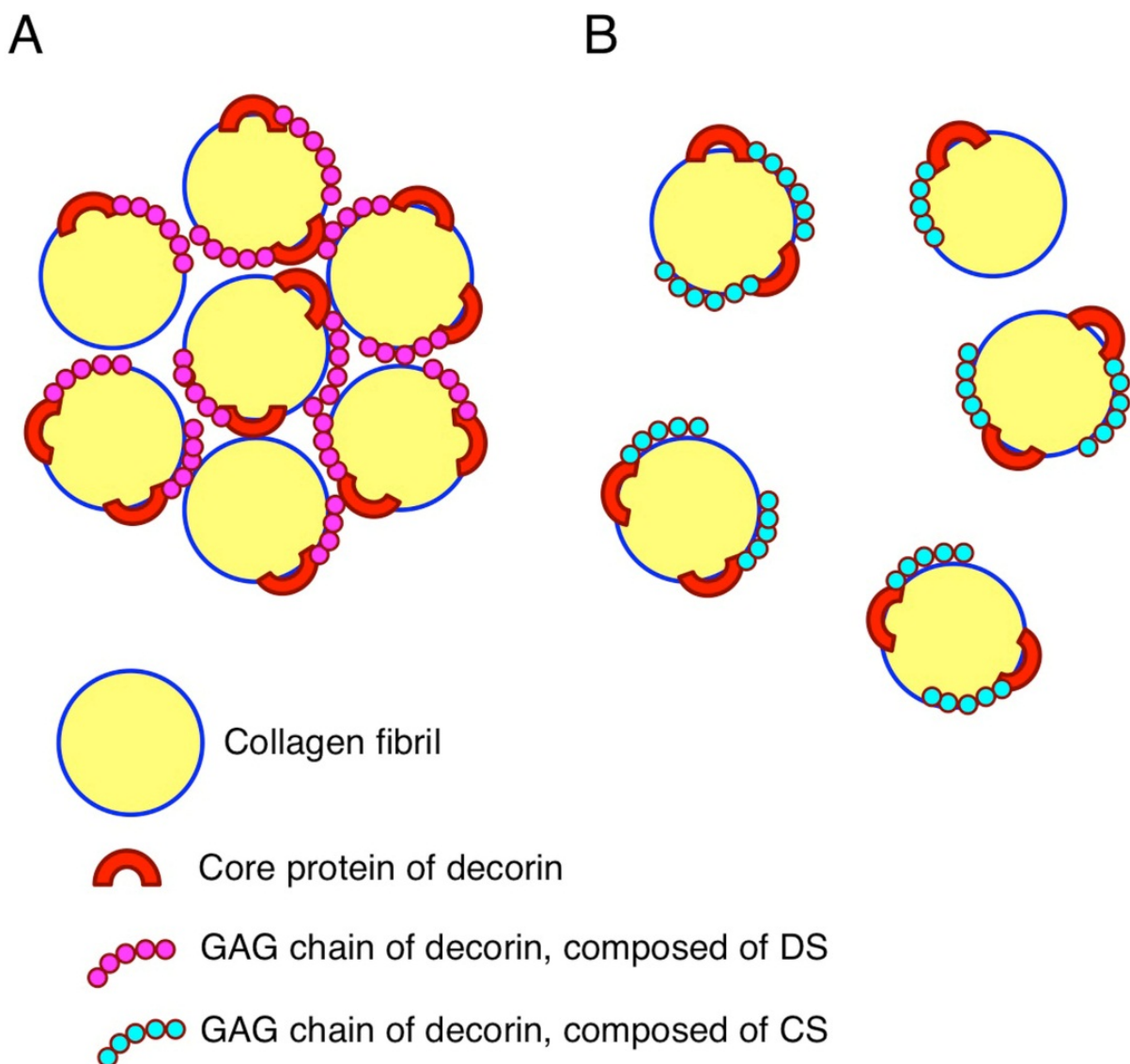


H&E-stained light microscopy (LM) on skin specimens of a patient (a compound heterozygous mutation, P281L/C289S; patient 5) (a) and an age- and sex-matched control (b). Scale bars indicate 500  $\mu\text{m}$ . Electron microscopy (EM) of the patient (c) and the control (d). Scale bars indicate 1  $\mu\text{m}$ .

**Figure 3.** Pathological studies [6].



In view of these glycobiological and pathological findings, skin fragility in this disorder is suggested to be caused by impaired assembly of collagen fibrils resulting from loss of DS in the GAG chain of decorin [6]. Decorin DS regulates the interfibrillar distance in collagen fibrils and permits the extracellular matrix to resist physical stress, possibly through electrostatic interaction between decorin DS chains and adjacent collagen fibrils (Fig. 4A) [19]. Collagen fibrils are dispersed in patients' skin tissues where the decorin GAG chains are exclusively composed of CS (Fig. 4B), whereas collagen fibrils in controls' skin specimens are tightly assembled through the GAG chains of decorin exclusively composed of DS (Fig. 4A).



Possible relationship between collagen fibrils and decorin in skin specimens of normal control subjects (A) and of patients (B).

**Figure 4.** Schema of binding model of decorin to collagen fibrils [20].

#### 4. Delineation of D4ST1-deficient EDS

Independently identified three conditions, ATCS, EDSKT, and MCEDS caused by loss-of-function mutations in CHST14, were supposed to be a single clinically recognizable type of connective tissue disorder [7, 21]. Shimizu et al. [22] presented detailed clinical information of two additional unrelated patients and a comprehensive review of all reported 20 patients, which could definitely unite the three conditions named as “D4ST1-deficient EDS (DD-EDS)”. Kosho et al. [23] concluded that categorization of the disorder into a form of “EDS” was appropriate clinically because the disorder satisfied all the hallmarks of EDS including skin hyperextensibility, joint hypermobility, and tissue fragility affecting the skin, ligaments, joints, blood vessels, and internal organs [1] and etiologically because multisystem fragility in the disorder was illustrated to be caused by impaired assembly of collagen fibrils resulting from loss of DS in the decorin GAG chains [6].

To date, 26 patients have been reported to have homozygous or compound heterozygous CHST14 mutations (Table 2) [24, 25, 26]. Clinical characteristics are summarized in Table 3, consisting of progressive multisystem fragility-related manifestations and various malformations [23].

Characteristic craniofacial features including large fontanelle, hypertelorism, short and downslanting palpebral fissures, blue sclerae, short nose with hypoplastic columella, low-set and rotated ears, high palate, long philtrum, thin upper lip vermilion, small mouth, and micro-retrognathia are noted at birth to early childhood (Fig. 5A, B). Slender and asymmetrical facial shapes with protruding jaws are noted from school age (Fig. 5C) [12, 15, 22].

Congenital multiple contractures, most specifically adduction-flexion contractures of thumbs and talipes equinovarus, were cardinal features (Fig. 5D, G, J, K, M). In childhood, peculiar fingers described as “tapering”, “slender”, and “cylindrical” are also common features (Fig. 5E, F, H, I). Talipes deformities (planus, valgus) (Fig. 5L, N) and spinal deformities (scoliosis, kyphoscoliosis) with tall vertebral bodies and decreased physiological curvature (Fig. 5O, P, Q, R, S, T) occur and progress. Malfanoid habitus, recurrent joint dislocations, and pectus deformities (flat and thin, excavatum, carinatum) are also evident [12, 15, 22].

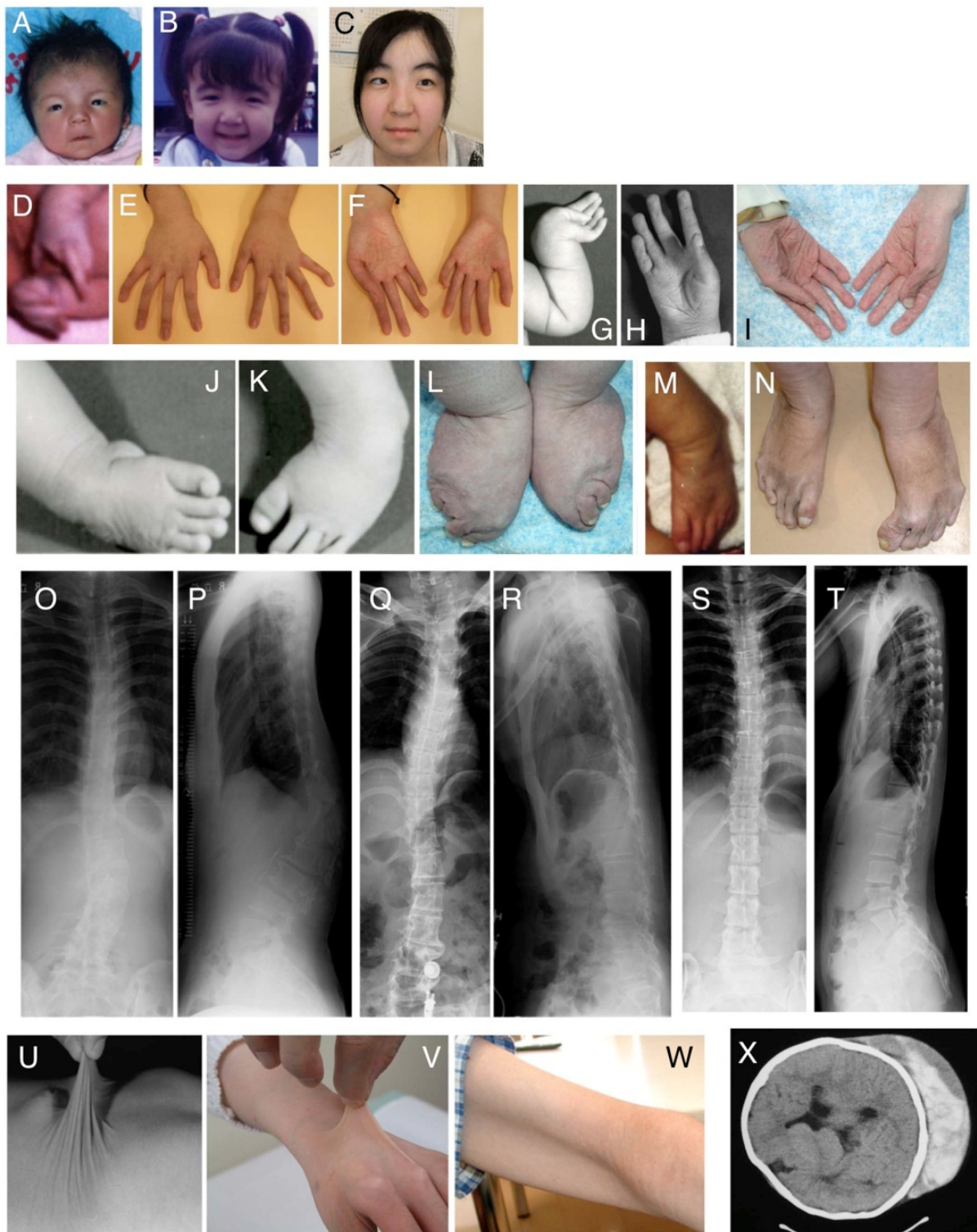
Cutaneous features include hyperextensibility (Fig. 5U, V) to redundancy (Fig. 5W), bruiseability, fragility leading to atrophic scars, acrogeria-like fine palmar creases or wrinkles (Fig. 5F, I), hyperalgesia to pressure, and recurrent subcutaneous infections with fistula formation (Kosho et al., 2005; Kosho et al., 2010; Shimizu et al., 2011).

Recurrent large subcutaneous hematomas are the most serious complication, which sometimes progress acutely and massively to be treated intensively (admission, blood transfusion, surgical drainage) and are supposed to be caused by rupture of subcutaneous arteries or veins (Fig. 5X) [12, 15, 22].

<b><i>Craniofacial</i></b>	<b><i>Cardiovascular</i></b>
Large fontanelle (early childhood)	Congenital heart defects (ASD)
Hypertelorism	Valve abnormalities (MVP, MR, AR, ARD)
Short and downslanting palpebral fissures	Large subcutaneous hematomas
Blue sclerae	<b><i>Gastrointestinal</i></b>
Short nose with hypoplastic columella	Constipation
Ear deformities (prominent, posteriorly rotated, low-set)	Diverticula perforation
Palatal abnormalities (high, cleft)	<b><i>Respiratory</i></b>
Long philtrum and thin upper lip	(Hemo)pneumothorax
Small mouth/micro-retrognathia (infancy)	<b><i>Urogenital</i></b>
Slender face with protruding jaw (from school age)	Nephrolithiasis/cystolithiasis
Asymmetric face (from school age)	Hydronephrosis
<b><i>Skeletal</i></b>	Dilated/atonic bladder
Marfanoid habitus/slender build	Inguinal hernia
Congenital multiple contractures (fingers, wrists, hips, feet)	Cryptorchidism
Recurrent/chronic joint dislocations	Poor breast development
Pectus deformities (flat, excavated)	<b><i>Ocular</i></b>
Spinal deformities (scoliosis, kyphoscoliosis)	Strabismus
Peculiar fingers (tapering, slender, cylindrical)	Refractive errors (myopia, astigmatism)
Progressive talipes deformities (valgus, planus, cavum)	Glaucoma/elevated intraocular pressure
<b><i>Cutaneous</i></b>	Microcornea/microphthalmia
Hyperextensibility/redundancy	Retinal detachment
Bruisability	<b><i>Hearing</i></b>
Fragility/atrophic scars	Hearing impairment
Fine/acrogeria-like palmar creases	<b><i>Neurological</i></b>
Hyperalgesia to pressure	Ventricular enlargement/asymmetry
Recurrent subcutaneous infections/fistula	<b><i>Development</i></b>
	Hypotonia/gross motor delay.

ASD, atrial septal defect; MVP, mitral valve prolapse; MR, mitral valve regurgitation; AR, aortic valve regurgitation; ARD, aortic root dilation

**Table 3.** Clinical manifestations in DD-EDS [23]



**Figure 5.** Clinical photographs of patients with DD-EDS [12, 15]. Patient 12 at birth (D), at age 23 days (A), 3 years (B), 6 years (X), and 16 years (C, E, F, O, P). Patient 13 at age 2 months (J, K), 3 months (G), 14 months (U), 5 years (H), and 28 years (I, L, Q, R). Patient 14 in the neonatal period (M) and at age 28 years (N, W). Patient 16 at age 19 years (S, T, V). Patient number is according to Table 2.



## 5. Conclusion

DD-EDS is a newly recognized and delineated form of EDS, characterized by progressive multisystem fragility-related manifestations (skin hyperextensibility and fragility, progressive spinal and foot deformities, large subcutaneous hematoma) and various malformations (facial features, congenital eye/heart/gastrointestinal defects, congenital multiple contractures). The cause of multisystem connective tissue fragility is supposed to be impaired assembly of collagen fibrils resulting from loss of DS in the decorin GAG chains. It is the first human disorder affecting biosynthesis of DS, which emphasizes a role for DS in human development and extracellular matrix maintenance [27].

## Author details

Tomoki Kosho

*Department of Medical Genetics, Shinshu University School of Medicine, Asahi, Matsumoto, Japan*

## Acknowledgement

The author is thankful to all the patients and their families for participating in this study. The authors also express the gratitude to all the collaborators. All the studies were supported by Research on Intractable Diseases from Japanese Ministry of Health, Welfare, and Labor.

## 6. References

- [1] Steinmann B, Royce PM, Superti-Furga A. 2002. The Ehlers–Danlos syndrome. In: Royce PM, Steinmann B, editors. *Connective tissue and its heritable disorders*. New York: Wiley-Liss, p431–523.
- [2] Mao JR, Bristow J. 2001. The Ehlers-Danlos syndrome: on beyond collagens. *J Clin Invest* 107:1063-1069.
- [3] Beighton P, De Paepe A, Steinmann B, Tsipouras P, Wenstrup R. 1998. Ehlers–Danlos syndromes: revised nosology, Villefranche, 1997. *Am J Med Genet* 77:31–37.
- [4] De Paepe A, Malfait F. 2012. The Ehlers-Danlos syndrome, a disorder with many faces. *Clin Genet* 82:1-11.
- [5] Dündar M, Müller T, Zhang Q, Pan J, Steinmann B, Vodopiutz J, Gruber R, Sonoda T, Krabichler B, Utermann G, Baenziger JU, Zhang L, Janecke AR. 2009. Loss of dermatan-4-sulfotransferase 1 function results in adducted thumb-clubfoot syndrome. *Am J Hum Genet* 85:873–882.
- [6] Miyake N, Kosho T, Mizumoto S, Furuichi T, Hatamochi A, Nagashima Y, Arai E, Takahashi K, Kawamura R, Wakui K, Takahashi J, Kato H, Yasui H, Ishida T, Ohashi H, Nishimura G, Shiina M, Saitsu H, Tsurusaki Y, Doi H, Fukushima Y, Ikegawa S, Yamada S, Sugahara K, Matsumoto N. 2010. Loss-of-function mutations of *CHST14* in a new type of Ehlers–Danlos syndrome. *Hum Mutat* 31:966–974.



- [7] Malfait F, Syx D, Vlummens P, Symoens S, Nampoothiri S, Hermanns-Lê, Van Lear L, De Paepe A. Musculocontractural Ehlers–Danlos syndrome (former EDS type VIB) and adducted thumb clubfoot syndrome (ATCS) represent a single clinical entity caused by mutations in the dermatan-4-sulfotransferase 1 encoding *CHST14* gene. 2010. *Hum Mutat* 31:1233–1239.
- [8] Dündar M, Demiryilmaz F, Demiryilmaz I, Kumandas S, Erkilic K, Kendirch M, Tuncel M, Ozyazgan I, Tolmie JL. 1997. An autosomal recessive adducted thumb-club foot syndrome observed in Turkish cousins. *Clin Genet* 51:61–64.
- [9] Dündar M, Kurtoglu S, Elmas B, Demiryilmaz F, Candemir Z, Ozkul Y, Durak AC. 2001. A case with adducted thumb and club foot syndrome. *Clin Dysmorphol* 10:291–293.
- [10] Sonoda T, Kouno K. 2000. Two brothers with distal arthrogryposis, peculiar facial appearance, cleft palate, short stature, hydronephrosis, retentio testis, and normal intelligence: a new type of distal arthrogryposis? *Am J Med Genet* 91:280–285.
- [11] Janecke AR, Unsinn K, Kreczy A, Baldissera I, Gassner I, Neu N, Utermann G, Müller T. 2001. Adducted thumb-club foot syndrome in sibs of a consanguineous Austrian family. *J Med Genet* 38:265–269.
- [12] Kosho T, Takahashi J, Ohashi H, Nishimura G, Kato H, Fukushima Y. 2005. Ehlers–Danlos syndrome type VIB with characteristic facies, decreased curvatures of the spinal column, and joint contractures in two unrelated girls. *Am J Med Genet Part A* 138A:282–287.
- [13] Yeowell HN, Steinmann B. 2008. Ehlers-Danlos Syndrome, Kyphoscoliotic Form. n: Pagon RA, Bird TD, Dolan CR, Stephens K, Adam MP, editors. *GeneReviews™* [Internet]. Seattle (WA): University of Washington, Seattle; 1993-.2000 Feb 02 [updated 2008 Feb 19].
- [14] Yasui H, Adachi Y, Minami T, Ishida T, Kato Y, Imai K. 2003. Combination therapy of DDAVP and conjugated estrogens for a recurrent large subcutaneous hematoma in Ehlers–Danlos syndrome. *Am J Hematol* 72:71–72.
- [15] Kosho T, Miyake N, Hatamochi A, Takahashi J, Kato H, Miyahara T, Igawa Y, Yasui H, Ishida T, Ono K, Kosuda T, Inoue A, Kohyama M, Hattori T, Ohashi H, Nishimura G, Kawamura R, Wakui K, Fukushima Y, Matsumoto N. 2010. A new Ehlers–Danlos syndrome with craniofacial characteristics, multiple congenital contractures, progressive joint and skin laxity, and multisystem fragility-related manifestations. *Am J Med Genet Part A* 152A:1333–1346.
- [16] Evers MR, Xia G, Kang HG, Schachner M, Baezinger JU. 2001. Molecular cloning and characterization of a dermatan-specific *N*-acetylgalactosamine 4-O-sulfotransferase. *J Biol Chem* 276:36344–36353.
- [17] Mikami T, Mizumoto S, Kago N, Kitagawa H, Sugahara K. 2003. Specificities of three distinct human chondroitin/dermatan *N*-acetylgalactosamine 4-O-sulfotransferases demonstrated using partially desulfated dermatan sulfate as an acceptor: implication of differential roles in dermatan sulfate biosynthesis. *J Biol Chem* 278:36115–36127.
- [18] Trowbridge JM, Gallo RL. 2002. Dermatan sulfate: new functions from an old glycosaminoglycan. *Glycobiol* 12:117R–25R.

- [19] Nomura Y. 2006. Structural changes in decorin with skin aging. *Connect Tissue Res* 47:249–255.
- [20] Kosho T. 2011. Discovery and delineation of a new type of Ehlers-Danlos syndrome caused by dermatan 4-*O*-sulfotransferase deficiency. *Shinshu Med J* 59:305-319.
- [21] Janecke AR, Baenziger JU, Müller T, Dündar M. 2011. Letter to the Editors. Loss of dermatan-4-sulfotransferase 1 (D4ST1/*CHST14*) function represents the first dermatan sulfate biosynthesis defect, "Dermatan sulfate-deficient adducted thumb-clubfoot syndrome". *Hum Mutat* 32:484–485.
- [22] Shimizu K, Okamoto N, Miyake N, Taira K, Sato Y, Matsuda K, Akimaru N, Ohashi H, Wakui K, Fukushima Y, Matsumoto N, Kosho T. 2011. Delineation of dermatan 4-*O*-sulfotransferase 1 deficient Ehlers-Danlos syndrome: observation of two additional patients and comprehensive review of 20 reported patients. *Am J Med Genet Part A* 155:1949-1958
- [23] Kosho T, Miyake N, Mizumoto S, et al. 2011. A response to: loss of dermatan-4-sulfotransferase 1 (D4ST1/*CHST14*) function represents the first dermatan sulfate biosynthesis defect, "dermatan sulfate-deficient Adducted Thumb-Clubfoot Syndrome". Which name is appropriate, "Adducted Thumb-Clubfoot Syndrome" or "Ehlers-Danlos syndrome"? *Hum Mutat* 32:1507-1509.
- [24] Voermans NC, Kempers M, Lammens M, van Alfen N, Janssen MC, Bönnemann C, van Engelen BG, Hamel BC. 2012. Myopathy in a 20-year-old female patient with D4ST-1 deficient Ehlers-Danlos syndrome due to a homozygous *CHST14* mutation. *Am J Med Genet A* 158A:850-855.
- [25] Mendoza-Londono R, Chitayat D, Kahr WH, Hinek A, Blaser S, Dupuis L, Goh E, Badilla-Porras R, Howard A, Mittaz L, Superti-Furga A, Unger S, Nishimura G, Bonafe L. 2012. Extracellular matrix and platelet function in patients with musculocontractural Ehlers-Danlos syndrome caused by mutations in the *CHST14* gene. *Am J Med Genet A* 158A:1344-1354.
- [26] Winters KA, Jiang Z, Xu W, Li S, Ammous Z, Jayakar P, Wierenga KJ. 2012. Re-assigned diagnosis of D4ST1-deficient Ehlers-Danlos syndrome (adducted thumb-clubfoot syndrome) after initial diagnosis of Marden-Walker syndrome. *Am J Med Genet A* 158A:2935-2940.
- [27] Zhang L, Müller T, Baenziger JU, Janecke AR. 2010. Congenital disorders of glycosylation with emphasis on loss of dermatan-4-sulfotransferase? *93:289–307*.