

# We are IntechOpen, the world's leading publisher of Open Access books Built by scientists, for scientists

## 4,800

Open access books available

## 122,000

International authors and editors

## 135M

Downloads

Our authors are among the

## 154

Countries delivered to

## TOP 1%

most cited scientists

## 12.2%

Contributors from top 500 universities

**WEB OF SCIENCE™**Selection of our books indexed in the Book Citation Index  
in Web of Science™ Core Collection (BKCI)

Interested in publishing with us?  
Contact [book.department@intechopen.com](mailto:book.department@intechopen.com)

Numbers displayed above are based on latest data collected.  
For more information visit [www.intechopen.com](http://www.intechopen.com)



---

# Junctional and Dystrophic Epidermolysis Bullosa

---

Daisuke Tsuruta, Chiharu Tateishi and Masamitsu Ishii

Additional information is available at the end of the chapter

<http://dx.doi.org/10.5772/54610>

---

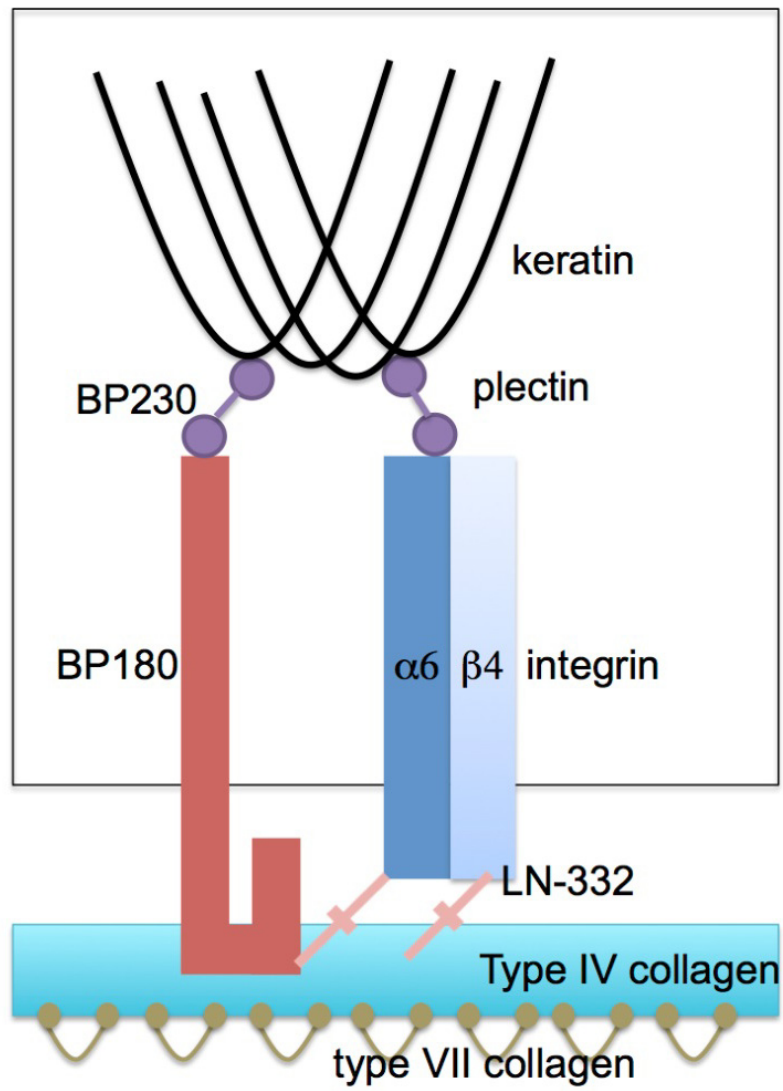
## 1. Introduction

Epidermolysis bullosa (EB) is a congenital genodermatosis, which affects mainly skin and occasionally other organs [1]. Lifelong blistering and erosion of the skin and mucous membrane, caused by mechanical trauma, threaten EB patients [1]. The most common cause of death is metastasizing squamous cell carcinoma [2]. EB is subdivided into mainly three categories by the location of tissue separation (blister) in the basement membrane zone (BMZ) at the electronmicroscopical level, EB simplex (EBS), dystrophic EB (DEB) and junctional EB (JEB)[1]. Some dermatologists also proposed to distinguish hemidesmosomal epidermolysis bullosa [3]. In EBS, blister locates at the level of basal keratinocytes, in DEB at the level of lamina lucida and in JEB at the level of the dermis [1]. EB is mainly caused by the mutation of keratin filament, hemidesmosome components or collagen genes [1]. Thus far, at least 10 different genes are identified as causative genes for EB [1,4,5].

## 2. The molecular components of BMZ (Figure 1)

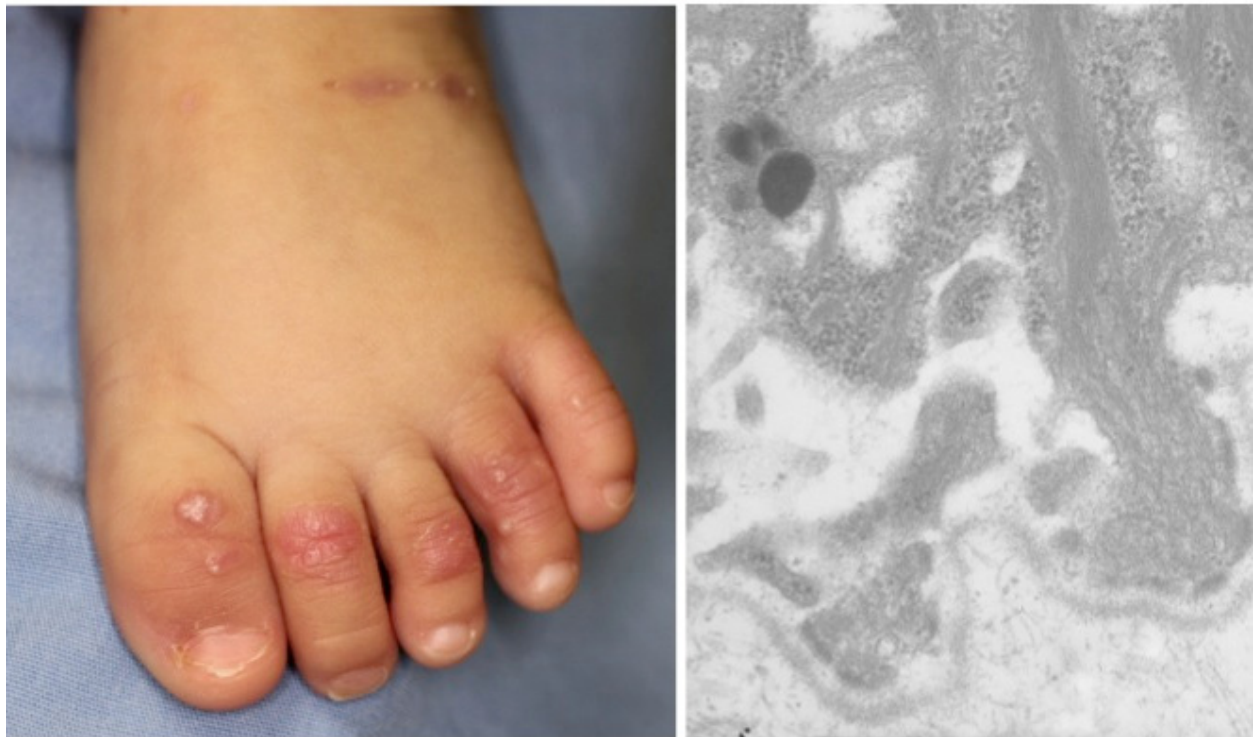The keratin is the most abundant structural proteins found in epithelial cells [6]. The keratins are polymers of type I and type II intermediate filaments [6]. In basal keratinocytes, type I intermediate filament is keratin 14 (K14) and type II intermediate filament is keratin 5 (K5)[6]. These two types of keratins are the major mutated molecules found in EBS [6].

Hemidesmosomes are very tight cell-matrix junction structures which connect basal keratinocytes to the basement membrane [7]. Hemidesmosomes tether keratin filaments to the cell surface [7]. Ultrastructurally, hemidesmosomes comprises the inner plaques, the outer plaques, anchoring fibrils and anchoring filaments [8]. At the molecular level, core of each hemidesmosome comprises of four transmembrane proteins, 180 kDa-bullous pemphigoid antigen (BP180, type XVII collagen, BPAG2),  $\alpha 6\beta 4$  integrins and CD151 tetraspanin protein [7]. Both BP180 and  $\alpha 6\beta 4$  integrin interacts with laminin-332 at the BMZ



**Figure 1.** Molecular components of basement membrane zone.

# IntobOn



# IntobOn

**Figure 2.** Clinical (left) and electronmicroscopical (right) appearances of dystrophic epidermolysis bullosa patient.

[9].  $\alpha 6\beta 4$  integrin is the unique integrin, because the other integrins normally attach to actin, while  $\alpha 6\beta 4$  integrin attaches to intermediate filament, keratin [10].  $\alpha 6\beta 4$  integrin attaches to intermediate filament by plectin [10]. BP180 tethers keratin through the interaction with BP230 in the cytoplasm [10]. Both BP180 and BP230 are the target of major subepidermal autoimmune bullous disease, bullous pemphigoid [11]. Basement membrane is mainly composed of collagen IV [12]. Laminin-332 and collagen VII adhere to collagen IV [7]. All these components are molecules which are affected by EB patients [1].

### 3. JEB (Figure 2)

The manner of inheritance in JEB patients is autosomal recessive [1]. As mentioned above, skin separation in JEB occurs in the lamina lucida [1]. Three subtypes of JEB exist, Herlitz JEB, non-Herlitz JEB and JEB with pyloric atresia [1]. Herlitz JEB is fatal subtype of JEB [1]. Most affected patients die from systemic infection through severe erosion on virtually entire skin [1]. Herlitz JEB is caused by homozygous or compound heterozygous premature termination codon (PTC) mutation of laminin-332 [13,14]. Non-Herlitz JEB is much milder than Herlitz JEB [1]. Either missense mutation of laminin-332 or mutation of BP180 is found in non-Herlitz JEB patients [15-17]. JEB with pyloric atresia is possibly life-threatening subtype, similar to Herlitz JEB [1]. However, JEB with pyloric atresia patients occasionally show non-life-threatening phenotype like non-Herlitz JEB patients [1]. Mutations in  $\alpha 6$  or  $\beta 4$  integrin genes are found in JEB with pyloric atresia patients [1,18,19]. PTC mutations of  $\alpha 6$  or  $\beta 4$  integrin genes are found in severe JEB with pyloric atresia patients, whereas missense mutations of these integrin genes are found in milder subtype of JEB with pyloric atresia patients [1,20].

### 4. DEB

Tissue separation of DEB occurs in the dermis [1]. Clinically, DEB patients show blistering of the skin in the large area along with scarring and milia formation [15]. Two fashions of inheritance are known in DEB, autosomal dominant and autosomal recessive [15]. DEB is known to be caused by mutations in collagen VII gene. More than 300 mutations are reported in DEB [15]. Glycine substitution mutation in one allele of gene encoding the collagenous domain of collagen VII is known to be strongly associated with DEB [21]. Such mutation probably has a dominant negative effect on collagen VII formation or assembly [15]. In the severest form of DEB, Hallopeau-Siemens recessive DEB, PTC mutation on both alleles of gene encoding collagen VII is found [22]. In the mildest form of recessive DEB, non-Hallopeau-Siemens recessive DEB, PTC mutations in one allele, missense or in-frame mutations are found in the genes encoding collagen VII [23].

### 5. Diagnosis

The hallmark of the diagnosis of EB is made by DNA-based mutational analysis [1]. However, it is required to minimize the effort to specify the possible affected gene through

history taking, clinical assessment, histopathological study, immunomapping study and electronmicroscopic study [1]. Using these methods, we can categorize the disease type of patients into at least three forms, EBS, JEB and DEB [1]. Histopathology or electronmicroscopy samples should be taken after gentle rubbing on non-blistered skin, in order not to misdiagnose the location of blister by degeneration of the affected skin [1]. Immunomapping study using anti-K5, K14,  $\alpha 6$  integrin,  $\beta 4$  integrin, BP180, plectin, laminin-332 or collagen VII antibody is quite useful to diagnose EB, if the affected mutation locates on the portion of epitope targeted by these antibodies [1]. In addition, immunohistochemical study using anti-collagen IV antibody is also useful to assess the portion of the split [1]. In EBS or JEB sample, positive staining of collagen IV is found at the floor of the blister, whereas in DEB sample, that is found at the roof of the blister [1]. After these careful assessments, DNA-based diagnoses are performed [1].

## 6. Treatment

Treatment of EB is mainly symptomatic one. Most important issue is to prevent local infection, including *Staphylococcus aureus*, *Streptococcus pyogenes* and *Pseudomonas aeruginosa*. If we fail to control local infection, subsequent sepsis occurs with high possibility. In order to prevent such local infection, semioclusive nonadherent dressings with or without topical antibiotics is selected for the treatment of EB. In addition, as esophageal ocular and oral complications are also found in EB patients, clinical care for erosions in these organs are also required to prevent local infection and resultant sepsis.

Allogeneic skin grafts, in which cells do not derived from patients, were tried for EB patients. These allografts were rejected but could produce cytokines to facilitate the wound healing and re-epithelization process.

## 7. Ongoing therapies

As symptomatic therapy is only available for EB, future gene-targeted therapy is highly expected and is being considered. To attempt to do so, cell-based therapies using fibroblasts and allogeneic bone marrow transplantation are the potential options. As the experimental level, such therapies were successful for JEB and DEB. Collagen VII is known to be synthesized mainly by keratinocytes and to a lesser extent by fibroblasts [19]. As fibroblasts are easy to culture and easy to get transfected by external genes than keratinocytes, cell-based therapies using fibroblasts are selected for the possible gene therapy for DEB [1]. In fact, Goto et al. successfully restores collagen VII by skin collagen VII gene transfected fibroblast introduction [24]. In addition, clinical study for five patients using this technique was already successful without any adverse effects [25]. Cultured patient keratinocytes transfected with laminin  $\beta 3$  gene through retroviral technique were successfully transferred and healed blister formation in one patient. Collagen VII protein therapy was also

introduced and was successful in an in vivo model. The missing or defective protein, synthesized by in vitro recombinant methods, is introduced to blistered skin. Successful treatment was already obtained in case of collagen VII [26,27].

Allogeneic bone marrow transplantation is the other option. In EB patients, basal keratinocytes produce defective gene product of BMZ [1]. It is known that, bone marrow cells have a potential to differentiate into epidermal keratinocytes [17]. Therefore, allogeneic bone marrow transplantation can correct such defective BMZ components. As an experimental level, Chino et al. was successful in correcting ameliorated collagen VII in collagen VII knock out mice by allogeneic bone marrow transplantation [28]. Moreover, clinical trial using this technology and cord blood transplantation were already started and were obtained successful results [1].

## 8. Conclusion

EB is a life-threatening and life-long disease with only symptomatic treatments, thus far. However, cell-based gene-targeting therapy is on the way to be successful.

## Author details

Daisuke Tsuruta\*, Chiharu Tateishi and Masamitsu Ishii

*Department of Dermatology, Osaka City University Graduate School of Medicine, Osaka, Japan*

## 9. References

- [1] Sawamura D, Nakano H, Matsuzaki Y. Overview of epidermolysis bullosa. *J Dermatol.* 2010;37:214-219.
- [2] Salas-Alanis JC, Cepeda-Valdes R, Mellerio JE, Christiano AM, Uitto J. Progress in epidermolysis bullosa: summary of a workshop in CILAD-2010\*. *Int J Dermatol.* 2012;51:682-687.
- [3] Pai S, Marinkovich MP. Epidermolysis bullosa: new and emerging trends. *Am J Clin Dermatol.* 2002;3:371-380.
- [4] Pulkkinen L, Marinkovich MP, Tran HT, Lin L, Herron GS, Uitto J. Compound heterozygosity for novel splice site mutations in the BPAG2/COL17A1 gene underlies generalized atrophic benign epidermolysis bullosa. *J Invest Dermatol.* 1999;113:1114-1118.
- [5] Uitto J, Richard G. Progress in epidermolysis bullosa: from eponyms to molecular genetic classification. *Clin Dermatol.* 2005;23:33-40.
- [6] Coulombe PA, Lee CH. Defining keratin protein function in skin epithelia: epidermolysis bullosa simplex and its aftermath. *J Invest Dermatol.* 2012;132(3 Pt 2):763-775.

---

\* Corresponding Author



- [7] Tsuruta D, Hashimoto T, Hamill KJ, Jones JC. Hemidesmosomes and focal contact proteins: functions and cross-talk in keratinocytes, bullous diseases and wound healing. *J Dermatol Sci.* 2011;62:1-7.
- [8] Shinkuma S, McMillan JR, Shimizu H. Ultrastructure and molecular pathogenesis of epidermolysis bullosa. *Clin Dermatol.* 2011;29:412-419.
- [9] Tsuruta D, Kobayashi H, Imanishi H, Sugawara K, Ishii M, Jones JC. Laminin-332-integrin interaction: a target for cancer therapy? *Curr Med Chem.* 2008;15:1968-1975.
- [10] Jones JC, Hopkinson SB, Goldfinger LE. Structure and assembly of hemidesmosomes. *BioEssays.* 1998;20:488-494.
- [11] Ujiie H, Shibaki A, Nishie W, Shimizu H. What's new in bullous pemphigoid. *J Dermatol.* 2010;37:194-204.
- [12] Abreu-Velez AM, Howard MS. Collagen IV in Normal Skin and in Pathological Processes. *North Am J Med Sci.* 2012;4:1-8.
- [13] Pulkkinen L, Christiano AM, Airenne T, Haakana H, Tryggvason K, Uitto J. Mutations in the gamma 2 chain gene (LAMC2) of kalinin/laminin 5 in the junctional forms of epidermolysis bullosa. *Nat Genet.* 1994;6:293-297.
- [14] Aberdam D, Galliano MF, Vailly J, Pulkkinen L, Bonifas J, Christiano AM, et al. Herlitz's junctional epidermolysis bullosa is linked to mutations in the gene (LAMC2) for the gamma 2 subunit of nicein/kalinin (LAMININ-5). *Nat Genet.* 1994;6:299-304.
- [15] McGrath JA, Pulkkinen L, Christiano AM, Leigh IM, Eady RA, Uitto J. Altered laminin 5 expression due to mutations in the gene encoding the beta 3 chain (LAMB3) in generalized atrophic benign epidermolysis bullosa. *J Invest Dermatol.* 1995;104:467-474.
- [16] McGrath JA, Gatalica B, Christiano AM, Li K, Owaribe K, McMillan JR, et al. Mutations in the 180-kD bullous pemphigoid antigen (BPAG2), a hemidesmosomal transmembrane collagen (COL17A1), in generalized atrophic benign epidermolysis bullosa. *Nat Genet.* 1995;11:83-86.
- [17] Nishie W, Sawamura D, Goto M, Ito K, Shibaki A, McMillan JR, et al. Humanization of autoantigen. *Nat Med.* 2007;13:378-383.
- [18] Vidal F, Aberdam D, Miquel C, Christiano AM, Pulkkinen L, Uitto J, et al. Integrin beta 4 mutations associated with junctional epidermolysis bullosa with pyloric atresia. *Nat Genet.* 1995;10:229-234.
- [19] Georges-Labouesse E, Messaddeq N, Yehia G, Cadalbert L, Dierich A, Le Meur M. Absence of integrin alpha 6 leads to epidermolysis bullosa and neonatal death in mice. *Nat Genet.* 1996;13:370-373.
- [20] Abe M, Sawamura D, Goto M, Nakamura H, Nagasaki A, Nomura Y, et al. ITGB4 missense mutation in a transmembrane domain causes non-lethal variant of junctional epidermolysis bullosa with pyloric atresia. *J Dermatol Sci.* 2007;47:165-167.
- [21] Christiano AM, Ryyanen M, Uitto J. Dominant dystrophic epidermolysis bullosa: identification of a Gly-->Ser substitution in the triple-helical domain of type VII collagen. *Proc Nat Acad Sci.* 1994;91:3549-3553.
- [22] Hilal L, Rochat A, Duquesnoy P, Blanchet-Bardon C, Wechsler J, Martin N, et al. A homozygous insertion-deletion in the type VII collagen gene (COL7A1) in Hallopeau-Siemens dystrophic epidermolysis bullosa. *Natu Genet.* 1993;5:287-293.



- [23] Christiano AM, Greenspan DS, Hoffman GG, Zhang X, Tamai Y, Lin AN, et al. A missense mutation in type VII collagen in two affected siblings with recessive dystrophic epidermolysis bullosa. *Nat Genet.* 1993;4:62-66.
- [24] Goto M, Sawamura D, Ito K, Abe M, Nishie W, Sakai K, et al. Fibroblasts show more potential as target cells than keratinocytes in COL7A1 gene therapy of dystrophic epidermolysis bullosa. *J Invest Dermatol.* 2006;126:766-772.
- [25] Wong T, Gammon L, Liu L, Mellerio JE, Dopping-Hepenstal PJ, Pacy J, et al. Potential of fibroblast cell therapy for recessive dystrophic epidermolysis bullosa. *J Invest Dermatol.* 2008;128:2179-2189.
- [26] Woodley DT, Keene DR, Atha T, Huang Y, Ram R, Kasahara N, et al. Intradermal injection of lentiviral vectors corrects regenerated human dystrophic epidermolysis bullosa skin tissue in vivo. *Molecular therapy : J Am Soc Gen Ther.* 2004;10:318-326.
- [27] Woodley DT, Keene DR, Atha T, Huang Y, Lipman K, Li W, et al. Injection of recombinant human type VII collagen restores collagen function in dystrophic epidermolysis bullosa. *Nat Med.* 2004;10:693-695.
- [28] Chino T, Tamai K, Yamazaki T, Otsuru S, Kikuchi Y, Nimura K, et al. Bonemarrow cell transfer into fetal circulation can ameliorate genetic skin diseases by providing fibroblasts to the skin and inducing immune tolerance. *Am J Pathol.* 2008;173:803-814.