

# We are IntechOpen, the world's leading publisher of Open Access books Built by scientists, for scientists

**4,800**

Open access books available

**122,000**

International authors and editors

**135M**

Downloads

Our authors are among the

**154**

Countries delivered to

**TOP 1%**

most cited scientists

**12.2%**

Contributors from top 500 universities



**WEB OF SCIENCE™**

Selection of our books indexed in the Book Citation Index  
in Web of Science™ Core Collection (BKCI)

Interested in publishing with us?  
Contact [book.department@intechopen.com](mailto:book.department@intechopen.com)

Numbers displayed above are based on latest data collected.

For more information visit [www.intechopen.com](http://www.intechopen.com)



---

# Implication of Clear Cell and Mucinous Histology

---

Jun Naniwa, Hiroaki Itamochi and Junzo Kigawa

Additional information is available at the end of the chapter

<http://dx.doi.org/10.5772/54931>

---

## 1. Introduction

The incidence of ovarian cancer in 2008 was projected to be 225,500 new cases and 140,200 deaths worldwide, representing 3.7% of all female cancers and 4.2% of all cancer deaths in women [1]. Ovarian cancer, one of the major causes of death from cancer in women, is commonly diagnosed at an advanced stage. Cytoreductive surgery followed by chemotherapy combining platinum and taxane is currently the standard treatment for ovarian cancer [2]. Ovarian cancer is one of the most sensitive solid tumors, with objective responses ranging from 60 to 80% even in patients with advanced stage. However, most patients ultimately recur and develop resistance to platinum and taxane.

Resistance to chemotherapy presents a major obstacle in attempting to improve the prognosis of patients with ovarian cancer. Accordingly, it is important to elucidate the mechanisms of chemoresistance to manage ovarian cancer. Recently, the biological characteristics of ovarian cancer have been clarified. It has long been known that ovarian cancers of serous histology appear to be more sensitive to chemotherapy than other histological subtypes. Patients with clear cell carcinoma or mucinous adenocarcinoma of the ovary showed a significantly worse prognosis in a retrospective review of several Gynecologic Oncology Group (GOG) trials [3]. Therefore, it is important to determine optimal regimens based on histological subtype. In this chapter, clear cell carcinoma and mucinous adenocarcinoma of the ovary are discussed.

## 2. Clear cell carcinoma

Clear cell carcinoma (CCC) has unique clinical and biological features [4]. In North America and Europe, CCC is the third most common histological subtype of epithelial ovarian cancer (EOC), with an estimated prevalence of 1-12% [5, 6]. For unknown reason, CCC comprises more than

20% of such cancers in Japan [7-9]. Interestingly, among Asian women living in the United States, CCC was diagnosed twice as frequently (11.1%) compared to Caucasians (4.8%) [10].

Several studies have analyzed the risk factors for ovarian cancer by histologic subtype. CCC was associated (odds ratio: 2.2-2.3) with an increased body mass index (BMI 30) [11, 12]. However, in the NIH-AARP Diet and Health Study BMI was correlated only with endometrioid histology [13].

It has long been recognized that CCC often is associated with endometriosis (22-70%), whereas hobnail cells bear a very strong morphological resemblance to endometrial Arias-Stella cells [14, 15]. Several studies have reported that endometriosis frequently shows a sequential change to EOC, including CCC. Therefore, atypical endometriosis is considered to be a precancerous change. Ovarian cancers associated with endometriosis tend to occur in younger women, and present 5-6 years earlier, on average, than high-grade serous carcinoma (HGSC) [16]. In National Cancer Institute Surveillance, Epidemiology and End Results (SEER) data, women with CCC were younger than patients with serous adenocarcinoma (SAC) (55 vs. 64 years; median age) [10].

An increased incidence of vascular thromboembolic complications is seen in patients with CCC [17, 18]. Up to 40% of patients with CCC may develop thromboembolic disease and this rate is double that in matched non-CCC controls with ovarian cancers [19].

### 3. Clinicopathological features

Ovarian CCC usually presents as a large pelvic mass [20, 21]. The size of masses range from 3 to 20 cm, with most tumors detected preoperatively either by clinical examination or imaging. Recent reports involving large institutional cohorts compared early-stage (I/II) to advanced-stage ovarian cancers (III/IV) and showed that 57-81% of CCC were diagnosed at an early stage [9, 22]. In SEER data, 56% of CCC were stage I, compared to 19% for SAC [10]. Combining the low overall incidence of CCC and their early stage propensity, CCC may make up only 1-5% of advanced stage patients in chemotherapy trials, largely due to their overall low incidence and tendency for early stage distribution at the time for initial diagnosis [6].

Sugiyama, et al. [9] retrospectively reviewed 101 patients with CCC in Japan who underwent complete surgical staging to determine clinicopathological features of CCC. Histologic evaluation was performed under central pathological review. Tumors were diagnosed as CCC if the following appeared in 90% or more of all specimens: a small to large sheet of polyhedral clear cells with delicate fibrovascular septa, tubules and papillae, clear or hobnail, or eosinophilic cells of organoid appearance, or clear cells with coalescent vacuoles containing "targetoid" eosinophilic PAS-positive globules. Of the 662 patients with EOC, 101 (15.3%) had CCC and 235 (35.5%) SAC. All patients underwent complete surgical staging, including intraperitoneal cytology, bilateral salpingo-oophorectomy, hysterectomy, omentectomy, pelvic-/paraortic lymphadenectomy, and aggressive cytoreductive surgery for advanced cases. Ninety-seven (96%) of 101 patients with CCC and 229 (97%) of 235 with SAC underwent platinum-based chemotherapy after initial surgery.

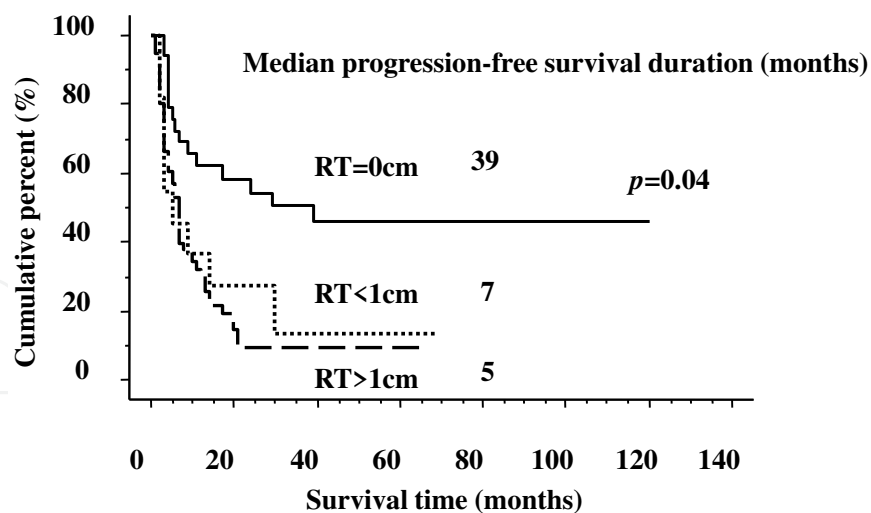
The median age did not differ between patients with CCC and those with SAC. The percentage of patients at stage I was significantly higher in CCC than SAC (16.6%), while significantly fewer patients were at stage III had CCC than SAC (61.7%). By contrast, the incidence of stage III was significantly lower in CCC than in SAC. Recurrence in patients with CCC occurred in 29% of stage I patients, 30% of stage II, 62% of stage III, and 73% at stage IV. Although none of the patients with stage Ia CCC relapsed, 14 of 38 patients (37%) with stage Ic did relapse.

In stage III disease the median survival time was significantly shorter for patients with CCC than those with SAC. The survival rate for patients at stage III was significantly lower in the CCC group than in the SAC group. Although estimated survival rates at 3 and 5 years in patients with no gross tumor did not differ significantly between CCC and SAC, survival rates in both patients with <2 cm and >2 cm residual disease were significantly lower in CCC than in SAC. Jenison, et al. [23] showed that the survival rates for CCC were consistently lower in each of the FIGO stages compared with SAC, although there was no statistical significance. In their study, median survival time for stage I patients with CCC was significantly shorter than that for those with SAC. Similarly, the survival rate for patients with stage Ic CCC was lower compared with patients with stage Ic SAC. Additionally, the median survival time for stage I patients with CCC was worse than those with SAC (31.8 months vs 42.3 months) and the time to recurrence in patients with stage I/II CCC was definitely shorter (12.2 months) [9]. Twenty-seven patients with stage III/IV CCC had measurable disease after initial surgery. The overall clinical response rate for SAC was 72.5%. In contrast, only three (11.1%) of 27 patients responded to platinum-based chemotherapy in CCC. Patients with CCC showed a very low rate of response and a high incidence of progressive disease. Another authors demonstrated that platinum-based chemotherapy did not appear to improve the survival of patients with CCC, compared with survival after non-platinum-based chemotherapy [24]. Additionally, CCC patients with residual tumor showed a high recurrence rate (Fig 1). CCC has a more aggressive course and a more malignant behavior than SAC. Therefore, new treatment strategies for CCC, including alternative regimens of chemotherapy, should be established.

#### **4. Mechanisms of platinum resistance in CCC of the ovary**

There is general acceptance of CCC that is insensitive to conventional platinum-based chemotherapy lead to a poor prognosis. Resistance to cisplatin (CDDP) is an important factor in the poor prognosis of patients with CCC. Several mechanisms involved in drug resistance have been proposed as explanations, including decreased drug accumulation, increased drug detoxification, increased DNA repair activity, and activation of receptor tyrosine kinases and its downstream signaling pathways [25-29].

Adenosine 5'-triphosphate (ATP)-binding cassette (ABC) transporters, such as ABCB1 (also known as P glycoprotein), ABCC1 (multidrug resistance associated protein-1) and ABCC3, are known to lower intracellular drug concentrations and are important multidrug resistance factors [30]. An immunohistochemical study of ABCB1 and ABCC1 in CCC and SAC tumors revealed that their expression of these transporters did not differ between CCC and SAC [31].



**Figure 1.** Progression free survival rate for stage III and IV patients, and residual tumor diameter. Progression free survival rates for the patients without residual disease were significantly greater, but there was no significant difference between those with <1 cm residual disease and with >1 cm. RT: residual tumor diameter

In addition, no significant differences were observed in the expression of ABCB1 and ABCC1 between responders and non-responders to platinum-based chemotherapy in both tumor types. These results suggest that multidrug resistance proteins do not contribute to chemoresistance in CCC. Ohishi, et al. [32] examined the expression of mRNA by ABCC superfamily members, ABCC1, ABCC2, and ABCC3, in CCC and SAC tumors. They found that only ABCC3 genes were expressed significantly more in CCC than SAC. Therefore, they concluded that increased expression of ABCC3 may, at least in part, be associated with the chemoresistant phenotype of CCC.

Several drug detoxification systems also can diminish intracellular drug activity. Cellular detoxification via the glutathione system is known to be involved in the metabolism of various cytotoxic agents, including the platinum agents, etoposide (VP-16), and mitomycin C (MMC) [27, 28, 33, 34]. Indeed, the glutathione concentrations in CCC cell lines increased significantly after exposure to CDDP or MMC [35]. A gene expression study showed that glutathione peroxidase 3 (GPx3), glutaredoxin (GLRX), and superoxide dismutase (SOD2) were expressed highly in CCC tumors and that the elevated levels of these, and perhaps other, antioxidant proteins may render the tumors more resistant to chemotherapy [36].

Nucleotide excision repair (NER) is a multienzyme DNA repair pathway in eukaryotes that has been implicated in drug resistance in human tumor cells [37]. Reed, et al. [38] examined the mRNA expression of two key genes, excision repaircross-complementing rodent repair deficiency, complementation group 1 (ERCC1) and xeroderma pigmentosum group B (XPB), that are involved in the NER pathway of EOC tumors. Expression of ERCC1 and XPB were higher in CCC tumors than in other histological tumor types. This phenomenon may be related to de novo drug resistance against chemotherapeutic agents in CCC. DNA mismatch repair systems (MMR), which correct errors that occur during DNA replication, also play a critical role in the sensitivity of DNA damaging agents. In experimental systems, cells deficient in

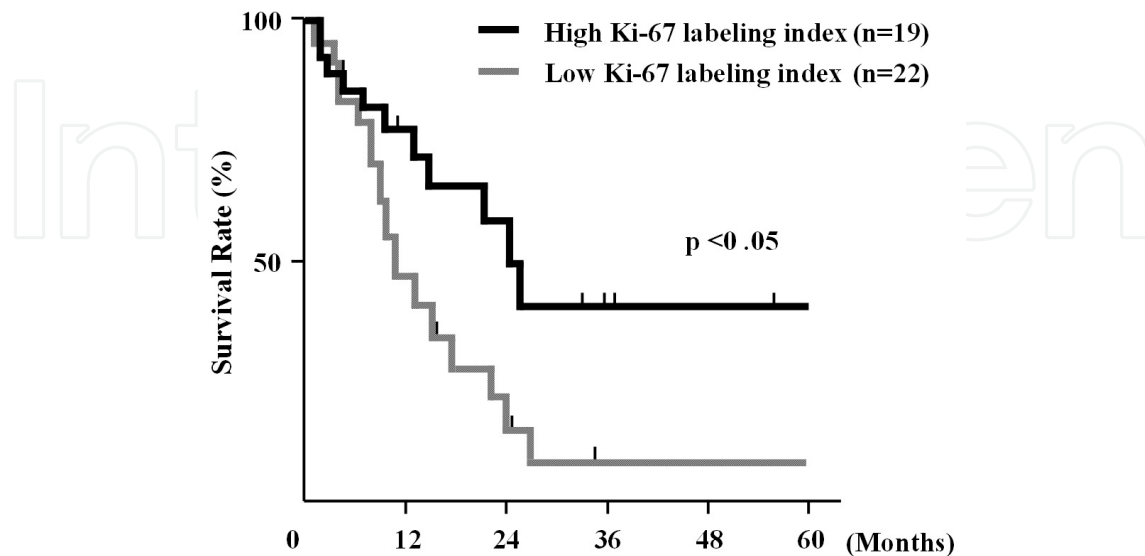
MMR are highly tolerant to the methylating chemotherapeutic drugs streptozocin and temozolomide and, to a lesser extent, CDDP and doxorubicin [39]. Loss of MMR may be caused either by a germline mutation of two major MMR genes, hMLH1 or hMSH2, or by somatic MMR gene inactivation through epigenetic silencing via methylation of the hMLH1 promoter. Cai, et al. [40] reported that elevated expression of hMLH1 and hMSH2 proteins are involved in the development of a subset of CCC, and that there is a strong correlation between alterations in the expression of hMLH1 and hMSH2 and the presence of MSI in CCC tumors.

Epidermal growth-factor receptor (EGFR) and v-erb-b2 erythroblastic leukemia viral oncogene homolog 2 (ERBB2; HER2) are cell-surface-receptor tyrosine kinases and can activate both the signaling pathways of mitogen-activated protein kinase and phosphatidylinositol 3'-kinase (PI3K)-Akt [41]. Activating these pathways leads to phosphorylated Bcl-2 antagonist cell death (BAD) and B-cell leukemia/lymphoma (Bcl)-2, thereby inhibiting chemotherapy-induced apoptosis [42]. An immunohistochemical study showed found EGFR in 61% of CCC tumors [43]. Molecular analyzes of various types of ovarian tumors showed HER2 to be overexpressed in CCC relative to other major histological types of EOC [44]. In ovarian cancer, the HER2 protein is overexpressed as a consequence of HER2 gene amplification in 20 to 25% of cases and predicts a poor prognosis [45, 46].

Cell proliferation is controlled by cyclin-dependent kinases (CDK), which are regulated by cyclin binding, phosphorylation, and CDK inhibitors (e.g. p16, p21, and p27) [47]. p53, known as a tumor suppressor protein, also up-regulates expression of p21 and causes cell the cycle to arrest at G1. Changes in the p53 gene are seen in 50 to 70% of cases of advanced serous adenocarcinoma [48, 49]. In contrast, the p53 mutation is rare in CCC, and immunohistochemical staining shows that CCC tends to express little or no p53 protein [50]. Cytotoxic drugs are primarily effective against proliferating cells; therefore, quiescent cells show a degree of resistance relative to cycling cells [51]. Dimanche-Boitrel, et al. [52] reported that less intracellular drug accumulates in resting cells. Itamochi et al. examined the proliferation activity and CDDP sensitivity of 11 CCC and 5 SAC cell lines, and this found that the doubling time for CCC cells was significantly longer than for SAC (61.4 vs 29.8 h) [7]. There was a significant reverse correlation between the S-phase fraction and the response to CDDP. These findings may relate to the high incidence of stage I patients with CCC, and also suggests that the resistance of CCC to CDDP may be caused by low cell proliferation. In addition, Ki-67, a nuclear antigen expressed in all states of the cell cycle except in resting cells in G0, has a significantly lower labeling index in CCC than in SAC [31]. Furthermore, a significantly higher Ki-67 labeling index (LI) is observed in responders than in non-responders in both CCC and SAC tumors.

The 5-year survival rate for high LI patients (over 18.4%; mean value for CCC) was significantly greater than that for low LI (less than 18.4%) ( 46.3% vs. 9.2%,  $p < 0.05$ ) (Fig. 2). A multivariable analysis revealed that the Ki-67 labeling index and residual tumor size were independent prognostic factors. Other authors have reported that immunohistochemical staining of CCC reveals a low expression of Ki-67, p53, and cyclin A, and significantly increased expression of both p21 and cyclin E, which are other histological subtypes [53]. These results suggest that

CCC has low tumor proliferation activity and that this low proliferation activity in CCC could be associated with chemoresistance.



**Figure 2.** Estimated survival rates for patient with clear cell carcinoma. When the cut-off value of Ki-67 labeling index (LI) was set at 18.4% (the mean value of clear cell carcinoma), the estimated 5-year survival rate for elevated Ki-67 LI patients was significantly greater than that for low Ki-67 LI (46.3% vs. 9.2%).

## 5. Future directions

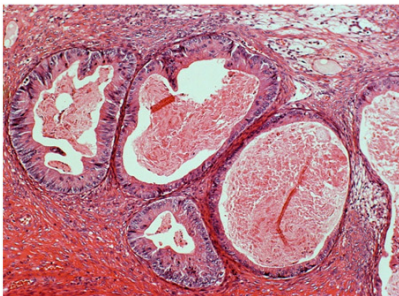
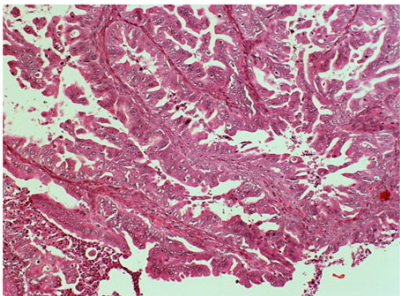
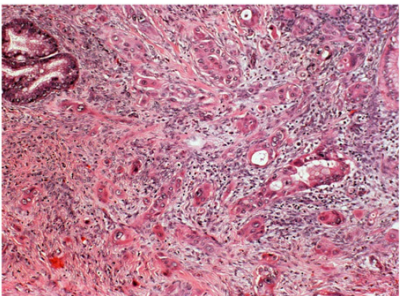
The clinicopathological features of CCC suggest that a new strategy for chemotherapy in CCC should be adopted, focusing on new agents without cross-resistance to platinum agents. Several anticancer agents with no cross-resistance to platinum analogues, such as paclitaxel (PTX), VP-16, and camptothecin (CPT-11) have been developed.

Activating the PI3K/Akt pathway and its downstream signaling mammalian target of rapamycin (mTOR) seems to indicate drug resistance and poor prognosis in many cancers. It has been reported that CCC has a high frequency of activating mutations of PIK3CA [54]. Because it is known well that activation of Akt signaling results in hypersensitivity to mTOR inhibition, CCC may be a good candidate for therapy with an mTOR inhibitor. Several clinical trials have shown potential antitumor activities for mTOR inhibitors (everolimus, deforolimus, and temsirolimus) in solid tumors. Temsirolimus (CCI779, a synthetic, ester analog of rapamycin) is indicated to treat advanced renal cell carcinoma. A phase II study is ongoing to evaluate the safety and efficacy of temsirolimus in combination with carboplatin and PTX followed by temsirolimus consolidation as first-line therapy for patients with stage III-IV CCC in the ovary (NCT01196429, ClinicalTrials.gov). We hope this combination therapy will improve the survival of patients with ovarian CCC.

## 6. Mucinous adenocarcinoma

Ovarian mucinous adenocarcinoma (MAC) is divided into intraepithelial and invasive carcinomas (Fig. 3). Intraepithelial mucinous carcinoma is characterized by marked epithelial atypia in the absence of stromal invasion. Invasive mucinous carcinoma is diagnosed once stromal invasion measuring more than 5 mm or more than 10 mm<sup>2</sup> is detected. Two types of invasive mucinous carcinoma are recognized: expansile and infiltrative. The former is characterized by confluent glandular growth uninterrupted by normal ovarian parenchyma, while the latter demonstrates a presence of small glands, nests or individual cells infiltrating the stroma.

Mucinous tumor of borderline malignancy	Mucinous intraepithelial carcinoma	Mucinous invasive carcinoma
Complex architecture	Basically borderline tumor	Expansile type or infiltrative type
No stromal invasion	No definite stromal invasion	Obvious invasion (>5mm)
Grade 1 atypia	Grade 2-3 atypia	

**Figure 3.** Criteria for central pathological review.

Intraepithelial mucinous carcinoma, FIGO stage I, has a recurrence rate of 5.8% [55]. Invasive mucinous carcinoma, FIGO stage I, has a 5-year survival rate of 91%. Patients with advanced tumors usually die of the disease [56]. Invasive mucinous carcinoma with an infiltrative pattern has a more aggressive course than mucinous carcinoma with an expansile pattern. Interestingly, invasive mucinous carcinoma of the ovary often coexists alongside areas of mucinous borderline lesions and benign mucinous cystadenomas, suggesting that these lesions may be precursors to invasive tumors [57].

Winter, et al. [3] reviewed the data from 6 GOG phase III trials of adjuvant chemotherapy with CDDP and PTX in women with stage III EOC after primary debulking surgery, both optimal and suboptimal. Of the 1,895 patients included in these 6 studies, 74% had SAC, while only 2% had MAC. The authors found that women with mucinous tumors had a progression-free survival of 10.5 months, compared to 16.9 months for women with serous tumors. Women with MAC had a relative risk of progression of 2.18 compared their serous counterparts



( $p < 0.001$ ) [69]. The relative risk of death from MAC for compared to SAC was 4.14 ( $p < 0.001$ ). Shimada, et al. [58] compared 24 women with primary MAC to 189 women with SAC and found response rates to platinum-based regimens of 12.5 % and 37.7% respectively. Pectasides, et al. [59] compared 47 women with advanced stage primary MAC to 94 with advanced-stage SAC, all of whom had received a platinum-based regimen in 1 of 9 Hellenic Cooperative Oncology Group studies. The authors found a better response rate in women with SAC (70% for serous vs 38.5 % for mucinous), although this did not translate into survival differences between the 2 groups.

## 7. Clinicopathological features

Seidman, et al. [60] carefully reviewed the pathology of 220 consecutive cases of epithelial ovarian cancer. After excluding carcinosarcomas and primary peritoneal cancers, they found the incidence of primary MAC to be 3.4%. Other authors reviewed 1400 cases of EOC from 14 centers in Japan [58]. In this large group, 16% patients had an initial diagnosis of invasive primary mucinous ovarian cancer. However, after a careful pathologic review, only 4.9% had invasive primary ovarian cancer, with the remainder reclassified as either mucinous intraepithelial carcinoma, mucinous borderline tumors, or metastases from another site. Seidman and colleagues argue that these lower estimates are likely a more accurate reflection of the incidence of mucinous ovarian cancer because the following problems were likely in the literature: (1) misclassification of a gastrointestinal primary tumor as an ovarian primary tumor (80% of mucinous epithelial tumors found in the ovary are extraovarian in origin); (2) misclassification of a mucinous borderline tumor as an invasive cancer; and (3) classification of pseudomyxoma peritoneii as being of ovarian origin when it is now standard to consider all such cases as intestinal in origin.

Mutations in KRAS, BRCA, and p53 are the most frequently studied single gene alterations in ovarian cancer pathogenesis. Some investigators have gone beyond analysis of single gene mutations and have used gene expression analysis to evaluate differences between serous and mucinous ovarian carcinomas. Marchini, et al. [61] carried out genomic analyses using a microarray chip with 16,000 genes and found that serous and mucinous tumors were easily distinguished on the basis of expression profiles. Using a probe set of 59,000 genes, Heinzelmann-Schwarz, et al. [62] likewise found clear separation in expression profiles between serous and mucinous tumors of the ovary.

The role of the KRAS oncogene has been explored extensively in EOC. The RAS family of G proteins is part of the pathway that signals cell division. Mutations in the RAS genes have been found to stimulate cell growth [63]. In the literature, 50% of MAC had KRAS mutations, compared to only 5% of SAC, 10% of endometrioid ovarian carcinomas, and no CCC [64]. Interestingly, the same KRAS mutations found in invasive mucinous tumors also are found in adjacent borderline and benign mucinous lesions in the same specimens [65].

Mutations of BRCA1 and BRCA2 are thought to play a significant role in developing SAC but not MAC. BRCA1 and BRCA2 are tumor suppressor genes that help to repair damaged DNA

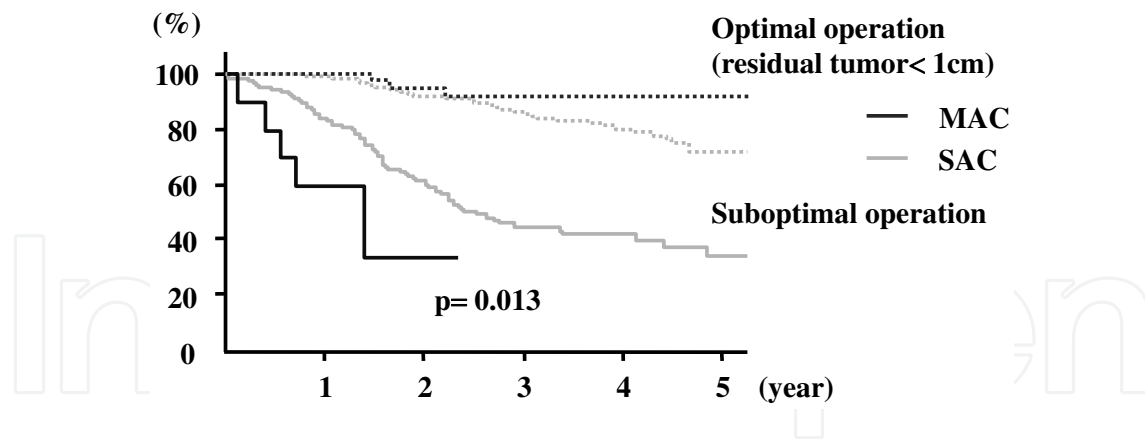
and are commonly mutated not only in inherited SAC but also in many cases of sporadic SAC. Tonin, et al. [66] reviewed the histopathologic subtypes of ovarian carcinomas in 58 families with hereditary breast and ovarian carcinomas. In those patients with known BRCA mutations, 64% had SAC, and only 2% had MAC. In contrast, among women with ovarian cancer negative for BRCA mutation, 29% had MAC, and this proportion was significantly higher than among women with BRCA mutation. Similarly, in a review of the literature that included 636 BRCA mutation-positive women with ovarian cancer, only 2% were found to have mucinous subtypes. p53 also seems to play a prominent role in carcinogenesis of serous ovarian tumors but not mucinous ovarian tumors [70]. Mutations in p53 have been found in almost 60% of serous tumors but in only 16% of mucinous tumors.

The expression of multiple individual proteins has been examined in serous and mucinous tumor specimens using immunohistochemical stains. Compared to serous tumors, mucinous tumors are more likely to express E-cadherin (62% vs. 4%,  $p < 0.001$ ) and less likely to stain positive for N-cadherin (8% vs. 68%,  $p < 0.001$ ). The cadherin family of glycoproteins helps cells establish contact with other cells and stabilize tissue architecture. The matrix metalloproteinases, which also play a role on cell migration and adhesion, have also been found to be expressed differently between serous and mucinous tumors. Kobel, et al. evaluated 21 proteins with immunohistochemistry in 500 ovarian cancer specimens. They found different expression between serous and mucinous subtypes in 20 of the 21 biomarkers they examined, including p53, cadherin, metalloproteinase, CA125, and WT-1. Collectively, these and other molecular studies point toward a distinct pathogenesis of MAC compared to other histological subtypes of ovarian cancer.

The majority of MAC are either well or moderately differentiated and this contributes to the low risk of relapse for FIGO stage I tumors. It also is known that patients at an early stage show good outcomes. On the other hand, patients with advanced mucinous adenocarcinoma are recognized to have poorer outcomes. There was no significant difference in survival between mucinous invasive adenocarcinoma and SAC in patients with optimal surgical management [58]. In contrast, patients with suboptimal therapy showed a significantly worse prognosis than those with SAC (Fig 4).

When a mucinous tumor is grossly limited to the ovary, there is little chance of occult lymph node metastasis. Cho, et al. [71] reviewed 26 cases of MAC noted to be grossly stage I intraoperatively. All of these patients underwent lymphadenectomy as part of their staging procedures, and none were found to have lymph node disease. In contrast, 10% of patients with apparent stage I SAC of the ovary have been reported to have occult nodal metastasis at the time of diagnosis. Using the Swedish Family Cancer Database of over 6,000 women with a diagnosis of ovarian cancer showed that the average overall survival was 34 months in women with serous subtypes, compared to 70 months for women with mucinous subtypes [72]. In addition, the hazard ratio for cause-specific survival from MAC compared to SAC was 0.49 (95% confidence interval, 0.41-0.57); the corresponding hazard ratio for overall survival was 0.56 (95% confidence interval, 0.48-0.64).

Patients with advanced-stage MAC had a worse prognosis than women with nonmucinous EOC [73]. The authors matched 27 patients with MAC to 54 patients with nonmucinous ovarian



**Figure 4.** Overall survival and residual tumor in mucinous adenocarcinoma (MAC). There was no significant difference in survival between mucinous invasive adenocarcinoma and serous adenocarcinoma (SAC) in patients with optimal surgical management. In contrast, patients with suboptimal surgery showed a significantly worse prognosis than those with serous adenocarcinoma.

cancer (2:1), all of whom had stage III or IV disease and had undergone primary therapy. There was no difference between patients with the mucinous tumors and nonmucinous with regard to histological grade, stage, optimal or suboptimal debulking, chemotherapy regimen, or length of follow-up. Patients with advanced MAC had a progression-free survival of 5.7 months, compared to 14.1 for patients with nonmucinous ovarian cancer, and an overall survival of 12.0 compared to 36.7 months.

## 8. Pathological diagnosis for MAC

Most MAC involving the ovary prove to be metastases, as opposed to ovarian primary carcinomas. Therefore, surgeons and pathologists must have a high suspicion toward metastatic disease when considering the origin of MAC found in the ovary. Seidman, et al.[74] found that only 23% of invasive mucinous carcinomas of the ovary were primary ovarian cancer. Most clinicians assume that metastases to the ovary have a gastrointestinal origin. However, although gastrointestinal tract tumors are the most common source of ovarian metastases, accounting for 45% of such tumors, they also see ovarian metastases from primary tumors of the pancreas (accounting for 20% of ovarian metastases), cervix (13%), breast (8%), and uterus (5%). The remaining 10% of ovarian metastases are from unknown primary tumors [68].

At surgical exploration a working differential diagnosis can be developed on the basis of tumor size and laterality. Among unilateral tumors, more than 80% of those larger than 10 cm are ovarian primary tumors, while 88% of those smaller than 10 cm are metastases. This division has been retrospectively validated by other investigators, who showed it to be correct 84% of the time in differentiating primary from metastatic mucinous carcinomas of the ovary [74]. Other authors also have found this algorithm is useful in predicting the site of origin for ovarian carcinomas [75, 76]. In addition, primary ovarian carcinomas tend to have a smooth capsule, while ovarian metastases often involve the gross ovarian surface. However, the algorithm

presented above and the status of the ovarian surface should be used clinically with caution: in one study, up to 24 % of the cases of colonic adenocarcinoma metastatic to the ovary showed unilateral ovarian involvement with tumor measurements of at least 10 cm [77]. In the same study, 46% of the cases with available information on gross intraoperative appearance had a smooth capsule.

Although gross examination of the adnexae can often predict the site of origin, both ovarian and extraovarian sources of primary disease should be explored. Intraoperatively, the surgeon should perform a careful exploration of potential gastrointestinal sources, including palpating the pancreas and running the entire small and large bowel. Postoperatively, the surgeon should consider a colonoscopy and mammogram if these screening tests have not been performed within the year prior to diagnosis.

Although the presence of certain histological features can favor a diagnosis of primary MAC over metastasis, there are cases where a definitive diagnosis cannot be provided due to the presence of discordant or overlapping features. Microscopic features that favor the diagnosis of primary ovarian MAC include a coexisting borderline and benign mucinous components, an expansile pattern of invasion, and a coexisting ovarian teratoma, Brenner tumor, or mural nodule. In contrast, the following microscopic features favor the diagnosis of metastatic adenocarcinoma to the ovary: (1) prominent desmoplastic response, (2) nodular pattern of invasion (i.e., tumor nodules among structures indigenous to the ovarian parenchyma), (3) small clusters of tumor cell within the corpora lutea or albicantia, (4) numerous pools of mucin dissecting the ovarian stroma (i.e., pseudomyxoma ovarii) in the absence of a coexistent ovarian teratoma, (5) an extensive signet ring cell pattern, (6) ovarian surface involvement, (7) vascular invasion, (8) hilar involvement, and (9) an extensive infiltrative pattern of invasion.

Immunohistochemistry may help determine the primary site of a mucinous carcinoma. Primary ovarian mucinous carcinomas tend to be positive for CK7 and CK20 with a predominance of CK7 expression, while colorectal primaries tend to express CK20 only. In addition, colorectal cancers usually express racemase and beta-catenin while primary mucinous ovarian cancers do not. In regard to other gynecological primaries metastatic to the ovary, it is worth mentioning that Human Papilloma Virus (HPV) in situ hybridization can confirm an endocervical origin because most of the endocervical adenocarcinoma are related to HPV. p16 immunostaining is useful only in well differentiated adenocarcinoma cases where a diffuse staining will be in keeping with an endocervical origin.

Attention must be paid to the fact that high-grade ovarian mucinous or endometrioid adenocarcinomas can be positive for p16. Estrogen and progesterone receptors usually are expressed in endometrioid carcinomas, metastasizing from the endometrium or primary to the ovary. Metastatic endocervical adenocarcinomas in ovaries cannot be distinguished from a primary mucinous carcinoma of the ovary because both tumors are progesterone receptor negative and usually negative for estrogen receptors, although they can have variable expression for the latter (weak/diffuse or strong/focal staining) [78]. The presence of mesothelin, fascin, and prostate stem cell antigen (PSCA) favor a pancreatic primary, while the presence of expressed Dpc4 favors an ovarian primary for differentiating primary ovarian tumors from metastasis from the pancreas [79]. Most breast cancers are CK7-positive/CK20-negative, unlike ovarian

primaries which typically express both. In addition, breast cancers almost always express estrogen receptors as well as gross cystic disease fluid protein (GCDFP)- 15 [80]. Mucinous ovarian carcinomas are unlikely to express these markers.

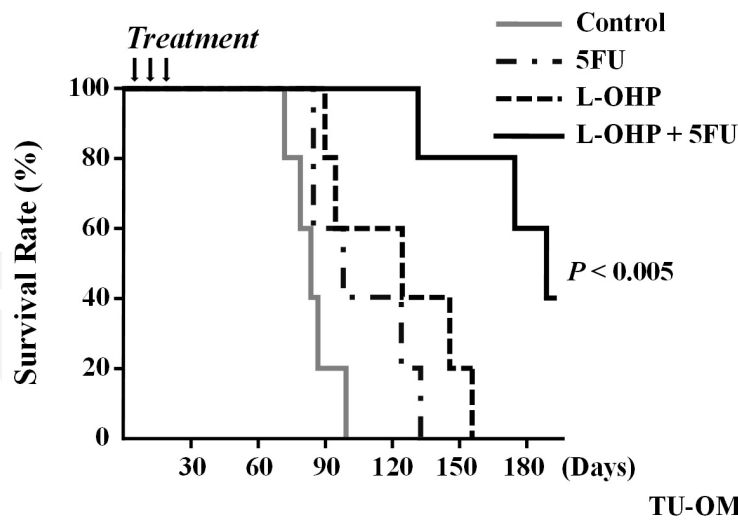
Carcinoembryonic antigen (CEA) is a well known serum tumor marker for gastrointestinal carcinomas. CEA has been noted to be elevated in almost one third of all ovarian carcinomas. However, CEA is much more likely to be elevated in mucinous ovarian carcinomas than in nonmucinous ovarian carcinomas (88% vs 19%) [81, 82]. Nolen, et al. [83] compared the levels of 58 serum biomarkers in serous ovarian carcinomas to mucinous, clear cell, and endometrioid ovarian carcinomas. Using immunoassays, they found significant differences between the 2 groups for 10 of the biomarkers examined. SAC had significantly higher levels of CA125, follicle-stimulating hormone, luteinizing hormone, and SMRP. Mucinous tumors had higher levels of CA72-4, matrixmetalloproteinase-9, CD40L, insulin-like growth factor-binding protein-1, myeloperoxidase, and tissue plasminogen activator-1.

## 9. Future directions

Realizing that MAC is a disease distinct from SAC, several collaborative groups have proposed innovative prospective chemotherapy protocols for patients with advanced or recurrent MAC. Sato, et al. [84] evaluated 6 different cytotoxic agents in 5 different primary mucinous ovarian cancer cell lines. All 5 cell lines resisted platinum agents and taxanes given as single agents. However, 2 of the 5 cell lines were sensitive to oxaliplatin, VP-16, and 5-fluorouracil (5-FU) as single agents. The investigators then treated the cell lines with oxaliplatin plus VP-16 and oxaliplatin plus 5-FU. They found that oxaliplatin with 5-FU had significant inhibition in 4 of the 5 cell lines, whereas the combination of oxaliplatin plus VP-16 was active in only 1 of the 5 cell lines. Moreover, the combination of oxaliplatin plus 5-FU appeared to be synergistic by providing significantly more inhibition than either drug alone. The authors then applied the cell line results to a mouse model of mucinous ovarian cancer xenograft and found that mice treated with oxaliplatin plus 5-FU survived significantly longer than mice treated with either agent alone or control mice treated with placebo (Fig 5).

These basic studies led to a single-arm phase II trial of S-1 and oxaliplatin that currently is enrolling women with advanced or recurrent mucinous ovarian cancer in. S-1 is an orally active drug made by Taiho Pharmaceuticals that combines 3 separate molecules. The first is tegafur, a prodrug that is converted to fluorouracil in cells. Next is gimeracil, an inhibitor of dihydropyrimidine dehydrogenase, an enzyme that degrades fluorouracil. The third component is oteracil, a molecule that inhibits the phosphorylation of fluorouracil in the gastrointestinal tract, reducing gastrointestinal toxicities. The primary endpoint of the study is response rate; secondary endpoints are toxicity, progression-free survival, and overall survival.

The GOG and the Gynecologic Cancer Intergroup (GCIG) are about to begin accrual to a 4-arm, phase III, randomized study comparing carboplatin and PTX with and without bevacizumab to oxaliplatin and capecitabine with and without bevacizumab in women with stage II-IV or recurrent, untreated, stage I, primary, mucinous ovarian or fallopian tube cancer. The



**Figure 5.** Survival in mice with mucinous adenocarcinoma cells (TU-OM-1 cell). Mice treated with oxaliplatin and 5-FU survived significantly longer than mice treated with either agent alone or control mice.

primary endpoint will be overall survival; secondary endpoints will be progression-free survival, response rate, toxicity, and quality of life. The study also assesses the translational endpoint, KRAS mutations and expression of vascular endothelial growth factor and epidermal growth factor. The targeted accrual for the study is 322 patients.

Based on the similarity of biological characteristics, the standard chemotherapy regimen for colorectal cancer has been given in patients with MAC. Therefore, the first phase-II chemotherapy study of oral S-1, a 5FU derivative, combined with oxaliplatin (SOX) for advanced or recurrent patients with MAC was conducted in the Japan ovarian mucinous adenocarcinoma study group.

We hope that future research in this field will enable to develop an effective strategy for conquest of chemoresistance in EOC.

	Clear cell	Serous	
No	101	235	
Median age	51 (31-72)	54 (23-82)	
FIGO stage			
Ia	49 (48.5%)	39 (16.6%)	
Ib	11 (10.9%)	15 (6.5%)	
Ic	0	2 (0.9%)	
II	38 (37.6%)	22 (9.4%)	
III	10 (9.9%)	145 (61.7%)	<i>P</i> <0.0001
IV	31 (30.7%)	38 (16.2%)	

**Table 1.** Patients Characteristics

## Author details

Jun Naniwa, Hiroaki Itamochi and Junzo Kigawa

Tottori University Hospital Cancer Center, Japan

## References

- [1] <http://www.cancer.org/Research/CancerFactsFigures/GlobalCancerFactsFigures/global-facts-figures-2nd-ed>
- [2] Heintz AP, Odicino F, Maisonneuve P, et al. Carcinoma of the ovary. FIGO 26th Annual Report on the Results of Treatment in Gynecological Cancer. *Int J Gynaecol Obstet* (2006). Suppl 1) S, 161-192.
- [3] Winter, W. E. rd, Maxwell GL, Tian C, et al. Prognostic factors for stage III epithelial ovarian cancer: a Gynecologic Oncology Group Study. *J Clin Oncol* (2007). , 25(24), 3621-3627.
- [4] Kobel, M, Kalloger, S. E, Boyd, N, et al. Ovarian carcinoma subtypes are different diseases: implications for biomarker studies. *PLoS Med* (2008). e232.
- [5] Kobel, M, Kalloger, S. E, Huntsman, D. G, et al. Differences in tumor type in low-stage versus high-stage ovarian carcinomas. *Int J Gynecol Pathol* (2010). , 29(3), 203-211.
- [6] Mackay, H. J, Brady, M. F, Oza, A. M, et al. Prognostic relevance of uncommon ovarian histology in women with stage III/IV epithelial ovarian cancer. *Int J Gynecol Cancer* (2010). , 20(6), 945-952.
- [7] Itamochi, H, Kigawa, J, Akeshima, R, et al. Mechanisms of cisplatin resistance in clear cell carcinoma of the ovary. *Oncology* (2002). , 62(4), 349-353.
- [8] Rauh-hain, J. A, Winograd, D, Growdon, W. B, et al. Prognostic determinants in patients with uterine and ovarian clear carcinoma. *Gynecol Oncol* (2012). , 125(2), 376-380.
- [9] Sugiyama, T, Kamura, T, Kigawa, J, et al. Clinical characteristics of clear cell carcinoma of the ovary: a distinct histologic type with poor prognosis and resistance to platinum-based chemotherapy. *Cancer* (2000). , 88(11), 2584-2589.
- [10] Chan, J. K, Teoh, D, Hu, J. M, et al. Do clear cell ovarian carcinomas have poorer prognosis compared to other epithelial cell types? A study of 1411 clear cell ovarian cancers. *Gynecol Oncol* (2008). , 109(3), 370-376.

- [11] Olsen, C. M, Nagle, C. M, Whiteman, D. C, et al. Body size and risk of epithelial ovarian and related cancers: a population-based case-control study. *Int J Cancer* (2008). , 123(2), 450-456.
- [12] Nagle, C. M, Olsen, C. M, Webb, P. M, et al. Endometrioid and clear cell ovarian cancers: a comparative analysis of risk factors. *Eur J Cancer* (2008). , 44(16), 2477-2484.
- [13] Yang, H. P, Trabert, B, Murphy, M. A, et al. Ovarian cancer risk factors by histologic subtypes in the NIH-AARP Diet and Health Study. *Int J Cancer* (2012). , 131(4), 938-948.
- [14] Campbell, I. G, & Thomas, E. J. Endometriosis: candidate genes. *Hum Reprod Update* (2001). , 7(1), 15-20.
- [15] Kennedy, A. W, Biscotti, C. V, Hart, W. R, et al. Ovarian clear cell adenocarcinoma. *Gynecol Oncol* (1989). , 32(3), 342-349.
- [16] Aris, A. Endometriosis-associated ovarian cancer: A ten-year cohort study of women living in the Estrie Region of Quebec, Canada. *J Ovarian Res* (2010).
- [17] Goff, B. A. Sainz de la Cuesta R, Muntz HG, et al. Clear cell carcinoma of the ovary: a distinct histologic type with poor prognosis and resistance to platinum-based chemotherapy in stage III disease. *Gynecol Oncol* (1996). , 60(3), 412-417.
- [18] Eltabbakh, G. H, Mount, S. L, Beatty, B, et al. Clinical and molecular differences between clear cell and papillary serous ovarian carcinoma. *J Surg Oncol* (2006). , 93(5), 379-386.
- [19] Duska, L. R, Garrett, L, Henretta, M, et al. When 'never-events' occur despite adherence to clinical guidelines: the case of venous thromboembolism in clear cell cancer of the ovary compared with other epithelial histologic subtypes. *Gynecol Oncol* (2010). , 116(3), 374-377.
- [20] Anglesio, M. S, Carey, M. S, Kobel, M, et al. Clear cell carcinoma of the ovary: a report from the first Ovarian Clear Cell Symposium, June 24th, 2010. *Gynecol Oncol* (2011). , 121(2), 407-415.
- [21] Pectasides, D, Pectasides, E, Psyrris, A, et al. Treatment issues in clear cell carcinoma of the ovary: a different entity? *Oncologist* (2006). , 11(10), 1089-1094.
- [22] Kobel, M, Kalloger, S. E, Santos, J. L, et al. Tumor type and substage predict survival in stage I and II ovarian carcinoma: insights and implications. *Gynecol Oncol* (2010). , 116(1), 50-56.
- [23] Jenison, E. L, Montag, A. G, Griffiths, C. T, et al. Clear cell adenocarcinoma of the ovary: a clinical analysis and comparison with serous carcinoma. *Gynecol Oncol* (1989). , 32(1), 65-71.



- [24] Takano, M, Kikuchi, Y, Yaegashi, N, et al. Clear cell carcinoma of the ovary: a retrospective multicentre experience of 254 patients with complete surgical staging. *Br J Cancer* (2006). , 94(10), 1369-1374.
- [25] Andrews, P. A, & Howell, S. B. Cellular pharmacology of cisplatin: perspectives on mechanisms of acquired resistance. *Cancer Cells* (1990). , 2(2), 35-43.
- [26] Andrews, P. A, Velury, S, Mann, S. C, et al. cis-Diamminedichloroplatinum(II) accumulation in sensitive and resistant human ovarian carcinoma cells. *Cancer Res* (1988). , 48(1), 68-73.
- [27] Fujiwara, Y, Sugimoto, Y, Kasahara, K, et al. Determinants of drug response in a cisplatin-resistant human lung cancer cell line. *Jpn J Cancer Res* (1990). , 81(5), 527-535.
- [28] Godwin, A. K, Meister, A, & Dwyer, O. PJ, et al. High resistance to cisplatin in human ovarian cancer cell lines is associated with marked increase of glutathione synthesis. *Proc Natl Acad Sci U S A* (1992). , 89(7), 3070-3074.
- [29] Kasahara, K, Fujiwara, Y, Nishio, K, et al. Metallothionein content correlates with the sensitivity of human small cell lung cancer cell lines to cisplatin. *Cancer Res* (1991). , 51(12), 3237-3242.
- [30] Borst, P, Evers, R, Kool, M, et al. A family of drug transporters: the multidrug resistance-associated proteins. *J Natl Cancer Inst* (2000). , 92(16), 1295-1302.
- [31] Itamochi, H, Kigawa, J, Sugiyama, T, et al. Low proliferation activity may be associated with chemoresistance in clear cell carcinoma of the ovary. *Obstet Gynecol* (2002). , 100(2), 281-287.
- [32] Ohishi, Y, Oda, Y, Uchiumi, T, et al. ATP-binding cassette superfamily transporter gene expression in human primary ovarian carcinoma. *Clin Cancer Res* (2002). , 8(12), 3767-3775.
- [33] Kigawa, J, Minagawa, Y, Cheng, X, et al. Gamma-glutamyl cysteine synthetase up-regulates glutathione and multidrug resistance-associated protein in patients with chemoresistant epithelial ovarian cancer. *Clin Cancer Res* (1998). , 4(7), 1737-1741.
- [34] Sharma, M, He, Q. Y, & Tomasz, M. Effects of glutathione on alkylation and cross-linking of DNA by mitomycin C. Isolation of a ternary glutathione-mitomycin-DNA adduct. *Chem Res Toxicol* (1994). , 7(3), 401-407.
- [35] Itamochi, H, Kigawa, J, Sultana, H, et al. Sensitivity to anticancer agents and resistance mechanisms in clear cell carcinoma of the ovary. *Jpn J Cancer Res* (2002). , 93(6), 723-728.
- [36] Schwartz, D. R, Kardia, S. L, Shedden, K. A, et al. Gene expression in ovarian cancer reflects both morphology and biological behavior, distinguishing clear cell from other poor-prognosis ovarian carcinomas. *Cancer Res* (2002). , 62(16), 4722-4729.

- [37] Xu, Z, Chen, Z. P, Malapetsa, A, et al. DNA repair protein levels vis-a-vis anticancer drug resistance in the human tumor cell lines of the National Cancer Institute drug screening program. *Anticancer Drugs* (2002). , 13(5), 511-519.
- [38] Reed, E, Yu, J. J, Davies, A, et al. Clear cell tumors have higher mRNA levels of ERCC1 and XPB than other histological types of epithelial ovarian cancer. *Clin Cancer Res* (2003). , 9(14), 5299-5305.
- [39] Claij, N. te Riele H. Microsatellite instability in human cancer: a prognostic marker for chemotherapy? *Exp Cell Res* (1999). , 246(1), 1-10.
- [40] Cai, K. Q, Albarracin, C, Rosen, D, et al. Microsatellite instability and alteration of the expression of hMLH1 and hMSH2 in ovarian clear cell carcinoma. *Hum Pathol* (2004). , 35(5), 552-559.
- [41] Agus, D. B, & Bunn, P. A. Jr., Franklin W, et al. HER-2/neu as a therapeutic target in non-small cell lung cancer, prostate cancer, and ovarian cancer. *Semin Oncol* (2000). Suppl 11) 53-63; discussion , 92-100.
- [42] Johnstone, R. W, Ruefli, A. A, & Lowe, S. W. Apoptosis: a link between cancer genetics and chemotherapy. *Cell* (2002). , 108(2), 153-164.
- [43] Fujimura, M, Hidaka, T, & Saito, S. Selective inhibition of the epidermal growth factor receptor by ZD1839 decreases the growth and invasion of ovarian clear cell adenocarcinoma cells. *Clin Cancer Res* (2002). , 8(7), 2448-2454.
- [44] Rowinsky, E. K, Donehower, R. C, Jones, R. J, et al. Microtubule changes and cytotoxicity in leukemic cell lines treated with taxol. *Cancer Res* (1988). , 48(14), 4093-4100.
- [45] Wang, Z. R, Liu, W, Smith, S. T, et al. c-myc and chromosome 8 centromere studies of ovarian cancer by interphase FISH. *Exp Mol Pathol* (1999). , 66(2), 140-148.
- [46] Slamon, D. J, Godolphin, W, Jones, L. A, et al. Studies of the HER-2/neu proto-oncogene in human breast and ovarian cancer. *Science* (1989). , 244(4905), 707-712.
- [47] Sherr, C. J. G. phase progression: cycling on cue. *Cell* (1994). , 79(4), 551-555.
- [48] Marks, J. R, Davidoff, A. M, Kerns, B. J, et al. Overexpression and mutation of in epithelial ovarian cancer. *Cancer Res* (1991). , 53.
- [49] Righetti, S. C. Della Torre G, Pilotti S, et al. A comparative study of gene mutations, protein accumulation, and response to cisplatin-based chemotherapy in advanced ovarian carcinoma. *Cancer Res* (1996). , 53.
- [50] Ho, E. S, Lai, C. R, Hsieh, Y. T, et al. mutation is infrequent in clear cell carcinoma of the ovary. *Gynecol Oncol* (2001). , 53.
- [51] Shah, M. A, & Schwartz, G. K. Cell cycle-mediated drug resistance: an emerging concept in cancer therapy. *Clin Cancer Res* (2001). , 7(8), 2168-2181.

- [52] Dimanche-boitrel, M. T, Pelletier, H, Genne, P, et al. Confluence-dependent resistance in human colon cancer cells: role of reduced drug accumulation and low intrinsic chemosensitivity of resting cells. *Int J Cancer* (1992). , 50(5), 677-682.
- [53] Shimizu, M, Nikaido, T, Toki, T, et al. Clear cell carcinoma has an expression pattern of cell cycle regulatory molecules that is unique among ovarian adenocarcinomas. *Cancer* (1999). , 85(3), 669-677.
- [54] Kuo, K. T, Mao, T. L, Jones, S, et al. Frequent activating mutations of PIK3CA in ovarian clear cell carcinoma. *Am J Pathol* (2009). , 174(5), 1597-1601.
- [55] Lee, K. R, & Scully, R. E. Mucinous tumors of the ovary: a clinicopathologic study of 196 borderline tumors (of intestinal type) and carcinomas, including an evaluation of 11 cases with 'pseudomyxoma peritonei'. *Am J Surg Pathol* (2000). , 24(11), 1447-1464.
- [56] Riopel, M. A, Ronnett, B. M, & Kurman, R. J. Evaluation of diagnostic criteria and behavior of ovarian intestinal-type mucinous tumors: atypical proliferative (borderline) tumors and intraepithelial, microinvasive, invasive, and metastatic carcinomas. *Am J Surg Pathol* (1999). , 23(6), 617-635.
- [57] Rodriguez, I. M, & Prat, J. Mucinous tumors of the ovary: a clinicopathologic analysis of 75 borderline tumors (of intestinal type) and carcinomas. *Am J Surg Pathol* (2002). , 26(2), 139-152.
- [58] Shimada, M, Kigawa, J, Ohishi, Y, et al. Clinicopathological characteristics of mucinous adenocarcinoma of the ovary. *Gynecol Oncol* (2009). , 113(3), 331-334.
- [59] Pectasides, D, Fountzilas, G, Aravantinos, G, et al. Advanced stage mucinous epithelial ovarian cancer: the Hellenic Cooperative Oncology Group experience. *Gynecol Oncol* (2005). , 97(2), 436-441.
- [60] Seidman, J. D, Horkayne-Szakaly I, Haiba M, et al. The histologic type and stage distribution of ovarian carcinomas of surface epithelial origin. *Int J Gynecol Pathol* (2004). , 23(1), 41-44.
- [61] Marchini, S, Mariani, P, Chiorino, G, et al. Analysis of gene expression in early-stage ovarian cancer. *Clin Cancer Res* (2008). , 14(23), 7850-7860.
- [62] Heinzelmann-schwarz, V. A, Gardiner-garden, M, Henshall, S. M, et al. A distinct molecular profile associated with mucinous epithelial ovarian cancer. *Br J Cancer* (2006). , 94(6), 904-913.
- [63] Bos, J. L. ras oncogenes in human cancer: a review. *Cancer Res* (1989). , 49(17), 4682-4689.
- [64] Gemignani, M. L, Schlaerth, A. C, Bogomolny, F, et al. Role of KRAS and BRAF gene mutations in mucinous ovarian carcinoma. *Gynecol Oncol* (2003). , 90(2), 378-381.

- [65] Mok, S. C, Bell, D. A, Knapp, R. C, et al. Mutation of K-ras protooncogene in human ovarian epithelial tumors of borderline malignancy. *Cancer Res* (1993). , 53(7), 1489-1492.
- [66] Tonin, P. N, Maugard, C. M, Perret, C, et al. A review of histopathological subtypes of ovarian cancer in BRCA-related French Canadian cancer families. *Fam Cancer* (2007). , 6(4), 491-497.
- [67] Evans, D. G, Young, K, Bulman, M, et al. Probability of BRCA1/2 mutation varies with ovarian histology: results from screening 442 ovarian cancer families. *Clin Genet* (2008). , 73(4), 338-345.
- [68] Schuijjer, M, & Berns, E. M. TP53 and ovarian cancer. *Hum Mutat* (2003). , 21(3), 285-291.
- [69] Sarrio, D, Moreno-bueno, G, Sanchez-estevez, C, et al. Expression of cadherins and catenins correlates with distinct histologic types of ovarian carcinomas. *Hum Pathol* (2006). , 37(8), 1042-1049.
- [70] Brun, J. L, Cortez, A, Commo, F, et al. Serous and mucinous ovarian tumors express different profiles of MMP-2,-7,-9, MT1-MMP, and TIMP-1 and-2. *Int J Oncol* (2008). , 33(6), 1239-1246.
- [71] Cho, Y. H, Kim, D. Y, Kim, J. H, et al. Is complete surgical staging necessary in patients with stage I mucinous epithelial ovarian tumors? *Gynecol Oncol* (2006). , 103(3), 878-882.
- [72] Ji, J, Forsti, A, Sundquist, J, et al. Survival in ovarian cancer patients by histology and family history. *Acta Oncol* (2008). , 47(6), 1133-1139.
- [73] Hess, V, Hern, A, & Nasiri, R. N, et al. Mucinous epithelial ovarian cancer: a separate entity requiring specific treatment. *J Clin Oncol* (2004). , 22(6), 1040-1044.
- [74] Seidman, J. D, Kurman, R. J, & Ronnett, B. M. Primary and metastatic mucinous adenocarcinomas in the ovaries: incidence in routine practice with a new approach to improve intraoperative diagnosis. *Am J Surg Pathol* (2003). , 27(7), 985-993.
- [75] Stewart, C. J, Brennan, B. A, Hammond, I. G, et al. Accuracy of frozen section in distinguishing primary ovarian neoplasia from tumors metastatic to the ovary. *Int J Gynecol Pathol* (2005). , 24(4), 356-362.
- [76] Yemelyanova, A. V, Vang, R, Judson, K, et al. Distinction of primary and metastatic mucinous tumors involving the ovary: analysis of size and laterality data by primary site with reevaluation of an algorithm for tumor classification. *Am J Surg Pathol* (2008). , 32(1), 128-138.
- [77] Lewis, M. R, Deavers, M. T, Silva, E. G, et al. Ovarian involvement by metastatic colorectal adenocarcinoma: still a diagnostic challenge. *Am J Surg Pathol* (2006). , 30(2), 177-184.

- [78] Ronnett, B. M, Yemelyanova, A. V, Vang, R, et al. Endocervical adenocarcinomas with ovarian metastases: analysis of 29 cases with emphasis on minimally invasive cervical tumors and the ability of the metastases to simulate primary ovarian neoplasms. *Am J Surg Pathol* (2008). , 32(12), 1835-1853.
- [79] Cao, D, Ji, H, & Ronnett, B. M. Expression of mesothelin, fascin, and prostate stem cell antigen in primary ovarian mucinous tumors and their utility in differentiating primary ovarian mucinous tumors from metastatic pancreatic mucinous carcinomas in the ovary. *Int J Gynecol Pathol* (2005). , 24(1), 67-72.
- [80] Oien, K. A. Pathologic evaluation of unknown primary cancer. *Semin Oncol* (2009). , 36(1), 8-37.
- [81] Tholander, B, Taube, A, Lindgren, A, et al. Pretreatment serum levels of CA-125, carcinoembryonic antigen, tissue polypeptide antigen, and placental alkaline phosphatase, in patients with ovarian carcinoma, borderline tumors, or benign adnexal masses: relevance for differential diagnosis. *Gynecol Oncol* (1990). , 39(1), 16-25.
- [82] Tuxen, M. K, Soletormos, G, & Dombernowsky, P. Tumor markers in the management of patients with ovarian cancer. *Cancer Treat Rev* (1995). , 21(3), 215-245.
- [83] Nolen, B, Marrangoni, A, Velikokhatnaya, L, et al. A serum based analysis of ovarian epithelial tumorigenesis. *Gynecol Oncol* (2009). , 112(1), 47-54.
- [84] Sato, S, Itamochi, H, Kigawa, J, et al. Combination chemotherapy of oxaliplatin and 5-fluorouracil may be an effective regimen for mucinous adenocarcinoma of the ovary: a potential treatment strategy. *Cancer Sci* (2009). , 100(3), 546-551.