

We are IntechOpen, the world's leading publisher of Open Access books Built by scientists, for scientists

4,800

Open access books available

122,000

International authors and editors

135M

Downloads

Our authors are among the

154

Countries delivered to

TOP 1%

most cited scientists

12.2%

Contributors from top 500 universities



WEB OF SCIENCE™

Selection of our books indexed in the Book Citation Index
in Web of Science™ Core Collection (BKCI)

Interested in publishing with us?
Contact book.department@intechopen.com

Numbers displayed above are based on latest data collected.
For more information visit www.intechopen.com



Orbital Cisticercosis. A Challenger for Neurologists, Ophthalmologists, Neuro- Ophthalmologists, and General Practitioners

Humberto Foyaca Sibat, María Carolina Salazar Campos
and Lourdes de Fátima Ibañez Valdés

Additional information is available at the end of the chapter

<http://dx.doi.org/10.5772/52515>

1. Introduction

Cysticercosis is a disease closely related to poverty in general and in particular with a poor personal hygiene and food, socio-cultural factors, environmental, education for health in the community, and also very closely related to the hygienic and sanitary conditions of each region. This is a preventable and an eradicable disease [1] that currently affects more than 50 million people in the entire world, of which 400 thousand live in Latin America [2] is internationally accepted that the onset of epilepsy, intracranial hypertension or headache of unknown cause in a person originating, visitor or in contact with another person from an area where *T solium* is endemic suggests considering the diagnosis of NCC. The patient affected by the NCC can remain asymptomatic for several months or years, and its diagnosis can be confirmed by accident when a CT scan is carried out in search of another diagnosis. [3,4] According to WHO figures confirmed by Roman and collaborators [5] around 50 thousand people die each year as a result of the NCC and the epilepsy secondary to the NCC (ESNCC).

Taenia solium produces two different diseases: taeniasis (Te) and/or cysticercosis (CC). When the parasite is an adult expels its mature proglotides and eggs with the stool to the environment; the subsequent ingestion of these eggs of pork cause porcine cysticercosis (PCC). When a person swallows raw pork meat or not well cooked and infected with cysticerci (CT) then develops a new adult parasite. The human then becomes an accidental intermediate host. These oncosphere (primary larvae) penetrate the intestinal mucosa and enter the circulatory system. The Hematogenous spread of neural, muscular, and ocular tissues occurs. Within these tissues, the oncosphere develop into secondary larvae (i.e., the cysticerci).

When man eats the eggs of *T. solium* acquires CC which can be found in any tissue including heart, liver, lungs, pancreas, spleen, kidneys, and peritoneal cavity among others. (See Chapter 3) [6-32] As has been mentioned, the location of Ct (larval stage) in the CNS and the eye (considering the retina as an extension of the CNS) is called NCC and is considered the neurological disease more important of parasitic origin in man and the main cause of epilepsy late onset. [33] In the brain NCC is located mainly at the level of gray substance cortical or at the level of the union between the gray and white matter because it is the best blood supplied area. [34] The CC is considered is a serious problem for public health in several developing countries where social conditions, economic and cultural levels favor the maintenance of this zoonotic disease and it is seen as a growing community problem in those developed countries with a high rate of immigrants from endemic areas. WHO includes the NCC between neglected diseases or forgotten that cause a significant impact on the economy in several regions of the world. It affects 4% of the population in endemic areas [35,36] where the personal and food hygiene habits and sometimes the religious tendencies determine the incidence and prevalence of the disease, for example: Islamism. Islam was not the first religion to prohibit the consumption of pork, before that Judaism made it perhaps less severe restrictions; however some cases have been reported in the Jewish community in New York. [37]

Due to globalization a growing number of uncontrolled migrants from endemic areas of Latin America came to the USA every day therefore a significantly increasing number of cases of NCC are gradually diagnosed in the country, especially in the southwest, including Texas and California. [4, 6-8,33, 37, 38-41] It suffices to mention that a total of 1494 patients with NCC were confirmed between 1980 and 2004 of which 66% suffered from epilepsy, 16% had an obstructive hydrocephalus and 15% headache due to intraparenchymal NCC [IpNCC] (91%), intraventricular (6 %) or subarachnoid (2 %) either because travelled to endemic areas, were of Hispanic origin or had any contact with carriers of the parasite. [42] In Latin America has been described the existence of the NCC in 18 countries with an estimated 350,000 patients infected by the complex TE/CC. In 2008, Pawlowski [43] stipulated that in the world would have 2.5 million owning approximate mind of disabled people of *Taenia solium*, at least 20 million with CC, which causes on average 50.000 deaths a year. In his recent book, Hotez [2] reported that in the United States were confirmed between one and two thousand cases of NCC each year and considering the growing Latino population could have more than 41,000 Hispanics suffer from NCC in that country. [2,43,44] Neurocysticercosis is also virtually endemic in certain countries in Europe such as Romania, Poland and even Portugal. In Spain the growing strength of the migration of individuals coming from endemic areas has conditioned an increase in the frequency of this entity. [45]

Other less frequent locations of *T solium* in the CNS include: intra ventricular (Iv), subarachnoid (Sa), medullary (Me), intraocular (Io) and intraspinal (Ip). Some authors report a list of frequencies for these locations and some combinations among of them such as: IpNCC (55.23 %), IvNCC (15,69 %) %), SaNCC (11.63 %), MeNCC (3.4 %), IoNCC (0.58 %), IpNCC (0.09 %) and the frequency of different combinations in the following manner:

Iv-Ip (6.98 %), Sa-Ip (3.49 %) and Sa-Iv (2.32 %) reported by Amaral et al. [46] In a hospital-based study conducted in Mexico is reported a rate of up to 8.6 cases of NCC per 100 hospitalized, and in the series of necrosis of up to 2 453 per 100 000 inhabitants and pointed out that 43.3 % of the cases were asymptomatic [35, 47] and 80% were autopsy findings. [48] Official statistics report an annual average of 500 cases of CC, with a national rate raw 0.6 per 100,000 inhabitants. [49-51] this report does not include the cases that were not attended by professional health personnel or that were not included in the study for other reasons, and does not include the extra-parenchymal presentations or even other modalities of CC. In Brazil, the prevalence in autopsies varies from 0.12 to 9% and in a series of clinical cases it varies from 0.03 to 7.5 %; in studies sero-epidemiological of 0.6 to 5.2 %. [52] In Colombia there is not much information on the CC, only some work in the departments of Antioquia and Santander that reported 1 to 2% of affection to the population and 2% in Ecuador. [53, 54] On the other hand it has been estimated that 50 million people are infected by *T solium* in the world, of which 350 thousand live in Latin America [55] especially in those countries that do not have an adequate health infrastructure and proper health education program. [56] The main risk factors associated with the CC are the presence of peoples infected by *T solium* in the community with inadequate primary health care system, without proper health education and personal and food hygiene and without a sustainable supply of safe and clean water and where free-range pigs are able to ingest contaminated human feces [57-62] and the use of infected feces as an agricultural fertilizer. [63] The NCC has become a public health problem in different countries in Africa, Asia and Latin America [56, 64-68]

The orbits are two bony cavities occupied by the eyes and associated muscles, nerves, blood vessels, fat, and much of the lacrimal apparatus. Each orbit is shaped like a pear or a four-sided pyramid, with its apex situated posteriorly and its base anteriorly. The orbit is related to its superior side to the anterior cranial fossa and usually to the frontal sinus, laterally to the temporal fossa in (anterior) and to the middle cranial fossa (posterior), on its inferior side of the maxillary sinus, and medially to the ethmoid bone and the anterior extent of the sphenoid sinus.

Orbital cysticercosis is caused by the infestation of the larval form of the pork tapeworm *Taenia solium* in the orbital cavity affecting the eyeball (ocular cysticercosis) or the extra ocular structures found within the orbital cavity such as: extra ocular muscles, nerves, ganglions, and fatty tissue. Orbital cysticercosis may cause significant visual loss, especially if the cyst is located intraocularly or is compressing the optic nerve. [70]

Ocular cysticercosis may be extraocular (in the sub-conjunctival or orbital tissues) or intraocular (in the vitreous, sub-retinal space, or anterior chamber). [70-72] Ocular manifestations of cysticercosis vary from asymptomatic to painful blind eye and may be associated with neurological symptoms such as headache, fits, diplopia, and restriction of the ocular movements, nystagmus and papilloedema.

According to some authors the most common location of the Ocular CC is the sub retinal region (35 %), followed by the vitreous cysticercosis (22 %), conjunctival cysticercosis (22 %),

and anterior segment cysticercosis. (5 %) [73] While involvement of other regions (e.g., extraocular muscles, optic nerve) are relatively less common. [70]

Sub retinal cysticercosis (SrCC), vitreous cysticercosis (VCC) and anterior segment cysticercosis (AsCC) are more common in India. While either eye may be affected, bilateral involvement is rare [74] and multiple cysts may develop in the same eye. [75] Ocular manifestations may be devastating as the cysticercus enlarges. The cysticercus may lead to blindness in 3-5 years. [76] Decreased vision, pain, and recurrent redness of the involved eye are common symptoms of intraocular cysticercosis. [70]

Some authors consider that intraocular cysticercosis is predominant in the Western countries, whereas extraocular is more common in the Indian population attributed to geographic and environmental factors. [77, 79] However, other affirm that intraocular involvement is more common in India compared with Western countries. [78,] and involvement of conjunctiva is most commonly reported in India [80-99], whereas involvement of posterior segment of the eye is most commonly seen in Western countries. [100-109] compared with conjunctival region but it also can be seen in India. [110-112]

Orbital cysticercosis should be suspected in patients who have lived in an endemic area and who develop uveitis, leucocoria or Neuro-Ophthalmological signs, also in the presence of sub conjunctival cysts or lids nodules. Cysts deep within the orbit are best treated conservatively with a 4-week regimen of oral albendazole (15 mg/kg/d) in conjunction with oral steroids (1.5 mg/kg/d) in a tapering dose over a 1-month period. Treatment may increase inflammation as the cyst involutes, leading to worsening clinical status. Thus, concomitant administration of corticosteroids is recommended to avert an inflammatory response. [113,114]

In 2010, Rath et al., Studied 93 patients presenting orbital cysticercosis with mean age of 13 years and they concluded that orbital cysticercosis is a common clinical condition in the developing world which typically affects young individuals and has a wide spectrum of clinical manifestations; B-scan ultrasonography and computed tomography scan are useful in confirming the diagnosis and despite resolution of cysticercosis with medical management, a significant proportion of patients may have residual functional deficits. [77, 115,116]

1.1. Is orbital metastasis another challenger for differential diagnosis?

It may be, therefore our readership should remember that renal cell carcinoma (RCC) is a tumor of middle-aged men that metastasizes to the lung, liver, and bone. When this tumor spreads to the orbit, the orbital metastasis is likely to be the first indication of the cancer and up to 1993 only a few cases were reported. [117] In 1994, Schmidt et al [118] reported a 69 years-old-male patient with similar condition. Konya et al [119] reported two cases: a 44 and 59-years-old- male patients with proptosis and a tongue tumor due to RCC. Another patient was: 39-year-old black man with sickle cell trait, presented with a rapidly progressive painful proptosis of the left eye due to metastasis from renal medullary carcinoma. [120]

Most of patient reported at that time were from non-endemic areas for cysticercosis, this information was very important in the diagnostic process but at the present moment cysticercosis can be found in almost all countries. The next report came from India. It was a 69-year-old male who presented with pulsatile proptosis owing to metastasis of an asymptomatic renal cell carcinoma [121] this case was an example of the great challenger. In 2007, another three patients: two males of 67 and 58 years old males and a 23-years-old-female from India presenting iris mass, orbital metastasis were reported. [122] At this time, a total of 71 patients was reported in the international medical literature. This report suggested that patients presenting with atypical orbital or ocular masses, the possibility of renal cell carcinoma metastasis should be considered, especially if there is a history of previous renal disorder. Incisional biopsy with histopathological evaluation may be an important means to diagnose this condition and facilitate appropriate therapy. Other author reported similar findings. [123-126] Based on this review of the medical literature we can conclude that differential diagnosis between orbital metastasis and orbital cysticercosis it is not difficult considering that only three patients presenting proptosis of the eyes as the first clinical manifestation of RCC have been reported to the medical literature. [125]

Patients with hepatic cell carcinoma presenting primary symptoms of metastatic disease are rare and the retro-orbital mass as the initial manifestation of disease is also very uncommon as well. [127] Nevertheless, this an uncommon pathological disorder can also affect intracranial structures mainly in elderly patients or presenting as rapid onset of proptosis and visual loss (only three patients reported), or painful proptosis as the most common clinical sign of hepatocellular carcinoma metastatic to the orbit (ten patients reported). [128-132] In conclusion, hepatocellular carcinoma is a rare source of metastasis to the orbit, and only 14 histopathologically proven cases have been reported in the international medical literature. Proptosis is the most common presenting feature in the reviewed reports and a majority of patients have occult primary tumors at presentation and the diagnosis of the orbital mass is based on histopathology. [131]

The age of the patients, clinical features of the orbital lesion, presence of other metastatic lesions, epidemiological features of cysticercosis, CT scans, and ultrasonographic studies are elements that allow you to make a certain diagnosis.

In the previous chapter we reviewed some aspects on orbital cysticercosis according to their different locations within and outside of the eyeball without exceeding the limits of orbit, mainly those clinical features of the ocular cysticercosis associated with damage of other organs as part of the disseminated cysticercosis at the same time.

2. Vitreous cysticercosis and anterior chamber cysticercosis

2.1. Intraocular cysticercosis

It may be asymptomatic in the early stages. As the parasite grows, it causes a painless, progressive loss of vision related to the area of location.

Patients' complaints about an intermittent roundish, dark mobile mass (intravitreal location) or may experience visual field defects (sub retinal or CNS location).

Intraocular lesions caused by cysticercosis most commonly occur in the vitreous or subretinal space, but subchoroidal, sub hyaloid, and into the anterior chamber, also occur. [133-138] Lens involvement also can occur but it is extremely rare. (139)

A cyst in the anterior chamber can be manifested as an acute anterior uveitis, sometimes is so severe that is difficult to differentiate a cyst from a dislocated lens and always there is a cataract formation. The parasite can be seen moving freely into the cavity. (See figure 1)

When the parasite is freely mobile it may contribute to the absence of reaction in the anterior chamber. The portal of entry of the parasite into the anterior chamber has not been well documented although some author refers that the cyst may enter the anterior chamber either from the posterior ciliary arteries or from the angle. [154].

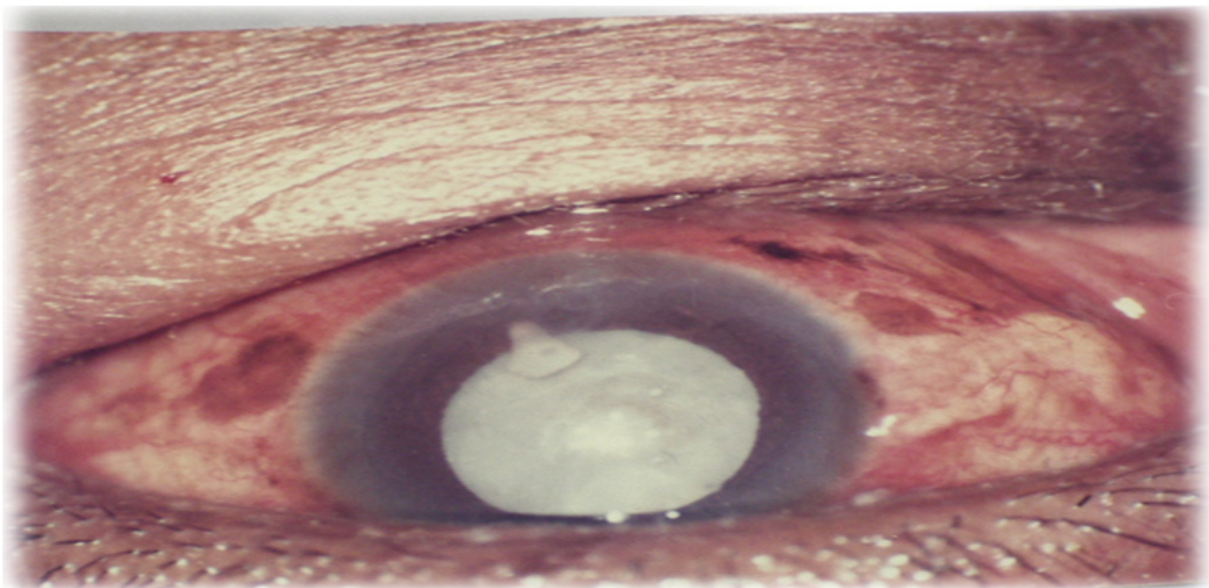


Figure 1. Anterior chamber cysticercosis with freely mobile cysticercus into the aqueous humor.

In the posterior segment, parasites gain access presumably through the posterior ciliary arteries. From this location, they usually pass through a rent in the retina into the vitreous. In rare cases the parasite may pass from the vitreous, through the pupil, into the anterior chamber. Infestation of the ocular adnexa is probably through the anterior ciliary arteries. [101-134,140]

The intraocular location of the cyst can cause retinal detachment, macular scarring, retinal vasculitis and vitritis [141] and usually affects young patients unilaterally. The cyst may be in either the vitreous cavity or the sub retinal space, and visual acuity at presentation is often poor. [142]

Most patients presenting intraocular cysticercosis can tolerate it well while the cysticercus is alive, however when the parasite dies, there is a marked inflammatory response to toxic

products released from the cyst, and the patient presents a blind painful eye. [136,142,143]. Only a few cases about cysticercosis resulting in glaucoma due to pupillary block have been reported. [72]

2.2. Intraocular cysticercosis

It can be recognized through clear media, the translucent cyst with a dense white spot formed by the invaginated scolex and the undulating movements are typical. We can see the scolex returning rapidly to the cyst when exposed to the ophthalmoscope or slit lamp light. [144,145] The frequency of different location of intraocular cysticercosis can be seen in the figure below.

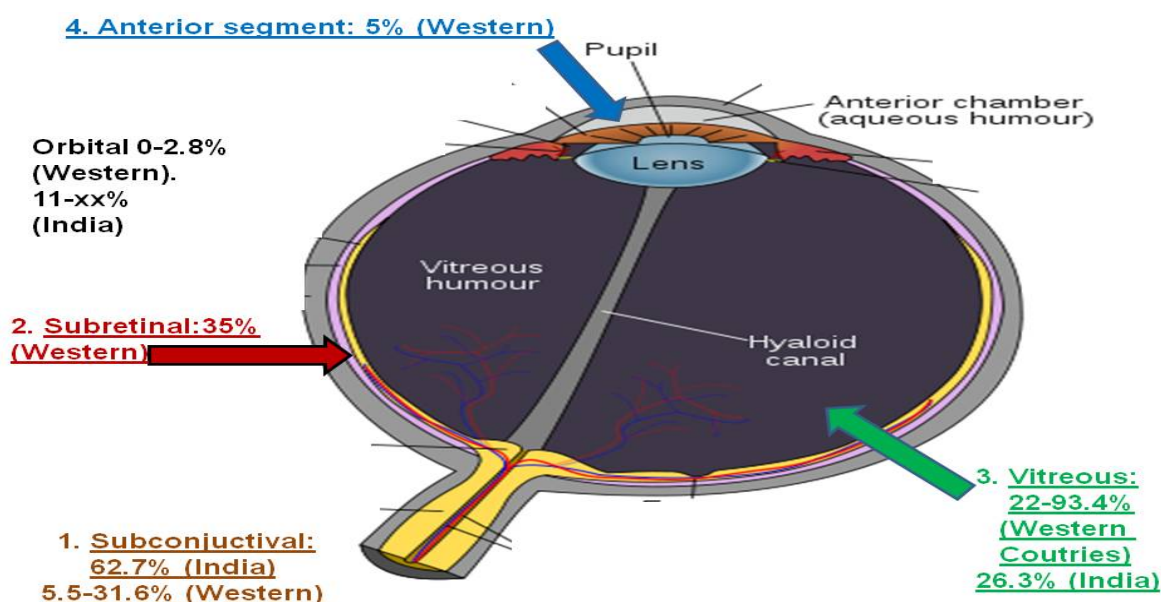


Figure 2. Frequency of intraocular cysticercosis in Western countries and India

After migration into the vitreous, a chorioretinal scar may develop in this area.

Laboratory tests:

Diagnostic paracentesis of the anterior chamber cysticercosis can show more than 50% of leukocytes in the aqueous humor with eosinophils. ELISA IgG serology test for cysticercosis and Western blot contribute to confirm the diagnosis although some cross reaction can be found in patients presenting Diphyllbothriosis, Taeniasis, Cysticercosis, Echinococcosis (Hydatidosis), Coenuriasis or Sparganosis.

Stool samples:

May not show any proglottids or eggs of *T. solium*.

Blood tests:

Are of limited value in diagnosing intraocular cysticercosis. FBC, serum chemistries and ESR may all be normal; eosinophilia is uncommon.

EITB (enzyme-linked immuno-electro transfer blot assay) has been shown to have greater than 98% sensitivity and specificity in patients with systemic disease, and can be completed with the determination of circulating antibody and antigen in the aqueous humor.

In ocular cysticercosis, serologic tests are helpful if positive, but false-negative tests may be reported, and their negativity does not rule out the disease. [143,146]

Imagenology

Fluorescein Angiography is useful in delineating the sub-retinal cyst located in the periphery of the retina. Plain X-rays of soft tissue or skull often reveal calcified cysticerci. The enhanced CT scan is valuable for identifying and following the evolution of orbital cysticercosis, which may appear as solid, cystic or calcified nodules.

MRI provides detailed images of living and degenerating cysticerci. [141]

Ultrasonography is an effective and economical alternative to MRI and CT for the detection of the intra-ocular cysticerci. It is a real time, dynamic examination, also allows direct visualization of the movements of the parasite when it is intraocular. U/S is effective for the detection of the cysts in the orbit and muscles too.

A cysticercus cyst with the scolex attached to the inner wall composes the "hanging drop sign." This sign was seen in cases studied using simultaneous A-and B-scan ultrasonography. This appearance was consistent and reproducible, regardless of whether the cyst was intraocular or extraocular in location. Serial B-scan ocular ultrasonography or CT scans of the orbit helps to follow the resolution of the cyst, which is recognized by the disappearance of the scolex. [15]

Optical Coherence Tomography (OCT) exam is seen as hyporeflexive area due to the presence of fluid in the cyst cavity. Sometimes the height of the cyst obscured the visualization of the scolex. In children, intraocular cysticercosis can simulate retinoblastoma mainly in the inflammatory response.

Therapeutic aspects

Medical treatment for intraocular cysticercosis is not advisable while that Albendazole or Praziquantel (PZQ), in conjunction with corticosteroids can be used for extraocular presentations with very good results.

Surgical treatment is used to remove the cysts from the adnexa, anterior and posterior segment. Removal of the cyst is mandatory to remove the source of the toxins causing inflammation and early removal has been advocated by many authors. [144,147] Reviews of treated cases suggest that early removal of the organism is associated with preservation of visual function. [137] If possible, ocular cysts should be removed before systemic treatment is undertaken to prevent damage from the dying process of the parasite. Freely mobile live cysticercus in the anterior chamber associated to NCC in patients complete asymptomatic has been reported in the medical literature. [148] or may be attached by inflammatory membranes to surrounding structures, such as the cornea, lens capsule, or iris. [149] In

general these cysts are around 2x2 mm in size, grayish-white in color and are freely mobile (See figure 2), changing its shape by protruding and retracting its scolex from and into the cyst cavity; sometimes the parasite is not neither attached to the iris, cornea or other intra-ocular anatomical structure and usually there are not an associated conjunctival or ciliary congestion and not abnormalities of the retina, macula vitreous or optic disc with preservation of the visual acuity but it can be associated with iridocyclitis [150-152] and secondary glaucoma [153] and as a rule the parasite is attached to the iris and only occasionally to the corneal endothelium or lens capsule.

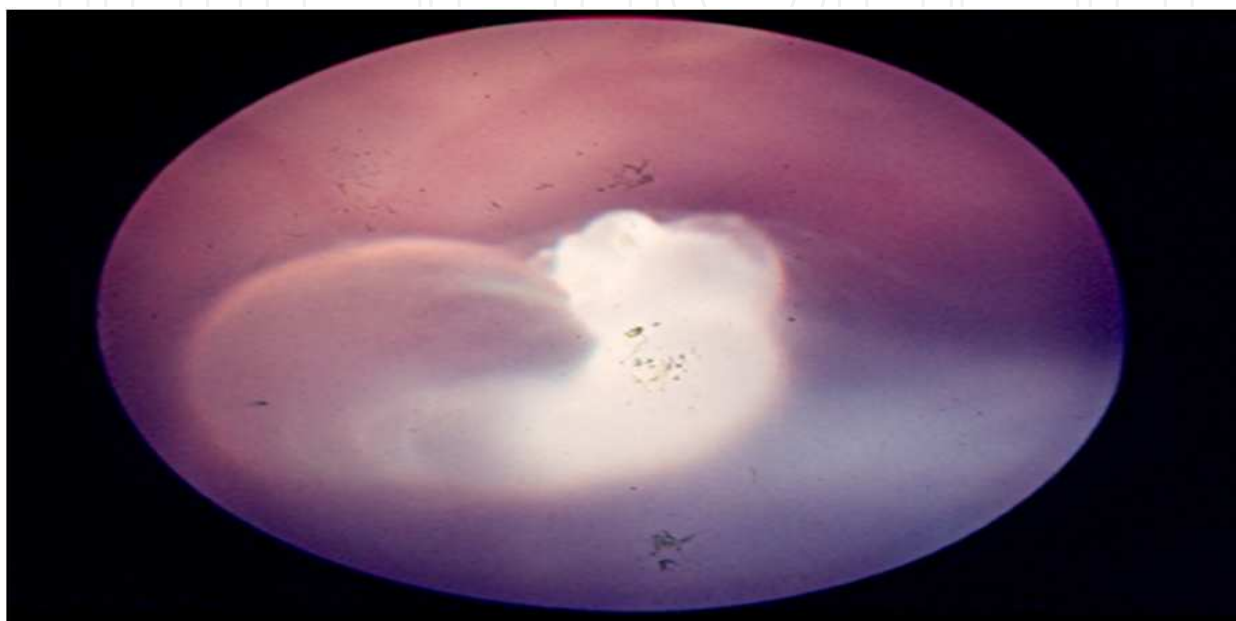


Figure 3. Intravitreal cysticercus moving freely

2.3. Ocular cysticercosis in South Africa

Some author reported a frequency of ocular involvement in cysticercosis around 13 to 46% [155,156] and its associated intraocular inflammation may also cause cataract formation [154] and iris atrophy. We found some differences and similarities compared with South African's patients that we will comment below.

Most of studies done in India and Western countries confirmed that orbital cysticercosis with ocular involvement is an uncommon pathological process that may cause severe damage of the eyes and an important involvement of the visual acuity. [80-84, 93, 142, 150, 156-158] The pathogenesis of ocular injury due to an intense inflammatory reaction secondary to intravitreal cysticercosis has been documented throughout an experimental animal model for intravitreal cysticercosis using New Zealand rabbits and *Taenia crassiceps cysticerci* since 1996. [159]

In 1964, Proctor [160] estimated a 1% incidence in South Africa of infestation by tapeworm cysts in 7 597 autopsies. Pammenter and Rossouw in 1984, [161] reported the results of serological tests in 79 patients with systemic cysticercosis in South Africa, from this study they confirmed that in isolated ocular cysticercosis serological tests are usually negative:

45,5% ELISA positive, the indirect haemagglutination test 33,3% positive, and the fluorescent antibody test 48,9% positive. Almost always these tests were positive in cases of systemic cysticercosis in our region. This experience was confirmed also by other. [162, 164].

In 1987, Welsh et al [106] studied thirteen cases of ocular cysticercosis at King Edward VIII Hospital over an 8-year period from 1976 to 1984. All patients came from rural areas, a reflection on the low standards of hygiene. At that time, adolescent females ingested tapeworm eggs for slimming purposes, but none of this report was under that category. From their review of the medical literature they found that up to 1952, 1 216 cases of ocular cysticercosis were reported and when studied their patients most of them were occasional and came to South Africa from India. Of the 13 patients with ocular cysts nine were found in the vitreous, three in the anterior chamber and one under the conjunctiva of the eye. The majority of patients were female and all were Zulus living in areas of KwaZulu Natal, most of them complained of loss of vision for an average of 3 months. The only exception was one patient with the sub-conjunctival cyst who had waited 2 years before seeking treatment, since the lump had not affected his vision. Today all types of cysticercosis in KwaZulu Natal practically disappeared and patients with cysticercosis can be seen only at the former Transkei or another province but emigrated from this region (currently region C and D) of the Eastern Cape Province which does not mean that cysticercosis is going to disappear in the next decade how we explained in the previous chapter.

All patients from Welsh' series [107] presenting vitreous cysticercosis complained of severe loss of vision, and there was always a marked vitreoretinal reaction and the patients with cysts in the anterior chamber showed severe anterior chamber reactions with anterior uveitis. The vision was reduced in all patients to where hand movements could not be seen or to perception of light being absent or to complete blindness, except for the patient with the subconjunctival cyst. In this series of patients because of the severity of the lesions, surgical removal, although partly successful, did not improve vision and the distribution of the cysts in the various structures of the eye was similar to cases reported in the literature. We would like to highlight that around 70's and 80's years several cases presenting bilateral involvement of the eyes and/or multifocal intra-ocular cysts were most commonly seen. [74,104,107,164,165]

Medical treatment for intraocular cysticercosis is not recommended based on South African's experiences with praziquantel (isquinoline pyrazine) [106] and another report from the same period of time. [166] Surgical removal is strongly recommended as the best treatment because complications associated with the cyst were minimal. Removal of vitreous cysts by pars plana vitrectomy is the method of choice. [110,167]

Removal of a cyst from the anterior chamber is relatively simple excepting cases pre-existing vitreoretinal-uveal reaction. [110, 168] The treatment of anterior chamber cysticercosis is essentially surgical. The different modalities used to remove the cyst include paracentesis, extraction with capsule forceps, cryo-extraction, diathermia, and viscoexpression. [78, 110,136, 168, 169]

In individuals with uveitis, the perioperative corticosteroid administration is recommended. Although surgical excision of orbital cysts was considered the ideal treatment modality, deep orbital dissection and difficulty in completely excising the cyst because of the surrounding inflammatory response, increase the chances of postoperative complications (e.g., decreased vision, diplopia). [110, 169]

Destruction of the larvae in situ of photocoagulation [170] cryotherapy, and diathermy has been attempted with some success. However, as intraocular cysticercosis may lead to severe inflammation following larval death, early surgical removal of the cyst is the treatment of choice. [137]

In years the 70s and 80s systemic cysticercosis was very common in rural areas of South Africa but ocular cysticercosis was not associated with any other systemic features and CT suggested that some patients with ocular cysticercosis had neurocysticercosis as well, although none was reported with accompanying systemic physical signs or symptoms. All patients had severe reactions to the cyst, whereas in the majority of reported cases there was a little ocular reaction. [107]

The treatment of anterior chamber cysticercosis is essentially surgical. The different modalities used to remove the cyst include paracentesis, extraction with capsule forceps, cryo-extraction, erysiphake extraction, and viscoexpression. [15,78] Viscoexpression allows removal of an intact cyst through a small limbal incision. In the treatment of intraocular cysticercosis, the most common surgical approach is removal through the pars plana route following vitrectomy. [168] Sub retinal cyst anterior to the equator may be removed trans-sclerally, whereas sub retinal cysts posterior to the equator and intravitreal cysts are best removed trans-vitreally. [137] Ideally, the cyst should be removed in toto. Complete surgical removal of the intact cyst results in good functional recovery in eyes with intraocular cysticercosis. [110, 136,137, 167]

3. Subretinal cysticercosis and optic nerve neurocysticercosis

3.1. Subretinal cysticercosis

The macular region is the site of choice for the subretinal cysticercus to lodge, maybe because of the high vascularization of this area but it can be seen in another subretinal area as well. In early stages, subretinal cysticercosis can appear as an acute central retinitis with retinal edema and subretinal exudates. The subretinal organism eventually develops into a cyst and the parasite and its movements can be recognized through the thin muscular layers. The observation of the cyst is more difficult when it is located in the periphery of the retina because scleral depression has to be used and the movements of the parasite cannot be observed clearly. (See figure 4 and 5)

Reportedly 35% of the cysts are in the subretinal space, 22% in the vitreous, 22% in the subconjunctival space, 5% in the anterior segment and 1% in the orbit. Among the intraocular cysts, 60% are found intravitreally and 40% are subretinal. [137,153]

When the parasite dies, an intraocular inflammation develops. Signs of acute anterior uveitis are present and severe opacification of the vitreous is observed. There are reports of dead and degenerating cysticerci causing a severe inflammatory reaction and ultimately loss of the eye. The cysts are known to release toxic products that cause severe inflammation mimicking endophthalmitis and even intraocular tumor. [171] The differential diagnosis with other parasitic infections and tumors has to be done. [144, 172, 173]

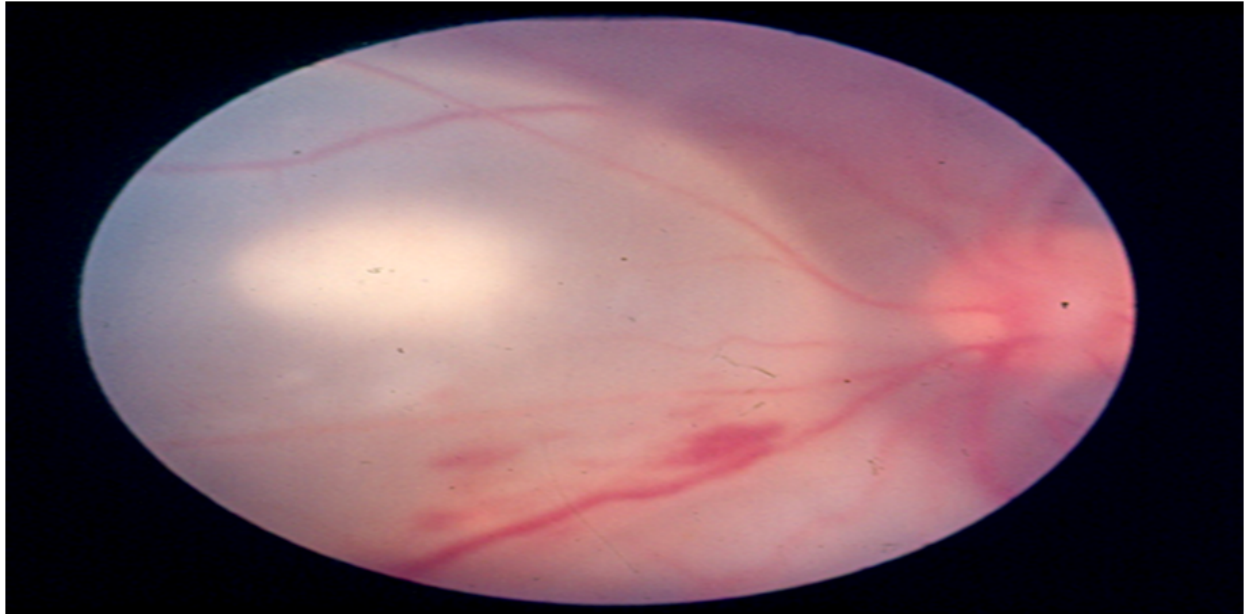


Figure 4. Shows subretinal cysticercosis seen by fundoscopy.

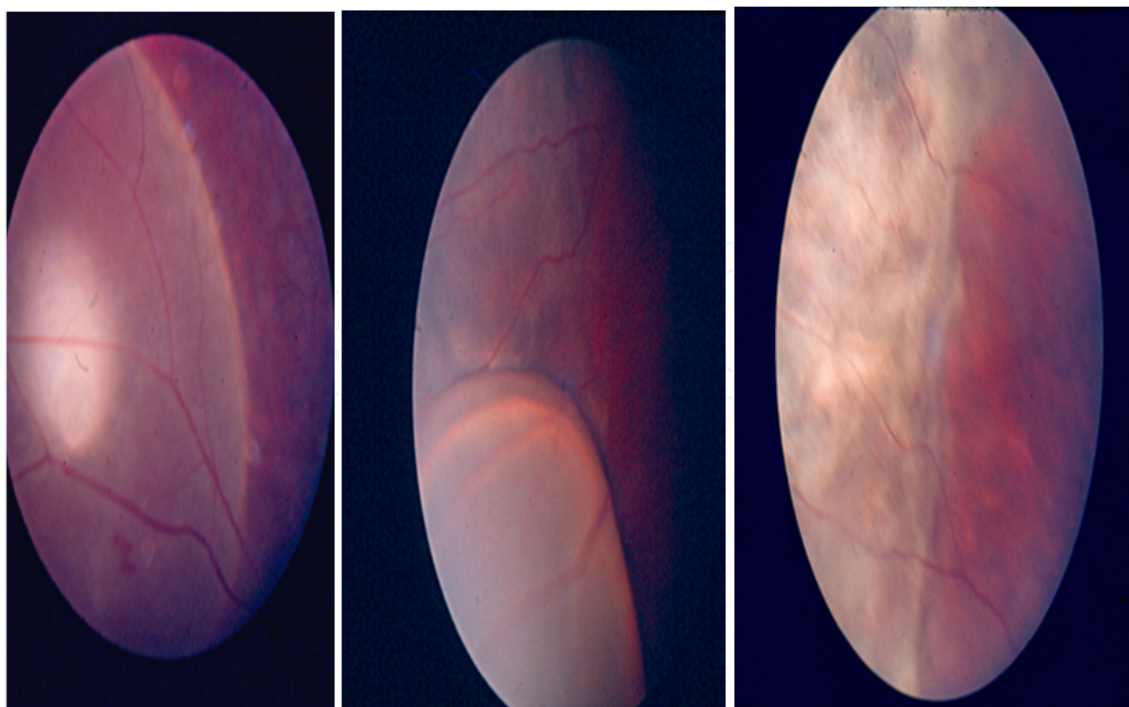


Figure 5. Another view of subretinal cysticercosis seen by fundoscopy (left & center) and picture of the fundus after surgical treatment on the right.

Seems to be that the viable cysts can evoke less inflammatory response, [170] while the degenerating cyst rapidly increases in size due to osmotic regulation and causes compression of the surrounding tissues and release of antigens into the surrounding tissue inducing inflammatory response. [106, 156,170, 173]

After the pars plana vitrectomy approach for removal of intravitreal cysts has developed, the prognosis of these eyes has improved. Another technique in conjunction with endolaser, diathermy, cryocoagulation, photocoagulation, and internal tamponade according to the retinal damage had been advocated for the treatment of cysticercosis. However, these methods will give rise to severe intraocular inflammation due to the toxins released from the dead larval tissues.

[137, 172, 174, 175] If the cyst is ruptured, care should be taken to remove all of the residual debris to prevent severe postoperative inflammation. Without treatment for intraocular parasites, the eyes go to the blindness in a short period of time.

Some report confirmed that the cyst usually presents in the sub-retinal space or vitreous cavity, where it can be observed ophthalmoscopically. The site of entry into the eye is most probably the choroidal vasculature from here the parasite can shift its location from sub-retinal space into the vitreous through a retinal break which could seal spontaneously, this passage incites inflammation, leaving behind a chorioretinal scar or even moves from anterior to posterior chamber and vice versa. [106,176-1978]

At this point, is good to remember what we explained before about cysts moving freely in the posterior chamber: apart from uveitis cysticercus may also lead to retinal hemorrhages, proliferative vitreoretinopathy, retinal detachment, disc edema, cyclitic membrane formation, and phthisis. [177,178]

In places where specialized retinal services are not available, external approach for the removal of sub retinal cyst is used. One of us (MCSC) has been used this surgical technique in places where other surgical approaches cannot be applied.

3.2. Approach to subretinal cyst removal using a conventional surgery technique

The conventional serial approach is a well-established surgical procedure for the treatment of subretinal cysts. This technique was the only one performed for many years to remove intraocular cysticercus (See figure 6) until advanced modern and easy methods were developed as the pars plana vitrectomy and internal tamponades.

The conventional method is more time consuming but it can be done in places where other facilities are not available.

Number one priority is localizing the cyst by indirect ophthalmoscopy at the pre-operative stage and then to proceed as follows:

1. To retract the lids using a wire lid retractor or sutures.
2. To perform a limbal peritomy by grasping the conjunctiva and Tenon`s capsule at the level of the limbus with a toothed forceps and with a conjunctival scissors. The

extension varies according to the size of the cyst. Radial relaxing incisions is made through the conjunctiva and Tenon's capsule in oblique meridians to prevent tearing of the conjunctiva during the surgery and avoid further complications as a symblepharon formation.

3. Scleral exposure has taken care to avoid damage of the vortex veins.
4. Isolated two or three rectus muscles according to the place the surgeon is going to do the scleral incision. Here is important to highlight do not cut the muscle belly to avoid bleeding. Using a muscle hook passed underside and 4-0 silk suture is passed around the muscle to do the fixation.

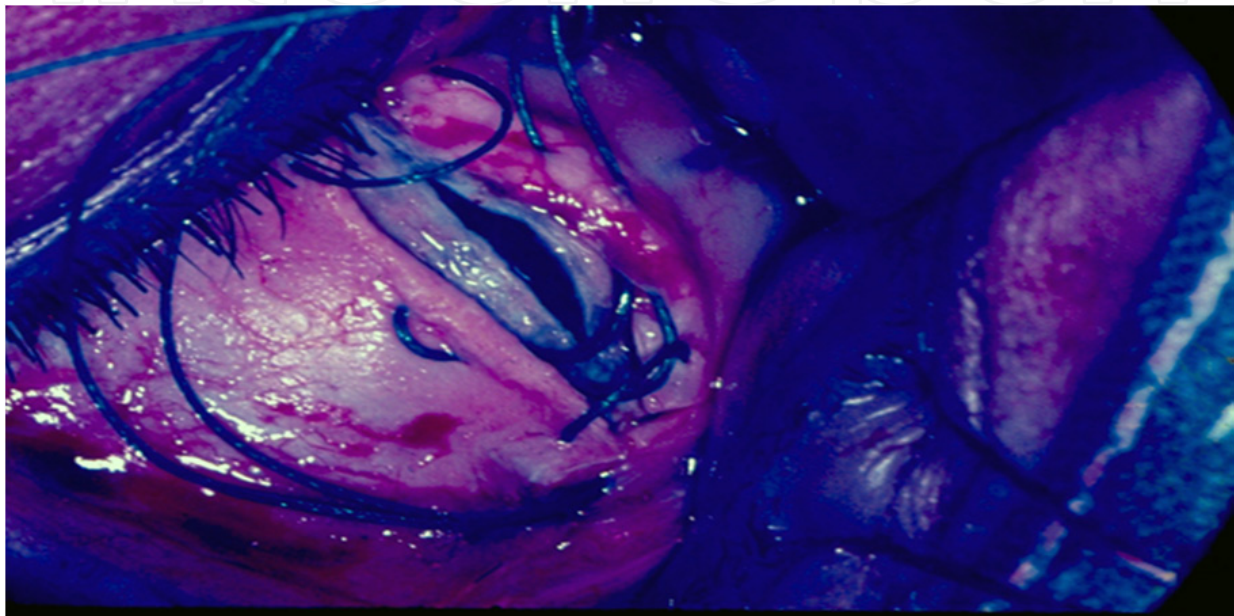


Figure 6. External approach to subretinal cysticercosis.

5. Localization of the subretinal cyst is done again with the indirect ophthalmoscope and the assistant help to mark the limits on the sclera where the incision will be made. These marks can be done with the use of the diathermy or with a surgical pen.
6. The Scleral incision has to be made at right angles to the surface of the sclera to maintain a uniform depth of the undermining. The incision should extend more than two thirds of the scleral thickness to have a floor for the placement of the diathermy treatment to avoid bleeding trans operators
7. 4-0 or 5-0 polyester sutures with spatulated needle to close the scleral flap are used. The sutures are placed 2mm apart in a radial fashion and approximately 1.5 mm from the edge of the scleral flap. Two or three mattress sutures are placed in each quadrant. If the incision is bigger than a single quadrant with 2 sutures in each one is enough. The sutures cannot be placed under the muscles.
8. The scleral lamina is perforated and the cyst is expressed out through a choroidal incision.
9. Sometimes more diathermy is necessary
10. Scleral sutures are closed, suture of the muscles release and closure of the Tenon's and the conjunctiva with Vicryl is done.

11. In case the cyst burst during the extraction a thorough irrigation has to be done.

Subretinal cyst anterior to the equator may be removed trans sclerally, whereas subretinal cysts posterior to the equator and intravitreal cysts are best removed transvitreally. [112]

Under conventional surgical procedures by sclerotomy exactly over the subretinal *cyst* localized by scleral depression under indirect ophthalmoscopy, other authors also obtained successful surgical removal of subretinal cysticerci including patients with an associated exudative retina detachment with extensive gliosis, fixed folds, focal retinitis, and multiple subretinal precipitates specially near to the cyst but fatal results in patients presenting multifocal intraocular cysticercosis and severe NCC (even in the non-pork eaters) is obtained. [178]

In the treatment of intraocular cysticercosis, the most common surgical approach is removal through the pars plana route following vitrectomy. Ideally, the cyst should be removed in toto. Complete surgical removal of the intact cyst results in good functional recovery in eyes with intraocular cysticercosis. [29] Systemic corticosteroids are used before and after surgical removal of the cysticercus.

Patnaik and Kalsi [178] also reported a progressive pre-retinal gliosis with the passage of time with the evagination of the scolex against the retina, the latter is perforated, often in more than one point. They comment that the cyst through one of these perforations can escape into the vitreous cavity and the detached retina continues to shrink with increasing gliosis and vitreous becomes progressively hazy which becomes totally impenetrable with massive exudation then the parasite cannot be located. It may be presumed that the sudden advent of massive inflammation is associated with rupture of the cyst or death of the parasite. The eye is lost with massive inflammation. Even the successful removal of the subretinal cyst if not conducted early enough may not prevent the progressive deterioration of the retina and vitreous probably because of continued inflammation. The same results were reported by others. [178-182]

3.3. Optic nerve neurocysticercosis

The cysticercosis does not affect the spinal nerves or cranial nerves.

The optic (second cranial) nerve is the nerve of sight, and it extends from the eye to the optic chiasm. Developmentally, it may be considered as a tract between the retina (a derivative of the brain) and the brain. The nerve fibers, which arise in the retina, converge on the optic disc, pierce the layers of the eye, and receive myelin sheaths. The optic nerve, itself, is surrounded by meningeal sheaths continuous with those of the brain, and also by the subarachnoid space. As is known the optic nerve originates from the axonal extensions of the ganglion cells of the retina which is an extension of the central nervous system. Therefore this type of presentation of cysticercosis should be grouped within the category of Neurocysticercosis. (NCC)

Although other zoonotic parasites (Trematode) have been found in the layers of the retina at longitudinal position [183] the size and shape of cysticercus exceed the thickness of the retina so that its location is below it, and in close relation to the vascular layer of which is nourished. For certain reasons when the larva is leaving the subretinal region only has the option to do so toward the vitreous cavity because the resistance given by the sclera to be crossed.

The NCC of the optic nerve is extremely uncommon and until today no more than 10 patients have been well documented. [184-200]

As we discussed in the previous chapter orbital cysticercosis as a presentation of disseminating cysticercosis has not been reported in the medical literature excepting one anecdotal case [194]. The first well documented patient presenting optic nerve cysticercosis was from India (1991). Other authors [185] reported a 15-years-old female with progressive deterioration of her visual acuity of seven months duration. Her CT scan revealed a right retrobulbar optic nerve thickened with small area of low attenuation in the thickened portion of the optic nerve. A diagnosis of optic nerve glioma or granulomas was considered and a right frontal craniotomy and extradural frontal orbitomy was performed, they found an intense fibrosis and on deeper incision a sago grain like cyst was identified and excised. Histopathology revealed it to be a cysticercosis. Postoperatively the patient's vision full was completely recovered but there was an oculomotor nerve paresis. Similar patient was not described previously. Five years later, Bousquest et al [186] reported a first case of intraoptic neurocysticercosis in a 12-year-old boy living on Reunion Island (France). They also initially considered a diagnosis of optic nerve tumor and later computerized tomography scans and surgical aspects confirmed a diagnosis of retrobulbar optic nerve cysticercosis recommending a conservative removal using en bloc orbitotomy because of good functional and aesthetic results. Despite a first case was reported before we would like to highlight that Bousquest [186] was the first to use the correct terminology for cysticercosis involving the optic nerve such as: Intraoptic neurocysticercosis.

Other anecdotic report about the occurrence of optic neuritis following oral albendazole therapy for orbital cysticercosis was done in 1998 [187] but this one served to highlight the importance of adding a steroid medication to Albendazole in the treatment of all cases of orbital cysticercosis mainly when cysts are in close proximity to the optic nerve. They confirmed a full visual recovery after resolution of optic neuritis after four weeks treatment with Prednisolone at the dose of 1mg/kg per day.

Another 15-years-old-female presenting cysticercosis of the optic nerve is reported by Gurha et al [188] This patient presented with rapidly diminishing vision in the left eye, headache and papillitis. A magnetic resonance imaging revealed a cystic lesion at the entrance of the optic canal. Surgery performed was a transcranial orbitotomy which included deroofing of the optic canal and removal of the cyst from under the sheath of the optic nerve and the outcome was a remarkable visual recovery. At the same time a 15-year-old boy presented with diminution of vision which rapidly progressed to no perception of light. In the ocular fundus, a neuroretinitis-like picture was seen. On CT-scan and ultrasonography, an optic

nerve swelling was detected with a shadow of scolex. Abnormal P-100 values of visual evoked potential can be useful for supporting a differential diagnosis.

This condition is often mistaken for optic nerve tumors and on neuroimaging the diagnosis is often delayed or missed. [197] However, imagenology studies based on contrast-enhanced MR imaging study and contrast-enhanced CT usually reveals a ring-enhancing cyst with a mural nodule located in the optic nerve although sometimes it only shows a thickened of the optic nerve with or without ring-enhancing lesion containing an eccentric nodule. [190,193, 197, 198] Ultrasonography can also help to determine the cause of optic neuritis due to the disorganization of the cyst with inflammation of the adjacent optic nerve. [187, 191, 193, 195, 197-201] and these investigations are useful to confirm: response to the treatment and patient's compliance. Other investigation to support the diagnostic process is an enzyme-linked immunosorbent assay test for cysticercosis. [190, 193, 195, 196]

Medical therapy in the form of steroids along with albendazol was ineffective. Surgical removal by lateral orbitotomy was done and a complete cyst with scolex was removed, which was confirmed histopathologically as a case of retrobulbar optic nerve cysticercosis. [189] Next patient, a 50-year-old woman with atypical optic neuritis was also treated with oral prednisolone and albendazole, with no improvement in vision [190] While other patients presenting optic nerve cysticercosis including bilateral optic nerve involvement improved dramatically with prednisone and albendazole. [191, 193,195]

4. Conjunctival cysticercosis

Ocular and extraocular cysticercosis are a commonly encountered manifestation of the disease caused by the *cysticercus cellulosae*. Any region of the eye may be afflicted including the subconjunctival space. The conjunctiva is a connection between the eyelids, sclera and cornea. It is the mucous membrane that lines the posterior surface of the eyelids (palpebral conjunctiva) and the anterior aspect of the globe (bulbar conjunctiva).

The host inflammatory response to cysticerci located into the conjunctival depends on the parasite's ability to evade host immunity; therefore, inflammation is restricted to degenerating cysts whose ability to evade host defenses is faltering. Lack of inflammation occurs with both healthy cysticerci (vesicular stage) and those that have involuted (inactive disease). Upon involution, cysts undergo granulomatous change and exhibit calcification. [70] It almost never happens in the conjunctiva region. Subconjunctival cysticercosis usually presents as a painful, yellowish, nodular subconjunctival mass with surrounding conjunctival congestion or may even present as an eyelid nodule or even as subconjunctival abscess from orbital myocysticercosis. [202] Patients presenting lacrimal canalicular obstruction have been reported as well. [85, 97]

The most common outcome is the spontaneous extrusion of the *T solium* cysticercus. [90-92, 94-96,98, 203] sometimes they got extruded from the orbit or from subconjunctival space but almost always associated with clinical improvement. [90]

Anterior subconjunctival cysts may be treated with excision biopsy. As the cyst is usually adherent to the adjacent muscle, excision may be difficult. Care must be taken to keep the extraocular muscle intact during dissection because an excessive intraoperative dissection of the subconjunctival cyst may damage the extraocular muscle fibers, leading to postoperative diplopia and strabismus. [89, 99]

5. Extraocular muscle cysticercosis

Extraocular muscles differ histologically from most other skeletal muscles in that they are made up of two different types of muscle cells. Each muscle cell is composed of groups of myofibrils called sarcomeres. Fast-twitch muscle fibrils generate fast eye movements and are composed of well-defined myofibrils with well-developed sarcomeres while slow-twitch muscle fibrils generate slow or tonic eye movements and are composed of poorly defined myofibrils with poorly developed sarcomeres. Cholinergic motor neurons supply both types of muscle fibers. The innervation to fast-twitch fibrils is thick and heavily myelinated, with a single (en plaque) neuromuscular junction, whereas the innervation to slow-twitch fibrils is thin, with multiple grapelike clusters of neuromuscular junctions. [204] The eye's major blood supply comes from the ophthalmic artery. The lateral muscular branch of the ophthalmic artery supplies the lateral rectus, superior rectus, and superior oblique muscles. The medial muscular branch supplies the inferior rectus, medial rectus, and inferior oblique muscles. Medial and lateral muscular branches of the artery give rise to seven anterior ciliary vessels, which travel with the four rectus muscles to provide circulation for the anterior segment of the eye. Each rectus muscle has two anterior ciliary vessels, except for the lateral rectus muscle, which has 1 vessel. These vessels pass anteriorly to the episclera and supply the anterior segment of the eye, including the sclera, limbus, and conjunctiva. [204]

The extraocular muscles rotate the eyeball around vertical, horizontal and antero-posterior axes. Extraocular muscles other than the medial rectus and lateral rectus have more than one action due to the angle they make with the optical axis of the eye while inserting into the eyeball. The superior and inferior oblique muscles make an angle of 51 degrees with the optical axis.

As we before-cited, orbital cysticercosis is an uncommon presentation of cysticercosis even in endemic countries. In some South African provinces where it was seen before, it does exist at the present moment, and infestation of extraocular muscle remains exceedingly rare; but because of the versatility of the presentation, cysticercosis still should be considered in the differential diagnosis of many orbital disorders, especially in an endemic region and extraocular muscle cysticercosis should be considered in the differential diagnosis of recent acquired motility disorder or proptosis. According to several publications in the international medical literature and based on our experience we fully support that cysticercosis is a pleomorphic disorder whose presentation depends on a combination of inflammatory response, topography of the lesions, degree of parasitic load and sequelae of previous infestation as was established by others as well. [78, 205-208]

The rectus muscles are all approximately 40 mm long and each receives innervation from the undersurface (intraconal space) at the junction of the middle and posterior thirds of the muscle or 26 mm from the insertion

To achieve a better understanding of this variant of solium tapeworm infestation of the extraocular muscles, we have decided to merge the contents of sub chapter in accordance to the affected muscles after committing a first attention to the more important type of presentation: the proptosis.

Before continue, our readership should remember that other causes of thickening of the extraocular muscle such as: fatty infiltration of the muscle can also cause a bulging of the eye anteriorly out of the orbit (Graves-Basedow disease) but in those cases we prefer the medical term: exophthalmos. In other words, we reserve the medical terminology of exophthalmos for those cases of protrusion of the eyes related to endocrine dysfunction.

One of the primary symptoms of extraocular cysticercosis is double vision (diplopia) from misalignment of the visual axes, and the pattern of image separation is the key to diagnosing which particular cranial nerve (and extraocular muscle) is involved. Therefore, at this stage is important to know how to approach these patients. Our first recommendation is to break down between monocular (i.e. present with one eye closed) and binocular diplopia (far more common). For causes of monocular diplopia is important to check the ophthalmological function mainly. If binocular diplopia is present then is important to look for: variations on the quality of diplopia through the day (myasthenia gravis), associated endocrinopathy (Graves-Basedow disease), orbital fracture (most likely to cause inferior oblique palsy), orbital tumours, gaze palsy (progressive supranuclear palsy, brainstem disorders, Wernicke's, Miller-Fisher, cavernous sinus syndrome, etc.). If your patient complains of diplopia on looking in one diagonal direction, it is either the same-sided and oriented rectus muscle or the other-sided oppositely-oriented oblique muscle; e.g. diplopia on looking up and right, it is either right superior rectus or left inferior oblique. If your patient complaints of diplopia on looking down and left is either left inferior rectus or right superior oblique. Finally, if you cover up an eye when the patient is complaining of diplopia, the eye that, when covered, takes away the most peripheral image is the problem.

5.1. Proptosis of the eyes secondary to cysticercosis

We use the medical terminology of proptosis when there is a protrusion of one or both eyeballs by at least two millimeters but less than 18 mm, which can be congenital, familial, or due to a pathological condition not secondary to endocrinopathies.

Apart from extraocular cysticercosis as a cause of proptosis other etiologies include: leukemias, orbital cellulitis, meningioma of the sphenoid wing, dacryoadenitis, mucormycosis, dermoid, orbital fracture of the apex, floor, medial wall or zygomatic bone, Duane syndrome, cavernous sinus syndrome, congenital glaucoma, nasopharyngeal angiofibroma, Hand-Schuller-Christian disease, hemangioma, high altitude cerebral edema

(proptosis), Beckwith–Wiedemann syndrome, aortic incompetence: manifests as a pulsatile pseudo proptosis, Wegener's granulomatosis and Pfeiffer syndrome.

Proptosis due to cysticercosis has been reported also in children, usually presenting progressive painful protrusion of the eye with redness, lacrimation and diminution of vision [206] but it is an uncommon cause of proptosis in all age groups with reported incidence varying from 0 to 20%, [208-213] some authors say that the commonest cause of proptosis is medial rectus cysticercosis [208] and the frequency of proptosis among other signs of orbital cysticercosis is around 20-30% preceded by ocular motility restriction (60-64%) and followed by diplopia (35-38%) and palpebral ptosis (12-16%). [77]

5.2. Levator palpebrae superioris muscle cysticercosis and palpebral ptosis

The Levator palpebrae superioris originates on the lesser wing of the sphenoid bone, just above the optic foramen. It broadens and becomes the Levator aponeurosis. This portion inserts on the skin of the upper eyelid, as well as the superior tarsal plate. It is a skeletal muscle. The superior tarsal muscle, a smooth muscle, is attached to the levator palpebrae superioris, and inserts on the superior tarsal plate as well. (See figure 7)

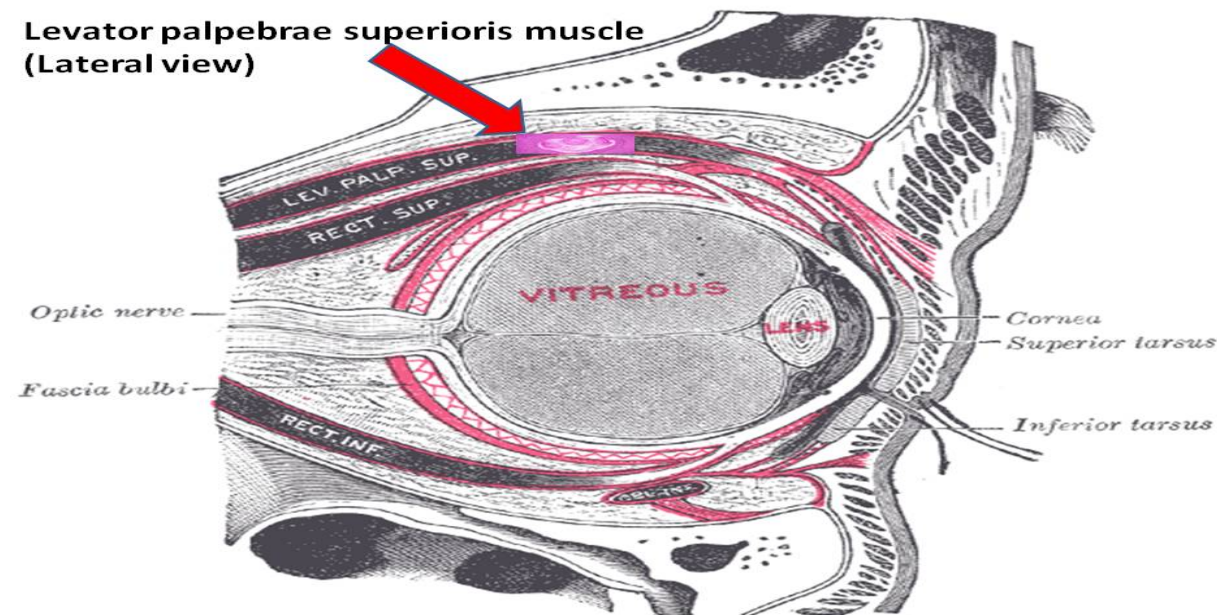


Figure 7. Representation of cysticercosis in the Levator palpebrae superioris.

It is well known that cysticercosis of the extraocular musculature is rare and within this group the affection of the eyelid is about 0.6% [77] despite the number of patients reported in the medical literature. [214-217] The Levator palpebrae superioris muscle cysticercosis presenting clinically as ptosis is much more uncommon than other affected extraocular muscles. [218, 219]

Cysticercosis of the Levator palpebrae superioris, superior rectus, eyelid or anterior orbit are important differential diagnoses for acquiring ptosis. [219] Features suggestive of Levator

palpebrae superioris myocysticercosis include a young patient from an endemic region with a suggestive exposure history, proptosis, mild lid edema or erythema and a palpable cystic eyelid mass. [136] Sekhar et al [78] reported that subconjunctival cyst might be related to ptosis and suggested that the surgical removal of the parasite is a good management.

Only six patients (all from India) have been reported in the medical literature, they had between 9 and 23 years of age and most of some of them complained of unilateral ptosis, inflammation of the upper eyelid and restricted ocular motility while another complained of mild upper eyelid discomfort without display or decreased vision and no lid erythema or edema plus full extraocular movements in all directions of gaze. [14, 29, 218, 219]

There are also other parasitic infestations that can induce ptosis. Echinococcosis [220] and trichuriasis [221] are the two widely mentioned parasitic infestations that can induce ptosis. Therefore neuroimaging studies are useful to distinguish myocysticercosis from other cystic lesions of the extraocular muscles, such as echinococcus granulosus (hydatid cyst), cystic tumors or extraocular myositis with cystic changes. A hydatid cyst lacks a scolex and does not usually demonstrate intense rim enhancement. However, CT may be preferable as intracranial CT can identify cerebral cysticercosis, which was as high as 16.7% in a case series of myocysticercosis. [155] The diagnosis by neuroimaging is important as myocysticercosis responds well to anti-helminthic therapy, while surgical excision is the primary treatment modality for hydatid cysts or tumors. Ultrasound and CT scan appear comparable in ability to detect the scolex. [29, 136]

In patients presenting fluctuating palpebral ptosis with negative neostigmine and electrophysiological tests (pseudo myasthenia) cysticercosis of midbrain should be investigated because focal encephalitis and edema at the midbrain may cause this symptomatology. [222]

Indeed, ocular cysticercosis is not a rare disease in the developing countries, and ptosis due to cysticercosis is sporadically reported [223] but it should keep it mind during the differential diagnosis of unilateral eyelid ptosis.

5.3. Superior rectus muscle cysticercosis

The superior rectus muscle is a muscle in the orbit. It is one of the extraocular muscles. It is innervated by the superior division of the oculomotor nerve (Cranial Nerve III). In the primary position (looking straight ahead), the superior rectus muscle's primary function is elevation, although it also contributes to intorsion and adduction.

Extraocular muscle cysticercosis is the most common site of this parasitic disease when involving the orbit. [224]

In some series of patients with extraocular cysticercosis, the superior rectus muscle is the most commonly affected (33.3%) compared other involved muscles. [77] and clinical features usually are painful unilateral ptosis, inflammation of the upper eyelid and some

restriction on down gaze. Diagnosis is made by neuroimagen studies that show a well-defined ring-enhancing lesion in the superior rectus muscle. [14]

Angotti-Neto et al [224] reported a 38-year-old Brazilian female patient with extraocular muscle enlargement and a small cystic lesion near the insertion of the superior rectus muscle treated with oral prednisone for almost one year due to a non-specific inflammation of right orbit diagnosis later confirmed as superior rectus muscle cysticercosis. That report illustrates the consequences of delayed antiparasitic treatment leading to leading to marked hypertrophy and limitation of infraduction and later an incomplete recovery. It also serves to emphasize that cysticercosis should be included in the differential diagnosis of extraocular muscle enlargement, especially in cases of orbital inflammation non-responsive to corticosteroid treatment. Although the differential diagnosis of extraocular muscle enlargement is extensive, including Graves' orbitopathy, myositis, carotid cavernous fistula, lymphoma, metastatic and primary tumors, when associated with other clinical signs such as lid retraction or pain with eye movement, a correct diagnosis can usually be established. [225] Less frequent conditions include arteriovenous fistulas and malformations and orbital tumors. [226]

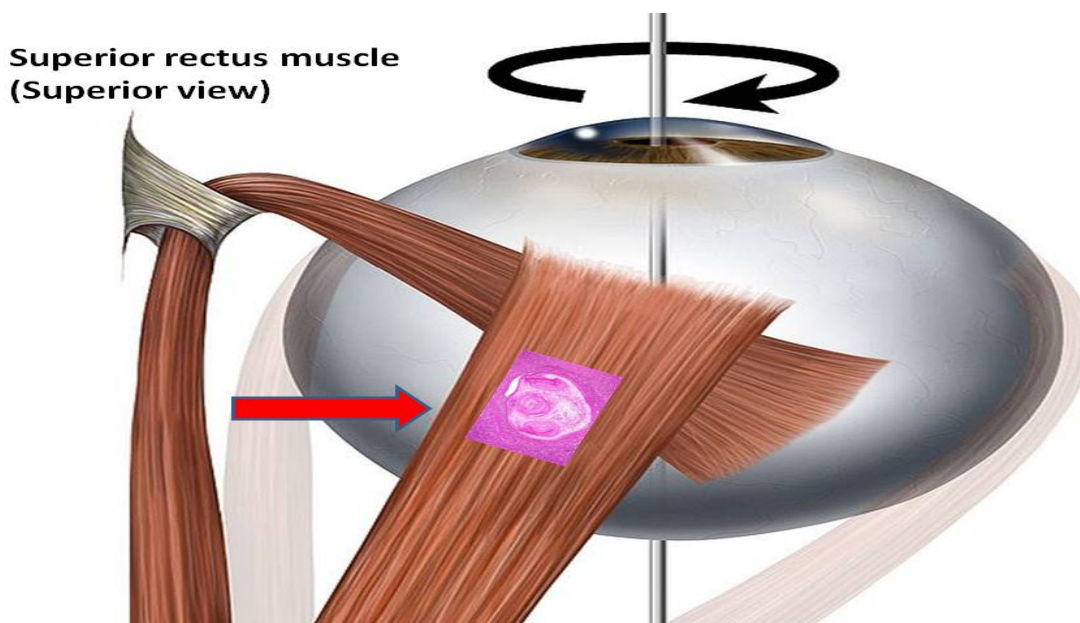


Figure 8. Cysticercus near to insertion of superior rectus muscle in the eyeball.

5.4. Inferior rectus muscle cysticercosis

The inferior rectus muscle is another muscle in the orbit. (See figure x) It depresses, adducts, and helps extort (rotate laterally) the eye. The inferior rectus muscle is the only muscle that is capable of depressing the pupil when it is in a fully abducted position.

An isolated paralysis of the inferior rectus muscle is often congenital in our experience. However, it may also occur following orbital trauma, especially after fracture of the orbital floor; from vascular disease; or in conjunction with myasthenia. [197] The diagnosis is made

on the basis of the prism and cover test in the diagnostic positions and an examination of ductions and versions. The deviation is greatest on attempts to look downward with the affected eye in abduction (Fig. 9). The unopposed action of the antagonistic superior rectus muscle causes the paretic eye to be incyclotropic and hypertrophic in primary position. When the patient fixates with the paretic eye in primary position, pseudoptosis may occur in the sound eye, creating diagnostic problems. Ocular torticollis is a frequent occurrence but is not of diagnostic value since the head may be tilted to either side. [197]

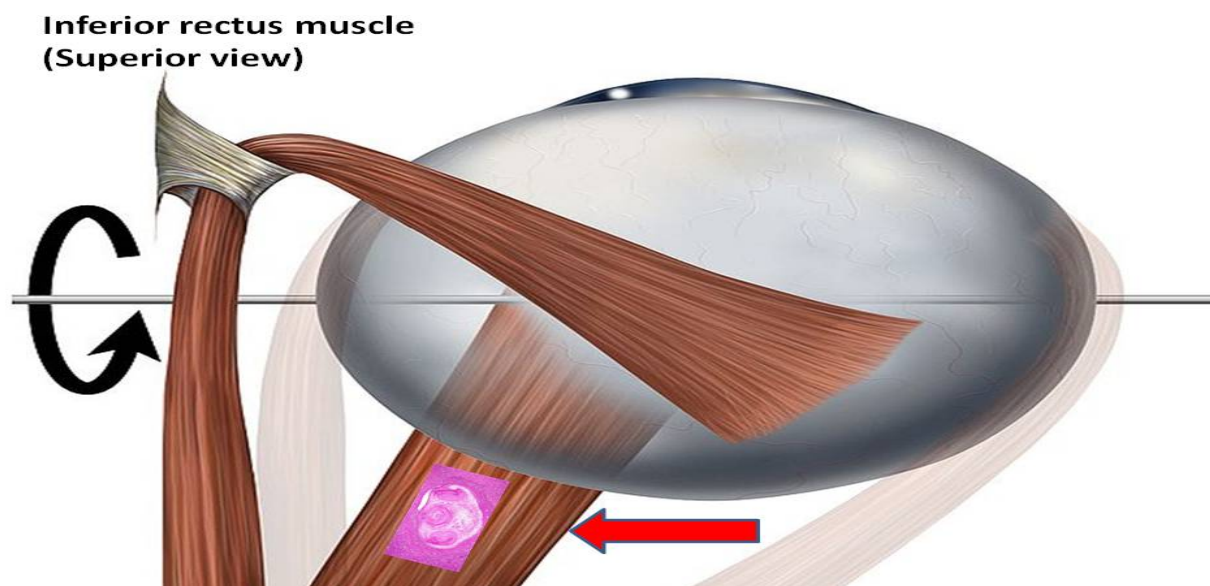


Figure 9. Representation of T solum cysticercosis in the inferior rectus muscle

The inferior rectus muscle was commonly involved in one study. [29] Inferior rectus cysticercosis like other the affected extraocular muscle typically shows fusiform enlargement of its belly and contain a well-defined, spherical cyst with a nodule attached to its wall. This nodule and the enlarged muscle show intense enhancement on the contrast-enhanced studies. [227, 228]

In Meher' series [227] about six patients presenting extraocular muscle cysticercosis two of them had inferior rectus muscle involvement and proptosis for the eyes but imaging studies of the brain showed no evidence of cerebral cysticerci in any of the patients and not palpable subcutaneous nodules were found.

Based on the clinical features of patients reported in the medical literature [229] and our observations, the commonest symptom and signs of the inferior rectus cysticercosis are eccentric proptosis and restriction of upward gaze no associated with loss of vision or painful eyes. MRI orbit is the investigation of choice which can reveal a cystic lesion in the belly of inferior rectus muscle, hypointense on T1 and hyperintense on T2 weighted images and a tiny eccentric hypointense speck suggestive of scolex can be seen.

Shadangi et al [229] have noticed that the cysticerci of the extraocular muscles travel forward, come to lie in a subconjunctival location and then extrude out spontaneously and

they have adopted a policy to wait and watch in these cases. They avoid giving steroids and anthelmintic as these suppress inflammation and delay the movement of the cyst outward, and hence, its extrusion. Because delayed treatment can favored chronic inflammatory process, associated fibrosis and permanent damage on the physiology of the muscles, in our opinion, each patient should be assessed individually and a decision should be taken accordingly.

Isolated inferior rectus muscle palsy resulting from a nuclear third nerve lesion as the initial manifestation of multiple sclerosis has been reported in the medical literature. [230]

5.5. Superior oblique muscle cysticercosis

The superior oblique muscle, or obliquus oculi superior, is a fusiform muscle originating in the upper, medial side of the orbit (i.e. from beside the nose) which abducts, depresses and internally rotates the eye. It is the only extraocular muscle innervated by the trochlear nerve (the fourth cranial nerve).

The primary (main) action of the superior oblique muscle is intorsion (internal rotation), the secondary action is depression (primarily in the adducted position) and the tertiary action is abduction (lateral rotation).

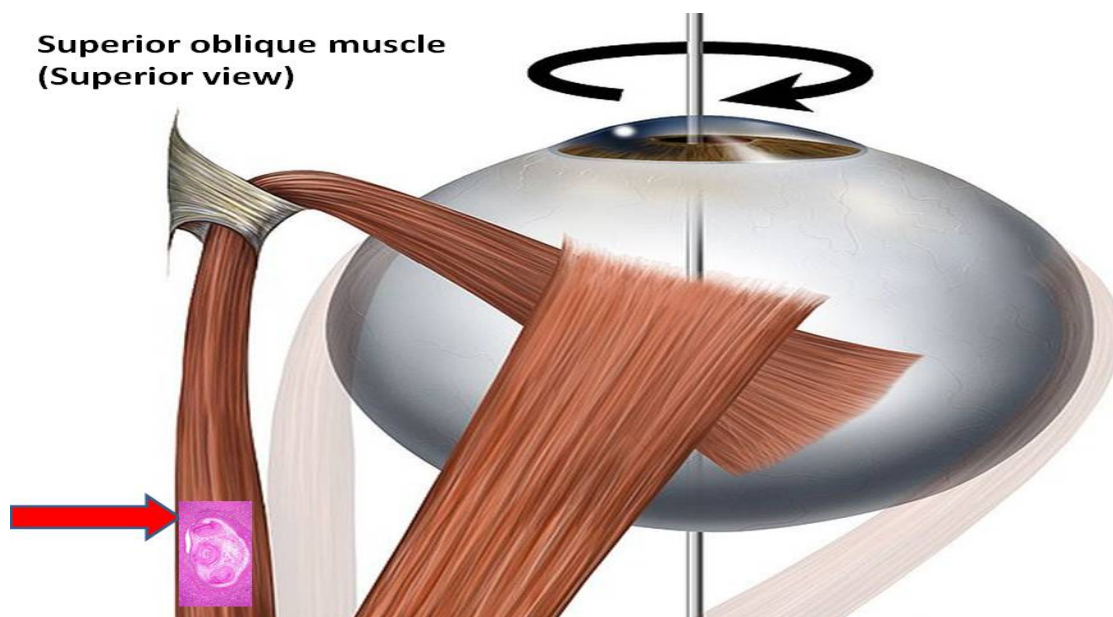


Figure 10. Superior oblique myocysticercosis

The depressing action of the superior oblique (making the eye look down towards the mouth) is most effective when the eye is in an adducted position. This is because as the eye is abducted (looks laterally), the contribution made by superior oblique to depression of the eye decreases, as the inferior rectus muscle causes this movement more directly and powerfully. The main muscle for abduction is the lateral rectus, so although superior oblique contributes to a downwards and lateral eye movement, testing this motion would not be specific enough as inferior and lateral recti muscles would also be tested. Therefore,

during neurological examinations, the superior oblique is tested by having the patient look inwards and downwards, testing only the depressing action of the muscle. This is a source of confusion on the subject as although clinical testing asks the patient to adduct and depress the eye, anatomically the muscle depresses and abducts it.

The great importance of intorsion and extorsion produced by the two oblique muscles can only be understood when it is considered with regards to the other muscle actions present. The two obliques prevent the eye from rotating about its long axis (retina to pupil) when the superior and inferior rectus muscles contract. This is because the orbit does not face directly forwards- the centre-line of the orbit is a little over 20 degrees out from the mid-line. But because the eyes do face forwards, when acting alone, as well as making the eye look up, superior rectus causes it to rotate slightly about the long axis, so the top of the eye moves medially (intorsion). Similarly, in addition to making the eye look down, inferior rectus would cause the eye to rotate about the long axis so the top of the eye moves slightly laterally (extorsion), if acting alone. Clearly this is undesirable as our vision would rotate when we looked up and down. For this reason, these two rectus muscles work in conjunction with the two obliques. When acting alone, superior oblique causes intorsion, inferior oblique, and extorsion. Hence, when inferior rectus contracts so we look down, superior oblique has also contracted to prevent extorsion of the eye, and when superior rectus contracts so we look up, inferior oblique contracts to prevent intorsion, thus the undesired rotatory actions of the inferior and superior rectus about the long axis of the eye are cancelled out. This keeps our vision horizontally level, irrespective of eye position in the orbit.

In one of the large series of patients presenting extraocular muscle cysticercosis (n=35) the average age was 19.6 years, no differences between female and males were found and the most common clinical feature was restricted ocular motility with diplopia and recurrent pain and redness. [194] In the superior oblique muscle cysticercosis are kept the same demographic and clinical feature described for other extraocular muscles. However, the lateral rectus, medial rectus and the superior oblique were affected to a greater extent and in all cases the extraocular muscle cysticercosis can be suspected in cases of acquired ocular motility disorder with recurrent ocular congestion. Perhaps the most interesting aspect of superior oblique cysticercosis is its clinical presentation as: Brown syndrome and Canine tooth syndrome.

Brown syndrome is defined as an ocular motility disorder, characterized by an inability to elevate the adducted eye actively or passively. In 1950, Harold W. Brown first published on an unusual motility disorder, characterized by the following: limited elevation in adduction; divergence in straight upgaze (V-pattern); same degree of limitation on versions, ductions, and forced ductions; widening of the palpebral fissure on adduction; normal or near normal elevation in abduction; restricted forced ductions to elevation in adduction; and compensatory chin elevation for binocular fusion.

Diplopia may occur when the patient looks up and to the contralateral side of the affected eye. Patients with congenital Brown syndrome rarely complain of diplopia, because most patients have developed suppression. The most common signs of Brown syndrome include:

supranasal orbital pain, tenderness. Limited elevation in adduction, an invariable sign, is the hallmark of Brown syndrome and pain that is associated with this ocular movement. The canine tooth syndrome is an ocular motility disorder comprising ipsilateral Brown's syndrome and superior oblique muscle dysfunction. Ocular motility shows ipsilateral deficit of elevation and depression, maximum in an adducted position. Typically this follows a dog bite (hence the name) that damages the trochlea and superior oblique muscle concurrently but it can be caused by trauma to the trochlear area, producing a "double Brown syndrome"; secondary to strengthening the superior oblique along with a residual superior oblique palsy, or a combination of local trauma to the trochlea causing restriction to upgaze along with closed head trauma producing a trochlear nerve disorder. Trochlear nerve palsy is the most common cause of vertical diplopia then apart from periocular pain, and lid swelling, an upgaze vertical diplopia can be present. [231-242]. Superior rectus muscle cysticercosis should be considered in the differential diagnosis of acquired motility disorder.

Lee and O'Halloran [239] described the case of a 5-year-old girl traumatized from a dog bite to the superior aspect of the orbit in the right eye. The dog's canine tooth penetrated deep into the posterior orbit and severed the attachment of the superior oblique muscle of the globe posterior to the trochlea leading to the clinical presentation before-cited.

The acquired Brown syndrome is known to occur after trauma, iatrogenic events, cysts of superior oblique muscle, tenosynovitis, and systemic lupus erythematosus. [238, 243,244] Although surgical excision and reconstruction of the superior oblique tendon has been reported [230] this aspect will be discussed under the subchapter of treatment.

Rao et al [238] reported seven patients presenting Brown syndrome secondary to superior oblique muscle cysticercosis. All patients had the ocular motility limitation, ie, limitation of elevation in adduction (characteristic of Brown syndrome) and associated pain and swelling in the superior nasal orbit.

5.6. Inferior oblique muscle cysticercosis

The inferior oblique muscle is a thin, 36 mm long narrow muscle placed near the anterior margin of the floor of the orbit. It originates a few millimeters behind the medial end of the inferior orbital rim just lateral to the lacrimal fossa and proceeds posteriorly and temporally at an angle of 51 degrees with the frontal plane passing beneath the inferior rectus (between the inferior rectus and the floor of the orbit) and inserting posterior to the equator on the inferior and lateral aspect of the globe. [204] Its actions are extorsion, elevation and abduction of the eye. The primary action is extorsion; secondary action is elevation; tertiary action is abduction (i.e. It extorts the eye and moves it upward and outwards). The field of maximal inferior oblique elevation is in the adducted position.

This muscle receives its innervation on its upper surface at the point where it passes beneath the lateral border of the inferior rectus, approximately 12 mm posterior to the lateral corner of the insertion of the inferior rectus. The inferior oblique muscle is unique in its anatomic relationships. This muscle behaves as though it has two potential insertions and two

potential points of origin. Because the inferior oblique is innervated near its middle, it may be weakened either proximal or distal to its point of innervation.

The inferior oblique muscle is the only muscle that is capable of elevating the eye when it is in a fully adducted position. While commonly affected by palsies of the inferior division of the oculomotor nerve, isolated palsies of the inferior oblique (without affecting other functions of the oculomotor nerve) are quite rare and can be confused with Brown syndrome.

In a series of 25 patients with inferior oblique palsy studied by Pollard [245], all presented with a head tilt to the side of the paretic muscle. None of these patients complained of tilting images, but incyclotorsion was measurable in all cases. The most important conclusion from this study is that inferior oblique palsy is a benign entity, with none of these patients having a brain tumor, myasthenia gravis or cysticercosis.

While many vertical deviations that appear to be due to an inferior oblique palsy based on the results of the three-step test may be caused by inferior oblique weakness, skew deviation should also be considered in any patient with a history of head trauma, or other neurological findings. The cyclotorsion observed in inferior oblique palsy is opposite that seen by the ocular tilt reaction, and differentiates the two entities clinically. We postulate that these deviations are caused by damage to the otolithic projections that correspond to those from the ipsilateral posterior semicircular canal (on the side of the hypotropic eye). [246]

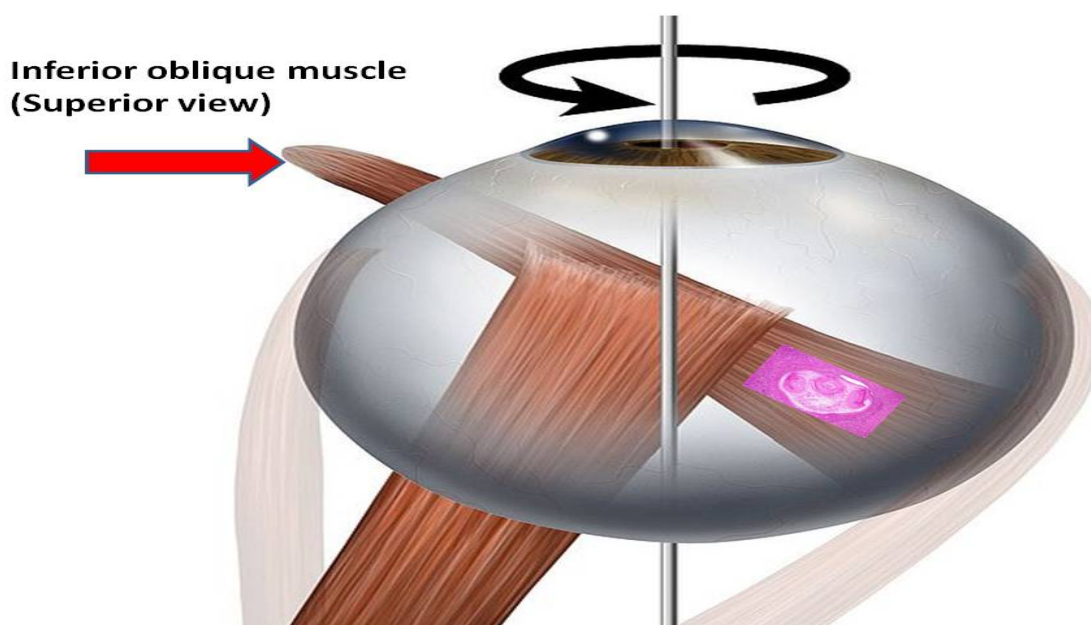


Figure 11. Illustration of inferior oblique muscle cysticercosis close to its insertion in the eyeball.

The common causes of inferior oblique muscle dysfunctions are facial trauma, endoscopic ethmoidectomy, superior oblique muscle palsy (overaction of the inferior oblique muscle), unilateral inferior oblique anterior transposition. [24, 247, 248] Overaction of the inferior oblique muscle is manifest by over the elevation of the adducted eye. It is a common enigma

in the field of ocular motility and it may occur secondary to a weak contralateral superior rectus muscle or a weak ipsilateral superior oblique muscle. [248-250]

Based on our experience and an extensive review of the medical literature we conclude that cysticercosis of the inferior oblique muscle practically does not exist in human beings compare with other presentations. Despite the inferior oblique muscle has the same change to be infected by *T. solium* like other extraocular muscles, we think it is rarer than the other because the inferior oblique is unique among the extraocular muscles in that, in many cases, weakening of this muscle, even with extensive surgery, seems to have relatively little effect on the movement of the globe or alignment of the eyes. Therefore isolated cysticercotic lesion on the inferior oblique muscle can be asymptomatic. Even in patients presenting a relatively uncommon inferior oblique paresis due to other causes, strabismus is much less than would occur after paresis of any of the other muscles. Effective weakening of this muscle could be made more difficult because of the unique anatomy. Likewise neurologically, the muscle innervation by the inferior branch of cranial nerve III makes isolated paralysis extremely uncommon. [250]

Of all the extraocular muscles supplied by the oculomotor nerve, the inferior oblique muscle is less likely to become paralyzed. The onset is usually congenital but the trauma has been mentioned as a cause. In primary position the affected eye may be hypotropic or the unaffected eye hypertrophic, depending on whether the patient fixates with the nonparalyzed or paralyzed eye. The greatest deviation occurs when the patient attempts to elevate the adducted paretic eye. Overreaction of the unopposed ipsilateral superior oblique muscle causes incyclotropia. In all patients whom we have evaluated, onset was congenital. As in the case of superior oblique paralysis, the anomalous head posture is more characteristic than in paralyzes of the vertical rectus muscles. As a rule the head is inclined toward the paralyzed side, and the face is turned to the uninvolved side, but there are exceptions. The Bielschowsky head tilt test is positive on tilting the head to the normal side. The forced duction test is necessary in making this diagnosis, since the prevalence of Brown syndrome is far greater than paralysis of the inferior oblique muscle and since the defect of ocular motility is clinically similar. However, with Brown syndrome the involved eye is frequently depressed more severely in adduction than it is with inferior oblique paralysis.

5.7. Lateral rectus muscle cysticercosis

Each rectus muscle inserts at a different distance from the limbus. The lateral rectus muscle is one of six extraocular muscles that control the movements of the eye (abduction in this case) and the only muscle innervated by the abducens nerve, cranial nerve VI. Its function is to bring the pupil away from the midline of the body. It is tested clinically by asking the patient to look laterally.

As we before-mentioned the extraocular muscles have differences undoubtedly related to their very specialized function. Both skeletal and extraocular muscles have several types of twitch fibers, but the extraocular muscles are unique, having tonically contracting fibers not

found in skeletal muscle. There are two muscle fiber layers in the medial and lateral recti. The shorter orbital layer inserts in the muscle pulley, and the longer global fibers insert into sclera at the muscle's *insertion*. The muscle fibers are long, traversing the entire length of the muscle, or in some cases, nearly so. The medial and lateral extraocular muscles have the lowest innervation ratio of any of the muscles of the body; that is, they have the *most* nerve fibers per muscle fiber which support the stringent requirements of accuracy of fixation and smoothness of following required to support a visual apparatus capable of both rapid, accurate movement and sustained fixation. There is evidence, not always corroborated but accumulating nonetheless, showing that the extraocular muscles participate in proprioception. Muscle spindles and other muscle sensors communicate by means of an *inflow* mechanism which is functional but apparently less powerful than the *outflow* mechanism generated from stimuli arising in the retina. [251]

**Lateral rectus muscle
(Superior view)**

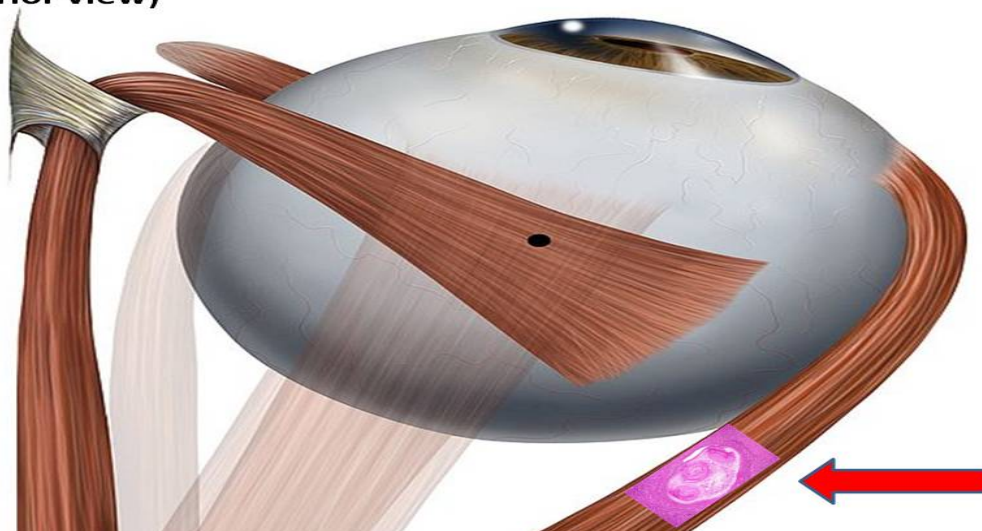


Figure 12. Illustration of the lateral rectus muscle myocysticercosis

Lateral rectus palsy is commonly seen in patients presenting intracranial hypertension due to NCC, because abducen nerves has the longest pathway along to the subarachnoid space and it can be damaged by raise intracranial pressure without focalizing the intracranial lesion. Like other extraocular muscles first clinical symptom is diplopia (horizontal) To differentiate horizontal diplopia secondary to abducen palsy from horizontal diplopia secondary to lateral rectus muscle cysticercosis is an easy task if other symptoms and signs of intracranial hypertension of orbital cysticercosis are present. In our series intracranial hypertension is most commonly seen in patients with intraventricular and subarachnoid NCC whom a complaint of epilepsy, headache, nausea, vomiting, and cognitive dysfunction and they can present meningeal sings and focal neurological signs. Patients with lateral rectus cysticercosis also complaint of proptosis of the affected eyes, painful eye movements and decrease visual acuity due to optic nerve damage. Imagenology studies are extremely useful to confirm the final diagnosis. [251]

With acquired sixth nerve paralysis it is essential to determine whether the restriction of abduction is caused by paralysis of the lateral rectus muscle, contracture of the medial rectus muscle or a combination of both conditions. The estimation of generating muscle force determines whether residual lateral rectus muscle function is present. [251]

To identify the cause of horizontal diplopia due to a lateral rectus muscle lesion or due to abducens palsy, imagenology studies are mandatory. Below, our readership can see the main differences in two well documented patients.

Abducens palsy is commonly seen as part of the clinical feature of intracranial hypertension because its long pathway across to the subarachnoid space but it is non useful as a focal neurological sing. Another multifactorial cause of abducens palsy is MÖBIUS syndrome which is characterized by congenital bilateral abducens paralysis associated with facial diplegia and microglossia.

In May 2012, the previous patient came to the department of ophthalmology in Nelson Mandela Academic Hospital complaining of pain on the left eye, horizontal diplopia, poor vision, and proptosis of the left eye. She was assessed by two of us (MCSC and HFS). Apart from CT scan findings, the ELISA test for Ig G antigen (*Tenia solium*) in the cerebro-spinal fluid was positive. She is still under medical treatment with prednisone and albendazol and responding well to the medications.

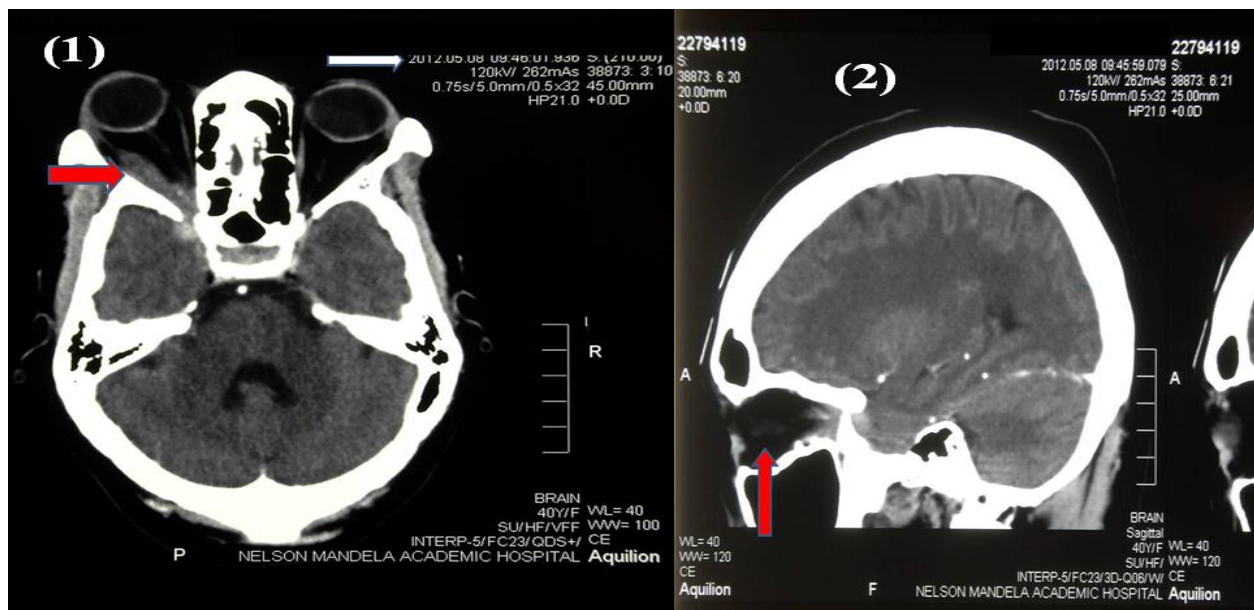


Figure 13. CT scan axial view (1) shows proptosis of the left eyes and lateral rectus myocysticercosis. Intramuscular cyst with “scolex” within is seen. Lateral view (2) shows enlargement of the lateral rectus muscle and an associated intraparenchymal neurocysticercosis (calcified lesions).

Another two patients from our series presented horizontal diplopia secondary to abducens palsy, headache and chronic seizure disorder came to Neurology clinic and CT scans of the brain confirmed intraventricular NCC (2) and subarachnoid NCC (1), in both patients ELISA tests for serum antigen and Western blot were positive for *T. solium*.

Extraocular cysticercosis associated to disseminate cysticercosis including NCC can be seen. It was communicated by Patwardhan and Bhatti. [111] in India. They reported a young male patient presented with a complaint of blurring of vision in the left eye for a few days. Funduscopy examination showed vitreous haze, localized in the lower half, of the vitreous. A clearly defined, spherical, white mass somewhat resembling a dislocated lens, was seen in the vitreous body and anterior to the retina, freely mobile, lying in the lower temporal quadrant. This mass showed occasional contractile waves passing through it. Systemic examination showed the presence of subcutaneous nodules on the scalp, and neck. CT Scan confirmed multiple neurocysticercosis cysts involving superior and medial rectus bilaterally and right lateral rectus.

One or more extraocular muscles may be simultaneously involved, although a propensity for involvement of the superior muscle complex and the lateral rectus muscles has been most commonly reported. [90, 194] As we explained before, according to muscle involved, patients will present different clinical manifestations such as; Brown syndrome, Canine tooth syndrome, Duane retraction, Skew deviation, overreaction, different types of diplopia, painful proptosis. Also acquired strabismus, recurrent redness and some of the clinical signs in patients with orbital cysticercosis can be observed. [70]

5.8. Medial rectus muscle cysticercosis

The medial rectus muscle is a muscle in the orbit. The medial rectus is said to insert in the normal eye 5.5 mm from the limbus.

As with most of the muscles of the orbit, it is innervated by the inferior division of the oculomotor nerve (Cranial Nerve III).

This muscle shares an origin with several other extrinsic eye muscles, the annulus tendineus, or common tendon.

It is the largest of the extraocular muscles and its only action is adduction of the eyeball. Its function is to bring the pupil closer to the midline of the body. It is tested clinically by asking the patient to look medially.

In our experience, an isolated paralysis of the medial rectus muscle due to cysticercosis without involvement of other muscles is very uncommon. In this type of weakness or paralysis the greatest defect of ocular motility occurs when the affected eye goes to adduction position. In the differential diagnosis of an isolated medial rectus paralysis, internuclear ophthalmoplegia is listed.

Cysticercosis as a cause of medial rectus myositis have been reported by others [197, 208, 218, 221, 252- 256] most of patients presented headache, orthotropia in primary gaze, painful drooping of the eyelid, decrease visual acuity, and on examination of the ocular motility, abduction deficit with the resulting horizontal diplopia is found. Sometimes the head of patients turns to the non-paretic side to allow them to attain single binocular vision. The most common extra ocular muscle to get involved in cysticercosis is the medial rectus. [197]

Isolated medial rectus cysticercosis may be associated with ptosis and upper lid retraction on attempted adduction (aberrant regeneration) in patients with partial third nerve paralysis. Medial rectus cysticercosis must be distinguished from internuclear ophthalmoplegia (INO), caused by lesions in the medial longitudinal fasciculus. In this condition unilateral or bilateral limitation of adduction is associated with nystagmus of the abducting eye. Convergence may or may not be normal and we will discuss briefly about this matter below. A clinical picture similar isolated medial rectus cysticercosis or INO can be caused by myasthenia gravis but a Tensilon test is diagnostic. Restriction of adduction may be caused by an excessively resected lateral rectus muscle.

**Medial rectus muscle
(Superior view)**

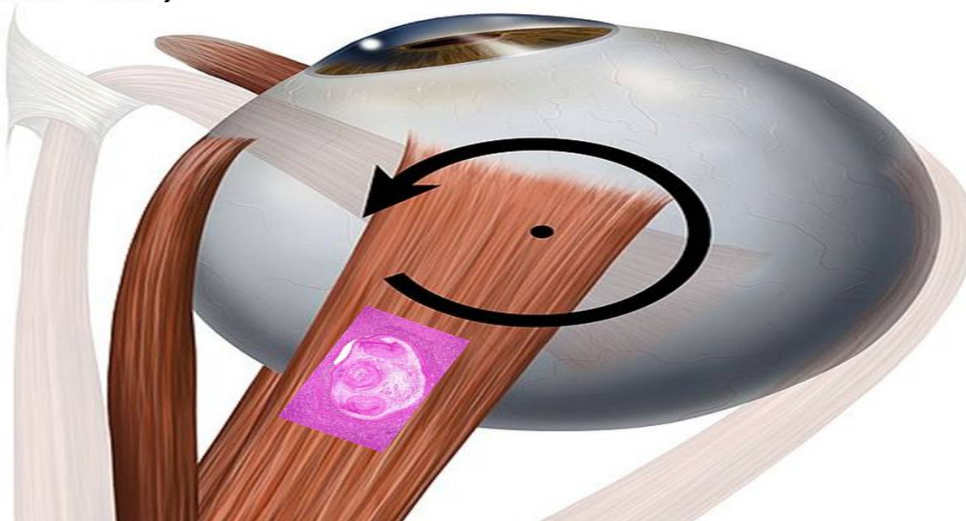


Figure 14. Medial rectus myocysticercosis

One of the most important differential diagnoses of medial rectus palsy cysticercosis is with isolated medial rectus palsy as a sign then clinically is easier to perform. There are an important number of publications related to isolated medial rectus palsy in of midbrain infarction but if impaired adduction of the ipsilateral eye is associated with a bilateral ptosis and normal pupil function midbrain infarction. [259-263]

6. Treatment of extraocular muscle cysticercosis

Contact B-scan ultrasonography was a diagnostic test of cysticercosis in 84.4% of patients [77] but the accuracy of a CT scan and MRI is more than 98% in our series.

Surgical excision of an extraocular muscle cyst had been described [77, 177, 194, 202]. In contrast to medical treatment, surgical excision is technically difficult due to the attachment of the cysts to underlying orbital structures, the amorphous consistency of degenerating cysticerci and the risk to neurovascular structures in the posterior orbit. [29] There is also a likelihood of postoperative restrictive myopathy arising from the fibrotic response in surgical excisions of large cysts or in cysts requiring extensive dissection from the

underlying muscle. [215] The potential risk of damage to adjacent tissue and adhesion from surgical exploration should not be taken lightly, particularly when effective medical therapy is available. As a general consent medical treatment with albendazole and prednisone is the best choice taken by most of the authors and recommended duration of treatment varies from a few days to up to 6 weeks. [29, 95,155, 194,197, 204- 208, 218,219, 220, 223, 224, 227-232,237-240, 242, 252, 253,255, 264-266]

In some, cyst elimination rates were more than 90%, and time to recovery of ocular motility ranged between 0.5 and 35 month. [136, 155, 265]

Although oral albendazole and prednisone are efficient, a long history of disease can lead to important residual ocular motility restriction [220] and some author found that oral albendazole and prednisone are not effective thus their role in ocular cysticercosis need to be studied. [256]

In the next figure we summarize the frequency of affected extraocular muscle by cysticercosis.

In some, cyst elimination rates were more than 90%, and time to recovery of ocular motility ranged between 0.5 and 35 month. [136, 155, 265]

Although oral albendazole and prednisone are efficient, a long history of disease can lead to important residual ocular motility restriction [220] and some author found that oral albendazole and prednisone are not effective thus their role in ocular cysticercosis need to be studied. [256]

In the next figure we summarize the frequency of affected extraocular muscle by cysticercosis before medical treatment.

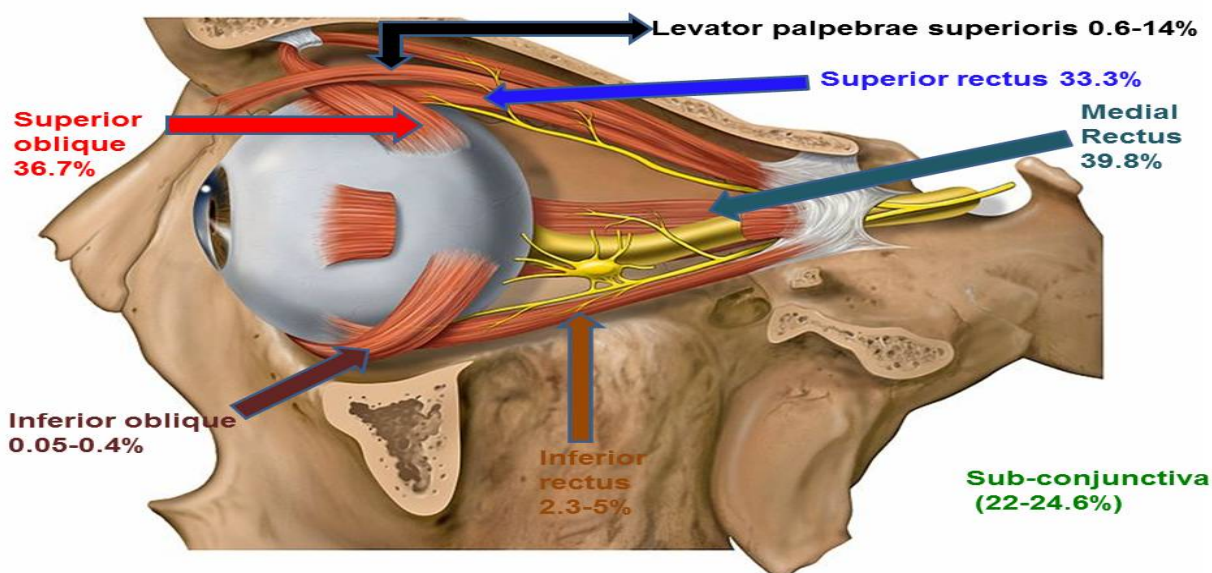


Figure 15. Distribution of extraocular myocysticercosis in the orbital cavity.

7. Conclusion

The cysticercosis of the orbit is an uncommon zoonotic parasitic disease. Its early diagnosis and appropriate treatment avoid the permanent loss of vision. The surgical treatment is the best choice in intraocular cysticercosis while medical treatment is the best choice for extraocular presentations including the extraocular muscles cysticercosis. The adequate knowledge of the anatomy and physiology of the intra orbital content contributes to a better diagnosis. Sometimes the patience helps resolve the conflicts that create the conjunctiva cysticercosis. It must take into account other processes that mimic the orbital cysticercosis in their differential diagnosis. Although it is a rare disease it is a challenge for those health professionals committed to the management of these patients.

Author details

Humberto Foyaca Sibat, María Carolina Salazar Campos
and Lourdes de Fátima Ibañez Valdés

*Department of Neurology and Department of Ophthalmology, Nelson Mandela Academic Hospital,
Faculty of Health Sciences, Walter Sisulu University, South Africa*

Acknowledgement

For understanding my long nights at the computer, I'd like to thank my wife Lourdes de Fátima, who was worked with me on this project; to my first daughter Zayra Susana who died in 1979 but continues inspiring me from wherever she is; to my second daughter Lorna Maria who is a good lawyer and encourages me all the time to continue moving forward, and to my children Fatima Susana Adolfini (3 years old) and Thabo Humberto Jorge (4 years old) for helping me to find peace of mind, persistence and hope every time I needed. My father, my sisters, nephews, nieces, aunts, uncles, cousins and almost all members of my family contributed to this project in one way or another - to all of them: a great Thank You indeed.

8. References

- [1] Sotelo J. Neurocysticercosis. Eradication of cysticercosis is an attainable goal. *BMJ*. 2003;326(7388):511–512.
- [2] Hotez PJ; Bottazi ME, Franco-Paredes C, Ault SK, Periago MR. The Neglected Tropical Diseases of Latin America and the Caribbean: A Review of Disease Burden and Distribution and a Roadmap for Control and Elimination. *PLoS Neglected Tropical Diseases* 2008; 2: e300 doi:10.1371/journal.pntd.0000300.
- [3] García HH, Gonzalez AE, Evans CA, Gilman RH; Cysticercosis Working Group in Peru. *Taenia solium* cysticercosis. *Lancet*. 2003; 362: 547-556.
- [4] García HH, Del Brutto OH; Cysticercosis Working Group in Peru. Neurocysticercosis: updated concepts about an old disease. *Lancet Neurol*. 2005; 4:653-661.

- [5] Román G, Sotelo J, Del Brutto O, Flisser A, Dumas M, Wadia N et al. A proposal to declare neurocysticercosis an international reportable disease. *Bull World Health Organ* 2000; 78: 399-406.
- [6] Sawhney IM, Singh G, Lekhra OP, Mathuriya SN, Parihar PS, Prabhakar S. Uncommon presentations of neurocysticercosis. *J Neurol Sci.* 1998;154(1):94-100.
- [7] Loo L, Braude A: Cerebral cysticercosis in San Diego: a report of 23 cases and review of the literature. *Medicine (Baltimore)* 1982;61:341-350.
- [8] McComick G, Zec Chi-S, Heiden J. Cysticercosis Cerebri. Review of 127 cases. *Arch Neurol* 1982; 39:534-539.
- [9] Carpio A. Neurocysticercosis: an update. *Lancet Infect Dis* 2002;2:751-762.
- [10] Wadia N, Desai S, Bhatt M: Disseminated cysticercosis. New observations, including CT scan findings and experience with treatment by praziquantel. *Brain* 1988, 111:597-614.
- [11] Bhalla A, Sood A, Sachdev A, Varma V. Disseminated cysticercosis: a case report and review of the literature *Medical Case Reports* 2008; 2:137-140.
<http://www.jmedicalcasereports.com/content/2/1/137> (accessed May 04, 2012).
- [12] Foyaca-Sibat H, Ibanez-Valdes LdeF, Mashiyyi MK. Disseminate Cysticercosis. One-day treatment in a case. *Rev Electron Biomed / Electron J Biomed* 2004;3:39-43.
<http://biomed.uninet.edu/2004/n3/foyaca-n.html> (accessed 05 May,2012).
- [13] Park SY, Min HK, Jung HK, Kwan YS. Disseminated cysticercosis. *Journal of Korean Neurosurgical Society.* 2011;49(3):190-193.
- [14] Basu G, Surekha V, Ganesh A. Disseminated cysticercosis. *Trop Doct.* 2009;39(1):48-99.
- [15] Pushker N, Bajaj MS, Balasubramanya R. Disseminated cysticercosis involving orbit, brain and subcutaneous tissue. *J Infect.* 2005;51(5):245-248.
- [16] Narang P, Chhibbers S, Puri SK. Middle-aged man with altered behaviour and seizures. *The British Journal of Radiology,* 81 (2008), 984–986.
- [17] Jakhere SG, Chemburkar VC, Yeragi BS, Bharambay HV. Imaging findings of disseminated cysticercosis with unusual involvement of spleen and pancreas. *J Glob Infect Dis.* 2011 Jul;3(3):306-308.
- [18] Sandeep GJ, Vipul CC, Bhakti SY, Himanshu VB. Imaging Findings of Disseminated Cysticercosis with Unusual Involvement of Spleen and Pancreas. *J Glob Infect Dis.* 2011;3(3):306–308.
- [19] Niakara A, Cisse R, Traore A, Niamba PA, et al. Myocardial localization of a disseminated cysticercosis. Echocardiographic diagnosis of a case. *Arch Mal Coer Vaiss* 2002;95(6):606-608.
- [20] Blandon R, Leandro IM: Human Cardiac cysticercosis. *Rev Med Panama.* 2002;7- 40.
- [21] Foyaca-Sibat H, L. Ibanez-Valdes L: Generalized Cysticercosis With Cardiac Involvement. *The Internet Journal of Neurology.* 2007 Volume 7 Number 2.
<http://www.ispub.com/journal/the-internet-journal-of-neurology/volume-7-number-2/generalized-cysticercosis-with-cardiac-involvement.html>. (accessed 05 May 2012)
- [22] Thomas MB, Thomas KM, Awotedu AA, Blanco-Blanco E, Anwary M. Cardiocysticercosis. *S Afr Med J* 2007;97(7):504-505.
- [23] Eberly MD, Soh EK, Bannister SP, Taraf-Motamen H, Scott JS: Isolated Cardiac Cysticercosis in an adolescent; *Pediatr Infect Dis J.* 2008; 27(4); 369-71.

- [24] Jain BK, Sankhe SS, Agrawal MD, Naphade PS. Disseminated cysticercosis with pulmonary and cardiac involvement. *Indian J Radiol Imaging* 2010;20:310-313.
- [25] Scholtz L & Mentis H, Pulmonary cysticercosis. *SAMT* 1987 ;72(17) :573
- [26] Mamere AE, Muglia VF, Simao GN, Belucci AD, Carlos dos Santos A, Trad CS, et al. Disseminated cysticercosis with pulmonary involvement. *J Thorac Imaging* 2004;19:109–111.
- [27] Banu A, Veena N. A rare case of disseminated cysticercosis: Case report and literature review. *Case Report*. 2011;29(2):180-183.
- [28] Sekhar GC, Honavar SG. Myocysticercosis: experience with imaging and therapy. *Ophthalmology*. 1999;106(12):2336-2340.
- [29] Bhigjee AI. Disseminated cysticercosis. *J Neurol Neurosurg Psychiatry* 1999;66(4):545
- [30] Thomas MB, Thomas KM, Awotedu AA, Blanco-Blanco E, Anwary M. Cardiocysticercosis. *South Africa Medical Journal*. 2007; 97(7): 504-505
- [31] Sobnach S, Khosa SA, Pather S, Longhurst S, Kahn D, Raubenheimer PJ. First case report of pharyngeal cysticercosis. *Trans R Soc Trop Med Hyg*. 2009;103(2):206-208.
- [32] White AC Jr. Neurocysticercosis: updates on epidemiology, pathogenesis, diagnosis and management. *Ann Rev Med* 2000;51:187-206.
- [33] Foyaca-Sibat H. Epilepsy Secondary to Parasitic Zoonoses of the Brain, *Novel Aspects on Epilepsy*, Humberto Foyaca-Sibat (Ed.), ISBN: 978-953-307-678-2, InTech, Rijeka, 2011.
- [34] Sarti E, Schantz PM, Plancharte A, Wilson M, Gutierrez R, Lopez AS, Roberts J, Flisser. Prevalence and risk factor for *Taenia solium* taeniasis and cysticercosis in humans and pigs in a village in Morelos, Mexico. *Am J Trop Med Hyg* 1992; 46:677-684.
- [35] Garg RK. Neurocysticercosis. *Postgrad Med J* 1998; 74(872):321-326.
- [36] Schantz PM, Moore AC, Muñoz JL, et al.: Neurocysticercosis in an Orthodox Jewish community in New York City. *N England J Med* 1992;327:692-696.
- [37] Rousseau MC, Guillotel B, Delmont J. Neurocysticercosis in the South-East of France 1988-1998. *Presse Med* 1999;28(39):2141-2144.
- [38] O'Neal S, Noh J, Wilkins P, Keene W, Lambert W, Anderson J, Compton Luman J, Townes J. *Taenia solium* Tapeworm Infection, Oregon, 2006-2009. *Emerg Infect Dis*. 2011 Jun;17(6):1030-1036.
- [39] Kelesidis T, Tsiodras S. Extraparenchymal neurocysticercosis in the United States: a case report. *Journal of Medical Case Reports* 2011;5:359 .
- [40] Serpa JA, Graviss EA, Kass JS, White AC Jr. Neurocysticercosis in Houston, Texas: an update. *Medicine (Baltimore)*. 2011;90(1):81-86.
- [41] Wallin M, Kurtzke J. Neurocysticercosis in the United States: review of an important emerging infection. *Neurology* 2004; 63: 1559-1564.
- [42] Pawlowski ZS. Control of neurocysticercosis by routine medical and veterinary services. *Trans R Soc Trop Med Hyg* 2008;102:228-232.
- [43] Takayanagui OM, Odashima NS. Clinical aspects of neurocysticercosis. *Parasitol Int*. 2006;55:S111–S115.
- [44] Sánchez L, Abad L, Lozano E, Maldonado G. Neurocysticercosis intraventricular. Presentación de un caso localizado en el tercer ventrículo. *Radiologia*. 2002;44:309-313.

- [45] Amaral L, Maschietto M, Maschietto R, Cury R, Ferreira NF, Mendonça R, et al. Unusual manifestations of neurocysticercosis in MR imaging : analysis of 172 cases. *Arq Neuropsiquiatr*. 2003;61:533–541.
- [46] Sarti E. La taeniasis y cisticercosis en México (revisión bibliográfica). *Salud Pública Mex* 1986; 28:556-563.
- [47] Rabiela MT, Lombardo L, Flores F. Cisticercosis cerebral. Estudio de 68 casos de autopsia. *Patología (Mex)* 1972; 10:27-40.
- [48] Lopez-Hernández A, Garaizar C. Childhood Cerebral Cysticercosis: clinical features and computed tomographic findings in 98 Mexican children. *Can J Neurol SC* 1982;9:401-407.
- [49] Flisser A. Neurocysticercosis in Mexico. *Parasitol Today*.1988; 4:131-137.
- [50] Sotelo J, Penagos P, Escobedo F, Del Brutto OH: Short course of albendazole therapy for neurocysticercosis. *Arch Neurol*. 1988;45:1130-1133.
- [51] Agapejev S. Epidemiology of Neurocysticercosis. in Brazil. *Rev Inst Med Trop Sao Paulo* 1996;38(3):207-216.
- [52] Ramírez G, Pradilla G, Rodríguez M, González C. Cisticercosis. Estudio de 80 casos. *Acta Med Colombiana* 1986;11:62-73.
- [53] Botero D. Cisticercosis en Colombia. Investigaciones realizadas hasta 1988. *An Acad Med Medellin* 1989;2(II):75-82.
- [54] Takayanagui OM, Jardim E. Clinical aspects of neurocysticercosis: analysis of 500 cases. *Arq Neuropsiquiatr* 1983; 41(1):50-63.
- [55] White AC Jr. Neurocysticercosis: updates on epidemiology, pathogenesis, diagnosis and management. *Ann Rev Med* 2000;51:187-206.
- [56] Foyaca-Sibat H, Del Rio AR, Ibañez-Valdés LdeF, Vega-Novoa EC, Awotedu A. "Neuroepidemiological survey for Epilepsy and knowledge about neurocysticercosis at Sidwadweni location, South Africa" *Electron J Biomed* 2004;2(1):40-48.
<http://www.biomed.edu/2004/n1/foyaca.html>
- [57] Foyaca-Sibat H, Del Rio-Romero AH, Ibañez-Valdés LdeF, Vega-Novoa E. Neuroepidemiological Survey For Epilepsy And Knowledge About Neurocysticercosis At Ngqwala Location, South Africa. *The Internet Journal of Neurology* 2005 3(2).
http://www.ispub.com/journal/the_internet_journal_of_neurology/volume_3_number_2_31/article/neuroepidemiological_survey_for_epilepsy_and_knowledge_about_neurocysticercosis_at_ngqwala_location_south_africa.html
- [58] Foyaca-Sibat H, A. Del Rio-Romero, Ibañez-Valdés LdeF : Prevalence Of Epilepsy And General Knowledge About Neurocysticercosis At Ngangelizwe Location, South Africa . *The Internet Journal of Neurology*. 2005 Volume 4 Number 1.
http://www.ispub.com/journal/the_internet_journal_of_neurology/volume_4_number_1_30/article/prevalence_of_epilepsy_and_general_knowledge_about_neurocysticercosis_at_ngangelizwe_location_south_africa.html
- [59] Foyaca-Sibat H, Del Rio A: "Epilepsy, Neurocysticercosis and, Poverty at Mphumaze and Marhambeni Locations, in South Africa". *The Internet Journal of Neurology (ISSN: 1531-295X)*. 2007;7(1):8-14.

- http://www.ispub.com/journal/the_internet_journal_of_neurology/volume_7_number_1_7/article/epilepsy_neurocysticercosis_and_poverty_at_mphumaze_and_marhambeni_locations_in_south_africa.html
- [60] Foyaca-Sibat H, Ibañez-Valdés LdeF, Del Rio IA: "Prevalence of Epilepsy and General Knowledge about Neurocysticercosis at Ngangelizwe Location, South Africa". The Internet Journal of Neurology.(ISSN: 1531-295X). 2005; 4(1):23-37.
http://www.ispub.com/journal/the_internet_journal_of_neurology/volume_4_number_1_30/article/prevalence_of_epilepsy_and_general_knowledge_about_neurocysticercosis_at_ngangelizwe_location_south_africa.html
- [61] Foyaca-Sibat H, Del Rio- Romero AI: "Prevalence Of Epilepsy In An Endemic Area For Neurocysticercosis In South Africa". The Internet Journal of Neurology.(ISSN: 1531-295X). 2008;9(1):8-18.
http://www.ispub.com/journal/the_internet_journal_of_neurology/volume_9_number_1_6/article/prevalence_of_epilepsy_in_an_endemic_area_for_neurocysticercosis_in_south_africa.html
- [62] Turkulov V, madle-Samardzija N, Canak G, Vukadinov J, Aleksic-Dordevic M. Clinical and diagnostic approaches to neurocysticercosis. *Med Pregl* 2001; 54(7-8):353-356.
- [63] Chimelli L, Lovalho AF, Takayanagui OM. Neurocysticercosis: contribution of autopsies in the consolidated of mandatory notification in Ribeirao Preto-SP, Brazil. *Arq Neuropsiquiatr* 1998; 56(3B):577-584.
- [64] Sanchez AL, Ljungstrom I, Medina MT. Diagnosis of human neurocysticercosis in endemic countries: clinical study in Honduras. *Parasitol Int* 1999;48(1):81-89.
- [65] Foyaca-Sibat H, Ibañez-Valdés LdeF & J. Moré-Rodríguez : Parasitic Zoonoses Of The Brain: Another Challenger?. The Internet Journal of Neurology. 2010 Volume 12 Number 2.
http://www.ispub.com/journal/the_internet_journal_of_neurology/volume_12_number_2_4/article/parasitic-zoonoses-of-the-brain-another-challenger.html
- [66] Foyaca-Sibat H and Ibañez-Valdés L de F. (2011). Treatment of Epilepsy Secondary to Neurocysticercosis, Novel Treatment of Epilepsy, Humberto Foyaca-Sibat (Ed.), ISBN: 978-953-307-667-6, InTech, Available from:
<http://www.intechopen.com/articles/show/title/treatment-of-epilepsy-secondary-to-neurocysticercosis>
- [67] Foyaca-Sibat H.(2011). Epilepsy Secondary to Parasitic Zoonoses of the Brain. Novel Aspects on Epilepsy, Humberto Foyaca-Sibat (Ed.), ISBN: 978-953-307-678-2, InTech, Available from: <http://www.intechopen.com/articles/show/title/epilepsy-secondary-to-parasitic-zoonoses-of-the-brain>
- [68] Murthy GR, Rao AV. Sub-conjunctival cysticercosis. *Indian J Ophthalmol.* Jul 1980;28(2):77-78.
- [69] Menon-Mehta S. Ocular Cysticercosis Treatment & Management. *eMedicine*.2011<http://emedicine.medscape.com/article/1204683-treatment>
- [70] Ziaei M, Elgohary M, Bremner FD. Orbital cysticercosis, case report and review. *Orbit.* Oct 2011;30(5):230-235.
- [71] Ratra D, Phogat Ch, Singh M, Choudhari NS : Intravitreal cysticercosis presenting as neovascular glaucoma. *Indian J Ophthalmol.* 2010;58(1):70-73.

- [72] Kruger-Leite E, Jalkh AE, Quiroz H, Schepens CL. Intraocular cysticercosis. *Am J Ophthalmol* 1985; 99(3):252-257.
- [73] Topilow HW, Yimoyines DJ, Freeman HM, et al. Bilateral multifocal intraocular cysticercosis. *Ophthalmology*. 1981;88(11):1166-1172..
- [74] Kapoor S, Kapoor MS. Ocular cysticercosis. *J Pediatr Ophthalmol Strabismus*. May-Jun 1978;15(3):170-173..
- [75] Sharma T, Sinha S, Shah N, et al. Intraocular cysticercosis: clinical characteristics and visual outcome after vitreoretinal surgery. *Ophthalmology*. May 2003;110(5):996-1004.
- [76] Rath S, Honavar SG, Naik M, Anand R, Agarwal B, Krishnaiah S et al. Orbital cysticercosis: clinical manifestations, diagnosis, management, and outcome. *Ophthalmology* 2010; 117(3):600-5, 605.
- [77] Sekhar GC, Lemke BN. Orbital cysticercosis. *Ophthalmology* 1997; 104(10):1599-1604.
- [78] Natarajan S, Malpani A, Kumar NP, Dutta B. Management of intraocular cysticercosis. *Graefes Arch Clin Exp Ophthalmol* 1999; 237(10):812-814.
- [79] Reddy PS, Satyendran OM. Ocular cysticercosis. *Am J Ophthalmol* 1964;57:664-667
- [80] Malik SR, Gupta AK, Choudhry S. Ocular cysticercosis. *Am J Ophthalmol* 1968;66:1168-1171
- [81] Sen DK, Mathur RN, Thomas A. Ocular cysticercosis in India. *Br J Ophthalmol* 1967;51:630-632
- [82] Rao N, Balakrishnan E. Cysticercosis of the eye. *Orient Arch Ophthalmol* 1967;5:249-252.
- [83] Reddy CC, Gupta VP, Sarada P, Prabhakar V, Reddy DL, Anjaneyulu C. Ocular cysticercosis: A study of 15 cases. *Indian J Ophthalmol* 1980;28:69-72
- [84] Sen DK Cysticercosis cellulosa in the lacrimal gland. orbit end eye lid *Acta Ophthalmologica* 1980;58:144-147.
- [85] Murthy GR, Rao AV. Sub-conjunctival cysticercosis. *Indian J Ophthalmol*. 1980;28(2):77-78.
- [86] Sud RN, Grewal SS Spontaneous expulsion of subconjunctival cysticercosis cellulosa, *Afro Asian J Ophthalmology* 1982;13:82-83.
- [87] Nath K, Gogi R, Zaidi N, Johri A. Cystic lesions of conjunctiva (A clinico-pathological study). *Indian J Ophthalmology* 1983; 31 (1): 1-4.
- [88] Honavar SG, Sekhar CG. Ultrasonological characteristics of extraocular cysticercosis. *Orbit*. Dec 1998;17(4):271-284.
- [89] Bansal RK, Gupta A, Grewal S, Mohan K. Spontaneous extrusion of cysticercosis : Report of three cases. *Indian J Ophthalmol* 1992;40:59-60 Available from: <http://www.ijo.in/text.asp?1992/40/2/59/24401>
- [90] Raina UK, Taneja S, Lamba PA, Bansal RL. Spontaneous extrusion of extraocular cysticercus cysts. *Am J Ophthalmol* 1996;121:438-41.
- [91] Magu, S., Nada, M., Khurana, A.K., Chugh, J.P. Spontaneous extrusion of subconjunctival cysticercus cellulosa. *British Journal of Ophthalmology*. 2000;85(1): 116-117 .
- [92] David S, Mathai E. Ocular cysticercosis-a review of 25 cases. *J Assoc Physicians India* 2000;48:704-707.

- [93] Raina, U.K., Jain, S., Arora, R., Mehta, D.K., Sharma, V. Photographic documentation of spontaneous extrusion of a subconjunctival cysticercus cyst. *Clinical and Experimental Ophthalmology*. 2002; 30(5): 361-362.
- [94] Mohan K, Saroha V, Sharma A, et al. Extraocular muscle cysticercosis: clinical presentations and outcome of treatment. *J Pediatr Ophthalmol Strabismus*. Jan-Feb 2005;42(1):28-33..
- [95] Chand K, Srivastava SK. Spontaneous expulsion of subconjunctival *Cysticercus cellulosae*. *MJAFI*. 2006;62:188-9.
- [96] Kaur A, Agrawal A, Agrawal PK, et al. Lacrimal canicular obstruction by *Cysticercus cellulosae*. *Orbit*. Jun 2006;25(2):163-165.
- [97] Reddy B, Raj, Maurya, A. Spontaneous extrusion of subconjunctival cysticercosis. *Annals of Ophthalmology*. 2007;39(3): 241-242
- [98] Mehdi G, Ansari HA, Akhtar K, Shukla M. Ocular manifestations of cysticercosis: a case report. *Indian J Pathol Microbiol*. 2007;50(2):345-346
- [99] Lesh Jr. Ocular cysticercosis. *Am J Ophthalmol* 1949;32:523-526
- [100] Duke-Elder S, Perkins ES. *System of Ophthalmol. Diseases of uveal tract*. CV Mosby: St. Louis; 1966;11:478-488.
- [101] Hutton WL, Vaiser A, Svnder WB. Pars plana vitrectomy for removal of intravitreal cysticercosis. *Am J Ophthalmol* 1976;81:571-573
- [102] Messner KH, Kammerer WS. Intraocular cysticercosis. *Arch Ophthalmol*. Jun 1979;97(6):1103-5.
- [103] Wood TR, Binder PS. Intravitreal and intracameral cysticercosis. *Ann Ophthalmol*. Jul 1979;11(7):1033-1036
- [104] Topilow HW, Yimoyines DJ, Freeman HM, et al. Bilateral multifocal intraocular cysticercosis. *Ophthalmology*. Nov 1981;88(11):1166-72. (repetido en 77)
- [105] Welsh NH, Peters AL, Crewe-Brown W, Blignaut P, Donnoli P, da Souza BS, et al. Ocular cysticercosis. A report of 13 cases. *S Afr Med J* 1987;71:719-722
- [106] Susanna S, King W, Alan H, Friedman, Fredrick AJ. Infectious causes of posterior uveitis. In : principles and practice of Ophthalmology-clinical practice. Albert DM, [108]
- [107] Seo MS, Woo JM, Park YG. Intravitreal cysticercosis. *Korean J Ophthalmol*. Jun 1996;10(1):55-59
- [108] Adegbehingbe BO, Soetan EO, Adeoye AO. Case report: intraocular cysticercosis. *West Afr J Med*. Dec 2003;22(4):354-355.
- [109] Natarajan S, Malpani A, Kumar Nirmalan P, Dutta B. Management of intraocular cysticercosis. *Graefes Arch Clin Exp Ophthalmol*. Oct 1999;237(10):812-4.
- [110] Patwardhan N, Bhatti SS. Intra-ocular cysticercosis. A case report. *Journal of the Bombay Ophthalmologists' Association*. 2000;10(3):161-164.
- [111] Sharma T, Sinha S, Shah N, et al. Intraocular cysticercosis: clinical characteristics and visual outcome after vitreoretinal surgery. *Ophthalmology*. May 2003;110(5):996-1004
- [112] Ziaei M, Elgohary M, Bremner FD. Orbital cysticercosis, case report and review. *Orbit*. 2011 Oct;30(5):230-235.
- [113] Honavar SG, Sekhar CG. Ultrasonological characteristics of extraocular cysticercosis. *Orbit*. 1998;17(4):271-284.

- [114] Kaur A, Agrawal A, Agrawal PK, et al. Lacrimal canalicular obstruction by cysticercus cellulosa. *Orbit*. 2006;25(2):163-165.
- [115] Pushker, N., Bajaj, M.S., Betharia, S.M. Orbital and adnexal cysticercosis. *Clinical and Experimental Ophthalmology*. 2002; 30(5): 322-333.
- [116] Madigubba S, Vishwanath K, Reddy G, Vemuganti GK. Changing trends in ocular cysticercosis over two decades: An analysis of 118 surgically excised cysts. *Indian J Med Microbiol* 2007;25:214-219. Available from: <http://www.ijmm.org/text.asp?2007/25/3/214/34761> (Accessed on June 09, 2012)
- [117] Schmidt M, Schmidt T, Ugi I. Orbital metastasis of kidney carcinoma. *Klin Monbl Augenheilkd*. 1994 Jul;205(1):40-43.
- [118] Konya E, Hara Y, Umekawa T, Uejima S, Sugiyama T, Kurita T. Two cases of renal cell carcinoma detected by metastasis to another organ. *Hinyokika Kyo*. 1997;43(9):647-650.
- [119] Zdinak LA, Nik NA, Hidayat AA, Hargett NA. Renal medullary carcinoma metastatic to the orbit: a clinicopathologic report. *Ophthal Plast Reconstr Surg*. 2004 Jul;20(4):322-5.
- [120] Sharma K, Verma A, Rathi B, Kumar R, Kanaujia V. Metastatic tumor of orbit presenting as pulsatile proptosis. *Ann Ophthalmol (Skokie)*. 2006 Spring;38(1):69-72.
- [121] Shome D, Honavar SG, Gupta P, Vemuganti GK, Reddy PV. Metastasis to the eye and orbit from renal cell carcinoma--a report of three cases and review of literature. *Surv Ophthalmol*. 2007 Mar-Apr;52(2):213-23.
- [122] Mudiyansele SY, Prabhakaran VC, Davis GJ, Selva D. Metastatic renal cell carcinoma presenting as a circumscribed orbital mass. *Eur J Ophthalmol*. 2008;18(3):483-485.
- [123] Mancini V, Battaglia M, Lucarelli G, Di Lorenzo V, Ditunno P, Bettocchi C, Selvaggi FP. Unusual solitary metastasis of the ciliary body in renal cell carcinoma. *Int J Urol*. 2008 ;15(4):363-365.
- [124] Preechawai P, Amrith S, Yip CC, Goh KY. Orbital metastasis of renal cell carcinoma masquerading as cysticercosis. *Orbit*. 2008;27(5):370-373.
- [125] Alasil T, Khazai B, Loreda L, Rauser ME. Renal cell carcinoma metastasis to the ciliary body responds to proton beam radiotherapy: a case report. *J Med Case Rep*. 2011;3;5:345
- [126] Zubler MA, Rivera R, Lane M. Hepatoma presenting as a retro-orbital metastasis. *Cancer*. 1981;48(8):1883-1885.
- [127] Wakisaka S, Tashiro M, Nakano S, Kita T, Kisanuki H, Kinoshita K. Intracranial and orbital metastasis of hepatocellular carcinoma: report of two cases. *Neurosurgery*. 1990 ;26(5):863-866.
- [128] Font RL, Maturi RK, Small RG, Garcia-Rojas M. Hepatocellular carcinoma metastatic to the orbit. *Arch Ophthalmol*. 1998 Jul;116(7):942-945.
- [129] Barbat V, Morin Y, Metge F, Hamard H. Hepatocellular carcinoma: a case revealed by metastatic orbital tumor. *Rev Med Interne*. 2000;21(1):86-90.
- [130] Gupta R, Honavar SG, Vemuganti GK. Orbital metastasis from hepatocellular carcinoma. *Surv Ophthalmol*. 2005;50(5):485-489.
- [131] Fonseca Júnior NL, Frizon L, Paves L, Wolosker AM, Manso PG. An unusual orbital metastatic lesion: the only finding in a case of hepatocellular carcinoma: case report. *Arq Bras Oftalmol*. 2008 Nov-Dec;71(6):865-867.
- [132] Danis P.: Intraocular cysticercus. *Arch Ophthalmol* 91: 238-9 1974.

- [133] George T, Mathai A, Challa JK, Braganza A, Thomas R. Intravitreal cysticercosis: w did it get there?. *Aust N Z J Ophthalmol*. May;26(2): 159-60, 1998.
- [134] Bajaj MS, Pushker N.: Optic nerve cysticercosis. *Clin Experiment Ophthalmol*. Apr; 30 (2): 140-3, 2002.
- [135] Pushker N, Bajaj MS, Chandra M, Neena. Ocular and orbital cysticercosis. *Actathalmol Scand*. 2001;79 (4):408-413.
- [136] Sharma T, Sinha S, Shah N et al.: Intraocular cysticercosis: clinical characteristics visual outcome after vitreoretinal surgery. *Ophthalmology*. May; 110(5); 996-1004,2003.
- [137] Sachdeva RS, Manchada SK,et al: Freely mobile cysticercus in the anterior chamber. *Indian J Ophthalmol* 43: 135-6, 1995.
- [138] Barraquer J: Lens extraction and extraction of the cysticercus. Annual meeting of AAO and Otolaringology. New York Oct 23, 1963.
- [139] Gross J, Gross FJ, Friedman A. Sistemic Infectious and Inflammatory Diseases. In Tasman w and Jaeger EA, eds. *Duane`s Clinical Ophthalmology* .Philadelphia. JB Lippincott 1995.
- [140] Wender JD, Rathinam SR, Shaw RE, Cunningham ET Jr. Intraocular cysticercosis: case series and comprehensive review of the literature. *Ocul Immunol Inflamm*. 2011;19(4):240-245.
- [141] Chung GW, Lai WW, et al.: Magnetic resonance imaging in the diagnosis of subretinal cysticercosis. *Am J Ophthalmol* 2002;134 (6): 931-932.
- [142] Chowdhary A, Bansal R, Singh K, Singh V.: Ocular cysticercosis- -a profile. *Trop Doct*. 2003;33(3): 185-188.
- [143] David S, Mathai E.: Ocular cysticercosis: a review of 25 cases. *J Assoc Physicians India*. 2000;;48(7):704-707.
- [144] Cano MR.: Ocular Cysticercosis. In Ryan SJ: *Retina* third edition volume II, Medical Retina. St Louis Mosby chapter 92 (1553-1556) 2001.
- [145] George T, Mathai A, Challa JK, Braganza A, Thomas R.: Intravitreal cysticercosis: How did it get there?. *Aust N Z J Ophthalmol*. 1998;26(2):159-160.
- [146] Sloan L et al: Evaluation of enzyme-linked immunoassay for serological diagnosis of cysticercosis. *J Clin Microbiol* 1995;33:3124.
- [147] Sabrosa NA, Zajdenweber M.: Nematode infections of the eye: toxocariasis, onchocerciasis, diffuse unilateral subacute neuroretinitis and cysticercosis. *Ophthalmol Clin North Am*. 2002;15(3): 351-356.
- [148] Sachdeva RSD, Manchanda SK, Abrol S, Wadhwa SC, Ramachandran KA. Freely mobile cysticercus in the anterior chamber. *Indian J Ophthalmol* 1995;43:135-136.
- [149] Wender JD, Rathinam SR, Shaw RE, Cunningham ET Jr. Intraocular cysticercosis: case series and comprehensive review of the literature. *Ocul Immunol Inflamm*. 2011;19(4):240-245.
- [150] Malik SRK, Gupta AK, Chowdhary S. Ocular cysticercosis. *Am J Ophthalmol* 1968;66:1168-1171
- [151] Mathur RN, Abraham L. Cysticercosis of the eye. *Arch Ophthalmol* 67:562-563, 1962
- [152] Gemmel MA. Immunology and regulation of cestode zoonosis. In: *Immunology of Parasitic Infections*, 2nd ed., Cohen S, Sadun EH, eds. London, Blackwell Scientific Publication, 1982

- [153] Chandra A, Singh MK, Singh VP, et al. A live cysticercosis in anterior chamber leading to glaucoma secondary to pupillary block. *J Glaucoma*. Mar 2007;16(2):271-273.
- [154] Adegbehingbe BO, Soetan EO, Adeoye AO. Case report: intraocular cysticercosis. *West Afr J Med*. 2003;22(4):354-355.
- [155] Sihota R, Honavar SG. Oral albendazole in the management of extraocular cysticercosis. *Br J Ophthalmol* 1994;78:621-3.
- [156] Kruger Leite E, Jalkh AE, Quiroz H, Scheppens CL. Intraocular cysticercosis. *Am J Ophthalmol* 1985;99: 252-257.
- [157] Mais FA. Cryosurgery in ocular cysticercosis. *Rev Bras Ophthalmol*. 1969;28:99-106.
- [158] Wittig EO. Ocular cysticercosis—an epidemiological study. *Arq Neuropsiquiatr*. 2001;59:696-701.
- [159] Graefe's Archive for Clinical and Experimental Ophthalmology. August 1996, Volume 234, Issue 8, pp 515-520.
- [160] Proctor N. Tapeworm cyst infestation. *Med Proc* 1964; 10: 168-171.
- [161] Pammenter MD, Rossouw EV. Serological tests for the diagnosis of cysticercosis. *S Afr Med j* 1984;65:875-878.
- [162] Keane JR. Neuro-ophthalmologic signs and symptoms of cysticercosis. *Arch Ophthalmol* 1982; 100: 1445-1448.
- [163] Foyaca-Sibat H, Cowan LD, Carabin H, Serrano-Ocaña G, Krecek RC, Willingham A. "Accuracy of serological exam for the diagnosis of neurocysticercosis in outpatients with epilepsy, Eastern Cape Province, South Africa" *PLOS Neglected Trop. Dis.* Dec. 2009;3(3):1-7.
- [164] Welsh N, Proctor E. *Taenia solium* in the anterior chamber. *Aust j Ophthalmol* . 1977; 1: 73-76.
- [165] Aracena T, Roca FP. Macula and peripheral subretinal cysticercosis. *Ann Ophthalmol* 1981; 13: 1265-1267.
- [166] Santos R, Chavarria M, Aguirre A. Failure of medical treatment in two cases on intraocular cysticercosis. *Amy Ophthalmol* 1984;97:249-250.
- [167] Hutton WL, Vaiser A, Svnder WB. Pars plana vitrectomy for removal of intravitreal cysticercosis. *Am J Ophthalmol* 1976;81:571-573.
- [168] Das JC, Chaudhuri Z, Bansal RL, et al. Viscoexpression of anterior chamber cysticercus cellulosa. *Indian J Ophthalmol*. Jun 2002;50(2):133-135.
- [169] Beri S, Vajpayee RB, Dhingra N, et al. Managing anterior chamber cysticercosis by viscoexpression: a new surgical technique. *Arch Ophthalmol*. 1994;112(10):1279-1280.
- [170] Atul K, Kumar TH, Mallika G, et al. Socio-demographic trends in ocular cysticercosis. *Acta Ophthalmol Scand*. 1995;73(5):438-441.
- [171] Agarwal B, Vemuganti GK, Honavar SG. Intraocular cysticercosis simulating retinoblastoma in a 5 year old child. *Eye*. 2003;17:447-449.
- [172] Luger MH, Stilma JS, Ringens PJ, van-Baaren J.: In-toto removal of a subretinal Cisticercosis cellulosa by pars plana vitrectomy. *Br J Ophthalmol*. 1991;75(9): 561-563.
- [173] Bartholomew RS.: Subretinal cysticercosis. *Am J Ophthalmol*. 1975;79:670-673.
- [174] Zinn KM, Guillory SL and Friedman AH.: Removal of intravitreal cysticerci from the surface of the optic nerve head: a pars plana approach. *Arch Ophthalmol* 1980;98:714-716.

- [175] Santos R, Dalma A, Ortiz E, et al. Management of subretinal and vitreous cysticercosis: role of photocoagulation and surgery. *Ophthalmology*. Aug 1979;86(8):1501-1507.
- [176] Jain IS, Dhir SP, Chattopadhyaya PR, Kumar P. Ocular cysticercosis in North India. *Indian J Ophthalmol*. 1979;27(2):54-58.
- [177] Messner KH, Kammerer WS. Intraocular cysticercosis. *Arch Ophthalmol*. 1979;97(6):1103-1105.
- [178] Patnaik B, Kalsi R. Intraocular cysticercosis in the non-pork eaters. *Indian J Ophthalmol* 1979;27:203-205 Available from: <http://www.ijo.in/text.asp?1979/27/4/203/32629>
- [179] Segal P, Mrzyglod S, Smolarz-Dudarewicz J. Subretinal cysticercosis in the macular region. *Am J Ophthalmol* 1964; 57:655.
- [180] Gupta A, Gupta R, Pandav SS, Dogra MR, Joshi K. Successful surgical removal of encapsulated subretinal cysticercus. *Retina* 1998;18:563-566.
- [181] Lombardo J. Subretinal cysticercosis. *Optometry and vision science* 2001; 78: 188-94.
- [182] Barkeh H, Wong S, Muhaya M. A Rare Case of Subretinal Cysticercosis. *Med J Malaysia*. 2005;60(5):650-652.
- [183] Shea M, Maberley AL, Walters J, Freeman RS, Fallis AM. Intraretinal larval trematode. *Trans Am Acad Ophthalmol Otolaryngol*. 1973;77(6):784-791.
- [184] BawaYS, Wahi PL. Cysticercosis cellulosa of the optic disc with generalized cysticercosis. *Br J Ophthalmol*. 1962; 46(12):753-755.
- [185] Madan VS, Dhamija RM, Gill HS, Boparai MS, Souza PD, Sanchete PC, Bhardwaj JR. Optic nerve cysticercosis: a case report. *J Neurol Neurosurg Psychiatry*. 1991 May; 54(5): 470-471.
- [186] Bousquet CF, Dufour TF, Derome PC. Retrobulbar optic nerve cysticercosis. Case report. *J Neurosurg*. 1996;84(2):293-296.
- [187] Tandon R, Sihota R, Dada T, Verma L. Optic neuritis following albendazole therapy for orbital cysticercosis. *Aust N Z J Ophthalmol*. 1998 Nov;26(4):339-341.
- [188] Gurha N, Sood A, Dhar J, Gupta S. Optic nerve cysticercosis in the optic canal. *Acta Ophthalmol Scand* 1999;77(1):107-109
- [189] Betharia SM, Tandon R, Thanikachalam S, Ramkrishna K, Sen S, Kashyap S, Vashishta S. Retrobulbar optic nerve cysticercosis with surgical removal: a case report. *Orbit* 1999;18(4):311-316
- [190] Menon V, Tandon R, Khanna S, Sharma P, Khokhar S, Vashisht S, Garg I. Cysticercosis of the optic nerve. *J Neuroophthalmol*. 2000 Mar;20(1):59-60.
- [191] Gulliani, B. P; Subhash D; Malik MS; Jain DC. Bilateral Cysticercosis of the Optic Nerve. *Journal of Neuro-Ophthalmology*: 2001;21(3):217-218
- [192] Verma L, Agarwal T, Kulkarni A, Mahajan H, Tandon R. Optic Nerve Cysticercosis. *Arch Ophthalmol*. 2002;120(10):1408-1409.
- [193] Bajaj MS, Pushker N. Optic nerve cysticercosis. *Clin Experiment Ophthalmol*. 2002 Apr;30(2):140-144
- [194] Sundaram PM, Jayakumar N, Noronha V. Extraocular muscle cysticercosis - a clinical challenge to the ophthalmologists. *Orbit*. Dec 2004;23(4):255-262.
- [195] Sudan R, Muralidhar R, Sharma P. Optic nerve cysticercosis: case report and review of current management. *Orbit*. 2005;24(2):159-162.

- [196] Venkatesh R, Ravindran RD, Bharathi B, Sengupta S. Optic nerve cysticercosis. *Ophthalmology*. 2008;115(11):2094.
- [197] Taksande B, Jajoo U, Yelwatkar S, Ashish J. Unusual presentation of orbital cysticercosis-ptosis, diminution of vision and medial rectus weakness: a case report. *Cases J*. 2009; 2: 7025. This article is available from:
<http://casesjournal.com/casesjournal/article/view/7025>
- [198] Chandra S, Vashisht S, Menon V, Berry M, Mukherji SK. Optic nerve cysticercosis: imaging findings. *AJNR Am J Neuroradiol*. 2000;21(1):198-200.
- [199] Goyal, J. L.; Das, S.; Kumar, S.; Chauhan, D.; Baheti, U.; Sangit, V. et al. Retrobulbar Cysticercosis Masquerading as Optic Nerve Glioma. *Orbit*;2007;26(1):
- [200] Chung GW, Lai WW, et al.: Magnetic resonance imaging in the diagnosis of subretinal cysticercosis. *Am J Ophthalmol* 2002;134(6):931-932.
- [201] Wender JD, Rathinam SR, Shaw RE, Cunningham ET Jr. Intraocular cysticercosis: case series and comprehensive review of the literature. *Ocul Immunol Inflamm*. 2011;19(4):240-245.
- [202] Grover AK, Puri P. Orbital myocysticercosis presenting as subconjunctival abscess. *Ind J Ophthalmol*. 1996;44:229-231
- [203] Baskararajan G. Srinivasan A. Sivarama Zuleramanian P. Thivagarajan S Case of cysticercosis; presenting with persistent diplopia and spontaneous extrusion. *Indian J Ophthalmol* 1981;28:219-220.
- [204] Graham RH. Extraocular Muscle Anatomy. Medscape. Jun 2011 Available at the URL: <http://emedicine.medscape.com/article/1189799-overview> (last review Jul 05, 2012)
- [205] DiLoreto DA, Kennedy RA, Neigel JM, Rootman J. Infestation of extraocular muscle by *Cysticercus cellulosae*. *Br J Ophthalmol*. 1990;71:751-752
- [206] Menon V, Kumar G, Prakash P. Cysticercosis of extraocular muscles. *J Pediatr Ophthalmol Strabismus*. 1994;31:126-129
- [207] Madan N, Chopra K, Popli V. Proptosis as a Manifestation of Cysticercosis. *Indian Pediatric*. 1995;32:914-917.
- [208] Ursekar MA, Dastur DK, Manghani DK, Ursekar AT. Isolated cysticercal infestation of extraocular muscles: CT and MR findings. *AJNR Am J Neuroradiol*. 1998;19:109-113
- [209] Trivedi N, Malthus RN. CT evaluation of proptosis. *Proceedings of the 44th Annual Conference of AH India Ophthalmological Society* 1968, pp 45.
- [210] Vashisht S, Hemlata RK, Dayal Y, Bhargav. Orbital lesion. A CT Study. *ISRI* 1986;4: 40.
- [211] Pupo PP. Cysticercosis of the nervous system—Clinical manifestations. *Revropsychiatr* 1964;27:70-82.
- [212] Canelas HM. Neurocysticercosis. Its incidence, diagnosis and clinical forms. In: *Tropical Neurology*. Eds Ven Bogasert L, Pereyrakafer J, Poch CW. Buenos Aires, Lopezco, 1963, pp 149-162.
- [213] Powell ST, Proctor SM, Wilmost AJ, et al. Cysticercosis and epilepsy in Africans. A clinical and serological study. *Ann Trop Med Parasitol* 1966, 60:150-153.
- [214] Jampol LM, Caldwell JBH, Albert DM. *Cysticercus cellulosae* in the eye. *Arch Ophthalmol* 1973;89:319-320
- [215] Perry HD, Font RL. Cysticercosis of the eyelid. *Arch Ophthalmol*;96:1255-1257

- [216] Sen DK. Cysticercus cellulosae in the eyelid, orbit and lacrimald. *Acta Ophthalmol (Kbh)* 1980;58:144–147
- [217] Sing G, Kaur J. Cysticercosis of the eyelid. *Ann Ophthalmol* 1982;47–950
- [218] Kundra R, Kundra SN. Unilateral ptosis due to cysticercosis of extraocular muscle. *Indian J Pediatr.* 2004;71(2):181-182.
- [219] Chan EW, Looi A. Cysticercosis of the Levator Palpebrae Superioris. *Annals Academy of Medicine.* 2010;39(12):938-940.
- [220] Basset D, Girou C, Nozais IP, et al. Neotropical echinococcosis in Suriname: Echinococcus oligarthrus in the orbit and Echinococcus vogeli in the abdomen. *Am J Trop Med Hyg* 1998; 59:787-90.
- [221] Kamath KR. Severe infection with Trichuris trichiura in Malaysian children. A clinical study of 30 cases treated with stilbazium iodine. *Am J Trop Med Hyg* 1973; 22:600-605.
- [222] Netravathi N, Banuprakash AS, Khamesra R, Singh NH. Cysticercosis of midbrain presenting with fluctuating ptosis. *Ann Indian Acad Neurol.* 2011;14(3):208–210.
- [223] Wiwanitkit S, Wiwanitkit V. Cysticercosis and ptosis. *Ann Indian Acad Neurol* 2012;15:68
- [224] Angotti-Neto H, Gonçalves AC, Moura FC, Monteiro ML. Extraocular muscle cysticercosis mimicking idiopathic orbital inflammation: case report. *Arq Bras Oftalmol.* 2007;70(3):537-539.
- [225] Monteiro ML. Liposarcoma of the orbit presenting as an enlarged medial rectus muscle on CT scan. *Br J Ophthalmol.* 2002;86(12):1450.
- [226] Trokel SL, Hilal SK. Recognition and differential diagnosis of enlarged extraocular muscles in computed tomography. *Am J Ophthalmol,* 1979; 87(4): 503-512.
- [227] Meher A, Ursekar, Darab K. Dastur, Daya K. Manghani, and Atul T. Ursekar. Isolated Cysticercal Infestation of Extraocular Muscles: CT and MR Findings. *Am J Neuroradiol* 1998;19:109–113.
- [228] DiLoreto DA, Kennedy RA, Neigel JM, Rootman J. Infestation of ocular muscle by Cysticercus cellulosae. *Br J Ophthalmol* 1990;74:751–752
- [229] Shadangi P, Saggari V, et al; Isolated Cysticercosis Of Inferior Rectus Muscle Presenting With Eccentric Proptosis.- A rare case report and treatment review. *Journal of Clinical and Diagnostic Research.* 2010;4(3):2536-2539.
- [230] Lee AG; Tang RA, Wong GOD, Schiffman JS, Singh S. Isolated Inferior Rectus Muscle Palsy Resulting From a Nuclear Third Nerve Lesion as the Initial Manifestation of Multiple Sclerosis. *Journal of Neuro-Ophthalmology* 2001;20(4):246-247
- [231] Ellis FH, Helveston EM. Superior oblique palsy: diagnosis and classification. *Int Ophthalmol Clin* 1976; 16: 127-135.
- [232] Brooks AM, Essex WB, West RH: Cysticercosis of superior oblique muscle. *Aust J Ophthalmol* 1983;11:119-122.
- [233] Mafee MF, Folk ER, Langer BG, Miller MT, Lagouros P, Mittleman D. Computed tomography in the evaluation of Brown syndrome of the superior oblique tendon sheath. *Radiology,* 1985;154(3): 691-695.
- [234] Ozkan SB, Aribal ME, Sener EC, Sanac AS, Gurcan F. Magnetic resonance imaging in evaluation of congenital and acquired superior oblique palsy. *J. Pediatr. Ophthalmol. Strabismus.* 1997; 34(1): 29-34.

- [235] Wright KW. Brown's syndrome: Diagnosis and management. *Trans. Am. Ophthalmol. Soc.*, 1999; 97:1023-1029.
- [236] Thorne JE, Volpe NJ, Liu GT. Magnetic resonance imaging of acquired Brown syndrome in a patient with psoriasis. *Am. J. Ophthalmol.* 1999;127(2): 233-235
- [237] Pramod K, Pandey P, Chaudhuri Z, Bhatia A. Extraocular muscle cysticercosis presenting as brown syndrome. *Am J Ophthal* 2001;131(4):526-527.
- [238] Bajaj MS, Pushker N, Sen S, et al. Cysticercosis of superior oblique muscle: surgical excision and reconstruction of superior oblique tendon. *Can J Ophthalmol* 2002; 37(7):423-426.
- [239] Rao VB, Sahare P, Varada V. Acquired brown syndrome secondary to superior oblique muscle cysticercosis. *J. Am. Assoc. Pediatr. Ophthalmol. Strab.* 2003;7(1):23 – 27.
- [240] Venkateshwar B, Rao VB, Prashant P, Sahare P, Varada VV. Acquired brown syndrome secondary to superior oblique muscle cysticercosis. *J AAPOS* 2003;7(1):23-27. Available at the URL://pubget.com/paper/12690365/Acquired_brown_syndrome_secondary_to_superior_oblique_muscle_cysticercosis (Last revision on July, 03, 2012)
- [241] Lee WB, O'Halloran HS. A report of canine tooth syndrome. *Orbit* 2004;23(1):53-57.
- [242] Pandey PK, Bhatia A, Garg D, Singh R. Canine tooth syndrome due to superior oblique myocysticercosis. *J Pediatr Ophthalmol Strabismus.* 2006;43(3):185-187.
- [243] Case report: tenosynovitis of the left superior oblique muscle. *Ophthalmology Times Europe.* 2006. Available at the URL:
<http://www.oteurope.com/ophthalmologytimeseurope/mail/emailContent.jsp?id=314314>
- [244] Alonso-Valdivielso JL, Alvarez Lario B, Alegre López J, Sedano Tous MJ, Buitrago Gómez A. Acquired Brown's syndrome in a patient with systemic lupus erythematosus. *Ann Rheum Dis.* 1993; 52(1):63–64.
- [245] Pollard ZF. Diagnosis and treatment of inferior oblique palsy. *J Pediatr Ophthalmol Strabismus.* 1993;30(1):15-18.
- [246] Donahue S, Lavin PJM, Mohney B, Hamed L. Skew deviation and inferior oblique palsy. *Amer J Ophthal* 2001;132(5):751-756
- [247] Hüseyin B, Cem M, Soner D. Inferior Oblique Paresis, Mydriasis, and Accommodative Palsy as Temporary Complications of Sinus Surgery. *Journal of Neuro-Ophthalmology* 2004;24(3):225-227.
- [248] Parks M, Mitchell P. Oblique Muscle Dysfunctions. Chapter 17. Full text available the URL:
<http://www.oculist.net/downat0502/prof/ebook/duanes/pages/v1/v1c017.html#ove>
- [249] Kim M, Lee YC. A Case of Contralateral Pseudo Inferior Oblique Overaction after Unilateral Inferior Oblique Anterior Transposition. *J Korean Ophthalmol Soc.* 2000;41(9):2018-2023.
- [250] Surgical anatomy of the inferior oblique. Paralysis. *Cyber-Sight. Orbis/Telemedicine.* Available at the URL://telemedicine.orbis.org/bins/volume_page.asp?cid=1-2161-2163-2177
- [251] Sixth Nerve Paralysis: Diagnosis. Paralysis. *Cyber-Sight. Orbis/Telemedicine.* Available at the URL://www.cybersight.org/bins/volume_page.asp?cid=1-12628-351-355-521

- [252] Stewart CR, Salmon JF, Murray AD, Sperryn C. Cysticercosis as a cause of severe medial rectus muscle myositis. *Am J Ophthalmol.*1993;116(4):510-511.
- [253] Wong YC, Goh KY, Choo CT, Seah LL, Rootman J. An unusual cause of acquired horizontal diplopia in a young adult. *Br J Ophthalmol.* 2005;89(3):390–391.
- [254] Khwaja GA, Singh AC, Chaudhry Neera, Gupta Meena, Chowdhury D. Recurrent Headache and Unilateral Ptosis. *JIACM.* 2008;9(3):218–220.
- [255] Taksande B, Jajoo U, Yelwatkar S, Ashish J. Unusual presentation of orbital cysticercosis-ptosis, diminution of vision and medial rectus weakness: a case report. *Cases J.* 2009; 2: 7025. This article is available from: <http://casesjournal.com/casesjournal/article/view/7025>
- [256] Tuli N. A Non Responding Case Of Extraocular Muscle Cysticercosis Mimicking As Pseudo-Tumor Orbit In A Child. *The Internet Journal of Ophthalmology and Visual Science.* 2010;7(2)
- [257] Medial Rectus Muscle Paralysis. *Cyber-Sight. Orbis/Telemedicine.* Available at the URL://www.cybersight.org/bins/volume_page.asp?cid=1-12628-351-355-515&lang=1 (accessed on July 08, 2012)
- [258] Castro O, Johnson LN, Mamourian AC. Isolated inferior oblique paresis from brainstem infarction. Perspective on oculomotor fascicular organization in the ventral midbrain tegmentum. *Arch Neurol* 1990;47:235-237
- [259] Kwon JH, Kwon SU, Ahn HS, Sung KB, Kim JS. Isolated superior rectus palsy due to contralateral midbrain infarction. *Arch Neurol* 2003;60:1633-1635.
- [260] Rabadi MH, Beltmann MA. Midbrain infarction presenting isolated medial rectus nuclear palsy. *Am J Med* 2005;118:836-837.
- [261] Lee DK, Kim JS. Isolated inferior rectus palsy due to midbrain infarction detected by diffusion-weighted MRI. *Neurology* 2006;66:1956-1957
- [262] Bal S, Lal V, Khurana D, Prabhakar S. Midbrain infarct presenting as isolated medial rectus palsy. *Neurol India* 2009;57:499-501
- [263] Sarwal A. Isolated medial rectus palsy in midbrain infarction. *Amer Acad Neurol.* 2009; 10: 200. Available at the URL: <http://www.aan.com/globals/axon/assets/6555.pdf> (accessed on July 08, 2012)
- [264] Puri P, Grover AK. Medical management of orbital myocysticercosis: a pilot study. *Eye* 1998;12:795–799
- [265] Pandey PK, Chaudhuri Z, Sharma P, Bhomaj S. Extraocular muscle cysticercosis: a clinical masquerade. *J Pediatr Ophthalmol Strabismus* 2000;37:273-278.
- [266] Jethani J. Outcome of treatment of extraocular muscle cysticercosis. *J Pediatr Ophthalmol Strabismus.* 2005;42(5):263-264