

# We are IntechOpen, the world's leading publisher of Open Access books Built by scientists, for scientists

4,800

Open access books available

122,000

International authors and editors

135M

Downloads

Our authors are among the

154

Countries delivered to

TOP 1%

most cited scientists

12.2%

Contributors from top 500 universities



WEB OF SCIENCE™

Selection of our books indexed in the Book Citation Index  
in Web of Science™ Core Collection (BKCI)

Interested in publishing with us?  
Contact [book.department@intechopen.com](mailto:book.department@intechopen.com)

Numbers displayed above are based on latest data collected.  
For more information visit [www.intechopen.com](http://www.intechopen.com)



---

# Two-Step Hanging Maneuver for an Isolated Resection of the Dorsal Sector of the Liver

---

Hideaki Uchiyama, Shinji Itoh and Kenji Takenaka

Additional information is available at the end of the chapter

<http://dx.doi.org/10.5772/51768>

---

## 1. Introduction

Resection of malignant lesions arising in the dorsal sector of the liver is a challenging procedure because the sector is located deep in the abdominal cavity and surrounded by the inferior vena cava (IVC) and the major hepatic veins [1 – 9]. A hanging maneuver is an innovative procedure in hepatic surgeries, in which the liver parenchyma is hung by a tape, thereby making a straight cutting line [10 – 14]. This technique was applied in two patients who had a hepatocellular carcinoma (HCC) in the dorsal sector. Patient 1 was a 46-year-old female, who was found to have an HCC, approximately 3 cm in diameter, located just above the IVC. The patient had a large inferior right hepatic vein (IRHV). The superior right hepatic vein (SRHV) and the IRHV were individually controlled with a tape after dividing several short hepatic veins from the right side of the IVC. A cotton tape was introduced from the groove between the SRHV and the middle hepatic vein (MHV) to the right and left Glisson sheaths via the space just next to the left side of the IRHV. The liver was split into the right and left hemilivers by pulling the tape upwards. Next, the tape was introduced from the space behind the confluence of the MHV and the left hepatic vein (LHV) to the space behind the left Glisson sheath via the fissure of the ligamentum venosum after dividing a few small Glisson branches into the caudate lobe from the left Glisson sheath. The liver parenchyma was divided between the medial sector and the dorsal sector by pulling the tape medially. Finally, the dorsal sector including the tumor was resected by dividing the short hepatic veins from the left side of the IVC. Patient 2 was a 59-year-old male, who was found to have an HCC, approximately 3 cm in diameter, located in the Spiegel lobe (a part of the dorsal sector) during a follow-up for chronic hepatitis B. The tumor compressed the left side of the IVC and protruded inferomedially. Cotton tape was introduced from the groove between the MHV and the LHV to the groove between the right and left Glisson sheaths via the posterior surface of the liver after dividing all the short hepatic

veins from the right side of the IVC. The liver was split into the right and left hemilivers by pulling the tape upwards. The liver parenchyma was divided between the medial sector and the dorsal sector as in Patient 1. The operation time was 623 and 435 minutes and the intraoperative blood loss was 834 and 1320 grams, respectively. No complications occurred in the two patients. The application of hanging maneuvers enables surgeons to safely resect tumors located deep in the dorsal sector of the liver.

This surgical technique requires a lot of indispensable procedures for hepatic surgeries. This chapter presents the step-by-step surgical procedures regarding hanging maneuvers for an isolated resection of the dorsal sector.

## 2. Patients

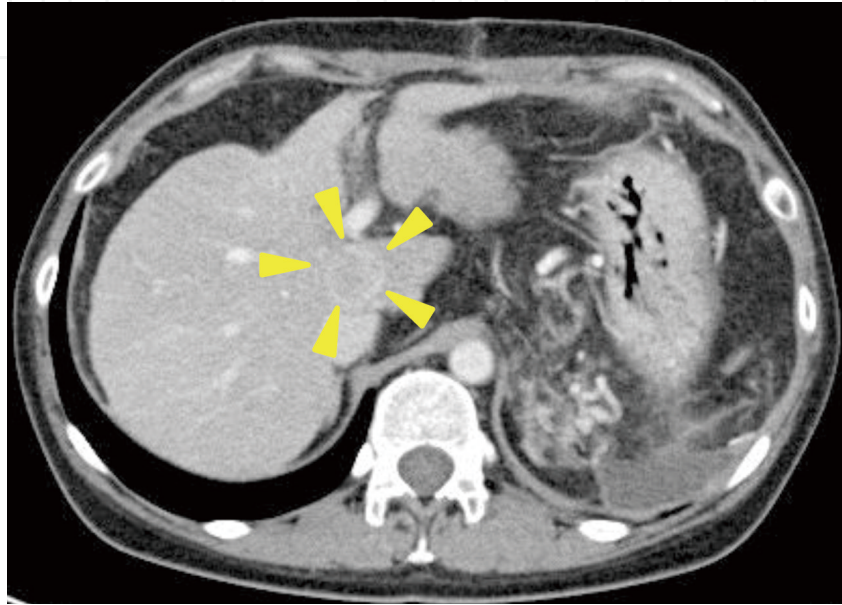
The patients' characteristics and preoperative laboratory data are summarized in Table 1. Patient 1 had a cirrhotic liver caused by hepatitis B and had undergone laparoscopic splenectomy approximately two months before hepatectomy to control intractable ascites caused by splenomegaly accompanied with cirrhosis. Patient 2 had a fibrotic liver caused by chronic hepatitis B. Both patients had a solitary HCC in the dorsal sector.

	Patient 1	Patient 2
age	46	59
gender	female	male
native liver disease	cirrhosis caused by hepatitis B	chronic hepatitis B
white blood cell (/ $\mu$ l)	4900	5400
hemoglobin (g/dl)	7.9	14.7
platelet ( $\times 10^3$ / $\mu$ l)	235	171
total bilirubin (mg/dl)	0.49	0.42
albumin (g/dl)	3.2	4.6
prothrombin time – international normalized ratio	1.05	0.95
indocyanine green dye retention at 15 minutes (%)	27	13
tumor diameter (cm)	3	3

**Table 1.** Patient characteristics and preoperative laboratory data

### 3. Surgical procedures in patient 1

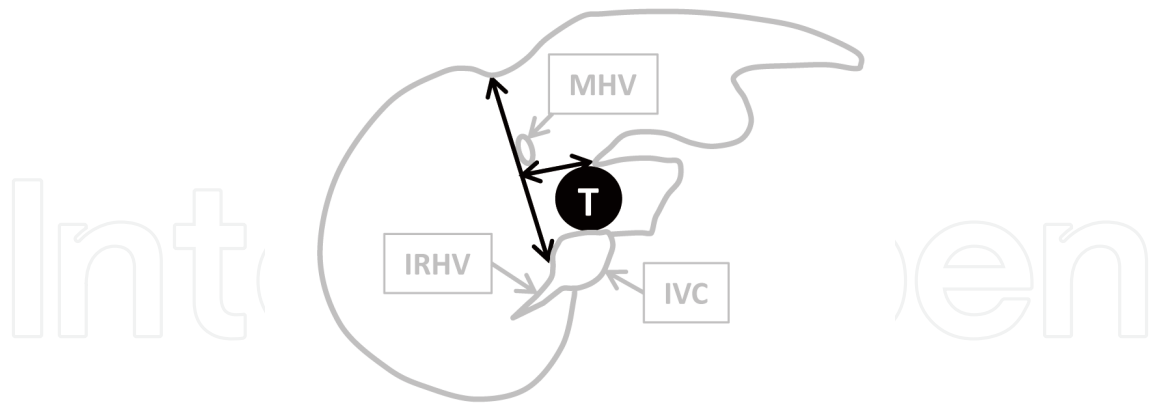
The HCC, approximately 3 cm in diameter, was located just above the IVC (Figure 1). A limited hepatectomy was selected because the patient had a relatively advanced cirrhotic liver and the preoperative evaluations predicted that an extended hepatectomy would have led to postoperative liver failure.



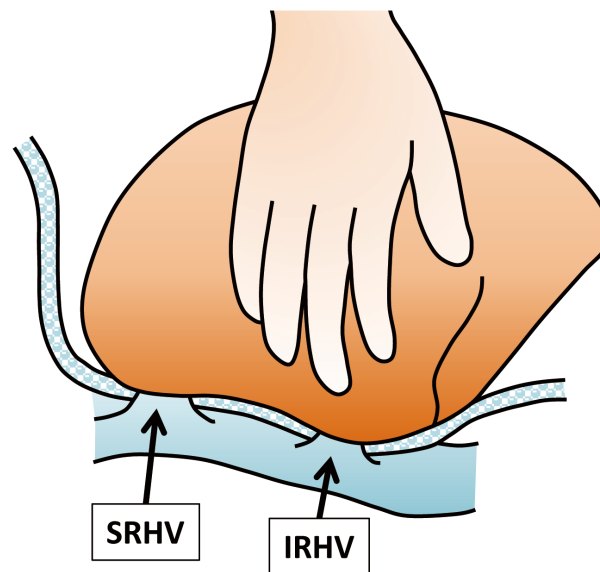
**Figure 1.** Hepatocellular carcinoma in Patient 1 located just above the inferior vena cava

Figure 2 shows a schematic diagram of the surgical procedure. Patient 1 had a relatively large IRHV. This vein was kept intact because its division could have caused congestion of the posterior sector. The liver was split into the right and left hemilivers by dividing the liver parenchyma along the right side of the middle hepatic vein using a hanging maneuver with a cotton tape introduced into the space between the posterior surface of the liver and the anterior surface of the IVC. The liver parenchyma was divided between the medial sector and the dorsal sector using a hanging maneuver with a cotton tape placed in the fissure of the ligamentum venosum.

The patient was placed in the supine position. The abdomen was opened by bilateral subcostal incisions with an upper midline extension. There was a small amount of ascites and the liver had a cirrhotic appearance. Cholecystectomy was performed and a tube was inserted into the cystic duct for cholangiography. The right lobe was mobilized clockwise by dividing the right triangular ligament. The IVC ligament was divided, and the SRHV and the IRHV were individually encircled with a tape. A thin cotton tape was introduced from the groove between the SRHV and the confluence of the MHV and the LHV to the left-side space of the IRHV (Figure 3).



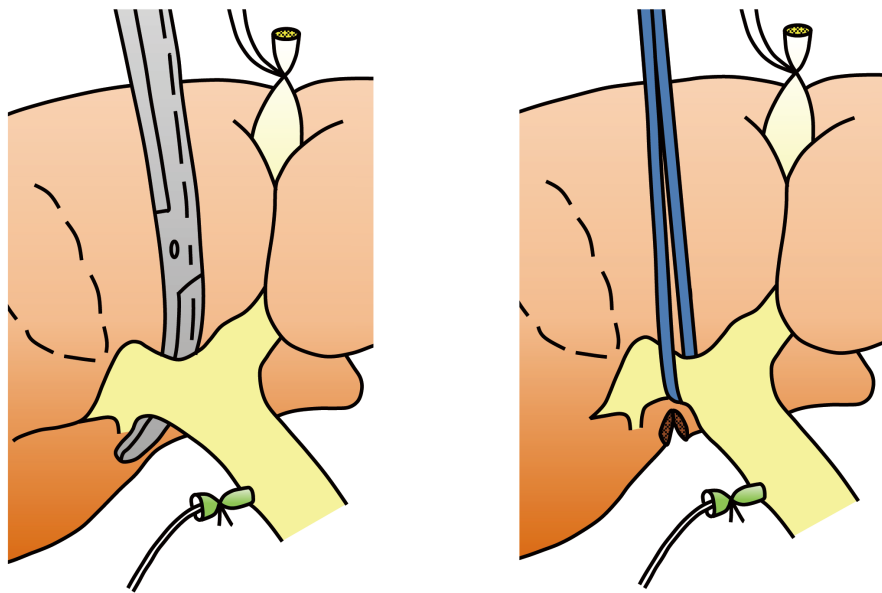
**Figure 2.** Schematic diagram of the hanging maneuvers for the isolated resection of the dorsal sector used in Patient 1 IRHV, the inferior right hepatic vein; IVC, the inferior vena cava; MHV, the middle hepatic vein; T, tumor



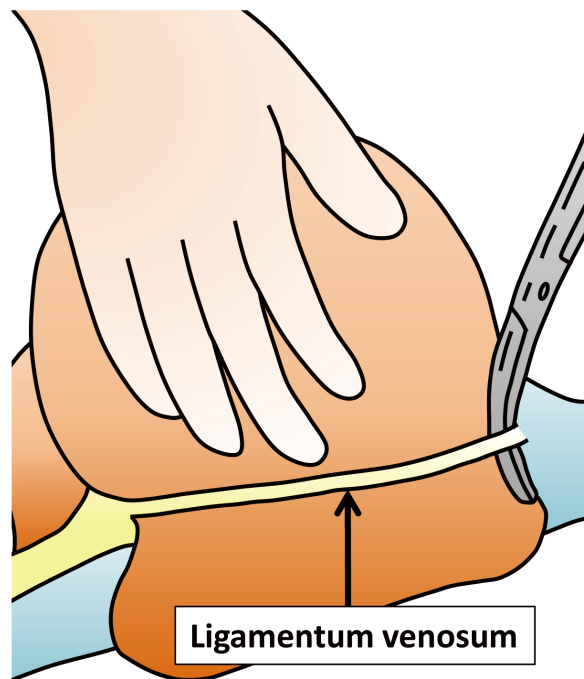
**Figure 3.** Introducing a cotton tape along the left-side spaces of the superior and the inferior hepatic veins SRHV, the superior right hepatic vein; IRHV, the inferior right hepatic vein

The procedure moved on to the hepatic hilum. The right Glisson sheath was encircled with a tape. A small notch was made on the lowest part of the dividing plane as a hook for the hanging tape (Figure 4).

The left lateral lobe was mobilized counterclockwise by dividing the left triangular ligament. The ligamentum venosum was divided near the LHV (Figure 5). Thereafter, the confluence of the MHV and the LHV was encircled with a tape.

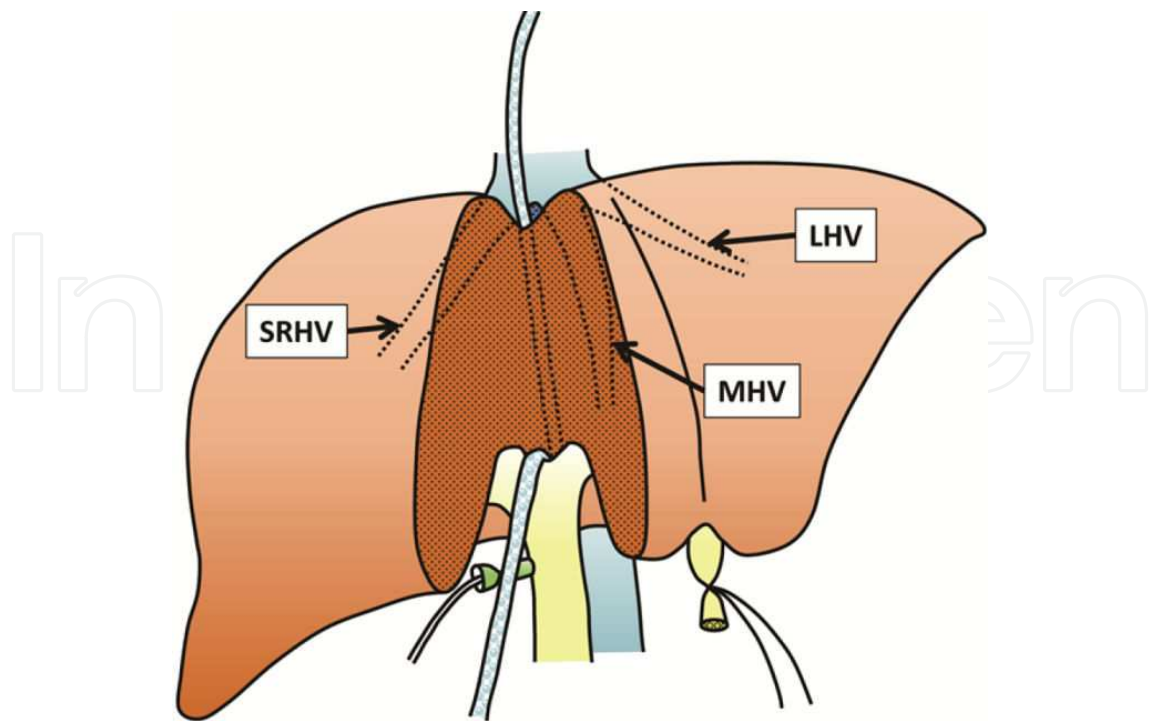


**Figure 4.** Taping of the right Glisson sheath

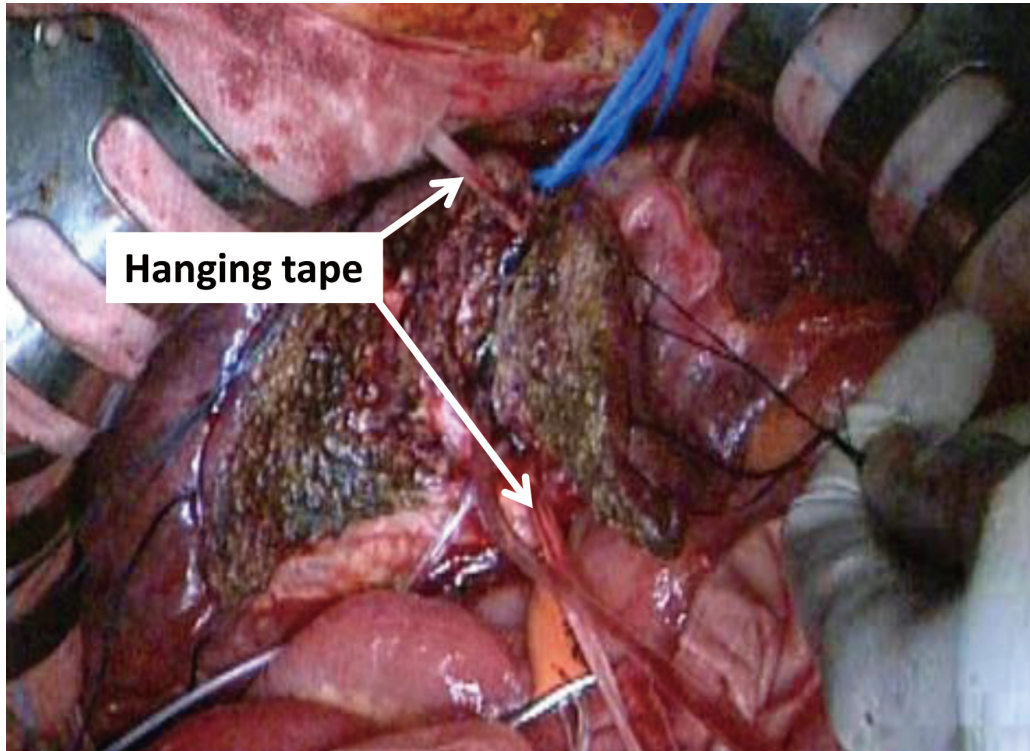


**Figure 5.** Division of the ligamentum venosum

The tail of the cotton tape was introduced into the groove between the right and the left Glisson sheath. The liver was split into the right and the left hemilivers by pulling up the cotton tape upwards (Figure 6, 7).

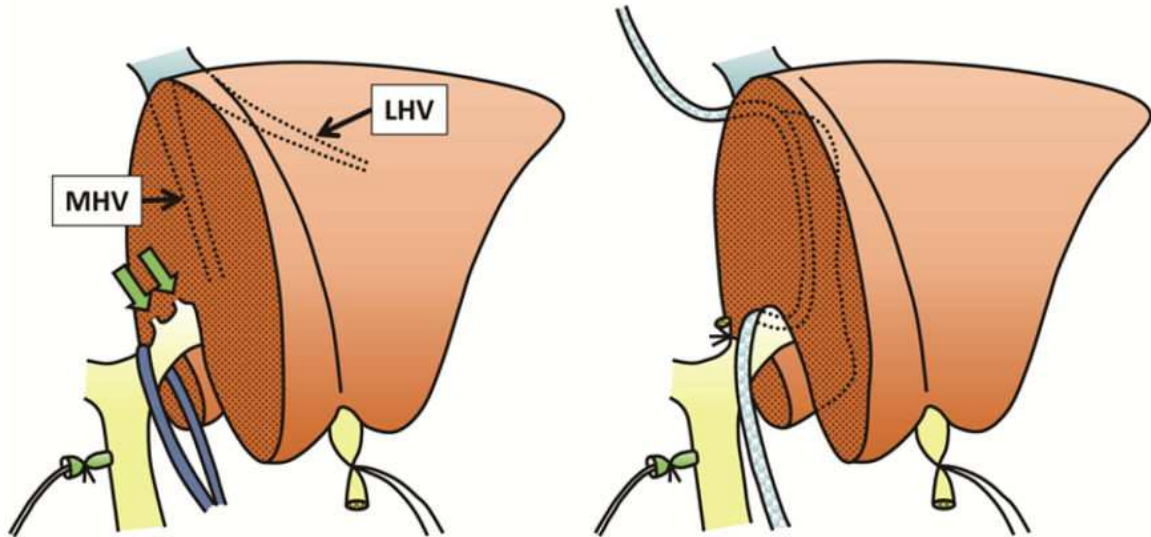


**Figure 6.** Splitting of the liver into the right and left hemilivers using a hanging maneuver (schematic diagram) LHV, the left hepatic vein; MHV, the middle hepatic vein; SRHV, the superior right hepatic vein

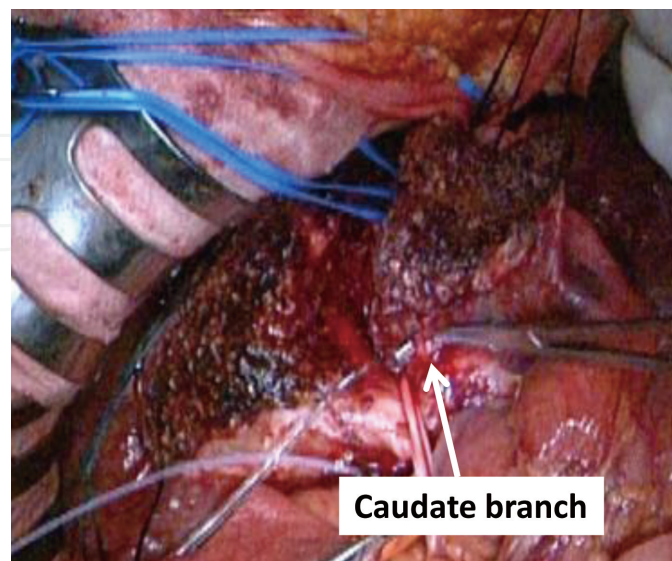


**Figure 7.** Splitting of the liver into the right and left hemilivers using a hanging maneuver (photograph)

Splitting the liver into the two hemilivers revealed a few caudate branches from the left Glisson sheath (Figure 8). These branches were divided to make a space behind the left Glisson sheath (Figure 9). A cotton tape was introduced from the space behind the confluence of the MHV and the LHV to the space behind the left Glisson sheath via the fissure of the ligamentum venosum. The liver parenchyma was transected between the medial sector and the dorsal sector by medially lifting the cotton tape (Figure 10).

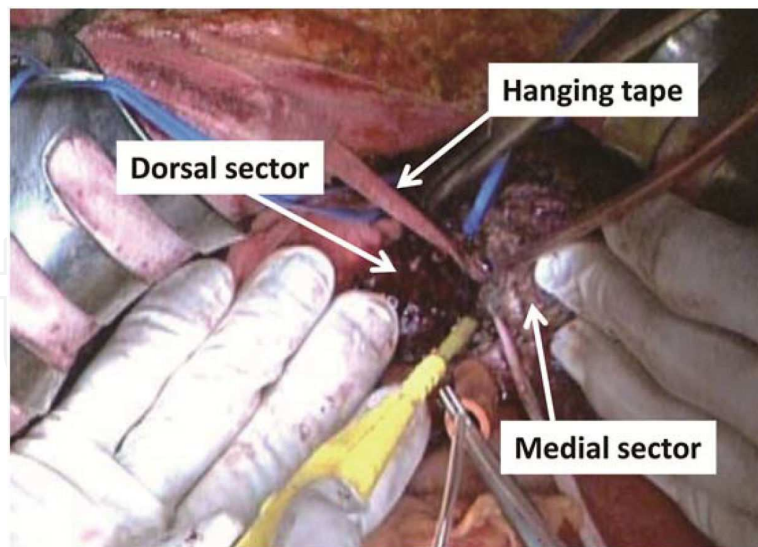


**Figure 8.** Division of the caudate branch from the left Glisson sheath (left) and a hanging maneuver for transecting the liver parenchyma between the medial sector and the dorsal sector (right) Green arrows indicate the caudate branch from the left Glisson sheath. LHV, the left hepatic vein; MHV, the middle hepatic vein



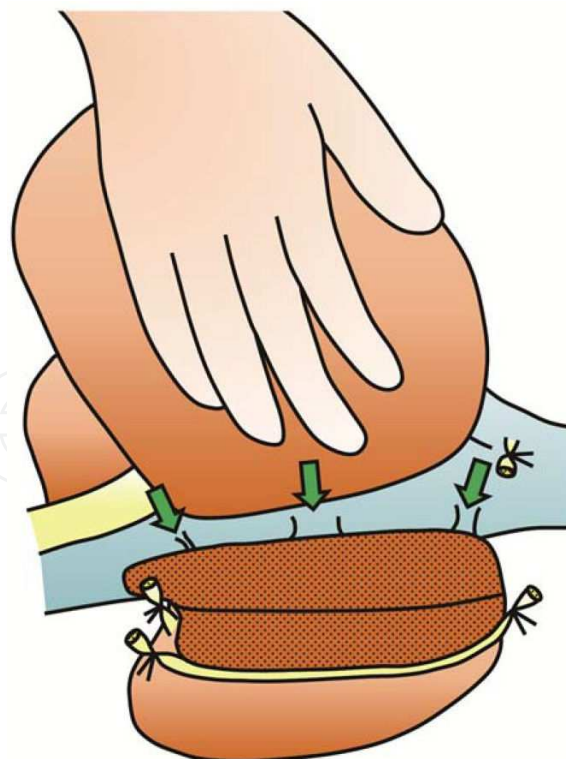**Figure 9.** Division of the caudate branch from the left Glisson sheath



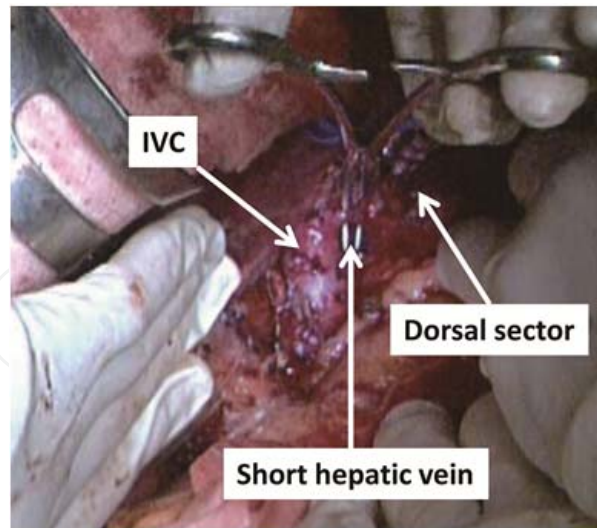


**Figure 10.** A hanging maneuver for transecting the liver parenchyma between the medial sector and the dorsal sector

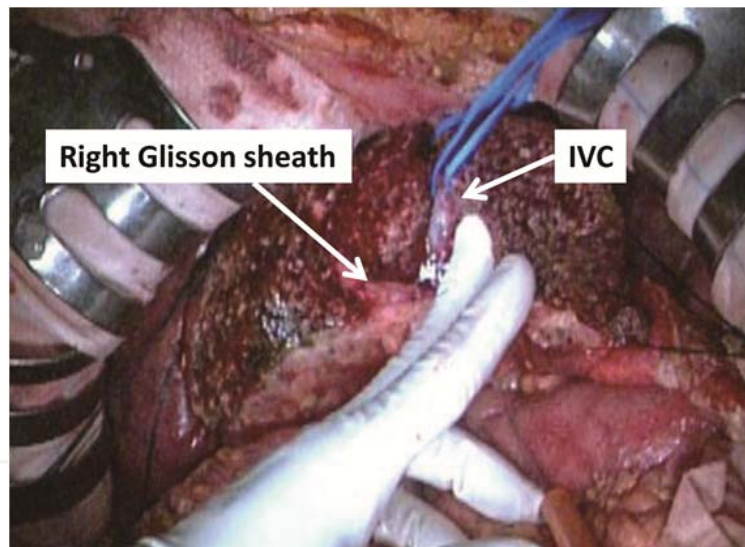
All the short hepatic veins from the dorsal sector were divided from the left side of the IVC (Figure 11, 12). The IVC ligament was divided, and the dorsal sector including the tumor was retrieved from the surgical field (Figure 13).



**Figure 11.** Division of the short hepatic veins from the left side of the inferior vena cava (schematic diagram) Green arrows indicate the short hepatic veins to be divided.



**Figure 12.** Division of the short hepatic veins from the left side of the inferior vena cava (photograph) IVC, the inferior vena cava



**Figure 13.** Completion of the isolated resection of the dorsal sector IVC, the inferior vena cava

#### 4. Surgical procedures in patient 2

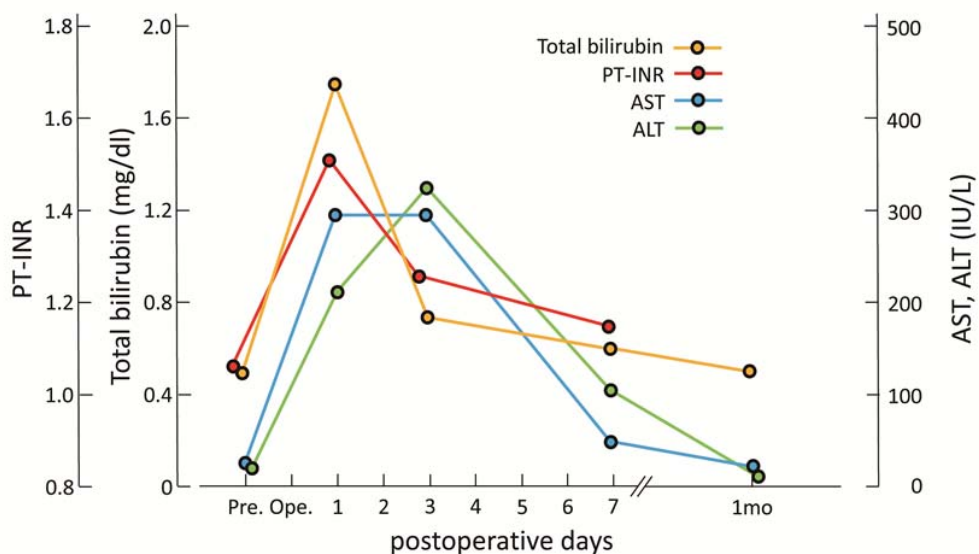
The surgical procedures in Patient 2 were reported previously [15]. The procedures differed in two points from the procedures used in Patient 1: All the short hepatic veins were divided from the right side of the IVC and the liver was split into hemilivers along the left side of the MHV by introducing cotton tape through the groove between the MHV and the LHV.

## 5. Surgical results

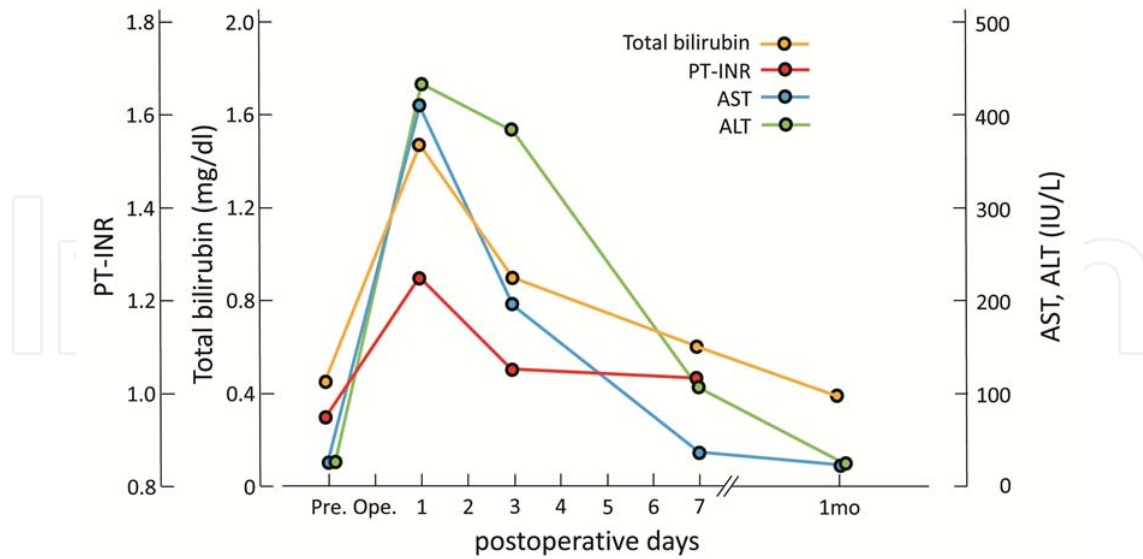
The surgical results are summarized in Table 2. Patient 1 required transfusion of two units of red blood cell because of pre-existing anemia. The resected specimens had an acceptable tumor-free surgical margin. Kinetics of the laboratory data are shown in Figure 14 and 15. Both patients exhibited rapid recovery of laboratory data. Follow-up CT after the surgeries demonstrated that there were no perfusion abnormalities in the livers (Figure 16).

	Patient 1	Patient 2
operation time (minutes)	623	435
intraoperative blood loss (grams)	834	1320
blood transfusion	two units of concentrated red blood cell	none
length of postoperative hospital stay (days)	13	15
complications	none	none

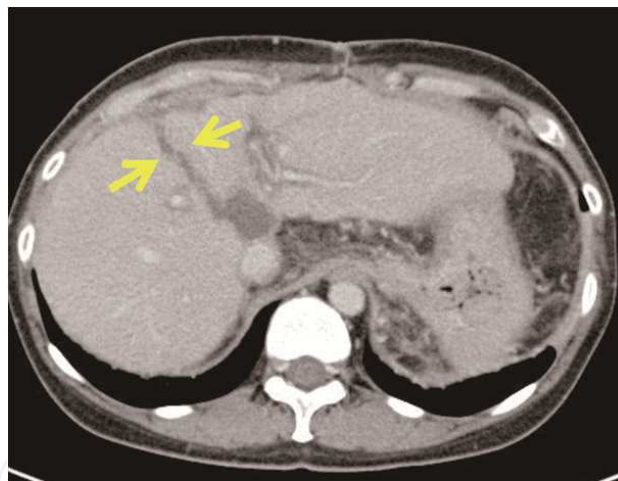
**Table 2.** Surgical results



**Figure 14.** Kinetics of laboratory data in Patient 1 ALT, alanine aminotransferase; AST, aspartate aminotransferase; PT-INR, prothrombin time – international normalized ratio



**Figure 15. Kinetics of laboratory data in Patient 2** ALT, alanine aminotransferase; AST, aspartate aminotransferase; PT-INR, prothrombin time – international normalized ratio



**Figure 16. Follow-up CT of Patient 1 two months after the surgery** Yellow arrows indicate the dividing plane between the right and left hemilivers.

## 6. Conclusion

Livers with malignant lesions to be resected are often cirrhotic. Parenchymal transection of cirrhotic liver from the dorsal direction may cause uncontrollable bleeding. The application of hanging maneuvers to an isolated resection of the dorsal sector enables surgeons to safely transect the liver parenchyma only via an anterior approach.

## Author details

Hideaki Uchiyama\*, Shinji Itoh and Kenji Takenaka

\*Address all correspondence to: huchi@surg2.med.kyushu-u.ac.jp

Department of Surgery, Fukuoka City Hospital, Japan

## References

- [1] Abdalla EK, Vauthey JN, Couinaud, C. The caudate lobe of the liver: implications of embryology and anatomy for surgery. *Surg Oncol Clin N Am* 2002; 11(4): 835-848.
- [2] Asahara T, Dohi K, Hino H, Nakahara H, Katayama K, Itamoto T, Ono E, Moriwaki K, Yuge O, Nakanishi T, Kitamoto M. Isolated caudate lobectomy by anterior approach for hepatocellular carcinoma originating in the paracaval portion of the caudate lobe. *J Hepatobiliary Pancreat Surg* 1998; 5(4): 416-421.
- [3] Chaib E, Ribeiro MA Jr, Souza YE, D'Albuquerque LA. Anterior hepatic transection for caudate lobectomy. *Clinics* 2009; 64(11): 1121-1125.
- [4] Kosuge T, Yamamoto J, Takayama T, Shimada K, Yamasaki S, Makuuchi M, Hasegawa H. An isolated, complete resection of the caudate lobe, including the paracaval portion, for hepatocellular carcinoma. *Arch Surg* 1994; 129(3): 280-284.
- [5] Takayama T, Tanaka T, Higaki T, Katou K, Teshima Y, Makuuchi M. High dorsal resection of the liver. *J Am Coll Surg* 1994; 179(1): 72-75.
- [6] Yanaga K, Matsumata T, Hayashi H, Shimada M, Urata K, Sugimachi K. Isolated hepatic caudate lobectomy. *Surgery* 1994; 115(6): 757-761.
- [7] Utsunomiya T, Okamoto M, Tsujita E, Ohta M, Tagawa T, Matsuyama A, Okazaki J, Yamamoto M, Tsutsui S, Ishida T. High dorsal resection for recurrent hepatocellular carcinoma originating in the caudate lobe. *Surg Today* 2009;39(9): 829-832.
- [8] Yamamoto J, Kosuge T, Shimada K, Yamasaki S, Takayama T, Makuuchi M. Anterior transhepatic approach for isolated resection of the caudate lobe of the liver. *World J Surg* 1999;23(1): 97-101.
- [9] Yamamoto T, Kubo S, Shuto T, Ichikawa T, Ogawa M, Hai S, Sakabe K, Tanaka S, Uenishi T, Ikebe T, Tanaka H, Kaneda K, Hirohashi K. Surgical strategy for hepatocellular carcinoma originating in the caudate lobe. *Surgery* 2004;135(6): 595-603.
- [10] Belghiti J, Guevara OA, Noun R, Saldinger PF, Kianmanesh R. Liver hanging maneuver: a safe approach to right hepatectomy without liver mobilization. *J Am Coll Surg* 2001; 193(1): 109-111.

- [11] Kim SH, Park SJ, Lee SA, Lee WJ, Park JW, Hong EK, Kim CM. Various liver resections using hanging maneuver by three Glisson's pedicles and three hepatic veins. *Ann Surg* 2007; 245(2): 201-205.
- [12] Kim SH, Park SJ, Lee SA, Lee WJ, Park JW, Kim CM. Isolated caudate lobectomy using the hanging maneuver. *Surgery* 2006; 139(6): 847-850.
- [13] López-Andújar R, Montalvá E, Bruna M, Jiménez-Fuertes M, Moya A, Pareja E, Mir J. Step-by-step isolated resection of segment 1 of the liver using the hanging maneuver. *Am J Surg* 2009; 198(3): e42-48.
- [14] Ogata S, Belghiti J, Varma D, Sommacale D, Maeda A, Dondero F, Sauvanet A. Two hundred liver hanging maneuvers for major hepatectomy: a single-center experience. *Ann Surg* 2007; 245(1): 31-35.
- [15] Uchiyama H, Itoh S, Higashi T, Korenaga D, Takenaka K. A two-step hanging maneuver for a complete resection of Couinaud's segment I. *Dig Surg* 2012; 29(3): 202-205.

