

We are IntechOpen, the world's leading publisher of Open Access books Built by scientists, for scientists

4,800

Open access books available

122,000

International authors and editors

135M

Downloads

Our authors are among the

154

Countries delivered to

TOP 1%

most cited scientists

12.2%

Contributors from top 500 universities



WEB OF SCIENCE™

Selection of our books indexed in the Book Citation Index
in Web of Science™ Core Collection (BKCI)

Interested in publishing with us?
Contact book.department@intechopen.com

Numbers displayed above are based on latest data collected.

For more information visit www.intechopen.com



Anesthetic Considerations for Patients with Liver Disease

Aparna Dalal and John D. Jr. Lang

Additional information is available at the end of the chapter

<http://dx.doi.org/10.5772/54222>

1. Introduction

The liver is the largest gland in the body. The average human liver weighs approximately 1.5-1.7 kg, and holds a blood volume of approximately 500 ml. It receives approximately 25% of the cardiac output, of which 75% is supplied by the portal vein and the other 25% by the hepatic artery. Its venous drainage is to the inferior vena cava via the hepatic veins. The hepatic ductal system produces the bile which is then stored in the gall bladder.

The liver synthesizes most proteins, with the exception of gamma globulins and factor VIII. It is also responsible for protein degradation, glucose homeostasis, fatty acid β -oxidation, bilirubin production and excretion. Hepatocytes are embryologically less differentiated; hence the liver is the only organ capable of regeneration after surgical resection or trauma.

Hepatic blood flow is predominantly dependent upon systemic blood flow and pressure-based on pressure flow regulation and hepatic arterial buffer response. There is also central nervous system control of the hepatic blood flow via the thoracic sympathetic fibers. Sympathetic stimulation may cause the blood volume which is present in the liver to be expelled into the circulation, thus providing additional circulatory volume if needed.

Hepatic blood flow is reduced by all anesthetic agents and techniques via reductions in hepatic blood flow and hepatic oxygen uptake. The volatile agents, desflurane and sevoflurane have the least significant effect on total hepatic blood flow. Other perioperative causes of a reduction of hepatic blood flow include mechanical ventilation, hypercarbia, positive end-expiratory pressure, hypotension, hemorrhage, hypoxemia and surgery. A significant decrease in hepatic blood flow can result in parenchymal centrilobular necrosis when extreme resulting in further worsening of perioperative liver dysfunction.

In liver disease, anesthetic drug distribution, metabolism and elimination may be altered. Uptake and onset of anesthetic drug action is usually unaffected. Hepatic clearance of an agent is dependent upon volume of distribution, functional hepatic blood flow, hepatic extraction ratio and hepatic microsomal activity. As a result, opioids may accumulate and the pharmacological actions of drugs such as benzodiazepines may be prolonged. In extreme situations, actions of non-depolarizing muscle relaxants such as vecuronium and rocuronium may also be prolonged.

The liver plays a critical role in coagulation as it is the principal site of synthesis for the majority of clotting factors: II, V, VII, IX, X, XI, and XII. All coagulation factors except for VIII, which is mainly produced by the endothelium, are markedly reduced in patients with liver disease. Patients with chronic liver disease may also develop thrombocytopenia secondary to splenomegaly caused by prolonged portal hypertension. Additionally, reduced levels of thrombopoietin, which regulates platelet production in the liver, may also further contribute to platelet counts in more advanced disease. Also, antithrombin-III (AT-III) levels fall due to reduced synthesis and/or increased consumption due to fibrinolysis. All of the proteins involved in fibrinolysis except for tissue plasminogen activator (tPA) and plasminogen activator inhibitor (PAI-1) are synthesized in the liver. However, tPA levels can be increased due to decreased clearance by the liver predisposing patients to further risks of intra- and perioperative hemorrhage. Hemostatic changes associated with surgical bleeding are thrombocytopenia, platelet function defects, inhibition of platelet aggregation and adhesion by nitric oxide and prostacyclin, decreased levels of coagulation factors: II, V, VII, IX, X, XI, quantitative and qualitative abnormalities of fibrinogen, low levels of α 2-antiplasmin, Factor XIII and thrombin activatable fibrinolysis inhibitor, and elevated tPA. Hemostatic changes associated with thrombosis are elevated vWF, decreased levels of ADAMTS-13 (a vWF cleaving protease), and decreased levels of anti-coagulants: ATIII, Protein C and S, α 2 macroglobulin, elevated levels of heparin cofactor II, elevated VIII, decreased levels of plasminogen, normal or increased PAI-1. Hypercoagulability can occur in patients with liver disease, especially those with cholestatic disease.

In the setting of acute liver failure (ALF), the coagulopathy encountered can be much more severe. Plasma concentrations of coagulation factors with the shortest half-life fall first; factors V and VII (12 hrs and 4-6hrs respectively) and factors II, VII and X subsequently. In a review of over 1000 patients with ALF by the US Acute Liver Failure Study Group, the mean international normalization ratio (INR) in ALF was 3.8 +/- 4.0 (range 1.5 - >10) with most having a moderately prolonged INR (1.5 to 5) and only 19% with an INR >5. Moreover, thrombocytopenia is common with 40% of patients having platelet counts < 90,000 on admission. [1]

2. Pathophysiology of End Stage Liver Disease

Liver disease can be acute or chronic. Common causes of chronic liver disease are viral hepatitis (B & C), autoimmune hepatitis, non-alcoholic steatohepatitis (NASH), Laennec's cir-

rhosis, cryptogenic cirrhosis, and metabolic diseases such as hemochromatosis and Wilson's disease. Cholestatic causes of liver disease include primary biliary cirrhosis and primary sclerosing cholangitis.

Predominant pathophysiological manifestation of liver disease is portal hypertension. There is increased resistance to portal blood flow due to hepatic parenchymal scarring and fibrosis, and splanchnic hyperemia resulting in hypersplenism, thrombocytopenia and the progression formation of varices. Normal portal pressures are usually in the range of 5-12 mmHg. Portal hypertension is generally defined when any 2 of the following 3 criteria are met: splenomegaly, ascites or bleeding esophageal varices. Portal pressures at this time are usually > 20 mmHg.

The combination of decreased production of albumin and portal hypertension results in the accumulation of ascites. It also occurs due to renal retention of sodium and water, and localization of this excess fluid in the peritoneal cavity. Tense ascites may decrease functional residual capacity (FRC), adversely affect pulmonary gas exchange and increase risk of aspiration. Hydrothorax or pleural effusions may produce atelectasis. Secondary hyperaldosteronism may manifest as hypokalemic metabolic alkalosis. Additionally, there is intra- and extra-pulmonary shunting, elevated mixed venous oxygen saturation (SvO₂), altered lactate metabolism. The hyperdynamic circulation is a result of decreased systemic vascular resistance (SVR) and compensatory increased cardiac output to maintain tissue perfusion. Inadequate synthesis of coagulation factors produces coagulopathy. There is delayed gastric emptying creating putting the patient at-risk for aspiration. Increased ammonia levels (hyperammonemia) can result in hepatic encephalopathy.

3. Other clinically relevant associations with patients with liver disease includes

Portopulmonary hypertension (POPH) is a pulmonary hypertension syndrome with vascular obstruction and increased resistance to pulmonary arterial flow due to varying degrees of pulmonary endothelial/smooth muscle proliferation, vasoconstriction and in-situ thrombosis. The development of POPH has not been demonstrated to correlate with the severity of liver disease.

Hepatopulmonary syndrome (HPS) is characterized by arterial hypoxemia caused by intrapulmonary vascular dilatations. The clinical triad of 1) portal hypertension; 2) hypoxemia; and 3) pulmonary vascular dilatations characterizes the clinical presentation of HPS [2].

Hepatorenal syndrome is a form of pre-renal acute kidney injury that occurs in decompensated cirrhosis. The syndrome is classified into two types: Type 1 is characterized by a doubling of the serum creatinine level to greater than 2.5 mg/dl in less than 2 weeks while Type 2 is characterized by a stable or slower progressive course of renal failure [3].

Hepatic encephalopathy occurs due to accumulation of circulating neurotoxins such as unmetabolized ammonia, gamma aminobutyric acid, gut-derived false neurotransmitters lead-

ing to altered neurotransmission by glutamate or altered cerebral energy homeostasis. [4] Clinically, it is manifested by neuropsychiatric abnormalities and generalized clonus on clinical examination.

4. Assessing perioperative risk

Patient operative risk is dictated by severity of liver disease, co-existing medical diseases and type of surgery (i.e., upper abdominal, emergent, cardiac etc.) It may also be dependent on the anesthetic conducted and ability to maintain hepatic blood flow.

An important measure for assessing mortality risk is the Child-Pugh Classification. Though this was first used to stratify risk for surgical correction of portal hypertension, it is also found to be predictive of survival in cirrhosis. The score is assigned based upon bilirubin, albumin, prothrombin time (PT), ascites and encephalopathy. One point is given for each of the following: albumin > 3.5 g/dl, INR < 1.7, bilirubin < 2 mg/dl, no ascites, no encephalopathy. 2 points are given for each of the following: Albumin 1.8- 3.5 g/dl, INR between 1.7-2.3, bilirubin 2-3 mg/dl, slight to moderate ascites, grade 1-2 encephalopathy. 3 points are given for each of the following: albumin < 1.8 g/dl, INR > 2.3, bilirubin > 3 mg/dl, tense ascites, grade 3-4 encephalopathy. Class A = 5-6 points, Class B = 7-9 points, Class C = 10-15 points. [5] Child Pugh A, B, C predicts a perioperative mortality risk of 10, 30 and 80% respectively. [6]

Other measures for predicting mortality include ascites, increased serum creatinine, preoperative GI bleed, high ASA physical status score and previous abdominal surgery. Steatosis and steatohepatitis may also be considered as risk factors for postoperative complications, especially after abdominal procedures. The Model of End Liver Disease (MELD) score predicts severity based upon serum creatinine, total bilirubin, and PT INR. It is used to estimate long term survival, as well as list patients for liver transplantation with the United network of Organ Sharing (UNOS). (need a reference here)

Elective surgery is contraindicated when the patient has acute viral hepatitis, alcoholic hepatitis, fulminant hepatic failure, severe chronic hepatitis, is a Child Pugh C patient or has other manifestations of end stage liver disease.

Patients with advanced liver disease should be effectively managed so that hepatic perfusion and hepatic oxygen delivery are maximized and sequelae of their liver disease such as hepatic encephalopathy, cerebral edema, coagulopathy, hepatopulmonary syndrome, portopulmonary hypertension and portal hypertension has been identified and treated accordingly if possible.

5. Preoperative evaluation of patients with liver disease

Assessment of hepatic function includes evaluating risks for aggravating underlying liver disease, extra-hepatic complications, alterations of hepatic synthetic function and altered drug disposition.

Liver function tests do not measure hepatic function. They represent release of damaged or dead hepatocyte intracellular contents into the systemic circulation, hence provide a snapshot at that point in time only. Actual liver function is represented by albumin, prothrombin time and pseudocholinesterase concentrations. Obtaining liver function tests in healthy patients is not recommended as abnormal liver function tests (LFTs) exist in about 1 in 700 patients, and a vast majority of these patients do not have advanced liver disease. Thus, patients with asymptomatic elevations in serum transaminase levels (less than two times normal values) may undergo anesthesia and surgery with good outcomes.

Patients with chronic hepatitis should be screened prior to elective surgery even if they are asymptomatic. The INR is the most sensitive indicator of hepatocellular dysfunction. At present, though it is accepted that abnormal hemostasis is a result of liver disease, it is debatable whether the abnormal tests really predict bleeding risk [7]. Moreover, the relationship of coagulation profiles to the risk of bleeding with chronic as well as acute liver disease is uncertain [8]. Low platelet count may not be solely responsible for an increased risk of bleeding as the platelet function is also important. Bleeding time is no longer recommended as a test of platelet function. The current consensus is for a pre-procedure platelet count > 50,000, since it appears that a platelet count above 50,000 is likely to be adequate based on previous studies [9].

It is also important to assess the patient for extra-hepatic pathophysiology related to liver disease. The diagnostic criteria for POPH include a mean pulmonary artery pressure (mPAP) greater than 25 mmHg at rest and a pulmonary vascular resistance (PVR) of > 240 dynes.s.cm⁻⁵ [10]. A better measure is a transpulmonary gradient > 12 mmHg (mPAP-PAOP) as this reflects the obstruction to flow (PVR) and also distinguishes the contribution of intravascular volume and flow to the mPAP [11].

The European Respiratory Society (ERS)/European Association for Study of the Liver (EASL) Task Force have certain set diagnostic criteria for hepatopulmonary syndrome (HPS). These include diagnosis of liver disease, an A-a oxygen gradient > 15 mmHg, pulmonary vascular dilatation documented by "positive" delayed, contrast-enhanced echocardiography with left heart, detection of microbubbles for > 4 cardiac cycles after right heart opacification of microbubbles and brain uptake > 6% following 99mTc macroaggregated albumin (MAA) lung perfusion scanning. HPS can be diagnosed when there is a cirrhosis with ascites, serum creatinine of >1.5 mg/dL, no improvement of serum creatinine after at least 2 days with diuretic withdrawal and volume expansion with albumin, absence of shock, no current or recent treatment with nephrotoxic drugs and absence of parenchymal kidney disease as indicated by proteinuria > 500 mg/day, microhematuria, and/or abnormal renal ultrasonography. [12]

6. Cardiac assessment of End Stage Liver Disease (ESLD) patients

Cirrhotic patients with ESLD may suffer from cirrhotic cardiomyopathy. This is comprised of increased cardiac output and compromised ventricular response to stress. This entity is

likely mediated by decreased beta-agonist transduction, increased circulating inflammatory mediators resulting in cardiac depression, and accompanying repolarization abnormalities [13-18]. Low systemic vascular resistance and bradycardia are also commonly seen in ESLD. Patients with ESLD may also demonstrate diastolic dysfunction. [19]. The electrophysiologic abnormalities found in cirrhotic cardiomyopathy include QT-interval prolongation, electrical and mechanical dyssynchrony and chronotropic incompetence [20-22]. Carvedilol administered to patients with ESLD has been demonstrated to reduce portal pressures by decreasing net splanchnic blood flow. [23].

Additionally, ESLD are also at risk for the development of coronary artery disease (CAD), however the liver itself has not been implicated. Approximately 25 % of these patients have at least one moderate or severe coronary artery with critical stenosis. Obstructive CAD was most common among patients with 2 traditional cardiac risk factors such as smoking, diabetes mellitus (DM),and/or hyperlipidemia [24]. Left ventricular hypertrophy and hyperdynamic systolic function in ESLD may result in hemodynamically significant left ventricular outflow tract obstruction (LVOTO). One retrospective review of 106 transplant recipients found inducible LVOTO on pre-operative dobutamine stress echocardiography (DSE) in 40% of patients [25]. In this study, an outflow gradient of 36 mm Hg was significantly associated with intraoperative hypotension. Many ESLD patients also have prolonged corrected QT interval (QTc) on an electrocardiogram which can be associated with an increased risk of ventricular arrhythmias. Though it is not a contraindication to surgery and anesthesia, one should look for electrolyte disturbances or the use of QT interval-prolonging drugs. All patients with ESLD should undergo a preoperative echocardiography to assess ventricular function, ventricular size, valvular function, pulmonary artery pressure, and to exclude the presence of a significant LVOTO or pericardial effusion. Pre-operative echocardiography is useful to calculate pulmonary artery systolic pressure. Pulmonary artery systolic pressures (PASP) values of 45-50 mmHg and /or right ventricular dysfunction are usually used for screening POPH. Right heart catheterization should be performed to gauge the mean pulmonary artery pressure (PAP), pulmonary capillary wedge pressure (PCWP) and transpulmonary gradient (TPG) as 5% to 10% of ESLD candidates have POPH [26]. A preoperative mPAP of 35 to 50 mm Hg has been associated with a 50% risk of mortality after liver transplantation in patients with POPH [26], and mortality approached 100% among patients with POPH and mPAP \geq 50 mm Hg [27]. Thus, POPH warrants perioperative treatment with vasodilators such as epoprostenol, sildenafil or nitric oxide. Stress testing of ESLD patients can be done to detect CAD. Dobutamine stress echocardiography has been found to have a negative predictive value in ESLD patients to be 85%.[28,29]. The predictive value of nuclear single-photon emission computed tomography (SPECT) stress imaging is limited by the chronic vasodilatory state exhibited by patients with ESLD [30]. The specificity of abnormal SPECT findings for obstructive CAD by coronary angiography is only 61% [31]. Coronary angiography is the gold standard for detecting CAD. When possible, it is important make an assessment of CAD risk in the ESLD patient before revascularization becomes contraindicated (usually an excessive bleeding risk due to coagulopathy and/or thrombocytopenia). Transesophageal echocardiography (TEE) and/or pulmonary artery

catheterization may be used intraoperatively to allow for real-time hemodynamic monitoring and volume management..

7. Anesthetic agents

All volatile anesthetics decrease the mean arterial pressure and portal blood flow. Halothane has consistently the most dramatic effect in reducing hepatic arterial blood flow. [32,33]. On the other hand, sevoflurane, desflurane and isoflurane have been consistently shown to better preserve hepatic blood flow and function. Intravenous anesthetics have a modest impact on hepatic blood flow, and no meaningful adverse impact on postoperative liver function if the mean arterial pressure is adequately maintained throughout the time anesthetized. Induction agents such as etomidate and thiopental decrease hepatic blood flow, either from increased hepatic arterial vascular resistance or from reduced cardiac output and/or blood pressure. [34]. Ketamine has little impact on hepatic blood flow. [35] Propofol increases total hepatic blood flow in both hepatic arterial and portal venous circulation, suggesting a significant vasodilator effect. [36,37].

Opioids such as morphine have significantly reduced metabolism in patients with advanced cirrhosis. The elimination half-life of morphine is prolonged, potentially exaggerating sedative and respiratory depressant effects. Fentanyl is highly lipid soluble with a short duration of action, which is also metabolized in the liver. Fentanyl elimination is not appreciably altered in patients with cirrhosis. [38,39]. However, unlike fentanyl, the half-life of alfentanil is almost doubled in patients with cirrhosis. [40]. Remifentanyl is a synthetic opioid with an ester linkage that allows for rapid hydrolysis by blood and tissue esterases. Its elimination is unaltered in patients with severe liver disease. [41].

Thiopental has a small hepatic extraction ratio. However, its elimination half-life is unchanged in cirrhotics, as it has a large volume of distribution. The clearance of etomidate is unchanged in cirrhotic patients, but its clinical recovery time maybe unpredictable due to increased volumes of distribution [42]. The elimination kinetic profile of propofol is similar in cirrhotic patients as well as normal patients, but the mean clinical recovery times maybe longer after discontinuation of infusions. [43]. The half-life of midazolam is prolonged due to reduced clearance, reduced protein binding, resulting in a prolonged duration of action and an enhanced sedative effect, especially after multiple doses or prolonged infusions. [44] Dexmedetomidine, an α_2 -adrenergic agonist, with sedative and analgesic properties, is primarily metabolized in the liver. Dose adjustments are therefore indicated when used in patients with significant hepatic dysfunction. [45].

Vecuronium and rocuronium are steroidal muscle relaxants which undergo hepatic metabolism, hence have decreased clearance, prolonged half-lives, and prolonged neuromuscular blockade in patients with cirrhosis. [46,47]. Atracurium and cisatracurium which undergo Hofmann elimination and ester hydrolysis respectively, have clinical duration of actions similar to those in normal patients. [48,49]

8. Intraoperative considerations

For liver surgery where major bleeding is anticipated, it is prudent to secure intravenous access using large bore peripheral catheters as well as central venous access catheters. Rapid sequence induction is recommended in patients with tense ascites to minimize the risk of aspiration. Circulatory collapse should be prevented by concomitant administration of intravenous colloid solutions because intravascular volume re-equilibrium occurs 6 to 8 hrs after removal of larger volumes of ascitic fluid. [50]. Large volumes of colloids and crystalloids maybe given within a few minutes with the assistance of commercially available rapid infusion devices. Red cell salvage should be facilitated with use of Cell savers with/without leukocyte filters. Blood administration may be associated with hyperkalemia and hypocalcemia.

Bleeding during liver surgery could be either surgical, due to previous or acquired coagulation disturbances, or both. The preoperative INR has no predictive value in relation to intraoperative blood loss and the value of fresh frozen plasma (FFP) administration to correct abnormal INR values is debatable and may even increase bleeding due to the volume load [51]. Intraoperative hemostasis panels consisting of INR, fibrinogen and platelet count, and platelet function assays for both platelet count and function, may help to differentiate between the above. A very useful intraoperative test for coagulation is the thromboelastograph (TEG). This test denotes the net effect of pro and anti-coagulants and pro and anti-fibrinolytic factors and the resulting clot tensile strength. It provides information on the rate and strength of clot formation and also clot stability/fibrinolysis. (Table 1)

Parameter	Interpretation	Preferred therapy for abnormal values
R	R is the time of latency from the time that the blood was placed in the TEG® analyzer until the initial fibrin formation.	FFP
α	The α -value measures the rapidity (kinetics) of fibrin build-up and cross-linking and the speed of clot strengthening.	Cryoprecipitate
K	K time is a measure of the rapidity to reach a certain level of clot strength.	FFP
MA	MA, or Maximum Amplitude, is a direct function of the maximum dynamic properties of fibrin and platelet bonding and represents the ultimate strength of the fibrin clot.	Platelet

Table 1. TEG Parameters

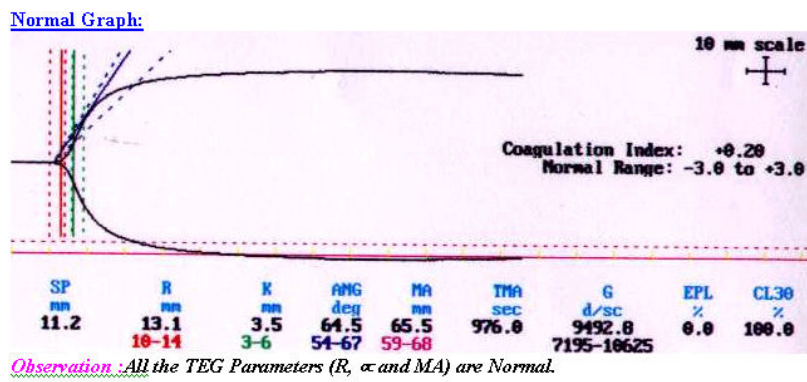


Figure 1. The Normal TEG Graph

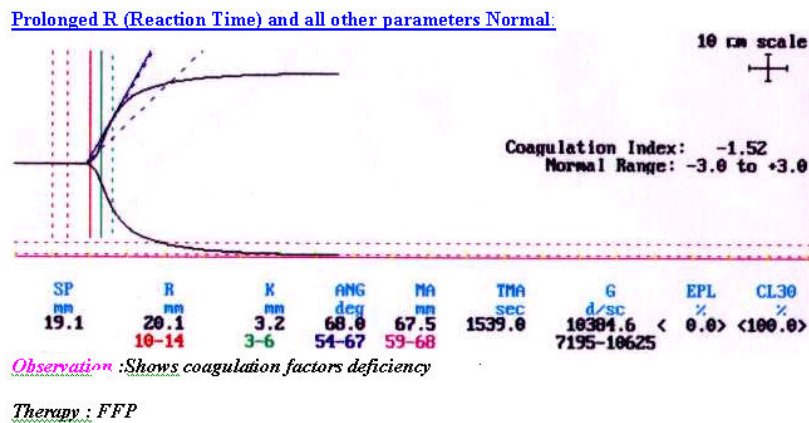


Figure 2. Prolonged Reaction Time

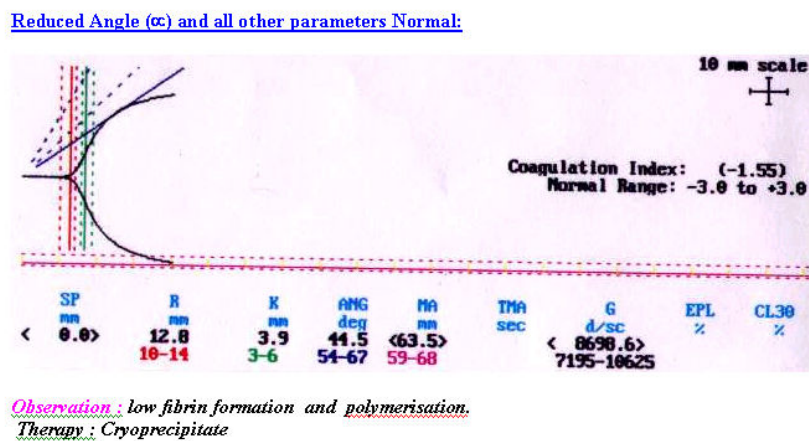


Figure 3. Reduced Angle

Reduced Maximum Amplitude (MA) and all other parameters normal:

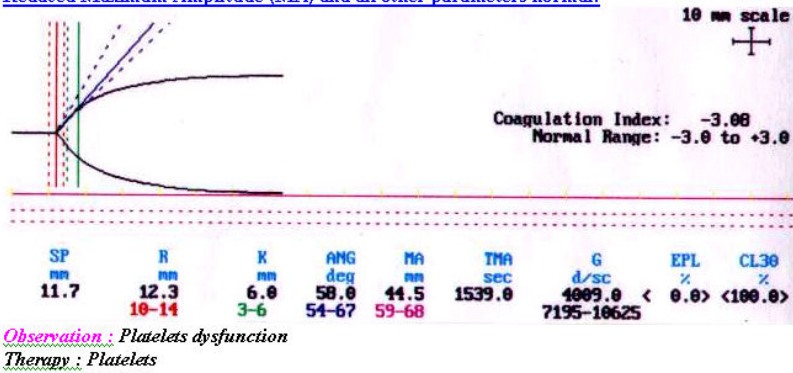


Figure 4. Reduced Maximum Amplitude.

FIBRINOLYSIS :
EPL more than 7.5% :

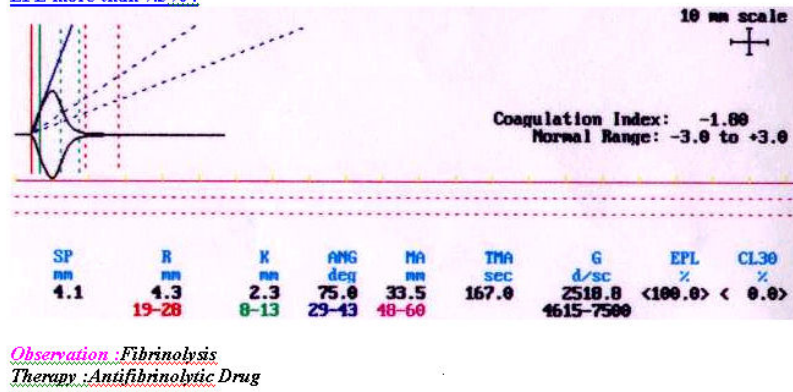


Figure 5. Fibrinolysis

Hyper Coagulability:




Figure 6. Hypercoagulability.

In addition, it is possible to detect heparin-like activity and to measure functional fibrinogen. (Figure 1-5,) Moreover, the only way to currently detect intraoperative hypercoagulability is via TEG. (Figure 6) Thus, TEG may act to facilitate specific goal directed therapy. If fibrinolysis is diagnosed on the TEG and it is causing clinically significant microvascular ooze, small doses of epsilon aminocaproic acid (EACA) or tranexamic acid (TA) are suitable anti-fibrinolytics. Factor VII has been used to control massive bleeding during liver surgery; however, it has not proved to be consistently effective to control bleeding and is associated with significant side effects. [52]

Transesophageal echocardiography (TEE) is a very useful cardiac monitoring tool to monitor function of the ventricles and assess intraoperative regional wall motion abnormalities (RWMAs), especially in patients with CAD. The monitoring of right heart systolic function is essential in patients with POPH. Moreover, it can be used effectively to assess volume status and guide fluid therapy.

9. Post-operative considerations

Surgery and anesthesia can further worsen hepatic function. Moreover, undiagnosed pre-existing liver disease is often the cause of hepatic dysfunction postoperatively. Depending upon the surgical procedure, one may observe continued “third space” losses.. Potential for renal dysfunction or failure as a result of surgery is exacerbated with pre-existing liver disease. As well, preoperative or intraoperative coagulopathy can continue postoperatively or can develop during first 24-48 hrs after surgery secondary to worsening hepatic dysfunction.

Postoperative jaundice occurs as a result of overproduction and under excretion of bilirubin, direct hepatocellular injury, or extra-hepatic obstruction. [53] Multiple blood transfusions can increase the levels of unconjugated bilirubin because approximately 10 % of stored whole blood undergoes hemolysis within 24 hours of transfusion. Each 0.5 – 1 unit of blood stored in CPDA-1 yields 7.5 g of hemoglobin, which is then converted to approximately 250 mg of bilirubin. [54] This may overwhelm the liver’s ability to conjugate and excrete bilirubin. Immediate postoperative jaundice (< 3wks) can also occur due for multiple reasons including but not exclusive to hemolysis, anesthesia, hypotension, hypovolemia, drugs, infection, sepsis, bleeding, resorption of hematoma, bile duct ligation or injury, hepatic artery ligation, retained common bile duct stone, postoperative pancreatitis, Gilbert’s syndrome, Dubin-Johnson Syndrome, inflammatory bowel syndrome, heart failure. [53] Delayed postoperative jaundice (>3 wks) can be a result of drugs, blood transfusion, post-intestinal bypass status and total parenteral nutrition. [53]

10. Postoperative pain relief role of epidural analgesia

Thoracic epidural analgesia provides excellent analgesia for liver resections. [55] The catheter is usually inserted at the T6-T9 space. Ropivacaine or bupivacaine are common local an-

esthetics used with or without the addition of small amounts of opioids such as fentanyl, sufentanil, hydromorphone or morphine. It also reduces the gastrointestinal paralysis compared with systemic opioids. [56]. There is benefit of using combined general and epidural anesthesia in patients with high-risk surgery, but this has not been extensively studied in hepatic surgery. The reasons are probably associated with the concerns with coagulation issues in this group. Additional concerns maybe harbored as neuroaxial blocks themselves are associated with risks. Estimated risk of having serious neurological injury may be as high as 0.08 %.[57, 58]. Moreover, direct spinal cord injury can occur without paraesthesias, whereas pain is more common in lesions affecting nerve roots. [59]. The incidence of persistent neurological deficit has been reported as 0.005-0.07 %. [60,61]. At our institution, we follow a practice where time from anticoagulant drug administration to epidural catheter placement is 3-5 days for warfarin, INR < 1.5, 4 hrs for heparin low dose subcutaneously, 12 hrs for low molecular weight heparin (LMWH), 5 days for clopidogrel and zero for aspirin. The time from epidural catheter removal to anticoagulant drug administration is at least 24 hrs for warfarin, 2 hrs for low dose heparin and 6-8 hrs for LMWH.

It is essential to understand that the degree of underlying parenchymal disease is not the only factor which is responsible for perioperative coagulopathy. Other important factors include amount of blood loss, dilution coagulopathy, amount and quality of residual liver parenchyma, its exposure to ischemia to name a few. [62-64]. Persistent pain or transient coagulopathy may cause delayed epidural catheter removal in patients undergoing partial hepatectomy [65]. The risk of meningitis or epidural abscess is in the range of 0.0004-0.05% [66,67].

11. Liver – specific surgical procedures

Transjugular Intrahepatic Portosystemic Shunt Procedure (TIPS)

TIPS is a procedure used in patients with end stage liver disease to decrease portal pressure and attenuate complications related to portal hypertension. It is usually done in the interventional radiology suite. The goal of this procedure is diversion of portal blood flow into the hepatic vein. The stent is passed through the internal jugular vein over a wire into the hepatic vein, which is located using fluoroscopic guidance. This stent is then advanced through the hepatic parenchyma into the portal vein. This will decompress the portal circulation. Usually, general anesthesia is requested for this procedure, as the radiologists prefer that the patients do not move during this procedure and it may be prolonged. Sedation is usually not preferred as there maybe potential respiratory depression in cirrhotic patients with underlying pulmonary dysfunction or hypoxemia from hepatopulmonary syndrome. Additionally, the presence of ascites may produce risk of aspiration. For this procedure, the central venous pressure (CVP) is monitored. After the stent is placed, the portal pressures are measured. Reduction of the difference between the two reflects the effectiveness of TIPS. Potential complications of this procedure include pneumothorax with internal jugular vein (IJV) cannulation, hematoma formation, inadvertent carotid puncture, cardiac arrhythmia

with intracardiac catheter passage, acute life threatening hemorrhage with hepatic artery puncture, hepatic capsular tear, extrahepatic portal venous puncture, development of pulmonary edema and congestive cardiac failure.

12. Radiofrequency Ablation (RFA) of hepatic tumors

Radiofrequency ablation of tumors up to 3 cm in size is currently used to treat non-resectable malignant tumors. During this procedure, a high-frequency, alternating current is delivered through a needle-like probe into the tumor, which induces coagulative necrosis of the tumor and surrounding tissue.[68,69]. PFA is done either percutaneously or laparoscopically. In a study which analyzed nationwide RFAs, it was found that procedure-specific complications were frequent (18.2 %), with transfusion requirements (10.7 %), intraoperative bleeding (4.3 %), and hepatic failure (2.8 %) being the most common. Postoperative complications were also common (12.0 %), with arrhythmias, heart failure, coagulopathy, and open surgical approach acting as significant predictors. [70]

Transarterial Chemoembolization (TACE)

Usually, an adequate amount of emulsion containing oil-based contrast agent Lipiodol and anticancer agents is injected through a catheter then the selected arteries are embolized by embolic agents. Superselective TACE is generally used to minimize damage to non-tumorous areas by using a microcatheter to embolize only the cancerous segment.[71-73] Epirubicin and cisplatin are commonly used as anticancer agents, and miriplatin, a new platinum drug, came into use in 2010.[74,75]. Indications for TACE are wide-ranging, and the procedure is generally performed in patients with hypervascular hepatocellular cancer (HCC) who are not indicated for surgery or local therapy for reasons such as multiple bilobar HCC, liver dysfunction, old age or co-morbidity, and in whom the first branch from the main portal vein is not occluded. In practice, this technique is commonly indicated for patients who are Child–Pugh class A or B with multiple tumors with a diameter of 3 cm or more or with four or more HCC. [76,77]. When TACE is combined with RFA, there may be several advantages. For example, TACE decreases the blood flow which in turn reduces the heat loss, thus increasing the size of the RFA ablative zone. In addition, the inclusion of TACE makes the evaluation of ablative margins easier, and enhances the control of satellite lesions.

Hepatic Resections

Liver resections can be done either open or robotic/laparoscopic. Hepatic resection procedures include partial resection, subsegmental resection, segmental resection, two segment resection, extended two-segment resection or three-segment resections. Pre-operative assessment should include the evaluation of the risk assessment using the CTP or MELD score, hepatic parenchymal function, and correction of severe anemia or coagulopathy, management of severe esophageal varices. The choice of anesthetic drugs as well as their doses should be based on the above assessment. There is a risk of significant blood loss. Therefore,

it may be prudent to secure large bore intravenous access and be prepared for rapid infusion of colloids and crystalloids. Blood and blood products should be made available for perioperative use. Control of bleeding during resection is usually done with pressure, coagulation and hilar clamping or via the Pringle maneuver. Hilar occlusion produces a minimal increase in systemic arterial pressure, increase in systemic vascular resistance and a minimal decrease in cardiac index. There may be risk of air embolism with extensive resection and disruption of hepatic veins. Most surgeons request a low central venous pressure to facilitate dissection and minimize blood loss from the hepatic vessels and vena cava. Postoperative concerns are similar to those in major abdominal surgery. Central neuroaxial analgesia is not recommended if there is risk of coagulopathy which may result in hematoma formation in the epidural or spinal space.

Donor Liver Hepatectomy

One method of expanding donor pool for liver transplantation is the use of living donor grafts. Adult-to-adult living donor liver transplantation (LDLT) is a complex procedure that poses serious health risks to and provides no direct health benefit for the donor. Because of this uneven risk-benefit ratio, ensuring donor autonomy through informed consent is critical. However, informed consent for LDLT is sub-optimal as donors do not adequately appreciate disclosed information during the informed consent process, despite United Network for Organ Sharing/CMS regulations requiring formal psychological evaluation of donor candidates. [78] Types of donor liver grafts can be left lobe, left lobe and caudate, right lobe, extended right lobe and right lateral sector. After preoperative evaluation and screening, a virtual resection and volume analysis is done using contrast enhanced computed tomography (CT). These not only estimate SLV but can also determine segmental volume, delineate surgical planes, define anatomical landmarks of hepatic vasculature and biliary structures and calculate anticipated graft and remnant liver volumes post resection. It is essential that the minimal donor remnant volume be at least 30% of the original volume. Additionally, when right-lobe LDLT is planned, whether the middle hepatic vein (MHV) should remain in the donor or be resected is controversial. The MHV primarily provides various drainage of the right anterior lobe and segment IV. Most transplant surgeons prefer to leave the MHV in the donor to avoid congestion of segment IV and reduce the risk of liver failure in the donor.[79] The anesthesia management is similar to that of hepatectomy. In donors, several complications have been reported. In one study, right hepatectomy (resection of segments 5–8) was done in 101 donors, left lobectomy (resection of segments 2–3) in 11 donors, and left hepatectomy (resection of segments 2–4) in one donor. Minor anesthetic complications were shoulder pain, pruritus and urinary retention related to epidural morphine, and major morbidity included central venous catheter-induced thrombosis of the brachial and subclavian vein, neuropraxia, foot drop and prolonged postdural puncture headache. One of 113 donors died from pulmonary embolism on the 11th postoperative day. [80]. It was also observed that donor patients experienced significant postoperative pain despite the use of thoracic patient-controlled epidural analgesia (PCEA) infusion catheters as compared to patients who had undergone major hepatic resection. This was attributed to the longer surgical duration for donor hepatectomy and neuroplasticity which may play a role

in exaggerated postoperative pain perception along with various psychological factors.[81]. It is also interesting to note that approximately 10% of donors had a platelet count < 150,000 x 10⁹/liter, 2 to 3 years post-donation. [82]

13. Conclusion

Patients with liver disease are at increased risk for both perioperative morbidity and mortality. They require delineation of the degree of liver dysfunction present prior to undergoing surgery and have outcomes that are primarily dictated by the degree of hepatic dysfunction and type of surgery performed. They can certainly pose significant challenges for perioperative care.

Author details

Aparna Dalal* and John D. Jr. Lang

*Address all correspondence to: dalala1@uw.edu

The University of Washington School of Medicine, Department of Anesthesiology & Pain Medicine, NE Pacific, Seattle, WA, USA

References

- [1] Munoz S, Reddy R, Lee W et al. Coagulopathy in acute liver failure. *Neurocrit Care* 2008;9:103-7
- [2] Rodriguez-Roisin, R, Krowka MJ, Hepatopulmonary syndrome: a liver-induced lung vascular disorder. *N Eng J Med* 2008; 358: 2378-2387.
- [3] Gines P, Schrier RW. Renal failure in cirrhosis. *N Engl J Med*, 2009; 361: 1279-90.
- [4] Riordan SM, Williams R: Treatment of hepatic encephalopathy. *N Engl J Med* 1997; 337:473-479.
- [5] Pugh RHN, Murray-Lyon IM, Dawson JL, et al. Transection of oesophagus for bleeding of oesophageal varices. *Br J Surg* 60:646-649,1973.
- [6] Mansour A, Watson W, Shayani V, Pickelman J: Abdominal operations in patients with cirrhosis: Still a major surgical challenge. *Surgery* 1997; 22:730-736.
- [7] Agarwal B, Shaw S, Hari MS et al. Continuous renal replacement therapy in patients with liver disease. *J. Hepatol* 2009;51:504-9

- [8] Rockey DC, Caldwell SH, Goodman ZD et al. Liver Biopsy (AASLD Position Paper) *Hepatology*, 2009;3:1017- 1044.
- [9] Tripodi A, Primignani M, Chantarangkul V et al. Thrombin generation in patients with cirrhosis: the role of platelets. *Hepatology* 2006;44:440-445.
- [10] Rodriguez-Roisin R, Krowka M, Hervé P, Fallon M. Pulmonary-hepatic vascular disorders (PHD). *Eur Respir J* 2004; 24:861-880.
- [11] Ramsay M. Portopulmonary Hypertension and Right Heart failure in Patients with Cirrhosis. *Curr Opin Anaesthesiol* 2010;
- [12] Salerno F, Gerbes A, Gines P et al. Diagnosis, prevention and treatment of hepatorenal syndrome in cirrhosis. *Gut*, 2007; 56: 1310-8.
- [13] Alqahtani SA, Fouad TR, Lee SS. Cirrhotic cardiomyopathy. *Semin Liver Dis* 2008; 28:59–69.
- [14] Baik SK, Fouad TR, Lee SS. Cirrhotic cardiomyopathy. *Orphanet J Rare Dis* 2007; 2:15.
- [15] Gaskari SA, Honar H, Lee SS. Therapy insight: cirrhotic cardiomyopathy. *Nat Clin Pract Gastroenterol Hepatol* 2006;3:329 –37.
- [16] Liu H, Song D, Lee SS. Cirrhotic cardiomyopathy. *Gastroenterol Clin Biol* 2002; 26:842–7.
- [17] Moller S, Henriksen JH. Cirrhotic cardiomyopathy: a pathophysiological review of circulatory dysfunction in liver disease. *Heart* 2002;87:9 –15.
- [18] Myers RP, Lee SS. Cirrhotic cardiomyopathy and liver transplantation. *Liver Transpl* 2000;6 Suppl 1:44 –52.
- [19] Ward CA, Liu H, Lee SS. Altered cellular calcium regulatory systems in a rat model of cirrhotic cardiomyopathy. *Gastroenterology* 2001;121:1209–8.
- [20] Bernardi M, Calandra S, Colantoni A, et al. Q-T interval prolongation in cirrhosis: prevalence, relationship with severity, and etiology of the disease and possible pathogenetic factors. *Hepatology* 1998;27: 28–34.
- [21] Henriksen JH, Fuglsang S, Bendtsen F, Christensen E, Moller S. Dyssynchronous electrical and mechanical systole in patients with cirrhosis. *J Hepatol* 2002;36:513–20.
- [22] Kelbaek H, Rabol A, Brynjolf I, et al. Haemodynamic response to exercise in patients with alcoholic liver cirrhosis. *Clin Physiol* 1987;7:35– 41.
- [23] Tripathi D, Hayes PC. The role of carvedilol in the management of portal hypertension. *Eur J Gastroenterol Hepatol* 2010;22:905–11.
- [24] Tiukinhoy-Laing SD, Rossi JS, Bayram M, et al. Cardiac hemodynamic and coronary angiographic characteristics of patients being evaluated for liver transplantation. *Am J Cardiol* 2006;98:178–81

- [25] Maraj S, Jacobs LE, Maraj R, et al. Inducible left ventricular outflow tract gradient during dobutamine stress echocardiography: an association with intraoperative hypotension but not a contraindication to liver transplantation. *Echocardiography* 2004;21:681–5.
- [26] Swanson KL, Wiesner RH, Nyberg SL, Rosen CB, Krowka MJ. Survival in portopulmonary hypertension: Mayo Clinic experience categorized by treatment subgroups. *Am J Transplant* 2008;8: 2445–53.
- [27] Martinez-Palli G, Taura P, Balust J, Beltran J, Zavala E, Garcia- Valdecasas JC. Liver transplantation in high-risk patients: hepatopulmonary syndrome and portopulmonary hypertension. *Transplant Proc* 2005;37:3861– 4.
- [28] Williams K, Lewis JF, Davis G, Geiser EA. Dobutamine stress echocardiography in patients undergoing liver transplantation evaluation. *Transplantation* 2000;69:2354–6.
- [29] Donovan CL, Marcovitz PA, Punch JD, et al. Two-dimensional and dobutamine stress echocardiography in the preoperative assessment of patients with end-stage liver disease prior to orthotopic liver transplantation. *Transplantation* 1996;61:1180–8.
- [30] Davidson CJ, Gheorghide M, Flaherty JD, et al. Predictive value of stress myocardial perfusion imaging in liver transplant candidates. *Am J Cardiol* 2002;89:359–60.
- [31] Aydinalp A, Bal U, Atar I, et al. Value of stress myocardial perfusion scanning in diagnosis of severe coronary artery disease in liver transplantation candidates. *Transplant Proc* 2009;41:3757– 60.
- [32] Gatacel C, Lossner MR, Payen D: The postoperative effects of halothane versus isoflurane on hepatic artery and portal vein blood flow in humans. *Anesth Analg* 2003; 96:740-745.
- [33] Grundmann U, Zizzis A, Bauer C, Bauer M: In vivo effects of halothane, enflurane, and isoflurane on hepatic sinusoidal microcirculation. *Acta Anaesthesiol Scand* 1997; 41:760-765.
- [34] Thomson IA, Fitch W, Hughes RL, et al: Effects of certain I.V. anaesthetics on liver blood flow and hepatic oxygen consumption in the greyhound. *Br J Anaesth* 1986; 58:69-80.
- [35] Thomson IA, Fitch W, Campbell D, et al: Effects of ketamine on liver blood flow and hepatic oxygen consumption: Studies in the anaesthetized greyhound. *Acta Anaesthesiol Scand* 1988; 32:10-14.
- [36] Carmichael FJ, Crawford MW, Khayyam N: Effect of propofol infusion on splanchnic hemodynamics and liver oxygen consumption in the rat. *Anesthesiology* 1993; 79:1051-1060.

- [37] Wouters PF, Van de Velde MA, Marcus MAE, et al: Hemodynamic changes during induction of anesthesia with etanolone and propofol in dogs. *Anesth Analg* 1995; 81:125-131.
- [38] Tegeder I, Lötsch J, Geisslinger G: Pharmacokinetics of opioids in liver disease. *Clin Pharmacokinet* 1999; 37:17-40.
- [39] Haberer JP, Schoeffler P, Couderc E, et al: Fentanyl pharmacokinetics in anaesthetized patients with cirrhosis. *Br J Anaesth* 1982; 54:1267-1270.
- [40] Ferrier C, Marty J, Bouffard Y, et al: Alfentanil pharmacokinetics in patients with cirrhosis. *Anesthesiology* 1985; 62:480-484.
- [41] Dershwitz M, Hoke JF, Rosow CE, et al: Pharmacokinetics and pharmacodynamics of remifentanyl in volunteer subjects with severe liver disease. *Anesthesiology* 1996; 84:812-820
- [42] Van Beem H, Manger FW, Van Boxtel C, et al: Etomidate anaesthesia in patients with cirrhosis of the liver: Pharmacokinetic data. *Anaesthesia* 1983; 38:61-62
- [43] Servin F, Cockshott ID, Farinotti R, et al: Pharmacokinetics of propofol infusions in patients with cirrhosis. *Br J Anaesth* 1990; 65:177-183.
- [44] Trouvin JH, Farinotti R, Haberer JP, et al: Pharmacokinetics of midazolam in anaesthetized cirrhotic patients. *Br J Anaesth* 1988; 60:762-767.
- [45] Baughman VL, Cunningham FE, Layden T: Pharmacokinetic/pharmacodynamic effects of dexmedetomidine in patients with hepatic failure. *Anesth Analg* 2000; 90(Suppl):S391.
- [46] Arden JR, Lynam DP, Castagnoli KP, et al: Vecuronium in alcoholic liver disease: A pharmacokinetic and pharmacodynamic analysis. *Anesthesiology* 1988; 68:771-776.
- [47] Magorian T, Wood P, Caldwell J, et al: The pharmacokinetics and neuromuscular effects of rocuronium bromide in patients with liver disease. *Anesth Analg* 1995; 80:754-759.
- [48] De Wolf AM, Freeman JA, Scott VL, et al: Pharmacokinetics and pharmacodynamics of cisatracurium in patients with end-stage liver disease undergoing liver transplantation. *Br J Anaesth* 1996; 76:624-628.
- [49] Ward S, Neill EA: Pharmacokinetics of atracurium in acute hepatic failure (with acute renal failure). *Br J Anaesth* 1983; 55:1169-1172.
- [50] Menon KVN, Kamath PS: Managing the complications of cirrhosis. *Mayo Clin Proc* 2000; 75:501-509.
- [51] Massicotte L, Capitanio U, Beaulieu D et al. Independent validation of a model predicting the need for RBC transfusion in liver transplantation. *Transplantation* 2009;88:386-91.

- [52] Shami VM, Caldwell SH, Hespenheide E. Recombinant factor VIIa for coagulopathy in fulminant hepatic failure compared to conventional therapy. *Liver Transplant* 2003;9:138-143.
- [53] Nyberg LM, Pockros PJ: Postoperative jaundice. In Schiff ER, Sorrell MF, Maddrey WC, ed. *Schiff's Diseases of the Liver*, 8th ed. Philadelphia: Lippincott-Raven; 1999:599-605.
- [54] Zuck TF, Basinger TA, Peck CC, et al: The in vivo survival of red blood cells stored in modified CDP with adenine: Report of a multi-institutional cooperative effort. *Transfusion* 1972; 17:374-382.
- [55] Werawatganon T, Charuluxanun S. Patient controlled intravenous opioid analgesia versus continuous epidural analgesia for pain after intra-abdominal surgery. *The Cochrane Database of Systematic Reviews* 2005, Issue 1. Art. No.: CD004088.pub2. DOI: 10.1002/14651858.CD004088.pub2.
- [56] Jørgensen H, Wetterslev J, Møiniche S, Dahl JB. Epidural local anaesthetics versus opioid-based analgesic regimens for postoperative gastrointestinal paralysis, PONV and pain after abdominal surgery. *The Cochrane Database of Systematic Reviews* 2001, Issue 1. Art. No.: CD001893. DOI: 10.1002/14651858.CD00001893.
- [57] Horlocker TT, Abel MD, Messick JM Jr, Schroeder DR. Small risk of serious neurologic complications related to lumbar epidural catheter placement in anesthetized patients. *Anesth Analg* 2003;96:1547-52
- [58] Rosenquist RW, Birnbach DJ. Editorial Epidural insertion in anesthetized adults: will your patients thank you? *Anesth Analg* 2003;96:1545-6.
- [59] Tsui BC, Armstrong K. Can direct spinal cord injury occur without paresthesia? A report of delayed spinal cord injury after epidural placement in an awake patient. *Anesth Analg* 2005;101:1212-4.
- [60] Wheatley RG, Schug SA, Watson D. Safety and efficacy of postoperative epidural analgesia. *Br J Anaesth* 2001;87:47-61.
- [61] Horlocker TT, Wedel DJ. Neurologic complications of spinal and epidural anesthesia. *Reg Anesth Pain Med*. 2000;25(1):83-98. Review.
- [62] Borromeo CJ, Stix MS, Lally A, Pomfret EA. Epidural catheter and increased prothrombin time after right lobe hepatectomy for living donor transplantation. *Anesth Analg*. 2000 Nov;91(5):1139-41.
- [63] Schumann R, Zabala L, Angelis M, Bonney I, Tighiouart H, Carr DB. Altered hematologic profiles following donor right hepatectomy and implications for perioperative analgesic management. *Liver Transpl*. 2004 Mar;10(3):363-8.
- [64] Siniscalchi A, Begliomini B, De Pietri L, Braglia V, Gazzi M, Masetti M, Di Benedetto F, Pinna AD, Miller CM, Pasetto A. Increased prothrombin time and platelet counts

- in living donor right hepatectomy: implications for epidural anesthesia. *Liver Transpl.* 2004 Sep;10(9):1144-9.
- [65] Tsui S L, Young B H, NG KFJ, et al. Delayed epidural catheter removal: the impact of postoperative coagulopathy. *Anaesth Intensive Care* 2004;32:630-6
- [66] Moen V, Dahlgren N, Irestedt L. Severe neurological complications after central neuraxial blockades in Sweden 1990-1999. *Anesthesiology* 2004;101:950-9.
- [67] Wang LP, Hauerberg J, Schmidt JF. Incidence of spinal epidural abscess after epidural analgesia. *Anesthesiology* 1999;91:1928-36.
- [68] Curley SA, Marra P, Beaty K, Ellis LM, Vauthey JN, Abdalla EK, et al. Early and late complications after radiofrequency ablation of malignant liver tumors in 608 patients. *Ann Surg.* ;239:450-8.
- [69] Krishnamurthy VN, Casillas J, Latorre L. Radiofrequency ablation of hepatic lesions: A review. *Appl Radiol.* 2003;32:11-26.
- [70] Justin P. Fox, MD 1, Joshua Gustafson, MD2, Mayur M. Desai, PhD MPH1,3, Minia Hellan, MD4, Thav Thambi-Pillai, MD5, and James Ouellette, DO4. Short-Term Outcomes of Ablation Therapy for Hepatic Tumors: Evidence from the 2006-2009 Nationwide Inpatient Sample *Ann Surg Oncol* DOI 10.1245/s10434-012-2397-0.
- [71] Matsui O, Kadoya M, Yoshikawa J et al. Small hepatocellular carcinoma: treatment with subsegmental transcatheter arterial embolization. *Radiology* 1993; 188: 79-83.
- [72] Matsui O, Kadoya M, Yoshikawa J, Gabata T, Takashima T, Demachi H. Subsegmental transcatheter arterial embolization for small hepatocellular carcinomas: local therapeutic effect and 5-year survival rate. *Cancer Chemother Pharmacol* 1994; 33 (Suppl): S84-8.35
- [73] Takayasu K, Arii S, Kudo M et al. Superselective transarterial chemoembolization for hepatocellular carcinoma. Validation of treatment algorithm proposed by Japanese guidelines. *J Hepatol* 2012; 56: 886-92.
- [74] Okabe K, Beppu T, Haraoka K et al. Safety and short-term therapeutic effects of miriplatin-lipiodol suspension in transarterial chemoembolization (TACE) for hepatocellular carcinoma. *Anticancer Res* 2011; 31: 2983-8.
- [75] Okusaka T, Kasugai H, Ishii H et al. A randomized phase II trial of intra-arterial chemotherapy using SM-11355 (Miriplatin) for hepatocellular carcinoma. *Invest New Drugs* 2011; doi. 10.1007/s10637-011-9776-4.
- [76] Kudo M, Izumi N, Kokudo N et al. Management of hepatocellular carcinoma in Japan: Consensus-Based Clinical Practice Guidelines proposed by the Japan Society of Hepatology (JSH) 2010 updated version. *Dig Dis* 2011; 29: 339-64.
- [77] Clinical Practice Guidelines for hepatocellular carcinoma – The Japan Society of Hepatology 2009 update. *Hepatol Res* 2010; 40 (Suppl 1): 2-144.

- [78] Elisa J. Gordon,^{1,2,5} Amna Daud, et al. Informed Consent and Decision-Making About Adult-to-Adult Living Donor Liver Transplantation: A Systematic Review of Empirical Research (*Transplantation* 2011;92: 1285–1296)
- [79] Hertl M, Cosimi AB: Living donor liver transplantation: how can we better protect the donors? *Transplantation* 83:263, 2007
- [80] S. Ozkardeslera, D. Ozzeybeka, et al. Anesthesia-Related Complications in Living Liver Donors: The Experience from One Center and the Reporting of One Death *American Journal of Transplantation* 2008; 8: 2106–2110
- [81] Jacek B. Cywinski, MD, Brian M. Parker, MD, Meng Xu, Samuel A. Irefin, MD. A Comparison of Postoperative Pain Control in Patients After Right Lobe Donor Hepatectomy and Major Hepatic Resection for Tumor. *Anesth Analg* 2004;99:1747–52.
- [82] James F. Trotter, et al. Laboratory Test Results After Living Liver Donation in the Adult-to-Adult Living Donor Liver Transplantation Cohort Study *LIVER TRANSPLANTATION* 17:409-417, 2011

