

# We are IntechOpen, the world's leading publisher of Open Access books Built by scientists, for scientists

4,800

Open access books available

122,000

International authors and editors

135M

Downloads

Our authors are among the

154

Countries delivered to

TOP 1%

most cited scientists

12.2%

Contributors from top 500 universities



WEB OF SCIENCE™

Selection of our books indexed in the Book Citation Index  
in Web of Science™ Core Collection (BKCI)

Interested in publishing with us?  
Contact [book.department@intechopen.com](mailto:book.department@intechopen.com)

Numbers displayed above are based on latest data collected.  
For more information visit [www.intechopen.com](http://www.intechopen.com)



---

# General Introduction: Advances in Hepatic Surgery

---

J.H.M.B. Stoot, R.J.S. Coelen, J.L.A. van Vugt and  
C.H.C. Dejong

Additional information is available at the end of the chapter

<http://dx.doi.org/10.5772/54710>


---

## 1. Introduction

Hepatic resection is a commonly performed procedure for a variety of malignant and benign hepatic tumours [1, 2]. Historically, liver resection, irrespective of the indication, was associated with a high morbidity and mortality [2-4]. During the last decades however, perioperative outcome after hepatic resection has improved, due to increased knowledge of liver anatomy and function, improvement of operating techniques and advances in anaesthesia and postoperative care [1, 3, 4].

Hepatic resectional surgery is possible since the liver has the ability to regenerate. Although it is doubtful whether the ancient Greeks already appreciated this unique quality of the liver, it was first described in the myth of Prometheus (Προμηθεύς): he enraged the Gods for his disrespect (ὕβρις) after climbing the Mount Olympus and stealing the torch in order to give fire to the humans. He was punished by Zeus and chained to a rock in the Caucasus Mountains. Every couple of days, an eagle came and ate part of his liver. As the liver regenerated every time, the eagle returned again and again to eat the liver and thereby torture poor Prometheus (figure 1). With this ancient knowledge it was considered possible to take parts of the liver, as this organ has enough capacity to work with a smaller part and is able to regenerate.

Apart from the eagle, no human dared to remove a part of the liver. In the ancient period of the Assyrian and Babylonian cultures of 2000 - 3000 BC the liver played an important role to predict the future by reading the surface of sacrificed animals [5]. This was also common in the Etruscan society, where the haruspices predicted the future from sheep livers. Hippocrates (460-377 BD), one of the founding fathers of ancient medicine, produced not only an oath with ethical rules, which is still used in modern times for all doctors. His careful observations also led to the recommendation to incise and drain abscesses of the liver with a knife [5]. Celsus documented the treatment of exposed liver in war wounds. Although he was not a physician,



**Figure 1.** Prometheus chained (243 x 210 cm), Peter Paul Rubens, ca. 1611-1618, Philadelphia, Philadelphia Museum of Art.

he described his observations in the first century AD from the Alexandrian school led by Herophilus of Chalcedon and Erisastratus of Chios [5]. In the same era, the Greek Galen became one of the emperor's physicians in Rome and wrote reports about the dissection of many species of animals, including primates. He described the central role of the liver in absorption and digestion and his work remained of great importance for the coming centuries [5]. In the centuries thereafter many reports were produced describing the treatment of war or trauma wounds.

Glisson performed extensive investigations of the vascular anatomy in 1654 (figure 2) [6]. It took more than two centuries before his work was rediscovered and further clarified by Rex (1888) in Germany and Cantlie (1897) in England [5, 7]. These contributions led to the division of the liver in a left and right lobe [5].



**Figure 2.** Francis Glisson (1599-1677).

## 2. History of hepatic surgery

It still took 17 centuries before Hildanus successfully performed the first partial liver resection for trauma [8]. The introduction of ether anaesthesia (1846) and the growing knowledge of antiseptics (1867) made successful elective abdominal operations possible (table 1) [5]. Langenbuch was the first to perform a successful elective liver resection in 1887 (figure 3) and Wendel did the first hemihepatectomy in 1911 [8]. The principles of liver haemostasis and regeneration were determined in the period 1880-1900 [8]. The knowledge of the principle of inflow and outflow of the liver and vascular control was one of the major advancements. Before that, wedge resections and mattress sutures were mostly used. This insight of inflow and outflow reduction was marked by the publication of James Hogart Pringle of Glasgow, Scotland (figure 4) [9]. He described the idea of digital control of the hilar ligament to reduce liver haemorrhage. In his famous report (1908) on liver haemorrhage after trauma, eight patients were included. Three died before the operation, one refused the operation and all four operated patients died; two died during the operation and two shortly

thereafter [5, 9]. However, his idea of digital vascular control of the hilum was more successful in the laboratory setting, where he operated three rabbits with better results, which led to his publication. Nowadays, more than a century later, the 'Pringle manoeuvre' or 'Pringle's pinch' is still used worldwide in hepatic resectional surgery and taught to all young surgeons to control haemorrhage of the liver.

1846	Introduction of Ether anaesthesia	Morton
1863	Bacterial fermentation of wine	Pasteur
1867	Antisepsis	Lister
1870	First successful excision of section of the liver	Bruns
1880	Discovery of Streptococci, staphylococci and pneumococci	Pasteur
1881	First successful gastrectomy	Billroth
1882	First successful cholecystectomy	Langenbuch
1883	First human colon anastomosis	Billroth and Senn
1884	Pancreas excised for cancer	Billroth
1886	Report on appendicitis	Fitz
	Introduction of sterilisation by steam	Von Bergmann
	First elective liver resection for adenoma	Lius
1887	First successful elective liver resection	Langenbuch
1887	Successful packing of stabwound of liver	Burckhardt
1888	First successful laparotomy for traumatic liver injury	Willet

**Table 1.** Advances in the beginning of surgery [5].



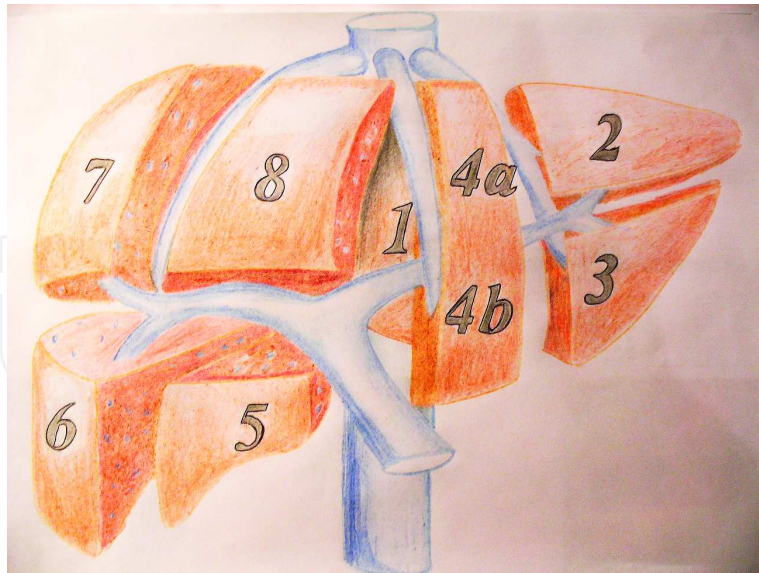
**Figure 3.** James Hogarth Pringle (1863-1941).



**Figure 4.** Carl Langenbuch (1846-1901).

Liver surgery became gradually more popular as a better understanding of anatomic segments was established after the work of Couinaud [10]. The classic morphological (outside) anatomy with two main lobes (left and right) was extended by the internal hepatic anatomy with several independent functional segments (figure 5). Each hepatic segment consists of liver parenchyma with an efferent hepatic vein branch and a portal triad; a hepatic artery branch, an afferent portal vein, and an efferent bile duct. The classic right lobe consists of four segments, the left lobe consists of three segments and the caudate lobe is segment 1.

With knowledge of the segmental anatomy of the liver, a safe transection plane could be chosen for resection without excessive blood loss and without necrosis of remnant liver. This specific anatomy of independent functional segments made it possible to resect parts of the liver without compromising the hepatic function of remnant segments. Moreover, as already described by the myth of Prometheus, the liver has regeneration capacity in contrast to other human organs. In other words after partial resections, the liver can recover its mass and function. The term 'function of the liver' is actually a collective term for a range of functions including amongst others ammonia detoxification, urea synthesis, bile synthesis and secretion, protein synthesis, gluconeogenesis and clearance or detoxification of drugs, bacterial toxins and bacteria [11]. As the liver is the main detoxifying organ in humans, adaptation of its function is crucial to survive. Regeneration however, takes time. After liver surgery with a reduction of the hepatic cell mass, a 'survival programme' may start for vital liver functions [12]. Some of these functions are increased rapidly in the remnant liver after resection [13]. In the light of major hepatic resections, it is conceivable that too little functional liver remnant may lead to liver failure, a lethal complication of liver surgery.



**Figure 5.** The anatomy of the liver with separate segments following Couinaud's classification. In this drawing only major venous vessels are displayed (portal vein, caval vein and hepatic veins).

### 3. Resectional hepatic surgery

Hepatobiliary surgery incorporates a wide range of indications for surgical treatment of the liver, varying from biopsy and resection to liver transplantation. The most important indications for surgical treatment are liver lesions: these comprise a wide range of both benign and malignant lesions, which can be either primary tumours (hepatocellular carcinoma) or secondary tumours (i.e. metastases). Also, some infectious diseases of the liver (such as echinococcosis) may be an indication for surgery. Irreversible liver dysfunction caused by acute or chronic liver diseases, may be an indication for transplantation of the liver. Other benign diseases of the liver such as symptomatic simple cysts and Polycystic Liver Disease (PCLD) may also warrant surgical treatment. Other reasons for surgery of the liver may be after severe injury or trauma of the liver. The latter indications are beyond the scope of this chapter. Since hepatic lesions form the main surgical indication for hepatic diseases, the focus will be on resectional liver surgery.

#### 3.1. History of hepatic surgery for malignant lesions

The report of the first anatomical right hepatectomy for cancer by Lortat-Jacob in 1952 marked a new era in liver surgery [14]. In the beginning, however, blood loss and mortality were considerable. A multicentre analysis in 1977 of more than 600 hepatic resections for various indications showed an operative mortality of 13%, which rose to 20% for major resections [15]. Despite this, pioneers in liver surgery continued the quest for improving this challenging field of expertise and gradually mortality decreased to 5.6% [16]. The 5 year survival rates have

increased from 20% in the beginning [16, 17] to as high as 67% in selected patients [18]. Earlier developments in liver surgery have been marked by major contributions of Starzl (USA), Bismuth (France) and Ton That Tung (Vietnam) [19-22]. With better knowledge of the segmental anatomy, it was shown that parenchyma-sparing segmental resections were equally effective as classic lobar resections, and in this way more functional remnant liver was preserved [3, 23, 24]. Also, anaesthetic care and liver transection techniques were modernized and improved over time [1, 3, 4, 25, 26].

Over the last decades, it was shown in several large series that perioperative results became more encouraging, with operative mortality rates less than 5% in high volume centres [3, 24, 25]. Due to these improvements in liver surgery which not only proved to prolong life but also to be a potentially curative treatment option for primary and metastatic cancers [27, 28], liver surgery became standard of care for selected patients with primary and secondary hepatobiliary malignancies. Moreover, with the increasing improvements in the safety of hepatic resections, this evolved to the most effective treatment for some benign diseases [29].

It is hard to pinpoint one discriminating factor that made the improvements in outcome possible [3]. Many factors contribute to the gradually improved outcome. Most important factors in this regard are probably the better knowledge of hepatic anatomy and thus anatomically based resections, better patient selection, general improvements in operative and anaesthetic care and the development of hepatobiliary surgery as a distinct area of specialisation [3].

### **3.2. Transection techniques in hepatic resection**

Parenchymal transection is the most challenging part of liver resection. Due to the complicated vascular and biliary anatomy of the liver, haemorrhage is a great risk [30-35]. The firstly performed liver resections failed as a consequence of haemorrhage or patients died shortly after because of bleeding [31]. Before the 1980s, mortality after hepatic resection was 10 to 20% and haemorrhage was a common cause [30]. Moreover, blood transfusion in the perioperative period is associated with poorer outcome in the long term [33]. In contrast to patient- or tumour-related factors, surgical techniques can be changed in order to prevent blood loss and transfusion.

Parenchymal division was first described in 1958 when Lin and colleagues introduced the finger fracture technique (digitoclasy) in which liver tissue is crushed between the surgeon's fingers [30]. Vessels and bile ducts are exposed, identified and then divided. Soon this technique was improved by using surgical clamps (i.e. Kelly clamp) and called the crush-clamp technique [30, 31]. Division of the vessels and bile ducts can be achieved by suture ligation, bipolar electrocautery, vessel sealing devices or vascular clips. It is frequently combined with intermittent inflow occlusion by portal triad clamping (Pringle maneuver) [31].

Subsequently, many transection techniques have been developed in order to improve results. The Cavitron Ultrasonic Surgical Aspirator (CUSA, Tyco Healthcare, Mansfield, MA, USA) combines ultrasonic energy with aspiration and results in a more precise transection plane.



Vessels and bile ducts are exposed and can then be divided with a method according to the surgeon's preference [30, 31]. In a recent study, liver parenchyma transection using CUSA was associated with higher numbers of potentially dangerous air embolism although patients did not show clinical symptoms [36]. The Harmonic Scalpel (Ethicon Endo-Surgery, Cincinnati, OH, USA) is comparable to the CUSA, but it uses ultrasonic shears and vibration to cut through the parenchyma. It instantly coagulates blood vessels by protein denaturation and is mainly used in laparoscopic procedures, because of the difficulties using the other transection instruments in this setting. The hydro or water jet uses a high-pressure water jet to dissect liver parenchyma and expose vessels and bile ducts after which they can be divided. Like with the Harmonic Scalpel, less thermal damage is caused. In radiofrequency-assisted liver resection radiofrequent electrodes are inserted in the transection plane and radio frequent energy is applied for one to two minutes, followed by transection of the coagulated liver using a conventional scalpel. [30, 31].

In a review including seven randomized controlled trials with a total of 556 patients, the clamp-crush technique was quicker and associated with lower rates of blood loss and transfusion compared with CUSA, hydrojet and radiofrequency dissecting sealer. No significant differences in mortality, morbidity, liver dysfunction, ICU stay and length of hospital stay were found. The crush-clamp technique comes with low costs and does not need any extra advanced tools. However, not all techniques in the trials were combined with vascular occlusion. This may have led to a bias in favour of the clamp-crush technique [32, 34]. The CRUNSH trial will demonstrate whether vascular stapling is superior to the crush-clamp method in elective hepatic resection [37]. Palavecino and colleagues developed the so-called 'two-surgeon method', combining a saline-linked cautery and an ultrasonic dissector. Exposure of vessels and biliary ducts and haemostasis are performed simultaneously. Retrospectively, significantly lower transfusion rates were seen [33].

In conclusion, the clamp-crush technique seems to be superior especially as it is an easy method and comes with low costs. It might be regarded as the golden standard with which new devices or methods should be compared. However, high-quality randomized controlled trials are missing. Besides, the surgeon's experience plays an important role. Because of this, one could say that the method of choice is the clamp-crush technique and other techniques can be applied, or combined, dependent on the surgeon's experience and preference.

### **3.3. Malignant lesions**

The liver has an important function as a detoxifying organ and due to the anatomical position in the abdomen; most gastro-intestinal organs drain their venous blood to the liver. This makes the liver a frequent location of metastases from a variety of intra-abdominal and sometimes even extra-peritoneal primary cancers. Also, primary cancers can arise in the liver. Of these the hepatocellular carcinoma is the most common malignancy. With a normal functioning liver, resection is the treatment of choice for most of these malignant lesions.

Metastases of colorectal origin are the most frequent malignant lesions in the liver. With nearly one million new cases diagnosed each year and around half a million deaths annually, colorectal cancer is one of the most common causes of cancer related death worldwide [38]. Over half of the patients with colorectal cancer will develop liver metastases [39]. Moreover, up to 25% of these patients present with liver metastases at the same time of the primary diagnosis [40]. Colorectal liver metastases may therefore be regarded as a major health problem [39].

The only chance of long-term survival in patients with liver metastases is provided by resection of these liver metastases, with 5-year survival rates around 30-40% [41]. Until recently, however, few patients with malignant liver lesions were considered for partial hepatic resection. Due to the restricted resection criteria, only 10-20% of the patients with malignant lesions were selected. Palliative chemotherapy was offered for the remaining proportion of the patients, resulting in a median survival of 6-12 months [8, 42]. Due to the increased safety of liver surgery, liver resection is currently also used for other metastases such as neuroendocrine tumours [43], sarcoma's [44], melanoma [45-47], gastric cancer [48-50] and breast cancer [48, 51, 52].

The selection criteria for liver resections were initially fairly strict: unilobar distribution, less than four metastases, maximum tumour size of 5 cm and tumour free margin of 1 cm. These resection criteria have been evaluated over time and have gradually been abandoned, as these appeared to be not as important as previously assumed [53-55]. Even in elderly patients and poor prognostic groups, complete tumour resection results in a good long-term survival [56-58].

In the treatment of malignant liver disease, many improvements have been developed in recent years: new surgical strategies for safer resection (including two stage hepatectomy and portal vein embolisation), more effective chemotherapy, and additional techniques such as local ablation therapies to increase possible curative treatment [59-64]. The combination of these developments has led to an important progress and has resulted in more patients being considered suitable for liver resection to almost 30% [62]. Better survival of patients with primary or metastatic liver cancer has been reported in recent years and liver resection is currently the only potentially curative treatment option.

### **3.4. Benign hepatic lesions**

In case of malignant hepatic disease, surgical resection is currently felt justified despite a morbidity and mortality, which may be as high as 42% and 6.5% respectively [1, 3, 65-67]. In case of benign hepatic disease, however, this decision remains more difficult. Due to the widespread use of imaging modalities such as ultrasonography, computed tomography (CT), and magnetic resonance imaging (MRI), benign hepatic masses are increasingly being identified. However, not all benign hepatic tumours require resection. Careful diagnosis with contrast enhanced CT or MRI needs to be performed first. Benign lesions can grossly be divided in solid and non-solid lesions (table 2).

Solid lesions	Symptoms	Treatment
Hepatocellular adenoma	Variable: from incidental finding to severe abdominal pain and shock in case of rupture	<5cm watchful waiting, stop oral contraceptives ≥5cm resection to prevent rupture and malignant degeneration
Focal Nodular Hyperplasia	Mostly incidental finding	Surgery rarely indicated
Angiomyolipoma	Mostly incidental finding	Surgery rarely indicated
Nodular regenerative hyperplasia	Mostly asymptomatic, should be considered in patients with clinical signs of portal hypertension without evidence of cirrhosis	No proven treatment
Non-solid lesions		
Simple hepatic cyst	Variable: from incidental finding to abdominal pain	Surgery indicated only in case of symptoms
Biliary cystadenoma	Variable: from incidental finding to abdominal pain	Surgery may be indicated (malignant degeneration)
Biliary hamartoma	None	Surgery not indicated
Cavernous haemangioma	Variable, depending on size	Surgery rarely indicated
Hydatid disease	Variable: from incidental finding to severe abdominal pain and shock	Surgery indicated to relieve symptoms and to prevent rupture

**Table 2.** Most important benign liver lesions, divided in solid and non-solid lesions.

### 3.5. History of hepatic surgery for benign lesions

The first case of surgical resection for a presumably benign liver tumour was described in 1886 by Antonio Lius in Italy [68]. Lius was the assistant of Theodore Escher who excised a pedunculated adenoma with the size of a child's head (15.5 cm in greatest diameter) from the left liver lobe of 67-year-old woman. An uncontrollable bleeding was encountered during the operation and the patient died several hours following surgery. The German surgeon Von Langenbuch was the first to perform a successful resection of a benign solid pedicled liver mass weighing 370 gram of the left liver in a 30-year-old woman who complained of abdominal discomfort in the years following her first child's birth in 1887 [69]. Postoperatively, secondary haemorrhage occurred due to a bleeding hilar vessel. This was managed at re-exploration and the patient survived. The course of symptoms and events in the latter case suggests the tumour was most likely a hepatocellular adenoma.

It is nowadays well established that small benign lesions compatible with a diagnosis of haemangioma, focal nodular hyperplasia (FNH) or hepatocellular adenomas (HCAs) are no indication for liver resection [53]. Hepatocellular adenomas are considered the most important, albeit uncommon, benign tumours of the liver that mostly occur in women. They are known for their increased risk of haemorrhage and malignant transformation into hepatocellular carcinoma (HCC) if size exceeds 5 cm. Therefore, surgical resection of HCAs is recommended

for larger lesions [53, 54]. Focal nodular hyperplasia and haemangiomas have not been regarded as potentially premalignant lesions.

The first case report of malignant transformation of a HCA was published in 1981 by Tesluk and Lawrie [70]. The patient was a 34-year-old female with a large HCA measuring 16 cm in diameter. She first presented with tumour haemorrhage after which her oral contraceptive use was discontinued and the tumour subsequently shrank to a stable 5 cm. Three years later a partial hepatectomy was performed when the tumour had reverted to its size at first presentation. Histological analysis revealed a well-differentiated HCC. The patient died of sepsis five weeks postoperatively.

Foster and Berman were the first to report an estimated risk of malignant transformation in 1994, as they found a frequency of 13% in their series of 13 patients [71]. More recently, a systematic review of the literature of the past 40 years containing more than 1600 HCAs worldwide identified 68 reports of malignant transformation resulting in an overall frequency of 4.2% among all adenoma cases [72]. Nowadays several other risk factors for malignant potential of HCAs apart from size have been identified [73-84]. These are listed in table 3.

Risk factors
Tumour size $\geq$ 5 cm
Presence of $\beta$ -catenin activating mutation
Presence of liver cell dysplasia within HCA
Patients with glycogen storage disease
History of androgen or anabolic steroid intake
Male sex
Obesity/overweight

**Table 3.** Risk factors for malignant transformation of hepatocellular adenomas.

### 3.6. Surgical treatment of hepatocellular adenomas

The identification of several risk factors for malignant potential of HCAs in recent years, provides better indications for surgical treatment of these presumably benign tumours. Also, the Bordeaux adenoma tumour markers (table 4) have greatly contributed to the subtype classification of HCAs and have given clearer insights into the pathological mechanism of malignant evolution [79]. More recently, MR imaging techniques have been shown to be of value in identifying premalignant HCAs [85, 86]. These advances in risk factor stratification, together with tumour subtyping prior to hepatic surgery, might aid in selecting HCAs at high risk of malignant evolution for surgical resection. Unfortunately, routine performance of biopsy of an HCA has not been implemented yet owing to the risk of sampling error, bleeding, needle-track tumour seeding and the difficult interpretation of  $\beta$ -catenin staining. However, a change towards a more stringent selection process in the near future is inevitable and may

imply a major reduction of the number of liver resections, and thus morbidity and even mortality, in a selected group of predominantly young patients.

HCA type	Frequency (%)	Malignant transformation	Markers
$\beta$ -catenin activated	10-15	Yes	$\beta$ -catenin+/GS+
HNF1 $\alpha$ inactivated	30-50	Rarely	LFABP-
Inflammatory	35	No	SAA+/CRP+
Unclassified	5-10	No	None

CRP, C-reactive protein; GS, glutamine synthetase; HCA, hepatocellular adenoma; HNF1 $\alpha$ , hepatocyte nuclear factor 1 $\alpha$ ; LFABP, liver-fatty acid binding protein; SAA, serum amyloid A; +, positive; -, negative. Table adapted with permission from Stoot et al. 2010 [72].

**Table 4.** Types of HCAs and their immunohistochemical markers.

Concerning the management of ruptured HCAs, emergency surgery is associated with high morbidity and mortality rates [73, 85]. Although this treatment is still suggested by some authors [86], the maximally invasive therapy of immediate liver resection has gradually been abandoned. Many liver surgeons prefer conservative management of ruptured HCAs consisting of immediate resuscitation with laparotomy and gauze packing [74]. Selective arterial embolisation for ruptured HCAs may be a valuable alternative although it has rarely been reported [55, 63, 70, 72, 87].

In conclusion, hepatic resection for benign tumours is mainly reserved for HCAs at risk for malignant evolution or haemorrhage. Advances in pathological subtyping, radiological imaging and risk stratification have led to new insights and aid in justifying hepatic resection in a more selected population.

#### 4. Advances in the surgical treatment of benign cystic lesions: hydatid disease

Surgical treatment may also be indicated for infectious diseases of the liver such as benign lesions caused by the parasitic infection called Echinococcosis. Human echinococcosis is a zoonosis caused by larval forms (metacestodes) of Echinococcus (E.) tapeworms found in the small intestine of carnivores. Two species are of clinical importance – *E. granulosus* and *E. multilocularis* – causing cystic echinococcosis (CE) and alveolar echinococcosis (AE) in humans, respectively [87]. Besides, in the beginning of the 20<sup>th</sup> century the so-called neotropical echinococcosis species *E. oligarthrus* and *E. vogeli* were discovered to cause polycystic echinococcosis (PE). *E. vogeli* causes disease similar to AE and *E. oligarthrus* has a more benign character [88]. Echinococcosis is endemic worldwide in large sheep-raising areas including Africa, the Mediterranean region of Europe, the Middle East, Asia, South America, Australia and New Zealand [89-96]. Human cystic echinococcosis is one of the most neglected parasitic

diseases in the world. In many endemic regions most infected patients suffer considerably from this disease, usually because of the lack of treatment possibilities due to poor infrastructure and shortage of equipment and drugs [97, 98]. The incidence of hydatid disease in Western industrial nations is relatively low [93, 94, 99]. Migration and travelling has led to an increase of the prevalence of this disease in Northern parts of Europe and North America [96, 100]. The diagnosis of hepatic echinococcosis can be made with a combination of patients' symptoms, liver imaging findings, detection of Echinococcus-specific antibodies and microscopic or molecular examination of cyst fluid. The most frequent site for cystic lesions is the liver (60% of patients), followed by the lungs in about 20% of patients. The remaining lesions are found throughout the body [92, 95, 99, 101, 102].

The natural course of this infection can be extremely variable [101]. The hepatic cysts can spontaneously collapse, calcify or even disappear. These patients can remain symptom-free for years. It is not uncommon that the cysts are detected when abdominal imaging is performed for a different reason. On the other hand, the cysts can also steadily grow about 1-3 cm in diameter per year [96, 99]. They do not tend to grow infiltratively or destructively, but pressure or mass effects of the cysts can displace healthy tissue and organs. Thus, most patients present with symptoms from mechanical effects on other organs or structures, which can lead to pain in the upper right quadrant, hepatomegaly and jaundice, depending on the location and nature of the cysts [91, 96, 99, 101]. Infection of the cysts can result in sepsis and/or the formation of liver abscesses. A feared complication is rupture of hepatic hydatid cysts into the peritoneal cavity. This can result in serious anaphylaxis, sepsis and/or peritoneal dissemination. The content of the ruptured cyst can disseminate into the biliary tract leading to cholangitis or cholestasis, but also to the pleurae or lungs leading to pleural hydatidosis or bronchial fistula, respectively [91, 92, 102].

#### **4.1. History of hepatic surgery for hydatid disease**

Hydatid disease was already recognized by Hippocrates more than two millennia ago. This benign disease has been shown to act as a malignant disease as it has the tendency to disseminate to other organs and to cause a devastating disease sometimes even leading to death. The serious effects of this disease were known in the late 1880s, when Loretta performed the first left lateral liver resection for echinococcosis in Bologna [8]. Last years many developments have improved the course of hydatid disease: better medical therapy, improved surgical procedures and the development of minimally invasive techniques.

From a historical perspective, the main treatment option of hepatic hydatid disease was the open surgical approach with side packing and several radical or more conservative surgical techniques [96, 99]. This terminology in literature might be confusing. Conservative surgery means that tissue-sparing techniques are used; the hydatid cyst is evacuated and the pericyst is left in situ, while in radical procedures both the cyst and the pericyst are removed. The most common conservative techniques include simple tube drainage, marsupialization, capitonnage, deroofting, partial cystectomy or open or closed total cystectomy with or without omentoplasty. Conservative operations have good results regarding blood loss and length of hospital stay [103, 104]. In contrast, the cyst content and the entire pericystic membrane are

removed in radical procedures; a total pericystectomy or liver resection (hemihepatectomy or lobectomy) is performed [90, 94, 101, 104].

In surgical interventions of hepatic hydatid cysts, complete removal of the parasite should be performed. Also, prevention of intraoperative spilling of cyst content and saving healthy hepatic tissue is of utmost importance [91, 93, 96]. Spilling could not only lead to recurrence of hydatid disease, it could also lead to anaphylactic shock before the introduction of the antihelminthic drugs. Therefore, surgeons need to perform procedures with a focus on safe and complete exposure of the cyst, safe decompression of the cyst, safe evacuation of the cyst contents, sterilization of the cyst, treatment of biliary complications and management of the remaining cyst cavity. Especially in non-endemic areas where the number of operations is low, the technique needs to be safe and easily reproducible, with a low complication rate. In the former century, hydatid disease was operated with a high risk of morbidity and recurrence, possibly due to the spilling of cyst content during the operation. In the 1970s, Saidi developed a special cone, which was frozen to the cyst in order to reduce the risk of spilling cyst contents. This cone also simplified the disinfection of the cyst cavity [105]. Recently, this old treatment, also known as the 'frozen seal method', was evaluated in a non-endemic area and it was concluded to be an effective surgical treatment for hepatic hydatid disease [104]. In this retrospective study, 112 consecutive patients were treated surgically with the 'frozen seal' method for hydatid disease between 1981 and 2007. Recurrence rate was observed in 9 (8%) patients and morbidity occurred in twenty patients (17.9%). More importantly, no mortality was observed in this study of more than 25 years of surgically treated 'echinococcosis'. It was concluded that this surgical method used in the past century was still safe and effective in the new millennium. This technique is especially useful in non-endemic areas as it provides high efficacy and low morbidity rates.

Apart from the 'frozen-seal method', surgical treatment options may vary from conservative treatment (cystectomy) to radical treatment (complete open resection) to laparoscopic techniques. The debate on best surgical treatment is still ongoing: should this be conservative surgery or radical surgery in which the cyst is totally removed including the pericyst by total pericystectomy or partial hepatectomy or should it be the open or laparoscopic approach [101, 102].

#### **4.2. Percutaneous treatments**

With the introduction of antihelminthic drugs, new possibilities for treatment arose. By using this medication, the risk of anaphylaxis became smaller and percutaneous treatments were developed. One of these treatments for hydatid disease is PAIR: Percutaneous Aspiration, Injection and Re-aspiration. In a recent meta-analysis of operative versus non-operative treatment (PAIR) of hepatic echinococcosis [92], PAIR plus chemotherapy proved to be superior compared to surgery. The meta-analysis showed that PAIR was associated with improved efficacy, lower rates of morbidity, mortality, disease recurrence and shorter hospital stay [92].

In conclusion, the main treatment options for hepatic cystic echinococcosis are threefold: medical therapy, surgery and percutaneous drainage (Puncture Aspiration Injection and Reaspiration, also known as PAIR) or a combination of these therapies [91, 92, 100]. In the last

revision of the WHO IWGE it was stated that surgery remains the cornerstone of treatment of hydatid disease, since it has the potential to remove the hydatid cyst and lead to complete cure. However, it is advised to evaluate surgical treatment carefully against other less invasive options such as percutaneous interventions. [88]

## 5. Improvements in pre-operative planning

An important way to improve the outcome in liver surgery is to prevent liver resection related complications. One of the main feared complications in liver surgery remains postresectional liver failure. This major complication may occur if the extent of tumour involvement requires major liver resection (3 or more segments), leaving a small postoperative remnant liver [3, 106, 107]. Due to impaired liver function this may even result in mortality. Obviously, limiting the liver resection, in order to leave enough liver remnant volume for proper function of the liver, can prevent this. However, major hepatectomies are performed increasingly often, mainly because indications for liver resection are continuously being extended. Former contraindications such as bilobar disease, number of metastases and even extrahepatic disease have been abandoned gradually and compromised liver function may be expected after aggressive induction chemotherapy. Consequently, postoperative remnant liver volume and function have become the main determinants of respectability [108-110]. In order to improve outcome in extended resections and thus to prevent postoperative liver failure after liver resection, a reliable volumetric assessment of the part of the liver to be resected as well as future residual liver volume should be a critical part of preoperative evaluation particularly. The safety of liver resection may increase if an estimate of minimal remnant liver volume is obtained via CT-volumetry [106, 111].

The utility of existing professional image-processing software is often limited by costs, lack of flexibility and specific hardware requirements such as coupling to a CT-scanner. In addition, the intended operation should be known to the investigator to predict the remnant liver volume accurately and requires the expertise of a liver surgeon. Therefore, CT-volumetry has hitherto been a multidisciplinary modality requiring the efforts of dedicated surgeons and radiologists and expensive software. Prospective CT-volumetric analysis of the liver on a Personal Computer performed by the operating surgeon in patients undergoing major liver would greatly enhance this preoperative assessment. ImageJ is a free, open-source Java-based image processing software programme developed by the National Institute of Health (NIH) and may be used for this purpose [112]. OsiriX<sup>®</sup> is Apple's version for image analysis and has been tested for CT volumetry of the liver [113]. It is also a freely available, user-friendly software system, which can be used for virtual liver resections and volumetric analysis [113].

As more major liver resections are performed, it is becoming more important to perform liver volumetry. Recently, these two open source image processing software packages were investigated to measure prospectively the remnant liver volume in order to reduce the risk of post-resectional liver failure. Volumes of total liver, tumour and future resection specimen of the included patients were measured preoperatively with ImageJ and OsiriX by two surgeons



and a surgical trainee [114]. Results were compared with the actual weights of resected specimens and the measurements of the radiologist using professional CT scanner-linked Aquarius iNtuition® software. It was concluded that the prospective hepatic CT-volumetry with ImageJ or OsiriX® was reliable and can be accurately used on a Personal Computer by non-radiologists. ImageJ and OsiriX® yield results comparable to professional radiological software iNtuition®.

## 6. Minimally invasive surgery

To minimize the damage of treatment, laparoscopic surgery was introduced to avoid large incisions for many gastrointestinal operations in the previous century. After the first laparoscopic cholecystectomy in 1987 [115], the number of indications for this minimally invasive approach increased. The outcome has encouraged surgeons to develop a laparoscopic technique for many procedures including liver resections [116]. Although this type of surgery is technically more demanding and thereby time-consuming [117, 118], it proved to be beneficial for patients with less pain and better recovery compared to open liver surgery [119-121].

### 6.1. The history of laparoscopic surgery

The fundamentals of laparoscopic surgery were laid down in the early twentieth century when the German surgeon Kelling reported on the endoscopic visualization of the peritoneal cavity in an anesthetized dog using a Nitze cystoscope (1887) in 1902 [122]. Following the introduction of endoscopic inspection of the abdominal contents in an animal model, fellow countryman Jacobeus started experimenting with laparoscopy in human cadavers as well as living humans. In 1911 he reported on 80 laparoscopic examinations of the abdominal cavity [123, 124]. In the years thereafter the laparoscopic approach was enhanced with the introduction of illumination techniques, advancement in lens systems, the use of more than one single trocar and induction of pneumoperitoneum (Goetze and Veress). The era of therapeutic laparoscopy was then born, making it possible to minimize damage of treatment and avoid large incisions for many gastrointestinal operations. However, it was not until 1987 that the first laparoscopic cholecystectomy was performed [115].

At first, liver surgery was thought to be unsuitable for laparoscopic techniques since it might impose the risk of gas embolisms and major blood loss during transection of the liver. Also, sceptics pointed out the suspected risk of trocar site metastases in skin incisions. Gradually, as some expert centres progressively reported feasibility and safety, it became more popular.

This novel approach for liver resections was introduced during the 1990s. At first the procedure was only used for diagnostic laparoscopies and liver biopsies, later indications were extended to fenestration of liver cysts and anatomic liver resections. In 1992, Gagner et al. reported the first laparoscopic wedge resection of the liver. Only three years later, Cuesta et al. were the first to perform two cases of limited laparoscopic liver surgery of segment II and IV in the Netherlands [125]. The first laparoscopic left lateral bisegmentectomy of the liver was performed by the group of Azagra [126]. Since then, several studies have reported the feasibility

and safety of laparoscopic resections for liver tumours in centres with extensive experience in both hepatobiliary surgery and laparoscopic surgery [116, 117, 127-130].

However, after its introduction, laparoscopic liver resection remained challenging because of the difficulties concerning safe mobilization and exposure of this fragile and heavy organ. Therefore, in the beginning only superficial and peripheral lesions in anterolateral segments were selected for the laparoscopic approach. In recent times, centres with extensive experience in laparoscopy and hepatic surgery have also performed major hepatic resections laparoscopically with satisfactory outcomes. Importantly, no evidence of a compromised oncological clearance in laparoscopic liver resection has hitherto been found [120]

## **6.2. Advantages of the laparoscopic technique**

The laparoscopic approach is said to have shifted the pain of the patient to the surgeon, as the latter had to obtain new operative skills and more demanding techniques. In fact laparoscopic surgery is a totally different concept of surgery. The conventional three-dimensional field is inherently two-dimensional, and the tactile feedback is impaired as compared to open surgery. Moreover, a full ambidexterity is required, as well as the skills to manipulate fragile structures with long instruments under minimal tactile feedback. Also, the surgeon becomes even more dependent on his team and instruments, as he will need experienced assistance for traction and camerawork and needs to trust the material even more compared to open surgery. For patients the most important presumed advantages of the laparoscopic procedure are reduced blood loss [119, 120], less postoperative pain [118, 127, 131], earlier functional recovery [127, 130], shorter postoperative hospital stay [118, 120, 121, 127, 130-132] and improved cosmetic aspects [127, 130]. Reoperations are reported to be easier due to reduced adhesions [127, 130-132]. Also, open-close procedures with large incisions can be avoided if peritoneal metastases are detected at laparoscopy.

However, up till now no randomised controlled trials comparing the open and laparoscopic liver resection technique have been reported. This may well be one of the reasons why many surgeons remained reluctant to incorporate this new laparoscopic approach. The currently available evidence is primarily based on case-series and identifies a technique that is reproducible with limited morbidity and mortality. In a consensus statement on laparoscopic liver resections, Buell J et al [133] concluded that resection of segments 2 and 3 by the laparoscopic approach should be the standard of care. In that same year a large international study reported comparable encouraging results concerning the superiority of laparoscopic liver resections in terms of complications from 109 patients: the complication rate was only 12% and there were no perioperative deaths [134]. Median hospital length of stay was 4 days. Negative margins were achieved in 94.4% of patients.

Overall survival rates and disease-free survival rates for the entire series were 50% and 43% at 5-year respectively. It was concluded that laparoscopic liver resection for colorectal metastases was safe, feasible and comparable to open liver resection for both minor and major liver resections in oncologic surgery. This is confirmed in a recent meta-analysis on short and long-term outcomes after laparoscopic and open resection. This study included a total of 26 studies, incorporating a population of 1678 patients [135]. Although laparoscopic liver resections

resulted in longer operation time, most endpoints were superior for the laparoscopic approach compared with open resection, including reduced blood loss, portal clamp time, overall and liver specific complications, ileus and length of hospital stay. As for the long-term outcomes, no difference was found for oncologic outcomes between the laparoscopic and open surgical techniques. Therefore, it was concluded that the laparoscopic liver resection was a feasible alternative to open surgery in experienced hands [135].

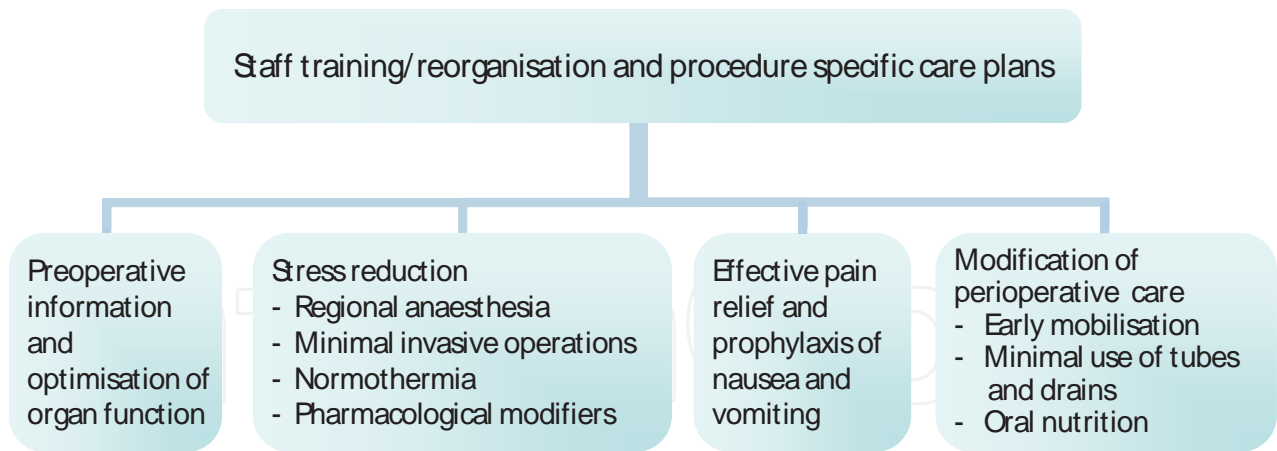
## 7. Enhanced Recovery After Surgery (ERAS) or fast-track liver surgery

Another recent development in elective liver surgery is the introduction of Enhanced Recovery After Surgery (ERAS) programmes, also referred to as fast track perioperative care. These multimodal enhanced recovery programmes proved to be beneficial in open colonic and liver surgery [136, 137]. The multimodal recovery programme is evidence based and combines several interventions in perioperative care to reduce the stress response and organ dysfunction with a focus on enhancing recovery [137, 138]. In patients undergoing colorectal surgery, the ERAS<sup>®</sup> programme enabled earlier recovery and consequently shorter length of hospital stay [137-140]. Also, reduction of postoperative morbidity in patients undergoing intestinal resection was reported [141-144]. In other fields of elective surgery similar programmes have also shown a reduction in hospital stay of several days [145, 146].

One of the pioneers of the fast track colonic surgery is the Danish surgeon Henrik Kehlet. He treated 60 consecutive patients with colonic resection in a fast track surgery programme and reported a median postoperative hospital stay of 2 days. At that time, patients undergoing a colonic resection usually required 5 to 10 days postoperative hospital stay [147, 148]. Previously, he stressed the importance of a multimodal approach in order to improve rehabilitation after surgery (figure 6) [149]. This rehabilitation programme after surgery combined a number of interventions to reduce stress of the surgical intervention, risk of organ dysfunction and loss of functional capacity. Stress induced organ dysfunction, pain, nausea and vomiting, ileus, hypoxemia and sleep disturbances, immobilisation and semi-starvation had to be reduced.

Factors were identified that contribute to postoperative functional deterioration. These were actually traditional postoperative care principles such as use of drains, nasogastric tubes, fasting regimes and bed rest. Kehlet initiated a multimodal programme that abandoned the traditional care principles and introduced innovations such as: carbohydrate loading before surgery, regional anaesthetic techniques, maintenance of normal temperature during surgery, minimally invasive or laparoscopic surgical techniques, optimal treatment of postoperative pain and prophylaxis of nausea and vomiting [139, 150]. This programme improved postoperative recovery, physical performance and pulmonary function and reduced hospital length of stay [142].

In collaboration with Kehlet, the Enhanced Recovery After Surgery (ERAS) group was initiated to investigate the perioperative care in four other hospitals (Royal Infirmary, Edinburgh, UK, The Karolinska Institutet at Ersta Hospital, Stockholm, Sweden, the University Hospital of Northern Norway, Tromsø, Norway and Maastricht University Medical Centre) [151]. Thus,



**Figure 6.** Multimodal interventions may lead to a reduction in postoperative morbidity and improved recovery. [149] Figure adapted with kind permission from Kehlet *et al.* 1997.

with Kehlet's programme as a starting point, a new evidence based programme was developed incorporating different aspects leading to faster recovery. Preoperative counselling, perioperative intravenous fluid restriction, optimal pain relief preferably without the use of opioid analgesia, early oral nutrition, enforced mobilisation, no nasogastric tubes and no drains are the key elements of this protocol (figure 7). Since the colonic programme showed improvements in recovery, the liver surgeons of the ERAS<sup>®</sup> group (Maastricht, Edinburgh and Tromsø) set up an ERAS-programme for every patient undergoing open liver resection [136] ([www.erassociety.org](http://www.erassociety.org)).

So far, the ERAS programmes have shown promising results with respect to improved recovery and outcome in open elective colorectal and liver surgery [136, 137]. One of the first studies on ERAS for liver surgery showed that the majority of patients treated within this multimodal enhanced recovery programme tolerated fluid within four hours of surgery and a normal diet one day after surgery. As an effect of the accelerated functional recovery, these patients were discharged two days earlier than the patients treated with traditional care, without significant differences in readmission, morbidity and mortality rates [136].

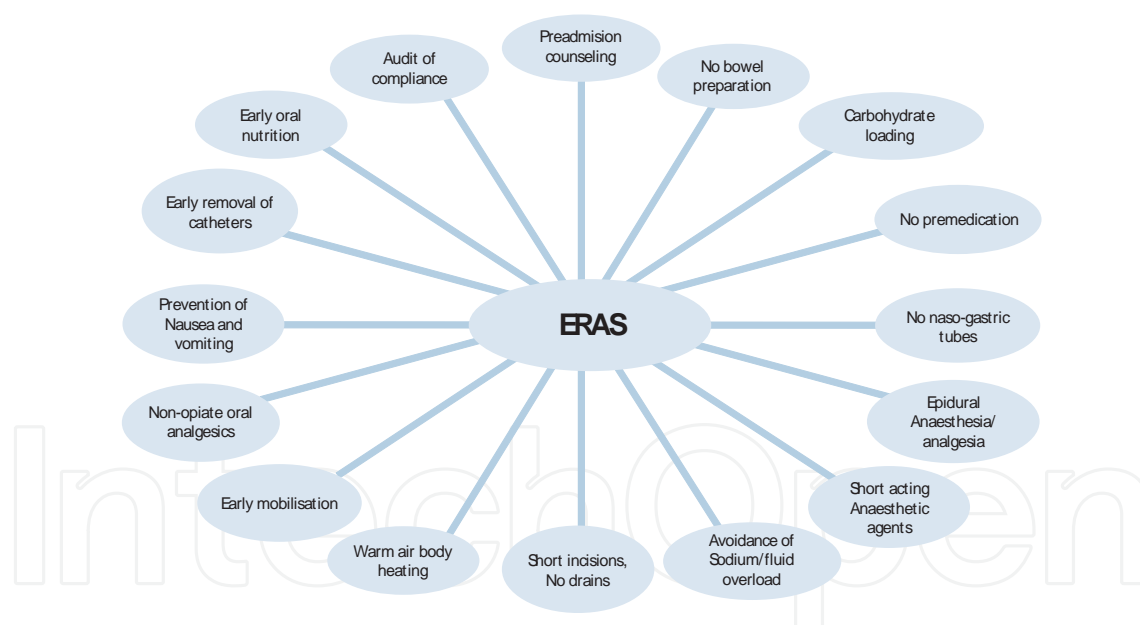
These results were confirmed in a recent systematic review including seven studies on fast-track programmes for hepatopancreatic resections, incorporating more than 550 patients treated in fast track setting [152]. This study showed that the primary hospital stay was reduced significantly after the introduction of a multimodal perioperative care programme for open liver surgery [152]. Moreover, there were no significant differences in rates of readmission, morbidity and mortality.

### 7.1. Synergy of ERAS and laparoscopic liver surgery

For solid tumours in the liver, the open approach for resection is gradually replaced by the laparoscopic technique in many expert centres worldwide. The results, mostly from cohort studies, suggest benefits with notably shorter postoperative stay [120]. Recently, the added value of a fast-track ERAS-programme in laparoscopic liver surgery specifically has been

elucidated [153]. A group consisting of patients undergoing laparoscopic liver resections in an ERAS-setting was compared with historical data from consecutive laparoscopic liver resections performed either in that same centre before the introduction of the ERAS-programme or in other major liver centres in the Netherlands performing laparoscopic liver surgery in a traditional perioperative care programme.

- A significant difference with a median of two days in time to full functional recovery was observed between the ERAS-treated group and the traditional care group. The difference in median hospital length of stay (LOS) of two days between these two groups did not attain significance. The authors suggested that it was probably due to the small number of patients in this multicentre pilot-study. Apart from faster functional recovery in patients in the enhanced recovery group, this study also showed reduced blood loss in this group.
- As from a historical perspective, this multicentre fast-track laparoscopic liver resection study was the first study to explore the effect of ERAS and laparoscopic surgery. This small study suggests that a multimodal enhanced recovery programme for laparoscopic liver surgery is feasible, safe and may lead to accelerated functional recovery and reduction in length of hospital stay. With these findings it may be concluded that the additional effect of ERAS leads to an improvement of liver surgery and outcome.



**Figure 7.** Important elements of the Enhanced Recovery After Surgery programme. [138] Figure adapted with kind permission from Fearon *et al.* 2005.

## 8. Recent developments in hepatic malignancies

As for the recent developments in the treatment of liver diseases, these can be mainly divided into surgical and non-surgical treatment modalities. Developments in surgical treatment can

be divided in true surgical and perioperative care improvements. The focus is on the surgical treatments in this chapter, but some thoughts will also be spent on the non-surgical treatment modalities, an interesting and expanding field of expertise.

For malignant liver tumours, the majority of which are colorectal liver metastases, the main concern is the resectability if colorectal cancer is diagnosed. Colorectal cancer is one of the most common causes of cancer related death worldwide [38] and more than half of patients with colorectal cancer will develop liver metastases [39]. Unfortunately, only 20% of the patients can be treated with surgical resection of these liver metastases [154]. The remaining 80% of the patients present with lesions, which are not suitable for a safe resection. This can be caused by large diameters of the lesions, location of the lesion near vascular and biliary structures and extrahepatic disease. Also, the number of lesions can be the cause of non-resectability: resection can only be carried out safely if 25-30% of functioning liver remains after resection [155]. The non-surgical treatment by means of chemotherapy for the patients with unresected liver metastases has proven very successful in decreasing the size and number of liver lesions. It was shown that new chemotherapy regimens could change the previously unresectable liver metastases into resectable liver disease [156]. With neoadjuvant chemotherapy more patients with colorectal liver metastases can be offered a treatment with curative intent [156]. It was concluded that neoadjuvant chemotherapy enables liver resection in some patients with initially unresectable colorectal metastases. Long-term survival proved to be similar to that reported for a priori surgical candidates [56]. As for the future perspective of chemotherapy, neoadjuvant treatment will improve curability and long-term survival for selected patients.

Other non-surgical therapies for malignant liver disease are external irradiation (whole liver irradiation) [157, 158], stereotactic liver irradiation [159-162] and injectable small radioactive particles that irradiate the tumours within the liver (e.g. Yttrium-90(<sup>90</sup>Y) radio-embolisation [163, 164], radioactive holmium microspheres [165, 166]). These modalities may have curative potential but future studies have to be awaited. Another attractive field of development are the thermal ablative therapies for unresectable liver metastases. These ablative thermal therapies can be used either percutaneously or in adjunct with surgery and have shown to decrease focal liver lesions [167-170]. Microwave ablation is a tumour destruction method to treat patients with unresectable liver lesions [169]. It can be used with a single insertion of the probe and it was shown to be a safe and effective method for treating unresectable hepatic tumours, with a low rate of local recurrence [170]. Overall survival is comparable to alternative ablation modalities [169].

### **8.1. Future perspectives**

As for surgical treatments, different treatment strategies have been developed to increase the number of patients suitable for surgery as described earlier. Current research has focussed on improving resectability in terms of the quantity of resected liver tissue, but at the same time studies focussed on reducing perioperative distress in patients undergoing liver resections by multimodal perioperative treatment protocols and minimally invasive surgery. Since the introduction of laparoscopic liver surgery in 1992, more liver resections have been performed with this minimally invasive approach for primary and secondary malignant liver lesions [129,

134, 153]. For future perspectives, some gain might be expected from even less invasive modalities as the first reports on single incision laparoscopic resections have been presented [171-173]. Also, a two-stage laparoscopic approach for malignant liver disease and the robotic approach for liver resections have been published [174-176].

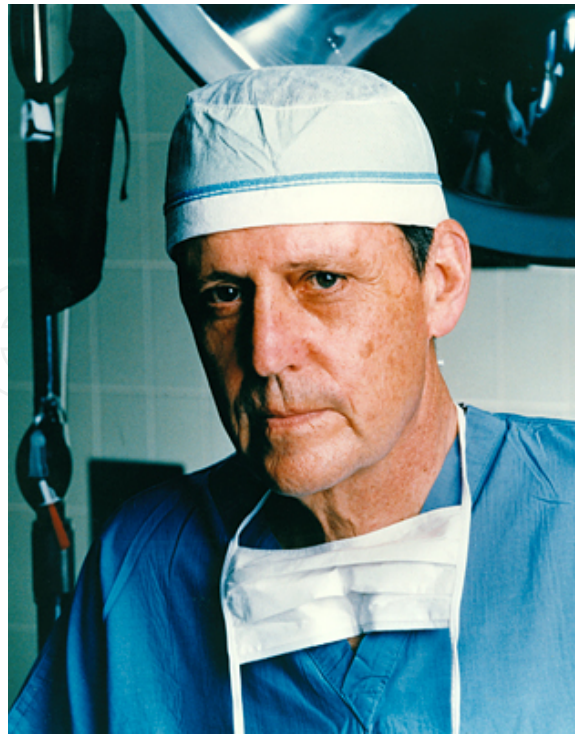As discussed previously in this chapter, the recent developments in liver surgery include the introduction of laparoscopic surgery and enhanced recovery programmes, which focus on improvement of postoperative recovery and/or shorter hospital length of stay. A significantly accelerated recovery after open liver resection was previously reported if patients were managed within a multimodal ERAS protocol. Median hospital length of stay was reduced from 8 to 6 days (25%) [136]. Moreover, since there was a delay between recovery and discharge of the patients a further reduction of stay should be possible. Regarding the results of previous, non-randomised randomized studies and case series, it seems that laparoscopic left lateral liver sectionectomy is associated with shorter hospital length of stay, less postoperative pain, better quality of life and a faster recovery [177]. In most trials aiming at a reduction of hospital length of stay, surgery and/or perioperative management are not standardised. No randomised trials have hitherto been reported to study the added value of ERAS and/or laparoscopy for liver surgery. There is a need for a randomised controlled trial covering these aspects of improving the recovery and outcome of liver surgery.

## 9. Liver transplantation

Liver transplantation surgery is one of the main advances in hepatic surgery. Until recently, it was considered to be too complex, since artificial organ support, like haemodialysis in renal failure, was considered impossible. The term liver transplantation was first used in an article of Welch (NY, USA) in 1955 [178]. The first experimental liver transplantation surgery was performed on animals (dogs) in the 1950s and 1960s by Starzl (Denver, USA, figure 8) and Moore (Boston, USA). These transplantations failed as a result of the stagnation of blood in the mesenterial vessels and a lack of blood flow to the heart after clamping the inferior vena cava. Methods for a venovenous bypass to the superior vena cava were developed, whereupon transplantation seemed to be realizable. Despite the fact that immunosuppressive drugs became available at that time, most grafts were rejected though. As a result, only a few dogs survived [178-181].

### 9.1. The history of liver transplantation in humans

In 1963 the first three orthotopic liver transplantations in humans were performed by Starzl and colleagues. All livers came from non-heart beating donors (NHBDs). Although the first transplantation was performed in one session, the second and third took two sessions; the first session was designated for the preparation of the removal of the liver from the donor and in the second session the liver was removed and transplanted in the recipient after the donor died. In the donor patient extracorporeal perfusion was performed via the femoral vein and artery. The structures in the hepatoduodenal ligament were cut through and the liver was



**Figure 8.** Thomas E. Starzl (1926).

taken out with the vena cava. In the recipient the liver was taken out likewise and a venovenous bypass was made to circumvent the hemodynamic effects of clamping the vena cava [182]. Immunosuppressive therapy, by ways of azathioprine and prednisone, was applied since these drugs were proven to be effective in renal transplantation [183]. The first patient was a three-year-old boy with biliary atresia who died during the operation due to haemorrhage, the second and third patient were adult males suffering from liver cancer who died 7 and 22 days postoperative, as a result of lung embolism [182]. Starzl then decided to take a break to have a period of reflection. Four years later, in 1967, he decided to try again and he then performed the first successful liver transplantation with a one-year-survival [184].

Infections were frequently occurring complications [185]. The most important complication of these early transplantations however, was severe blood loss. This was caused by manipulation of abdominal veins which had been under great pressures due to chronic liver diseases [179]. The first orthotopic liver transplantation in Europe was performed in Cambridge in 1968 by Calne [186]. In the same year consensus was achieved concerning the concept of cerebral death. From that moment on, heart-beating donation with donor organs originating from heart beating, brain dead donors was possible [184]. Nowadays the above described venovenous bypass has been abandoned in many centres in Europe. Since the beginning of the 1990's most centres use the so called 'piggyback' technique. The liver is exposed from the vena cava after which the vena cava is partially clamped longitudinally. After the liver has been flushed with albumin to remove ischemic waste products, a side-to-side cavocaval anastomosis is made. In doing so, the hemodynamic stability of the patient is guaranteed. Then, the portal liaison is



made by an end-to-end anastomosis, the liver is perfused and the arterial anastomosis is made. Finally the biliary ducts are connected by way of end-to-end anastomosis and in case of sclerosis a Roux-en-Y-reconstruction [187, 188].

## 9.2. Immunosuppressive drugs

The discovery and appliance of immunosuppressive medication to prevent graft rejection has been an important development in transplantation surgery. Despite the fact that graft rejection has been a serious problem during the early years of liver transplantation, many transplanted patients survived more than 20 years as a result of this immunosuppressive therapy with an azathioprine-prednisone cocktail. Some time later, a third immunosuppressive drug, antilymphocyte-globulin (ALG), was added to the therapy [178, 189, 190]. Then Calne discovered the possibility to use cyclosporin A, a calcineurin inhibitor, as an immunosuppressive drug [191]. After cyclosporine A was first used in renal transplantations in 1980 [192], it was then applied in liver transplantation and the one-year-survival rate in liver transplantation turned out to have increased to 80% [193]. Currently Tacrolimus (FK 506), also a calcineurin inhibitor, is recommended [194-197]. A detailed overview of the development and the working mechanisms of immunosuppressive drugs is beyond the scope of this chapter.

## 9.3. Split liver transplantation

The concept of liver transplantation has been developed gradually, which made it a widely accepted treatment with an increasing number of indications and good survival rates. This caused a shortage of donor organs, especially among children, and long waiting lists. New techniques had to be developed to answer to this growing demand. In 1984 Bismuth developed the reduced-size adult liver transplantation; an adult left lobe was transplanted into a child. This is a unique method, only applicable in liver transplantation surgery because of its segmental anatomy with independently functioning parts [198]. Further development of segmental liver surgery resulted in the split liver transplantation (SLT); the donor liver is splitted, the left part (segment 2 and 3 with the common hepatic duct and common hepatic artery) is transplanted into a child and the right part (segment 1, 4-7 with the vena cava) into an adult. In the recipient of the left liver part, the vena cava is preserved and an anastomosis is made with the left hepatic vein. The other anastomoses are made in the usual way. In the recipient of the right liver part, an anastomosis is made between the right hepatic artery of the donor liver and the common hepatic artery of the recipient by means of a saphenous vein interposition graft. Two intrahepatic biliary ducts are connected with the jejunum through a Roux-en-Y loop, the other anastomosis are executed in the usual way [199]. There are two ways of splitting the liver, in situ and ex situ, both with its (dis)advantages. The main disadvantage of in situ splitting is a longer operation time and therefore the need for a haemodynamically stable patient. Splitting ex situ on the other hand, is done in blood vacuum. The time of cold ischemia is longer and it is harder to distinguish structures from each other. Hence, strict donor selection is essential and there is a trend to only select donors <50 years or who are haemodynamically stable. Bile spill is reported as the most common complication. Other complications are an insufficient hepatic artery, portal vein thrombosis, intra-abdominal haemorrhage and

gastro-intestinal bleeding. Mortality rates of 11% have been reported [200, 201]. In Europe, in 2003, 89% of all liver transplantations consisted of full-size transplantations, 4% of SLT's and 5% of reduced-liver transplantations. In specialized centres, the survival rates of these techniques are comparable to the survival rates of regular transplantation [202].

#### **9.4. Living-donor liver transplantation (LDLT)**

In 1987 Raia (Brazil) developed the living-donor liver transplantation (LDLT) from an adult into a child. The operation itself was successful, but the recipient child died due to a transfusion reaction [203]. The first successful LDLT from mother to son with a left liver lobe was performed in Australia by Strong [204] after which this method was refined by many other pioneers. It is a very difficult operation technique in which precise knowledge of the anatomy is a prerequisite. Because of a great shortage of donor organs in Asia, most experience with the LDLT was gained there. Innovative surgery was the only possibility to tide over this shortage. These techniques seemed to be effective; waiting-list-related mortality among children was reduced to almost 0% [205, 206]. Since Fan (Honk Kong) introduced the adult-to-adult living liver transplantation with a hemi-liver (dependent on the size of donor and recipient either the right or left lobe is transplanted) in 1997, the availability of donor livers for adults increased [207].

The main advantage of LDLT is limitation of warm ischemia because operations can be planned simultaneously [208]. The results of LDLT are comparable to those of regular (orthotopic) liver transplantation. According to the Japanese Liver Transplantation Society the 5-year-survival rate in adults is 69%. In children this rate is significantly higher with 83% [205]. In the USA the reported survival rate in adults is 80% [209]. In Europe, a 5-year-survival of 75% (80% in children, 66% in adults) between 1991 and 2001 was reported [202, 205]. In Europe, in 2003, only 1.6% of all liver transplantations consisted of LDLT [202].

The main disadvantages of this technique are the potential complications in the healthy donor and the psychological impact [189, 210]. The number of postoperative complications in donors is reported to be 20%. Worldwide 10 (0.15%) donor deaths have been reported. The mortality rate in Europe, in 2010, was 0.2% (6/2906) [211]. The critical period for death and primary dysfunction is within 6 months from the operation. In a graft too small for the recipient, dysfunction will develop with hyperbilirubinemia, ascites and liver function failure resulting in coagulation disorders and renal failure. A graft which is too big for the recipient will result in necrosis because of shortage in blood supply. Besides good patient selection, proper calculation to determine the correct graft size has to be done to prevent these complications [189, 205].

#### **9.5. Improving survival**

In 1997 the Institute of Medicine (USA) declared NHBD-organs to be medically effective and ethically acceptable [178]. From that time on, the trend exists to use NHBD- and marginal organs (livers with steatosis) again to tide over the shortage of donor organs and shorten the waiting lists. Marginal livers are associated with primary non-function [212]. The main

problem of NHBD's is the prolonged period of warm ischemia. A distinction between controlled NHBD's (Maastricht type I and II) and uncontrolled NHBD's (Maastricht type III and IV) is made. Controlled NHBD's provide organs with less chance on ischemic damage and a greater chance on good post-transplantation function. In this group of patients a controlled end of vital support takes place after which a circulation stop occurs. In most cases the patient is already in the operation theatre with a transplantation team on site. This way, the time of warm ischemia is minimalised. In uncontrolled NHBD's a non-foreseen circulation stop occurs, usually before arrival in the hospital, possibly followed by resuscitation. A variable period of warm ischemia occurs with a higher chance on complications [212, 213]. Cold ischemia causes damage of sinusoidal endothelial cells and warm ischemia of hepatocytes [214]. Besides, warm ischemia intensifies the effects of cold ischemia and predisposes for a higher incidence of ischemic biliary structures both on the short and the long term. In such cases, re-transplantation might be needed [215]. Since the University of Wisconsin Solution, introduced in 1988, has become the golden standard for cooling donor organs and the maximum period of cold ischemia has been limited to 12 hours, ischemic damage due to cold ischemia has been reduced drastically with increased graft survival [202]. However, as a consequence of warm ischemia graft survival is lower in NHBD's compared to heart-beating donors with a 3-year-survival of 63.3% versus 72.1%. The risk of primary non-function is also significantly higher among NHBD's: 11.8% versus 6.4% [189, 216]. For this reason NHBD's can be used to overcome organ shortage, on condition that strict criteria are maintained: strict donor (<60 years) and recipient (haemodynamically stable and not intubated) selection, minor warm (<30 minutes) and cold (<8 hours) ischemia, no extensive steatosis of the donor liver and the use of at most one inotropic drug (to prevent hypotension and thus hypoperfusion) [212].

With the gradual progression in surgical competences, management of postoperative complications and the development of immunosuppressive drugs to prevent graft rejection, liver transplantation has nowadays become a widely accepted treatment for an increasing number of indications and it has become the golden standard for patients with irreversible decompensated chronic liver failure (e.g. as a result of cirrhosis or hepatocellular cancer) and acute liver failure (e.g. as a result of hepatic viruses or intoxication with medication). In the early days cancer was the most common indication for liver transplantation. In Europe, however, with 50% the most important indication for liver transplantation was cirrhosis (of which 24% was caused by a virus (especially Hepatitis C) and 18% by alcohol abuse), followed by pathology of the biliary tract (13%), primary liver tumours (10%), of which hepatocellular cancer is the most common, and acute liver failure (9%), with fulminant viral hepatitis as the most important cause. The most important indications in children are biliary atresia (56%) and metabolic diseases (21%) [202]. Due to the development of different methods and techniques, organ shortage has been reduced and waiting lists have been shortened. Hence, one can conclude that liver transplantation is a recent and very important advancement, which has expanded in a short time. It is a perfect example of modern and innovative medical practice, in which the challenge remains to find solutions to new problems time after time.

## Author details

J.H.M.B. Stoot<sup>1,2,3\*</sup>, R.J.S. Coelen<sup>1,2</sup>, J.L.A. van Vugt<sup>2</sup> and C.H.C. Dejong<sup>1,4</sup>

\*Address all correspondence to: [jan@stoot.com](mailto:jan@stoot.com)

1 Department of Surgery, Maastricht University Medical Centre, Maastricht, The Netherlands

2 Department of Surgery, Orbis Medical Centre, Sittard, The Netherlands

3 Department of Surgery, Atrium Medical Centre, Heerlen, The Netherlands

4 NUTRIM School for Nutrition, Metabolism and Toxicology, Maastricht University Medical Centre, Maastricht, The Netherlands

## References

- [1] Poon, R. T, et al. Improving perioperative outcome expands the role of hepatectomy in management of benign and malignant hepatobiliary diseases: analysis of 1222 consecutive patients from a prospective database. *Ann Surg*, (2004). discussion 708-10., 698-708.
- [2] Cescon, M, et al. Trends in perioperative outcome after hepatic resection: analysis of 1500 consecutive unselected cases over 20 years. *Ann Surg*, (2009). , 995-1002.
- [3] Jarnagin, W. R, et al. Improvement in perioperative outcome after hepatic resection: analysis of 1,803 consecutive cases over the past decade. *Ann Surg*, (2002). discussion 406-7., 397-406.
- [4] Tsao, J. I, et al. Trends in morbidity and mortality of hepatic resection for malignancy. A matched comparative analysis. *Ann Surg*, (1994). , 199-205.
- [5] Foster, J. H. History of liver surgery. *Arch Surg*, (1991). , 381-387.
- [6] Glisson, F. *Anatomia Hepatis*. London, England, 1654.
- [7] Cantlie, J. On a new arrangement of the right and left lobes of the liver. *J. Anat. Physiol.*, (1898). , 4-9.
- [8] Hardy, K. J. Liver surgery: the past 2000 years. *Aust N Z J Surg*, (1990). , 811-817.
- [9] Pringle, J. H. V. Notes on the Arrest of Hepatic Hemorrhage Due to Trauma. *Ann Surg*, (1908). , 541-549.
- [10] Couinaud, C. *Le Foie. Etudes anatomiques et chirurgicales*. Paris: Masson, (1957).

- [11] Guyton, A, & Hall, J. The liver as an organ, in Textbook of Medical Physiology(1996). Philadelphia: WB Saunders. , 883-888.
- [12] Taub, R. Liver regeneration: from myth to mechanism. *Nat Rev Mol Cell Biol*, (2004). , 836-847.
- [13] van de Poll M.C., et al., Effect of major liver resection on hepatic ureagenesis in humans. *Am J Physiol Gastrointest Liver Physiol*, (2007). , G956-G962.
- [14] Lortat-jacob, J. L, Robert, H. G, & Henry, C. Excision of the right lobe of the liver for a malignant secondary tumor]. *Arch Mal Appar Dig Mal Nutr*, (1952). , 662-667.
- [15] Foster, J. H, & Berman, M. M. Solid liver tumors. *Major Probl Clin Surg*, (1977). , 1-342.
- [16] Ekberg, H, et al. Determinants of survival in liver resection for colorectal secondaries. *Br J Surg*, (1986). , 727-731.
- [17] Adson, M. A, et al. Resection of hepatic metastases from colorectal cancer. *Arch Surg*, (1984). , 647-651.
- [18] Simmonds, P. C, et al. Surgical resection of hepatic metastases from colorectal cancer: a systematic review of published studies. *Br J Cancer*, (2006). , 982-999.
- [19] Iwatsuki, S, Shaw, B. W, & Jr, T. E. Starzl, Experience with 150 liver resections. *Ann Surg*, (1983). , 247-253.
- [20] Bismuth, H, Houssin, D, & Castaing, D. Major and minor segmentectomies "reglees" in liver surgery. *World J Surg*, (1982). , 10-24.
- [21] Bismuth, H. Surgical anatomy and anatomical surgery of the liver. *World J Surg*, (1982). , 3-9.
- [22] Tung, T. T. Les resections majeures et mineures du foie. Paris: Masson, (1979).
- [23] Billingsley, K. G, et al. Segment-oriented hepatic resection in the management of malignant neoplasms of the liver. *J Am Coll Surg*, (1998). , 471-481.
- [24] Fan, S. T, et al. Hepatectomy for hepatocellular carcinoma: toward zero hospital deaths. *Ann Surg*, (1999). , 322-330.
- [25] Farid, H, & Connell, T. O. Hepatic resections: changing mortality and morbidity. *Am Surg*, (1994). , 748-752.
- [26] Poon, R. T. Recent advances in techniques of liver resection. *Surg Technol Int*, (2004). , 71-77.
- [27] Adam, R, et al. Patients with initially unresectable colorectal liver metastases: is there a possibility of cure? *J Clin Oncol*, (2009). , 1829-1835.
- [28] Tomlinson, J. S, et al. Actual 10-year survival after resection of colorectal liver metastases defines cure. *J Clin Oncol*, (2007). , 4575-4580.

- [29] Charny, C. K, et al. Management of 155 patients with benign liver tumours. *Br J Surg*, (2001). , 808-813.
- [30] Poon, R. T. Current techniques of liver transection. *HPB (Oxford)*, (2007). , 166-173.
- [31] Aragon, R. J, & Solomon, N. L. Techniques of hepatic resection. *J Gastrointest Oncol*, (2012). , 28-40.
- [32] Gurusamy, K. S, et al. Techniques for liver parenchymal transection in liver resection. *Cochrane Database Syst Rev*, (2009). , CD006880.
- [33] Palavecino, M, et al. Two-surgeon technique of parenchymal transection contributes to reduced transfusion rate in patients undergoing major hepatectomy: analysis of 1,557 consecutive liver resections. *Surgery*, (2010). , 40-48.
- [34] Pamecha, V, et al. Techniques for liver parenchymal transection: a meta-analysis of randomized controlled trials. *HPB (Oxford)*, (2009). , 275-281.
- [35] Rahbari, N. N, et al. Meta-analysis of the clamp-crushing technique for transection of the parenchyma in elective hepatic resection: back to where we started? *Ann Surg Oncol*, (2009). , 630-639.
- [36] Koo, B. N, et al. Hepatic resection by the Cavitron Ultrasonic Surgical Aspirator increases the incidence and severity of venous air embolism. *Anesth Analg*, (2005). table of contents., 966-970.
- [37] Rahbari, N. N, et al. Clamp-crushing versus stapler hepatectomy for transection of the parenchyma in elective hepatic resection (CRUNSH)--a randomized controlled trial (NCT01049607). *BMC Surg*, (2011). , 22.
- [38] Boyle, P, & Leon, M. E. Epidemiology of colorectal cancer. *Br Med Bull*, (2002). , 1-25.
- [39] Steele, G, & Jr, T. S. Ravikumar, Resection of hepatic metastases from colorectal cancer. Biologic perspective. *Ann Surg*, (1989). , 127-138.
- [40] Manfredi, S, et al. Epidemiology and management of liver metastases from colorectal cancer. *Ann Surg*, (2006). , 254-259.
- [41] Scheele, J, et al. Resection of colorectal liver metastases. *World J Surg*, (1995). , 59-71.
- [42] Thirion, P, et al. Modulation of fluorouracil by leucovorin in patients with advanced colorectal cancer: an updated meta-analysis. *J Clin Oncol*, (2004). , 3766-3775.
- [43] Mayo, S. C, et al. Surgical management of hepatic neuroendocrine tumor metastasis: results from an international multi-institutional analysis. *Ann Surg Oncol*, (2010). , 3129-3136.
- [44] Rehders, A, et al. Hepatic metastasectomy for soft-tissue sarcomas: is it justified? *World J Surg*, (2009). , 111-117.
- [45] Mondragon-sanchez, R, et al. Repeat hepatic resection for recurrent metastatic melanoma. *Hepatogastroenterology*, (1999). , 459-461.

- [46] Pawlik, T. M, et al. Hepatic resection for metastatic melanoma: distinct patterns of recurrence and prognosis for ocular versus cutaneous disease. *Ann Surg Oncol*, (2006). , 712-720.
- [47] Frenkel, S, et al. Long-term survival of uveal melanoma patients after surgery for liver metastases. *Br J Ophthalmol*, (2009). , 1042-1046.
- [48] Karavias, D. D, et al. Liver resection for metastatic non-colorectal non-neuroendocrine hepatic neoplasms. *Eur J Surg Oncol*, (2002). , 135-139.
- [49] Hirai, I, et al. Surgical management for metastatic liver tumors. *Hepatogastroenterology*, (2006). , 757-763.
- [50] Makino, H, et al. Indication for hepatic resection in the treatment of liver metastasis from gastric cancer. *Anticancer Res*, (2010). , 2367-2376.
- [51] Lermite, E, et al. Surgical resection of liver metastases from breast cancer. *Surg Oncol*, (2009). , e79-e84.
- [52] Sakamoto, Y, et al. Hepatic resection for metastatic breast cancer: prognostic analysis of 34 patients. *World J Surg*, (2005). , 524-527.
- [53] Figueras, J, et al. Effect of subcentimeter nonpositive resection margin on hepatic recurrence in patients undergoing hepatectomy for colorectal liver metastases. Evidences from 663 liver resections. *Ann Oncol*, (2007). , 1190-1195.
- [54] Figueras, J, et al. Surgical resection of colorectal liver metastases in patients with expanded indications: a single-center experience with 501 patients. *Dis Colon Rectum*, (2007). , 478-488.
- [55] Khatri, V. P, Petrelli, N. J, & Belghiti, J. Extending the frontiers of surgical therapy for hepatic colorectal metastases: is there a limit? *J Clin Oncol*, (2005). , 8490-8499.
- [56] Adam, R, et al. Five-year survival following hepatic resection after neoadjuvant therapy for nonresectable colorectal. *Ann Surg Oncol*, (2001). , 347-353.
- [57] Figueras, J, et al. Surgical treatment of liver metastases from colorectal carcinoma in elderly patients. When is it worthwhile? *Clin Transl Oncol*, (2007). , 392-400.
- [58] Adam, R, et al. Liver resection of colorectal metastases in elderly patients. *Br J Surg*, (2010). , 366-376.
- [59] De Haas, R. J, Wicherts, D. A, & Adam, R. Resection of colorectal liver metastases with extrahepatic disease. *Dig Surg*, (2008). , 461-466.
- [60] Adam, R, et al. Is hepatic resection justified after chemotherapy in patients with colorectal liver metastases and lymph node involvement? *J Clin Oncol*, (2008). , 3672-3680.
- [61] Wicherts, D. A, et al. Impact of portal vein embolization on long-term survival of patients with primarily unresectable colorectal liver metastases. *Br J Surg*, (2010). , 240-250.

- [62] Choti, M. A, et al. Trends in long-term survival following liver resection for hepatic colorectal metastases. *Ann Surg*, (2002). , 759-766.
- [63] De Haas, R. J, et al. R1 resection by necessity for colorectal liver metastases: is it still a contraindication to surgery? *Ann Surg*, (2008). , 626-637.
- [64] Wicherts, D. A, et al. Long-term results of two-stage hepatectomy for irresectable colorectal cancer liver metastases. *Ann Surg*, (2008). , 994-1005.
- [65] Virani, S, et al. Morbidity and mortality after liver resection: results of the patient safety in surgery study. *J Am Coll Surg*, (2007). , 1284-1292.
- [66] Dixon, E, et al. Mortality following liver resection in US medicare patients: does the presence of a liver transplant program affect outcome? *J Surg Oncol*, (2007). , 194-200.
- [67] Fong, Y, Blumgart, L. H, & Cohen, A. M. Surgical treatment of colorectal metastases to the liver. *CA Cancer J Clin*, (1995). , 50-62.
- [68] Lius, A. Di un adenoma del fegato. *Gazz delle cliniche*, (1886).
- [69] Langenbuch, C. Ein Fall von Resektion eines linksseitigen Schnurlappens der Leber. *Berl Klin Wochenschr*, (1888). , 37-38.
- [70] Tesluk, H, & Lawrie, J. Hepatocellular adenoma. Its transformation to carcinoma in a user of oral contraceptives. *Arch Pathol Lab Med*, (1981). , 296-299.
- [71] Foster, J. H, & Berman, M. M. The malignant transformation of liver cell adenomas. *Arch Surg*, (1994). , 712-717.
- [72] Stoot, J. H, et al. Malignant transformation of hepatocellular adenomas into hepatocellular carcinomas: a systematic review including more than 1600 adenoma cases. *HPB (Oxford)*, (2010). , 509-522.
- [73] Bioulac-sage, P, et al. Hepatocellular adenoma subtypes: the impact of overweight and obesity. *Liver Int*, (2012).
- [74] Dokmak, S, et al. A Single Center Surgical Experience of 122 Patients with Single and Multiple Hepatocellular Adenomas. *Gastroenterology*, (2009).
- [75] Franco, L. M, et al. Hepatocellular carcinoma in glycogen storage disease type Ia: a case series. *J Inherit Metab Dis*, (2005). , 153-162.
- [76] Gorayski, P, et al. Hepatocellular carcinoma associated with recreational anabolic steroid use. *Br J Sports Med*, (2008). discussion 75., 74-75.
- [77] Labrune, P, et al. Hepatocellular adenomas in glycogen storage disease type I and III: a series of 43 patients and review of the literature. *J Pediatr Gastroenterol Nutr*, (1997). , 276-279.
- [78] Velazquez, I, & Alter, B. P. Androgens and liver tumors: Fanconi's anemia and non-Fanconi's conditions. *Am J Hematol*, (2004). , 257-267.



- [79] Zucman-rossi, J, et al. Genotype-phenotype correlation in hepatocellular adenoma: new classification and relationship with HCC. *Hepatology*, (2006). , 515-524.
- [80] Anthony, P. P, Vogel, C. L, & Barker, L. F. Liver cell dysplasia: a premalignant condition. *J Clin Pathol*, (1973). , 217-223.
- [81] Ho, J. C, Wu, P. C, & Mak, T. K. Liver cell dysplasia in association with hepatocellular carcinoma, cirrhosis and hepatitis B surface antigen in Hong Kong. *Int J Cancer*, (1981). , 571-574.
- [82] Lee, R. G, Tsamandas, A. C, & Demetris, A. J. Large cell change (liver cell dysplasia) and hepatocellular carcinoma in cirrhosis: matched case-control study, pathological analysis, and pathogenetic hypothesis. *Hepatology*, (1997). , 1415-1422.
- [83] Su, Q, et al. Human hepatic preneoplasia: phenotypes and proliferation kinetics of foci and nodules of altered hepatocytes and their relationship to liver cell dysplasia. *Virchows Arch*, (1997). , 391-406.
- [84] Tao, L. C. Oral contraceptive-associated liver cell adenoma and hepatocellular carcinoma. Cytomorphology and mechanism of malignant transformation. *Cancer*, (1991). , 341-347.
- [85] Van Aalten, S. M, et al. Hepatocellular adenomas: correlation of MR imaging findings with pathologic subtype classification. *Radiology*, (2011). , 172-181.
- [86] Laumonier, H, et al. Hepatocellular adenomas: magnetic resonance imaging features as a function of molecular pathological classification. *Hepatology*, (2008). , 808-818.
- [87] Brunetti, E, Kern, P, & Vuitton, D. A. Expert consensus for the diagnosis and treatment of cystic and alveolar echinococcosis in humans. *Acta Trop*, (2010). , 1-16.
- [88] Tappe, D, Stich, A, & Frosch, M. Emergence of polycystic neotropical echinococcosis. *Emerg Infect Dis*, (2008). , 292-297.
- [89] Ammann, R. W, & Eckert, J. Cestodes. Echinococcus. *Gastroenterol Clin North Am*, (1996). , 655-689.
- [90] Dziri, C, Haouet, K, & Fingerhut, A. Treatment of hydatid cyst of the liver: where is the evidence? *World J Surg*, (2004). , 731-736.
- [91] Gourgiotis, S, et al. Surgical techniques and treatment for hepatic hydatid cysts. *Surg Today*, (2007). , 389-395.
- [92] Khuroo, M. S, et al. Percutaneous drainage compared with surgery for hepatic hydatid cysts. *N Engl J Med*, (1997). , 881-887.
- [93] Smego, R. A, et al. Percutaneous aspiration-injection-reaspiration drainage plus albendazole or mebendazole for hepatic cystic echinococcosis: a meta-analysis. *Clin Infect Dis*, (2003). , 1073-1083.
- [94] Smego, R. A, & Jr, P. Sebanego, Treatment options for hepatic cystic echinococcosis. *Int J Infect Dis*, (2005). , 69-76.

- [95] Yagci, G, et al. Results of surgical, laparoscopic, and percutaneous treatment for hydatid disease of the liver: 10 years experience with 355 patients. *World J Surg*, (2005). , 1670-1679.
- [96] Sayek, I, Tirnaksiz, M. B, & Dogan, R. Cystic hydatid disease: current trends in diagnosis and management. *Surg Today*, (2004). , 987-996.
- [97] Seimenis, A. Overview of the epidemiological situation on echinococcosis in the Mediterranean region. *Acta Trop*, (2003). , 191-195.
- [98] Menezes da Silva A.M., Human echinococcosis: a neglected disease. *Gastroenterol Res Pract*, 2010. (2010). p. pii: 583297.
- [99] Buttenschoen, K. and D. Carli Buttenschoen, Echinococcus granulosus infection: the challenge of surgical treatment. *Langenbecks Arch Surg*, (2003). , 218-230.
- [100] Khuroo, M. S, et al. Percutaneous drainage versus albendazole therapy in hepatic hydatidosis: a prospective, randomized study. *Gastroenterology*, (1993). , 1452-1459.
- [101] Dervenis, C, et al. Changing concepts in the management of liver hydatid disease. *J Gastrointest Surg*, (2005). , 869-877.
- [102] Guidelines for treatment of cystic and alveolar echinococcosis in humans WHO Informal Working Group on Echinococcosis. *Bull World Health Organ*, (1996). , 231-242.
- [103] Mueller, L, et al. A retrospective study comparing the different surgical procedures for the treatment of hydatid disease of the liver. *Dig Surg*, (2003). , 279-284.
- [104] Stoot, J. H, et al. More than 25 years of surgical treatment of hydatid cysts in a nonendemic area using the "frozen seal" method. *World J Surg*, (2010). , 106-113.
- [105] Saidi, F, & Nazarian, I. Surgical treatment of hydatid cysts by freezing of cyst wall and instillation of 0.5 per cent silver nitrate solution. *N Engl J Med*, (1971). , 1346-1350.
- [106] Schindl, M. J, et al. The value of residual liver volume as a predictor of hepatic dysfunction and infection after major liver resection. *Gut*, (2005). , 289-296.
- [107] Shoup, M, et al. Volumetric analysis predicts hepatic dysfunction in patients undergoing major liver resection. *J Gastrointest Surg*, (2003). , 325-330.
- [108] Shah, S. A, et al. Surgical resection of hepatic and pulmonary metastases from colorectal carcinoma. *J Am Coll Surg*, (2006). , 468-475.
- [109] Fusai, G, & Davidson, B. R. Management of colorectal liver metastases. *Colorectal Dis*, (2003). , 2-23.
- [110] Scheele, J, et al. Resection of colorectal liver metastases. What prognostic factors determine patient selection?. *Chirurg*, (2001). , 547-560.

- [111] Karlo, C, et al. CT- and MRI-based volumetry of resected liver specimen: comparison to intraoperative volume and weight measurements and calculation of conversion factors. *Eur J Radiol*, (2010). , e107-e111.
- [112] Dello, S. A, et al. Liver volumetry plug and play: do it yourself with ImageJ. *World J Surg*, (2007). , 2215-2221.
- [113] Van Der Vorst, J. R, et al. Virtual liver resection and volumetric analysis of the future liver remnant using open source image processing software. *World J Surg*, (2010). , 2426-2433.
- [114] Dello, S. A, et al. Prospective volumetric assessment of the liver on a personal computer by nonradiologists prior to partial hepatectomy. *World J Surg*, (2010). , 386-392.
- [115] Dubois, F, Berthelot, G, & Levard, H. Laparoscopic cholecystectomy: historic perspective and personal experience. *Surg Laparosc Endosc*, (1991). , 52-57.
- [116] Dagher, I, et al. Laparoscopic liver resection: results for 70 patients. *Surg Endosc*, (2007). , 619-624.
- [117] Descottes, B, et al. Laparoscopic liver resection of benign liver tumors. *Surg Endosc*, (2003). , 23-30.
- [118] Farges, O, et al. Prospective assessment of the safety and benefit of laparoscopic liver resections. *J Hepatobiliary Pancreat Surg*, (2002). , 242-248.
- [119] Morino, M, et al. Laparoscopic vs open hepatic resection: a comparative study. *Surg Endosc*, (2003). , 1914-1918.
- [120] Simillis, C, et al. Laparoscopic versus open hepatic resections for benign and malignant neoplasms--a meta-analysis. *Surgery*, (2007). , 203-211.
- [121] Kaneko, H. Laparoscopic hepatectomy: indications and outcomes. *J Hepatobiliary Pancreat Surg*, (2005). , 438-443.
- [122] Kelling, G. Ueber Oesophagoskopie, Gastroskopie und Kōlioskopie. *Münch Med Wochenschr*, (1902). , 21-24.
- [123] Jacobeus, H. Ueber die Möglichkeit die Zystoskopie bei Untersuchung seröser Höhlungen anzuwenden. *Münch Med Wochenschr*, (1910). , 2090-2092.
- [124] Jacobeus, H. Kurze Uebersicht über meine Erfahrungen mit der Laparo-thoraskopie. *Münch Med Wochenschr*, (1911). , 2017-2019.
- [125] Cuesta, M. A, et al. Limited laparoscopic liver resection of benign tumors guided by laparoscopic ultrasonography: report of two cases. *Surg Laparosc Endosc*, (1995). , 396-401.
- [126] Azagra, J. S, et al. Laparoscopic anatomical (hepatic) left lateral segmentectomy-technical aspects. *Surg Endosc*, (1996). , 758-761.

- [127] Cherqui, D, et al. Laparoscopic liver resections: a feasibility study in 30 patients. *Ann Surg*, (2000). , 753-762.
- [128] Cherqui, D. Laparoscopic liver resection. *Br J Surg*, (2003). , 644-646.
- [129] Dagher, I, et al. Laparoscopic hepatectomy for hepatocellular carcinoma: a European experience. *J Am Coll Surg*, (2010). , 16-23.
- [130] Gigot, J. F, et al. Laparoscopic liver resection for malignant liver tumors: preliminary results of a multicenter European study. *Ann Surg*, (2002). , 90-97.
- [131] Buell, J. F, et al. An initial experience and evolution of laparoscopic hepatic resectional surgery. *Surgery*, (2004). , 804-811.
- [132] Chang, S, et al. Laparoscopy as a routine approach for left lateral sectionectomy. *Br J Surg*, (2007). , 58-63.
- [133] Buell, J. F, et al. The international position on laparoscopic liver surgery: The Louisville Statement, 2008. *Ann Surg*, (2009). , 825-830.
- [134] Nguyen, K. T, et al. Minimally invasive liver resection for metastatic colorectal cancer: a multi-institutional, international report of safety, feasibility, and early outcomes. *Ann Surg*, (2009). , 842-848.
- [135] Mirnezami, R, et al. Short- and long-term outcomes after laparoscopic and open hepatic resection: systematic review and meta-analysis. *HPB (Oxford)*, (2011). , 295-308.
- [136] Van Dam, R. M, et al. Initial experience with a multimodal enhanced recovery programme in patients undergoing liver resection. *Br J Surg*, (2008). , 969-975.
- [137] Wind, J, et al. Systematic review of enhanced recovery programmes in colonic surgery. *Br J Surg*, (2006). , 800-809.
- [138] Fearon, K. C, et al. Enhanced recovery after surgery: a consensus review of clinical care for patients undergoing colonic resection. *Clin Nutr*, (2005). , 466-477.
- [139] Kehlet, H, & Wilmore, D. W. Multimodal strategies to improve surgical outcome. *Am J Surg*, (2002). , 630-641.
- [140] Wilmore, D. W, & Kehlet, H. Management of patients in fast track surgery. *Bmj*, (2001). , 473-476.
- [141] Basse, L, Madsen, J. L, & Kehlet, H. Normal gastrointestinal transit after colonic resection using epidural analgesia, enforced oral nutrition and laxative. *Br J Surg*, (2001). , 1498-1500.
- [142] Basse, L, et al. Accelerated postoperative recovery programme after colonic resection improves physical performance, pulmonary function and body composition. *Br J Surg*, (2002). , 446-453.

- [143] Delaney, C. P, et al. Prospective, randomized, controlled trial between a pathway of controlled rehabilitation with early ambulation and diet and traditional postoperative care after laparotomy and intestinal resection. *Dis Colon Rectum*, (2003). , 851-859.
- [144] Zutshi, M, et al. Randomized controlled trial comparing the controlled rehabilitation with early ambulation and diet pathway versus the controlled rehabilitation with early ambulation and diet with preemptive epidural anesthesia/analgesia after laparotomy and intestinal resection. *Am J Surg*, (2005). , 268-272.
- [145] Podore, P. C, & Throop, E. B. Infrarenal aortic surgery with a 3-day hospital stay: A report on success with a clinical pathway. *J Vasc Surg*, (1999). , 787-792.
- [146] Trondsen, E, et al. Day-case laparoscopic fundoplication for gastro-oesophageal reflux disease. *Br J Surg*, (2000). , 1708-1711.
- [147] Basse, L, et al. A clinical pathway to accelerate recovery after colonic resection. *Ann Surg*, (2000). , 51-57.
- [148] Schoetz, D. J, et al. Ideal" length of stay after colectomy: whose ideal? *Dis Colon Rectum*, (1997). , 806-810.
- [149] Kehlet, H. Multimodal approach to control postoperative pathophysiology and rehabilitation. *Br J Anaesth*, (1997). , 606-617.
- [150] Kehlet, H, & Dahl, J. B. Anaesthesia, surgery, and challenges in postoperative recovery. *Lancet*, (2003). , 1921-1928.
- [151] Nygren, J, et al. A comparison in five European Centres of case mix, clinical management and outcomes following either conventional or fast-track perioperative care in colorectal surgery. *Clin Nutr*, (2005). , 455-461.
- [152] Spelt, L, et al. Fast-track programmes for hepatopancreatic resections: where do we stand? *HPB (Oxford)*, (2011). , 833-838.
- [153] Stoot, J. H, et al. The effect of a multimodal fast-track programme on outcomes in laparoscopic liver surgery: a multicentre pilot study. *HPB (Oxford)*, (2009). , 140-144.
- [154] Adam, R. Chemotherapy and surgery: new perspectives on the treatment of unresectable liver metastases. *Ann Oncol*, (2003). Suppl 2: , ii13-ii16.
- [155] Abdalla, E. K, et al. Improving resectability of hepatic colorectal metastases: expert consensus statement. *Ann Surg Oncol*, (2006). , 1271-1280.
- [156] Adam, R, et al. Rescue surgery for unresectable colorectal liver metastases downstaged by chemotherapy: a model to predict long-term survival. *Ann Surg*, (2004). discussion 657-8., 644-657.
- [157] Yeo, S. G, et al. Whole-liver radiotherapy for end-stage colorectal cancer patients with massive liver metastases and advanced hepatic dysfunction. *Radiat Oncol*, (2010). , 97.

- [158] Krishnan, S, et al. Conformal radiotherapy of the dominant liver metastasis: a viable strategy for treatment of unresectable chemotherapy refractory colorectal cancer liver metastases. *Am J Clin Oncol*, (2006). , 562-567.
- [159] Scheffter, T. E, & Kavanagh, B. D. Radiation therapy for liver metastases. *Semin Radiat Oncol*, (2011). , 264-270.
- [160] Andolino, D. L, et al. Stereotactic body radiotherapy for primary hepatocellular carcinoma. *Int J Radiat Oncol Biol Phys*, (2011). , e447-e453.
- [161] Minn, A. Y, Koong, A. C, & Chang, D. T. Stereotactic body radiation therapy for gastrointestinal malignancies. *Front Radiat Ther Oncol*, (2011). , 412-427.
- [162] Chang, D. T, et al. Stereotactic body radiotherapy for colorectal liver metastases: a pooled analysis. *Cancer*, (2011). , 4060-4069.
- [163] Saxena, A, et al. Factors predicting response and survival after yttrium-90 radioembolization of unresectable neuroendocrine tumor liver metastases: a critical appraisal of 48 cases. *Ann Surg*, (2010). , 910-916.
- [164] Evans, K. A, et al. Survival outcomes of a salvage patient population after radioembolization of hepatic metastases with yttrium-90 microspheres. *J Vasc Interv Radiol*, (2010). , 1521-1526.
- [165] Jakobs, T. F, et al. Hepatic yttrium-90 radioembolization of chemotherapy-refractory colorectal cancer liver metastases. *J Vasc Interv Radiol*, (2008). , 1187-1195.
- [166] Smits, M. L, et al. Holmium-166 radioembolization for the treatment of patients with liver metastases: design of the phase I HEPAR trial. *J Exp Clin Cancer Res*, (2010). , 70.
- [167] Mayo, S. C, & Pawlik, T. M. Thermal ablative therapies for secondary hepatic malignancies. *Cancer J*, (2010). , 111-117.
- [168] Jiao, D, et al. Microwave ablation treatment of liver cancer with 2,450-MHz cooled-shaft antenna: an experimental and clinical study. *J Cancer Res Clin Oncol*, (2010). , 1507-1516.
- [169] Bhardwaj, N, et al. Microwave ablation for unresectable hepatic tumours: clinical results using a novel microwave probe and generator. *Eur J Surg Oncol*, (2009). , 264-268.
- [170] Martin, R. C, Scoggins, C. R, & McMasters, K. M. Safety and efficacy of microwave ablation of hepatic tumors: a prospective review of a 5-year experience. *Ann Surg Oncol*, (2009). , 171-178.
- [171] Kobayashi, S, et al. A single-incision laparoscopic hepatectomy for hepatocellular carcinoma: initial experience in a Japanese patient. *Minim Invasive Ther Allied Technol*, (2010). , 367-371.
- [172] Gaujoux, S, et al. Single-incision laparoscopic liver resection. *Surg Endosc*, (2010). , 1489-1494.

- [173] Patel, A. G, et al. Video. Single-incision laparoscopic left lateral segmentectomy of colorectal liver metastasis. *Surg Endosc*, (2010). , 649-650.
- [174] Giulianotti, P. C, et al. Robotic liver surgery: results for 70 resections. *Surgery*, (2010). , 29-39.
- [175] Jain, G, et al. Stretching the limits of laparoscopic surgery": two-stage laparoscopic liver resection. *J Laparoendosc Adv Surg Tech A*, (2010). , 51-54.
- [176] Machado, M. A, et al. Two-stage laparoscopic liver resection for bilateral colorectal liver metastasis. *Surg Endosc*, (2010). , 2044-2047.
- [177] Alkari, B, Owera, A, & Ammori, B. J. Laparoscopic liver resection: preliminary results from a UK centre. *Surg Endosc*, (2008). , 2201-2207.
- [178] Starzl, T. E, & Fung, J. J. Themes of liver transplantation. *Hepatology*, (2010). , 1869-1884.
- [179] Calne, R. Y. Early days of liver transplantation. *Am J Transplant*, (2008). , 1775-1778.
- [180] Starzl, T. E, et al. Reconstructive problems in canine liver homotransplantation with special reference to the postoperative role of hepatic venous flow. *Surg Gynecol Obstet*, (1960). , 733-743.
- [181] Moore, F. D, et al. Experimental whole-organ transplantation of the liver and of the spleen. *Ann Surg*, (1960). , 374-387.
- [182] Starzl, T. E, et al. HOMOTRANSPLANTATION OF THE LIVER IN HUMANS. *Surg Gynecol Obstet*, (1963). , 659-676.
- [183] Starzl, T. E, Marchioro, T. L, & Waddell, W. R. THE REVERSAL OF REJECTION IN HUMAN RENAL HOMOGRAFTS WITH SUBSEQUENT DEVELOPMENT OF HOMOGRAFT TOLERANCE. *Surg Gynecol Obstet*, (1963). , 385-395.
- [184] Starzl, T. E, et al. Orthotopic homotransplantation of the human liver. *Ann Surg*, (1968). , 392-415.
- [185] Schroter, G. P, et al. Infections complicating orthotopic liver transplantation: a study emphasizing graft-related septicemia. *Arch Surg*, (1976). , 1337-1347.
- [186] Calne, R. Y, et al. Liver transplantation in man. II. A report of two orthotopic liver transplants in adult recipients. *Br Med J*, (1968). , 541-546.
- [187] GooszenLeerboek chirurgie. Bohn Stafleu van Loghum, (2006). , 425-426.
- [188] Levi, D. M, et al. Liver transplantation with preservation of the inferior vena cava: lessons learned through 2,000 cases. *J Am Coll Surg*, (2012). discussion 698-9., 691-698.
- [189] Abbasoglu, O. Liver transplantation: yesterday, today and tomorrow. *World J Gastroenterol*, (2008). , 3117-3122.
- [190] Groth, C. G, et al. Historic landmarks in clinical transplantation: conclusions from the consensus conference at the University of California, Los Angeles. *World J Surg*, (2000). , 834-843.

- [191] Calne, R. Y, et al. Cyclosporin A initially as the only immunosuppressant in 34 recipients of cadaveric organs: 32 kidneys, 2 pancreases, and 2 livers. *Lancet*, (1979). , 1033-1036.
- [192] Starzl, T. E, et al. The use of cyclosporin A and prednisone in cadaver kidney transplantation. *Surg Gynecol Obstet*, (1980). , 17-26.
- [193] Starzl, T. E, et al. Liver transplantation with use of cyclosporin a and prednisone. *N Engl J Med*, (1981). , 266-269.
- [194] Starzl, T. E, et al. FK 506 for liver, kidney, and pancreas transplantation. *Lancet*, (1989). , 1000-1004.
- [195] Todo, S, et al. Liver, kidney, and thoracic organ transplantation under FK 506. *Ann Surg*, (1990). discussion 306-7., 295-305.
- [196] Grady, O, et al. Tacrolimus versus microemulsified ciclosporin in liver transplantation: the TMC randomised controlled trial. *Lancet*, (2002). , 1119-1125.
- [197] Haddad, E. M, et al. Cyclosporin versus tacrolimus for liver transplanted patients. *Cochrane Database Syst Rev*, (2006). , CD005161.
- [198] Bismuth, H, & Houssin, D. Reduced-sized orthotopic liver graft in hepatic transplantation in children. *Surgery*, (1984). , 367-370.
- [199] Pichlmayr, R, et al. Transplantation of a donor liver to 2 recipients (splitting transplantation)--a new method in the further development of segmental liver transplantation]. *Langenbecks Arch Chir*, (1988). , 127-130.
- [200] Ng, K. K, & Lo, C. M. Liver transplantation in Asia: past, present and future. *Ann Acad Med Singapore*, (2009). , 322-310.
- [201] Chen, C. L, & De Villa, V. H. Split liver transplantation. *Asian J Surg*, (2002). , 285-290.
- [202] Adam, R, et al. Evolution of liver transplantation in Europe: report of the European Liver Transplant Registry. *Liver Transpl*, (2003). , 1231-1243.
- [203] Raia, S, Nery, J. R, & Mies, S. Liver transplantation from live donors. *Lancet*, (1989). , 497.
- [204] Strong, R. W, et al. Successful liver transplantation from a living donor to her son. *N Engl J Med*, (1990). , 1505-1507.
- [205] Sugawara, Y, & Makuuchi, M. Living donor liver transplantation: present status and recent advances. *Br Med Bull*, (2005). , 15-28.
- [206] Broering, D. C, et al. Is there still a need for living-related liver transplantation in children? *Ann Surg*, (2001). discussion 721-2., 713-721.
- [207] Lo, C. M, et al. Adult-to-adult living donor liver transplantation using extended right lobe grafts. *Ann Surg*, (1997). discussion 269-70., 261-269.



- [208] Shimada, M, et al. Living-donor liver transplantation: present status and future perspective. *J Med Invest*, (2005). , 22-32.
- [209] Brown, R. S, et al. A survey of liver transplantation from living adult donors in the United States. *N Engl J Med*, (2003). , 818-825.
- [210] Malago, M, Burdelski, M, & Broelsch, C. E. Present and future challenges in living related liver transplantation. *Transplant Proc*, (1999). , 1777-1781.
- [211] Dutkowski, P, et al. Current and future trends in liver transplantation in Europe. *Gastroenterology*, (2010). e1-4., 802-809.
- [212] Busuttil, R. W, & Tanaka, K. The utility of marginal donors in liver transplantation. *Liver Transpl*, (2003). , 651-663.
- [213] White, S. A, & Prasad, K. R. Liver transplantation from non-heart beating donors. *BMJ*, (2006). , 376-377.
- [214] Ikeda, T, et al. Ischemic injury in liver transplantation: difference in injury sites between warm and cold ischemia in rats. *Hepatology*, (1992). , 454-461.
- [215] Abt, P, et al. Liver transplantation from controlled non-heart-beating donors: an increased incidence of biliary complications. *Transplantation*, (2003). , 1659-1663.
- [216] Abt, P. L, et al. Survival following liver transplantation from non-heart-beating donors. *Ann Surg*, (2004). , 87-92.