

# We are IntechOpen, the world's leading publisher of Open Access books Built by scientists, for scientists

**4,800**

Open access books available

**122,000**

International authors and editors

**135M**

Downloads

Our authors are among the

**154**

Countries delivered to

**TOP 1%**

most cited scientists

**12.2%**

Contributors from top 500 universities



**WEB OF SCIENCE™**

Selection of our books indexed in the Book Citation Index  
in Web of Science™ Core Collection (BKCI)

Interested in publishing with us?  
Contact [book.department@intechopen.com](mailto:book.department@intechopen.com)

Numbers displayed above are based on latest data collected.

For more information visit [www.intechopen.com](http://www.intechopen.com)



---

# Neurosarcoidosis

---

Mohankumar Kurukumbi, Preema Mehta,  
Isha Misra and Jayam-Trouth Annapurni

Additional information is available at the end of the chapter

<http://dx.doi.org/10.5772/55118>

---

## 1. Introduction

Sarcoidosis is an inflammatory granulomatous disease that can affect multiple organ systems, most commonly the lungs. It can also affect other organs, such as the nervous system and heart. Although the exact etiology of sarcoidosis is unknown, it involves the development of noncaseating granulomas in various organs. Noncaseating epithelioid granulomas are the pathological hallmarks of sarcoidosis and symbolize the inflammatory sign of the disease. Granulomas are structured masses of activated macrophages and their derivatives (i.e., epithelioid and giant cells). Neurosarcoidosis is a manifestation of sarcoidosis specifically in the nervous system. It is caused by inflammation and abnormal cell deposits in the central and/or peripheral nervous system, including the brain, spinal cord, or peripheral nerves. In this chapter, we intend to give a brief overview of the common neurologic manifestations of sarcoidosis, as well as diagnosis and management of these symptoms. We will also discuss management of steroid resistant neurosarcoidosis and atypical cases, as well as the overall prognosis of the disease.

## 2. Epidemiology

Cases of sarcoidosis have been reported worldwide, with a prevalence of approximately 10-80 cases per 100,000 in North America and Europe. Within the United States, African Americans have a greater lifetime risk of developing sarcoidosis than Caucasians (2.4% vs. 0.85%). Worldwide, females have a slightly greater risk of developing this disease. The incidence of sarcoidosis can be described as having a bimodal pattern, with most cases occurring between the ages of 20-40 years old and a second commonly affected group being females who are over the age of 50 [1].

About 5-16% of patients with sarcoidosis have neurologic involvement. The most frequent neurologic abnormality includes cranial and peripheral neuropathy, followed by mononeuropathy, myopathy, psychiatric disorders, cerebellar ataxia, hydrocephalus and papilledema. Neurosarcoidosis is also more prevalent in people of African descent and uncommon in people of Chinese descent and Southeast Asians. It is estimated that isolated neurosarcoidosis, without clinical evidence of systemic sarcoidosis, occurs in less than 1% of sarcoidosis patients [2].

### 3. History

Sarcoidosis was first clinically described in 1878 by a dermatologist Dr. Johnathan Hutchinson, who called the disease 'Mortimer's Malady', in reference to his patient's name [3]. He wanted to prove it by a biopsy but the patient refused. Then in 1889, Dr. Ernest Besnier described a similar case which he called lupus pernio due to the "chillblain-like swelling" of the nose and the lupus-vulgaris appearance of the fingers. Besnier also did not have histologic findings. It was not until 1892, Tenneson showed a second case of lupus pernio accompanied by histological studies showing lesions which contained epithelioid cells and giant cells. This was the first description of a sarcoid granuloma. Cesar Boeck, in 1899, called it 'Multiple Benign Sarkoid of Skin' which later gave birth to the term 'sarcoidosis'. A few years later, central nervous system (CNS) involvement by sarcoidosis was recognized in 1905 by Winkler [3].

### 4. Etiology and pathogenesis

Currently, the etiology of sarcoidosis is unknown. There have been hypotheses made including infectious agents, occupational/environmental factors, genetic factors and autoimmune disorders. There has not been a specific pathogen or pathogenic agent linked to the disease. One thought is that the inflammatory response in sarcoidosis, which is characterized by large numbers of activated macrophages and T lymphocytes bearing the CD4-helper phenotype, along with cytokine production is most consistent with a Th1-type immune response commonly triggered by antigens [4]. Also, seeing the trends of blacks and family clusters having increased numbers of the disease, there is a possibility that it is genetic. Many patients with sarcoidosis have the HLA-Factor B 8 (on chromosome 6) and DR 3. Another theory includes inhalation of an antigen that causes granulomatous inflammation in mediastinal lymph nodes and then extends to the lungs and other tissues.[5] Environmental factors involve infections, such as *Mycobacterium tuberculosis* and *Propionibacterium acnes* or *P. granulosum* and non-infectious environmental exposures, such as pesticides and insecticides, pine pollen, silica or talc, metal dusts, and man-made mineral fibers. Exposure to these factors can cause diseases that are histologically and clinically indistinguishable from sarcoidosis [4].

Neurosarcoidosis and multiple sclerosis can present with similar symptoms, such as optic neuritis. It is important to be able to differentiate the two, due to different responses to management and therapy. Since sarcoidosis is often a multisystem disease, solitary nervous-

system sarcoidosis is difficult to diagnose, which may delay treatment. The neurological symptoms make it a serious and commonly devastating complication of sarcoidosis [6].

## 5. Clinical manifestations of neurosarcoidosis

Neurosarcoidosis is seen in approximately 5% of sarcoidosis patients. Of these patients, some may have neurological findings on initial presentation, while others present de novo with neurological signs and symptoms that are consistent with a diagnosis of sarcoidosis [7]. Onset of neurosarcoidosis is most common in the fourth or fifth decades, and typically occurs after patients have had systemic symptoms for some time.

### 5.1. Cranial nerve findings

Cranial mononeuropathies frequently occur in neurosarcoidosis. In 2009, Joseph and Scolding conducted a study of 30 new cases of sarcoidosis, and reported cranial neuropathies in 80% of the patients [8]. The 7<sup>th</sup> cranial nerve is often affected. In fact, peripheral facial nerve palsy has been noted in up to 50% of patients with neurosarcoidosis. Oftentimes, Bell palsy is found to be the first manifestation of sarcoidosis and may resolve prior to development of additional symptoms. While facial neuropathies may arise due to basilar meningitis, some cases can be attributed to granulomatous inflammation of the extracranial part of the nerve [9].

Recent studies have found optic neuropathy to be a more common manifestation than previously thought. Patients can present with myriad complaints, ranging from blurry vision and papilledema to retro-bulbar pain and pupillary abnormalities. Palsies of the 8<sup>th</sup> cranial nerve also occur, leading to auditory and vestibular problems. Extra-ocular movements can become impaired due to involvement of the 3<sup>rd</sup>, 4<sup>th</sup>, and 6<sup>th</sup> cranial nerves. Olfactory involvement is rare, but has been reported in some cases, leading to anosmia and impaired taste.

### 5.2. Neuroendocrine manifestation

Neuroendocrine dysfunction is often seen in neurosarcoidosis patients, causing them to present with polyuria, changes in thirst, sleep, appetite, temperature, or libido. The hypothalamus and pituitary gland are also often affected, leading to thyroid, gonadal, and adrenal-related symptoms. This usually occurs as a result of subependymal granulomatous infiltration of the 3<sup>rd</sup> ventricle [9]. Other common symptoms include impaired taste and smell, slurred speech, weakness of trapezius and sternocleidomastoid muscles, and tongue deviation and atrophy. Additionally, carpal tunnel syndrome appears to occur more often in sarcoidosis patients, than in the general population. Occasionally, patients may present with the rare Heerfordt syndrome, characterized by fever, uveitis, parotid gland swelling, and facial nerve palsy [10].

### 5.3. Other CNS findings

In addition to the hypothalamus and pituitary gland, central nervous system involvement can affect the cerebral cortex, cerebellum, and occasionally the spinal cord. This can occur due to granulomatous inflammation in a perivascular pattern. Granulomas in various parts of the brain parenchyma have even been known to mimic brain tumors such as gliomas, meningiomas, and schwannomas.

Meningeal symptoms have been reported in a substantial number of patients; and can cause many of the aforementioned symptoms. Examination of the cerebrospinal fluid typically shows a mononuclear infiltrate and elevated protein. Cognitive and behavioral problems, along with focal neurologic deficits can occur. If the spinal cord is affected, myelopathies and radiculopathies can occur, and the cauda equina may be affected. Communicating and non-communicating hydrocephalus have been seen in these patients, and sudden death can also occur due to an acute obstruction of CSF flow. Seizures may also occur due to a variety of causes. They are seen as an initial finding in 10% of patients. Sudden death can also occur with involvement of the brainstem leading to central hypoventilation [9].

### 5.4. Peripheral neuropathy and myopathy

Patients can present with various types of peripheral neuropathies, including, but not limited to mononeuropathy, sensory polyneuropathy, and acute and chronic inflammatory polyneuropathy. Nerve biopsy typically shows noncaseating granulomas, but necrotizing vasculitis may also be seen. Muscle involvement is commonly seen, and is typically secondary to granulomas in the perimysium; however, only a very small number of patients are actually symptomatic. Onset of myopathy usually occurs later in the course of the disease, after involvement of other organ systems has already been noted. Patients may present with acute myopathy, in a similar manner to polymyositis, or may have more chronic symptoms with associated muscle wasting [9].

### 5.5. Atypical presentations

Sarcoidosis has been shown to affect many parts of both the central and peripheral nervous systems, and patients present with a wide variety of neurological symptoms. Often this can cause difficulties in making a diagnosis, as the reported symptoms are diverse and can mimic several other disease processes, such as Guillain-Barre Syndrome, Multiple Sclerosis, and even psychiatric diagnoses. In April 2012, Spiegel et al noted psychiatric manifestations, such as delirium and psychosis, in about 20% of neurosarcoidosis patients, which is equivalent to approximately 1% of all patients with sarcoidosis. Although this is a rare occurrence, these patients can experience striking auditory and visual hallucinations and delusions [11].

Patients have also reportedly presented with hypersomnolence and hyperphagia consistent with Kleine-Levine-Critchley syndrome [12]. In sum, as neurosarcoidosis can present in many ways, clinicians should maintain a high index of suspicion for the disease, especially in those patients who are not known to have sarcoidosis prior to presenting with neurological manifestations. The disease can be very severe and often life-threatening.

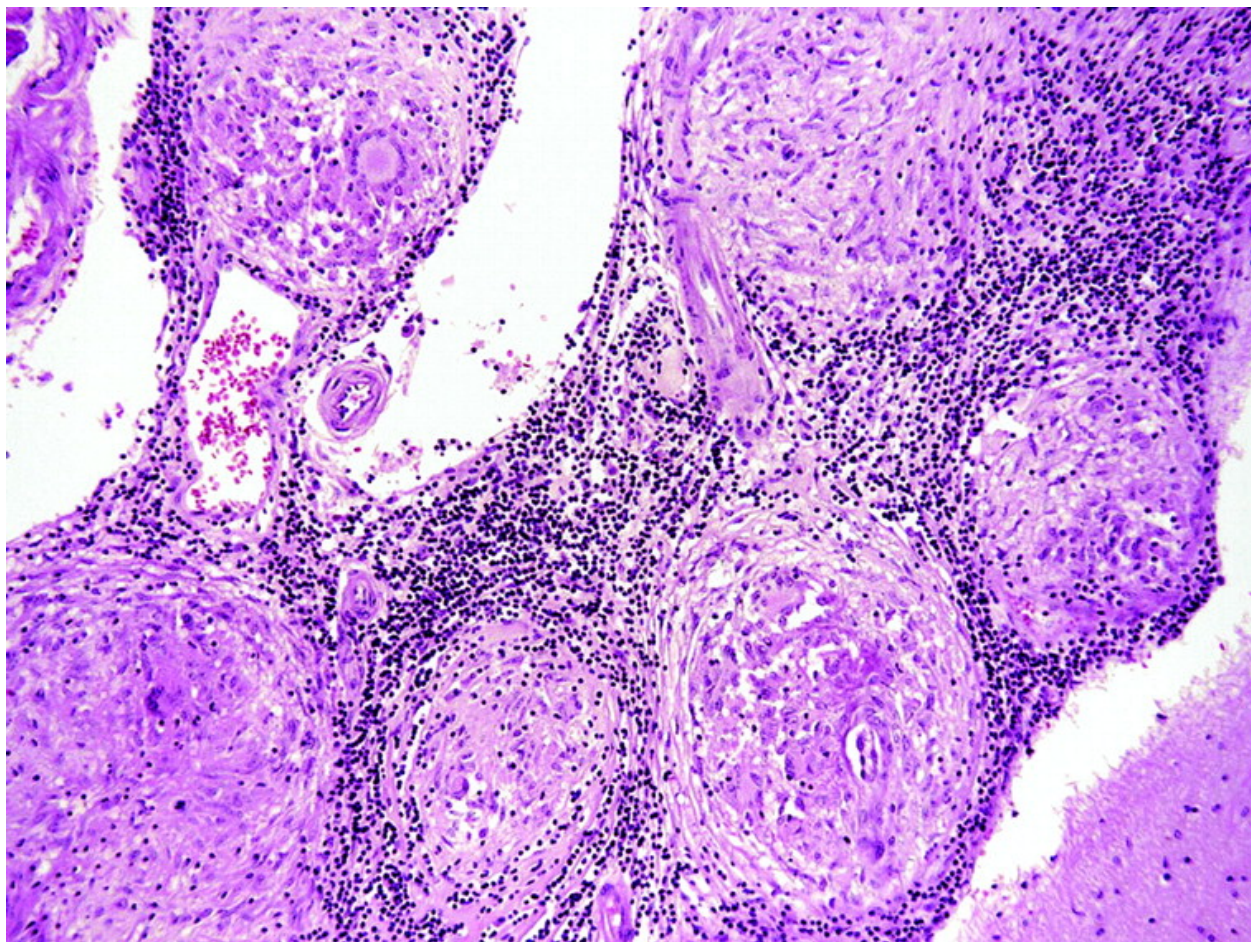
## 6. Diagnosis

Neurosarcoidosis has no pathognomonic sign, therefore it is a diagnosis of exclusion. This presents a great challenge, especially when the patient does not previously have a confirmed diagnosis of systemic sarcoidosis. The differential diagnosis encompasses a diverse number of pathologies such as Bell's palsy due to Lyme disease, optic neuropathy due to MS, tuberculosis, carcinomatous or lymphomatous meningitis causing multiple cranial nerve palsies. Additional pathologies include metastatic lesions, encephalopathy via syphilis or CNS vasculitis, peripheral neuropathy, or parenchymal lesions such as astrocytomas. Therefore, it is important to think of all the possibilities and rule them out [8].

If neurosarcoidosis is suspected, the patient should be evaluated for evidence of extraneural disease due to the difficulty of obtaining nerve tissue for evaluation. It is imperative to check the skin, lymph nodes and lungs. Other tests that may be useful include ophthalmologic examination, endoscopic nasal and sinus examinations. Radiological tests include neuroimaging (discussed later) and chest x-ray or CT scan to search for hilar adenopathy or parenchymal changes consistent with pulmonary sarcoidosis, serum angiotensin converting enzyme (ACE) assays (nonspecific) and lumbar puncture to analyze CSF. CSF findings may show an increased opening pressure, protein up to 250mg/dL, mononuclear pleocytosis, IgG elevation, oligoclonal bands, glucose normal or low; and CSF ACE is possibly elevated. CSF ACE levels have a relative low sensitivity. Although most studies do not mention immunoglobulins levels in CSF, there is evidence that elevation of immunoglobulin IgG with a high CSF to serum IgG index may be common in CNS sarcoidosis [13]. CSF eosinophilia has also been reported as a consequence of neurosarcoidosis, [14] but may also be present in other infections, inflammatory, and neoplastic conditions, including lepto-meningeal spread of gliomas [15]. Of note, always be cautious of doing a LP in a patient that possibly has increase intracranial pressure. If this is suspected, check for papilledema by using a fundoscope and MRI imaging preceding the LP [8]. Routine laboratory tests may show hyperglobulinemia, hypercalcemia or elevation of alkaline phosphatase [16]. Hypercalcemia occurs in approximately 13-20% of cases due to high levels of 1,25-dihydroxy-vitamin D causing hyperabsorption of calcium [17,18].

Sarcoid lesions in the CNS do not differ from those encountered in other organs. Most cases of CNS sarcoidosis diagnosed by histology have shown variable degrees of meningoencephalomyelitic infiltration, either localized or widespread. This results in focal or disseminated meningeal nodules or plaques, and affecting particularly the basal meninges. Although sarcoid lesions can occur almost anywhere in the central nervous structures, most often they are located perivascularly, with varying degrees of associated gliosis and fibroblast proliferation [3].

One may need to use other tests such as EEG, evoked potentials, and angiography to exclude other causes. Another test, the Kveim-Siltzbach, is not standardized and is not available universally. However, it can show positive granuloma results 4-6 weeks after injecting part of a spleen from a patient with known sarcoidosis into the skin. According to a study by C K Liam and A Menon, the Kveim-Siltzbach test can show false negative results when done in



**Figure 1.** Noncaseating granuloma in parietal lobe showing the granuloma surrounded by epithelioid cells and nodular inflammatory infiltrates (hematoxylin and eosin, 10x). [35]

conjunction with corticosteroid use possibly due immunosuppressive effects. There is also concern that HIV and hepatitis transmission could occur through this technique [8].

As a last resort, a biopsy is done of the meninges, brain, or spinal cord. Biopsies from extraneural tissue are recommended as it is less risky, but if it is highly suspected and a person with known sarcoidosis with neurologic involvement is deteriorating despite therapy, the neural tissue can be sampled [19]. Most common sites include the meninges and mass lesions.

## 7. Neuroimaging

Neurosarcoidosis does not have a specific finding on imaging that can assure the diagnosis. However, neuroimaging along with neurologic evaluation, CSF analysis, biopsy and others can aid in making the diagnosis. Oftentimes, it is a brain contrast-enhanced MRI and CSF analysis that gives the presumptive diagnosis. Contrast MRI allows one to visualize meningeal or parenchymal involvement of active inflammation with disruption of the blood brain barrier as well as masses and hydrocephalus.

As mentioned previously, cranial nerve palsies are the most common presentation in neurosarcoidosis, which can be seen on MRI with inflammation along with spinal cord involvement as well [20]. There have been studies done in which enhanced CT was shown to be normal, but the enhanced MRI was abnormal, implying greater sensitivity of MRI for detection neurosarcoidosis lesions [21].

In neurosarcoidosis, leptomeningeal disease is a common pattern of involvement, which may be localized or widespread. Less commonly, granulomatous masses can be found within the cerebral parenchyma. There have been cases showing patients with cranial nerve palsies demonstrating clear evidence of focal meningeal disease on gadolinium-DTPA enhanced MRI brain scans. Neurosarcoidosis is difficult to diagnose when patients have no evidence of granulomatous disease outside the nervous system because of the difficulty of obtaining tissue for histological examination. Therefore, primarily neurological evaluation, neuroimaging and lumbar puncture are done. However, diffuse meningeal infiltration particularly in the skull base region is frequently found at necropsy. Two cases presented by Khaw et al showed Gadolinium-DTPA enhanced MRI's in patients with cranial nerve palsies; one with solely cranial nerve palsies and the other along with gynecologic manifestations. In both of these cases, the meninges were affected by the disease and patients presented with multiple lower cranial nerve palsies, which was not picked up by CT or non-contrast MRI [22].

According to Pawate et al, a study done on 54 cases of neurosarcoidosis, the majority (23%) were found to have intraparenchymal T2 hyperintense lesions on brain MRI. 19% were found to have meningeal involvement seen with gadolinium enhanced MRI. Few of these cases showed intracranial masses, normal brain or solely spinal cord involvement on MRI [23].

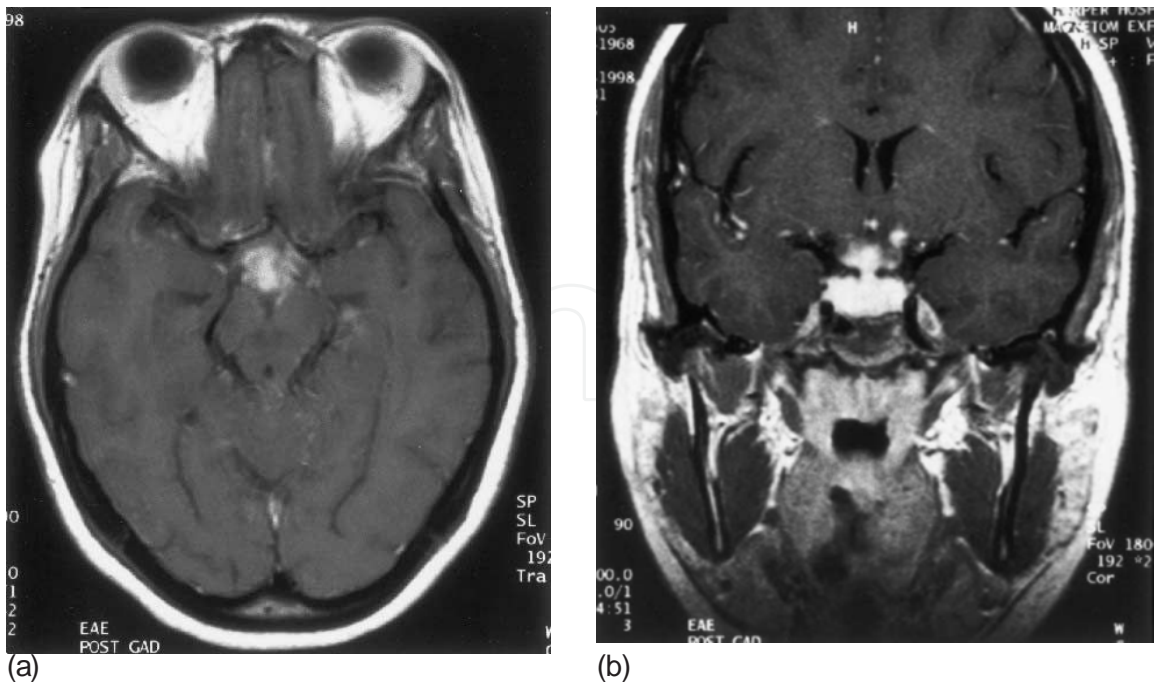
When the CNS is involved, brain enhanced MRI and CSF studies are sensitive in the detection of CNS inflammation, however they lack specificity. This continues to make diagnosing neurosarcoidosis a clinical challenge.

## 8. Management of neurosarcoidosis

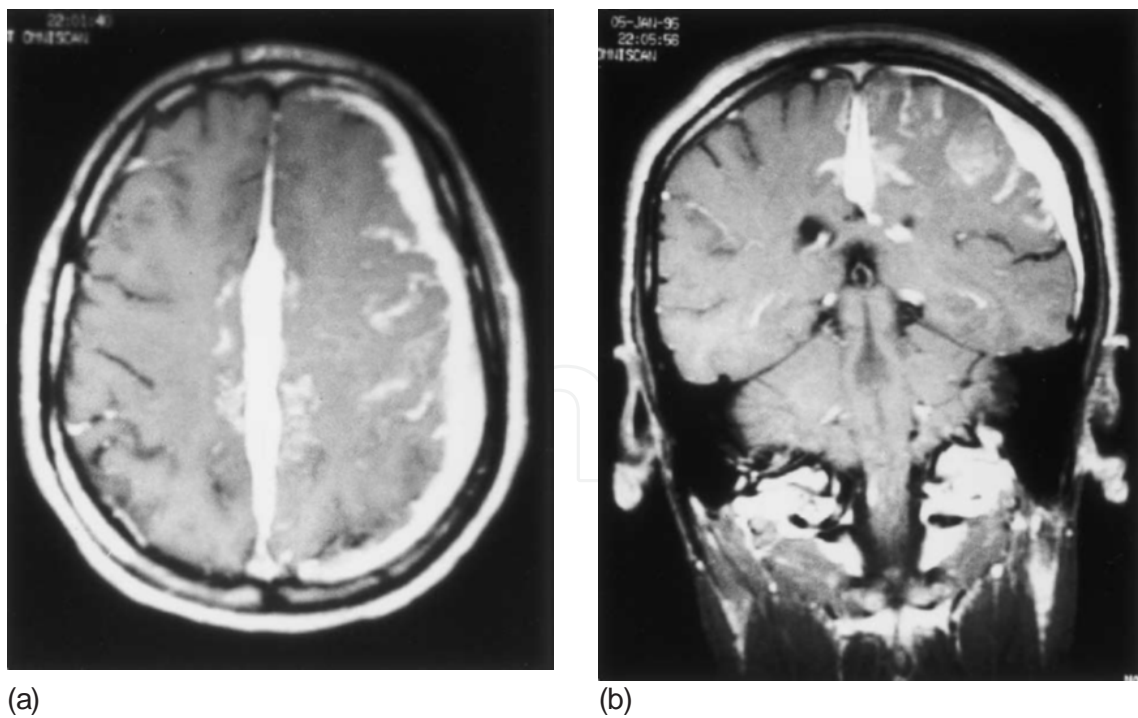
While sarcoidosis is a progressive autoimmune disease and there is currently no cure, symptomatic treatment is available. Corticosteroids have become the treatment of choice for neurosarcoidosis. The dosage and duration of therapy varies based upon the type and severity of the symptoms. For instance, patients who present with peripheral facial nerve palsy or meningeal symptoms are given about 0.5mg/kg/day of prednisone for two weeks. On the other hand, a patient with myopathy is given the same dosage for four weeks, and a patient with a mass lesion or symptomatic hydrocephalus is given two to three times this amount for four weeks. Very severe cases of neurosarcoidosis benefit from IV methylprednisone 20mg/kg/day for three days, followed by 1-1.5mg/kg/day of prednisone for two to four weeks [24].

The exact mechanism by which corticosteroids have benefited patients with neurosarcoidosis is unclear, but is generally believed to be secondary to its anti-inflammatory and immunomodulatory effects. Corticosteroids are known to prevent leukocytes from gaining access to sites





**Figure 2.** Neurosarcoidosis involving the pituitary-hypothalamic axis. T-1 gadolinium-enhanced Axial (a) and coronal (b) views shows an area of abnormal enhancement involving the sellar, suprasellar regions and the interpeduncular cistern. The diagnosis was confirmed by a biopsy [3].



**Figure 3.** Meningeal neurosarcoidosis. Axial (a) and coronal (b) MRI T-1 weighted images post infusion of gadolinium DTPA in a patient with systemic sarcoidosis show thickening and enhancement of the dura surrounding the left hemisphere [3].

of inflammation, interfere with their function along with that of endothelial cells and fibroblasts, and suppress production of various humoral factors [25]. It is always important to keep in mind, however, that as with all medications, corticosteroids are not without side effects. Common side effects of corticosteroids include cognitive and personality changes, weight gain with central obesity, development of striae, diabetes mellitus, cataracts and predisposition to various infections. Cardiovascular effects are also known to occur, such as hypertension, dyslipidemia, and increased risk of myocardial infarction and stroke. Patients receiving long term corticosteroid therapy are at risk for osteoporotic fractures, especially in the setting of other general risk factors such as being over age 60 or having osteoporosis prior to corticosteroid treatment. Additionally, avascular necrosis, especially of the hip, has been known to occur in a number of patients [1]. Therefore, it is important to carefully monitor the dosage, and to always use the lowest possible effective dose. If treatment with corticosteroids is to be discontinued, it is essential to decrease the dose gradually. Abrupt discontinuation of corticosteroid therapy can cause adrenal insufficiency.

### **8.1. Alternative therapies for refractory neurosarcoidosis**

Several therapies have been proposed for those patients in whom corticosteroid treatment is unsuccessful, or in those who have contraindications to treatment. Many of these studies have shown methotrexate to be an effective treatment. Methotrexate has been successful in two-thirds of sarcoidosis patients regardless of the organ systems that are affected. In one study, EE Lower et al observed 554 sarcoidosis patients, of which 71 had neurosarcoidosis. They found that treatment with methotrexate and cyclophosphamide was associated with higher response rates than treatment with corticosteroids only [26].

In 2007, TF Scott et al used aggressive therapy with corticosteroids and alternative immunosuppressants in 48 patients. Over half of these cases had favorable outcomes [27]. Later, in 2011, G Androdias et al observed a small group of patients with neurosarcoidosis, and found evidence suggesting that Mycophenolate mofetil was effective in treatment of CNS symptoms. The agent was also found to have a steroid sparing effect and was better tolerated than several other immunosuppressive agents [28]. Additional studies have shown anti-TNF agents such as infliximab to be effective; and cytokine modulators such as thalidomide and pentoxifylline have also been used in a limited number of cases [29].

### **8.2. Other treatments**

Surgical resection of CNS mass lesions is usually not recommended, unless the mass persists or continues to enlarge despite appropriate immunomodulatory therapy. If the patient presents with symptomatic hydrocephalus, a ventriculoperitoneal shunt can be placed. It is important to continue immunosuppressive treatment following placement of the shunt as inflammation can lead to obstruction. Cranial or spinal irradiation is suggested in refractory cases if no response is seen with corticosteroids and at least two other agents [30]. Additionally, symptom-specific treatment may be needed, such as hormone replacement therapy for hypopituitarism, and antipsychotics for patients with psychosis.

## 9. Prognosis of neurosarcoidosis

While many patients with neurosarcoidosis have a monophasic illness, relapsing-remitting and progressive disease patterns are also seen. RA Luke et al followed 25 patients with neurosarcoidosis for a minimum of 5 years or until death. 68% of the patients were found to have the monophasic pattern and 32% had a relapsing pattern [31]. The authors also noted that relapses were more common in patients with cerebral symptoms and in those presenting with hydrocephalus. Furthermore, relapses occurred more frequently in those who were taking smaller doses of corticosteroids (10mg or less).

Although the long term outcomes in neurosarcoidosis patients have not yet been clearly defined in studies, some general conclusions can be made. Patients with peripheral facial nerve palsy often show improvement within 2-4 weeks. Some patients with optic neuropathy show improvement, while others with a more progressive disease pattern can become blind. In 1999, G.A. Christoforidis et al conducted a retrospective study of 461 patients with sarcoidosis, confirmed on biopsy. These researchers reported that patients with optic nerve involvement often did not respond as well to corticosteroid treatment as those with other CNS manifestations did. The researchers suggest that because the other cranial nerves are surrounded by Schwann cells, they can regenerate more easily than the optic nerve, whose myelin sheath is produced by oligodendrocytes [32].

Symptoms such as peripheral neuropathy and myopathy also tend to follow a more chronic and progressive pattern. Aseptic meningitis usually improves within a few weeks, yet CSF abnormalities (asymptomatic chronic pleocytosis) can persist for some time after. Mass lesions often persist for some time, but can also resolve on occasion. Additionally, patients with encephalopathy often exhibit a progressive pattern. Typically immunomodulatory medications are not helpful in patients with endocrinopathies, and these patients need to be treated with hormonal replacement therapy. Also, a series of 68 patients were followed by JP Zajicek et al in 1998, who noted spinal cord involvement in 28% of the patients [33]. The authors concluded that spinal cord disease had a poorer prognosis, as a significant percentage of these patients were found to have deteriorated at follow-up. Patients with seizures have historically been shown to have a poorer prognosis, but more recent studies have disproved this [8].

In general, as the outcome in patients with neurosarcoidosis depends on the severity and types of neurological symptoms, it is difficult to make a conclusive statement regarding the prognosis of the disease. Reportedly, about 10% of patients with neurosarcoidosis die of the disease, typically secondary to CNS parenchymal involvement, hydrocephalus, or other severe symptoms; or due to immune-compromise secondary to treatment.

## 10. Concluding remarks

Neurosarcoidosis can range from mild to life threatening; and can affect any part of the central and peripheral nervous systems. It can present at any point during the course of the disease

process. Many patients do not experience neurological symptoms until the disease has progressed for some time, and systemic symptoms are present. Other patients have neurological manifestations of the disease at the time of initial presentation. Overall, however, neurosarcoidosis only represents a small portion of the total population of patients with a diagnosis of sarcoidosis - about 5%. If patients present with neurological symptoms, with no prior diagnosis of sarcoidosis, it might prove difficult for clinicians to make a diagnosis. This is because these symptoms are quite general and can be seen with a multitude of other diseases. Patients have been reported to have not only general cranial nerve palsies and peripheral neuropathies, but also have been known to present with meningeal symptoms, hydrocephalus, seizures, and even psychosis.

Since the exact cause of neurosarcoidosis is not known, it is important to be aware of any clinical signs early on. It is also important to differentiate it from other diseases with similar manifestations, such as multiple sclerosis due to differences in management and treatment. There are many clinical and lab tests available, as well as imaging that can help determine if one has neurosarcoidosis. Although there is no pathognomonic sign, brain contrast MRI is a vital tool along with CSF analysis that can give a presumptive diagnosis. They are highly sensitive, although lack specificity, which makes it difficult to definitively diagnose it. Gullapalli and Phillips found a sensitivity of brain MRI of about 82–97% for MS; for CSF abnormality and CSF ACE, sensitivity was 50–80% and 50%, respectively [34]. The most definitive diagnosis can be made from histological analysis of neural tissue via biopsy if there is still doubt despite the other tests or at autopsy. However, it is used as a last resort due to being the most invasive method.

As with other sarcoidosis patients, corticosteroids are the main treatment for neurosarcoidosis. However, some manifestations are more responsive to steroids than others. Additionally, many patients taking corticosteroids for an extended period of time often experience serious side effects; and there are also several contraindications to taking these medications. For this reason, several alternative therapies have been proposed for sarcoidosis patients, and several studies have found methotrexate and cyclophosphamide to be especially effective in treatment of neurological symptoms. Many other immunomodulatory medications have also been shown to be effective along with various symptom-specific treatments.

While many studies have been conducted with regards to the long term outcomes of neurosarcoidosis patients, no definitive conclusions can be made as yet. However, the prognosis for these patients is mainly dependent on the neurological manifestations they experience. Patients with cranial nerve palsies, and particularly optic neuropathies, have been shown in many cases to respond well to corticosteroid treatment. More serious symptoms on the other hand, such as seizures and spinal cord involvement generally suggest a poor prognosis. However, one must also keep in mind, that various disease patterns have been reported in neurosarcoidosis patients. Neurosarcoidosis may present as a monophasic, relapsing-remitting, or chronic progressive pattern. Thus, additional studies need to be conducted before any conclusive statements can be made regarding the outlook for patients with neurosarcoidosis.

## Nomenclature

CNS: central nervous system

CD4: cluster of differentiation 4

Th1: type 1 helper cells

HLA: human leukocyte antigen

MS: multiple sclerosis

ACE: angiotensin converting enzyme

CSF: cerebrospinal fluid

LP: lumbar puncture

MRI: magnetic resonance imaging

HIV: human immunodeficiency virus

EEG: electroencephalogram

CT: computed tomography

DTPA: diethylene triamine pentaacetic acid

Mg: milligrams

Kg: kilograms

IV: intravenous

TNF: tumor necrosis factor

## Author details

Mohankumar Kurukumbi<sup>1</sup>, Preema Mehta<sup>2</sup>, Isha Misra<sup>2</sup> and Jayam-Trouth Annapurni<sup>1</sup>

\*Address all correspondence to: mohan311@gmail.com

<sup>1</sup> Department of Neurology, Howard University Hospital, Washington, DC, USA

<sup>2</sup> Howard University College of Medicine, Washington, DC, USA

## References

- [1] Fitzgerald PA. Chapter 26. Endocrine Disorders. In: McPhee SJ, Papadakis MA, Rabow MW, eds. CURRENT Medical Diagnosis & Treatment 2012. New York: McGraw-Hill; 2012.

- [2] Smith JK, Matheus MG, Castillo M. Imaging manifestations of neurosarcoidosis. *AJR* 2004; 182:289-95.
- [3] Vinas F, Rengachary S. Diagnosis and Management of Neurosarcoidosis. *Journal of Clinical Neuroscience* (2001) 8(6), 505-513
- [4] Hunninghake GW, Costabel U, Ando M, et al. ATS/ERS/WASOG statement on sarcoidosis. *Sarcoidosis Vasc Diffuse Lung Dis* 1999; 16: 149–73.
- [5] Mochizuki T, Negoro K, Morimatsu M, Arita K. Two siblings with sarcoidosis diagnosed by younger sister's central nervous symptoms. *Rinsho Shinkeigaku* 1996; 36: 1249-1255.
- [6] Hoitsma E. Neurosarcoidosis: a clinical dilemma. *Lancet Neurol.* 2004 Jul;3(7): 397-407).
- [7] Burns TM. Neurosarcoidosis. *Arch Neurol* 2003; 60:1166. Stern BJ, Krumholz A, Johns C, et al. Sarcoidosis and its neurological manifestations.
- [8] Joseph FG and Scolding NJ. Neurosarcoidosis: a study of 30 new cases. *J Neurol Neurosurg Psychiatry.* 2009; 80(3):297.
- [9] Lacomis D. Neurosarcoidosis. *Curr Neuropharmacol.* 2011; 9(3):429-436.
- [10] Bopp FP et al. Heerfordt syndrome: a cause of facial paralysis. *J La State Med Soc.* 1990; 142(2):13-5
- [11] Speigel DR et al. Neurosarcoidosis and the Complexity in its Differential Diagnoses. *Innov Clin Neurosci.* 2012 ; 9(4) :10-16.
- [12] Afshar K et al. Sarcoidosis : a rare cause of Kleine Levine Critchley syndrome. *Sarcoidosis Vasc Diffuse Lung Dis.* 2008 ; 25(1) :60-3.
- [13] Fried ED, Landau AJ, Sher JH, Rao C. Spinal cord sarcoidosis: a case report and review of the literature. *J Assoc Acad Min Phys* 1993; 4:132-137.
- [14] Scott TF. A new cause of cerebrospinal fluid eosinophilia: Neurosarcoidosis. *Am J Med* 1988; 84: 973-974.
- [15] Defendini R, Hunter SB, Schlemingi EB, Leifer E, Rowland LP. Eosinophilic meningitis in a case of disseminated glioblastoma. *Arch Neurol* 1981; 38: 52-53.
- [16] Glaser GH. Neurologic complications of internal disease. In: Baker AB, Baker LH (eds) *Clinical Neurology.* Hagerstown: Maryland Harper & Row,1979: 3(44): 1-53.
- [17] Stuart CA, Neelon FA, Lebovitz HE. Hypothalamic insufficiency: the cause of hypopituitarism in sarcoidosis. *Ann Intern Med* 1978; 88: 589-594.
- [18] Winnacker JL, Becker KL, Katz S. Endocrine aspects of sarcoidosis. *N Engl J Med* 1968; 278: 427-434.

- [19] Peeples DM, Stern BJ, Jiji V, Sahni KS. Germ cell tumors masquerading as central nervous system sarcoidosis. *Arch Neurol* 1991; 48:554.
- [20] Bihan H, Christozova V, Dumas JL, et al. Sarcoidosis: clinical, hormonal, and magnetic resonance imaging (MRI) manifestations of hypothalamic-pituitary disease in 9 patients and review of the literature. *Medicine (Baltimore)* 2007; 86:259.
- [21] Zajicek JP et al. Central nervous system sarcoidosis – diagnosis and management. Association of Physicians of Great Britain and Ireland. *QJM* 1999; 92(2):103-117.
- [22] Khaw KT, Manji H, Britton J, Schon F. Neurosarcoidosis – demonstration of meningeal disease by gadolinium enhanced magnetic resonance imaging. *J Neurol Neurosurg Psychiatry*. 1991 Jun;54(6):499-502.
- [23] Pawate S, Moses H, Sriram S. Presentations and outcomes of neurosarcoidosis: a study of 54 cases. *QJM* 2009; 102:449.
- [24] Stern BJ and Corbett J. Neuro-ophthalmologic Manifestations of Sarcoidosis. *Curr Treat Opin Neurol* 2007; 9(1):63.
- [25] Boumpas DT et al. Glucocorticoid therapy for immune related diseases: basic and clinical correlates. *Ann Intern Med*. 1993; 119(12):1198-208.
- [26] Lower EE et al. Diagnosis and Management of Neurological Sarcoidosis. *Arch Intern Med*. 1997; 157 (16): 1864-1868.
- [27] Scott TF et al. Aggressive therapy for neurosarcoidosis: long-term follow-up of 48 treated patients. *Arch Neurol* 2007; 64:691.
- [28] Androdias G et al. Mycophenolate mofetil may be effective in CNS sarcoidosis but not in sarcoid myopathy. *Neurology* 2011; 76:1168.
- [29] Baughman RP, Lower EE. Chapter 329. Sarcoidosis. In: Longo DL, Fauci AS, Kasper DL, Hauser SL, Jameson JL, Loscalzo J, eds. *Harrison's Principles of Internal Medicine*. 18th ed. New York: McGraw-Hill; 2012. <http://www.accessmedicine.com/content.aspx?aID=9138725>. Accessed August 14, 2012.
- [30] Menninger MD et al. Role of Radiotherapy in the treatment of neurosarcoidosis. *Am J Clin Oncol*. 2003; 26(4):e 115.
- [31] Luke RA, Stern BJ, Krumholz A, Johns CJ. Neurosarcoidosis: the long-term clinical course. *Neurology* 1987; 37:461.
- [32] MR of CNS Sarcoidosis : Correlation of Imaging Features to Clinical Symptoms and Response to Treatment. GA Christoforidis et al. *AJNR Am J Neuroradiol* 20 :655-669, April 1999.
- [33] Zajicek JP, Scolding NJ, Foster O, et al. Central nervous system sarcoidosis--diagnosis and management. *QJM* 1999; 92:103.

- [34] Gullapalli D, Phillips LH. Neurologic manifestations of sarcoidosis. *Neurol Clin* 2002;20: 59–83.
- [35] Joseph FG, Scolding NJ, Sarcoidosis of the nervous system: Review. *Pract Neurol* 2007;7:234-244

IntechOpen

IntechOpen



