

# We are IntechOpen, the world's leading publisher of Open Access books Built by scientists, for scientists

**4,800**

Open access books available

**122,000**

International authors and editors

**135M**

Downloads

Our authors are among the

**154**

Countries delivered to

**TOP 1%**

most cited scientists

**12.2%**

Contributors from top 500 universities



**WEB OF SCIENCE™**

Selection of our books indexed in the Book Citation Index  
in Web of Science™ Core Collection (BKCI)

Interested in publishing with us?  
Contact [book.department@intechopen.com](mailto:book.department@intechopen.com)

Numbers displayed above are based on latest data collected.

For more information visit [www.intechopen.com](http://www.intechopen.com)



---

# Iron Overload and Hematopoietic Stem Cell Transplantation

---

Zeynep Arzu Yegin, Gülsan Türköz Sucak and  
Taner Demirer

Additional information is available at the end of the chapter

<http://dx.doi.org/10.5772/53819>

---

## 1. Introduction

Hematopoietic stem cell transplantation (HSCT) is an established treatment modality with a curative potential in a variety of hematological disorders. Although remarkable advances in transplant immunology and supportive care allowed widespread use of HSCT, transplant related morbidity and mortality remain as a problem [1-7]. Early complications including sinusoidal obstruction syndrome (SOS), hemorrhagic cystitis, engraftment syndrome, idiopathic pneumonia syndrome (IPS), infections and graft versus host disease (GVHD) are the major causes of morbidity and non relapse mortality (NRM). High doses of radiotherapy and chemotherapy of the conditioning regimen have adverse effects on all organs and tissues of the recipient, which also triggers several early and late effects of variable intensity [1, 3, 5-8]. Iron overload (IO) is a relatively common condition in patients with hematological malignancies and HSCT recipients. Free iron which accompanies IO might contribute to the already existing prooxidant state in HSCT recipients by inducing the formation of reactive oxygen species (ROS). Tissue peroxidation and organ damage, as a consequence, contribute to the development of some early transplant complications [2, 4, 5, 9]. Increasing number of transplants performed each year and improved transplant techniques result in a rise in the number of long term survivors. The primary goal of HSCT is to cure the primary disease. However long term transplant related morbidity might be very challenging and might significantly impair the quality of life. Late effects might be the consequence of the direct toxicity of chemoradiotherapy and/or the immunologic complications mainly consisting of GVHD. Besides the secondary late effects including osteoporosis and dental caries, very late effects, namely cardiovascular toxicity considered as tertiary late effect may also occur. Among this wide spectrum of complications, IO has a substantial role as a contributor to liv-

er toxicity, infections and SOS and as a predictor of transplant outcome. Hematopoietic SCT recipients have been demonstrated to have a high degree of liver iron content (LIC) almost in the range of hereditary hemochromatosis (HH) and IO was shown to cause liver fibrosis, heart failure, hypogonadism, diabetes and endocrinopathy in HSCT recipients in the long run [4, 6, 7, 10].

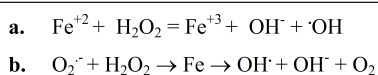
Iron is an essential element which plays a key role in several biochemical reactions including oxygen transport and electron transfer. It mediates the conversion of hydrogen peroxide ( $\text{H}_2\text{O}_2$ ) to highly toxic free radicals leading to tissue damage by oxidation of proteins, peroxidation of membrane lipids and modification of nucleic acids [4]. Under normal circumstances, an appreciable concentration of free iron does not exist outside physiological sinks. Any released ferrous iron ( $\text{Fe}^{+2}$ ) is immediately chelated in cells by compounds such as citrate or adenosine diphosphate. Thus, labile iron could not participate in the Haber–Weiss reaction, which catalyses the formation of ROS. Free iron may directly initiate lipid peroxidation which destroys membrane structure resulting in increased oxidative stress and cellular damage. Excess iron accumulation causes chronic free radical induced tissue damage in multiple organs and leads to progressive organ dysfunction, which results in significant morbidity and mortality. In this respect, IO should be prevented in order to preclude the adverse impact of free iron on natural homeostasis [9, 11].

This chapter will focus on iron balance and the course of excess iron in HSCT recipients. The adverse impact of IO on transplant outcome and the preventive strategies will also be discussed.

## 2. Body

### 2.1. Iron homeostasis

Iron is vital for all living organisms and takes part in several metabolic processes, including DNA synthesis, oxygen and electron transport. Although iron is a critical element in cell growth and multiplication, it is potentially toxic in excess amounts by generating ROS [5, 11-13]. Reactive oxygen species have a potential to damage DNA and proteins by lipid peroxidation. Labile iron participates in free radical formation via Fenton reaction which was first recognized in 1894. Namely, trace amounts of iron as  $\text{Fe}^{+2}$  could catalyze the oxidation of tartrate by  $\text{H}_2\text{O}_2$ . Consequently, superoxide anion ( $\text{O}_2^-$ ) or  $\text{H}_2\text{O}_2$  is converted to toxic free radicals such as hydroxyl radical ( $\text{OH}^\cdot$ ). This process is mediated by the Fenton reaction catalyzed by iron, where  $\text{O}_2^-$  reduces ferric iron ( $\text{Fe}^{+3}$ ) to produce oxygen and  $\text{Fe}^{+2}$ . This reduced iron becomes reoxidized by  $\text{H}_2\text{O}_2$  to produce  $\text{OH}^\cdot$  [5, 11].



**Figure 1.** a. Fenton reaction; b. Iron catalyzed Haber–Weiss reaction or the superoxide driven Fenton reaction [5].

There are no physiological mechanisms in humans to excrete excess iron and iron homeostasis is primarily regulated at the level of absorption [4, 9, 11, 14-16]. The majority of iron absorption occurs via enterocytes in the proximal small intestine. The conversion of dietary inorganic non-heme iron to  $\text{Fe}^{+2}$  is facilitated by the brush border ferri reductases. Iron is transported across the cellular membrane by the divalent metal transporter 1 (DMT1) which transfers  $\text{Fe}^{+2}$  across the apical membrane and into the cell through a proton coupled process [9, 15, 16]. Ferroportin is an iron efflux pump that mediates the export of  $\text{Fe}^{+3}$  from the enterocyte. Prior to transport,  $\text{Fe}^{+2}$  is converted to  $\text{Fe}^{+3}$  by either hephaestin or ceruloplasmin both of which have ferroxidase activity. Subsequently, iron is uploaded to transferrin which is the primary iron transporter in the circulation. Ferric iron bound to transferrin is soluble and non reactive. The majority of iron (60–70%) is incorporated into hemoglobin while the rest is stored in hepatocytes, myoglobin and reticuloendothelial macrophages [9]. Hepcidin, the main regulator of iron absorption, inhibits intestinal absorption and release of storage iron in iron-overloaded states, whereas its expression is markedly decreased in iron deficiency states. Hepcidin interacts directly with ferroportin, causing its internalization, degradation and blocking iron release from cells to plasma. Hepcidin acts as an acute phase reactant which is responsible for the anemia of inflammation. Its production is upregulated by body iron excess and inflammation whereas downregulated by anemia and hypoxia [9, 14, 16].

Cell survival depends on the balance between the destructive and beneficial effects of iron [9, 12]. Natural iron homeostasis comprises regulation mechanisms to control iron excess. The primary protective pathway is the sequestration of iron in ferritin or transferrin. Ferritin is the chief storage molecule while transferrin is functionary for the transport of iron. Ferritin captures and buffers the intracellular iron pool, thus it makes iron available for critical cellular processes while protecting lipids, DNA and proteins from potentially toxic effects of iron. Iron stored in ferritin is not capable of catalyzing radical reactions and is considered as safe. It is well known that serum ferritin concentration closely parallels body iron reserves. However, as free iron is the main form of iron which can precipitate in oxidative stress, any measure of unbound iron will result in deleterious effects. The balance of free iron to bound iron changes and free iron becomes available to catalyze free radical reactions in iron overloaded states [5, 9]. Large amounts of excess iron in the circulation are likely to exceed the serum iron binding capacity (SIBC) and non transferrin bound iron (NTBI) will emerge eventually. Non transferrin bound iron bypasses the normal regulatory mechanism of receptor mediated iron uptake and is able to stimulate the peroxidation of membrane lipids and the formation of ROS. The intracellular counterpart of NTBI is considered as labile iron pool (LIP) which is bound mainly to low molecular weight compounds. Labile iron pool is catalytically active and capable of initiating free radical reactions. The expansion of the LIP and simultaneously increased NTBI may trigger cell toxicity. Generation of LIP leads to unregulated iron uptake and subsequent intracellular storage either within ferritin molecules or as hemosiderin. The adverse effects of IO can arise from the elevation of NTBI and LIP in plasma and might as well cause organ damage mediated by the accumulation of tissue iron in target organs. The equilibrium between the LIP and iron locked in the ferritin shell is critical to maintain the normal function of cellular iron enzymes. Imbalance in this equilibrium results in the uncontrolled loading of organs, such as the liver, heart and endocrine glands,

with free iron which generates free radicals and causes cell damage [12, 17]. Eventually, NTBI and LIP may be more relevant iron markers than serum ferritin and transferrin as a predictor of IO induced tissue damage. Alterations in ferritin levels are seen commonly in clinical practice often reflecting perturbations in iron homeostasis or metabolism. Serum ferritin differs markedly from tissue ferritin in molecular weight, iron and carbohydrate content, subunit size and amino acid sequence. The extracellular form of ferritin, termed as serum ferritin, is used as a clinical marker of iron status. Tissue ferritin is the more efficient storage form of iron than is serum ferritin and the function of serum ferritin has to be clarified in these circumstances [9, 12]. Serum ferritin is usually correlated with NTBI, whereas inflammation, acute and chronic liver diseases and malignancies may also cause elevated serum ferritin levels regardless of the iron stores [12].

## 2.2. Iron overload and stem cell transplantation

Iron overload is a significant problem in autologous (auto) and allogeneic (allo) HSCT recipients and may adversely affect transplant outcome [4, 18]. The diagnosis of IO has been reported in up to 88% of long term survivors of HSCT on the basis of serum ferritin levels [19]. Iron overloaded state may last for a long time after transplantation. In a cross sectional study by Majhail et al, in which LIC on MRI was used for diagnosis, the prevalence of IO was reported to be 32% in allo-HSCT recipients who had survived 1 year or more following HSCT [20]. In another study by the same group, serum ferritin levels were found to be above 1000 ng/ml in 34% of allo-HSCT and 13% of auto-HSCT recipients. Thus, IO may be less prevalent among recipients of auto-HSCT compared to allo-HSCT as expected [21].

The main causes of IO in HSCT are prolonged dyserythropoiesis, increased intestinal iron absorption due to anemia and chemotherapy associated mucositis which leads to increased iron absorption, transfusion burden and release of iron from injured tissues [8, 22].

Iron overload is particularly common in HSCT recipients with hemoglobinopathies and hematological malignancies which require frequent transfusions and is associated with ineffective erythropoiesis such as acute leukemia and myelodysplastic syndrome (MDS). Transfusion load is considered to be the principal cause of IO in this group, as each unit of packed red blood cells (PRBC) contains approximately 200–250 mg iron. Since there is no physiological mechanism for excreting excess iron, iron accumulation is inevitable after 10–20 transfusions [22–24]. Ineffective erythropoiesis might be a contributing factor leading to excessive iron absorption particularly in MDS and thalassemia which is mediated by erythroid regulators of iron metabolism which suppress hepcidin and result in increased iron absorption. Elevated growth differentiation factor 15 (GDF-15) levels are considered to be the initiating event in this context. Ineffective erythropoiesis either as a feature of the underlying disease or a consequence of intensive treatment leads to inhibition of hepcidin possibly due to overexpression of GDF-15 and thus increases iron absorption and toxicity. Hematopoietic SCT recipients are at risk of IO due to prior transfusion load, increased iron absorption related to elevated GDF-15 levels and peri-transplant transfusions [22, 24, 25].

Bone marrow (BM) and tumor cell destruction which occurs as a consequence of high dose therapy and release of iron from damaged cells as well as underutilization of iron due to the

inhibition of erythropoiesis as a result of cytotoxic therapy are important factors in the etiology of IO. Erythropoiesis, which is the main route of iron utilization, is temporarily halted by the conditioning regimen [8, 22, 23, 26]. Conditioning treatment with chemo/radiotherapy during HSCT causes toxicity and immunosuppression leading to organ damage and infectious complications mainly in the first 3 months of the procedure [27]. Free iron, which acts as a free radical catalyser, might increase the toxicity of the conditioning regimen during HSCT. Serum iron parameters were demonstrated to be elevated 2–3 days during conditioning chemotherapy prior to stem cell infusion in a report by Gordon et al [13]. Non transferrin bound iron appears shortly after conditioning regimen and remains detectable in most patients throughout the peri-transplant period. Transferrin saturation (TS) increases during the conditioning regimen, often reaching to levels above 80% with the consequent emergence of NTBI [28]. The ability of ferritin to sequester iron and binding of iron to transferrin is exhausted in HSCT recipients receiving conditioning regimen, thus leading to excess NTBI formation. The extent of BM suppression caused by the conditioning regimen is correlated with the elevation of NTBI [27]. A substantial decrease in plasma anti-oxidant defense has also been demonstrated in HSCT recipients, and NTBI levels were found to be inversely correlated with plasma antioxidant capacity in a report by Yegin et al [29]. A derangement of the prooxidative/antioxidative balance was demonstrated as antioxidants only partially recover to baseline values until day 14 after HSCT [30, 31].

Hepatic toxicity due to chemotherapy and radiation might lead to hepatocellular damage with subsequent further release of hepatic iron stores. Liver damage may also disturb transferrin synthesis [28, 30]. A decrease in transferrin due to hepatic toxicity, stored iron leaking from injured liver to blood and a suppression of erythropoietic activity during treatment may cause elevated TS levels. Thus, increasing TS succeeds and contributes to the appearance of potentially toxic NTBI in the circulation. Iron in its NTBI form is a potent catalyst in Fenton's reaction which produces ROS capable of causing cellular damage through various mechanisms. Tissue damage such as mucositis and liver injury is common after HSCT and may be partly mediated by NTBI during cytotoxic chemoradiotherapy [28, 29, 32]. It is indicated that increased NTBI levels may contribute to organ toxicity and infectious complications in the early post-transplant period [29].

Complication	Incidence	Mechanism of Injury
Infection	Variable	Immune dysregulation, mediated in part by IO, iron-rich microbial environment
Chronic liver disease	Common	Multifactorial, including IO
SOS	Common (up to 54%)	Conditioning regimen, prior irradiation, possibly IO
IPS	Uncommon (2-8%)	Pro-inflammatory events and increased ROS (mediated by IO)

**Table 1.** Complications of IO in patients undergoing HSCT [24]

Complication	Comments
<b>Early (&lt;1 year)</b>	
<b>Infections</b>	<b>Mucormycosis, invasive aspergillosis, listeria monocytogenes and other infections</b>
<b>Acute GVHD</b>	<b>No clear evidence available, elevated ferritin might increase risk</b>
<b>SOS</b>	<b>Iron overload might increase risk</b>
<b>NRM</b>	<b>Elevated ferritin associated with increased risk in allo and auto-HSCT recipients</b>
<b>Late (" /&gt;1 year)</b>	
<b>Infections</b>	<b>Mucormycosis, invasive aspergillosis and other infections</b>
<b>Chronic GVHD</b>	<b>No clear evidence available, decreased risk reported with elevated ferritin</b>
<b>Liver Function Abnormalities</b>	<b>Iron overload increases risk</b>
<b>Cardiac Late Effects</b>	<b>Iron overload might increase risk</b>
<b>NRM</b>	<b>No clear evidence available</b>

**Table 2.** The Role of IO in Early and Late Complications of HSCT [4]

Iron toxicity may play an important role in the pathogenesis of transplant related complications [Table 1, 2]. In a series of 25 patients who underwent HSCT, very high levels of ferritin (>3000 ng/ml) and TS (>100%) dramatically increased transplant related mortality (TRM) and decreased overall survival (OS) which was particularly attributed to infections [32]. As iron is an essential element for all pathological microorganisms, excess amounts of free iron might increase microbial growth and the probability of severe infections [33]. The coexistence of excess plasma iron with the damage to the mucosal barrier may also predispose to infectious events with bacterial translocation. Hypoferraemia is a normal response to infection and appears to be a part of a natural resistance mechanism whereas hyperferremia can predispose to bacterial and fungal infections. In this context, elevated TS and ferritin levels are proven risk factors for the development of systemic fungal infections in patients with hematological malignancies [1, 33, 34]. Furthermore, an increase in late fungal infections, especially mucormycosis, has been reported in iron loaded patients after HSCT [35]. Elevated pre-transplant ferritin levels seem to effect prognosis adversely in myeloablative HSCT primarily due to increased NRM. On the other hand, elevated iron stores apart from providing a milieu for infection and organ toxicity, may also be in relevance to tumor growth. Thus elevated ferritin levels might be in association with relapse and relapse mortality [36]. Mahindra et al reported that elevated pre-transplant serum ferritin level was an independent adverse risk factor for OS in patients undergoing non myeloablative HSCT. Inferior survival in patients with elevated ferritin was related to both higher rates of treatment related mortality and relapse mortality [37]. On the other hand it should also be noted that ferritin is an acute phase reactant and a marker of inflammation besides its role as a surrogate marker of iron status. Thus, elevated ferritin levels might as well indicate a group of patients with more aggressive primary disease biology and a subgroup of patients who are already more

likely to experience disease relapse. Thus the association of elevated ferritin levels with relapse might be unrelated to IO.

The adverse impact of IO on transplant outcome has been demonstrated most convincingly in patients with thalassemia where class III patients with extensive liver damage had higher TRM [38]. Besides increased TRM, other complications attributed to IO includes fungal infections, hepatic dysfunction and hepatic SOS/Veno occlusive disease (VOD) [4, 27, 38, 39]. In fact, thalassemia is a benign disorder and ferritin is directly a marker of excess iron and elevated levels could not be attributed to the biology of an underlying malignant pathology. As a result of the above mentioned data, pre-transplant serum ferritin was included in a prognostic scoring system for acute leukemia and MDS patients undergoing allo-HSCT [40]. The late morbidity of IO is primarily due to the involvement of heart and liver. Although iron related liver function test (LFT) abnormalities have been reported, there are no studies that describe the role of IO in late onset cardiomyopathy and hepatic fibrosis/cirrhosis in patients transplanted for diseases other than thalassemia. Post-transplant iron depletion therapy has been shown to reverse hepatic fibrosis and cardiomyopathy in children with thalassemia who have undergone allo-HSCT [4].

### **2.3. Iron overload and transplant complications**

#### *2.3.1. Liver complications*

Liver disease is a frequent cause of morbidity and mortality following allo-HSCT and affects 90% of recipients and up to 5–10% of toxic deaths are liver related. Liver injury in the early post-transplant period may be secondary to drug toxicity, SOS, acute GVHD, opportunistic infections, total parenteral nutrition, tumor invasion and cholestatic disorders [3, 41]. Long term liver disease is also a common complication of HSCT, as 57, 5% of survivors developed chronic liver disease (CLD) at 2 years after transplantation in a retrospective series of 106 patients reported by Tomas et al. In this retrospective study, the combination of chronic hepatitis C and IO was presented as the most frequent cause of CLD [41]. On the other hand, chronic GVHD also contributes to liver toxicity. The timing and pattern of LFT abnormalities, history of pre or post transplantation hepatitis, presence of GVHD at other sites and transfusion burden might be helpful in determining the etiology of liver disease. Accurate diagnosis of the etiology of liver dysfunction is generally problematic even though the patterns of biochemical, clinical and histological abnormalities can aid diagnosis. Liver biopsy in patients following HSCT is not without risks, particularly due to thrombocytopenia during the early post-transplant period. The most common indication for liver biopsy is to assess the possibility of GVHD in allo-HSCT in the late post-transplant period with persistently abnormal LFTs and no evidence of GVHD on other sites. In this clinical setting, the sensitivity and specificity of serum ferritin as a marker of IO is not well defined due to its concomitant role as an acute phase reactant [3, 5, 8, 24, 41-43]. Liver biopsy may be performed when atypical clinical features are present or multiple disease processes are likely to occur simultaneously or when there is poor response to therapy that has been instituted [44]. The management of liver dysfunction under these conditions may be complicated as overlap-



ping features often complicate the diagnosis and establishing the correct diagnosis is crucial to institute disease specific therapy. Autopsies performed in 10 patients who died early after HSCT showed iron accumulation in a range equivalent to that of patients suffering from HH [26]. A cumulative cirrhosis incidence of 3, 8% by 20 years after HSCT has been reported previously [8]. This rate seems to be an underestimation as the majority of long term survivors have not been subjected to liver biopsy. In a retrospective study by Sucak et al, severe IO was demonstrated in 75% of 24 liver biopsies which were performed with the presumptive diagnosis of hepatic GVHD in 20 patients with persistent elevation of liver enzymes in the post-transplant setting. The initial clinical diagnosis of GVHD was refuted in 43, 5% of the patients. Median number of post-transplant transfusions, TS and ferritin levels were found to be significantly higher in patients who had histologically proven hepatic IO. A significant correlation between serum ferritin levels and histological grade of iron in the hepatocytes was also demonstrated [10]. In another study by Iqbal et al, the diagnosis obtained at laparoscopic liver biopsies altered targeted therapy in 31% of patients. Iron overload was found in 81, 25% of a total of 32 biopsies [45]. A diagnosis of IO after HSCT was demonstrated based on histological evidence of siderosis found in 52, 4% of liver biopsies performed at 15–110 days post-transplant in another study. Liver biopsies were performed for diagnostic purposes in patients with chronic liver dysfunction. An improvement in LFT was observed in 21 of the 23 patients (91%) with IO who underwent phlebotomy [41]. Namely, IO seems to be underestimated as a cause of liver dysfunction in HSCT setting and liver biopsy which allows disease specific therapy could be life saving.

Hepatic IO may also worsen the natural course of chronic viral hepatitis and the response to antiviral therapy. Fujita et al demonstrated that liver iron deposition was more common in chronic hepatitis C compared to hepatitis B and was associated with liver disease progression. Increased hepatic iron stores in chronic hepatitis C were related to resistance to Interferon/Ribavirin treatment [46]. Thalassaemic patients with liver fibrosis and hepatomegaly who undergo HSCT, have a markedly reduced OS and event free survival compared to patients without evidence of liver disease. The liver disease in these patients is due to a combination of severe IO and chronic viral hepatitis both of which improve with effective iron chelation therapy [19, 26, 47]. Iron is also deposited in other tissues such as myocardium or BM. Slow and spontaneous decrease in iron stores has been reported in thalassaemic children in the years following HSCT. This natural iron depletion could normalize iron stores in individuals with mild siderosis. However, in patients with moderate to severe IO this slow depletion could not prevent the development of liver dysfunction. For this reason, iron depletion protocols have been developed for patients with severe IO [19, 23, 26, 47].

### 2.3.2. Sinusoidal obstruction syndrome (*veno occlusive disease*)

Sinusoidal obstruction syndrome is a treatment related toxicity associated with auto and allo-HSCT which is seen in 6–54 % of the recipients. The severity of SOS ranges from a mild reversible to a progressive course with a mortality rate close to 100% [5, 24].

The role of pre-transplant hyperferritinemia in the development of SOS was first demonstrated by Morado et al in a cohort of 180 auto-HSCT recipients. In this prospective

study, SOS was defined in 12, 2% of patients based on McDonald criteria. Patients with pre-transplant ferritin levels above 300 mg/dl were shown to have a higher risk of developing SOS [48]. In a recent report by Maradei et al, a pre-transplant serum ferritin level above 1000 ng/dl was identified as an independent risk factor for the development of SOS [39]. A retrospective study of 250 HSCT recipients by Sucak et al, in which SOS incidence was reported to be 29, 7%, demonstrated significantly higher pre-transplant serum ferritin levels in patients with SOS [49]. In another study reported by Sucak et al, pre-transplant ferritin levels were found to be higher in HSCT recipients who developed SOS in the post-transplant setting [50]. Serum ferritin may be increased in conditions other than IO in this particular group of patients, including chronic inflammation and infection. Nevertheless, values higher than 1000 ng/ml were rarely reported in these inflammatory conditions [1, 25, 29, 39, 48-51].

Iron induced hepatotoxicity is multifactorial which involves oxidative stress and modulation of gene expression of Kupffer cells. Cellular injury is induced by iron generated ROS and peroxidation of lipid membranes [39]. Risk factors associated with the development of SOS are defined as preexisting liver dysfunction, previous abdominal irradiation, high dose total body irradiation, high dose preoperative regimens, advanced disease and HLA mismatch or unrelated HSCT. The typical hepatocellular lesion of SOS mainly occurs in zone 3 of hepatic acines including a characteristic endothelial lesion which is shown to be associated with hypercoagulability. The oxidant effect of iron on endothelial and hepatocyte membranes mediated by ROS contributes to the development of these typical lesions of SOS [48, 50]. The risk of SOS is higher in carriers of at least one allele of the hemochromatosis gene, HFE, which predisposes to iron deposition in the liver [24].

### 2.3.3. Infections

Patients with HH and other diseases with IO are considered to be more susceptible to infections, as iron adversely affects the phagocytic, chemotactic and bactericidal capacity of granulocytes and monocytes and inhibits the activity of natural killer cells and macrophages [35, 52]. A number of studies have demonstrated the adverse impact of IO on the development of infections in HSCT recipients. Tachibana et al observed an association between IO and blood stream infections (BSI) in 114 patients who underwent allo-HSCT. They found that pre-transplant serum ferritin levels significantly predicted BSI within the 100-day period after allo-HSCT [1]. A direct correlation between hepatic IO and BSI was demonstrated in a retrospective cohort of 154 allo-HSCT recipients, as patients with hepatic IO tended to experience more frequent and prolonged episodes of lethal BSI [53]. Altes et al reported a ferritin level above 1500 µg/l was associated with the occurrence of bacteremia and febrile days in first 3 months after auto-HSCT [27]. A prospective study investigated the risk factors for 140 early infection episodes which occurred in 367 multiple myeloma (MM) patients undergoing auto-HSCT. Bone marrow iron stores were identified as significant risk factors for early severe infections [54]. Pre-transplant serum ferritin levels were demonstrated to be associated with fungal infections after allo-HSCT in several studies [33-35, 49, 55, 56]. Tunçcan et al identified the predictive role of pre-transplant serum ferritin level in the development of

hepatosplenic candidiasis among 255 HSCT recipients. Hepatosplenic candidiasis was diagnosed in 6 (2, 3%) patients. Pre-transplant serum ferritin levels were significantly higher in patients with hepatosplenic candidiasis [55]. Özyilmaz et al studied the relationship between serum ferritin level and pulmonary fungal infections in 148 allo – HSCT recipients. In this study, the sensitivity and specificity of ferritin > 1000 ng/ml for the prediction of fungal pulmonary infections were found to be 67% and 70%, respectively [56].

#### 2.3.4. Idiopathic Pneumonia Syndrome (IPS)

Idiopathic pneumonia syndrome comprises a group of disorders that result in interstitial pneumonitis and/or widespread alveolar injury with an incidence of 2–8 % and a mortality of up to 70% in the HSCT setting. There is increasing evidence implicating ROS and pro-inflammatory events as major contributing factors to IPS [5, 24]. The mechanism of iron induced IPS probably involves endothelial injury by catalytically active iron released from heme groups, which can trigger a cascade of events leading to acute lung injury and pulmonary fibrosis [24]. Currently, there are no studies regarding the direct association of IO and IPS, except the oxidative milieu, which is partly a consequence of IO.

#### 2.3.5. Graft-versus-host disease (GVHD)

The role of IO in the pathogenesis of GVHD has been evaluated in a number of studies. There are conflicting results regarding the relationship between IO and GVHD in HSCT recipients. In a prospective cohort of 190 allo – HSCT recipients reported by Pullarkat et al, the effect of elevated pre-transplant ferritin on acute GVHD was assessed. Grade 2 or above acute GVHD was diagnosed in 48% of patients. Acute GVHD was more frequent in patients with high ferritin levels ( $\geq 1000$  ng/ml). This was attributed to the increased ROS mediated injury on exposure to the conditioning regimen in iron overloaded patients, as antigen exposition following tissue injury was indicated to be the initiating event in the pathogenesis of GVHD [38]. Similarly in a report by Platzbecker et al, which was performed in 172 patients with MDS, transfusion burden reflected by ferritin levels, was found to be correlated with a higher probability of acute GVHD [57]. On the other hand, Mahindra et al investigated 222 patients who underwent myeloablative allo-HSCT and demonstrated that pre-transplant ferritin level  $> 1910$   $\mu\text{g/l}$  was associated with decreased incidence of chronic GVHD [58]. Furthermore, in a study of 264 patients who underwent allo-HSCT for various hematological malignancies, no significant difference in the cumulative incidence of acute and chronic GVHD was demonstrated in high ( $\geq 599$  ng/ml) and low ( $< 599$  ng/ml) ferritin groups [59]. Alessandrino et al reported that transfusion dependency was an independent risk factor for the development of acute GVHD, but not for chronic GVHD [60]. On the other hand, IO might as well mimic GVHD resulting in unnecessary continuation or intensification of immunosuppressive therapy for GVHD [18]. Apart from hepatocellular, cardiac and other organ dysfunction, IO may worsen the natural course of liver GVHD, similar to the status with chronic hepatitis and its response to therapy [3, 18, 23, 51, 57]. It is speculated that intestinal iron absorption is increased as a result of epithelial injury related to chemotherapy or GVHD. Suggesting

that IO might be the consequence rather than being the cause of intestinal GVHD [23]. The liver and the intestinal mucosa, which express essential iron regulatory genes including hepatic antimicrobial protein (HAMP), the gene that encodes hepcidin and ferroportin 1, are targets of conditioning related toxicity as well as GVHD, initiated by donor derived T lymphocytes. The ensuing release of cytokines including IL-6, might directly affect the expression of hepcidin as IL-6 is a potent inducer of hepcidin via STAT3 [61]. Graft versus host disease also involves the interaction of Fas ligand expressed on activated donor T lymphocytes with host tissue including enterocytes and hepatocytes. T lymphocyte induced tissue damage disrupts iron homeostasis leading to uncontrolled iron accumulation which may aggravate tissue damage related to the development of GVHD and infections [15]. The pattern of the relationship between IO and GVHD remains to be confirmed in future studies.

#### **2.4. Prognostic role of iron overload in stem cell transplantation**

Several recent reports demonstrated that IO is an adverse prognostic factor for patients undergoing allo-HSCT [1, 17, 22, 36, 59, 62-66]. In a retrospective cohort of 114 AML and MDS patients, the OS rate at 5 years was found to be significantly better in patients with ferritin levels < 1000 ng/ml [1]. Tanaka et al evaluated the outcome of 47 patients with acute leukemia or MDS who underwent reduced intensity HSCT. High ferritin level which was defined as >1000 ng/ml was associated with worse 2 year OS on multivariate analysis [62]. Another study by the same group demonstrated the adverse impact of elevated ferritin levels on 5 year OS in a cohort of 143 patients with acute lymphoblastic leukemia (ALL) and acute myeloblastic leukemia (AML) who received allo-HSCT with myeloablative and non myeloablative conditioning regimens [63]. Transfusion dependency, predicted by serum ferritin levels, was found to be independently associated with reduced OS and increased NRM in a retrospective cohort of 357 MDS patients undergoing allo-HSCT [60]. The transplant iron score which included serum ferritin level above 1000 ng/ml was tested in 78 patients who received allo or auto-HSCT. The independent impact of IO on transplant survival was indicated with the most pronounced predictive power of the iron score restricted to allo-HSCT recipients. A high iron score ( $\geq 2$ ) was associated with 50% absolute decrease in OS at 1 year [67]. Lim et al reported the adverse impact of elevated serum ferritin on OS in 99 MDS patients who underwent reduced intensity HSCT [64]. Altes et al demonstrated that serum ferritin levels  $\geq 3000$   $\mu\text{g/l}$  and TS  $\geq 100\%$  were associated with a decreased OS and increased TRM, which was attributed to a high infectious mortality [32]. On the other hand Pullarkat et al analyzed 190 patients and demonstrated that elevated pre-transplant ferritin levels were associated with increased risk of death and day 100 mortality, mainly due to acute GVHD and infections [38]. Mahindra et al demonstrated a pre-transplant serum ferritin > 685 ng/ml was associated with lower OS and relapse free survival in 315 patients with Hodgkin and non Hodgkin lymphoma who received auto-HSCT, whereas same ferritin level exhibited a higher incidence of relapse and relapse mortality. They identified the baseline ferritin level was best correlated with poor survival. They concluded that elevated iron stores may also increase tumor growth, as tumor cells require more iron for DNA synthesis due to rapid proliferation [36]. Same group confirmed their results in a study of 222 allo-HSCT recipients

with a serum ferritin level  $>1910 \mu\text{g/l}$  associated with lower OS, lower relapse free survival and higher NRM rates [58]. Furthermore they demonstrated inferior survival rates related to higher rates of TRM and relapse mortality in patients with elevated ferritin levels who received non myeloablative conditioning [37]. In a large retrospective study by Armand et al, an elevated pre-transplant serum ferritin level was significantly associated with lower OS and disease free survival. This association was particularly restricted to patients with acute leukemia and MDS which was particularly attributed to transfusion load. They suggested a possible role of iron chelation therapy in the pre and post - transplant setting, as they showed an absolute difference of 37% in 5-year OS for patients with MDS between the highest and lowest ferritin quartiles [66]. Sucak et al demonstrated an adverse impact of a pre-transplant serum ferritin level  $>500 \text{ ng/ml}$  on OS and TRM in 250 patients who received auto and allo-HSCT, underscoring the prognostic effect of IO in auto transplants [49]. The same group confirmed their results with a more toxic form of iron, NTBI, in a retrospective cohort of 149 patients. In concordance with the previous report, a significant impact of NTBI on day 30 and day 100 survival was shown in auto-transplanted patients for the first time in iron and transplant connection [29]. Notwithstanding, in a prospective study by Armand et al, pre-transplant IO predicted by LIC which is considered to be the gold standard indicator of IO, was not found to be associated with increased mortality, relapse, SOS or GVHD [68]. Therefore, they assumed that the adverse prognostic impact of pre-transplant hyperferritinemia may be related to factors independent of IO. Taken together, it is speculated that ferritin may be prognostic not because it reflects iron stores but because it is an acute phase reactant [68, 69].

## 2.5. Diagnosis of iron overload

### 2.5.1. Liver biopsy

Liver remains to be the most accessible parenchymal organ that can be used to estimate tissue iron load after HSCT. Iron overload is not uncommonly seen in various other primary liver diseases such as alcoholic liver disease, chronic viral hepatitis, non alcoholic steatohepatitis, liver cirrhosis and HH. Histological evaluation of liver specimens is essential in the management of these disorders. The reported incidence of significant liver fibrosis in HSCT recipients varies from 5% to 80% and LIC has been demonstrated to have a particular role in the progression of fibrosis [26, 41, 70]. Though ferritin continues to be the mainstay for the initial clinical evaluation of IO, liver biopsy is still the gold standard for quantifying iron. Measurement of hepatic iron stores provides the most reliable estimate of body iron burden. Liver iron content exceeding  $80 \text{ mcmol/g}$  of liver dry weight was found to be consistent with IO with a hepatic index greater than 1,  $9 \text{ mmol/kg/year}$ . However, the need for a relatively large volume of tissue as well as its invasive nature has made this procedure less appealing to most clinicians and patients [4, 9, 53]. Although liver biopsy is an invasive procedure and can not be safely administered in patients with very low platelet counts, a liver biopsy can be advantageous in some HSCT recipients as it can also exclude alternative causes of hepatic dysfunction, such as infections and GVHD. In high risk patients, liver biopsy using a transjugular approach may be a feasible alternative to percutaneous biopsy [4, 17].

### 2.5.2. *Non-invasive procedures*

Superconducting quantum interference device (SQUID) assesses total body iron by using biomagnetic susceptometry. Ferritin and hemosiderin are the only paramagnetic materials in the human body, thus the magnitude of these parameters is directly related to the amount of iron in a certain volume of tissue. The device utilizes the magnetic property of iron in ferritin and hemosiderin to estimate hepatic iron stores. Furthermore, it is considered to be the non invasive reference standard for estimation of LIC as it has an excellent correlation with liver biopsy. However, widespread clinical use is limited by its cost, complexity and very limited availability [4, 9, 17].

Liver iron content measurement has limited predictive value for extrahepatic iron deposition. The liver is the dominant iron reservoir for the body, accounting for more than 80% of the total body iron and has high capacity mechanisms for clearing both transferrin and NTBI species from the circulation. The heart and endocrine tissues have tightly regulated transferrin uptake and develop IO only when there is circulating NTBI. High liver iron (15-20 mg/g dry weight) damages liver parenchyma and increases circulating NTBI levels dramatically. As no liver iron can be considered safe from a cardiac and endocrinological perspective, extrahepatic monitoring by magnetic resonance imaging (MRI) is essential [71]. Magnetic resonance imaging becomes increasingly important in the evaluation of iron status as it is non invasive, more rapidly and widely available. Designating liver iron by older MRI techniques and equipment showed variable correlation with the biopsy estimates of LIC. More recent MRI techniques T2\* and R2\* MRI are reproducible methods for non invasive estimation of LIC with reported sensitivity and specificity of 89% and 80%, respectively [4, 17, 72-74]. It has the additional benefit of identifying relatively early IO within organs prior to the onset of dysfunction. Magnetic resonance imaging can be used to co-measure iron deposition within the heart, liver and pituitary gland as it does not appear that a single organ gives the full picture of total body IO. In fact, patients can accumulate cardiac iron, despite apparently normal hepatic iron levels and thus be at risk for arrhythmia or congestive heart failure. The discordance of values in two tissues can be resolved with the use of MRI to detect cardiac iron. Cardiovascular MRI could potentially be used not only to determine myocardial iron content but also cardiac function and therefore could be used to investigate the effects of iron mediated organ damage. Non invasive measurement of LIC has also been achieved using an MRI technique based on the proton transverse relaxation rates within the liver. The technique can be implemented on, most clinical 1, 5-T MRI measurements, making it readily available to the clinical community. This technique resulted in a high specificity and sensitivity over a greater range of LIC than any other MRI-based method of LIC assessment [9].

### 2.5.3. *Ferritin*

High prevalence of IO in long term survivors of HSCT emphasizes the need for routine screening for IO in this population. Ferritin is a cellular iron storage protein that buffers iron in a soluble and non toxic form. Under normal conditions ferritin levels in the serum are low but steadily increase in conditions of IO. Therefore, assessment of serum ferritin levels serves as a simple and widely used surrogate marker for IO. Serum ferri-

tin levels are however subject to natural fluctuation and can also be greatly affected by a range of inflammatory conditions that are particularly relevant in HSCT recipients. Although being a useful test for initial screening of IO in HSCT recipients, serum ferritin is not a reliable indicator of total body iron burden particularly in patients who have ongoing acute infections or inflammatory diseases [2, 4, 17, 20, 22, 23, 38, 75, 76]. Serial serum ferritin measurements can compensate the potential fluctuations and help to establish a general picture of IO over time. Nevertheless, at 1 year after-transplantation when inflammatory stress has largely subsided, most patients have a serum ferritin of <1000 ng/ml and no clinical evidence of IO; serum ferritin in these patients decline slowly with time [23]. Unlike tissue ferritin a substantial proportion of serum ferritin is glycosylated which suggests that plasma ferritin is actively secreted from reticuloendothelial system or parenchymal cells. Serum ferritin in contrast to tissue ferritin was claimed to have a low iron content even in iron loaded patients in some earlier studies. It is therefore claimed that serum ferritin does not provide a major source of hepatic iron either in normal individuals or in patients with IO diseases [4, 20, 22, 23, 75]. On the contrary a direct correlation between serum ferritin levels and transfusion burden has been observed with a level of 1000 ng/ml after a median of 21 PRBC transfusions. Thus repeated measurement of serum ferritin levels seems to be a valid method to monitor secondary IO in patients with transfusion dependent anemias and MDS [17]. Majhail et al studied the prevalence of IO in 56 allo-HSCT recipients and demonstrated the poor predictive value of ferritin for estimating LIC. The overall prevalence of IO was 32%. Clinically significant IO (LIC>7 mg/g) was uncommon in patients with serum ferritin levels less than 1000 ng/ml. However, the LIC on MRI was moderately correlated with serum ferritin. As a result, they indicated ferritin to be a good screening test but a poor predictor of tissue IO and recommended estimation of LIC before initiating chelation therapy. They considered that this lack of association between ferritin and LIC might be related to the variability in ferritin levels because of ineffective erythropoiesis or underlying inflammation or infection [20]. Whereas in a study by Bazuave et al, serum ferritin, transferrin, TS, iron, soluble transferrin receptor (sTfR) and C reactive protein levels in 230 HSCT recipients were measured. All iron parameters were found to be significantly associated with survival. A combination of ferritin and TS was shown to have the highest prognostic power. They concluded that the predictive power of ferritin was derived from its association with IO rather than inflammation. Inferior survival in patients with IO was related to both TRM and relapse. As sTfR and TS were found to have superior prognostic value when compared to ferritin, they suggested to combine serum ferritin with TS for prediction of IO [2].

Recent evidence suggests that the determination of iron status before HSCT has important prognostic implications. There is a gap between the time that patients are identified for HSCT and the time that actual transplant takes place. During this period, most patients stay transfusion dependent. After patients are exposed to conditioning regimen and stem cell infusion, serum ferritin levels are prone to a false elevation due to its role as an acute phase reactant. Thus, accurate evaluation and diagnosis of iron toxicity after HSCT remains as a challenge [53, 67] [Table 3].

Diagnostic Test	Advantages	Disadvantages
Liver Biopsy	Reference method, can assess degree of hepatic fibrosis, can evaluate other causes of hepatic dysfunction (GVHD)	Invasive procedure, not feasible in patients with thrombocytopenia or coagulopathy
SQUID	Good correlation with liver biopsy, noninvasive	Very limited availability
MRI	Good correlation with liver biopsy (T2 or R2 MRI), noninvasive, widely available	Variety of MRI techniques have not been validated with liver biopsy, contraindications (metal implants, claustrophobia)
Serum ferritin and TS	Noninvasive, widely available	Sensitive but not specific for IO, poor correlation with liver biopsy

**Table 3.** Diagnostic Tests for Assessment of Body Iron Stores in HSCT Recipients [4]

#### 2.5.4. Non Transferrin Bound Iron (NTBI)

Non transferrin bound iron is toxic to living systems because it can act as a catalyst in the formation of ROS which in turn stimulate lipid peroxidation in membranes. In iron-overloaded states when SIBC becomes fully saturated, NTBI complexes appear in the serum. In a study by Harrison et al, serum ferritin was raised in 21 of 28 patients following treatment for hematological malignancy, whereas only 16% of them had LFT abnormalities. However, NTBI was detected in 4 of 6 patients with an unexplained elevated LFTs. Therefore, they considered that NTBI might be a more specific indicator of IO than the serum ferritin concentrations [77]. Assessment of NTBI is a potentially useful approach that allows the estimation of toxic iron levels. However, the methods for determining this free fraction of body iron and its precise prognostic significance require fine tuning [17].

#### 2.6. Treatment of iron overload

The current paradigm of managing post-transplant IO is based on extensive experience in children with transfusion dependent anemias [4]. Post-transplant iron depletion therapy has been shown to reverse hepatic fibrosis and cardiomyopathy in patients with thalassemia [4, 78]. However, there is no published data indicating the benefit of iron removal therapy on long term morbidity and mortality in HSCT recipients, especially for diseases other than thalassemia [4].

Decisions regarding the management of IO should be individualized and based on a review of several factors including the need for ongoing PRBC transfusion therapy, time since transplantation, ability to tolerate iron depleting therapy and urgency to reduce body iron stores [Table 4]. For instance, coexisting anemia can preclude the use of phlebotomy whereas renal impairment might increase the risk of toxicity from iron chelating drugs. Also depletion of iron stores would be more imperative in patients with IO related liver test abnormalities or cardiac dysfunction compared to those without end organ toxicities [4].



Modality	Advantages	Disadvantages
Phlebotomy	Extensive experience with proven efficacy, no significant side effects	Not feasible in patients with anemia or poor venous access
Deferoxamine	Extensive experience with proven efficacy	Inconvenient administration route and schedule, side effects (ototoxicity, growth retardation)
Deferiprone	Oral iron chelator	Unproven efficacy, side effects (neutropenia, hepatic fibrosis)
Deferasirox	Oral iron chelator, efficacy similar to deferoxamine	Long term toxicity profile not established, side effects (nephrotoxicity)

**Table 4.** Treatment Options for Iron Overload after HSCT [4]

Iron overload may be a cause of persistent hepatic dysfunction after HSCT. Patients with LIC > 15 mg/g dry weight should be treated aggressively with both phlebotomy and chelation; when LIC is 7–15 mg/g dry weight, phlebotomy is indicated; when LIC is under 7 mg/g dry weight treatment is indicated only if there is evidence of liver disease. Mobilization of iron from heavily overloaded patients improves cardiac function, normalizes serum alanine transaminase levels and results in improved liver histology [24, 79].

In patients with extreme IO, effective pre-transplant chelation therapy is suggested to improve post-transplant survival, as IO is clearly related to treatment related morbidity and mortality after HSCT [4, 24, 67, 79]. In the pre-transplant period vigorous iron chelation may be important but prospective studies are required to prove a survival benefit after HSCT. In the post-transplant period phlebotomy sometimes combined with erythropoiesis stimulating agents (ESA) may be successfully applied in thalassemia. For those patients who can not be phlebotomized iron chelation can be considered. Prospective studies of the impact of iron chelation therapy before and after HSCT on post-transplant morbidity and mortality are mandatory [4, 24].

The American Society for Blood and Marrow Transplantation (ASBMT) 2012 guidelines recommend annual serum ferritin measurement in patients who received PRBC transfusions pre or post-transplantation. Subsequent monitoring with serum ferritin should be considered among patients with elevated levels, especially in the presence of abnormal LFTs, PRBC transfusions or HCV infection. Additional diagnosing testing including liver biopsy, MRI or SQUID may be indicated if therapy is intended for presumptive IO. Current prescribing guidelines recommend continuation of iron reduction till ferritin levels are below 500 ng/ml [3, 9, 51, 60, 72].

### 2.6.1. Phlebotomy

Phlebotomy is a feasible option for the treatment of IO following HSCT. Many studies have documented its efficacy in early and late post-transplant setting. It has been shown that sub-clinical left ventricular diastolic dysfunction and impaired left ventricular contractility in patients with thalassemia may be reversed by phlebotomy initiated after HSCT [51]. Iron

overload should be treated by means of phlebotomy and/or chelation therapy especially when IO coexists with chronic viral hepatitis. Phlebotomy has the advantage over chelation of better compliance, fewer side effects and lower costs. The use of ESA may facilitate the success of this strategy in patients with low hemoglobin levels [4, 19, 22, 26, 70].

After normalization of transaminases and serum ferritin with aggressive phlebotomy, maintenance phlebotomy is required every 3–6 months to prevent iron reaccumulation and keep serum ferritin in a low normal range. The gradual rise in ferritin after successful iron depletion suggests that there is a signal for increased iron absorption and the signal persists well beyond the peri-transplant period. It may be that post-transplant immunosuppressants reduce the level of cytokines that normally stimulate hepcidin production and allow increased absorption of dietary iron. In addition hepatic GVHD may result in disordered hepcidin regulation, as it likely does in chronic viral hepatitis and might explain increased risk of IO and the need for maintenance phlebotomy after successful iron depletion [23].

### 2.6.2. Iron chelation

Treatment with phlebotomy is not possible in patients who are transfusion dependent. Chelation may be preferred for iron depletion [9]. There are limited data on the pharmacological chelation of iron during the post-transplant period including the safety, optimal dose, time for initiation of treatment and duration of therapy [51, 80, 81].

Deferoxamine, the first available iron chelator, has a proven efficacy and safety with decades of experience and has also been studied in HSCT recipients. Recommended treatment schedule is at least 5 nights per week subcutaneous delivered via a pump for 8–12 hours [4, 9]. It is effective in lowering serum ferritin levels and LIC and prevents endocrinological complications. Long term treatment is also associated with a reduction in cardiac complications and improved survival. Redness and induration at the infusion site are the most common side effects. Audiological, ophthalmological, growth and bone toxicities may be minimized by avoiding overchelation. Deferoxamine treatment in the HSCT setting is complicated by the short half life and the ability to release iron to bacteria and fungi. Deferoxamine supports the growth of zygomycetes because it acts as xeno-sidephore delivering iron to iron uptaking molecules of the species [22, 51, 81]. The greatest challenge with DFO is patient adherence with therapy because the need for parenteral administration is cumbersome, uncomfortable, inconvenient and time consuming [51]. Cardiac morbidity and mortality continue to occur in patients treated with DFO, likely related to difficulties with adherence [4, 9, 22, 51, 81].

Deferiprone is an oral iron chelator which was first identified in 1980s and subsequently approved for clinical use in Canada and Europe especially when DFO is contraindicated. Deferiprone is not commercially available in all countries and has not been investigated in HSCT recipients. It has a short half life of only 1, 5 hours and thus requires 3 times daily dosing. Unfortunately, it does not control liver iron as effective as DFO even after years of continued treatment. In contrast, a recent study in patients with thalassemia showed better myocardial function in those receiving Deferiprone. Retrospective studies have also demonstrated reduced cardiac morbidity and mortality and lower myocardial iron deposition among patients

treated with Deferiprone compared with DFO and Deferasirox (DFX). A reduction or stabilization of serum ferritin levels and LIC in most patients with transfusional IO was demonstrated. The high risk of agranulocytosis necessitates weekly blood monitoring. Thus, toxicity profile of the drug may be inappropriate for transplant recipients [4, 9, 81].

A novel oral iron chelator, DFX was approved by the US Food and Drug Administration in 2005 and represents a significant advancement in the treatment of IO. It is a tridentate oral iron chelator which is lipid soluble but highly protein bound. It has a plasma half life about 12 hours and thus is ideal for once daily dosing. It binds iron in a 2/1 ratio. It is excreted by the hepatobiliary system and the chelated iron is excreted via the feces. The effective dose is between 20-40 mg/kg. It is generally well tolerated by patients although some dose modifications may be necessary for diarrhea. Phase III trials demonstrated that DFX at 20-30 mg/kg/day led to the maintenance or reduction of iron burden as measured by LIC in chronically transfused patients. Reductions in LIC and serum ferritin are similar to those found in the subcutaneous use of DFO. Commonly reported side effects include skin rash, nausea, vomiting and diarrhea and elevations in serum creatinine levels, which may be important in patients treated with calcineurin inhibitors. Gastrointestinal disturbances often improve with continued administration of the drug. Elevations in serum creatinine occur in approximately 1/3 of subjects. Side effects associated with DFX therapy may overlap or exacerbate early complications such as calcineurin induced renal injury seen after allo-HSCT, which makes it complicated to use early after HSCT. The availability of an oral iron chelator has simplified the treatment of IO, but more experience with its use in HSCT recipients is needed [4, 9, 22, 80, 81].

### 3. Conclusion

The role of IO in HSCT recipients and guidelines for screening strategies warrants further studies. The value of routine screening for IO, the method of determining it, whether it should be with serum ferritin, by determining LIC with non invasive MRI or biopsy and identifying a subgroup of patients who might benefit from phlebotomy and/or iron chelating agents requires future prospective studies. The possibility of IO should be considered in patients who are candidates for HSCT. Red blood cell transfusion should be limited whenever possible and chelation and/or phlebotomy should be considered in the course of documented IO. pre-transplant preventive measures should also be adopted to avoid IO and improve survival in these patients.

### Author details

Zeynep Arzu Yegin<sup>1</sup>, Gülsan Türköz Sucak<sup>1</sup> and Taner Demirer<sup>1</sup>

\*Address all correspondence to: [Taner.Demirer@medicine.ankara.edu.tr](mailto:Taner.Demirer@medicine.ankara.edu.tr)

<sup>1</sup> Gazi University Faculty of Medicine, Department of Hematology, Ankara, Turkey

Ankara University Faculty of Medicine, Department of Hematology, Ankara, Turkey

## References

- [1] Tachibana T, Tanaka M, Takasaki H, Numata A, Ito S, Watanabe R, Hyo R, Ohshima R, Hagihara M, Sakai R, Fujisawa S, Tomita N, Fujita H, Maruta A, Ishigatsubo Y, Kanamori H. Pretransplant serum ferritin is associated with bloodstream infections within 100 days of allogeneic stem cell transplantation for myeloid malignancies. *Int J Hematol* 2011;93(3):368-374.
- [2] Bazuaye GN, Buser A, Gerull S, Tichelli A, Stern M. Prognostic impact of iron parameters in patients undergoing allo-SCT. *Bone Marrow Transplant* 2012; 47(1):60-64.
- [3] Majhail NS, Rizzo JD, Lee SJ, Aljurf M, Atsuta Y, Bonfim C, Burns LJ, Chaudhri N, Davies S, Okamoto S, Seber A, Socie G, Szer J, Van Lint MT, Wingard JR, Tichelli A; Center for International Blood and Marrow Transplant Research (CIBMTR); American Society for Blood and Marrow Transplantation (ASBMT); European Group for Blood and Marrow Transplantation (EBMT); Asia-Pacific Blood and Marrow Transplantation Group (APBMT); Bone Marrow Transplant Society of Australia and New Zealand (BMTSANZ); East Mediterranean Blood and Marrow Transplantation Group (EMBMT); Sociedade Brasileira de Transplante de Medula Ossea (SBTMO). Recommended screening and preventive practices for long-term survivors after hematopoietic cell transplantation. *Biol Blood Marrow Transplant* 2012;18(3):348-371.
- [4] Majhail NS, Lazarus HM, Burns LJ. Iron overload in hematopoietic cell transplantation. *Bone Marrow Transplant* 2008;41(12):997-1003.
- [5] Evens AM, Mehta J, Gordon LI. Rust and corrosion in hematopoietic stem cell transplantation: the problem of iron and oxidative stress. *Bone Marrow Transplant* 2004;34(7):561-571.
- [6] Carreras E. Early complications after HSCT. In: Apperley J, Carreras E, Gluckman E, Masszi T. *Haematopoietic Stem Cell Transplantation*. Chapter 11; 2012 Revised Edition. p177-194.
- [7] Tichelli A, Socie G on behalf of the Late Effects Working Party of the EBMT. Late effects in patients treated with HSCT. In: Apperley J, Carreras E, Gluckman E, Masszi T. *Haematopoietic Stem Cell Transplantation*. Chapter 15; 2012 Revised Edition. p249-269.
- [8] Strasser SI, Sullivan KM, Myerson D, Spurgeon CL, Storer B, Schoch HG, Murakami CS, McDonald GB. Cirrhosis of the liver in long-term marrow transplant survivors. *Blood* 1999;93(10):3259-3266.
- [9] Knovich MA, Storey JA, Coffman LG, Torti SV, Torti FM. Ferritin for the clinician. *Blood Rev* 2009;23(3):95-104.
- [10] Sucak GT, Yegin ZA, Ozkurt ZN, Aki SZ, Karakan T, Akyol G. The role of liver biopsy in the workup of liver dysfunction late after SCT: is the role of iron overload underestimated? *Bone Marrow Transplant*. 2008;42(7):461-467.

- [11] Emerit J, Beaumont C, Trivin F. Iron metabolism, free radicals, and oxidative injury. *Biomed Pharmacother* 2001;55(6):333-339.
- [12] Lee DH, Jacobs DR Jr. Serum markers of stored body iron are not appropriate markers of health effects of iron: a focus on serum ferritin. *Med Hypotheses* 2004;62(3):442-445.
- [13] Gordon LI, Brown SG, Tallman MS, Rademaker AW, Weitzman SA, Lazarus HM, Kelley CH, Mangan C, Rubin H, Fox RM, et al. Sequential changes in serum iron and ferritin in patients undergoing high-dose chemotherapy and radiation with autologous bone marrow transplantation: possible implications for treatment related toxicity. *Free Radic Biol Med* 1995;18(3):383-389.
- [14] Deugnier Y, Brissot P, Loréal O. Iron and the liver: update 2008. *J Hepatol* 2008;48 Suppl 1:S113-123.
- [15] Deeg HJ, Spaulding E, Shulman HM. Iron overload, hematopoietic cell transplantation, and graft-versus-host disease. *Leuk Lymphoma* 2009;50(10):1566-1572.
- [16] Ma AD, Gordeuk VR. Iron metabolism, iron overload and the porphyrias. In: *American Society of Hematology Self Assessment Program*. Chapter 4; 2010. p93-108.
- [17] Malcovati L. Impact of transfusion dependency and secondary iron overload on the survival of patients with myelodysplastic syndromes. *Leuk Res* 2007;31 Suppl 3:S2-6.
- [18] Kamble RT, Selby GB, Mims M, Kharfan-Dabaja MA, Ozer H, George JN. Iron overload manifesting as apparent exacerbation of hepatic graft-versus-host disease after allogeneic hematopoietic stem cell transplantation. *Biol Blood Marrow Transplant* 2006;12(5):506-510.
- [19] Socié G, Salooja N, Cohen A, Rovelli A, Carreras E, Locasciulli A, Korthof E, Weis J, Levy V, Tichelli A; Late Effects Working Party of the European Study Group for Blood and Marrow Transplantation. Nonmalignant late effects after allogeneic stem cell transplantation. *Blood* 2003;101(9):3373-3385.
- [20] Majhail NS, DeFor T, Lazarus HM, Burns LJ. High prevalence of iron overload in adult allogeneic hematopoietic cell transplant survivors. *Biol Blood Marrow Transplant* 2008;14(7):790-794.
- [21] Majhail NS, DeFor TE, Lazarus HM, Burns LJ. Iron-overload after autologous hematopoietic cell transplantation. *Leuk Res* 2009;33(4):578-579.
- [22] Pullarkat V. Iron overload in patients undergoing hematopoietic stem cell transplantation. *Adv Hematol* 2010;2010. pii: 345756.
- [23] Kamble R, Mims M. Iron-overload in long-term survivors of hematopoietic transplantation. *Bone Marrow Transplant* 2006;37(8):805-806.
- [24] De Witte T. The role of iron in patients after bone marrow transplantation. *Blood Rev* 2008;22 Suppl 2:S22-28.

- [25] Koreth J, Antin JH. Iron overload in hematologic malignancies and outcome of allogeneic hematopoietic stem cell transplantation. *Haematologica* 2010;95(3):364-366.
- [26] Strasser SI, Kowdley KV, Sale GE, McDonald GB. Iron overload in bone marrow transplant recipients. *Bone Marrow Transplant* 1998;22(2):167-173.
- [27] Altes A, Remacha AF, Sarda P, Baiget M, Sureda A, Martino R, Briones J, Brunet S, Canals C, Sierra J. Early clinical impact of iron overload in stem cell transplantation. A prospective study. *Ann Hematol* 2007;86(6):443-447.
- [28] Sahlstedt L, Ebeling F, von Bonsdorff L, Parkkinen J, Ruutu T. Non-transferrin-bound iron during allogeneic stem cell transplantation. *Br J Haematol* 2001;113(3):836-838.
- [29] Yegin ZA, Paşaoğlu H, Aki SZ, Özkurt ZN, Demirtaş C, Yağci M, Acar K, Sucak GT. Pro-oxidative/antioxidative imbalance: a key indicator of adverse outcome in hematopoietic stem cell transplantation. *Int J Lab Hematol* 2011;33(4):414-423.
- [30] Dürken M, Nielsen P, Knobel S, Finckh B, Herrnring C, Dresow B, Kohlschütter B, Stockschräder M, Krüger WH, Kohlschütter A, Zander AR. Nontransferrin-bound iron in serum of patients receiving bone marrow transplants. *Free Radic Biol Med* 1997;22(7):1159-1163.
- [31] Dürken M, Herrnring C, Finckh B, Nagel S, Nielsen P, Fischer R, Berger HM, Moison RM, Pichlmeier U, Kohlschütter B, Zander AR, Kohlschütter A. Impaired plasma antioxidative defense and increased nontransferrin-bound iron during high-dose chemotherapy and radiochemotherapy preceding bone marrow transplantation. *Free Radic Biol Med* 2000;28(6):887-894.
- [32] Altès A, Remacha AF, Sureda A, Martino R, Briones J, Canals C, Brunet S, Sierra J, Gimferrer E. Iron overload might increase transplant-related mortality in hematopoietic stem cell transplantation. *Bone Marrow Transplant* 2002;29(12):987-989.
- [33] Altes A, Remacha AF, Sarda P, Sancho FJ, Sureda A, Martino R, Briones J, Brunet S, Canals C, Sierra J. Frequent severe liver iron overload after stem cell transplantation and its possible association with invasive aspergillosis. *Bone Marrow Transplant* 2004;34(6):505-509.
- [34] Kontoyiannis DP, Chamilos G, Lewis RE, Giralt S, Cortes J, Raad II, Manning JT, Han X. Increased bone marrow iron stores is an independent risk factor for invasive aspergillosis in patients with high-risk hematologic malignancies and recipients of allogeneic hematopoietic stem cell transplantation. *Cancer* 2007;110(6):1303-1306.
- [35] Maertens J, Demuyneck H, Verbeken EK, Zachée P, Verhoef GE, Vandenberghe P, Boogaerts MA. Mucormycosis in allogeneic bone marrow transplant recipients: report of five cases and review of the role of iron overload in the pathogenesis. *Bone Marrow Transplant* 1999;24(3):307-312.
- [36] Mahindra A, Bolwell B, Sobecks R, Rybicki L, Pohlman B, Dean R, Andresen S, Sweetenham J, Kalaycio M, Copelan E. Elevated ferritin is associated with relapse af-

- ter autologous hematopoietic stem cell transplantation for lymphoma. *Biol Blood Marrow Transplant* 2008;14(11):1239-1244.
- [37] Mahindra A, Sobecks R, Rybicki L, Pohlman B, Dean R, Andresen S, Kalaycio M, Sweetenham J, Bolwell B, Copelan E. Elevated pretransplant serum ferritin is associated with inferior survival following nonmyeloablative allogeneic transplantation. *Bone Marrow Transplant* 2009;44(11):767-768.
- [38] Pullarkat V, Blanchard S, Tegtmeier B, Dagens A, Patane K, Ito J, Forman SJ. Iron overload adversely affects outcome of allogeneic hematopoietic cell transplantation. *Bone Marrow Transplant* 2008;42(12):799-805.
- [39] Maradei SC, Maiolino A, de Azevedo AM, Colares M, Bouzas LF, Nucci M. Serum ferritin as risk factor for sinusoidal obstruction syndrome of the liver in patients undergoing hematopoietic stem cell transplantation. *Blood* 2009;114(6):1270-1275.
- [40] Armand P, Kim HT, Cutler CS, Ho VT, Koreth J, Ritz J, Alyea EP, Antin JH, Soiffer RJ. A prognostic score for patients with acute leukemia or myelodysplastic syndromes undergoing allogeneic stem cell transplantation. *Biol Blood marrow Transplant* 2008;14(1):28-35.
- [41] Tomás JF, Pinilla I, García-Buey ML, García A, Figuera A, Gómez-García de Soria VGG, Moreno R, Fernández-Rañada JM. Long-term liver dysfunction after allogeneic bone marrow transplantation: clinical features and course in 61 patients. *Bone Marrow Transplant* 2000;26(6):649-655.
- [42] Ho GT, Parker A, MacKenzie JF, Morris AJ, Stanley AJ. Abnormal liver function tests following bone marrow transplantation: aetiology and role of liver biopsy. *Eur J Gastroenterol Hepatol* 2004;16(2):157-162.
- [43] Choi SW, Islam S, Greenson JK, Levine J, Hutchinson R, Yanik G, Teitelbaum DH, Ferrara JL, Cooke KR. The use of laparoscopic liver biopsies in pediatric patients with hepatic dysfunction following allogeneic hematopoietic stem cell transplantation. *Bone Marrow Transplant* 2005;36(10):891-896.
- [44] Strasser SI. When should liver biopsy be performed after hematopoietic stem cell transplantation? *J Gastroenterol Hepatol* 2008;23(2):167-169.
- [45] Iqbal M, Creger RJ, Fox RM, Cooper BW, Jacobs G, Stellato TA, Lazarus HM. Laparoscopic liver biopsy to evaluate hepatic dysfunction in patients with hematologic malignancies: a useful tool to effect changes in management. *Bone Marrow Transplant* 1996;17(4):655-662.
- [46] Fujita N, Sugimoto R, Urawa N, Araki J, Mifuji R, Yamamoto M, Horiike S, Tanaka H, Iwasa M, Kobayashi Y, Adachi Y, Kaito M. Hepatic iron accumulation is associated with disease progression and resistance to interferon/ribavirin combination therapy in chronic hepatitis C. *J Gastroenterol Hepatol* 2007;22(11):1886-1893.

- [47] Gaziev J, Sodani P, Polchi P, Andreani M, Lucarelli G. Bone marrow transplantation in adults with thalassemia: Treatment and long-term follow-up. *Ann N Y Acad Sci* 2005;1054:196-205.
- [48] Morado M, Ojeda E, Garcia-Bustos J, Aguado MJ, Arrieta R, Quevedo E, Navas A, Hernandez-Navarro F. Serum Ferritin as Risk Factor for Venous-occlusive Disease of the Liver. Prospective Cohort Study. *Hematology* 2000;4(6):505-512.
- [49] Sucak GT, Yegin ZA, Ozkurt ZN, Aki SZ, Yağci M. Iron overload: predictor of adverse outcome in hematopoietic stem cell transplantation. *Transplant Proc* 2010;42(5):1841-1848.
- [50] Sucak GT, Aki ZS, Yagci M, Yegin ZA, Ozkurt ZN, Haznedar R. Treatment of sinusoidal obstruction syndrome with defibrotide: a single-center experience. *Transplant Proc* 2007;39(5):1558-1563.
- [51] Unal S, Kuskonmaz B, Hazirolan T, Eldem G, Aytac S, Cetin M, Uckan D, Gumruk F. Deferasirox use after hematopoietic stem cell transplantation in pediatric patients with beta-thalassemia major: preliminary results. *Pediatr Hematol Oncol* 2010;27(6):482-489.
- [52] Marx JJ. Iron and infection: competition between host and microbes for a precious element. *Best Pract Res Clin Haematol* 2002;15(2):411-426.
- [53] Ali S, Pimentel JD, Munoz J, Shah V, McKinnon R, Divine G, Janakiraman N. Iron overload in allogeneic hematopoietic stem cell transplant recipients. *Arch Pathol Lab Med* 2012;136(5):532-538.
- [54] Miceli MH, Dong L, Graziutti ML, Fassas A, Thertulien R, Van Rhee F, Barlogie B, Anaissie EJ. Iron overload is a major risk factor for severe infection after autologous stem cell transplantation: a study of 367 myeloma patients. *Bone Marrow Transplant* 2006;37(9):857-864.
- [55] Tunçcan OG, Yegin ZA, Ozkurt ZN, Erbaş G, Aki SZ, Senol E, Yağci M, Sucak G. High ferritin levels are associated with hepatosplenic candidiasis in hematopoietic stem cell transplant candidates. *Int J Infect Dis* 2010;14 Suppl 3:e104-107.
- [56] Özyilmaz E, Aydogdu M, Sucak G, Aki SZ, Ozkurt ZN, Yegin ZA, Kokturk N. Risk factors for fungal pulmonary infections in hematopoietic stem cell transplantation recipients: the role of iron overload. *Bone Marrow Transplant* 2010;45(10):1528-1533.
- [57] Platzbecker U, Bornhäuser M, Germing U, Stumpf J, Scott BL, Kröger N, Schwerdtfeger R, Böhm A, Kobbe G, Theuser C, Rabitsch W, Valent P, Sorrow ML, Ehninger G, Deeg HJ. Red blood cell transfusion dependence and outcome after allogeneic peripheral blood stem cell transplantation in patients with de novo myelodysplastic syndrome (MDS). *Biol Blood Marrow Transplant* 2008;14(11):1217-1225.
- [58] Mahindra A, Bolwell B, Sobecks R, Rybicki L, Pohlman B, Dean R, Andresen S, Sweetenham J, Kalaycio M, Copelan E. Elevated pretransplant ferritin is associated



- with a lower incidence of chronic graft-versus-host disease and inferior survival after myeloablative allogeneic haematopoietic stem cell transplantation. *Br J Haematol* 2009;146(3):310-316.
- [59] Kataoka K, Nannya Y, Hangaishi A, Imai Y, Chiba S, Takahashi T, Kurokawa M. Influence of pretransplantation serum ferritin on nonrelapse mortality after myeloablative and nonmyeloablative allogeneic hematopoietic stem cell transplantation. *Biol Blood Marrow Transplant* 2009;15(2):195-204.
- [60] Alessandrino EP, Della Porta MG, Bacigalupo A, Malcovati L, Angelucci E, Van Lint MT, Falda M, Onida F, Bernardi M, Guidi S, Lucarelli B, Rambaldi A, Cerretti R, Marengo P, Pioltelli P, Pascutto C, Oneto R, Pirolini L, Fanin R, Bosi A. Prognostic impact of pre-transplantation transfusion history and secondary iron overload in patients with myelodysplastic syndrome undergoing allogeneic stem cell transplantation: a GITMO study. *Haematologica* 2010;95(3):476-484.
- [61] Andrews NC. Forging a field: the golden age of iron biology. *Blood* 2008;112:219-230.
- [62] Tanaka M, Tachibana T, Numata A, Takasaki H, Matsumoto K, Maruta A, Ishigatsubo Y, Kanamori H. A prognostic score with pretransplant serum ferritin and disease status predicts outcome following reduced-intensity SCT. *Bone Marrow Transplant* 2012;47(4):596-597.
- [63] Tachibana T, Tanaka M, Takasaki H, Numata A, Maruta A, Ishigatsubo Y, Kanamori H. Pre-SCT serum ferritin is a prognostic factor in adult AML, but not ALL. *Bone Marrow Transplant* 2011;46(9):1268-1269.
- [64] Lim ZY, Fiaccadori V, Gandhi S, Hayden J, Kenyon M, Ireland R, Marsh J, Ho AY, Mufti GJ, Pagliuca A. Impact of pre-transplant serum ferritin on outcomes of patients with myelodysplastic syndromes or secondary acute myeloid leukaemia receiving reduced intensity conditioning allogeneic haematopoietic stem cell transplantation. *Leuk Res* 2010;34(6):723-727.
- [65] Armand P, Kim HT, Cutler CS, Ho VT, Koreth J, Ritz J, Alyea EP, Antin JH, Soiffer RJ. A prognostic score for patients with acute leukemia or myelodysplastic syndromes undergoing allogeneic stem cell transplantation. *Biol Blood Marrow Transplant* 2008;14(1):28-35.
- [66] Armand P, Kim HT, Cutler CS, Ho VT, Koreth J, Alyea EP, Soiffer RJ, Antin JH. Prognostic impact of elevated pretransplantation serum ferritin in patients undergoing myeloablative stem cell transplantation. *Blood* 2007;109(10):4586-4588.
- [67] Storey JA, Connor RF, Lewis ZT, Hurd D, Pomper G, Keung YK, Grover M, Lovato J, Torti SV, Torti FM, Molnár I. The transplant iron score as a predictor of stem cell transplant survival. *J Hematol Oncol* 2009; 2:44.
- [68] Armand P, Sainvil MM, Kim HT, Rhodes J, Cutler C, Ho VT, Koreth J, Alyea EP, Neufeld EJ, Kwong RY, Soiffer RJ, Antin JH. Does iron overload really matter in stem cell transplantation? *Am J Hematol* 2012;87(6):569-572.

- [69] Carreras E. Risk assessment in haematopoietic stem cell transplantation: the liver as a risk factor. *Best Pract Res Clin Haematol* 2007;20(2):231-246.
- [70] Liatsos C, Mehta AB, Potter M, Burroughs AK. The hepatologist in the haematologists' camp. *Br J Haematol* 2001;113(3):567-578.
- [71] Wood JC. Impact of iron assessment by MRI. *Hematology Am Soc Hematol Educ Program* 2011;2011:443-450.
- [72] Gandon Y, Olivie D, Guyader D, Aubé C, Oberti F, Sebille V, Deugnier Y. Non-invasive assessment of hepatic iron stores by MRI. *Lancet* 2004;363(9406):357-362.
- [73] Voskaridou E, Douskou M, Terpos E, Papassotiriou I, Stamoulakatou A, Ourailidis A, Loutradi A, Loukopoulos D. Magnetic resonance imaging in the evaluation of iron overload in patients with beta thalassaemia and sickle cell disease. *Br J Haematol* 2004;126(5):736-742.
- [74] St Pierre TG, Clark PR, Chua-anusorn W, Fleming AJ, Jeffrey GP, Olynyk JK, Pootrakul P, Robins E, Lindeman R. Noninvasive measurement and imaging of liver iron concentrations using proton magnetic resonance. *Blood* 2005;105(2):855-861.
- [75] Nielsen P, Günther U, Dürken M, Fischer R, Düllmann J. Serum ferritin iron in iron overload and liver damage: correlation to body iron stores and diagnostic relevance. *J Lab Clin Med* 2000;135(5):413-418.
- [76] Butt NM, Clark RE. Autografting as a risk factor for persisting iron overload in long-term survivors of acute myeloid leukaemia. *Bone Marrow Transplant* 2003;32(9):909-913.
- [77] Harrison P, Neilson JR, Marwah SS, Madden L, Bareford D, Milligan DW. Role of non-transferrin bound iron in iron overload and liver dysfunction in long term survivors of acute leukaemia and bone marrow transplantation. *J Clin Pathol* 1996;49(10):853-856.
- [78] Muretto P, Angelucci E, Lucarelli G. Reversibility of cirrhosis in patients cured of thalassemia by bone marrow transplantation. *Annals of Internal Medicine* 2002;136(9):667-672.
- [79] McDonald GB. Review article: management of hepatic disease following haematopoietic cell transplant. *Aliment Pharmacol Ther* 2006;24(3):441-452.
- [80] Yeşilipek MA, Karasu G, Kazik M, Uygun V, Ozturk Z. Posttransplant oral iron-chelating therapy in patients with beta-thalassemia major. *Pediatr Hematol Oncol* 2010;27(5):374-379.
- [81] Kwiatkowski JL. Real-world use of iron chelators. *Hematology Am Soc Hematol Educ Program* 2011;2011:451-458.

