

We are IntechOpen, the world's leading publisher of Open Access books Built by scientists, for scientists

4,800

Open access books available

122,000

International authors and editors

135M

Downloads

Our authors are among the

154

Countries delivered to

TOP 1%

most cited scientists

12.2%

Contributors from top 500 universities



WEB OF SCIENCE™

Selection of our books indexed in the Book Citation Index
in Web of Science™ Core Collection (BKCI)

Interested in publishing with us?
Contact book.department@intechopen.com

Numbers displayed above are based on latest data collected.

For more information visit www.intechopen.com



Colon Capsule Endoscopy: Quo Vadis?

Samuel N. Adler and Cesare Hassan

Additional information is available at the end of the chapter

<http://dx.doi.org/10.5772/53055>

1. Introduction

Capsule endoscopy was independently invented in the last decade of the 20th century by Gabriel Iddan and Paul Swain. They both were committed to develop a wireless camera that would transmit images for the insides of the digestive tract to an extracorporeal receiver. They faced many significant challenges. The last hurdle to be taken was made possible by the miniaturization of the photosensitive chip (CMOS). This device transmits images in digital format and is very economical with modest energy consumption. In this capsule the following elements were implanted: a light source (LED), a lens, the photosensitive chip, a power source (batteries) and a transmitter with and antenna (see Figure 1).

In the year 1996 the stomach of a pig was visualized by this method. The importance of this discovery remained as yet elusive to the medical community at large. Yet Paul Swain and Gabriel Iddan pursued their invention. Internal Review Board approval was obtained and the first human ingestion of a wireless capsule endoscope was performed by Paul Swain in Israel on October 17th 1999. In the year 2000 the scientific journal Nature realized that something of importance was taking place and devoted an article to wireless capsule endoscopy[1]. The question had to be addressed whether capsule endoscopy was a cute high tech toy or whether this device had clinical importance for the medical community. The results of a double blind controlled study comparing capsule endoscopy to push enteroscopy (the best available method at that time) in patients with occult gastrointestinal bleeding were presented at the Digestive Disease Week meeting in Atlanta in the year 2001. Capsule endoscopy was superior to push enteroscopy at a rate of two to one[2]. A few months later the US Food and Drug Administration approved the use of capsule endoscopy. From there on capsule endoscopy has captured the field of small bowel endoscopy. Capsule endoscopy of the small bowel was superior to conventional methods in diagnosing NSAID induced enteropathy, Crohn's disease of the small bowel, tumors of the small bowel and other diseases. Direct visualization of the gastrointestinal mucosa was superior to barium studies. For this

reason the gastroscope had replaced upper gastrointestinal series, the colonoscope had replaced barium enemas and it was now the capsule endoscopy's turn to replace the small bowel follow through examinations.

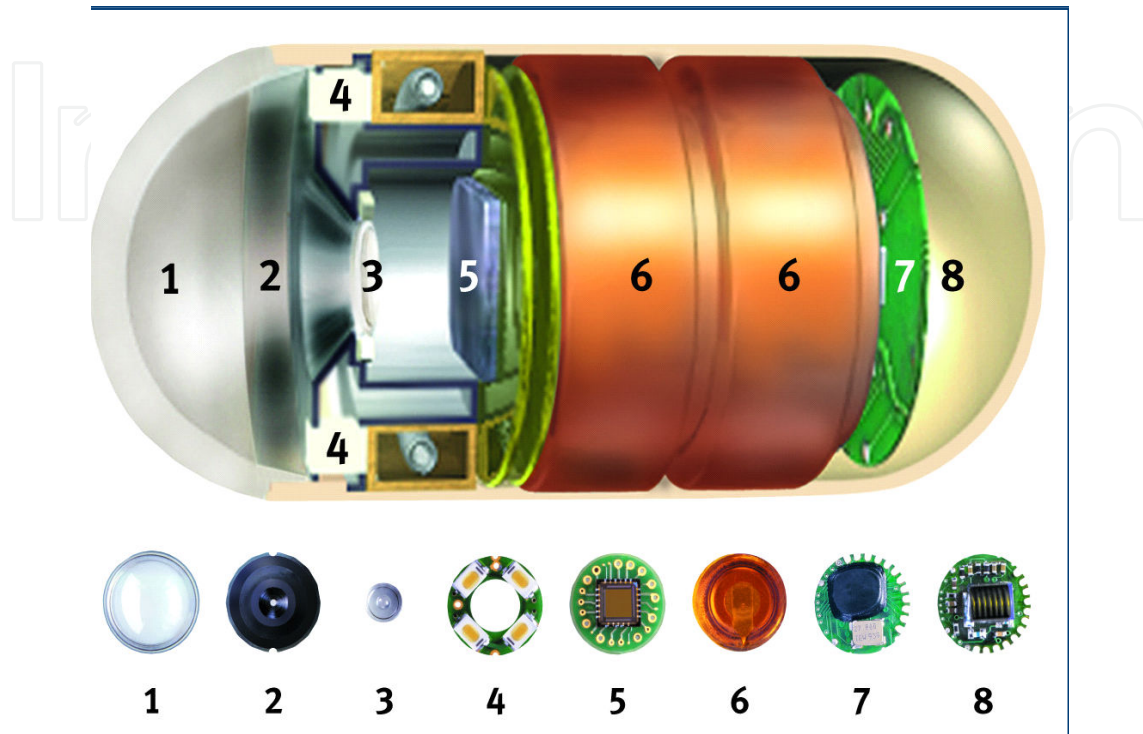


Figure 1. Optical dome, 2 Lens holder, 3. Lens, 4.Illuminating LEDs (light emitting diodes), 5. CMOS (Complementary Metal Oxide Semiconductor) image, 6. Battery, 7.ASIC (Application Specific Integrated Circuit) transmitter, 8. Antenna

Once capsule endoscopy had proven itself as a very useful and important diagnostic tool in the work up of small bowel disease, the concept of non invasive endoscopy sought expansion to other areas of the gastrointestinal tract as well. This chapter deals with capsule endoscopy of the colon.

2. History of capsule endoscopy of the colon

In contrast to capsule endoscopy of the small bowel, capsule endoscopy of the colon faces serious challenges for the following reasons.

1. Problem:

The small bowel is narrow (hence its name). As the capsule camera enters the small bowel it remains by and large fixed in its orientation and facing the same direction, either camera first or transmitter first. The capsule as a rule does not flip around its own axis. The capsule travels along its journey through the small bowel in the same orientation as it enters the small bowel. For this reason the single camera of the capsule will screen the entire small

bowel mucosa either in forward view if the capsule enters the small bowel with the camera end first or in backward view if the capsule enters with the transmitter end first. This is not true for the colon. In the large bowel with its wide diameter the capsule can tumble around its axis. A capsule with a single camera would screen certain areas twice and other areas not at all.

Solution:

The engineers solved this challenge by offering a colon capsule that has two cameras, one camera at each end. The colonic mucosa is visualized from both directions simultaneously. This guarantees complete visual coverage of the entire colonic surface.

2. Problem:

The capsule transit time to reach the end of the colon is significantly longer than the time required for the capsule to reach the cecum and the colon capsule consumes more energy than the small bowel capsule since it transmits images from two cameras. Yet the energy supply is limited to two watch batteries.

Solution:

To reduce energy requirements the colon capsule was put to sleep for an hour and a half, five minutes after ingestion. This hour and a half of transmit time became now available for transmission from the colon.

3. Problem:

The third hurdle is bowel cleansing. In standard colonoscopy some minimal amount of liquid debris can be aspirated, yet minimal amount of debris may compromise the capsule's ability to identify pathological findings.

Solution:

A more vigorous bowel preparation had to be offered to patients to assure proper cleansing for colon capsule examinations.

The first colon capsule was tested in the year 2005 and 2006[3]. The results of three studies were encouraging. Firstly the bowels could be adequately cleansed in 72 to 84% of patients. Secondly the capsule passed through the entire gastrointestinal tract while transmitting images from the entire colon in 81% of patients within 8 hours. Finally the capsule did identify pathologies such as polyps, tumors, colitis, diverticulosis and internal hemorrhoids. Proof of principle had been obtained. However the sensitivity of 58 to 64% to identify patients with polyps equal to or larger than 6 mm as compared to standard colonoscopy was suboptimal and fell short of expectations [4].

3. New features of colon capsule 2

The shortcomings of this first colon capsule were analyzed and the capsule underwent a thorough overhaul. The second generation colon capsule has the following improvements.

The angle of view of this new colon capsule camera was extended from 154 to 172 degrees for each camera. This change provides a near full panorama view (see Figure 2).

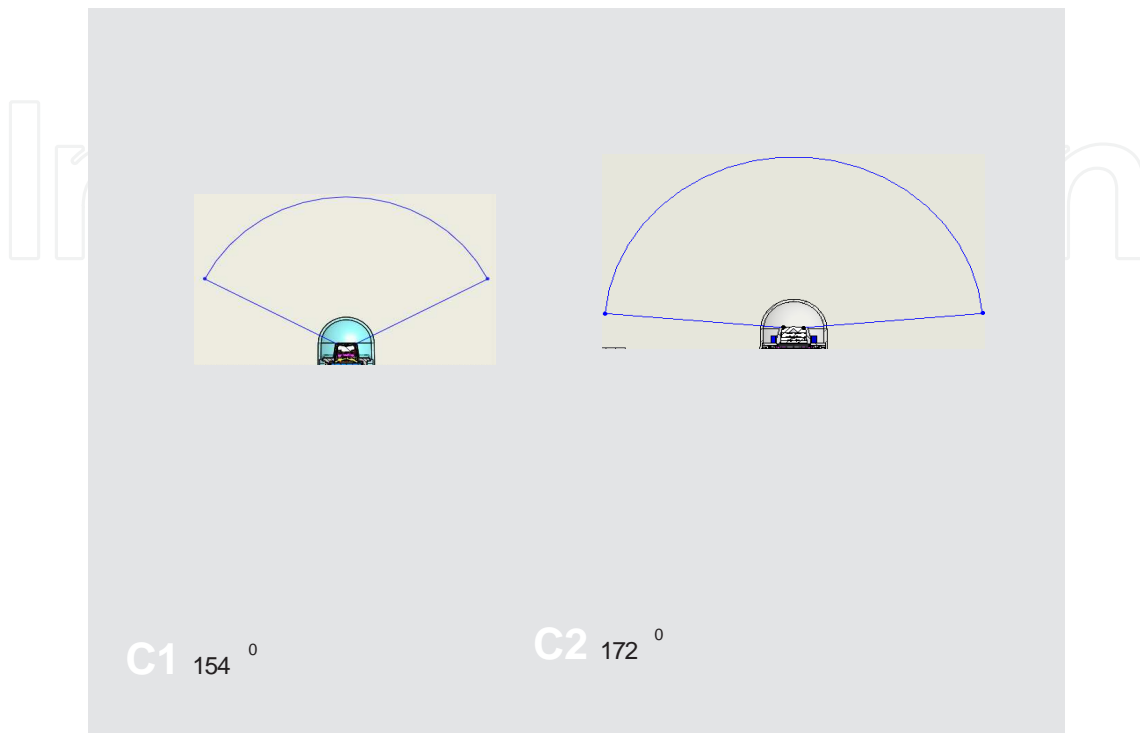

Figure 2. The left side image demonstrates the angle of view of the out dated C1 colon capsule. The right hand image demonstrates the angle of view of the C2 colon capsule with a near panoramic view.

The Data Recorder 3 (DR3), the device that collects the transmitted digital information from the capsule, is a true revolution in capsule endoscopy. Smart features have been imbedded in this device. Bidirectional communication between capsule and DR3 takes place. The DR3 receives information from the capsule and accordingly directs the capsule with corresponding instructions. The capsule receives online orders by the DR3. The capsule transmits its images at four images per second when in stationary condition. When DR3 recognizes that the incoming images indicate that the capsule is in motion it orders the capsule to raise the transmission rate to 35 images per second. This entire circle of receiving optical information from the capsule, online analysis by the DR3 and execution of the DR3 orders by the capsule takes place within a split second. Furthermore, DR3 also communicates with the patient undergoing the colon capsule examination and instructs the patient if and when to take a prokinetic agent, which shortens gastric transit time and moves the capsule more expediently from stomach into small bowel. The DR3 notifies the patient

- a. when to ingest the first booster laxative which accelerates small bowel transit time of the capsule and keeps the colon clean,
- b. if and when to ingest a second booster laxative
- c. if and when to insert a bisacodyl suppository

d. and finally notifies that the patient may eat and that the procedure is over.

This is how the second generation colon capsule system works. Three minutes after swallowing the capsule the rate of transmission is reduced to 16 images per minute to conserve energy. The received images are constantly analyzed by DR3. If after one hour DR3 notices that the colon capsule has not left the stomach it will instruct the subject by ringing an alarm tone and activating a vibrating device attached to the antenna to look at the LCD screen where the digit 0 is displayed. The patient's instruction sheet indicates that the appearance of digit 0 requires the subject to take a prokinetic agent such domperidone or metoclopramide. However if the capsule has left the stomach and entered the small bowel, the smart features of DR3 recognize that the capsule is now in the small bowel. DR3 orders the capsule to raise its transmission rate from 16 images per minute to 4 images per second and the patient to ingest the booster laxative. The purpose of this booster laxative is to shorten small bowel transit time of the colon capsule and to maintain adequate cleanliness of the bowel. Furthermore, all incoming images from the colon capsule are analyzed online by this "intelligent" DR3 that recognizes if the capsule is stationary or in motion. Once DR3 recognizes that the capsule is in motion it orders the capsule to raise its transmission rate of images to a staggering 35 frames per second. As mentioned, the process of recognition to execution takes place in a fraction of a second. This rapid transmission rate (35 frames per second) provides adequate number of colonic images while the capsule is in motion especially while flying through the transverse colon.

Polyp size is of course clinically very relevant. The larger the size of a polyp the greater the chances that the polyp has advanced neoplastic changes. The software program for colon capsule 2 is equipped with a polyp size assessor. The cursor is drawn from one side of the polyp to the other and the algorithm spits out the size of the polyp in mm. The same polyp seen from distance or from close up will have the same size measurement.

These technological achievements are very impressive (a data recorder communicating with capsule and patient, a data recorder that analyzes images, determines location, position –stationary versus motion, and accordingly alters transmission rate of frames per second by the capsule). Yet the gnawing question remains. Is this device medically relevant?

4. Results of clinical trials with colon capsule 2

We engaged in a five center prospective double blind feasibility study in Israel in which this second generation colon capsule was compared to standard colonoscopy for the identification of patients with colonic polyps. 104 patients were enrolled. Whereas in the European multicenter trial published in 2009 the sensitivity to identify patients with polyps was only 58% the sensitivity in the multicenter Israel trial with the second generation colon capsule rose to 89% [5]. This marked improved diagnostic sensitivity was reproduced by a recent European study with the second generation colon capsule [6]. This improvement (raise in diagnostic sensitivity from 58% to 89%) has to be attributed to the revolutionary new capsule platform of this second generation colon capsule for the following reasons. Firstly, the

three previous studies with the first generation colon capsule had a very similar design as the present studies with colon capsule 2 and are thus comparable. Secondly, good bowel cleansing is a determining factor for a successful study. Good bowel cleansing was obtained at similar rates in the studies with colon capsule 1 as in the new studies with colon capsule 2. Thirdly, capsule excretion of a capsule still transmitting images is a prerequisite for a successful colon capsule study. Capsule excretion rates of the studies with colon capsule 1 and the studies with colon capsule 2 were the same. The only factor which set this second generation colon capsule study apart from the previous studies is the new technological platform. It is for this reason that we credit the improvement in technology for the improved diagnostic sensitivity of 30%.

Colon capsule 2's negative predictive value of 97% is very high and is clinically very meaningful. The physician discussing the results of a negative colon capsule 2 study with his patient can reassure her/him that that a negative colon capsule 2 study has a 97% accuracy that there are no polyps.

The fact that the smart features of DR3 enable communication with the patient has opened the door to offer colon capsule examination as an out of clinic procedure [7].

5. Colon capsule endoscopy, Quo Vadis?

In the year 2011 the European Society of Gastrointestinal Endoscopy(ESGE) recognized the potential that colon capsule endoscopy offers and ordered the establishment of evidence based guidelines for colon capsule endoscopy[8]. This initiative was endorsed by the governing board of ESGE.

Technical concerns in relation to colon capsule endoscopy were addressed. Will the colon be adequately cleansed for high quality inspection? Will the power of the batteries within the capsule supply adequate energy to transmit images from the colon until excretion of the capsule? The experts therefore formulated precise guidelines and devoted an entire section on how to perform capsule endoscopy. To achieve high quality colon capsule endoscopy (good bowel preparation, high rate of capsule passage rate through entire colon and proper reading) strict implementation of all guidelines must be followed (diet, laxatives, booster ingestion, controlled frame rate during reading).

Here are some of the attractive features of colon capsule endoscopy that are mentioned in the published guidelines.

- "CCE (Colon capsule endoscopy) has consistently been shown to be a very safe procedure: no major complication has been reported in over 1500 procedures, of which around 40% were in asymptomatic individuals. CCE also appears to be a feasible procedure, with a very low rate of technical failures (i. e. 3%) and a high capsule excretion rate of about 90%".
- "A previous cost-effectiveness analysis has compared first-generation CCE with colonoscopy in a screening setting. Although CCE was not a cost-effective alternative when

equal uptake (adherence to participate in colon cancer screening) was assumed, it became an efficient option when it was assumed that uptake of CCE would be higher than that of colonoscopy for CRC screening, a premise that has not been demonstrated yet.”

- “CCE is a feasible and safe tool for visualization of the colonic mucosa in patients with incomplete colonoscopy and without stenosis.”
- “Small-bowel capsule endoscopy provides a very high diagnostic yield for small-bowel mucosal lesions and its use is recommended in specific scenarios of IBD (Inflammatory Bowel Disease). Similarly, CCE could be used to identify mucosal changes in the colorectal mucosa. ...”

We will dwell on two mentioned issues raised in the European Guidelines, namely the use of capsule colonoscopy in screening for colonic polyps and the use of capsule endoscopy in incomplete colonoscopy.

6. Can colon capsule endoscopy play a role in clinical medicine today?

- a. Screening patients for presence of colonic polyps as primary colon cancer prevention.

Colonoscopy is the accepted gold standard and the most sensitive method to investigate patients for the presence of colonic polyps. While colon cancer screening programs are available the participation rate of the general population has been disappointingly low. The reasons for the low adherence rate are multifactorial. Colonoscopy is associated with discomfort/pain, so there is a need for sedation, there are complications, albeit small, the procedure leads to loss of work and there is the issue of the invasion of one's privacy. Recently it has been reported that post procedural pain necessitating visits to the emergency room following colonoscopy has been underestimated. While these reservations may appear trivial to gastroenterologists, this is perceived differently in the general public. Inadomi et al published the results of a prospective randomized trial [9]. In the office setting eligible patients were offered either colonoscopy or fecal occult blood testing (FOBT). 12 months thereafter 38% of patients offered colonoscopy had completed the procedure, while 31% more, a total of 69% of patients offered FOBT had done the test.

They concluded that our common practice of universally recommending only colonoscopy may actually reduce adherence to colorectal cancer screening.

In a prospective study performed in Germany to examine whether colon capsule endoscopy could increase adherence to screening colonoscopy in a healthy population Groth et al found that offering capsule endoscopy led to a fourfold increase of screening uptake compared to standard colonoscopy [10].

Rex and Lieberman published a survey study that colon capsule endoscopy could raise colorectal cancer screening adherence rates among patients who decline screening colonoscopy. This was especially apparent when the participants in this survey were offered colon capsule endoscopy as an out of clinic test with no loss of work. We published a cohort study

of 41 patients who underwent colon capsule endoscopy as an out of clinic study. Successfully completed colon capsule endoscopy examinations in this out-of-clinic trial, including capsule excretion rates and colon cleansing levels were similar to those of the two published in-clinic trials. This study concluded that second generation colon capsule endoscopy may be offered as an out-of-clinic medically supervised procedure [11].

To summarize the above: offering colonoscopy only in colon cancer screening programs reduces adherence. Loss of work and the need to have a person accompany the subject to be screened by colonoscopy are significant reasons for decreased adherence to undergo colonoscopy screening. Reduced adherence compromises the effectiveness of colonoscopy even if colonoscopy admittedly is the gold standard. Colon capsule endoscopy can offer itself as a non invasive test to identify patients with colonic polyps. In the future colon capsule endoscopy could be offered as an out of clinic test which potentially could further increase adherence rates for colon cancer screening programs. Modern technology has set the tone. Invasive diagnostic tests will be replaced with less or non invasive tests. Colon capsule endoscopy may fit this paradigm.

b. Incomplete Colonoscopy.

For colonoscopy to reduce colon cancer rates certain criteria have to be met. Colonoscopy has to be carried out by competent endoscopists (operator dependent). Bowel cleansing has to be optimal. Cecal intubation has to be achieved (complete colonoscopy). Incomplete colonoscopy, ie the failure to intubate the cecum with the colonoscope, in general practice is higher than expected [12]. Complete colonoscopy rates have been reported from 60% to over 90% [13],[14],[15]. If for whatever reason complete colonoscopy cannot be achieved then ingestion of the colon capsule endoscope for visualization of the uninspected part of the colon is feasible. Colon capsule endoscopy in this setting may be especially attractive since it is the right colon which is usually not visualized in incomplete conventional colonoscopy whereas the right colon is routinely visualized by capsule endoscopy. A prospective multicenter European study demonstrated that colon capsule endoscopy in case of incomplete colonoscopy (74 cases) or contraindicated colonoscopy (26 cases) yields a high number of relevant diagnostic findings (36 %) including one right sided colonic cancer. Furthermore, the authors report that during a one year follow up of this study no adenocarcinoma of the colon was missed by the colon capsule[16]. It should be emphasized that this study was performed with the inferior (today outdated) first generation colon capsule.

7. Conclusion

Colon capsule endoscopy has come a long way in a very short time. Technological developments are so rapid that studies performed in the years 2006 and 2007 with the first generation of colon capsules are already outdated. Second generation colon capsule endoscopy has a diagnostic sensitivity of 89% or higher to identify patients with polyps equal to or larger than 5 mm. In addition to this high sensitivity colon capsule endoscopy is non invasive, painless, protects one's privacy, may be offered in the future as an out of clinic (or possibly

home procedure) and for all these reasons may increase adherence rates to participate in colon cancer screening. Therefore colon capsule endoscopy may become clinically important to practicing gastroenterologists.

Author details

Samuel N. Adler¹ and Cesare Hassan²

1 Division of Gastroenterology, BikurHolim Hospital, Jerusalem, Israel

2 Ospedale Nuovo Regina Margherita, Via Morosini, Roma, Italia

References

- [1] Iddan G, Meron G, Glukhovsky A, Swain P. Wireless capsule endoscopy. *NATURE* 2000;405. 417
- [2] Lewis BS, Swain P. Capsule endoscopy in the evaluation of patients with suspected small intestinal bleeding: Results of a pilot study. *Gastrointest Endosc.* 2002;56(3): 349-53.
- [3] Eliakim R, Fireman Z, Galnek IM, Yassin K, Waterman M, Kopelman Y, Lachter J, Koslowsky B, Adler SN. Evaluation of the PillCam Colon capsule in the detection of colonic pathology: results of the first multicenter, prospective, comparative study. *Endoscopy* 2006; 38(10): 963-970 [PMID: 17058158 DOI:10.1055/s-2006-944832
- [4] Van Gossum A, Munoz-Navas M, Fernandez-Urien I, Carretero C, Gay G, Delvaux M, Lapalus MG, Ponchon T, Neuhaus H, Philipper M, Costamagna G, Riccioni ME, Spada C, Petruzzello L, Fraser C, Postgate A, Fitzpatrick A, Hagenmuller F, Keuchel M, Schoofs N, Devière J. Capsule Endoscopy versus Colonoscopy for the Detection of Polyps and Cancer. *N Engl J Med* 2009; 361:264-270 [PMID: 19605831 DOI 10.1056/NEMJoa0806347
- [5] Eliakim R, Yassin K, Niv Y, Metzger Y, Lachter J, Gal E, Sapoznikov B, Konikoff F, Leichtmann G, Fireman Z, Kopelman Y, Adler SN. Prospective multicenter performance evaluation of the second-generation colon capsule compared with colonoscopy. *Endoscopy* 2009; 41:1026–1031 [PMID: 19967618 DOI:10.1055/s-0029-1215360
- [6] Spada C, Hassan C, Munoz-Navas M, Neuhaus H, Deviere J, Fockens P, Coron E, Gay G, Toth E, Riccioni ME, Carretero C, Charton JP, Van Gossum A, Wientjes CA, Sacher-Huvelin S, Delvaux M, Nemeth A, Petruzzello L, de Frias CP, Mayershofer R, Aminejab L, Dekker E, Galmiche JP, Frederic M, Johansson GW, Cesaro P, Costamagna G . Second-generation PillCam® Colon Capsule Compared with Colonoscopy. *Gastrointest Endoscopy* 2011; 74:581-589 DOI: 10.1016/j.gie.2011.03.1125

- [7] Adler S.N., Metzger Y.C., Sompolinsky Y., Hassan C. Capsule Colonoscopy with Pillcam Colon 2 is Feasible as an Outpatient Procedure. *UEGW 2011, Endoscopy 2011, 43 (Suppl I A215)*
- [8] Spada C, Hassan C, Galmiche J P, Neuhaus H, Dumonceau J M, Adler S, Epstein O, Gay G, Pennazio M, Rex DK, Benamouzig R, de Franchis R, Delvaux M, Devière J, Eliakim R, Fraser C, Hagenmuller F, Herrerias JM, Keuchel M, Macrae F, Munoz-Navas M, Ponchon T, Quintero E, Riccioni ME, Rondonott E, Marmo R, Sung JJ, Tajir H, Toth, Triantafyllou K, Van Gossum A, Costamagna G. Colon capsule endoscopy: European Society of Gastrointestinal Endoscopy (ESGE) Guideline. *Endoscopy*. 2012 May;44(5):527-36. Epub 2012 Mar 2. DOI <http://dx.doi.org/10.1055/s-0031-1291717>
- [9] Inadomi JM, MD, Vijan S, MD, MS, Janz NK, PhD, et al. Adherence to Colorectal Cancer Screening. *Arch Internal Medicine*. 2012; 172(7):575-582 DOI:10.1001/archinternmed.2012.332
- [10] Groth S, Krause H, Behrendt R, Hill H, Börner M, Bastürk M, Plathner N, Schütte F, Gauger U, Riemann JF, Altenhofen L, Rösch T. Capsule colonoscopy increases uptake of colorectal cancer screening. *BMC Gastroenterology* 2012, 12:80 DOI: 10.1186/1471-230X-12-80
- [11] Adler SN, Metzger YC, Sompolinsky Y, Hassan C. Capsule Colonoscopy with Pill-Cam COLON 2 is Feasible as an Out-of-Clinic Procedure. *Gastroenterology* 2012;142(5); Supp1:s53-s54
- [12] Dafnis G, Granath F, Pählman L, Ekblom A, Blomqvist P. Patient factors influencing the completion rate in colonoscopy. *Dig Liver Dis*. 2005 Feb;37(2):113-8
- [13] Bowles CJ, Leicester R, Romaya C et al. A prospective study of colonoscopy practice in the UK today: are we adequately prepared for national colorectal cancer screening tomorrow? *Gut* 2004; 53: 277–283
- [14] Lieberman DA, Weiss DG, Bond JH. Veterans Affairs Cooperative Study Group 380. et al. Use of colonoscopy to screen asymptomatic adults for colorectal cancer. *N Engl J Med* 2000; 343: 162–168
- [15] Neerincx M, Terhaar sive Droste JS, Mulder CJ, Räkens M, Bartelsman JF, Loffeld RJ, Tuynman HA, Brohet RM, van der Hulst RW. Colonic work-up after incomplete colonoscopy: significant new findings during follow-up. *Endoscopy*. 2010 Sep;42(9): 730-5. Epub 2010 Jul 28.
- [16] Pioche M, De Leusse A, Filoche B, Dalbies P-A, Adenis-Lamarre P, Jacob P, Gaudin J-L, Coulom P, Létard J-C, Borotto E, Huriez A, Cabaud J-M, Crampon D, Gincul R, Lévy P, Ben Soussan E, Garret M, Lapuelle J, Saurin J-C. Prospective, Multicenter Evaluation Of The Colon Pillcam Videocapsule In The Specific Indication Of Colonoscopy Failure Or Contra-Indication. *Endoscopy* 2011; 43 (Suppl I) A14