

# We are IntechOpen, the world's leading publisher of Open Access books Built by scientists, for scientists

**4,800**

Open access books available

**122,000**

International authors and editors

**135M**

Downloads

Our authors are among the

**154**

Countries delivered to

**TOP 1%**

most cited scientists

**12.2%**

Contributors from top 500 universities



**WEB OF SCIENCE™**

Selection of our books indexed in the Book Citation Index  
in Web of Science™ Core Collection (BKCI)

Interested in publishing with us?  
Contact [book.department@intechopen.com](mailto:book.department@intechopen.com)

Numbers displayed above are based on latest data collected.

For more information visit [www.intechopen.com](http://www.intechopen.com)



---

# **Desmoplastic Reaction in Biopsy Specimens of T1 Stage Colorectal Cancer Plays a Critical Role in Defining the Level of Sub-Mucosal Invasion**

Shigeki Tomita, Kazuhito Ichikawa and  
Takahiro Fujimori

Additional information is available at the end of the chapter

<http://dx.doi.org/10.5772/51900>

---

## **1. Introduction**

Observation of the mucosal crypt patterns using chromoendoscopy with magnification has been reported to be the most reliable method for determining whether a colorectal cancer (CRC) is early or advanced tumour. Moreover, brand-new endoscopic system have the capability to enhance visibility by the capillary pattern, which may prove to be reliable for detection of deep submucosal invasive CRC.

Early CRC is defined as a tumour whose invasion is limited to the mucosa or submucosa. The endoscopic mucosal resection and endoscopic mucosal dissection (EMR/ESD) have become useful for early CRC. However, EMR/ESD is applicable only to intramucosal carcinoma, and additional surgery is required if the resected lesion reveals submucosal invasion by pathological diagnosis. Therefore, endoscopist and surgical pathologist considered that it would be very useful to predict the depth of invasion of submucosal invasive CRC before EMR/ESD. On the other hand, desmoplastic reaction (DR) which is characterized by the infiltration of eosinophilic myofibroblasts in the stroma of invasive carcinoma is suggested to be a prognostic marker in CRC patients.

Here we describe that detection of DR in pre-treatment biopsy specimens is useful for predicting the depth of submucosal invasion and evaluation of submucosal depth with head invasion or stalk invasion in post EMR/ESD specimen is useful for predicting the lymph node metastasis and discuss relevant issues in arriving at the correct differential diagnosis based on histological findings for gastrointestinal endoscopist and surgical pathologist.

## 2. Correlations between lymph node metastasis and early colorectal carcinoma

The endoscopic mucosal resection and endoscopic submucosal dissection (EMR/ESD) have become useful for early CRC which is defined as a T1 stage tumour whose invasion is limited to the mucosa or submucosa according to the T categories for colorectal cancer of the American Joint Committee on Cancer (AJCC) staging system (Table 1).

---

Tx: No description of the tumor's extent is possible because of incomplete information.

---

Tis: The cancer is in the earliest stage (in situ). It involves only the mucosa. It has not grown beyond the muscularis mucosa (inner muscle layer).

---

T1: The cancer has grown through the muscularis mucosa and extends into the submucosa.

---

T2: The cancer has grown through the submucosa and extends into the muscularis propria (thick outer muscle layer).

---

T3: The cancer has grown through the muscularis propria and into the outermost layers of the colon or rectum but not through them. It has not reached any nearby organs or tissues.

---

T4a: The cancer has grown through the serosa (also known as the visceral peritoneum), the outermost lining of the intestines.

---

T4b: The cancer has grown through the wall of the colon or rectum and is attached to or invades into nearby tissues or organs.

---

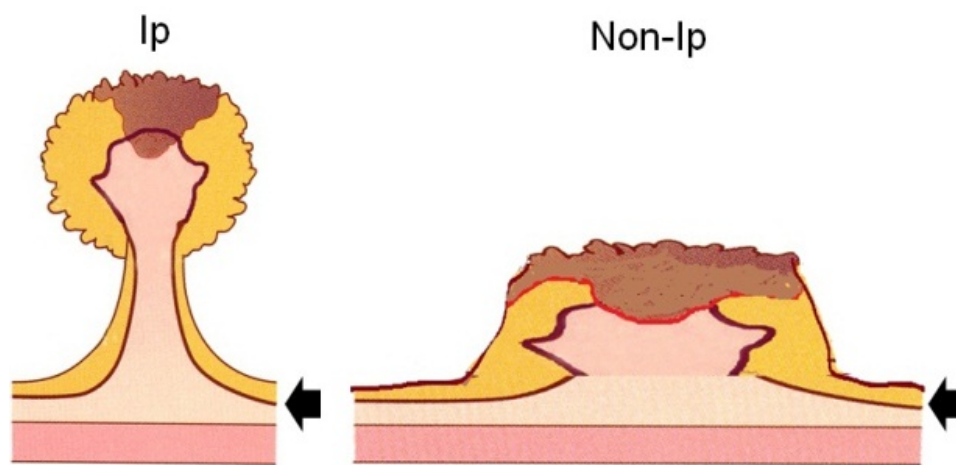
**Table 1.** T categories for colorectal cancer of the AJCC staging system.

The endoscopic mucosal dissection (EMR: endoscopic mucosal resection and ESD: endoscopic submucosal dissection) of intramucosal carcinoma is accepted as curative, as there is almost negative of lymph node metastasis. [1-4]. However, the reported prevalence rates of lymph node metastasis range from 6 to 12% of all patients with submucosal invasive colorectal carcinoma (SICC) [3-6]. Therefore, the endoscopic mucosal dissected cases of SICC with lymph node metastasis, and after EMR/ESD, surgical resection accompanied with lymph node dissection is necessary.

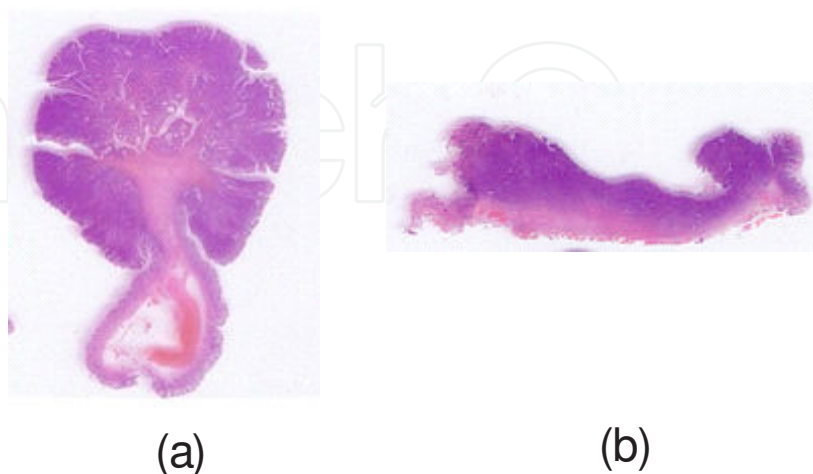
It has been known that we should be considered be additional resection is required due to the risk of lymph node metastasis following findings (1) massive submucosal invasion; (2) lymphatic/vessel invasion; or (3) poorly differentiated component in resected EMR/ESD specimens [7, 8]. There has been no standard method of measurement of submucosal invasion depth. Therefore, Japanese Society for Cancer of the Colon and Rectum has recently demonstrated definite for method of measurement of submucosal invasion depth.

### 3. Ip type (pedunculated lesion) and non-Ip type (nonpedunculated lesion) of early colorectal carcinoma

Macroscopic type (endoscopic finding) was assessed according to the macroscopic classification of early stomach carcinoma, with minor modifications. In shortly, SICCs were divided into two lesions: pedunculated (Ip type) (Figure. 1, Figure. 2(a)) and nonpedunculated (Non-Ip type) (Figure. 1b, Figure. 2(b)). Nonpedunculated lesion were subclassified as semi-pedunculated lesion (Isp type) and sessile lesion (Is type). Respectively. Ip type (pedunculated lesion) has typically head with stalk (Figure. 1, Figure 2).

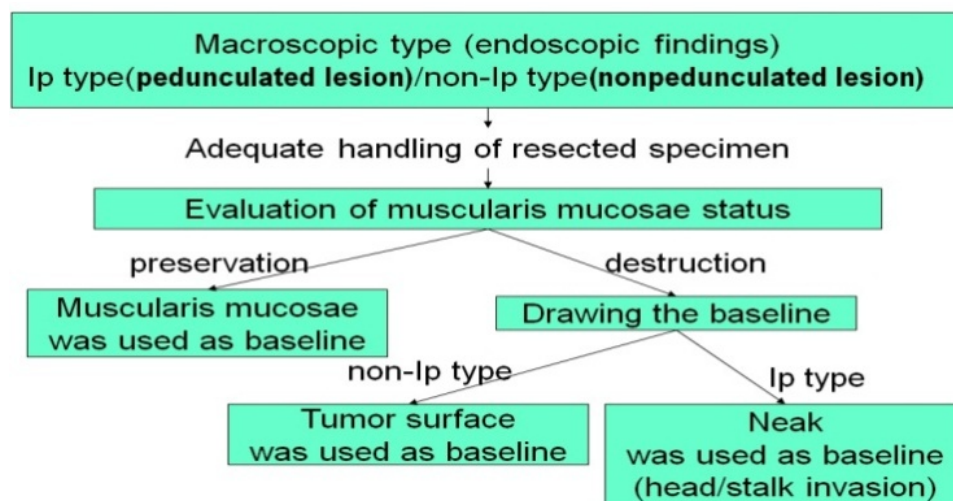


**Figure 1.** Schema of macroscopic (endoscopic) classification of SICCs: pedunculated(Ip type) and nonpedunculated(Non-Ip type). Arrowhead: muscularis mucosae.: 0  $\mu$ m



**Figure 2.** Histological appearance of pedunculated(Ip type) (a) and nonpedunculated(Non-Ip type) (b) on Hematoxylin and Eosin staining section.

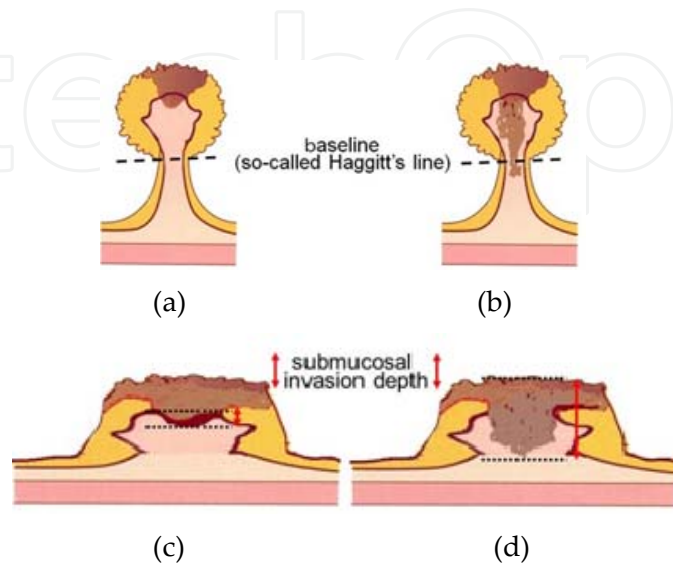
The method used for measurement of submucosal invasion depth (Figure. 3)



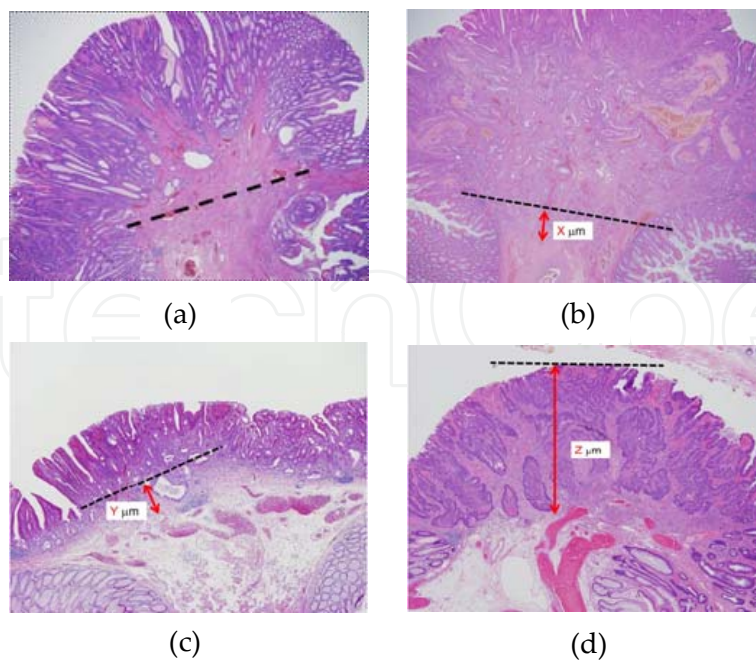
**Figure 3.** Algorithm of measurement of submucosal invasion depth.

Firstly, EMR/ESD resected specimens are divided into pedunculated (Ip type) and nonpedunculated (Non-Ip type). For pedunculated SICC, level 2 according to Haggitt's classification [9] was used as the baseline (so-called Haggitt's line), and submucosal invasion depth was measured as the vertical distance from this line to the deepest site of invasion. The baseline to distinguish between head invasion, (Figure. 4(a)) and stalk invasion, (Figure. 4(b)). In head invasion, submucosal invasion depth was regarded as 0  $\mu\text{m}$ . When the deepest portion of invasion was located below the baseline, the case was defined as a stalk invasion and the vertical distance from this line to the deepest portion of invasion was utilized as submucosal invasion depth.

On the other hand, nonpedunculated and when the muscularis mucosae could be identified in hematoxylin and eosin stain, the muscularis mucosae was used as baseline and the vertical distance from this line to the deepest site of invasion represented submucosal invasion depth, (Figure. 4(c))., however, when the muscularis mucosae could not be identified, the superficial aspect of the SICC was used as baseline, (Figure. 4(d)).



**Figure 4.** Schema of measurement of submucosal invasion depth. Ip type with head invasion (a) and stalk invasion (b), non-Ip type with muscular mucosae (c) and without muscular mucosae (d).



**Figure 5.** Histological findings with depth of submucosal invasion ( $\mu\text{m}$ ). Ip type with head invasion:  $0 \mu\text{m}$  (a) and stalk invasion:  $X \mu\text{m}$  (b), non-Ip type with muscular mucosae:  $Y \mu\text{m}$  (c) and without muscular mucosae:  $Z \mu\text{m}$  (d) on Hematoxylin and Eosin staining section

#### 4. Correlations between lymph node metastasis and depth of submucosal invasive colorectal carcinoma

The Japanese collaborative retrospectively study for 865 SICCs. This nationwide survey not only represents a first for Japan, but reviewing the literature using PubMed revealed no similar surveys from anywhere in the world at that time [3]. This study reported that pedunculated (Ip type) SICC, rate of lymph node metastasis was never in head invasion cases and stalk invasion cases with submucosal invasion depth <3000  $\mu\text{m}$  if lymphatic invasion was negative (Table 2).

And, For nonpedunculated (non-Ip type) SICC, rate of lymph node metastasis was also 0% if submucosal invasion depth was <1000  $\mu\text{m}$  (Table 3). In multivariate analysis, SM depth <1000 $\mu\text{m}$  ( $P < 0.006$ ), sprouting ( $P < 0.002$ ), and lymphatic invasion ( $P < 0.0001$ ) represented significant risk factors, with odds ratios of 5.404, 2.276, and 4.691, respectively. Several previously reports suggested that prognosis in patients with early colorectal carcinoma based on Haggitt's classification, finding that level 4 which is carcinoma invading the submucosa of the bowel wall below the stalk of the polyp but above the muscularis propria, represented the most important factor for lymph node metastasis [9, 10]. Therefore, these results revealed that submucosal invasion could be an important of predicting lymph node metastasis potential.

	Histological type at the deepest portion					
	LNM (+)	Ly (+)	V (+)	Sp (+)	wel, mod	por
SM depth ( $\mu\text{m}$ )	(%)	(%)	(%)	(%)	(%)	(%)
$X=0$ (n=53)	3 (5.7)	15 (28.3)	9 (17.0)	15 (28.3)	51 (96.2)	2 (3.8)
$0 < X < 500$ (n=10)	0 (0)	2 (20.0)	0 (0)	3 (33.3)	10 (100)	0 (0)
$500 \leq X < 1000$ (n=7)	0 (0)	1 (14.3)	0 (0)	2 (28.6)	7 (100)	0 (0)
$1000 \leq X < 1500$ (n=11)	1 (9.1)	2 (18.2)	3 (27.3)	7 (63.6)	11 (100)	0 (0)
$1500 \leq X < 2000$ (n = 7)	1 (14.3)	4 (57.1)	0 (0)	5 (71.4)	7 (100)	0 (0)
$2000 \leq X < 2500$ (n= 10)	1 (10.0)	4 (40.0)	3 (30.0)	1 (10.0)	9 (90.0)	1 (10.0)
$2500 \leq X < 3000$ (n= 4)	0 (0)	0 (0)	2 (50)	1 (25.0)	4 (100)	0 (0)
$3000 \leq X < 3500$ (n= 9)	2 (22.2)	4 (44.4)	3 (33.3)	5 (55.6)	8 (88.9)	1 (11.1)
$3500 \leq X$ (n= 30)	2 (6.7)	9 (30.0)	10 (33.3)	10 (33.3)	28 (93.3)	2 (6.7)

SICC, submucosal invasive colorectal carcinoma; SM depth, depth of submucosal invasion of SICC; LNM, lymph node metastasis; Ly, lymphatic invasion; V, venous invasion; Sp, sprouting; wel, well-differentiated adenocarcinoma; mod, moderately differentiated adenocarcinoma; por, poorly differentiated adenocarcinoma

**Table 2.** Relationship between clinicopathological factors and the rate of lymph node metastasis according to SM depth in pedunculated (Ip type) SICC (adapted from [3])

SM depth (µm)	Histological type at the deepest portion						Status of muscularis mucosae	
	LNМ (+) (%)	Ly (+) (%)	V (+) (%)	Sp (+) (%)	wel, mod (%)	por (%)	Identified (%)	Not identified (%)
0 < X < 500 (n=65)	0 (0)	5 (7.7)	3 (4.6)	9 (13.8)	64 (98.5)	1 (1.5)	64 (98.5)	1 (1.5)
500 ≤ X < 1000 (n=58)	0 (0)	12 (20.7)	7 (12.1)	7 (12.1)	58 (100)	0 (0)	51 (87.9)	7 (12.1)
1000 ≤ X < 1500 (n=52)	6 (11.5)	16 (30.8)	12 (23.1)	16 (30.8)	51 (98.1)	1 (1.9)	36 (69.2)	16 (30.8)
1500 ≤ X < 2000 (n = 82)	10 (12.2)	27 (32.9)	16 (19.5)	37 (45.1)	82 (100)	0 (0)	48 (58.5)	34 (41.5)
2000 ≤ X < 2500 (n= 84)	13 (15.5)	28 (33.3)	21 (25.0)	42 (50.0)	78 (92.9)	6 (7.1)	31 (36.9)	53 (63.1)
2500 ≤ X < 3000 (n= 71)	8 (11.3)	29 (40.8)	16 (22.5)	38 (53.5)	71 (100)	0 (0)	20 (28.2)	51 (71.8)
3000 ≤ X < 3500 (n= 72)	5 (6.9)	26 (36.1)	15 (20.8)	35 (48.6)	69 (95.8)	3 (4.2)	16 (22.2)	56 (77.8)
3500 ≤ X (n= 240)	35 (14.6)	92 (38.3)	74 (30.8)	133 (55.4)	237 (98.8)	3 (1.2)	48 (20.0)	192 (80.0)

**Table 3.** Relationship between clinicopathological factors and the rate of lymph node metastasis according to SM depth in nonpedunculated (non-Ip type) SICC (adapted from [3])

Surprisingly, Japanese collaborative retrospectively nationwide survey shows both of Ip type (pedunculated lesion) and non-Ip type (nonpedunculated lesion) of early colorectal carcinoma with rate of lymph node metastasis was also 0% if submucosal invasion depth was <1000 µm (Table 4). It is easy to measure one southern micrometer using by small ruler under microscopy for surgical pathologist. When if submucosal invasion depth was 1000 µm ≤, surgical pathologist should be advice to gastrointestinal endoscopist. And recently Japanese large-scale multicenter retrospectively study for 384 (head invasion: 240, stalk invasion: 144) pedunculated (Ip type) S ICCs demonstrated that incidence of lymph node metastasis was 3.5%. the incidence of lymph node metastasis was 0.0% inpatients with head invasion, as-compared with 6.2% in patients with stalk invasion (Tabel 4). Pedunculated type early invasive colorectal cancers pathologically diagnosed as head invasion can be only treated by endoscopic resection.



SM depth X ( $\mu\text{m}$ )			Ip type		Non-Ip type	
			n	pN positive (%)	n	pN positive (%)
head invasion (X=0)			53	3(5.7)*		
0	< X <	500	10	0(0)	65	0(0)
500	$\leq$ X <	1000	7	0(0)	58	0(0)
1000	$\leq$ X <	1500	11	1(9.1)*	52	6(11.5)
1500	$\leq$ X <	2000	7	1(14.3)*	82	10(12.2)
2000	$\leq$ X <	2500	10	1(10.0)*	84	13(15.3)
2500	$\leq$ X <	3000	4	0(0)	71	8(11.3)
3000	$\leq$ X <	3500	9	2(22.2)	72	5(6.9)
3500	$\leq$ X		30	2(6.7)	240	35(14.6)

Ip type: pedunculated lesion. Non-Ip type: nonpedunculated lesion

\*: vessels invasion

**Table 4.** Relationship between clinicopathological factors and the rate of the lymph node metastasis according to SM depth (summarized of Table 2 and 3, adapted from [11]. English translated version]

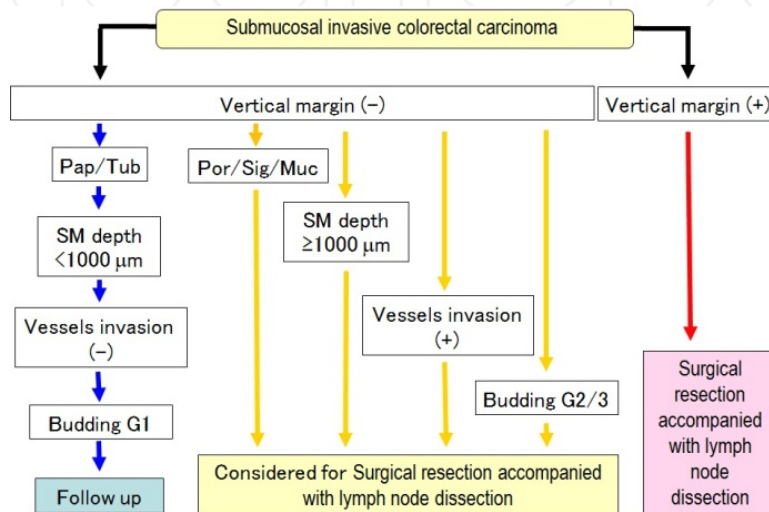
	Head invasion	Stalk invasion	Total
Lymph node metastasis n (%)	0/101 (0)	8/129 (6.2)	8/230 (3.5)
95% CI (%)	0.00–3.60P	2.70–11.90	1.50–6.70
		*P = 0.02	
Recurrence n (%)	0/219 (0)	1/121 (0.8)	1/340 (0.3)
95% CI (%)	0.00–1.70	0.02–4.50	0.01–1.60
		**P = 0.72	
Lymphovascular invasion†, n (%)	35/240 (15)	55/144 (38)	90/384 (23)
Lymphatic invasion, n (%)	21 (9)	33 (23)	54 (14)
Venous invasion, n (%)	16 (7)	37 (26)	53 (14)
Poorly differentiated component, n (%)	26/240 (11)	26/144 (18)	52/384 (14)

Lymphatic and/or venous invasion. CI, confidence interval

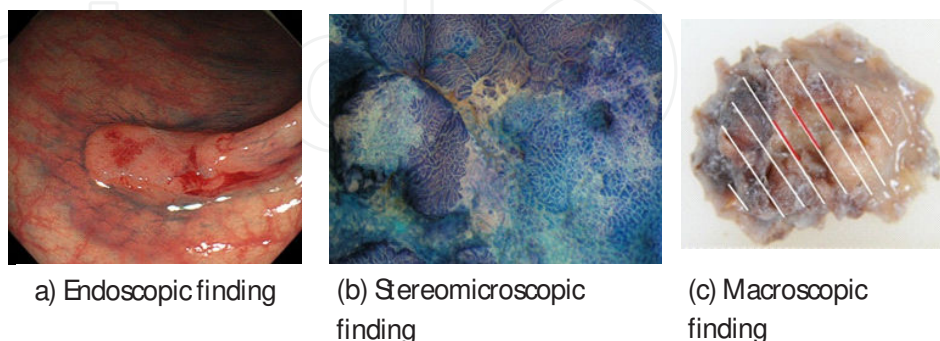
**Table 5.** Histopathological characteristics of 384 cases of pedunculated type early invasive colorectal cancer (adapted from [12])

## 5. The treatment of colorectal carcinoma with submucosal invasion state after endoscopic resection

Many new treatment methods have been developed over the last few decades. The Japanese Society for Cancer of the Colon and Rectum guidelines 2010 for the treatment of colorectal cancer (JSCCR Guidelines 2010 [13]) have been prepared to show standard treatment strategies for submucosal invasive colorectal cancer (Figure. 6).



**Figure 6.** Guide line for the treatment of colorectal carcinoma with submucosal invasion state after endoscopic resection. (adapted from JSCCR Guidelines 2010 [13] with minor modifications); Pap: papillary adenocarcinoma, Tub: tubular adenocarcinoma, Por: poorly differentiated adenocarcinoma, Sig: signet-ring cell carcinoma, Muc: mucinous adenocarcinoma, SM: submucosal invasion, Budding: tumor budding. The tumor budding denotes that at the invasion front of colorectal adenocarcinomas tumour cells, and the potential of tumour budding as a prognostic factor (G1:Grade 1 to G3: Grade 3) for routine surgical pathology [14,15])



**Figure 7.** Endoscopic, stereomicroscopic, macroscopic findings of the early colorectal carcinoma. Endoscopic finding of the pedunculated(Non-1p) type (a), several pits are arranged irregularly in the stereomicroscopic view (b), macroscopic appearance of SICC, post formalin-fixed. Most of the endoscopic detectable lesions were the irregular elevated type macroscopically. (White bar: mucosal invasion, Red bar: submucosal invasion) (c),

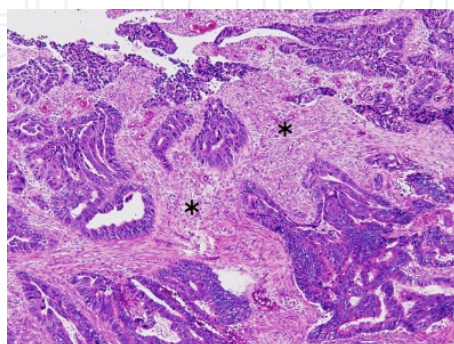
## 6. Detection of desmoplastic reaction in biopsy specimens of colorectal cancer

Early CRC, including submucosal invasive colorectal carcinoma (SICC), is defined as a tumor whose invasion is limited to the mucosa or submucosa. The endoscopic resection (EMR/ESD) have been useful for early CRC. However, endoscopic resection is applicable only to intramucosal carcinoma (Tis stage tumor), and additional surgery is required if the resected specimen reveals submucosal invasion by pathological diagnosis. However, the study of Japanese Society for Cancer of the Colon and Rectum have recently demonstrated that the depth of submucosal invasion is closely correlated with the prevalence of lymph node metastasis in patients with SICC (See. Correlations between lymph node metastasis and early colorectal Carcinoma).

Therefore, gastrointestinal endoscopist and surgical pathologist considered that it would be very useful to predict the depth of invasion of SICC before endoscopic resection for case selection. New endoscopic systems are possible to predict submucosal invasion depth without biopsy. However, these developed systems have not been used in everywhere. On the other hand, the stromal change associated with carcinoma invasion has been called desmoplastic reaction (DR), desmoplasia, and cancer-associated fibroblast. Reported incidence of the DR is suggested to be a prognostic marker in CRC patients [16, 17]. Recently, JSCCR studies have been assessed the DR in pretreatment biopsy specimens of SICRC to predict the submucosal depth in retrospective and prospective study.

The DR is characterized by modifications in the composition of stromal cells and extracellular matrix (ECM) components with eosinophilic change [18, 19] (Figure. 8). The main producers of many ECM compounds and represent the major cellular component including DR that often show differentiated phenotype with expression of the smooth muscle actin, platelet derived growth factor receptor- type I collagen [18, 20, 21].

The presence and histological findings of DR in biopsy specimens were evaluated by pathologists at each respective institute and the criteria for assessment of DR established in consensus meeting among JSCCR members including us. (Table 6).



**Figure 8.** Histological appearance of desmoplastic reaction (DR). Note the growth of eosinophilic spindle cells (myofibroblasts.\*) with submucosal invasive carcinoma component on Hematoxylin and Eosin staining section.

- 1) Existence of carcinoma is required for detection of DR.
  - 2) The histological findings of infiltrating carcinoma do not signify the presence of DR.
  - 3) DR contains areas of collagen fiber accumulation and myofibroblast proliferation, but inflammatory infiltration does not signify the presence of DR.
  - 4) All histological findings were determined by HE stain alone; detection of DR does not require the use of any special stains.
- DR, desmoplastic reaction.

**Table 6.** Criteria for detection of desmoplastic reaction (adapted from [22])

A retrospective study for detection of desmoplastic reaction in biopsy specimens of early colorectal cancer reported that 359 patients with SICRCs, who had undergone surgical or endoscopic mucosal resection, were analysed [23]. For pedunculated (Ip type) SICRCs was not significantly related to submucosal depth. However, for nonpedunculated (non-Ip type) the prevalence of DR in pretreatment biopsy specimens was significantly related to submucosal depth. When nonpedunculated(non-Ip type) SICRCs were further divided using a specific cut off value of 1000 µm for submucosal depth, the positivity ratio of DR in pretreatment biopsy specimens was significantly higher in SICRCs with an submucosal depth of 1000 µm than in cases where the submucosal depth was <1000 µm (Table 7). Detection of DR in pretreatment biopsy specimens is useful for the prediction of submucosal depth in nonpedunculated (non-Ip) SICRCs,

Depth of submucosal invasion (µm)	Pedunculated SICRC		Nonpedunculated SICRC	
	DR (-) (%)	DR (+) (%)	DR (-) (%)	DR (+) (%)
X<1000	3 (37.5)	5 (62.5)	30 (65.2)	16 (34.8)
1000 ≤ X < 2000	1 (50.0)	1 (50.0)	25 (56.8)	19 (43.2)
2000 ≤ X < 3000	5 (100)	0 (0.0)	22 (27.5)	58 (72.5)
3000 ≤ X < 4000	3 (33.3)	6 (66.7)	20 (29.9)	47 (70.1)
4000 ≤ X < 5000	0 (0.0)	1 (100)	11 (31.4)	24 (68.6)
5000 ≤ X < 6000	1 (100)	0 (0.0)	10 (43.5)	13 (56.5)
6000 ≤ X < 7000	2 (100)	0 (0.0)	5 (55.6)	4 (44.4)
7000 ≤ X < 8000	0 (0.0)	2 (100)	0 (0.0)	4 (100)
8000 ≤ X < 9000	0 (0.0)	0 (0.0)	4 (44.4)	5 (55.6)
9000 ≤ X < 10000	0 (0.0)	0 (0.0)	0 (0.0)	4 (100)
10000 ≤ X	1 (50.0)	1 (50.0)	2 (33.3)	4 (66.7)

**Table 7.** Relationship between depth of submucosal invasion and DR in biopsy specimens of patients with SICRCs - retrospective study - (adapted from [23])

After retrospective study [22], same study group confirmed verification of patients SICRC with 112 nonpedunculated (non-*Ip* type) cases. Finally, nonpedunculated (non-*Ip* type) case of the prevalence of DR was significantly correlated with submucosal depth. The sensitivity and specificity of detection of DR for prediction of pSM2 (tumor invasion  $<1000 \mu\text{m}$ ) in nonpedunculated SICRC were 68.6% and 92.0%, respectively.

Additionally, receiver operating characteristic (ROC), analysis confirmed  $950 \mu\text{m}$  as the best diagnostic cut-off value of submucosal depth for DR detection, and  $50 \mu\text{m}$ , which is the difference between the value of  $950 \mu\text{m}$  as determined by cut off value (COV) and  $1000 \mu\text{m}$ , the defining value of pSM2, is an acceptable measurement error range.

In statistics and diagnostic testing, positive predictive value (PPV) is the proportion of patients with positive test results who are correctly diagnosed, on the other hand, negative predictive value (NPV) is negative test results. Both of PPV and NPV are critical measure of the performance of a diagnostic method. In this studies revealed that PPV:0.93, NPV:0.59 in pedunculated and PPV:0.95, NPV:0.59 in nonpedunculated type. These results provide a basis for assessment of DR as a good indicator of pSM2. (Table 8).

Depth of submucosal invasion	Number of patients	DR-negative	DR-positive
pSM2	54	17	37
pM+ pSM1	27	24	3

pSM2, SM invasion  $\geq 1000 \mu\text{m}$ ; pM + pSM1, SM invasion  $< 1000 \mu\text{m}$ .

Sensitivity:  $(37/37+ 17) \times 100 = 68.5\%$ .

Specificity:  $(24/24+ 3) \times 100 = 88.9\%$ .

DR, desmoplastic reaction.

Depth of submucosal invasion	Number of patients	DR-negative	DR-positive
pSM2	51	16	35
pM+ pSM1	25	23	2

pSM2, SM invasion  $\geq 1000 \mu\text{m}$ ; pM + pSM1, SM invasion  $< 1000 \mu\text{m}$ .

Sensitivity:  $(35/35+ 16) \times 100 = 68.6\%$ .

Specificity:  $(23/23+ 2) \times 100 = 92.0\%$ .

DR, desmoplastic reaction.

**Table 8.** Relationship between depth of submucosal invasion and DR in biopsy specimens of patients with pedunculated (upper part) and nonpedunculated (lower part) type - prospective study - (adapted from [22])

## 7. Conclusion

In this issue, we have discussed the a critical role of pathological assessment for T1 stage colorectal cancer, several problems related to the pathological diagnosis of early CRC at increased risk of lymph node metastasis and submucosal invasion. A new endoscopic systems which may prove to be reliable for detection of deep submucosal invasive CRC. Moreover, current endoscopic resection (EMR/ESD) have become useful for early CRC, but, these resection is applicable only to intramucosal carcinoma, and additional surgery is required if the resected lesion reveals submucosal invasion by pathological diagnosis, because prevalence rates of lymph node metastasis about 10% of all patients with submucosal invasive colorectal carcinoma.

We believe that curative endoscopic management for early CRC may be need to accurately pathological diagnosis of submucosal depth. Assessment of DR in pretreatment biopsy specimen nonpedunculated (non-*Ip* type) and submucosal depth with head invasion or stalk invasion in pedunculated (*Ip* type) for post endoscopic resection (EMR/ESD) specimen may be useful for the clinicopathological diagnosis of colorectal carcinoma with invasion into the submucosal layer.

## Acknowledgment

The authors would like to thank member of Japanese Society for Cancer of the Colon and Rectum; Professor Ajioka (Division of Molecular and Functional Pathology, Department of Cellular Function, Graduate School of Medical and Dental Sciences, Niigata University), Dr Ueno (Department of Surgery, National Defense Medical College, Saitama, Professor Ohkura (Department of Pathology, Kyorin University School of Medicine), Professor Kashida (Department of Gastroenterology and Hepatology, Faculty of Medicine, Kinki University), Professor Togashi (Department of Gastroenterology, Fukushima Prefectural Aizu General Hospital), Professor Yao (Department of Human Pathology, Juntendo University School of Medicine) Dr Wada (Department of Pathology, Juntendo Shizuoka Hospital of Juntendo University School of Medicine), Professor Watanabe (Department of Surgical Oncology The University of Tokyo), Dr Ochiai (Pathology Division, Research Center for Innovative Oncology, National Cancer Center Hospital East), Professor Sugai (Diagnostic Pathology, Iwate Medical University, Morioka), Professor Sugihara (Surgical Oncology, Tokyo Medical and Dental University). And we also thank Dr Fujii (Center for Gastrointestinal Endoscopy, Kyoto-Katsura Hospital) for his insightful comments. Moreover, the authors greatly thank Ms C. Sato -Matsuyama, A. Shimizu, M. Katayama, (Department of Surgical and Molecular Pathology, DOKKYO Medical University School of Medicine) for technical assistance and to Ms. S. Kidachi, A. Kikuchi (Department of Surgical and Molecular Pathology, DOKKYO Medical University School of Medicine) for secretarial assistance in preparing the manuscript.

This work was partially supported by the Grant-in-Aid for Scientific Research (C: No 18659101, 23590410) from the Ministry of Education, Culture, Sports, Science and Technology (MEXT) of Japan and DOKKYO Medical University Young Investigator Award (2009, 2011, 2012).

## Author details

Shigeki Tomita, Kazuhito Ichikawa and Takahiro Fujimori

\*Address all correspondence to: sstomita@dokkyomed.ac.jp

Department of Surgical and Molecular Pathology, DOKKYO Medical University School of Medicine, Tochigi, Japan

## References

- [1] Morson. BC, Whiteway JE, Jones EA, Macrae FA, Williams CB. Histopathology and prognosis of malignant colorectal polyps treated by endoscopic polypectomy. *Gut* 1984;25(5): 437-444.
- [2] Fujimori T, Kawamata H, Kashida H. Precancerous lesions of the colorectum. *Journal of gastroenterology* 2001;36(9): 587-594.
- [3] Kitajima K, Fujimori T, Fujii S, Takeda J, Ohkura Y, Kawamata H, Kumamoto T, Ishiguro S, Kato Y, Shimoda T, Iwashita A, Ajioka Y, Watanabe H, Watanabe T, Muto T, Nagasako K. Correlations between lymph node metastasis and depth of submucosal invasion in submucosal invasive colorectal carcinoma: a Japanese collaborative study. *Journal of gastroenterology* 2004;39(6): 534-543..
- [4] Al Natour RH, Saund MS, Sanchez VM, Whang EE, Sharma AM, Huang Q, Boosalis VA, Gold JS. Tumor size and depth predict rate of lymph node metastasis in colon carcinoids and can be used to select patients for endoscopic resection. *Journal of gastrointestinal surgery* 2012;16(3): 595-602.
- [5] Cooper HS. Surgical pathology of endoscopically removed malignant polyps of the colon and rectum. *The American journal of surgical pathology* 1983;7(7): 613-623.
- [6] Minamoto T, Mai M, Ogino T, Sawaguchi K, Ohta T, Fujimoto T, Takahashi Y. Early invasive colorectal carcinomas metastatic to the lymph node with attention to their nonpolypoid development. *The American journal of gastroenterology* 1993;88(7): 1035-1039.
- [7] Coverlizza S, Risio M, Ferrari A, Fenoglio-Preiser CM, Rossini FP. Colorectal adenomas containing invasive carcinoma: pathologic assessment of lymph node metastatic potential. *Cancer* 1989;64(9): 1937-1947.
- [8] Netzer P, Forster C, Biral R, Ruchti C, Neuweiler J, Stauffer E, Schönegg R, Maurer C, Hüsler J, Halter F, Schmassmann A. Risk factor assessment of endoscopically removed malignant polyps. *Gut* 1998;43(5): 669-674.

- [9] Haggitt RC, Glotzbach RE, Soffer EE, Wruble LD. Prognostic factors in colorectal carcinomas arising in adenomas: implications for lesions removed by endoscopic polypectomy. *Gastroenterology* 1985;89(2): 328-36.
- [10] Pollard CW, Nivatvongs S, Rojanasakul A, Reiman HM, Dozois RR. The fate of patients following polypectomy alone for polyps containing invasive carcinoma. *Diseases of the colon and rectum* 1992;35(10): 933-937.
- [11] Japanese Society for Cancer of the Colon and Rectum. Japanese Society for Cancer of the Colon and Rectum (JSCCR) guidelines 2005 for the treatment of colorectal cancer. In Japanese, Tokyo, Kanehara: 2005.
- [12] Matsuda T, Fukuzawa M, Uraoka T, Nishi M, Yamaguchi Y, Kobayashi N, Ikematsu H, Saito Y, Nakajima T, Fujii T, Murakami Y, Shimoda T, Kushima R, Fujimori T. Risk of lymph node metastasis in patients with pedunculated type early invasive colorectal cancer: a retrospective multicenter study. *Cancer science* 2011;102(9): 1693-1697
- [13] Watanabe T, Itabashi M, Shimada Y, Tanaka S, Ito Y, Ajioka Y, Hamaguchi T, Hyodo I, Igarashi M, Ishida H, Ishiguro M, Kanemitsu Y, Kokudo N, Muro K, Ochiai A, Oguchi M, Ohkura Y, Saito Y, Sakai Y, Ueno H, Yoshino T, Fujimori T, Koinuma N, Morita T, Nishimura G, Sakata Y, Takahashi K, Takiuchi H, Tsuruta O, Yamaguchi T, Yoshida M, Yamaguchi N, Kotake K, Sugihara K; Japanese Society for Cancer of the Colon and Rectum. Japanese Society for Cancer of the Colon and Rectum (JSCCR) guidelines 2010 for the treatment of colorectal cancer. *International journal of clinical oncology* 2012;17(1): 1-29.
- [14] Prall F. Tumour budding in colorectal carcinoma. *Histopathology* 2007;50(1): 151-162.
- [15] Ueno H, Murphy J, Jass JR, Mochizuki H, Talbot IC. Tumour 'budding' as an index to estimate the potential of aggressiveness in rectal cancer. *Histopathology* 2002;40(2): 127-132.
- [16] Nakada I, Tasaki T, Ubukata H, Goto Y, Watanabe Y, Sato S, Tabuchi T, Tsuchiya A, Soma T. Desmoplastic response in biopsy specimens of early colorectal carcinoma is predictive of deep submucosal invasion. *Diseases of the colon and rectum* 1998;41(7): 896-900.
- [17] Tsujino T, Seshimo I, Yamamoto H, Ngan CY, Ezumi K, Takemasa I, Ikeda M, Sekimoto M, Matsuura N, Monden M. Stromal myofibroblasts predict disease recurrence for colorectal cancer. *Clinical cancer research* 2007;13(7): 2082-2090.
- [18] Ban S, Shimizu M. Muscularis mucosae in desmoplastic stroma formation of early invasive rectal adenocarcinoma. *World journal of gastroenterology* 2009;15(39): 4976-4979.
- [19] Karagiannis GS, Petraki C, Prassas I, Saraon P, Musrap N, Dimitromanolakis A, Diamandis EP. Proteomic signatures of the desmoplastic invasion front reveal collagen



type XII as a marker of myofibroblastic differentiation during colorectal cancer metastasis. *Oncotarget*. 2012;3(3): 267-285.

- [20] De Wever O, Demetter P, Mareel M, Bracke M. Stromal myofibroblasts are drivers of invasive cancer growth. *International journal of cancer* 2008;123(10): 2229-2238.
- [21] Kimura R, Fujimori T, Ichikawa K, Ajioka Y, Ueno H, Ohkura Y, Kashida H, Togashi K, Yao T, Wada R, Watanabe T, Ochiai A, Sugai T, Sugihara K, Igarashi Y. Desmoplastic reaction in biopsy specimens of early colorectal cancer: A Japanese prospective multicenter study. *Pathology international* 2012;62(8): 525-531.
- [22] Schmid SA, Dietrich A, Schulte S, Gaumann A, Kunz-Schughart LA. Fibroblastic reaction and vascular maturation in human colon cancers. *International journal of radiation biology* 2009;85(11): 1013-1025.
- [23] Hirose M, Fukui H, Igarashi Y, Fujimori Y, Katake Y, Sekikawa A, Ichikawa K, Tomita S, Imura J, Ajioka Y, Ueno H, Hase K, Ohkura Y, Kashida H, Togashi K, Nishigami T, Matsui T, Yao T, Wada R, Matsuda K, Watanabe T, Ochiai A, Sugai T, Sugihara K, Fujimori T. Detection of desmoplastic reaction in biopsy specimens is useful for predicting the depth of invasion of early colorectal cancer: a Japanese collaborative study. *Journal of gastroenterology* 2010;45(12): 1212-1218.