

We are IntechOpen, the world's leading publisher of Open Access books Built by scientists, for scientists

4,800

Open access books available

122,000

International authors and editors

135M

Downloads

Our authors are among the

154

Countries delivered to

TOP 1%

most cited scientists

12.2%

Contributors from top 500 universities



WEB OF SCIENCE™

Selection of our books indexed in the Book Citation Index
in Web of Science™ Core Collection (BKCI)

Interested in publishing with us?
Contact book.department@intechopen.com

Numbers displayed above are based on latest data collected.
For more information visit www.intechopen.com



More than Half of Patients Receiving Hemodialysis with Leg Ulcer Require Amputation

Masaki Fujioka

Additional information is available at the end of the chapter

<http://dx.doi.org/10.5772/52240>

1. Introduction

Patients receiving hemodialysis (HD) often develop leg ulcers, which are difficult to heal because of complications of other diseases, including diabetes mellitus (DM), calciphylaxis, collagen disease, peripheral arterial disorder (PAD), chronic anemia, and weakness of the skin (Figure 1) [1-3]. Especially, infection of an ulcer is associated with the risk of sepsis, which may be fatal if the blood access shunt becomes infected [4]. Some surgical treatment is usually required in these cases.

This article focuses on the prognosis and results of treating these wounds in patients receiving HD.

2. Patients and methods

We evaluated 57 patients receiving HD (male: 37, female: 20, and 32 because of diabetes mellitus, 22 because of chronic glomerulonephritis, 2 because of polycystic kidney, and 1 because of systemic lupus erythematosus) who had leg ulcers and underwent surgical treatment in our unit from 2004 through 2011. Patients ranged in age from 43 to 95 years (median age: 69 years).

Ninety-four patients with leg ulcers due to DM (male: 53, female: 41) who underwent surgical treatment in our unit from 2004 through 2011, were also investigated as a control. They ranged in age from 26 to 93 years (median age: 59.5 years) (no significant difference, Wilcoxon rank sum test).

I investigated differences in the cause of wounds, type of surgery, and their mortality to evaluate the severity of the wounds in patients receiving HD.

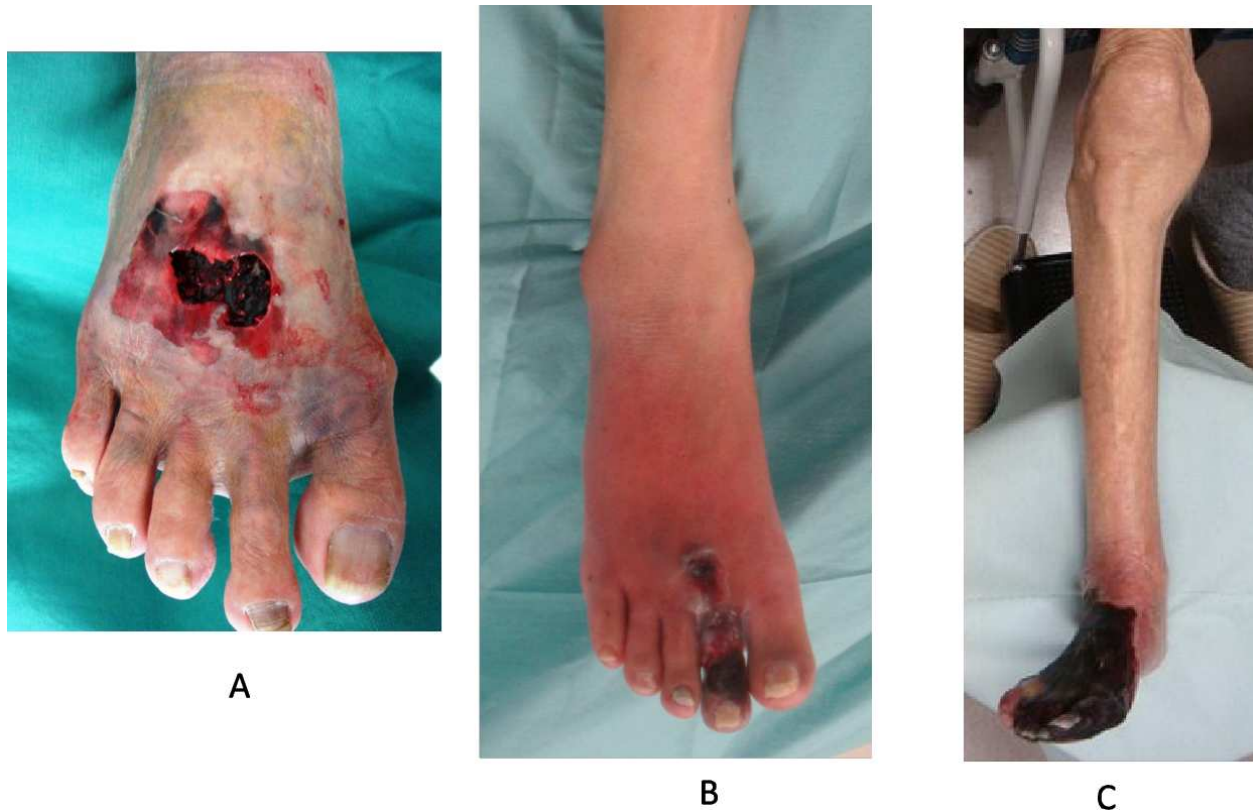

Figure 1. Patients receiving hemodialysis often develop leg ulcers due to several causes, including trauma (A: skin defect following developing a hematoma due to falling on a step), infection (B: diabetic gangrene), peripheral arterial disorder (C: leg dry necrosis due to arteriosclerosis obliterans).

3. Results

3.1. Causes of leg ulcers in patients with HD and DM

Leg ulcers in patients undergoing hemodialysis were originated due to ischemia in 34 cases (60%), infection in 13 cases (23%), and trauma in 10 cases (17%). Those in patients with DM were originally due to ischemia in 18 cases (19%), infection in 61 cases (65%), and trauma in 15 cases (16%) (Figure 2). HD-receiving patients were significantly more likely to develop leg ulcers due to PAD comparing to those with DM ($p < 0.001$, Chi-square test).

3.2. Treatments for leg ulcers in patients with HD and DM

In the HD-receiving patient group, 30 patients (52%) underwent amputation surgery. Among them, 19 (33%) required major (below or above the knee) amputations, while 39 (42%) underwent amputation surgery, including 11 (12%) major amputations in the patients

with leg ulcers due to DM (Figure 3). There was a significant differences between the groups in the frequency of amputation ($p < 0.05$, Chi-square test) and that of major amputation ($p < 0.001$, Chi-square test).

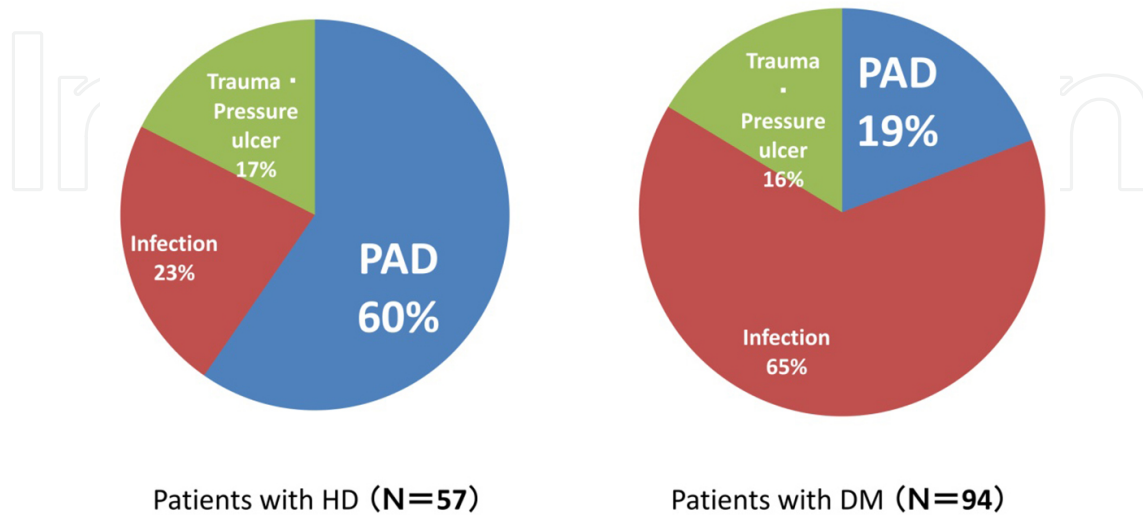


Figure 2. Causes of leg ulcers in patients with HD and DM (PAD: peripheral arterial disorder)

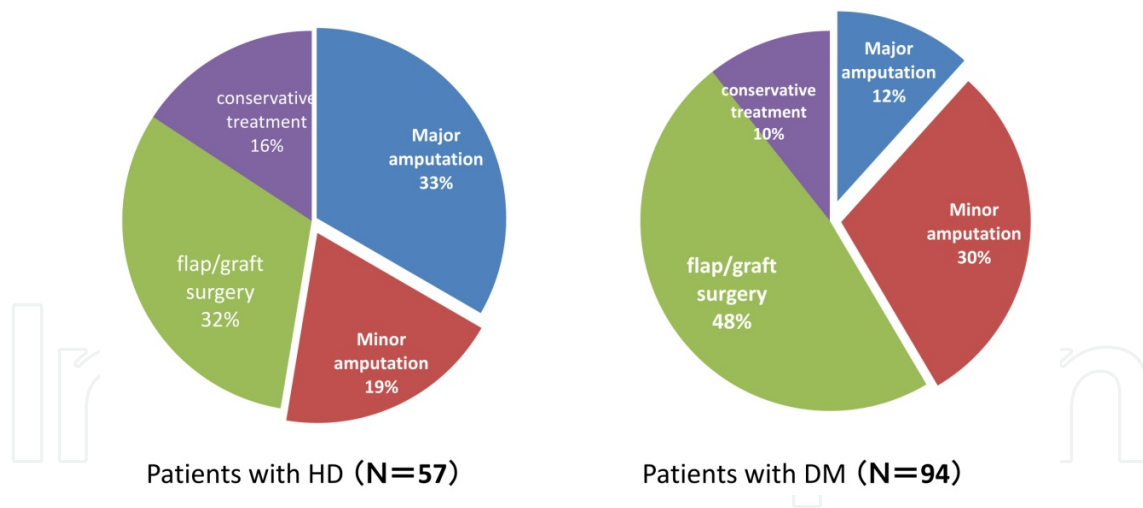


Figure 3. Treatments for leg ulcers in patients with HD and DM

3.3. Mortality of patients with leg ulcers

Three patients (5%) with HD died of contaminated foot ulcers, and 3 (3%) with DM (Figure 4). There were no significant differences in mortality between the 2 groups ($p > 0.05$, Chi-square test).

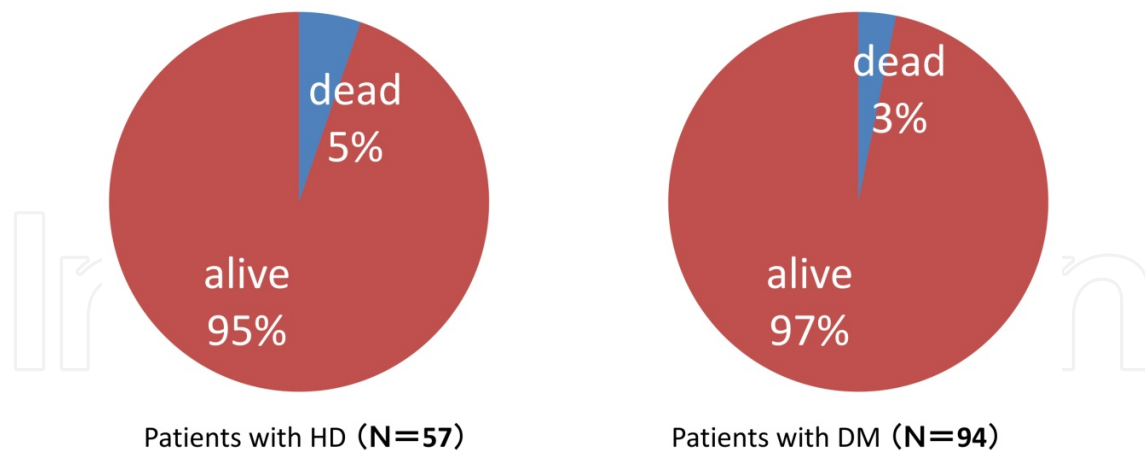


Figure 4. Mortality of patients with leg ulcers

4. Discussion

Chronic renal failure (CRF) affects all the systems of the body, causing neurological, gastrointestinal, cardiovascular, pulmonary, hematological, endocrine-metabolic, and dermatological disorders [5]. Among them, cutaneous disorders are one of the common problems in patients on long-term hemodialysis. The commonest skin disorders are xerosis and pruritus [6, 7]. The skin of patients on hemodialysis is dry, and so the skin barrier structure and function are impaired [8]. Formerly, it was believed that the impaired skin resistance and stimuli caused by scratching because of itchy skin cause continuous inflammations, which contribute to local skin ulcers [9]. Of course, these problems may be the causes of erosion or slight ulcers in HD-receiving patients. However, my study revealed that severe leg ulcers, which may require amputation, were mainly caused by some complications such as PAD and infection^[10].

Difficulty healing wounds is a frequent problem in patients on HD because of their poor general conditions, including malnutrition, inflammation, and PAD [1]. Mistrík et al. reported a significant decrease in skin blood flow during the HD procedure, and concluded that the skin blood flow may be impaired in HD patients, which leads to the development of difficulty in healing skin wounds^[3]. Regarding cutaneous infection, the incidence of fungal infection in patients undergoing hemodialysis was 67%, which suggested that adequate foot care had not been performed for these patients [11]. CRF patients exhibit impaired cellular immunity due to a decreased T-lymphocyte cell count; this could explain the increased prevalence of infections [12]. Consequently, patients receiving HD were associated with higher complication rates and mortality when they developed leg ulcers [13].

Patients with severely ischemic legs due to maintenance HD often require multiple surgeries because arteriosclerosis obliterans usually progresses, which causes other ischemic ulcers (Figure 5-8). Amputations of legs or fingers are sometimes performed for these complex ulcers, because patients receiving HD are thought to present with immunocompromised con-

ditions, and aggressive life-threatening infections such as sepsis require immediate surgical debridement in order to salvage the blood access line and save their lives (Figures 7, 9, 10). Administering antibiotics for a contaminated wound containing necrotic tissue is of no use because they cannot affect a non-vascularized or necrotic mass. Immediate surgical debridement is the only choice to improve these soft tissue infections [14, 15]. Surgical amputation is sometimes recommended to resurface these wounds, especially for some ischemic wounds including dry necrosis of toes and feet (Figure 9). My study revealed that more than half of patients underwent toe or leg amputation.

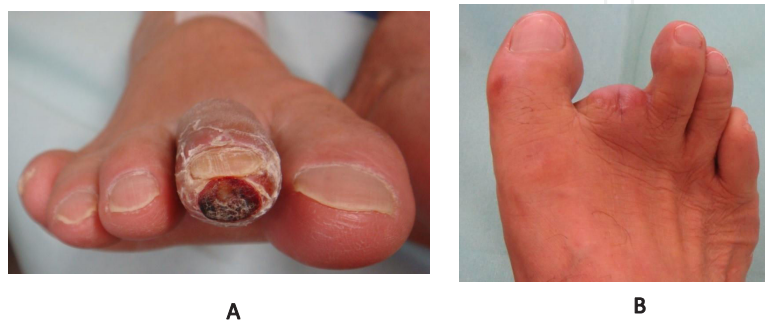


Figure 5. Case 1. Ischemic ulcer (A) The photograph shows a necrotic wound of right 2nd toe in a patient receiving HD at the initial examination. He was also diagnosed with peripheral arterial disorder. (B) He underwent amputation of the toe and the wound was healed.

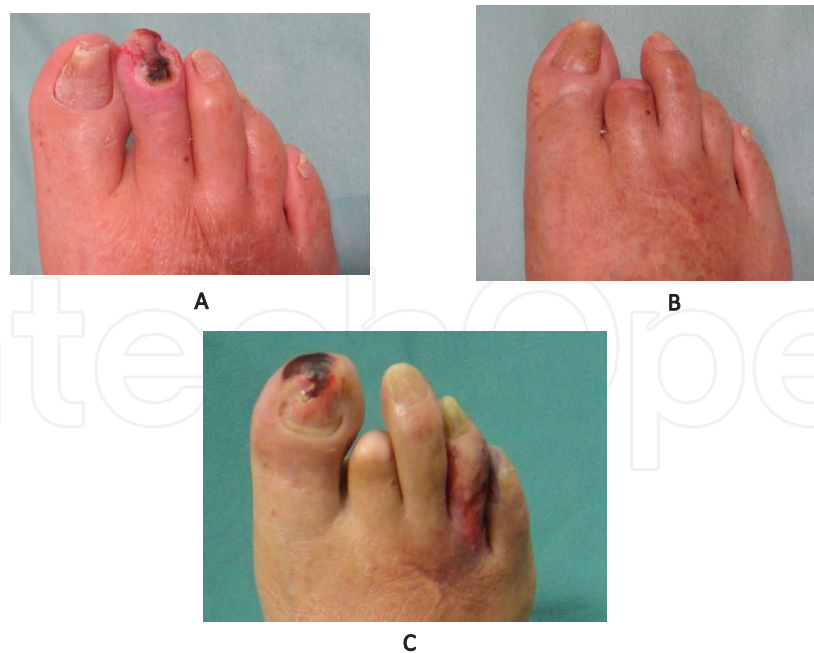

Figure 6. Case 2. Ischemic ulcer (PAD) (A) The photograph shows a necrotic wound of the right 2nd toe in a patient receiving HD at the initial examination. He was also diagnosed with peripheral arterial disorder. (B) He underwent amputation of the toe and the wound was healed. (C) However, he developed another ischemic ulcer 20 months later and required another amputation.

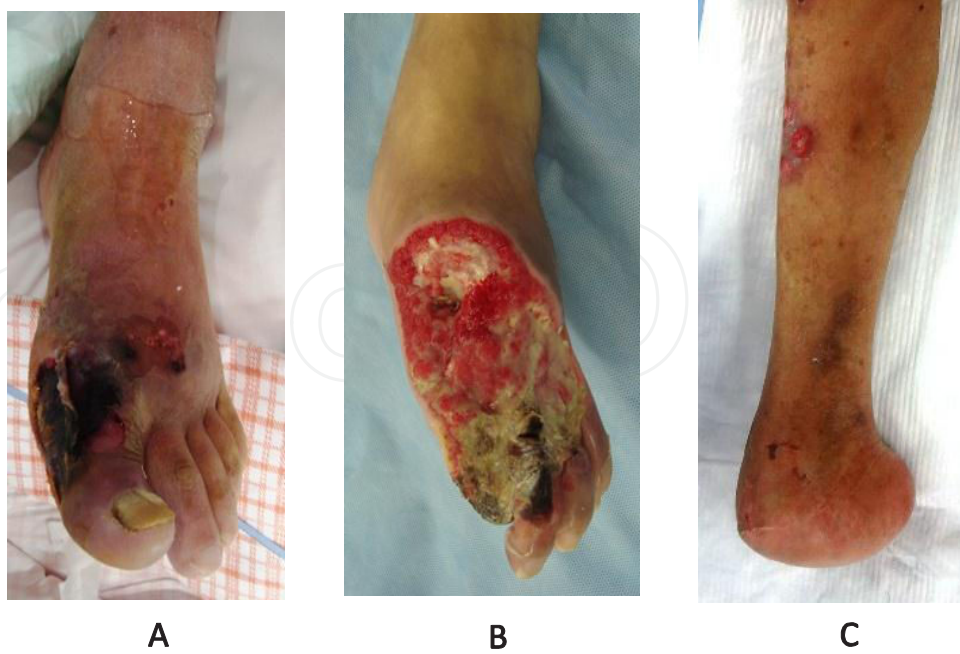

Figure 7. Case 3. Foot burn (trauma) (A) The patient was referred from an emergency unit for a complex necrotic ulcer caused by a burn to the left foot, with a high fever. As his blood access shunt in the right elbow also showed inflammation, amputation of the left big and 2nd toes was immediately performed. (B) As soft tissue necrosis progressed after debridement, and osteomyelitis occurred 1 month later, he underwent further amputation. (C) Finally, he underwent Chopart's joint amputation 2 months later.

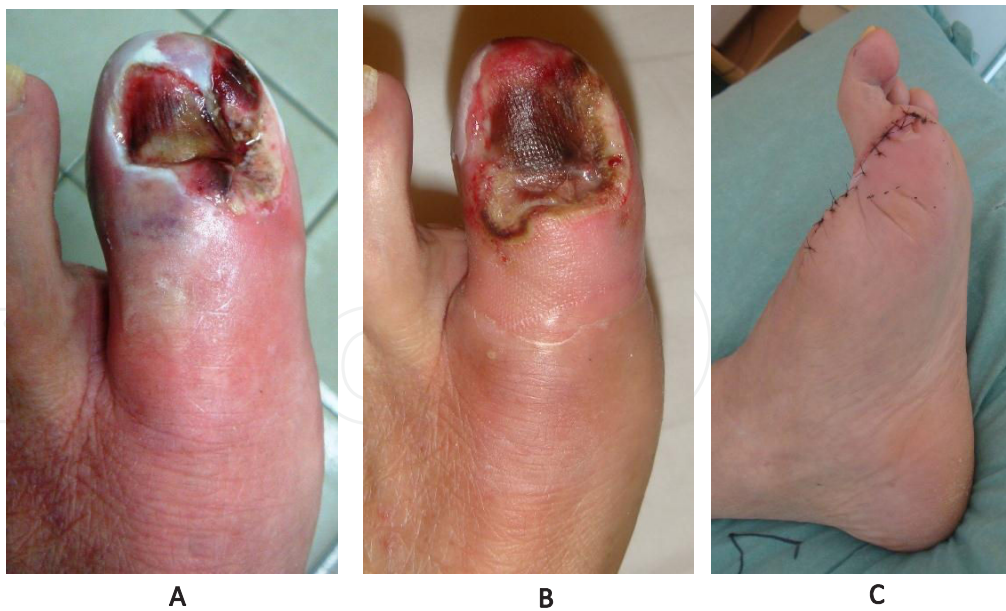

Figure 8. Case 4. Onychia periungualis (infection) (A) An HD-receiving patient developed onychia periungualis of the left 1st toe. (B) Although, he underwent the removal of the nail and antibiotic treatment, the ulcer and toe necrosis progressed. (C) The patient underwent amputation of the 1st and 2nd toes. (D) However, wound healing was unfavorable, because of the peripheral arterial disorder, thus, further amputation was required. (E) One month after the 3rd toe amputation, the wounds healed satisfactorily.

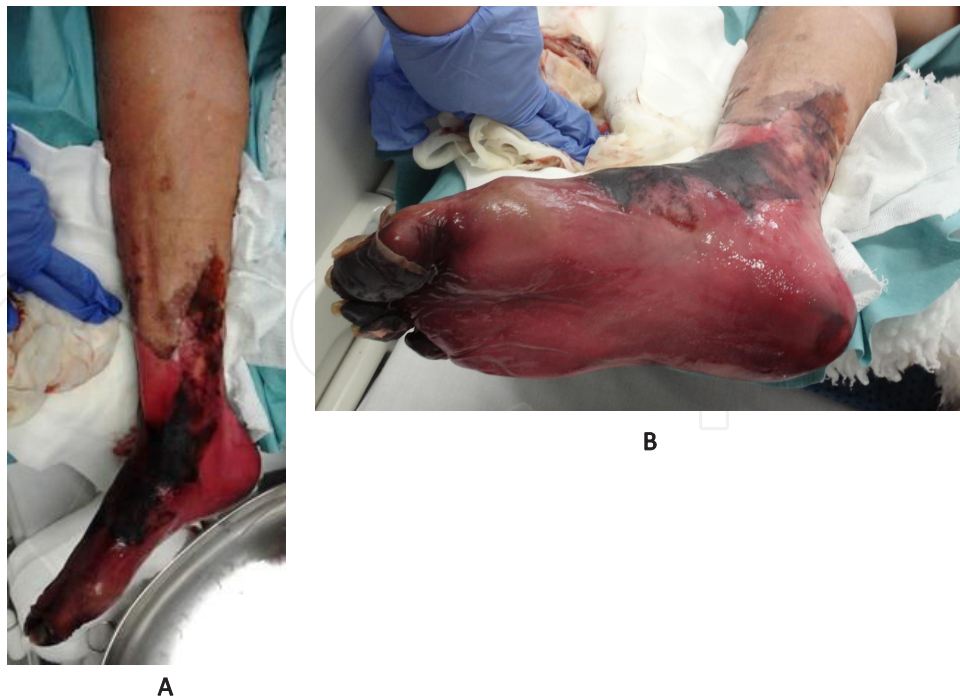


Figure 9. Case 5. Ischemic ulcer (PAD) (A) The photograph shows a necrotic wound of the right foot in a patient receiving HD at the initial examination. He was also diagnosed with peripheral arterial disorder. (B) As he developed sepsis and his blood access shunt in the right elbow also showed inflammation, he underwent below the knee amputation immediately, and the wound healed.

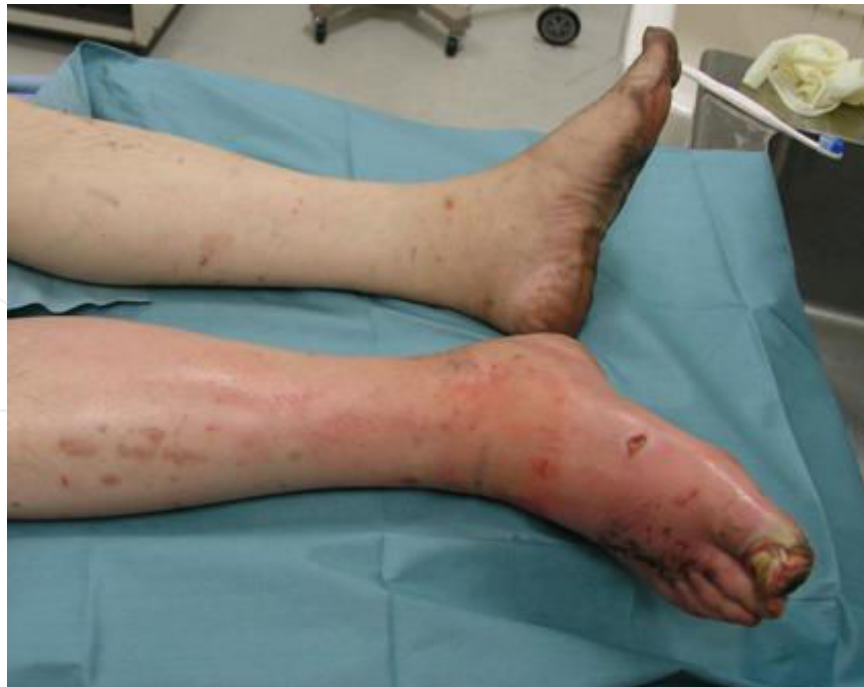

Figure 10. Case 6. Necrotizing fasciitis (infection) The photograph shows necrotizing fasciitis of the right foot in a patient receiving HD at the initial examination. He underwent below the knee amputation immediately.

I have investigated ulcers requiring surgical treatment, and the present study indicates that the development of severe leg ulcers in patients with HD is strongly influenced by ischemia due to PAD. Several investigators have reported incidences of peripheral arterial occlusive disease in patients receiving HD, ranging from 2.5 to 19.0% [16, 17].

These wounds usually develop infection, and often result in higher mortality rates because blood access shunts, especially when an artificial vessel is grafted, are easily infected. All my patients with infectious wounds (14 cases) required immediate debridement, including amputation to prevent such unfavorable general infections, because aggressive local inflammatory reactions had already developed.

On the other hand, the development of ulcers in patients with DM (control group) was mainly due to infection, which is so-called diabetic gangrene and is known to be life-threatening. My study revealed that there were no significant differences in mortality between the DM and HD groups. This suggested that the control of infection by aggressive debridement, including amputation, is the most important for the treatment of both local and general infection and saving the lives of patients. When initial debridement is insufficient and local infection recurs, further debridement should be performed. Wound infection cannot be controlled in the presence of necrotic tissue; therefore, amputation of fingers or legs is sometimes recommended, especially, when the patients show an septic status.

5. Conclusion

I conclude that patients receiving HD developed leg ulcers mainly due to PAD. They were likely to be more severe and progressive. Thus, they frequently require amputation before blood access shunts are infected.

Author details

Masaki Fujioka

Address all correspondence to: mfujioka@nmc.hosp.go.jp

Department of Plastic and Reconstructive Surgery, National Hospital Organization Nagasaki Medical Center, Ohmura City, Japan

References

- [1] Mistřík E, Dusilová-Sulková S, Bláha V, Sobotka L. Plasma albumin levels correlate with decreased microcirculation and the development of skin defects in hemodialyzed patients. *Nutrition*. 2010 Sep;26(9):880-5.

- [2] Stein, A. A. and Wiersum, J.: The Role of Renal Dysfunction in Abdominal Wound Dehiscence. *J. Urol.*, 1959;82:271.
- [3] Mistrík E, Dusilová-Sulková S, Bláha V, Sobotka L. Plasma albumin levels correlate with decreased microcirculation and the development of skin defects in hemodialyzed patients. *Nutrition*. 2010;26(9):880-885.
- [4] Fujioka Masaki, Oka Kiyoshi, Kitamura Riko, Yakabe Aya. Complex wounds tend to develop more rapidly in patients receiving hemodialysis because of diabetes mellitus. *Hemodial Int.* (2009). , 13(2), 168-171.
- [5] Hajheydari Z, Makhloogh A. Cutaneous and mucosal manifestations in patients on maintenance hemodialysis: a study of 101 patients in Sari, Iran. *Iran J Kidney Dis*. 2008;2(2):86-90.
- [6] Robinson-Boston, L., & Di Giovanna, J. J. Cutaneous Manifestations of end-stage renal disease. *J Am Acad Dermatol.* (2000). , 43, 975-986.
- [7] Udayakumar P, Balasubramanian S, Ramalingam KS, Lakshmi C, Srinivas CR, Mathew AC. Cutaneous manifestations in patients with chronic renal failure on hemodialysis. *Indian J Dermatol Venereol Leprol.* 2006;72(2):119-125.
- [8] Yosipovitch G, Duque MI, Patel TS, Ishiuiji Y, Guzman-Sanchez DA, Dawn AG, Freedman BI, Chan YH, Crumrine D, Elias PM. Skin barrier structure and function and their relationship to pruritus in end-stage renal disease. *Nephrol Dial Transplant.* 2007;22(11):3268-3272.
- [9] Razeghi E, Omati H, Maziar S, Khashayar P, Mahdavi-Mazdeh M. Chronic inflammation increases risk in hemodialysis patients. *Saudi J Kidney Dis Transpl.* 2008;19(5): 785-789.
- [10] Masaki Fujioka. Complex Wounds in Patients Receiving Hemodialysis. In: Maria GP. (ed.) *Technical Problems in Patients on Hemodialysis.*, Rijeka: InTech; (2011). , 121-146.
- [11] Bencini, P. L., Montagnino, G., Citterio, A., Graziani, G., Crosti, C., & Ponticelli, C. (1985). Cutaneous abnormalities in uremic patients. *Nephron*, 40, 316-321.
- [12] Pico, M. R., & Lugo-Somolinos, A. Cutaneous alterations in patients with chronic renal failure. *Int J Dermatol* (1992). , 31, 860-863.
- [13] Patel MS, Malinoski DJ, Nguyen XM, Hoyt DB. The impact of select chronic diseases on outcomes after trauma: a study from the National Trauma Data Bank. *J Am Coll Surg.* 2011;212(1):96-104.
- [14] Schultz GS, Sibbald RG, Falanga V, Ayello EA, Dowsett C, Harding K, Romanelli M, Stacey MC, Teot L, Vanscheidt W. Wound bed preparation: a systematic approach to wound management. *Wound Repair Regen.* 2003;11 Suppl 1:S1-28.

- [15] Attinger CE, Janis JE, Steinberg J, Schwartz J, Al-Attar A, Couch K. Clinical approach to wounds: débridement and wound bed preparation including the use of dressings and wound-healing adjuvants. *Plast Reconstr Surg.* 2006;117(7 Suppl):72S-109S.
- [16] Ibels LS, Stewart JH, Mahony JF, Neale FC, Sheil AG. Occlusive arterial disease in uraemic and haemodialysis patients and renal transplant recipients. A study of the incidence of arterial disease and of the prevalence of risk factors implicated in the pathogenesis of arteriosclerosis. *Q J Med.* (1977). , 46, 197-214.
- [17] Bergesio F, Ciuti R, Salvadori M, et al. Are lipid abnormalities reliable cardiovascular risk factors in dialysis patients? *Int J Artif Organs.* 1989;12:677-682.