

We are IntechOpen, the world's leading publisher of Open Access books Built by scientists, for scientists

4,800

Open access books available

122,000

International authors and editors

135M

Downloads

Our authors are among the

154

Countries delivered to

TOP 1%

most cited scientists

12.2%

Contributors from top 500 universities



WEB OF SCIENCE™

Selection of our books indexed in the Book Citation Index
in Web of Science™ Core Collection (BKCI)

Interested in publishing with us?
Contact book.department@intechopen.com

Numbers displayed above are based on latest data collected.

For more information visit www.intechopen.com



Navigation in Endovascular Aortic Repair

Geir Arne Tangen, Frode Manstad-Hulaas,
Reidar Brekken and Toril A. N. Hernes

Additional information is available at the end of the chapter

<http://dx.doi.org/10.5772/55097>

1. Introduction

The formation and growth of an aortic aneurysm may lead to rupture resulting in life threatening haemorrhage. Aortic replacement, either by open surgery or endovascular aortic repair (EVAR), is recommended when the maximum diameter of the aneurysm increases rapidly or exceeds 55mm for the thoracic aorta or 50-55mm for the abdominal aorta (Brewster et al., 2003; Hiratzka et al., 2010; Lederle et al., 2002; Moll et al., 2011).

In EVAR, instruments and the aortic prosthesis (stent graft) are normally inserted from the femoral arteries and into the aneurysmatic aorta under the guidance of fluoroscopy and digital subtraction angiography (DSA). Although mandatory in all endovascular procedures, radiation and contrast medium constitute some of the most important disadvantages in endovascular aortic repair in regards to skin erythema and contrast media-induced nephropathy (Geijer et al., 2005; Morcos et al., 2005). The radiation exposure to staff during endovascular procedures is low (Ho et al., 2007), but not negligible. It is possible to treat complex aortic aneurysms (e.g. juxtarenal and thoracoabdominal aneurysms) with endovascular technique, but the stent grafts usually have to be patient specific and may contain scallops, fenestrations or directional cuffs. Since the fluoroscopic and DSA images are 2-dimensional, the impression of depth is insufficient, making challenging procedures more time consuming. Poor opacification in some regions of the aorta and increased use of radiation and contrast medium constitute limitations in the endovascular approach to complex aneurysms (Greenberg et al., 2006).

In surgical *navigation*, pre-operative three-dimensional (3D) medical images are combined with a positioning system that is able to track the position of different instruments during intervention. The instruments can then be visualized within the 3D images, giving the physician a better spatial visualization and understanding of the patient's vascular anatomy, including the position and orientation of instruments. At the same time the use of radiation and contrast medium is reduced.

In this chapter we give a brief introduction to the development of the guidance techniques currently used during EVAR, before the present state-of-the-art and future navigation technology for EVAR are emphasized. Finally, we will discuss future clinical potential technological possibilities and challenges related to navigation in EVAR.

2. Current image guidance in EVAR

The visual information required during EVAR is common for all image-guided procedures; the operator needs to see the instrument(s) and the surrounding anatomy. In EVAR, this means that the catheters, guide wires, stent grafts and the vascular anatomy has to be sufficiently presented to the operator. This can be achieved by using X-rays, both without and in combination with a contrast medium.

In 1948 Coltman (Coltman et al. 1948) invented the first image intensifier, a device that made it possible to view X-ray images directly in daylight. If radiation was applied continuously, the movement of an object could be followed. Since the image intensifier was based on a fluorescent screen (Phosphor), the visualization technique became known as “fluoroscopy”. Today the flat panel detector with increased sensitivity to X-rays and better temporal resolution has replaced the image intensifier.

When a contrast medium is injected into the vascular system, in interventional radiology usually through a catheter directly into the vessel(s) of interest, an angiogram is acquired. However, in the original angiogram all other anatomical structures are overlaying the contrast-filled vessels. During the 1970s the digital video subtraction was developed, a technique that made it possible to subtract a pre-contrast X-ray image from a post-contrast X-ray image. Then only the contrast-loaded structures were presented. The digital video subtraction was originally developed for intravenously injected contrast medium, but Crummy et al. (Crummy et al. 1982) presented in 1981 a work where the technique was applied on intra-arterial catheter-based injections. This technique, today known as digital subtraction angiography (DSA), reduced the need for contrast medium and made it possible to obtain a vascular “roadmap”.

Fluoroscopy, angiography, DSA and roadmaps are used during EVAR to guide the instruments and facilitate an optimal positioning and alignment of the stent graft. Special attention is given to branching vessels to avoid vessel occlusion or compromised circulation. Despite that fluoroscopy and DSA are 2 dimensional images, they have until the present remained cornerstones in all image guided vascular interventions, including EVAR. Perhaps we are facing a paradigm shift?

3. Navigation technology in EVAR

Minimal invasive procedures require new technology for navigation. In procedures without direct visual access to the operating field, the operator depends on updated

images of the related anatomy. Using 2D images with limited contrast information can be a challenge to the operator. Extensive experience is required to be able to interpret the image information and relate it to the 3D anatomy and at the same time guide the instruments with high precision. The procedures can be time-consuming and result in considerable contrast and radiation dose to the patient and contribute to the accumulated radiation dose to the medical staff. These issues are addressed in modern navigation technology solutions.

The introduction of the stereotactic frame by Horsley and Clarke (Clarke & Horsley, 1906) made it possible for the surgeons to precisely target anatomical structures deep inside the brain during neurosurgery. After the invention of medical imaging technology, such as the computed tomography (CT) scanner in early 1970s and some years later the magnetic resonance imaging (MRI) scanner, the concept of image guided surgery/therapy has evolved immensely. Especially the introduction of the personal computer (PC) around 1980, when computing power became more available to researchers and the general public, contributed to the development of navigation technology. From its humble start in neurosurgery, image guided technology has gradually made its way into other areas of medicine like oncology, orthopedics etc., and can today be found as an integrated part in multiple medical disciplines.

3.1. Imaging and visualization technology

The technologic development in computer science, image processing and robot technology results in continuous advances in medical imaging equipment. The high-resolution 3D imaging only available in a CT lab a few years ago, now finds its way into the operating rooms (OR). Modern hybrid angiography suites are fully equipped ORs, reducing the complexity of patient logistics. An emergency patient today can in many cases be transferred directly to the angiography suite (or OR with intraoperative imaging equipment) without stopping at the separate CT lab, and thus save valuable time. In the angiography suite, a Cone-Beam CT acquires an advanced 3D image of the patient. The 3D image provides diagnostic information and can be used for navigation during the EVAR procedure. A 3D CT can also be acquired intra-operatively, presenting an updated 3D map of the relevant anatomy to the operator during the operation (Eide et al. 2011).

The advances in registration technology have made it possible to display a combination of image modalities to the EVAR operator. One example is the Syngo iPilot (Siemens, Medical Solutions, Erlangen, Germany), which combines 2D fluoroscopy/roadmap images with preoperative 3D CT models in real time, helping the operator navigate complex 3D vessel anatomy.

Modern computer graphics hardware and algorithms enables visualisation of high quality 3D renderings of image data in real-time. Surfaces can be extracted from the image data and visualized as polygon data objects. Image data can be visualized directly through 2D slices or as 3D voxel data with volume rendering techniques as shown in figure 1.

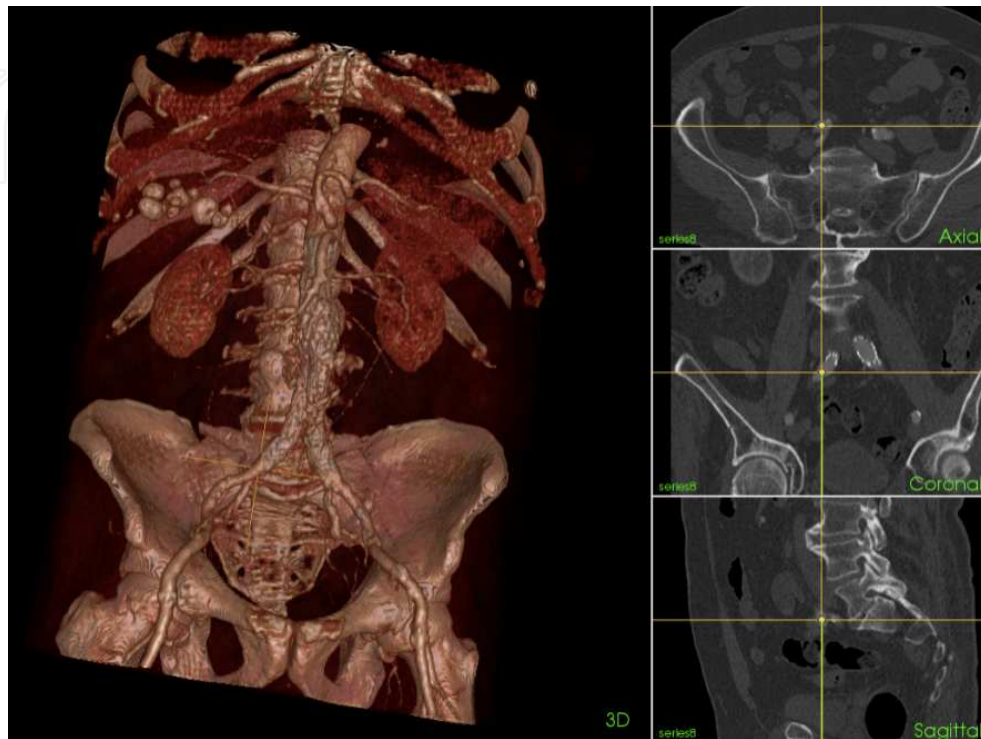


Figure 1. Visualization of vascular anatomy for an AAA patient. Left showing volume rendering and right showing orthogonal 2D slices

3.2. Position tracking systems

Mechanical systems for navigation, like the stereotactic frame, are feasible when fixed anatomical references like the skull is available. Optical position tracking systems and frameless stereotactic surgery has since taken over as preferred tracking technology. These systems supports sensors that can be integrated with most surgical equipment and provide position data with sub-millimeter precision. For endovascular applications the problem has been the line-of-sight limitation of optical systems, making tracking of flexible instruments inside the body difficult. The introduction of electromagnetic tracking systems have made navigation systems an option also for endovascular applications and other clinical areas where position tracking of needles, endoscopes, catheters or other flexible instruments inside the body is required. Aurora (Northern Digital Inc, Waterloo, ON, Canada), shown in figure 2, and 3D Guidance medSAFE (Ascension Technology Corp., Burlington, Vermont, USA) are commercial products that can be integrated into navigation systems.



Figure 2. A) Electromagnetic tracking system - NDI Aurora. (B) Tracking sensor – 0.5 mm diameter

However, electromagnetic tracking systems are sensitive to disturbances created by metallic objects and electromagnetic noise. For Endovascular applications this is specially challenging since the X-ray/fluoroscopy imaging equipment represents a substantial dynamic disturbance (Bø et al., 2012). To make navigation feasible in these cases either the disturbing equipment (i.e. X-ray equipment) must be moved to a safe distance during navigation or a correction scheme must be applied. Several methods for compensating the disturbances have been reported in literature. The most common approach is to sample reference points throughout the tracking volume. The same points are sampled with and without disturbances present and this is used to map the deformation field caused by the disturbance (Kindratenko, 2000).

3.3. Registration

In order to use 3D images for accurate navigation inside a patient the position coordinates output from the tracking system must be matched to the exact same location in the medical images. That is, the 3D coordinate system of the tracking system needs to be transformed to the coordinate system of the 3D medical image dataset. This has traditionally been done by performing a rigid registration, meaning that the two coordinate systems are matched by translation and rotation of one of them, no deformation is involved. This can be implemented as a point-pair registration using fiducial markers or using visible anatomical landmarks etc. Figure 3 shows an example from our research (Manstad-Hulaas et al, 2010 & 2012) where a tracked reference plate containing radio opaque fiducial markers is attached to the patient. The tracked fiducial marker coordinates are visualized as green spheres and the same markers show up as intensity spots in the CT image. By matching these two pointsets to each other, by the use of the navigation system, we perform a registration between the tracking system and the CT images.

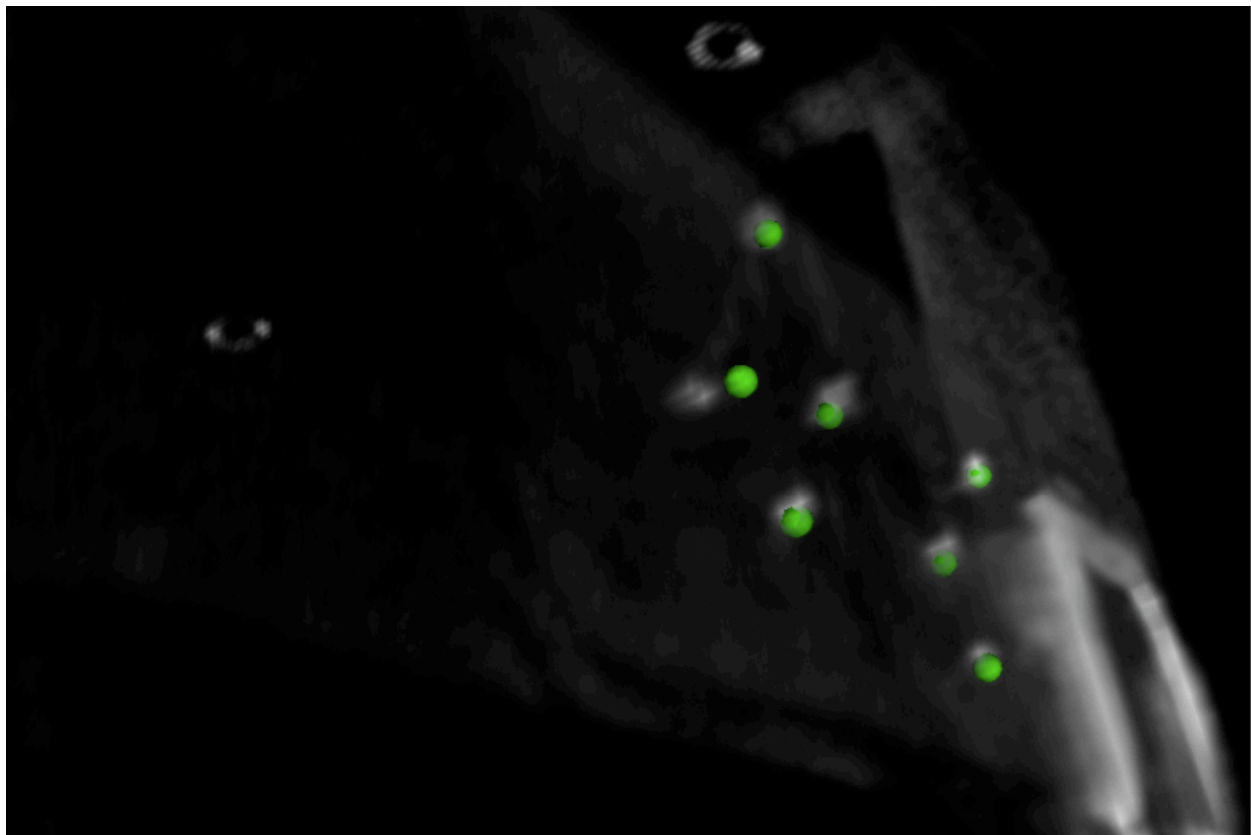


Figure 3. Registration by the use of fiducial markers. Green indicators show the positions in the position tracking systems coordinate system. Intensity spots show the corresponding marker positions in the images.

Registration can also involve matching images from different modalities to each other or matching images from the same modality acquired at different points in time. For endovascular applications augmenting the small intraoperative Cone Beam CT volume with information from a larger high-quality preoperative CT volume can give us a better navigation map for the guiding procedures. In our research we have compared two algorithms for image registration of Cone Beam CT to CT, and achieved a registration match of 5.05 ± 4.74 mm and 4.02 ± 1.52 mm. This can be sufficient for navigation if we use the intraoperative Cone Beam CT volume as the basis for high accuracy navigation and the preoperative CT information to provide overview etc. (Manstad-Hulaas et al, 2010).

3.4. Navigation systems

Visualization, position tracking, registration and control software are essential parts of a navigation system. In a wide range of medical specialties the use of navigation systems based on 3D images and tracked instruments and tools have been tested and to some degree taken into clinical practice. Examples include transbronchial biopsies, laparoscopic ultrasound and radiofrequency ablation, neuronavigation, orthopedic surgery and cardiac ablation (Eberhardt et al., 2010; Harms et al., 2001; Hayhurst et al., 2009; Hildebrand et al., 2008; Hernes et al., 2006; Knecht et al., 2008; Tigani et al., 2009; von Jako et al., 2009; Wood et al., 2007). Abi-Jaoudeh et

al. (2010) showed in an animal trial the feasibility of inserting a thoracic stent graft using a navigation system based on 3D images and electromagnetic tracking, but in general the use of navigation systems during endovascular procedures have been sparse.

4. Future possibilities and challenges

4.1. Research within navigation in AAA

In our research we have used a prototype navigation system for 3D navigation, CustusX (SINTEF, Dept Medical Technology, Trondheim, Norway), which has been developed for minimally invasive procedures. CustusX evolved through the cooperating partners SINTEF, St Olav's Hospital and Norwegian University of Science and Technology (NTNU). The activity in usage of navigation for guidance of surgical procedures, started in 1995 to support research studies in the operating room, mainly within neurosurgery, vascular surgery and laparoscopic surgery. It has since then evolved into new clinical areas such as spine surgery and lung biopsy applications.

The research within usage of navigation for guidance of endovascular treatment of AAA was in our research group, based on pre-operative CT-images in combination with an electromagnetic tracking system. The feasibility and accuracy of the navigation system was studied in a series of paper (Manstad-Hulaas et al. 2007, 2010 & 2011). The authors concluded that the navigation system had sufficient accuracy and was easy to use. Manstad-Hulaas et al. (2012) reported use of the navigation system in a study comprising patients scheduled for EVAR. Successfully catheterizations of the contralateral cuff with an electromagnetically tracked catheter were achieved in 6 of 7 patients (86%). In the control group, successful placement of a catheter within the main stent graft was achieved in 8 of 10 patients (80%). Maximum 8 attempts were needed to insert the guide wire correctly in the intervention group vs. 33 in the control group. A navigation system visualizing instruments in a 3D image of the vascular system was shown to be a reliable and useful tool during minimally invasive treatment of the aorta. Other examples on groups doing research using navigation in endovascular applications are as mentioned in previous chapter, Abi-Jaoudeh et al. A very interesting work is done by (Sidhu et al, 2012) reporting a new method for arterial cannulation using a tracked guidewire and the StealthStation navigation system (Medtronic Inc., USA).

4.2. Integration with medical imaging equipment

Solutions that integrate imaging and navigation have recently become commercially available. Some manufacturers have integrated 3D visualization into the angiography equipment, such as the syngo iPilot from Siemens. This might be a technique to enhance spatial information and reduce the use of contrast medium.

St. Jude Medical is performing clinical testing of a system called MediGuide (Gaspar et al, 2012) that supports electromagnetic tracking of catheter position, integrating this with existing angiography equipment. This enables the position of the catheter/instrument to be superim-

posed as a marker on the live fluoroscopy images. 3D models of arteries etc. can also be augmented on the live images, simplifying the navigation in complex vascular structures. Other research groups are also working on how to integrate electromagnetic tracking with catheter position extracted from fluoroscopy images for accurate navigation (Azizian M. et al, 2011).

3D ultrasound scanners with integrated electromagnetic tracking systems exist today. Examples are PercuNav (Phillips, Eindhoven, Netherlands) and SonixGPS (Ultrasonix, Toronto, ON, Canada), enabling fusion of pre-operative images with tracking and real-time 3D ultrasound for image guidance of needle tracking procedures (nerve blocks, biopsies, vascular access etc.).

4.3. Steerable tools and robot-assisted procedures

There have been increasing activity during the last years towards steerable tools and robot-assisted procedures, especially within the cardiac field to treat arrhythmias and atrial fibrillation. The motivation for this is to improve catheter stability and control and to achieve correct placement of the catheters during complex cardiac arrhythmia procedures. Normally the operators have had to use several catheters with different properties (preshaped tip and stiffness etc.). Multiple sequences with “catheter-over-wire” technique are performed to switch between the different guidewires and catheters. This increases the danger of trauma to the vessel wall, with risk of embolization etc. that can lead to stroke when working in the aortic arch or the coronary arteries (Nordon et al, 2010). The friction caused by the instrument resting against the vessel wall can also make it impossible to maneuver by twisting and pushing the guidewire/catheter. Also, the anatomy can be challenging when the operator must maneuver through tortuous iliac arteries etc. This can result in prolonged procedure time, extended use of radiation and require highly skilled and experienced operators.

Hansen Medical (Mountain View, CA, USA) has commercialized a robotic system for electrophysiology called Sensei. (Riga et al., 2010). The operator can control a steerable catheter consisting of an inner guide (11F outer diameter, 8.5F inner diameter) within an outer guide sheath (14F outer diameter, 11F inner diameter) from a remote control station with a joystick. Ablation therapy is performed through the catheter. The catheter also has force sensors integrated and force quantification is displayed to the operator to minimize the risk of trauma to the vessel. (Riga et al, 2010) has shown the feasibility of this robotic solution for advanced EVAR with fenestrated stent graft procedure with promising results. The last year Hansen has also released a product called Magellan with smaller dimension catheter (6F – 2 mm) targeting peripheral vascular interventions.

Hansen Medical's solution is based on mechanical steering of the catheter. Another alternative is magnetic steering (Remote Magnetic Navigation). The company Stereotaxis (St. Louis, MO, USA) has developed a robotic solution named Niobe where two large magnets placed beside the patient control the movement of the tip of a catheter. The system is operated from a remote control station. Since the system directly controls the tip of the instrument they claim that the risk for complications like perforation is minimized. The technology has been licensed to Siemens and Phillips which both have integrated the navigation system in their electrophysiology product line.

5. Conclusions

Navigation provides the operators with more anatomic information and makes EVAR safer and more accurate. Steerable catheters and accurate navigation technology can speed-up operating time and increase the possibilities for use of EVAR in more complex aneurysms.

Conflict of interest

The authors have no conflict of interest regarding commercial products mentioned in this text.

Acknowledgements

This work was funded by the Ministry of Health and Social Affairs of Norway, through the National Centre for 3D Ultrasound in Surgery (St. Olavs University Hospital, the Norwegian University of Science and Technology, SINTEF Trondheim, Norway), project 196726=V50 eMIT (Enhanced minimally invasive therapy, FRIMED program),

Author details

Geir Arne Tangen^{1,2}, Frode Manstad-Hulaas^{1,3}, Reidar Brekken^{1,2} and Toril A. N. Hernes^{1,2}

1 Norwegian University of Science and Technology, Dept. Circulation and Medical Imaging, Trondheim, Norway

2 SINTEF, Dept. Medical Technology, Trondheim, Norway

3 St. Olav's University Hospital, Trondheim, Norway

References

- [1] Abi-jaoudeh, N, Glossop, N, Dake, M, Pritchard, W. F, Chiesa, A, Dreher, M. R, et al. Electromagnetic navigation for thoracic aortic stent-graft deployment: a pilot study in swine. *Journal of Vascular and Interventional Radiology*. (2010). Jun,; 21(6), 888-95.
- [2] Azizian, M, & Patel, R. Data Fusion for Catheter Tracking using Kalman Filtering: Applications in Robot-Assisted Catheter Insertion. Presented at the Medical Imaging (2011). Visualization, Image-Guided Procedures, and Modeling, SPIE.

- [3] Brewster, D. C, Cronenwett, J. L, & Hallett, J. W. Jr., Johnston KW, Krupski WC, Matsumura JS. Guidelines for the treatment of abdominal aortic aneurysms. Report of a subcommittee of the Joint Council of the American Association for Vascular Surgery and Society for Vascular Surgery. *J Vasc Surg.* (2003). May;, 37(5), 1106-17.
- [4] Bø, L. E, Leira, H. O, Tangen, G. A, Hofstad, E. F, Amundsen, T, & Langø, T. (2012). Accuracy of electromagnetic tracking with a prototype field generator in an interventional OR setting. *Medical physics*, 39(1), 399.
- [5] Clarke, R. H, & Horsley, V. On a method of investigating the deep ganglia and tracts of the central nervous system cerebellum, *Br Med J* (1906).
- [6] Coltman, J. W. Fluoroscopic image brightening by electronic means. *Radiology.* (1948). Sep;, 51(3), 359-6.
- [7] Crummy, A. B, Stieghorst, M. F, Turski, P. A, Strother, C. M, Lieberman, R. P, Sackett, J. F, et al. Digital subtraction angiography: current status and use of intra-arterial injection. *Radiology.* (1982). November 1, 1982;, 145(2), 303-7.
- [8] Eberhardt, R, Morgan, R. K, Ernst, A, Beyer, T, & Herth, F. J. Comparison of suction catheter versus forceps biopsy for sampling of solitary pulmonary nodules guided by electromagnetic navigational bronchoscopy. *Respiration.* (2010). , 79(1), 54-60.
- [9] Eide, K. R, Ødegård, A, Myhre, H. O, Hatlinghus, S, & Haraldseth, O. DynaCT in pre-treatment evaluation of aortic aneurysm before EVAR. *European journal of vascular and endovascular surgery : the official journal of the European Society for Vascular Surgery*, ((2011).
- [10] Gaspar, T, Kircher, S, Arya, A, Sommer, P, Rolf, S, Hindricks, G, & Piorkowski, C. Enhancement of intracardiac navigation by new GPS-guided location system (Medi-Guide Technologies). *Europace : European pacing, arrhythmias, and cardiac electrophysiology : journal of the working groups on cardiac pacing, arrhythmias, and cardiac cellular electrophysiology of the European Society of Cardiology*, (2012). *Suppl 2*, iii25., 24.
- [11] Geijer, H, Larzon, T, Popek, R, & Beckman, K. W. Radiation exposure in stent-grafting of abdominal aortic aneurysms. *British Journal of Radiology.* (2005). Oct;, 78(934), 906-12.
- [12] Greenberg, R. K, West, K, Pfaff, K, Foster, J, Skender, D, Haulon, S, et al. Beyond the aortic bifurcation: branched endovascular grafts for thoracoabdominal and aortoiliac aneurysms. *J Vasc Surg.* (2006). May;discussion 86-7., 43(5), 879-86.
- [13] Harms, J, Feussner, H, Baumgartner, M, Schneider, A, Donhauser, M, & Wessels, G. Three-dimensional navigated laparoscopic ultrasonography: first experiences with a new minimally invasive diagnostic device. *Surg Endosc.* (2001). Dec;, 15(12), 1459-62.
- [14] Hayhurst, C, Byrne, P, Eldridge, P. R, & Mallucci, C. L. Application of electromagnetic technology to neuronavigation: a revolution in image-guided neurosurgery. *J Neurosurg.* (2009). Dec;, 111(6), 1179-84.

- [15] Hildebrand, P, Schlichting, S, Martens, V, Besirevic, A, Kleemann, M, Roblick, U, et al. Prototype of an intraoperative navigation and documentation system for laparoscopic radiofrequency ablation: first experiences. *European Journal of Surgical Oncology*. (2008). Apr; 34(4), 418-21.
- [16] Hiratzka, L. F, Bakris, G. L, Beckman, J. A, Bersin, R. M, Carr, V. F, Casey, D. E, et al. ACCF/AHA/AATS/ACR/ASA/SCA/SCAI/SIR/STS/SVM guidelines for the diagnosis and management of patients with Thoracic Aortic Disease: a report of the American College of Cardiology Foundation/American Heart Association Task Force on Practice Guidelines, American Association for Thoracic Surgery, American College of Radiology, American Stroke Association, Society of Cardiovascular Anesthesiologists, Society for Cardiovascular Angiography and Interventions, Society of Interventional Radiology, Society of Thoracic Surgeons, and Society for Vascular Medicine. *Circulation*. (2010). Apr 6;121(13):e, 266-369.
- [17] Ho, P, Cheng, S. W, Wu, P. M, Ting, A. C, Poon, J. T, Cheng, C. K, et al. Ionizing radiation absorption of vascular surgeons during endovascular procedures. *Journal of Vascular Surgery*. (2007). Sep; 46(3), 455-9.
- [18] Von Jako, R. A, Carrino, J. A, Yonemura, K. S, Noda, G. A, Zhue, W, Blaskiewicz, D, et al. Electromagnetic navigation for percutaneous guide-wire insertion: accuracy and efficiency compared to conventional fluoroscopic guidance. *Neuroimage*. (2009). Aug;47 Suppl 2(2):T, 127-32.
- [19] Kindratenko, V. A survey of electromagnetic position tracker calibration techniques. *Virtual Reality*, ((2000).
- [20] Knecht, S, Skali, H, Neill, O, Wright, M. D, Matsuo, M, & Chaudhry, S. GM, et al. Computed tomography-fluoroscopy overlay evaluation during catheter ablation of left atrial arrhythmia. *Europace*. (2008). Aug; 10(8), 931-8.
- [21] Lederle, F. A, Wilson, S. E, Johnson, G. R, Reinke, D. B, Littooy, F. N, Acher, C. W, et al. Immediate repair compared with surveillance of small abdominal aortic aneurysms. *N Engl J Med*. (2002). May 9; 346(19), 1437-44.
- [22] Manstad-hulaas, F, Ommedal, S, Tangen, G. A, Aadahl, P, & Hernes, T. N. Side-branched AAA stent graft insertion using navigation technology- a phantom study. *Eur Surg Res*. (2007). , 39(6), 364-71.
- [23] Manstad-hulaas, F, Tangen, G. A, Dahl, T, Hernes, T. A, & Aadahl, P. Three-Dimensional Electromagnetic Navigation vs. Fluoroscopy for Endovascular Aneurysm Repair: A Prospective Feasibility Study In Patients. *J Endovasc Ther*. (2012). Feb; 19(1), 70-8.
- [24] Manstad-hulaas, F, Tangen, G. A, Demirci, S, Pfister, M, Lydersen, S, & Hernes, T. N. Endovascular Image-Guided Navigation- Validation of Two Volume-Volume Registration Algorithms. *Minim Invasive Ther Allied Technol*. (2010). Nov 24.

- [25] Manstad-hulaas, F, Tangen, G. A, Gruionu, L. G, Aadahl, P, & Hernes, T. A. Three-Dimensional Endovascular Navigation with Electromagnetic Tracking- Ex Vivo and In Vivo Accuracy. *J Endovasc Ther.* (2011). Apr;; 18(2), 230-40.
- [26] Moll, F. L, Powell, J. T, Fraedrich, G, Verzini, F, Haulon, S, Waltham, M, et al. Management of abdominal aortic aneurysms clinical practice guidelines of the European society for vascular surgery. *European Journal of Vascular and Endovascular Surgery.* (2011). Jan;41 Suppl 1(1):SS58., 1.
- [27] Morcos, S. K. Prevention of contrast media-induced nephrotoxicity after angiographic procedures. *Journal of Vascular and Interventional Radiology.* (2005). Jan;; 16(1), 13-23.
- [28] Nagelhus Hernes TALindseth F, Selbekk T, Wolff A, Solberg OV, Harg E, et al. Computer-assisted 3D ultrasound-guided neurosurgery: technological contributions, including multimodal registration and advanced display, demonstrating future perspectives. *Int J Med Robot.* (2006). Mar;; 2(1), 45-59.
- [29] Nordon, I. M, Hinchliffe, R. J, Holt, P. J, Loftus, I. M, & Thompson, M. M. The requirement for smart catheters for advanced endovascular applications. *Proceedings of the Institution of Mechanical Engineers Part H, Journal of engineering in medicine,* ((2010).
- [30] Riga, C. V, Cheshire, N. J. W, Hamady, M. S, & Bicknell, C. D. The role of robotic endovascular catheters in fenestrated stent grafting. *Journal of vascular surgery : official publication, the Society for Vascular Surgery [and] International Society for Cardiovascular Surgery, North American Chapter,* ((2010).
- [31] Sidhu, R. Weir-McCall, J., Cochenec, F., Riga, C., DiMarco, A., & Bicknell, C. D. Evaluation of an electromagnetic 3D navigation system to facilitate endovascular tasks: a feasibility study. *European journal of vascular and endovascular surgery : the official journal of the European Society for Vascular Surgery,* ((2012).
- [32] Tigani, D, Busacca, M, Moio, A, & Rimondi, E. Del Piccolo N, Sabbioni G. Preliminary experience with electromagnetic navigation system in TKA. *Knee.* (2009). Jan;; 16(1), 33-8.
- [33] Wood, B. J, Locklin, J. K, Viswanathan, A, Kruecker, J, Haemmerich, D, Cebral, J, et al. Technologies for guidance of radiofrequency ablation in the multimodality interventional suite of the future. *Journal of Vascular and Interventional Radiology.* (2007). Jan;18(1 Pt 1):9-24.