

# We are IntechOpen, the world's leading publisher of Open Access books Built by scientists, for scientists

**4,800**

Open access books available

**122,000**

International authors and editors

**135M**

Downloads

Our authors are among the

**154**

Countries delivered to

**TOP 1%**

most cited scientists

**12.2%**

Contributors from top 500 universities



**WEB OF SCIENCE™**

Selection of our books indexed in the Book Citation Index  
in Web of Science™ Core Collection (BKCI)

Interested in publishing with us?  
Contact [book.department@intechopen.com](mailto:book.department@intechopen.com)

Numbers displayed above are based on latest data collected.

For more information visit [www.intechopen.com](http://www.intechopen.com)



---

# **Abdominoperineal Resection: Consideration and Limitations of Prostate Cancer Screening and Prostate Biopsy**

---

Zachary Klaassen, Ray S. King, Kelvin A. Moses,  
Rabii Madi and Martha K. Terris

Additional information is available at the end of the chapter

<http://dx.doi.org/10.5772/52291>

---

## **1. Introduction**

Prostate cancer and colorectal malignancies are the most common cancers in men, contributing to 15% and 9% of new cancer cases, respectively [1]. Furthermore, it is not uncommon to encounter patients with synchronous or metachronous colorectal and prostate cancers [2-3]. Abdominoperineal resection (APR) is often performed for surgical treatment of rectal cancer in addition to treatment of ulcerative colitis and familial polyposis coli. The technical aspects of an APR include a combined perineal and abdominal approach to resecting the rectum and mesorectum, in addition to the anus, perineal soft tissue and pelvic floor musculature [4].

The screening and treatment of patients with prostate cancer after an APR is challenging and unique. Enblad et al. [5] found a relative risk of 2.2 for the diagnosis of a second primary neoplasm in the prostate within 1 year after the diagnosis of rectal malignancy. After APR for colorectal pathologic features, however, there is no rectum for access to the prostate. This precludes the use of digital rectal examination (DRE) or transrectal ultrasound (TRUS)-guided prostate biopsies to diagnose primary tumors of the prostate [6-10].

Several methods have been described to evaluate the prostate in the patient with elevated prostate-specific antigen (PSA) levels who have undergone APR, including transperineal ultrasound (TPUS)-guided biopsy, transurethral ultrasounded guided perineal biopsy and computed tomography (CT)/magnetic resonance imaging (MRI) guided techniques. The aim of this chapter is to review the screening for prostate cancer in patients preparing for an APR and discuss post-APR screening and prostate biopsy techniques, limitations and practical considerations.

## 2. Abdominoperineal resection

Abdominoperineal resection is a surgery for carcinoma of the rectum and/or anus, performed through incisions in the abdomen and perineum. APR involves the removal of the anus, rectum, and the distal portion of the sigmoid colon along with regional lymph nodes. Without an anal opening, the patient has a permanent end-colostomy from the proximal sigmoid colon created through the anterior abdominal wall, typically placed in the left lower quadrant [11-12].

### 2.1. Diagnosis of rectal carcinoma

In patients with rectal cancer, the most common initial presenting symptom or complaint is bleeding, followed by changes in bowel habits, diarrhea, and lower abdominal pain. A DRE may detect rectal masses located within the distal 1/3 of the rectum. A potential source of confusion from a standard DRE may arise from carcinoma of the prostate encroaching on the nearby rectum, causing similar obstructive symptoms [11]. Flexible sigmoidoscopy or colonoscopy allow for a more thorough visual characterization, location, and size of the mass, and provides an opportunity for biopsy and histological examination. Endoluminal ultrasonography has recently been shown to be a diagnostic tool for characterizing the depth of invasion of the rectal mass. Pre-operative evaluation using colonoscopy and CT and/or MRI is indicated to rule-out synchronous lesions and/or metastatic disease [13].

### 2.2. Indications for treatment

Classic surgical dogma throughout the 20th century states that the standard treatment for rectal tumors located less than 8cm from the anal verge is to perform an APR. Careful surgical technique must be utilized to avoid complications such as recurrence of disease due to inadequate surgical margins, anastomotic breakdown, obstruction, and re-operation. Tumors located more proximally are generally treated successfully using the standard low anterior resection with restoration of bowel continuity. Absolute contraindications for anastomosis following resection of rectal cancer are invasion of the sphincter mechanism or the anal canal. The decision to preserve the anal sphincter can be affected by several factors including: level of the tumor, depth of invasion, extent of circumferential involvement, tumor fixation, local and metastatic invasion, age, and the ability to manage a colostomy. However, advances in instrumentation and techniques often allow for some tumors in the distal rectum to be resected and anastomosis performed [13-14].

### 2.3. Technique

APR can be performed by a single surgeon or with a two-surgeon (abdominal and perineal) team approach. Once the patient is prepped and draped, the anus is closed using a purse-string suture. A site for the colostomy should be selected prior to incision. The surgeon may consider preoperative ureteral stent placement to aid in identification of the ureters and to facilitate repair in case of inadvertent injury. A midline infra-umbilical incision is made, and the abdomen is explored for evidence of metastatic and/or synchronous disease. Once the tumor

is deemed resectable, the surgeon on the perineal side can begin dissection simultaneously. In the abdominal compartment, the sigmoid colon and rectum is mobilized by incision of the left lateral mesentery, paying careful attention to avoid the left ureter as it courses over the bifurcation of the iliac vessels. Identification and control of the inferior mesenteric artery is followed by its ligation distal to the first branch to maintain adequate blood supply to the colon segment used for the stoma. The rectum is then bluntly dissected posterior along the presacral space and mobilized to the tip of the coccyx. Anteriorly, the rectum is retracted away from the bladder and Denonvillier's fascia is incised to free the rectum away from the prostate to its posterior margin. The lateral ligaments that contain the middle rectal arteries are controlled and ligated. At this point the proximal sigmoid colon is divided using a stapling device and brought through the anterior abdominal wall. The colostomy is then matured.

On the perineal side, an elliptical incision is made around the anus. Dissection is then made through the sphincters and the ischiorectal fossa is entered. The presacral space is entered from below and the rectum is mobilized circumferentially. Careful dissection is performed to avoid perforation of the rectum and compromise the containment of the malignancy. The perineal dissection is completed by dividing the levator muscle on each side. The distal sigmoid and rectum can be delivered through the perineal opening. The perineal wound is closed primarily, with a closed drain left in place. The peritoneum is repaired above and the floor of the pelvis is closed [12, 14-16].

### **3. Concomitant prostate cancer screening in the patient preparing for an APR**

Patients scheduled to undergo APR represent a patient population in which prostate cancer screening may be indicated. Most cases of rectal cancer are diagnosed after 50 years of age [17], and are in the same age category of men at risk for prostate cancer diagnosis. However, the stage of rectal cancer should be taken into consideration when considering screening the same individual for prostate cancer: Stage T1 and T2 rectal tumors treated with APR have a ~90% 5-year survival, while stage T3 and T4 tumors are generally treated with neoadjuvant chemotherapy and/or radiation and generally have a 5-year survival of 50% and 25%, respectively [17]. Thus, prostate cancer screening in patients with advanced disease should be avoided.

Terris and Wren previously described a prostate cancer-screening program for 19 consecutive men scheduled for APR for colorectal carcinoma with no history of prostate cancer [18]. Screening included serum PSA and DRE and those with suspicious findings underwent TRUS-guided sextant biopsy. Six patients (31%) had a PSA >4.0 ng/mL (range 4.4 to 32.4 ng/mL, mean 9.3 ng/mL) of which two patients also had an abnormal DRE. TRUS-guided biopsy revealed prostate cancer in three individuals (50%). These patients included an individual with clinical stage T1c, Gleason 3+3=6 adenocarcinoma of the prostate treated with radiation, a second patient with clinical stage T2a, Gleason 3+4=7 adenocarcinoma of the prostate treated with radiation, and a third individual with a PSA of 32.4 ng/mL and DRE

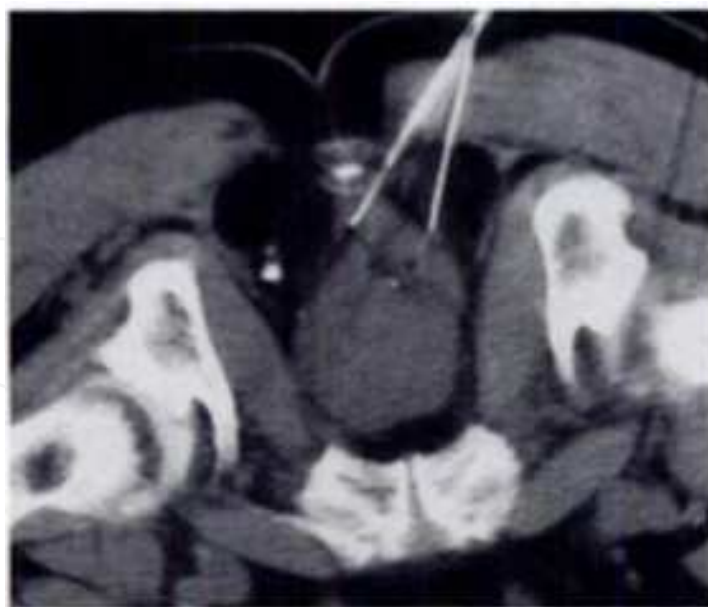
consistent with extracapsular extension of prostate cancer (clinical stage T3, Gleason 4+4=8 adenocarcinoma of the prostate) managed with androgen deprivation therapy. Concomitant prostate cancer screening for patients planning an APR should be a multi-disciplinary decision between the General Surgeons and Urologist in the male patient older than 50 years of age with clinical stage T1 or T2 rectal cancer and a life expectancy of more than 10 years.

#### 4. Post-APR prostate cancer screening and modalities for prostate biopsy

The clinical scenario of a patient with an elevated PSA and no access to the rectum precludes the urologist from performing a DRE or a TRUS biopsy of the prostate. Other approaches to the prostate to allow a biopsy include CT and MRI guided techniques, transurethral ultrasound guided perineal biopsy and TPUS-guided biopsy.

##### 4.1. CT and MRI-guided prostate biopsy

Transgluteal CT-guided prostate biopsy involves imaging the lower pelvis at 10-mm intervals and with a 10-mm slice thickness. The transgluteal approach allows sampling of both sides of the midline at the base, midgland and apical levels. When one entry site is used, the angle of the needle is projected to the contralateral side of the prostate; entry sites are chosen 3-4cm off the midline to avoid paraspinous ligaments and potential post-APR fibrosis around the tip of the coccyx (Figure 1) [19].



**Figure 1.** CT-guided percutaneous transgluteal biopsy of the prostate. Two needles are inserted at different angles to ensure adequate sampling of both sides of the prostate (Reprinted from American Journal of Roentgenology, Volume 166/Issue 6, Papanicolaou N, Eisenberg PJ, Silverman SG, McNicholas MM, Althausen AF. 1996, 1332-1334, with permission from The American Roentgen Ray Society).

Papanicolaou et al. [19] described this technique in 10 patients with a mean age of 67 years and mean PSA of 33.9 diagnosing prostate cancer in 6 patients (60%). While CT scan offers limited anatomical detail of the prostate, it does allow visualization of the peripheral zones to facilitate biopsy in patients without rectal access.

Limited experience with MRI-guided transperineal biopsy [20] and CT-MRI fusion to guide radiotherapy [21] has been described but is not widely available.

#### **4.2. Transurethral ultrasound guided perineal prostate biopsy**

The patient undergoing a transperineal biopsy guided by transurethral ultrasound is placed in the lithotomy position and a 26F resectoscope sheath is passed into the urethra. Subsequently, a 5.5 MHz transurethral ultrasound probe is passed through the sheath for visualization of the prostate. The width and height of the prostate are measured on the sagittal image and withdrawing the probe from the base to the apex of the prostate assesses length [22]. The advantage of this modality is that direct prostate imaging allows for precise guidance of transperineally placed biopsy needles. However, the major limitation is that one is only able to view the prostate in the sagittal plane. Seaman et al. [22] utilized this technique to perform 7 biopsies in 5 patients with a history of APR and elevated PSA (two patients had repeat biopsy secondary to increasing PSA), diagnosing prostate cancer in three patients (60%).

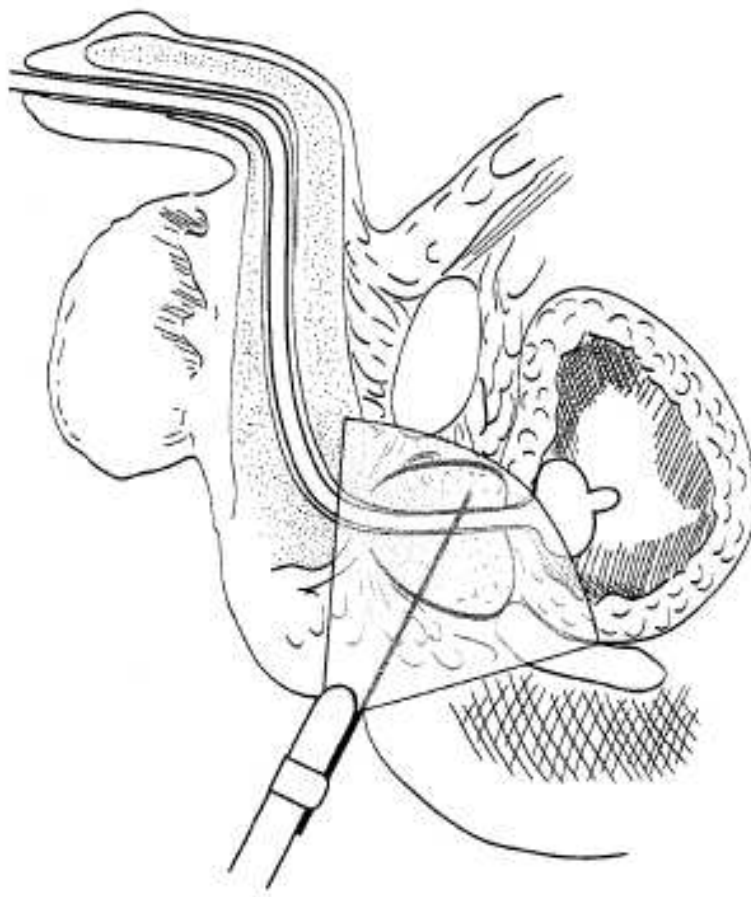
#### **4.3. Transperineal Ultrasound (TPUS) guided prostate biopsy**

The TPUS guided prostate biopsy is performed in the lithotomy position. A Foley catheter may be inserted to delineate the prostate anatomy and avoid the urethra with the biopsy needle [23]. The scrotum is then retracted anteriorly and the perineum is prepared in a sterile fashion. Then 1% Lidocaine is applied to the perineum for anesthesia. The transrectal ultrasound probe is adjusted to a frequency of 5-6 MHz and the prostate is visualized after traversing the course of the urethral catheter. The 18-gauge biopsy needle is then directed at a 45-degree angle and biopsy specimens are obtained through the posterior aspect of the prostate. The needle forms an acute angle with the long axis of the prostate apex is nearly parallel with the long axis of the prostate base and mid-gland (Figure 2). Biopsy specimens are then obtained from the medial and lateral aspect of the prostate apex, mid-gland and base as is performed for TRUS biopsy. A "fan technique" for obtaining a six-core TPUS guided biopsy has also been described (Figure 3) [24].

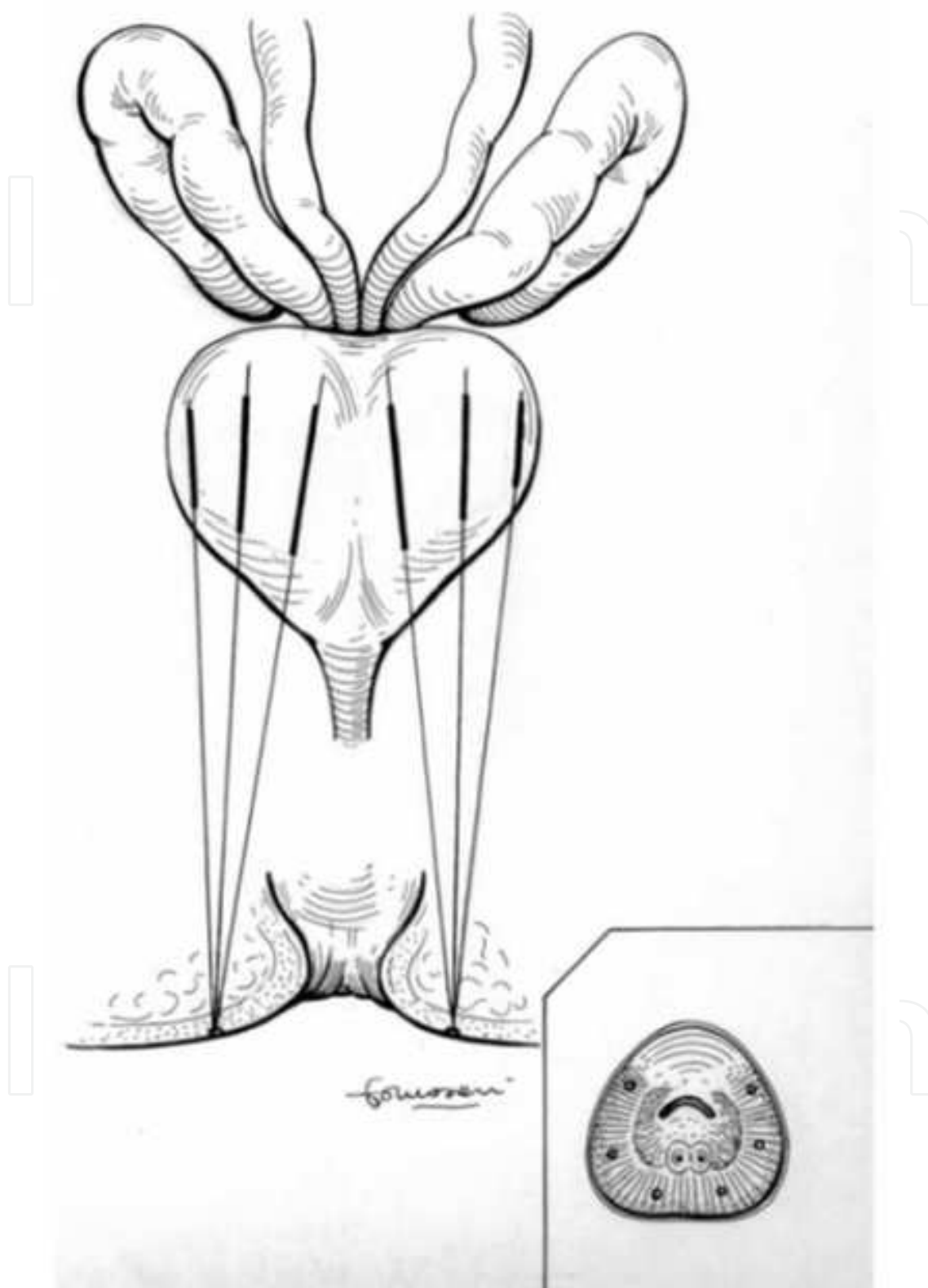
A number of studies have compared the efficacy of TPUS-guided biopsies compared to TRUS-guided biopsies in patients with a rectum [8, 24]. Shinghal and Terris [8] prospectively identified 20 patients with prostate cancer diagnosed by TRUS-guided biopsies to evaluate the accuracy of TPUS prostate biopsies. Six TPUS-guided biopsies were obtained, followed by sextant TRUS-guided biopsies prior to radical prostatectomy. Final pathology demonstrated that all 20 patients had adenocarcinoma of the prostate. TPUS-guided biopsies identified cancer in only 2 of 20 patients (10%) compared to 13 of 20 patients (65%) for TRUS-guided biopsies. The positive TPUS-guided biopsy specimens were higher Gleason

grade, and were found in patients with larger volume prostates and higher PSA. Emiliozzi et al. [24] performed a prospective study comparing TPUS versus TRUS-guided prostate biopsy in 107 patients with PSA > 4.0 ng/mL. The patients underwent TPUS-guided six core biopsy, followed by TRUS-guided six core biopsy. Prostate cancer was found in 43 of 107 patients (40%): 41 (95%) were found via the TPUS approach compared to 34 (79%) via the TRUS approach ( $p = 0.012$ ).

IntechOpen



**Figure 2.** Transperineal prostate biopsy. There is a relatively acute angle of the needle in regard to the long axis of the prostate. The needle becomes almost parallel with the long axis of the prostate middle and base (Reprinted from *The Journal of Urology*, Volume 169/Issue 1, Shinohara K, Gulati M, Koppie TM, Terris MK. 2003, 141-144, with permission from American Urological Association).



**Figure 3.** Scheme of the transperineal six-core fan biopsy. Cores are also taken from the far lateral aspect of the prostate (Reprinted from *Urology*, Volume 61/Issue 5, Emiliozzi P, Corsetti A, Tassi B, Federico G, Martini M, Pansadoro V. 2003, 961-966, with permission from Elsevier).



A number of studies have reported TPUS-guided biopsy in patients after APR [6, 9, 23] (Table). Shinohara et al. [23] reported the largest experience analyzing 28 patients with a history of APR who were referred for biopsy with a mean PSA of 22 ng/mL (median 9.5, range 4.1 to 237). The mean time from APR to referral was 14 years (range 1 to 33 years) and five patients had previously undergone radiation therapy as part of the treatment for colorectal cancer. Of the 28 patients, 23 were diagnosed with prostate cancer (82.1%), with a mean Gleason score of 6.6 (range 3 to 9). Twenty-two of the 23 patients (95.7%) elected for treatment, including prostatectomy (n=8), androgen deprivation therapy (n=7), external radiation therapy (n=6) and high dose radiation therapy (n=1).

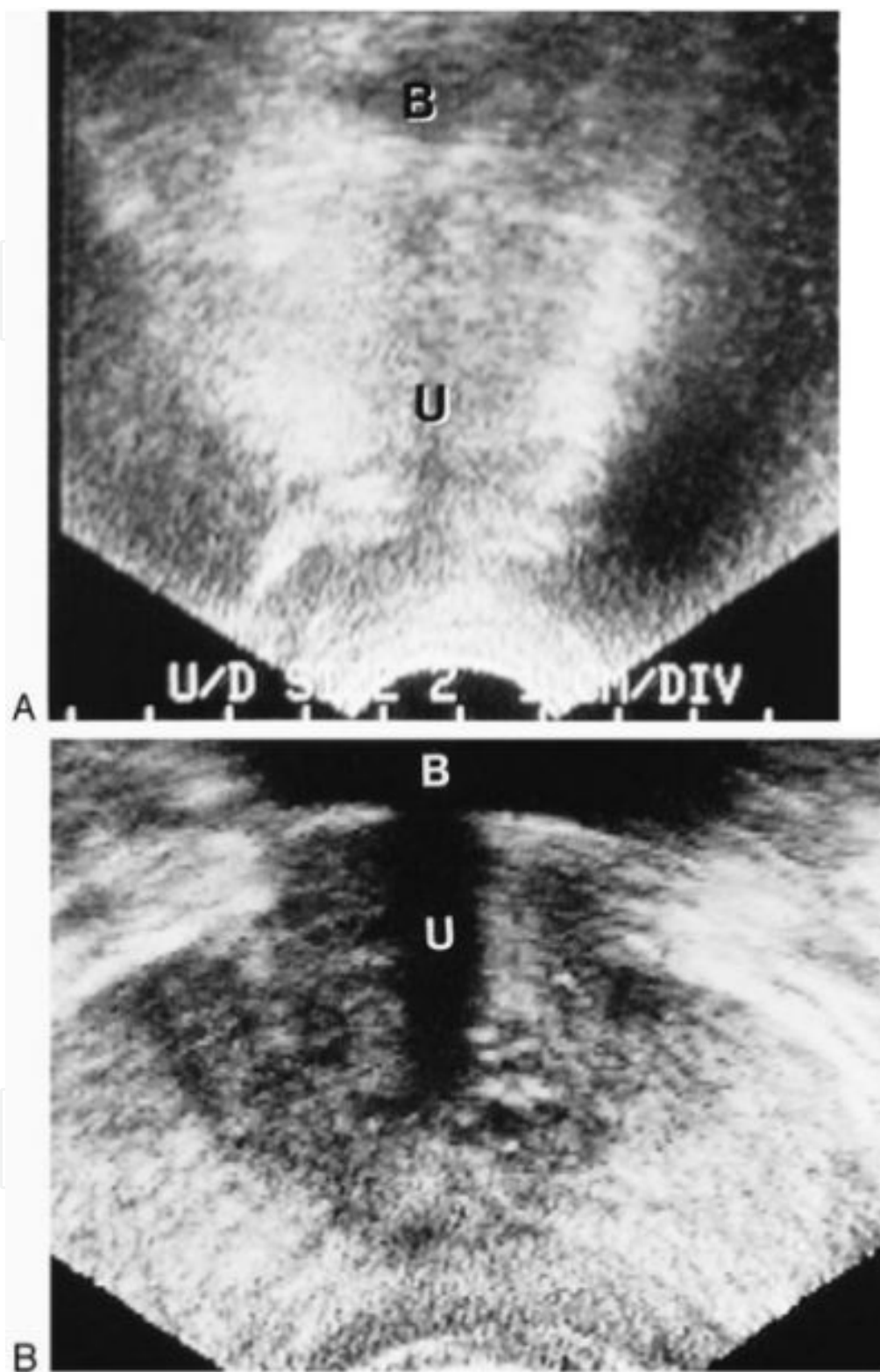
Study	Patients (N)	Median Age (Yrs)	Mean PSA (ng/mL)	Median PSA (ng/mL)	Mean Interval From APR to Biopsy (Yrs)	Biopsy Proven Prostate Cancer, N= (%)
Shinohara et al. [23]	28	65	22	9.5	14	23 (82%)
Twidwell et al. [6]	10	67	NR	NR	12	2 (20%)
Filderman et al. [99]	5	62	16.5	NR	NR	2 (40%)

**Table 1.** A comparison of studies analyzing transperineal ultrasound-guided prostate biopsy results in patients after abdominoperineal resection. (NR - not reported)

#### 4.4. Practical considerations for TPUS-guided prostate biopsy

##### 4.4.1. Image quality

The image quality of TPUS of the prostate compared to TRUS has been previously described by Terris et al. [7]. In a prospective study of 50 patients who had not undergone APR, TPUS was performed with a 4-MHz abdominal probe at a frequency of 5 - 7 MHz and TRUS at 7 MHz (Figure 4). TPUS allowed good visualization of the prostate in 48 (96%) patients in the coronal plane and in 45 (90%) patients in the sagittal plane. Prostate volume, as calculated by the prolate spheroid method, correlated well with TRUS calculations ( $r = 0.876$ ). Prostatic calcifications were seen in 12 patients (24%), identified by both TRUS and TPUS, however 29 patients (58%) with hypoechoic lesions identified by TRUS were not visualized by TPUS. Furthermore, six patients (12%) with cystic lesions visualized by TRUS were seen in half of the patients by TPUS (3/6). Image quality of TPUS is inadequate for staging purposes secondary to poor transverse and longitudinal visualization of the prostatic capsule. While the imaging quality of TPUS may be inferior to TRUS, it likely represents the most reliable modality in patients without access to the rectum and has been proposed as a diagnostic modality in patients at high risk for prostate cancer with previous negative TRUS-guided biopsies [25].



**Figure 4.** A) Transperineal image showing vague outline of the prostate in the coronal plane. (B) Transverse image of the prostate in the transverse plane. B = bladder; U = urethra (Reprinted from *Urology*, Volume 52/Issue 6, Terris MK, Hammerer PG, Nickas ME. 1998, 1070-1072, with permission from Elsevier).

#### 4.4.2. Improved sampling of the far lateral peripheral zone

When performing TPUS-guided biopsy, the needle forms an acute angle with the long axis of the prostate apex before becoming nearly parallel with the long axis of the prostate base and mid-gland. Geometrically, this allows sampling of more peripheral zone tissue, notably the far lateral peripheral zone [23, 25]. Eskew et al. [26] performed sextant biopsies in addition to cores taken from the far lateral and mid regions of the prostate in 119 patients, diagnosing prostate cancer in 48 patients (40.3%). Among these 48 patients, 17 (35%) had carcinoma only in the far lateral and mid regions of the prostate.

## 5. Conclusions

Evaluation of the prostate in men with an elevated PSA who have undergone APR is challenging due to inability to perform DRE and TRUS-guided prostate biopsy. TPUS-guided prostate biopsy is the most cost effective and feasible modality for diagnosing prostate cancer in these patients. However, given that men aged 50-75 are at increased risk for both prostate cancer and colorectal cancer, preoperative prostate cancer screening in men who are planning APR allows for proper assessment of the prostate before access to the rectum is compromised, provides a baseline PSA to compare with further testing after the APR, and may detect synchronous malignancies. A multidisciplinary approach is ideal when considering prostate cancer screening in men 50 years of age or older with reasonable life expectancy who are planning APR.

## Author details

Zachary Klaassen<sup>1</sup>, Ray S. King<sup>2</sup>, Kelvin A. Moses<sup>1</sup>, Rabii Madi<sup>1</sup> and Martha K. Terris<sup>1\*</sup>

<sup>1</sup> Department of Surgery, Section of Urology, Georgia Health Sciences University, Augusta, Georgia

<sup>2</sup> Department of Surgery, Georgia Health Sciences University, Augusta, Georgia

## References

- [1] Siegel R, Naishadham D, Jemal A. Cancer Statistics, 2012. *CA – A Cancer Journal for Clinicians* 2012;62(1) 10-29.
- [2] Lee T, Barringer M, Myers RT, Sterchi JM. Multiple primary carcinomas of the colon and associated extracolonic primary malignant tumors. *Annals of Surgery* 1982;195(4) 501-507.

- [3] Weir JA. Colorectal cancer: metachronous and other associated neoplasm. *Diseases of the Colon and Rectum* 1975;18(1) 4-5.
- [4] Park J, Guillem JG. Chapter 47 – Rectal Cancer. In: Cameron JL, Cameron AM (eds). *Current Surgical Therapy*, 10th ed. Philadelphia, PA: Elsevier Health Sciences; 2011.
- [5] Enblad P, Adami H, Glimmerlius B, Krusemo U, Pahlman L. The risk of subsequent primary malignant diseases after cancers of the colon and rectum. *Cancer* 1990;65(9) 2091-2100.
- [6] Twidwell JJ, Matthews RD, Huisam TK, Sands JP. Ultrasound evaluation of the prostate after abdominoperineal resection. *The Journal of Urology* 1993;150(3) 902-904.
- [7] Terris MK, Hammerer PG, Nickas ME. Comparison of ultrasound imaging in patients undergoing transperineal and transrectal prostate ultrasound. *Urology* 1998;52(6) 1070-1072.
- [8] Shinghal R, Terris MK. Limitations of transperineal ultrasound-guided prostate biopsies. *Urology* 1999;54(4) 706-708.
- [9] Filderman PS, Jacobs SC. Prostatic ultrasound in the patient without a rectum. *Urology* 1994;43(5) 722-724.
- [10] Koppie TM, Presti JC, Shinohara K, Terris MK, Carroll PR. Transperineal biopsy after abdominoperineal resection: A two center experience. *J Urol* 2000;163(1) 260.
- [11] Corman ML. *Colon and Rectal Surgery*, 5th Ed. Philadelphia: Lippincott Williams & Wilkins; 2005.
- [12] Perry WB, Connaughton JC. Abdominoperineal resection: how is it done and what are the results? *Clinics in Colon and Rectal Surgery* 2007;20(3) 213-220.
- [13] Murrell ZA, Dixon MR, Vargas H, Arneel TD, Kumar R, Stamos MJ. Contemporary indications for and early outcomes of abdominoperineal resection. *American Surgeon* 2005;71(10) 837-840.
- [14] Reshef A, Lavery I, Kiran R. Factors associated with oncologic outcomes after abdominoperineal resection compared with restorative resection for low rectal cancer: patient and tumor related or technical factors only? *Diseases of the Colon and Rectum* 2012;55(1) 51-58.
- [15] Simorov A, Reynoso J, Dolghi O, Thompson J, Oleynikov D. Comparison of perioperative outcomes in patients undergoing laparoscopic versus open abdominoperineal resection. *The American Journal of Surgery* 2011;202(6) 666-672.
- [16] Marr R, Birbeck K, Garvican J, Macklin CP, Tiffin NJ, Parsons WJ, Dixon MF, Mapstone NP, Sebag-Montefiore D, Scott N, Johnston D, Sagar P, Finan P, Quirke P. The modern abdominoperineal excision: the next challenge after total mesorectal excision. *Annals of Surgery* 2005;242(1) 74-82.
- [17] Surveillance, Epidemiology, and End Results (SEER) Program ([www.seer.cancer.gov](http://www.seer.cancer.gov)). Research Data (1973-2009), National Cancer Institute, DCCPS, Surveillance

Research Program, Surveillance Systems Branch, released April 2012, based on the November 2011 submission.

- [18] Terris MK, Wren SM. Results of a Screening Program for Prostate Cancer in Patients Scheduled for Abdominoperineal Resection for Colorectal Pathologic Findings. *Urology* 2001;57(5) 943-945.
- [19] Papanicolaou N, Eisenberg PJ, Silverman SG, McNicholas MM, Althausen AF. Prostatic biopsy after proctocolectomy: a transgluteal, CT-guided approach. *AJR American Journal of Roentgenology* 1996;166(6) 1332-1334.
- [20] D'Amico AV, Tempany CM, Cormack R, Hata N, Jinzaki M, Tuncali K, Weinstein M, Richie JP. Transperineal magnetic resonance image guided prostate biopsy. *The Journal of Urology* 2000;164(2) 385-387.
- [21] Lau HY, Kagawa K, Lee WR, Hunt MA, Shaer AH, Hanks GE. Short communication: CT-MRI image fusion for 3D conformal prostate radiotherapy: use in patients with altered pelvic anatomy. *The British Journal of Radiology* 1996;69(828) 1165-1170.
- [22] Seaman EK, Sawczuk IS, Fatal M, Olsson CA, Shabsigh R. Transperineal prostate needle biopsy guided by transurethral ultrasound in patients without a rectum. *Urology* 1996;47(3) 353-355.
- [23] Shinohara K, Gulati M, Koppie TM, Terris MK. Transperineal prostate biopsy after abdominoperineal resection. *The Journal of Urology* 2003;169(1) 141-144.
- [24] Emiliozzi P, Corsetti A, Tassi B, Federico G, Martini M, Pansadoro V. Best approach for prostate cancer detection: A prospective study on transperineal versus transrectal six-core prostate biopsy. *Urology* 2003;61(5) 961-966.
- [25] Igel TC, Knight MK, Young PR, Wehle MJ, Petrou SP, Broderick GA, Marino R, Parra RO. Systematic transperineal ultrasound guided template biopsy of the prostate in patients at high risk. *The Journal of Urology* 2001;165(5) 1575-1579.
- [26] Eskew LA, Bare RL, McCullough DL. Systematic 5 region prostate biopsy is superior to sextant method for diagnosing carcinoma of the prostate. *The Journal of Urology* 1997;157(1) 199-202.