

# We are IntechOpen, the world's leading publisher of Open Access books Built by scientists, for scientists

**4,800**

Open access books available

**122,000**

International authors and editors

**135M**

Downloads

Our authors are among the

**154**

Countries delivered to

**TOP 1%**

most cited scientists

**12.2%**

Contributors from top 500 universities



**WEB OF SCIENCE™**

Selection of our books indexed in the Book Citation Index  
in Web of Science™ Core Collection (BKCI)

Interested in publishing with us?  
Contact [book.department@intechopen.com](mailto:book.department@intechopen.com)

Numbers displayed above are based on latest data collected.

For more information visit [www.intechopen.com](http://www.intechopen.com)



---

# Surgical Advances in Laparoscopic Donor Nephrectomy

---

Cheguevara Afaneh, Meredith J. Aull, Joseph J. Del Pizzo and Sandip Kapur

Additional information is available at the end of the chapter

<http://dx.doi.org/10.5772/53945>

---

## 1. Introduction

### 1.1. Historical overview

Since it was first described in the 1990s, conventional laparoscopic donor nephrectomy has been the standard of care at most major transplant centers. Clayman et al. described the first successful conventional laparoscopic nephrectomy in 1991 for intrinsic renal disease [1]. Several years later, a conventional laparoscopic donor nephrectomy procedure was successfully performed in a large animal model [2], while Ratner and colleagues described the first successful conventional laparoscopic live donor nephrectomy one year later [3]. Donor were discharged home within two days and most returned to work within two weeks postoperatively. Moreover, recipient outcomes were significantly better than deceased donor allografts.

Over the next decade following the advent of conventional laparoscopic donor nephrectomy, the number of kidney transplants performed in the United States nearly doubled. The ability to perform the procedure using the conventional laparoscopic approach certainly influenced the willingness of donors to donate [4]. Moreover, the ease of donation has lead to more unexpected results, including altruistic donors, innovative protocols for ABO incompatibility and positive crossmatches, as well as kidney paired donation [5-7].

Laparoendoscopic single site surgery represents the next step in the evolution of conventional laparoscopic surgery. It is performed through a single small skin incision, often partially concealed at the umbilicus. Recently, several institutions, including our own, have reported on this technique for live donor nephrectomy [8-10]. Cosmesis, as well as possibly decreased postoperative pain and port-site related complications, are among the possible benefits compared to the conventional laparoscopic approach. Recipients have experienced similar postoperative results as those receiving allografts using the conventional laparoscopic procurement technique [11, 12].

## 2. Preoperative evaluation

### 2.1. Initial evaluation

All potential donors undergo a complete surgical, medical, and psychological evaluation in accordance with the clinical practice guidelines established by the American Society for Transplantation and the Consensus Statement on the Live Organ Donor [13, 14]. A discussion of the medical work-up is discussed elsewhere in this textbook. After a thorough medical and psychological evaluation, the patient is referred to the surgeon for preoperative consideration of anatomy and functional status of the donor kidneys.

### 2.2. Surgical preoperative considerations

#### 2.2.1. Anatomy and functionality

The use of preoperative imaging is a vital component of proper surgical planning. This allows determination of potential donor kidney size, function, and anatomy. This allows for determination of the safest and most feasible surgical approach. Potential donors typically undergo spiral computed tomography (CT) scans with intravenous contrast administration with vascular reconstructions to properly assess the renal hilum prior to surgery [15]. Magnetic resonance angiography is an alternative to spiral CT for evaluation of potential kidneys. Renal scintigraphy usually obtained when there is a >1 cm size discrepancy between kidneys.

#### 2.2.2. Laterality

Choosing the side of the nephrectomy should be given careful considering. The right kidney presents a technical challenge. Procurement of the right kidney using the endoscopic GIA stapling device to divide the anatomically shorter right renal vein results in losing anywhere from 1 cm to 1.5 cm from the total length [16]. This leads to a relatively short renal vein that complicates the recipient procedure and has been associated with acute renal vein thrombosis and early graft loss [17]. Short renal vasculature is no longer avoidable given surgical innovations. Left kidneys are preferentially chosen if the renal vasculature and function are comparable. Multiple left renal arteries or anomalous left renal veins are not absolute contraindications to procuring the left kidney [17]. The feasibility of procuring the right kidney has been clearly described from hand-assisted laparoscopy to the conventional laparoscopic approach to even using the laparoendoscopic single site approach [11, 18, 19].

#### 2.2.3. Contraindications

The contraindications to laparoendoscopic single site surgery are the same as those for any laparoscopic abdominal procedure. Certainly, previous abdominal surgery further complicates any laparoscopic procedure; it does not confer an absolute contraindication. In fact, the rate of conversion of laparoendoscopic single site surgery remains relatively low (<5%) as has been our experience [12].

### 3. Operative technique

#### 3.1. Positioning

Patients are placed in a modified flank position, and a 5 centimeter vertical periumbilical incision is made with the abdominal skin on stretch. After creation of a vertical midline anterior rectus fasciotomy, the abdomen is entered. The Gel Point device (Applied Medical, Rancho Santa Margarita, CA) as seen in figure 1 with three trocars already in place is inserted into the abdomen and pneumoperitoneum is established. Two 5-mm trocars and one 15-mm trocar are used. A bariatric 10-mm rigid laparoscope is used through the 15mm port with a right angle attachment for the light cord to maximize space for triangulation. Standard, non articulating laparoscopic instruments are used in the majority of the procedure. For right sided kidneys, a fourth trocar is placed through the Gelpoint device and a Diamond-Flex retractor (*Genzyme* Surgical Products, Tucker, GA) is used for exposure after mobilization of the right lobe of the liver by division of the triangular and coronary ligaments.



**Figure 1.** Gelport™ device. Three trocars are in place traversing the gel cap.

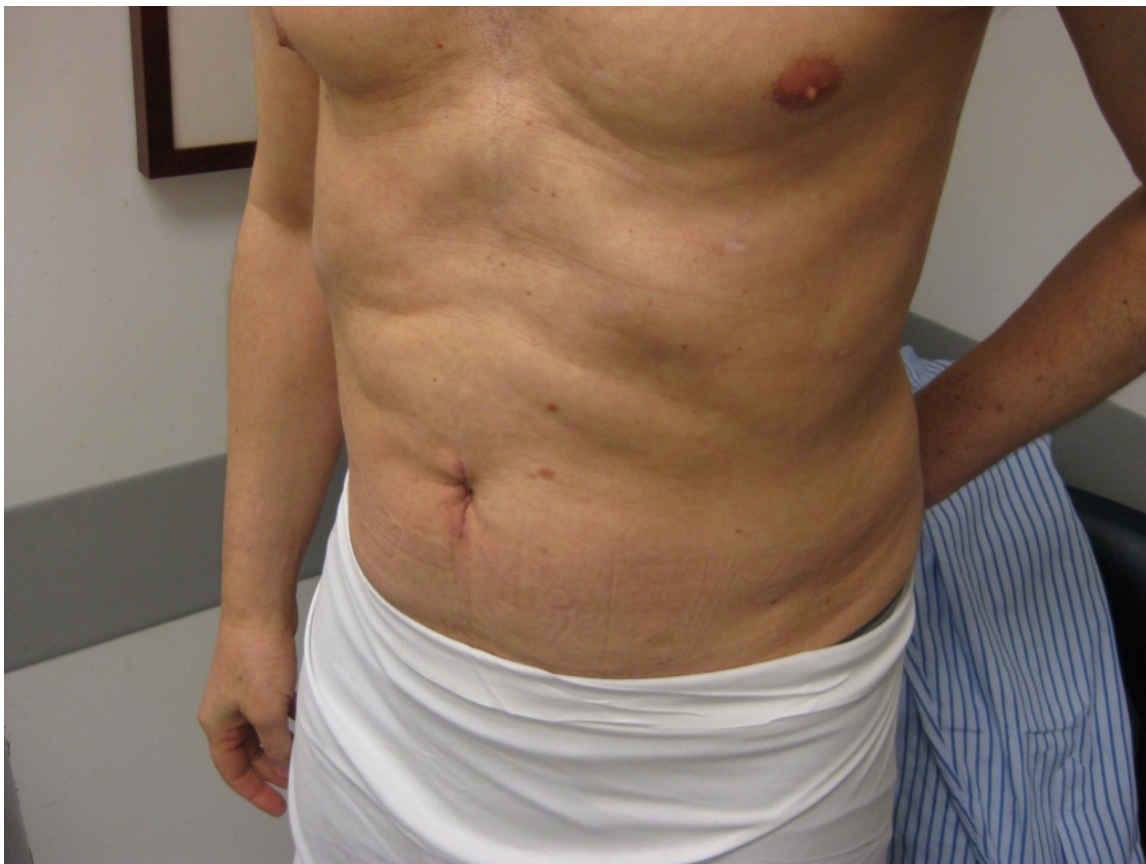#### 3.2. Procurement technique

##### 3.2.1. Left kidney

When procuring the left kidney using the laparoendoscopic single site procurement technique, the descending colon, pancreas and spleen are mobilized generously en bloc without the need for continuous retraction. The ureter and gonadal vein are identified and lifted off of the psoas muscle together, maintaining periureteral attachments and dissected towards the hilum. The lumbar vein, if present, is divided between titanium clips. The renal vein is skeletonized and the adrenal vein is divided between titanium clips, and the adrenal gland is released from the upper pole. The renal artery is dissected down to its aortic origin, and the interaortocaval region is skeletonized. Lastly, the posterior attachments were dissected free from the kidney. A 12-mm trocar replaces one of the 5-mm trocars in

anticipation of using the EndoGIA vascular stapling device (United States Surgical, Norwalk CT).

Once the recipient team is ready, the ureter and gonadal vein are divided together at the pelvic brim. The renal artery and then vein are divided using the vascular stapling device. An Endocatch bag is introduced, and the allograft is gently entrapped and extracted by removing the Gel cap. If necessary, the fascial incision is extended 1-2 cm to facilitate removal of the graft, taking care to leave the overlying skin intact without further extension of the incision. Fascia and skin are closed in the standard fashion after ensuring adequate hemostasis. No articulating or specialized laparoscopic instruments are needed and no extraumbilical incisions need to be made. The incision is well-concealed in the umbilicus using this technique (Figure 2).



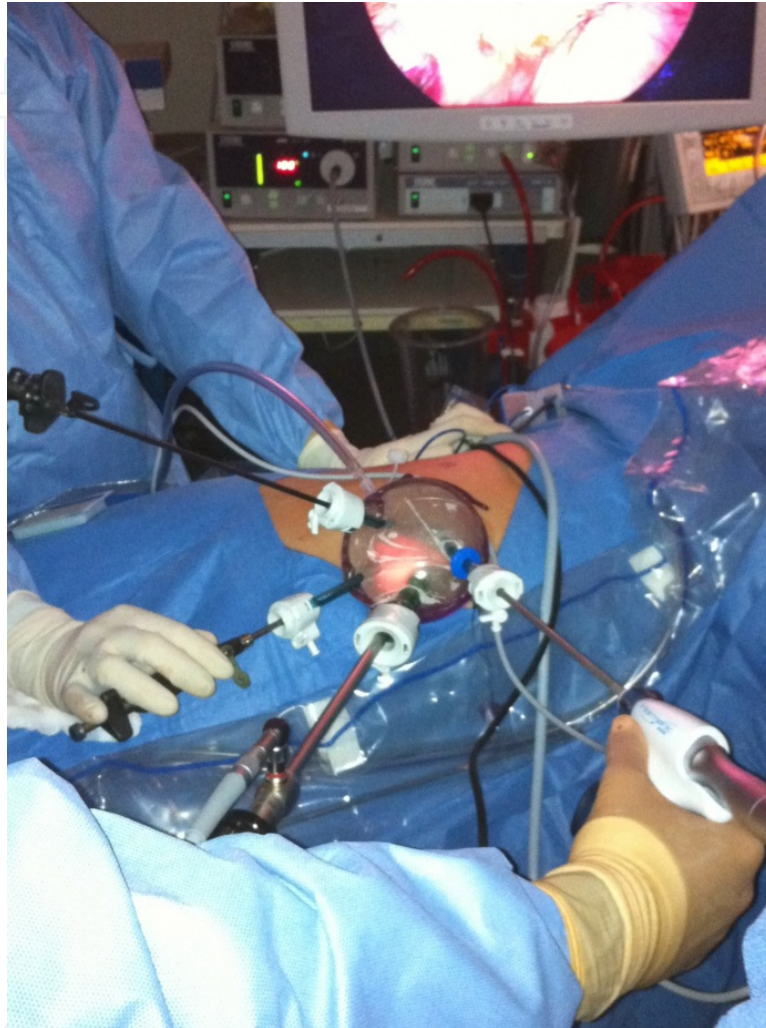
**Figure 2.** Postoperative incision. In this figure, the patient is 8 weeks postoperatively from a laparoendoscopic single site left donor nephrectomy.

### 3.2.2. *Right kidney*

The initial three trocars are placed as described above for left kidneys; however, the right kidney procurement technique requires a fourth trocar for retraction of the liver. Using mostly one handed dissection, the duodenum is kocherized bluntly to expose the inferior vena cava (IVC). The hepatic flexure is gently lifted and the plane between Gerota's fascia and the mesocolon is identified. The colon is bluntly dissected and mobilized in a medial



and caudal direction, down to the iliac vasculature. The ureter and gonadal vein are identified and lifted off of the psoas muscle together, maintaining periureteral attachments and dissected towards the hilum. At this point, a fourth trocar (5mm) is placed through the Gelport™ device for retraction of the right lobe of the liver (Figure 3).



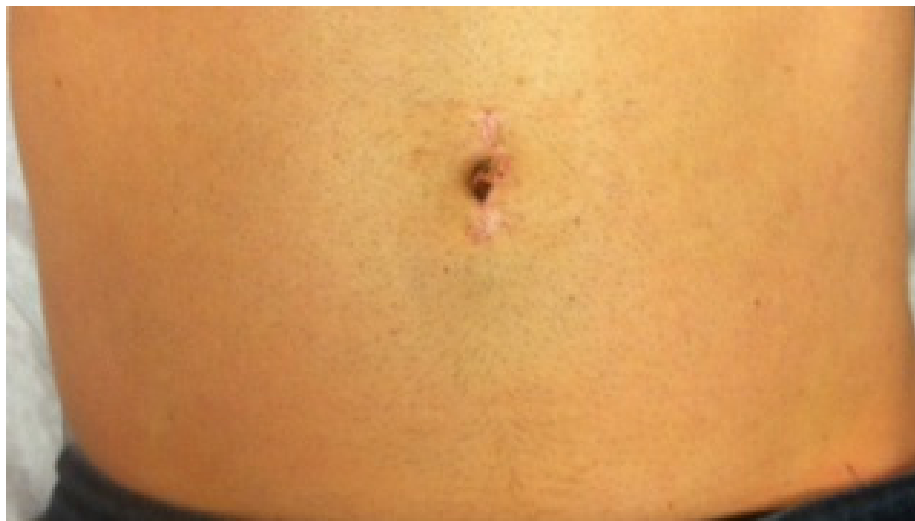**Figure 3.** Port placement for right sided kidney. In this figure, the four trocars are present traversing the Gelport™ device.

The renal vein is skeletonized down to the level of the IVC. The renal artery is dissected medial to the lateral edge of the IVC to maximize length, and the interaortocaval region is skeletonized. The adrenal gland is dissected free from the medial upper pole of the kidney using a harmonic scalpel. Lastly, the posterior and lateral attachments are divided. A 12-mm trocar replaces one of the 5-mm trocars in anticipation of using the EndoGIA vascular stapler (United States Surgical, Norwalk CT).

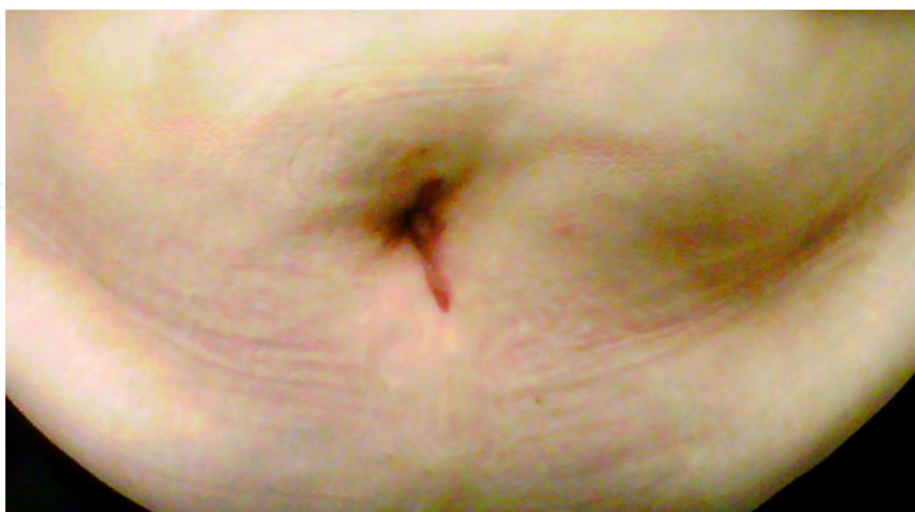
Once the recipient team is ready, the ureter is divided at the pelvic brim. The kidney is then retracted laterally. Using an EndoGIA vascular stapler, the renal artery is divided first, followed by the vein, with the vein being divided flush with the IVC to maximize length. An Endocatch bag is introduced, and the allograft is gently entrapped and extracted.

### 3.2.3. Obese donors

Obese donors represent a technically more challenging population. The technique mirrors that of the normal BMI donors; however there are several important technical aspects to consider [20]. First, mobilization of adjacent organs may be more difficult. Given the amount of intra-abdominal fat, visualization may be more difficult. As a result, there may be increased difficulty in identifying key landmarks. Male donors have additional visceral adipose tissue which may make it more difficult to retract [21]. The amount of perirenal fat must be taken into consideration when planning safe extraction of the allograft from an obese patient to avoid a renal laceration [20]. The incision remains well-concealed, even this population (Figure 4A&B).



A.



B.

**Figure 4.** Obese versus normal BMI. The images depict donors approximately 2 weeks following laparoendoscopic single site donor nephrectomy. Panel A is a non-obese donor and panel B is an obese donor.

## 4. Donor considerations

### 4.1. Morbidity

The donor nephrectomy is a unique procedure, as it entails operating on a healthy individual, as opposed to surgery for specific disease processes. To justify the procedure, the potential complications must be minimized as donor safety should be the priority.

Initial studies evaluating donor safety compared the open to the conventional laparoscopic approach. Various studies and reviews have demonstrated a complication rate ranging from 0% to 38% using the open procurement approach and 0% to 30% with the conventional laparoscopic approach [22, 23]. More recent studies have reported complications of less than 10% in conventional laparoscopic donor nephrectomy [24, 25]. In a single surgeon series of 750 laparoscopic donor nephrectomies, Harper et al. used the modified Clavien-Dindo system and reported an overall complication rate of 5.5% [24]. The majority of complications were classified as minor, with most (66%) being grade 1. Moreover, there were only four cases converted to an open procedure (0.4%). These values are similar to our experience as our complication rate for conventional laparoscopic donor nephrectomy was approximately 7%. Moreover, only one patient in that cohort required conversion to an open procedure (0.15%) [25].

Given the relatively novel nature of the laparoendoscopic single site procurement technique, donor morbidity must remain minimal. We reported a similar complication rate (approximately 7%) large series of laparoendoscopic single site donor nephrectomies, comparable to our conventional laparoscopic procurement technique [12, 25]. Other smaller, single center series have demonstrated similar outcomes comparing laparoendoscopic single site donor nephrectomies to conventional laparoscopic donor nephrectomies [26, 27]. Kurien and colleagues reported the first randomized controlled trial of 50 patients comparing conventional laparoscopic donor nephrectomies versus laparoendoscopic single-site donor nephrectomies [28]. They reported an intraoperative and postoperative complication rate of 16% in the laparoendoscopic single-site donor group, which was similar to the conventional laparoscopic donor nephrectomy group.

Certain complications are more specific to the laterality of the donor kidney. For example, in right sided donors, liver lacerations and injuries to the retro-aortic renal arteries are more common. On the other hand, intraoperative complications related to splenic lacerations during mobilization of the splenic flexure of the colon or injuries to the supra-adrenal branches of the left renal vein are more common in left sided donors [29].

### 4.2. Technical considerations

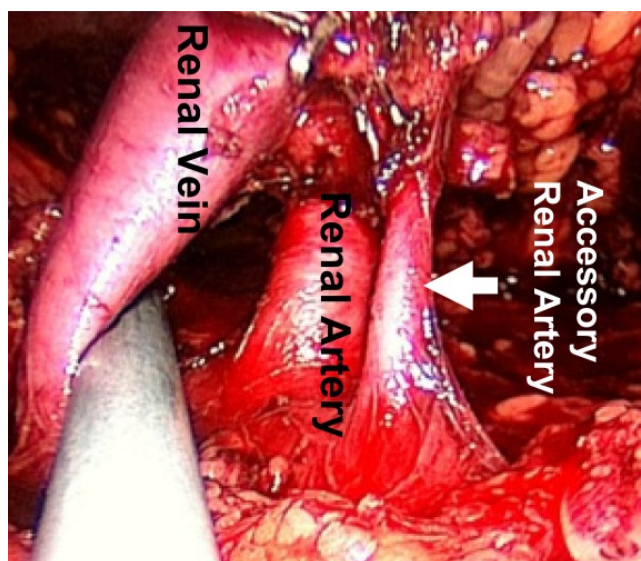
The use of laparoendoscopic single site surgery in living donor kidney procurement offers a new set of challenges to the laparoscopic surgeon. Technical limitations including a reduced working space and lack of instrument triangulation make it a technically challenging procedure. These limitations are more pronounced in the obese patient, where difficulties in exposure and visualization already exist, including additional visceral adipose tissue that is



more difficult to retract. Overweight male donors were even found to have higher rates of conversion to open procedures compared to overweight female donors, possibly related to the visceral fat distribution [21].

Procuring the right kidney poses additional threats as previous studies have demonstrated an increased risk of renal vein thrombosis [17, 18]. Our initial experience with hand-assisted laparoscopy saw a renal vein thrombosis rate of less than 3% [30]. In fact, we had not had any cases of renal vein thrombosis with the conventional laparoscopic procurement technique, or even more recently, with the laparoendoscopic single site donor nephrectomy technique [19, 30]. An important technical consideration is firing the stapling device flush against the IVC, while laterally retracting the kidney to maximize renal vein length to avoid this complication.

Various studies have compared outcomes of transplantation of kidneys with a single artery versus those with multiple arteries (Figure 5). Most of these studies have demonstrated similar survival and graft function between the two groups [31-33]. However, other studies have shown that kidneys harvested with multiple arteries are technically difficult leading to increased complications, such as vascular thrombosis, increased bleeding during nephrectomy, and increased operating times [34]. Our experience using the laparoendoscopic single site donor nephrectomy technique to procure kidneys with multiple vessels has been similar to those with single renal arteries and veins (approximate complication rate of 6%).



**Figure 5.** Multiple renal arteries. The image depicts a kidney with multiple renal arteries.

#### 4.3. Donor satisfaction

The true benefits of laparoendoscopic single site donor nephrectomy remain to be seen. Canes et al. compared 17 laparoendoscopic single site donor nephrectomies to a matched pair of 17 conventional laparoscopic donor nephrectomies and found no difference in standard perioperative parameters [27]. They did however identify superior patient scar

satisfaction, decreased oral analgesic use, and improved convalescence in the laparoendoscopic single site cohort. Kurien and colleagues demonstrated no difference in convalescence parameters in their randomized controlled trial comparing 25 laparoendoscopic single site donor nephrectomies to 25 conventional laparoscopic donor nephrectomies [28]. The laparoendoscopic cohort did have less pain requirements and a one-half day improvement in hospital stay; however, the warm ischemia time was slightly increased in that cohort. In an analysis of our series of our first 100 laparoendoscopic single site donor nephrectomies, the laparoendoscopic group had a slight, but significant improvement in convalescence compared to a group of 100 matched conventional laparoscopic donor nephrectomies [12]. However, the laparoendoscopic group had significantly longer operative times by almost 30 minutes on average.

## **5. Recipient outcomes**

### **5.1. Allograft function**

The benefit of live donor nephrectomy, compared to receiving an allograft from a deceased donor, is the prompt functionality of the allograft with more durable function. Comparisons of early and late allograft function in the recipient of open versus conventional laparoscopic donor nephrectomy have already been shown in several studies, including two randomized controlled trials [35, 36]. Similarly, all recent studies comparing allografts procured with the laparoendoscopic single site technique have shown similar early allograft function compared to allografts via conventional laparoscopic approaches [10-12, 28]. Moreover, these results have also been seen with right sided allografts, despite the shorter vasculature when compared to either right or left allografts [19, 30]. In addition, allografts from obese donors have seen similar early allograft function as allografts from non-obese donor irrespective of procurement technique [20]. In all of these studies, the incidence of delayed graft function remained low (<5%).

### **5.2. Survival**

Graft survival following conventional laparoscopic donor nephrectomy has been excellent. Given the infancy of the laparoendoscopic single site procurement technique, long-term or even intermediate-term follow-up remains limited. However, short-term follow-up suggests patient survival remains excellent at 1 year (100%) as well as overall graft survival at 1 year (98%) [11]. Kurien et al. demonstrated similar 1 year outcomes, including both patient and graft survival of 100% [28]. At the present, short-term outcomes appear similar to conventional laparoscopic procurement techniques.

## **6. Conclusion**

The single incision approach represents a technological advancement in renal allograft organ recovery. Perhaps with time, this could represent a paradigm shift that will require evolution of instrumentation, technique, and training models, just as conventional

laparoscopic donor nephrectomies did over a decade and a half ago. At this time, the benefits of single incision technique appears limited to superior cosmesis and a small improvement in convalescence. With time, however, the laparoendoscopic single site donor nephrectomy technique may further decrease the barriers to live organ donation and transplantation.

## Author details

Cheguevara Afaneh, Meredith J. Aull, Joseph J. Del Pizzo and Sandip Kapur  
*Department of Surgery, Division of Transplant Surgery, New York-Presbyterian Hospital- Weill Cornell Medical College, New York, NY, USA*

Joseph J. Del Pizzo

*Department of Urology, New York-Presbyterian Hospital- Weill Cornell Medical College, New York, NY, USA*

## 7. References

- [1] Clayman, R.V.; Kavoussi, L.R.; Soper, N.J., et al.. Laparoscopic nephrectomy. *N Engl J Med*, Vol.324, No.19, (May 1991), pp. 1370-1371.
- [2] Gill, I.S.; Carbone, J.M.; Clayman, R.V., et al. Laparoscopic live-donor nephrectomy. *J Endourol*, Vol.8, No.2, (April 1994), pp. 143-148.
- [3] Ratner, L.E.; Cisek, L.J.; Moore, R.G., et al. Laparoscopic live donor nephrectomy. *Transplantation*, Vol.60, No.9, (November 1995), pp. 1047-1049.
- [4] Ratner, L.E.; Hiller, J.; Sroka, M., et al. Laparoscopic live donor nephrectomy removes disincentives to live donation. *Transplant Proc*, Vol.29, No.8, (December 1997), pp. 3402-3403.
- [5] Montgomery, R.; Simpkins, C.E.; Segev, D.L. New options for patients with donor incompatibilities. *Transplantation*, Vol.82, No.2, (July 2006), pp. 164-165.
- [6] Montgomery, R.A.; Zachary, A.A.; Ratner, L.E., et al. Clinical results from transplanting incompatible live kidney donor/recipient pairs using kidney paired donation. *JAMA*, Vol. 294, No.13, (October 2005), pp. 1655-1663.
- [7] Leiser, D.B.; Aull, M.J.; Afaneh, C., et al. Living donor kidney paired donation transplantation: A single center experience. *Clin Transplant* 2012; 26(3):E213–E222.
- [8] Canes, D.; Desai, M.M.; Aron, M., et al. Transumbilical single-port surgery: Evolution and current status. *Eur Urol*, Vol.54, No.5, (November 2008), pp. 1020-1029.
- [9] Gill, I.S.; Canes, D.; Aron, M., et al. Single port transumbilical (E-NOTES) donor nephrectomy. *J Urol*, Vol.180, No.2, (August 2008), pp. 637-641.
- [10] Gimenez, E.; Leiser, D.; Wysock, J., et al. Laparoendoscopic single site live donor nephrectomy: Initial experience. *J Urol*, Vol.184, No.5, (November 2010), pp. 2049-2053.
- [11] Afaneh, C.; Aull, M.J.; Gimenez, E., et al. Comparison of laparoendoscopic single-site donor nephrectomy and conventional laparoscopic donor nephrectomy: donor and recipient outcomes. *Urology*, Vol.78, No.6, (December 2011), pp. 1332-1337.

- [12] Wang, G.J.; Afaneh, C.; Aull, M., et al. Laparoendoscopic single site live donor nephrectomy: single institution report of initial 100 cases. *J Urol*, Vol.186, No.6, (December 2011), pp. 2333-2337.
- [13] Abecassis, M.; Adams, M.; Adams, P., et al. For the Live Organ Donor Consensus Group: Consensus statement on the live organ donor. *JAMA*, Vol.284, No.22, (December 2000), pp. 2919-2926.
- [14] Kasiske, B.L.; Ravenscraft, M.; Ramos, E.L., et al. The evaluation of living renal transplant donors: clinical practice guidelines. Ad Hoc Clinical Practice Guidelines Subcommittee of the Patient Care and Education Committee of the American Society of Transplant Physicians. *J Am Soc Nephrol*, Vol.7, No.11, (November 1996), pp. 2288-2313.
- [15] Smith, P.A.; Ratner, L.E.; Lynch, F.C., et al. Role of CT angiography in the preoperative evaluation for laparoscopic nephrectomy. *Radiographics*, Vol.18, No.3, (May-June 1998), pp. 589.
- [16] Ratner, L.E.; Kavoussi, L.; Chavin, K., et al. Laparoscopic live donor nephrectomy: technical consideration and vascular length. *Transplantation*, Vol.65, No.12, (June 1998), pp. 1657-1658.
- [17] Mandal, A.K.; Cohen, C.; Montgomery, R.A., et al. Should the indications for laparoscopic live donor nephrectomy of the right kidney be the same as for the open procedure? Anomalous left renal vasculature is not a contraindication to laparoscopic left donor nephrectomy. *Transplantation*, 2001;71(5):660-4.
- [18] Buell, J.F.; Hanaway, M.J.; Potter, S.R., et al. Surgical techniques in right laparoscopic donor nephrectomy. *J Am Coll Surg*, 2002;195(1):131-7.
- [19] Afaneh, C.; Ramasamy, R.; Leeser, D.B., et al. Is right-sided laparoendoscopic single-site donor nephrectomy feasible? *Urology*, Vol.77, No.6, (June 2011), pp. 1365-1369.
- [20] Afaneh, C.; Sheth, S.; Aull, M.J., et al. Laparoendoscopic single-site nephrectomy in obese living renal donors. *J Endourol*, Vol.26, No.2, (February 2012), pp. 140-146.
- [21] Kok, N.F.; Izzermans, J.N.; Schouten, O., et al. Laparoscopic donor nephrectomy in obese donors: easier to implement in overweight women? *Transpl Int*, Vol.20, No.11, (November 2007), pp. 956-961.
- [22] Merlin, T.L.; Scott, D.F.; Rao, M.M, et al. The safety and efficacy of laparoscopic live donor nephrectomy: a systematic review. *Transplantation*, Vol.70, No.12, (December 2000), pp. 1659-1666.
- [23] Tooher, R.I.; Rao, M.M.; Scott, D.F., et al. A systematic review of laparoscopic live-donor nephrectomy. *Transplantation*, Vol.78, No.3, (August 2004), pp. 404-414.
- [24] Harper, J.D.; Breda, A.; Leppert, J.T., et al. Experience with 750 consecutive laparoscopic donor nephrectomies—is it time to use a standardized classification of complications? *J Urol*, Vol.183, No.5, (May 2010), pp. 1941-1946.
- [25] Ramasamy, R.; Afaneh, C.; Katz, M., et al. Comparison of complications of laparoscopic versus laparoendoscopic single site donor nephrectomy using the modified Clavien grading system. *J Urol*, Urol. 2011;186(4):1386-90.
- [26] Andonian, S.; Rais-Bahrami, S.; Atalla, M.A., et al. Laparoendoscopic single-site Pfannenstiel versus standard laparoscopic donor nephrectomy. *J Endourol*, Vol.24, No.3, (March 2010), pp. 429-432.

- [27] Canes, D.; Berger, A.; Aron, M., et al. Laparo-endoscopic single site (LESS) versus standard laparoscopic left donor nephrectomy: matched-pair comparison. *Eur Urol*, Vol.57, No.1, (January 2010), pp. 95-101.
- [28] Kurien, A.; Rajapurker, S.; Sinha, L., et al. First prize: Standard laparoscopic donor nephrectomy versus laparoendoscopic single-site donor nephrectomy: a randomized comparative study. *J Endourol*, Vol.25, No.3, (March 2011), pp. 365-370.
- [29] Minnee, R.C.; Bemelman, W.A.; Maartense, S., et al. Left or right kidney in hand-assisted donor nephrectomy? A randomized controlled trial. *Transplantation*, Vol.85, No.2, (January 2008), pp. 203-208.
- [30] Afaneh, C.; Aull, M.J.; Schubl, S., et al. The evolution of laparoscopic right donor nephrectomy: Progression to single site surgery. *J Transplant Technol Res*, Vol.1, Issue.2, No.103, (November 2011), pp. 1-7.
- [31] Desai, M.R.; Ganuple, A.P.; Gupta, R., et al. Outcome of renal transplantation with multiple versus single renal arteries after laparoscopic live donor nephrectomy: A comparative study. *Urology*, Vol.69, No.5, (May 2007), pp. 824-827.
- [32] Hsu, T.H.; Su, L.M.; Ratner, L.E.; Trock, B.J.; Kavoussi, L.R. Impact of renal artery multiplicity on outcomes of renal donors and recipients in laparoscopic donor nephrectomy. *Urology*, Vol.61, No.2, (February 2003), pp. 323-327.
- [33] Saidi, R.; Kawai, T.; Kennealey, P., et al. Living donor kidney transplantation with multiple arteries: recent increase in modern era of laparoscopic donor nephrectomy, *Arch Surg*, Vol.144, No.5, (May 2009), pp. 472-475.
- [34] Carter, J.T.; Freise, C.E.; McTaggart, R.A., et al. Laparoscopic procurement of kidneys with multiple renal arteries is associated with increased ureteral complications in the recipient. *Am J Transplant*, Vol.5, No.6, (June 2005), pp.1312-1318.
- [35] Kok, N.F.; Lind, M.Y.; Hansson, B.M., et al. Comparison of laparoscopic and mini incision open donor nephrectomy: single blind randomized controlled trial. *BMJ*, Vol.333, No.7561, (July 2006), pp. 221.
- [36] Simforoosh, N.; Basiri, A.; Tabibi, A., et al. Comparison of laparoscopic and open donor nephrectomy: a randomized controlled trial. *BJU Int*, Vol.95, No.6, (April 2005), pp. 851-855.