

# We are IntechOpen, the world's leading publisher of Open Access books Built by scientists, for scientists

4,800

Open access books available

122,000

International authors and editors

135M

Downloads

Our authors are among the

154

Countries delivered to

TOP 1%

most cited scientists

12.2%

Contributors from top 500 universities



WEB OF SCIENCE™

Selection of our books indexed in the Book Citation Index  
in Web of Science™ Core Collection (BKCI)

Interested in publishing with us?  
Contact [book.department@intechopen.com](mailto:book.department@intechopen.com)

Numbers displayed above are based on latest data collected.  
For more information visit [www.intechopen.com](http://www.intechopen.com)



---

# **B-Scan and 'En-Face' Spectral-Domain Optical Coherence Tomography Imaging for the Diagnosis and Follow-Up of White Dot Syndromes**

---

Benjamin Wolff, Alexandre Matet, Vivien Vasseur,  
José-Alain Sahel and Martine Mauget-Faÿsse

Additional information is available at the end of the chapter

<http://dx.doi.org/10.5772/53959>

---

## **1. Introduction**

The term 'white dot syndromes' (WDS) refers to several inflammatory diseases of the retina and choroid caused by immune dysregulation. They consist of the following disorders, with overlapping clinical features:

- Acute posterior multifocal placoid pigment epitheliopathy (APMPPE)
- Serpiginous choroidopathy
- Multiple evanescent white dot syndrome (MEWDS)
- Birdshot retinochoroidopathy
- Acute retinal pigment epitheliitis (ARPE)
- Multifocal choroiditis and panuveitis syndrome (MCP)
- Punctuate inner choroidopathy (PIC), and
- Acute zonal occult outer retinopathy (AZOOR)

These conditions usually occur following an influenza-like illness, but their patho-physiologic mechanism remains poorly understood. The white dot syndromes affect more frequently young females and individuals with mild myopia, and present as white or yellow, deep, round lesions in the central fundus. Their size and number can vary between each entity, as well as their uni- or bilateral involvement.

In addition to these clinical parameters, fluorescein (FA) and indocyanine green angiographies (ICGA) help in identifying the diagnosis [1]. They also help assess the level of inflammatory activity and detect complications.

The high resolution of the scans generated by Spectral Domain Optical Coherence Tomography (SD-OCT) offers a helpful tool in the management of WDS. SD-OCT allows a direct, non-contact visualization of involved retinal layers and thereby provides information concerning the:

- accurate location of the inflammatory process
- integrity of the photoreceptors inner segment / outer segment junction (IS/OS)
- course of the inflammatory process, leading to resolution or residual scarring
- presence of complications such as neovascularization

Moreover, the use of 'en-face' OCT for WDS allows a layer-by-layer view of the involved retina. This novel imaging technique generates frontal scans derived from SD-OCT.

The scans of "en face" OCT imaging of WDS were obtained by Spectral-domain OCT (Spectralis® Heidelberg Engineering, Heidelberg, Germany). For every case, the macula was analyzed using SD-OCT (Spectralis® Heidelberg Engineering, Heidelberg, Germany) and macular mapping consisting of 197 transverse sections in a 5.79 x 5.79 mm<sup>2</sup> central retinal area. Tridimensional reconstruction generated by the pooling of these sections provides a virtual macular brick, through which 496 shifting sections in the coronal plane result in the C-scan, or "en face" OCT.

In contrast, B-scans for conventional OCT are derived from sagittal and transverse sections. Enhanced depth imaging OCT (EDI-OCT) is a new tool that improves the sensitivity of the imaging in deeper layers of retinal tissue. The visualization of the choroid is increased and thus the obtained measurements are more accurate.

For each condition belonging to the WDS, we compared the results from SD-OCT "B-scan" and 'en-face' with data from classical retinal imaging, namely fundus photography and angiography.

## 2. MEWDS, Multiple evanescent white dot syndrome (figure 1)

MEWDS typically affects young females, and presents as a sudden visual loss with paracentral scotomas. In 80% of cases the condition remains unilateral. Fundus examination reveals small, discrete perifoveolar dots, very mild vitritis, and, in some cases, papillitis. On fluorescein angiography these dots appear hyperfluorescent, but are hypofluorescent on ICGA. The natural history leads usually to complete and spontaneous resolution within weeks.

- SD-OCT at the acute stage identifies the lesions in the outer retina as hyperreflective thickened lesions of the inner segment/outer segment (IS/OS) junction, alternating with

disruption of the IS/OS junction [2]. Small highly reflective dots involving the RPE inner layer, the IS/OS junction and the outer nuclear layer can be observed. EDI-OCT frequently demonstrates choroidal thickening.

- 'En-face' OCT shows multifocal involvement in the plane of the IS-OS junction, consisting of various round hyporeflective lesions alternating with large hyperreflective areas. Centrally, they may appear as confluent, which explains the "moth-eaten" appearance of the macula in some cases. Hypofluorescent spots on ICGA and IS-OS disruption zones on 'en-face' OCT are well correlated [3]. This correlation is also observed between SD-OCT B-scans and ICGA.

During follow-up, a progressive and complete restitution of outer retinal layers is observed. This observation is correlated with functional resolution [4]. However, focal gaps in IS/OS junction may persist in some cases and are associated with central visual field defects.

### **3. Acute posterior multifocal placoid pigment epitheliopathy (APMPPE) (figure 2 and 3)**

In this bilateral, often asymmetrical condition, that presents in healthy young adults, with both male and female being affected equally, fundus examination reveals yellowish-white plaques of 1 to 2 disc diameters, scattered from the fovea to the equator [5]. They may be associated with mild vitritis. Their FA appearance in the acute stage is pathognomonic: early blockade hypofluorescence, followed by late hyperfluorescence caused by staining. ICGA shows multiple lesions that may be confluent, and that remain hypofluorescent during all angiographic stages.

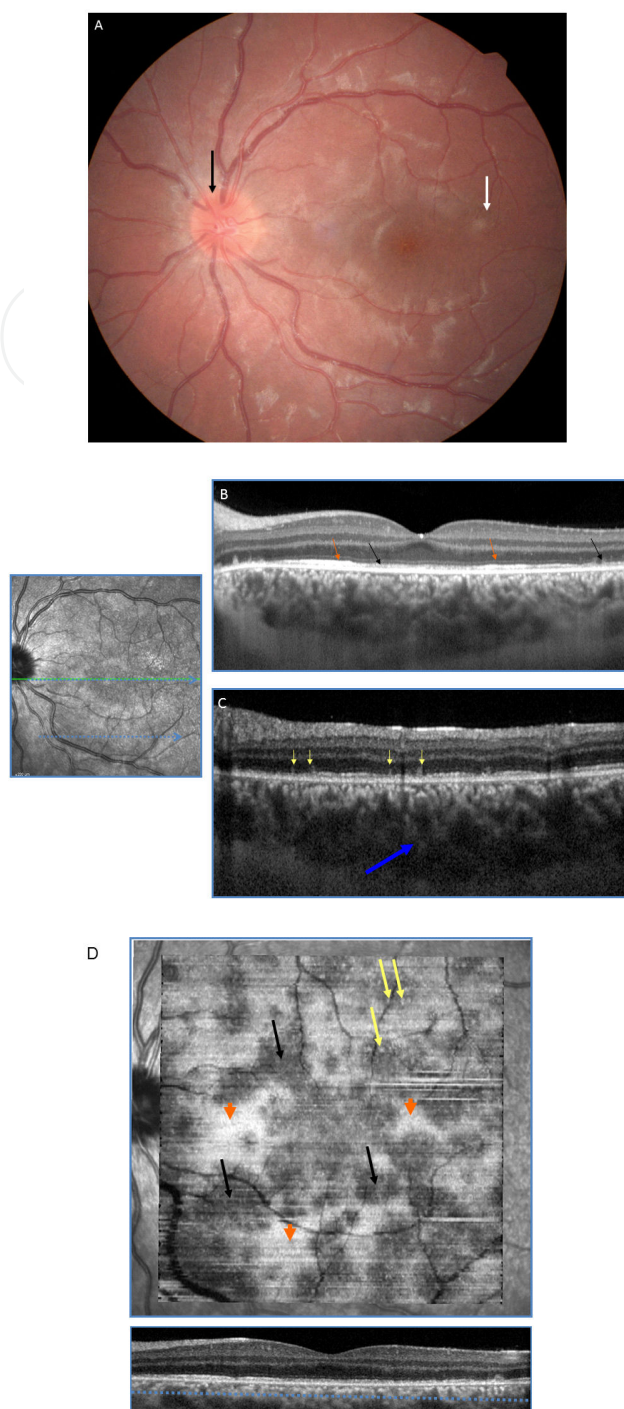
In the acute stage, SD-OCT shows:

- On B-scan: hyperreflective lesions in outer retinal layers, some extending to Henle's fibers layer. Irregularities in IS/OS, external limiting membrane, and inner pigment epithelium layer are also visible around those highly reflective lesions [6]. In the acute phase, an elevation of the IS/OS junction with subretinal fluid located between this layer and the RPE may be observed. In severe cases, this hyporeflective space between the IS/OS and external limiting membrane can mimic an encapsulated serous retinal detachment. Hyperreflective intrachoroidal spots are seen on EDI mode, suggesting choroidal inflammation.
- On 'en-face' OCT: the extent of the lesions, located in the external nuclear layer, are well defined. These lesions perfectly match the hypofluorescent plaques seen on ICGA. In severe cases with encapsulated serous retinal detachment, 'en-face' OCT reveals a wide hyporeflective lesion with hyperreflective borders. These large hyporeflective lesions may contain tiny reflective deposits.

In the late stages, SD-OCT shows:

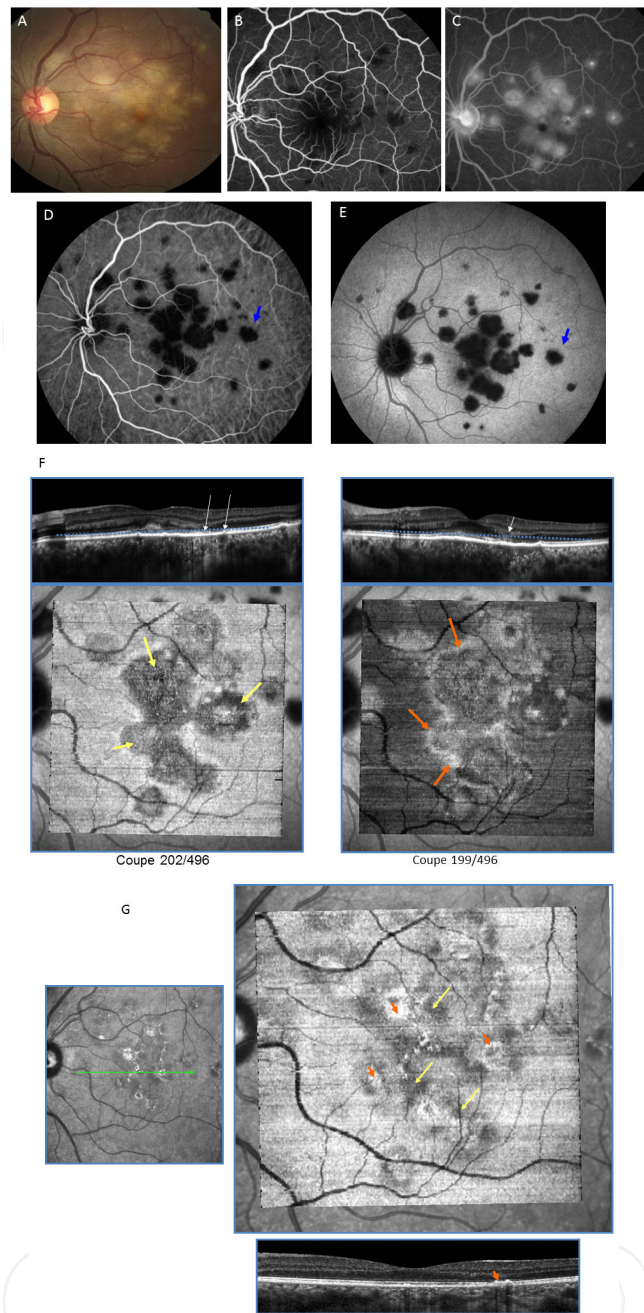
- On B-scans: retinal thinning with disruption of the IS/OS and inner pigment epithelium, located where hyperreflective lesions had been observed. Irregular or focal gaps in external

Int( )en

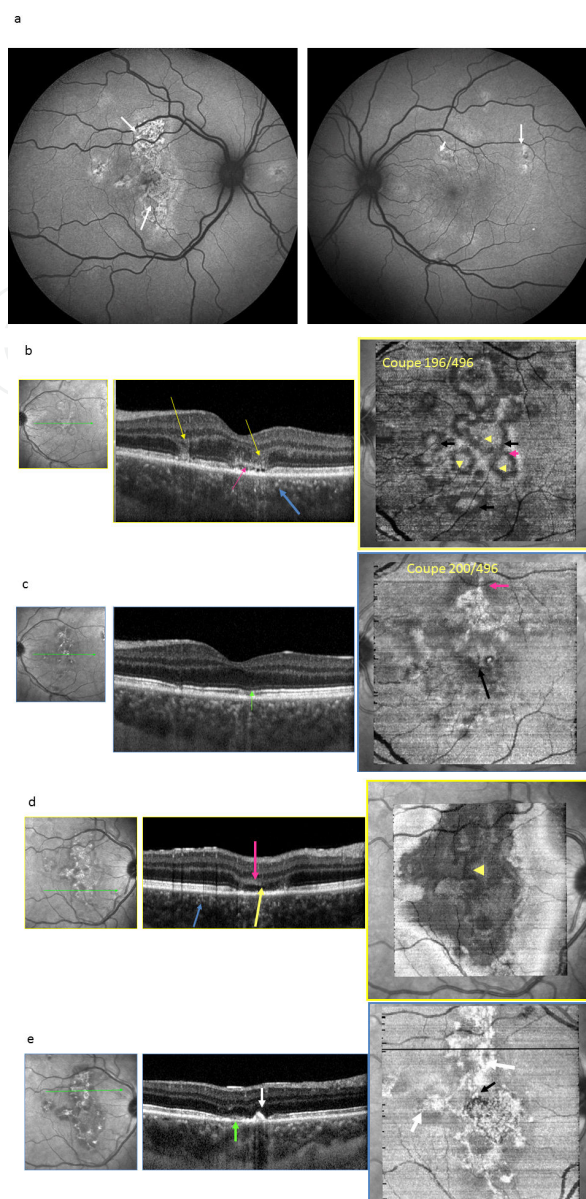


Int en

**Figure 1. MEWDS.**a) MEWDS acute phase: color fundus photography. Unilateral (Left eye) discrete perifoveal dots (white arrow) with light papillitis (black arrow), b) MEWDS acute phase: SD-OCT B-scan. Visualization of large IS/OS segment disruptions (black arrow) in the posterior pole, mostly in the foveal region, alternating with few focal, highly hyperreflective, thickened IS/OS zones (orange arrows). c) MEWDS acute phase: SD-OCT B-scan. Tiny hyperreflective elevations (spicules) (yellow arrows) visible in the areas with IS/OS disruption. Note the significant choroidal thickening (blue arrow). d) MEWDS acute phase: En Face OCT. Multifocal involvement in the plane of the IS-OS junction, consisting of various round or oval coalescing hyporefective lesions (black arrows) corresponding to areas of disrupted IS/OS junctions seen on B-scans, alternating with large hyperreflective areas (orange arrows). The « spicules » are imaged as very small hyperreflective spots (yellow arrows) within the hyporefective zones of IS/OS junction disruptions.



**Figure 2. AMPPE.**(a-e). AMPPE early phase: a: AMPPE typical presentation with yellowish-white plaques of 1 to 2 disc diameters, scattered from the fovea to the equator on color fundus photography. FA appearance in the acute phase is pathognomonic with early blockade hypofluorescence, (figure 2b) followed by late hyperfluorescence phase (figure 2c). ICGA shows multiple lesions that may be confluent, and that remain hypofluorescent during all angiographic phases (early phase: figure 2d) and late phase (figure 2e). f) AMPPE early phase: SD-OCT B-scan both images. Top: Hyperreflective lesions in the outer retinal layers, some extending to Henle's fibers layer. Irregularities in the IS/OS, external limiting membrane, and inner pigment epithelium layer are seen around the hyperreflective lesions (white arrows). Bottom: En face OCT. Left: Visualization of the hyporeflective lesions corresponding to the alterations in the IS/OS junction (yellow arrows). Right: Hyperreflective band within the outer nuclear layer (orange arrows) surrounding the hyporeflective lesions (corresponding to hypofluorescent spots on ICGA).g) AMPPE late phase. Left: SD-OCT B-scan. Areas of irregularly thickened pigment epithelium (orange arrow). Right: En face OCT. These irregularly thickened areas of pigment epithelium are visualized as hyperreflective zones (orange arrows). Hyporeflective areas are due to previous IS/OS junction involvement (yellow arrows).



**Figure 3. AMPPE.**a) AMPPE early phase of a more severe case. Autofluorescence images: Irregular autofluorescent areas in both eyes (white arrows). b) AMPPE early phase, left eye. Left: SD-OCT B-scan. Hyperreflective lesions (yellow arrows) in the outer retinal layers, extending to Henle's fibers layer. Irregularities in the IS/OS, external limiting membrane, and inner pigment epithelium layers are visible around the highly reflective lesions. Subretinal fluid is observed located between the IS/OS junction and the RPE (pink arrow) as well as hyperreflective small spots within the choroid (blue arrows). Right: En face OCT. Round or oval coalescing moderately reflective lesions (yellow arrow head) bordered by a hyporefective band (black arrows) located inside a hyperreflective area (pink arrow head). c) AMPPE late phase. Left: SD-OCT B-scan. Thinned IS/OS junction areas and RPE irregularities (green arrows) Right: En face OCT. Global improvement at the IS/OS junction plane with scarring represented by hyper- (pink arrows) and hyporefective areas (black arrows) d) AMPPE early phase. Left: SD-OCT B-scan. Severe alterations of the whole outer retina (pink arrows) with IS/OS segment disruption (yellow arrow) and hyperreflective spots within the choroid (blue arrow). Right: En face OCT. Scan at the level of IS/OS segment plane: extensive hyporefective lesions (yellow arrow head) corresponding to IS/OS segment disruption. e). AMPPE late phase. Left: SD-OCT B-scan. Outer retinal scar represented by alternation of thinning (green arrow) and thickening (white arrow) of the IS/OS and RPE tissues. Right: En face OCT. Global improvement at the IS/OS plane with the association of hyperreflective (white arrows) and hyporefective areas (black arrow) of the scarring process in the IS/OS and RPE complex.

limiting membrane can also occur [7]. In some cases, complete resolution of outer retinal defects may be seen. Classically, involvement of the pigment epithelium has been described [8]. It appears in the late stage as areas of irregular, thickened pigment epithelium.

- 'En-face' OCT demonstrates a decrease in the highly reflective lesions that are replaced with hyporeflective areas due to IS/OS junction involvement. Hyperreflective dots corresponding to focal areas of thickened RPE can be observed inside this hyporeflective IS/OS junction layer.

#### **4. Serpiginous choroiditis (figure 4)**

This chronic, progressive, bilateral and asymmetrical condition presents equally in men and women, from the 2<sup>nd</sup> to the 6<sup>th</sup> decade of life [9]. Various infectious etiologies have been suggested, among which tuberculosis must be formally ruled out [10]. Clinical and angiographic examination identifies greyish-white digitations starting from the optic disc. Its active border appears hypofluorescent on FA. ICGA is a useful tool for evaluating the response to treatment, since lesions are more extended on ICGA than on FA.

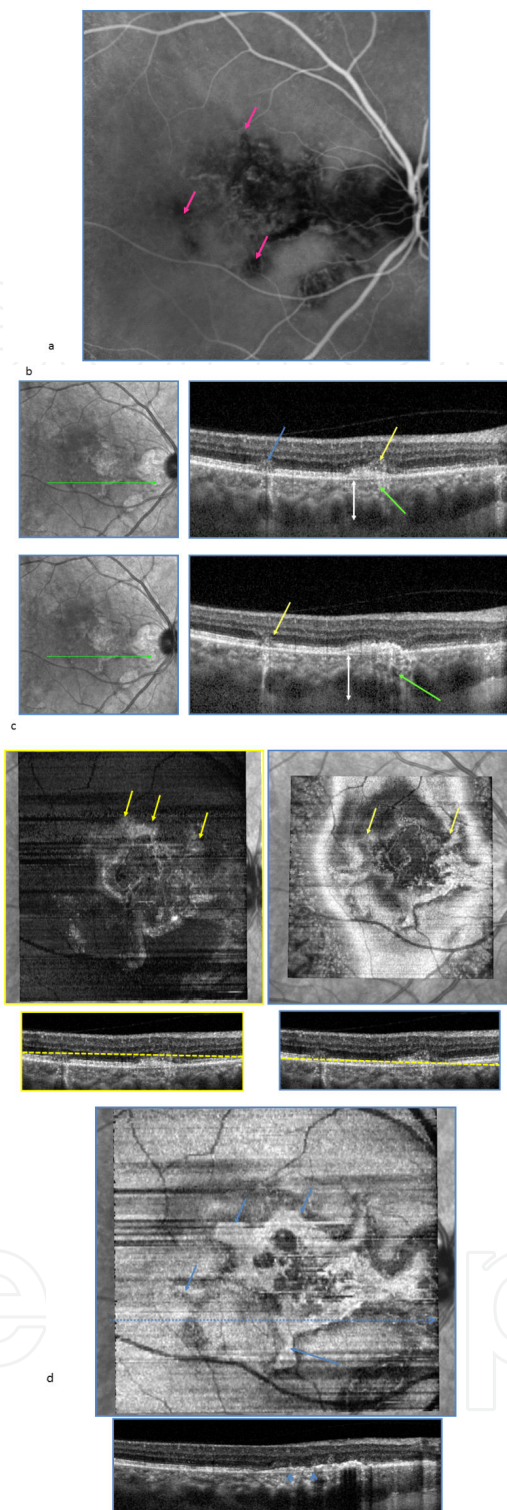
- On SD-OCT, in the active phase, hyperreflective lesions in the outer retinal layers can be observed, some extending to Henle's fibers layer. In the late stage, areas of irregular, thickened pigment epithelium are seen regarding a loss of structure in the external layers (IS/OS, Verhoeff's membrane) [11]. Many hyperreflective dots are present inside the choroid. Choroidal thickening is also seen on EDI.
- 'En-face' OCT confirms that the appearance of the network of digitations is due to outer retinal changes [12]. Active lesions are observed at the level of the ONL as branching mildly reflective lesions. In the late stage, hyperreflective digitations are seen at the level of the RPE and correspond to areas of thickened RPE.

#### **5. Punctuate inner choroiditis (PIC) and multifocal choroiditis and panuveitis (MCP) (figure 5)**

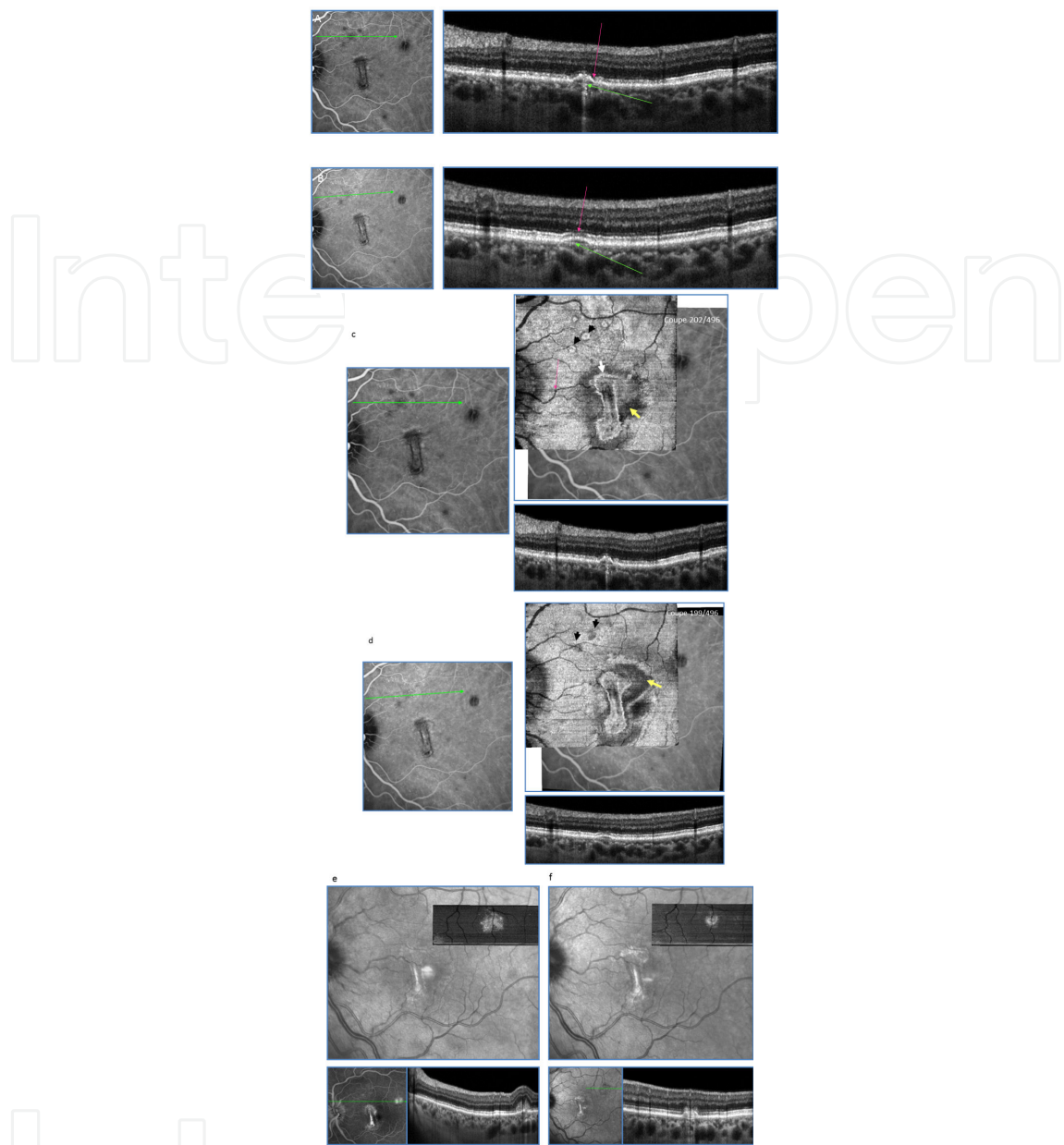
These two conditions share common characteristics: small, sharp lesions that evolve rapidly towards pigmented scars, affecting myopic females between 20 and 40 years of age. PIC differs from MCP by the absence of vitritis and the limitation of the lesions to the posterior fundus, while they can extend to the equatorial fundus in MCP [13]. FA is marked by a late hyperfluorescence. From mid-sequence on ICGA, the lesions appear hypofluorescent, and more numerous than on funduscopy.

- With SD-OCT, sections through a lesion show accumulation of drusenoid deposits between the pigment epithelium and Bruch's membrane [14]. Disruption of the IS/OS junction and RPE may be observed on the top of these elevations.





**Figure 4. SERPIGINOUS CHOROIDITIS.** a) Serpiginous choroiditis acute phase: ICGA. Hypo fluorescent digitations starting from the optic disc (pink arrows). b) Serpiginous choroiditis acute phase: SD-OCT (top and down) Hyperreflective lesions in the outer retinal layers, some extending to Henle’s fibers layer (yellow arrows). Numerous hyperreflective dots are present inside the choroid (green arrows). Choroidal thickening is seen on EDI (white double head arrow). c) Serpiginous choroiditis acute phase: Active lesions are observed at the level of the ONL (left) and IS/OS junction layer (right) as branching mildly reflective lesions (yellow arrows). d) Serpiginous choroiditis late phase: in the late stage, hyperreflective digitations are seen at the level of the RPE and correspond to areas of thickened RPE (blue arrows).



**Figure 5. CMF.**a) CMF acute phase: SD-OCT B-scan. Presence of deposits between the Bruch's membrane and RPE looking like fusiform, hyperreflective, small, dome shape elevations of the RPE (green arrows). An interruption of the IS/OS junction at the top of the dome shape elevation is also seen (pink arrow) b) CMF late phase: SD-OCT B-scan, Post treatment: the RPE elevation slowly and progressively decreases after treatment (green arrow) with the disappearance of the interruptions in the IS/OS junction (pink arrow). c) CMF acute phase: En Face OCT. Multiple, small, round or oval shaped hyperreflective lesions are seen in front of the RPE layer with a well defined hyporeflective centre and borders (black arrows).In the fovea, the hyperreflective CNV scar (with a hyperreflective border) is fibrous but still active (white arrow) with a hyporeflective area all around the scar corresponding to a serous retinal detachment(yellow arrow). d) CMF late phase: En Face OCT. Progressive disappearance of the outer retinal lesions which are faintly hyporeflective (black arrows). However, the CNV is still active (yellow arrow) e). Differentiation between CNV and choroiditis lesion. En face OCT, before anti-VEGF treatment: the moderately hyperreflective CNV has irregular edges. It corresponds on SD-OCT B-scan to the moderately hyperreflective pre- epithelial lesion associated with overlying retinal thickening. f). Differentiation between CNV and choroiditis lesion. En face OCT, after anti-VEGF treatment: the borders of the CNV become more hyperreflective and better defined.This corresponds on SD-OCT B-scan to an involuted CNV that has become more hyperreflective but still active (blurred limits in the superior part).

- In the macular area, 'en-face' OCT shows the presence of multiple hyperreflective lesions above the level of the pigment epithelium. These lesions often show mild central hyporeflectivity. Comparison of 'en-face' OCT with ICGA reveals that these highly reflective lesions and hypofluorescent dots on ICGA closely match. This correlation is also observed with SD-OCT B-scans.

During follow-up, these outer retinal lesions progressively regress on 'en-face' OCT, which is usually associated with functional recovery.

Both PIC and MCP are at high risk of neovascular complications.

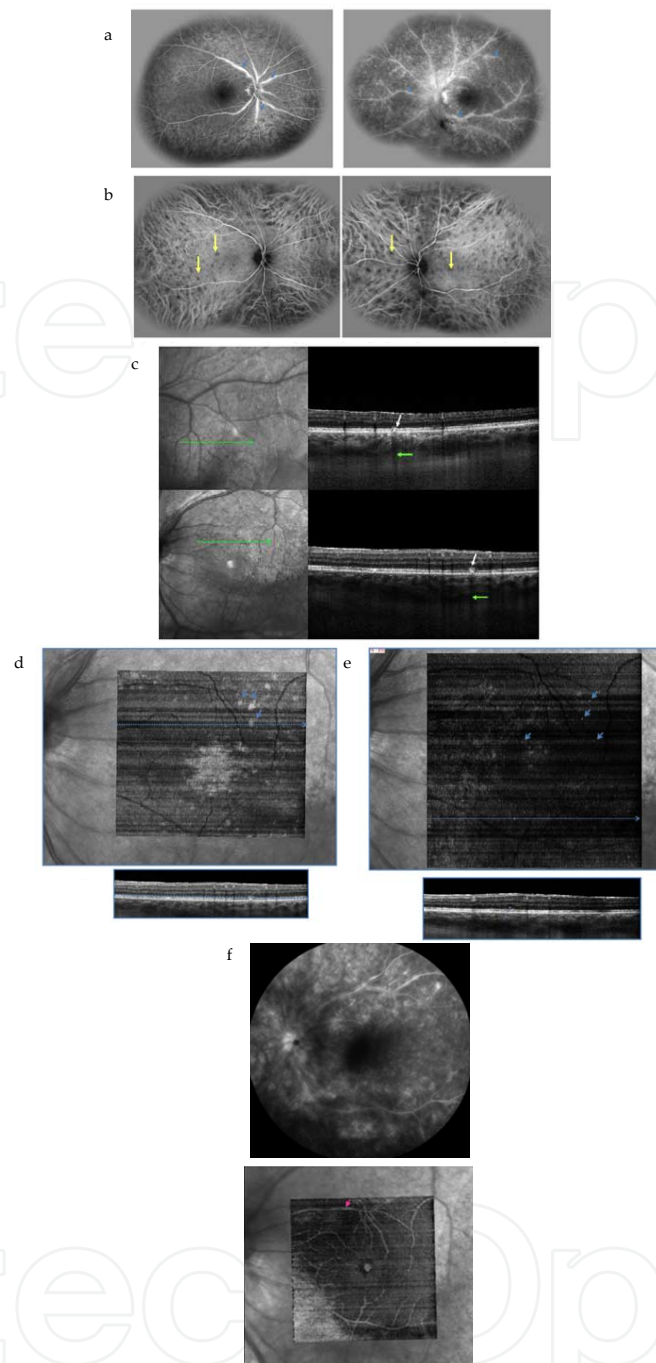
- When neovascularization occurs, a fusiform, hyperreflective thickening above the level of the pigment epithelium is seen on SD-OCT B-scans, and is usually associated with intraretinal cystoid exudative cavities [15].
- 'En-face' OCT imaging of this lesion, above the level of the pigment epithelium, reveals its irregular borders, thus distinguishing it from inflammatory lesions. 'En-face' OCT also allows analysis of all exudative cavities in one section, which is helpful for an improved, comparative follow-up.

This neovascularization can regress after repeated intravitreal anti-VEGF injections, providing that inflammation is sufficiently controlled.

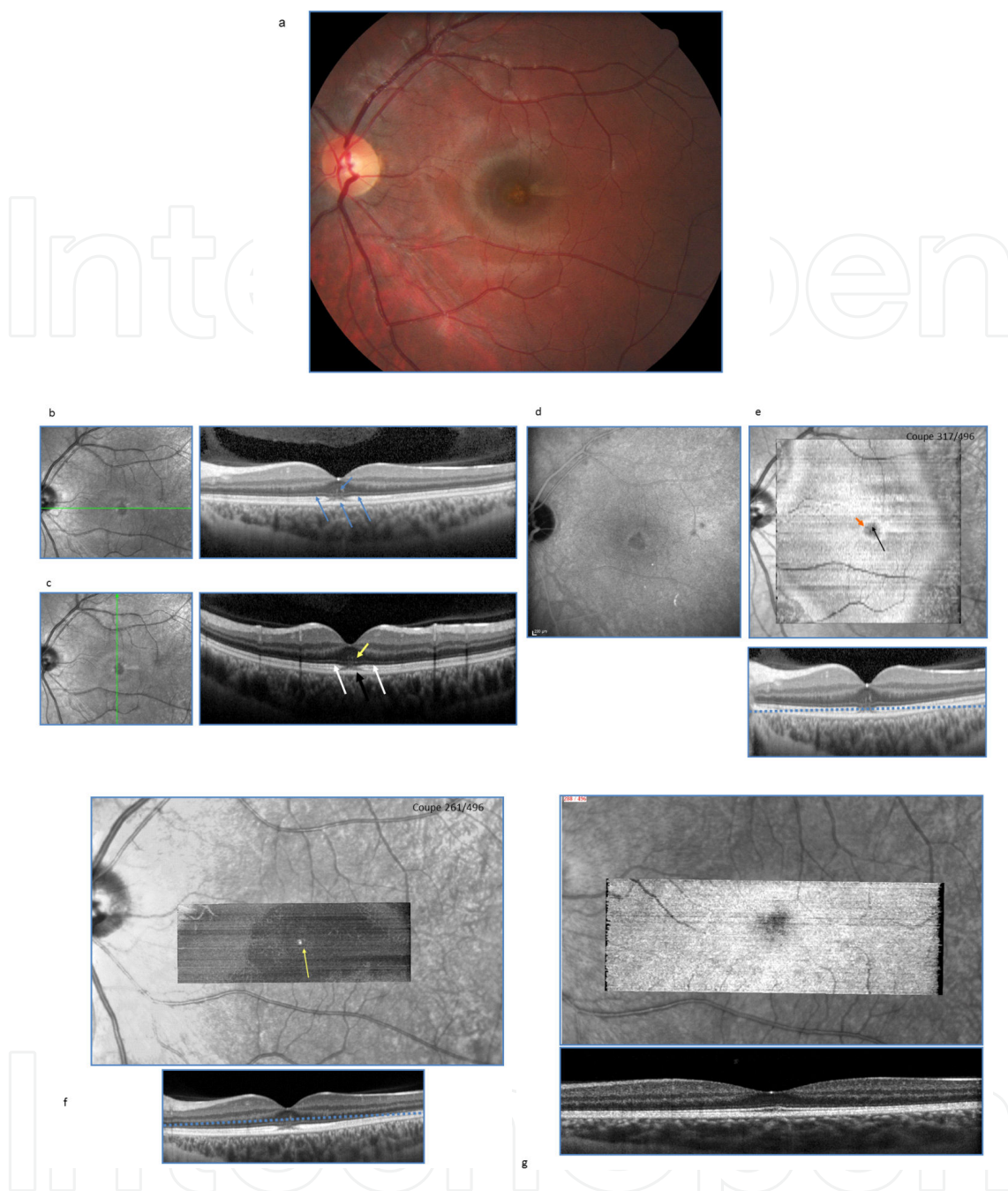
## 6. Birdshot chorioretinopathy (figure 6)

Birdshot chorioretinopathy is a slowly progressing, bilateral inflammation. It predominantly affects women and appears between 30 and 70 (mean age: 53) years. Association with HLA A29 is a common feature. Multiple hypopigmented choroidal lesions characterize the fundus [17]. FA is more useful in detecting complications (vasculitis, macular edema) than in analyzing the dots, for which ICGA is preferred. Indeed, they appear hypopigmented and often more numerous than on funduscopy.

- During active and severe phases, SD-OCT may identify drusenoid deposits between the pigment epithelium and IS/OS junction with a posterior shadow inside the choroid. Hyperreflective intraretinal dots, located in the outer nuclear layer (ONL) and corresponding to inflammatory deposits may be seen in acute phase. However, SD-OCT's main application for Birdshot chorioretinopathy is the screening for complications, mostly cystoid macular edema [18] or epiretinal membrane [19]. In the late phase, cases with poor control of inflammation (due to insufficient treatment or lack of response to appropriate therapy) evolve towards outer retinal atrophy, with IS/OS disruptions. SD-OCT is then an efficient tool to distinguish between these various causes of visual loss, and leads to appropriate treatment when needed [20].
- On 'en face' OCT, a hyperreflective border stretching along the retinal vessels and corresponding to vasculitis can be observed. Multiple hyperreflective dots can be seen inside the ONL. In acute and severe phases, mildly reflective lesions located above the RPE layer can be seen. The lesions match hypofluorescent lesions observed with ICGA.



**Figure 6. Birdshot chorioretinopathy.** a) Birdshot chorioretinopathy, active phase: marked retinal vasculitis observed on FA with dye leakage at the level of the vascular wall (blue arrows). b) Birdshot chorioretinopathy, active phase. ICGA: numerous hypofluorescent spots are visible scattered in the posterior pole and nasal to the optic nerve during all the angiography sequences (Yellow arrow). c) Birdshot chorioretinopathy, active phase. SD-OCT B-scan: small hyperreflective lesions (white arrows) are seen located inside the RPE behind the IS/OS and leading to a shadow cone (green arrow) at the choroidal level (drusenoid like deposits). d) En face OCT: Birdshot chorioretinopathy, severe clinical forms. Multiple hypermoderately hyperreflective spots are observed between the RPE and the IS/OS junction (blue arrows). e) Birdshot chorioretinopathy, active phase. En face OCT: small multiple hyperreflective spots are visualized in the outer nuclear layer (blue arrows). Corresponding b-scan in the bottom. f) Birdshot chorioretinopathy, active phase. Top: FA of a patient with moderate vasculitis. Bottom: « en face » OCT improves the visualization of vasculitis by the hyperreflective sheathing of the vascular wall (pink arrow).



**Figure 7. ARPE.** a) ARPE acute phase: Yellowish halo around the fovea on color fundus photography. b and c. ARPE acute phase, horizontal and vertical SD-OCT B-scan crossing the fovea: disruption of both the internal RPE layer and IS/OS junction in the fovea (black arrows). Small hyperreflective foveal deposits (yellow arrow) are seen at the level of the internal nuclear layer. A faint hyperreflective IS/OS segment thickening is visualized around the central disruption (white arrows). d) ARPE early phase. Late phase ICGA shows mild hyperreflective halo (cockade shape) in the fovea. e). ARPE early phase, En face OCT: scan at the IS/OS junction plane. Hyperreflective halo (cockade shape) is visualized surrounding the fovea that appears hyporefective (orange arrow). The halo corresponds to the faint hyperreflective thickening of the IS/OS junction around the hyporefective central zone corresponding to the central IS/OS junction disruption (black arrow). f) ARPE early phase, En face OCT. Punctuate hyperreflective foveolar spots corresponding to the central deposits found in the acute phase at the outer nuclear layer level (yellow arrow).g) ARPE late phase, SD-OCT B-scan (top) and En face OCT (down): return to normality with incomplete recovery of the central IS/OS junction disruption.

## 7. Acute retinal pigment epitheliitis (ARPE) (figure 7)

ARPE, or Krill's disease, named after its first description by Krill in 1974 [21], is a benign, self-limited, bilateral yet asymmetrical condition affecting adults between 10 and 40 years of age. Funduscopy identifies a yellowish halo around the fovea, without vitritis. ICGA is crucial to rule out a MEWDS that may have a similar presentation. It shows a typical, sharply demarcated, round, macular area [22].

- A subfoveal involvement with blurring of the inner pigment epithelium and IS/OS junction is visible on SD-OCT. Small hyperreflective deposits between the IS/OS junction and outer nuclear layer are identified in some cases. Around this disrupted foveal area, one can frequently observe IS/OS junction thickening.
- The extent of outer retinal damage, mainly at IS/OS level, is evidenced by 'en-face' OCT. The central lesion demonstrates a cockade-like appearance with a hyporeflective center and a hyperreflective border. This cockade appearance matches the pattern observed on ICGA. Punctuate, highly reflective, subfoveolar lesions, resolving within days, can also be observed. During follow-up, full resolution of all the abnormal findings occurs without treatment [22].

## 8. Conclusion

White dots syndromes refer to several disease that evolve quickly. Retinal and choroidal involvement follows different phases: invasive phase, intermediate phase and chronic phase. Retinal and choroidal changes observed with multimodal imaging are transient and may disappear quickly in some cases. All these entities probably share a common pathway leading to external retinal involvement. 'En face' OCT imaging enables the assessment of the extent of structural damage occurring in WDS. OCT with "en face" OCT enhances its sensitivity, allowing earlier diagnosis of retinal changes and a more reliable follow-up. Further prospective studies including more patients will be necessary to confirm these results.

## Author details

Benjamin Wolff\*, Alexandre Matet, Vivien Vasseur, José-Alain Sahel and Martine Mauget-Fajÿsse

\*Address all correspondence to: [bwolff@hotmail.fr](mailto:bwolff@hotmail.fr)

Professor Sahel Department, Rothschild Ophthalmologic Foundation, Paris, France

## References

- [1] Cohen SY, Dubois L, Quentel G, *et al.* Is indocyanine green angiography still relevant? *Retina* 2011;31:209–21.
- [2] Nguyen MHT, Witkin AJ, Reichel E, *et al.* Microstructural abnormalities in MEWDS demonstrated by ultrahigh resolution optical coherence tomography. *Retina* 2007;27:414–8.
- [3] Hangai M, Fujimoto M, Yoshimura N. Features and function of multiple evanescent white dot syndrome. *Arch Ophthalmol* 2009;127:1307–13.
- [4] Li D, Kishi S. Restored photoreceptor outer segment damage in multiple evanescent white dot syndrome. *Ophthalmology* 2009;116:762–70.
- [5] Fiore T, Iaccheri B, Androudi S, *et al.* Acute posterior multifocal placoid pigment epitheliopathy: outcome and visual prognosis. *Retina* 2009;29:994–1001.
- [6] Cheung CMG, Yeo IYS, Koh A. Photoreceptor changes in acute and resolved acute posterior multifocal placoid pigment epitheliopathy documented by spectral-domain optical coherence tomography. *Arch Ophthalmol* 2010;128:644–6.
- [7] Goldenberg D, Habet-Wilner Z, Loewenstein A, *et al.* Spectral domain optical coherence tomography classification of acute posterior multifocal placoid pigment epitheliopathy. *Retina*. 2012;32(7):1403-10.
- [8] Tarabishy AB, Lowder CY. Retinal pigment epithelium disturbances in acute posterior multifocal placoid pigment epitheliopathy. *Eye* 2010;24:1404–5.
- [9] Lim WK, Buggage RR, Nussenblatt RB. Serpiginous choroiditis. *Surv Ophthalmol* 2005;50:231–44.
- [10] Varma D, Anand S, Reddy AR, *et al.* Tuberculosis: an under-diagnosed aetiological agent in uveitis with an effective treatment. *Eye* 2006;20:1068–73.
- [11] Punjabi OS, Rich R, Davis JL, *et al.* Imaging serpiginous choroidopathy with spectral domain optical coherence tomography. *Ophthalmic Surg Lasers Imaging* 2008;39:S95–98.
- [12] van Velthoven MEJ, Ongkosuwito JV, Verbraak FD, *et al.* Combined en-face optical coherence tomography and confocal ophthalmoscopy findings in active multifocal and serpiginous chorioretinitis. *Am J Ophthalmol* 2006;141:972–5.
- [13] Kedhar SR, Thorne JE, Wittenberg S, *et al.* Multifocal choroiditis with panuveitis and punctate inner choroidopathy: comparison of clinical characteristics at presentation. *Retina* 2007;27:1174–9.
- [14] Spaide RF, Koizumi H, Freund KB. Photoreceptor outer segment abnormalities as a cause of blind spot enlargement in acute zonal occult outer retinopathy-complex diseases. *Am J Ophthalmol* 2008;146:111–20.

- [15] Vance SK, Khan S, Klancnik JM, *et al.* Characteristic spectral-domain optical coherence tomography findings of multifocal choroiditis. *Retina* 2011;31:717–23.
- [16] Julián K, Terrada C, Fardeau C, *et al.* Intravitreal bevacizumab as first local treatment for uveitis-related choroidal neovascularization: long-term results. *Acta Ophthalmol* 2011;89:179–84.
- [17] Shah KH, Levinson RD, Yu F, *et al.* Birdshot chorioretinopathy. *Surv Ophthalmol* 2005;50:519–41.
- [18] Monnet D, Levinson RD, Holland GN, *et al.* Longitudinal cohort study of patients with birdshot chorioretinopathy. III. Macular imaging at baseline. *Am J Ophthalmol* 2007;144:818–28.
- [19] Witkin AJ, Duker JS, Ko TH, *et al.* Ultrahigh Resolution Optical Coherence Tomography of Birdshot Retinochoroidopathy. *Br J Ophthalmol* 2005;89:1660–1.
- [20] Comander J, Loewenstein J, Sobrin L. Diagnostic testing and disease monitoring in birdshot chorioretinopathy. *Semin Ophthalmol* 2011;26:329–36.
- [21] Krill AE, Deutman AF. Acute retinal pigment epitheliitis. *Am J Ophthalmol* 1972;74:193–205.
- [22] Baillif S, Wolff B, Paoli V, *et al.* Retinal fluorescein and indocyanine green angiography and spectral-domain optical coherence tomography findings in acute retinal pigment epitheliitis. *Retina* 2011;31:1156–63.



