

We are IntechOpen, the world's leading publisher of Open Access books Built by scientists, for scientists

4,800

Open access books available

122,000

International authors and editors

135M

Downloads

Our authors are among the

154

Countries delivered to

TOP 1%

most cited scientists

12.2%

Contributors from top 500 universities



WEB OF SCIENCE™

Selection of our books indexed in the Book Citation Index
in Web of Science™ Core Collection (BKCI)

Interested in publishing with us?
Contact book.department@intechopen.com

Numbers displayed above are based on latest data collected.

For more information visit www.intechopen.com



Nocardiosis: Clinical and Pathological Aspects

Sharmila P. Patil, Nitin J. Nadkarni and Nidhi R. Sharma

Additional information is available at the end of the chapter

<http://dx.doi.org/10.5772/52376>

1. Introduction

1.1. Taxonomy and history

Nocardiosis is an opportunistic, localized or disseminated granulomatous infection caused by an aerobic actinomycete most commonly found in soil, decomposing vegetation, and other organic matter, as well as in fresh and salt water¹. Infection most commonly occurs through the respiratory tract. Manifestations of disease range from cutaneous infection caused by traumatic inoculation of the organism in a normal host to severe hematogenous spread to pulmonary or central nervous system (CNS) disease in an immunocompromised host².

Taxonomy of nocardia has undergone many revisions. Aerobic actinomycetes are bacteria belonging to the order Actinomycetales, *Nocardia* is a genus in the family Nocardiaceae. As Nocardiaceae branch into filaments they were misclassified as fungi. Like members of the genus *Mycobacterium*, the nocardiae contain tuberculostearic acids, but in contrast to mycobacteria, they also possess short-chain (40 to 60 carbon) mycolic acids and usually exhibit characteristic branching on Gram staining^{3,4,5,6}. More than 50 species have been identified by phenotypic and molecular methods. Originally referred to as *Nocardia asteroides* was later found to be a group of bacteria named *N asteroides* complex which was responsible for most of the human infections¹. On the basis of drug susceptibility patterns *N asteroides* complex was later separated into different species: *Nocardia abscessus*, *Nocardia brevicatena-paucivorans* complex, *Nocardia nova* complex, *Nocardia transvalensis* complex, *Nocardia farcinica* and *Nocardia asteroides*⁷. *Nocardia cyriacigeorgica* was recently differentiated from *N asteroides*⁸.

Some species are more prevalent in geographical locations with a specific climate. *Nocardia brasiliensis*, usually associated with cutaneous infection and mycetoma, is more commonly isolated in areas with tropical or subtropical climates and is often encountered in the southwestern or southeastern United States^{9,10}. Saubolle and Sussland recently reported that

nocardial infections in the United States seem to be more prevalent in the arid, warm climates of the southwest ¹¹.

The taxonomic history of the genus *Nocardia* is fraught with confusion and controversy. The organism initially placed in the genus *Nocardia* was isolated by veterinarian Edmond Nocard in 1888 from a case of bovine¹². One year later, Trevisan characterized the organism and named it *Nocardia farcinica*. Taxonomic studies by Gordon and Mihm in 1962 found no phenotypic differences between *Nocardia* strain and strains of isolates known as “*N. asteroides*”^{13,14}. Because of the uncertain taxonomic status of the *N. farcinica* type strain and because *N. asteroides* had become the most common designation of isolates of this genus, the name *N. asteroides* was chosen to replace *N. farcinica* as the type species of the genus *Nocardia*.

Nocardia exhibits varying degrees of acid-fastness, depending on the mycolic acid composition in the cell wall and type of stain used ³. The modified Kinyoun acid-fast stain uses 1% sulfuric acid as a decolorizer (instead of the more potent hydrochloric acid used in the decoloration step in the Ziehl- Neelsen staining procedure), which enhances the ability of *Nocardia* to retain the colored fuchsin¹⁵. Unlike mycobacteria, *Nocardia* has a “beaded” acid-fast appearance on microscopy. *Nocardia* can resemble *Actinomyces* species on Gram stain; however, *Actinomyces* species are not acid-fast and grow under anaerobic conditions¹.

2. Epidemiology

It has a universal distribution, affecting people mainly between 20-50 years of age ¹⁶. Males are more affected than females. Pathogenic species of *Nocardia* can be found in house dust, beach sand, garden soil, and swimming pools ¹⁵. Despite the occurrence of nocardiosis in many animals (e.g. cats, dogs, guinea pigs, and cattle), there is no evidence of respiratory spread from infected animals to humans¹⁷. There is also no evidence of person-to-person transmission. Patients with depressed cell-mediated immunity especially are at high risk for infection, including those with lymphoma, other malignancies, human immunodeficiency virus infection and solid-organ or hematopoietic stem cell transplant and those receiving long-term treatment with steroids or other immunosuppressive medications like azathioprine and cyclosporine^{18,19}. Among stem cell transplant patients, nocardiosis can develop at varying time periods, which range from 2 to 3 months to 1 to 2 years after transplant. Among solid organ transplant recipients, *Nocardia* infection has a frequency of 0.6% to 3% and has been well described in kidney, heart, and liver recipients^{20,21}. A case control study of 5126 solid organ transplant recipients, *Nocardia* infection was found highest among lung transplant recipients, followed by recipients of heart, small bowel, kidney, and liver transplants^{22,23,24}. Risk factors in these patients include the early rejection of grafts and intensive immunosuppressive therapy. Use of azathioprine and prednisone or high-dose prednisone alone may pose a greater risk of development of nocardiosis than combination therapy with cyclosporine and prednisone together^{25,26}.

With the comparatively recent advent of HIV infection, the incidence of nocardiosis has comparatively risen. It affects mainly rural more than the urban population and occurs in patients with CD4 T cell count less than 100 cells/ μ l. Such patients are more likely to develop pulmonary and extra pulmonary disease². Host resistance to nocardiosis depends on the number and phagocytic/lytic capability of the polymorphonuclear cells and the status of the cell mediated immunity. The last of this fails in AIDS patients and predisposes to severe forms of nocardiosis. However, low frequency of this complication in patients with advanced HIV can be attributed to sulphonamide therapy and the leading role of neutrophils in immune response to nocardia². Intravenous drug abusers can be predisposed to cutaneous nocardiosis since direct inoculation through injections sites can occur, leading to abscesses². Surgical wound infections due to *N. farcinica* has been described²⁷.

3. Microbiology

The genus *Nocardia* are branched gram-positive (Figure 1), variably acid-fast, strictly aerobic bacteria, as they age, they fragment into rod-shaped or coccoid elements¹⁵. Nocardiosis bacteria induces abscess and granulomatous response in the skin. In hematoxylin & Eosin staining of nocardiosis shows abscess (collection of neutrophils) and granules (grains) (Figure 2). Grains are closely aggregated with a peripheral radial deposition of intensely eosinophilic material – a Hoeppli – Splendore (HS) reaction (Figure 3a and 3b). H&E stains demonstrate the bacilli poorly. They are 1 micrometer diameter, gram positive, Grocott silver positive, usually positive with Zeihl Neelson stain, this differentiate nocardiosis from actinomyces and related bacilli. The Grocott silver method is the most sensitive screening stain for nocardiosis.

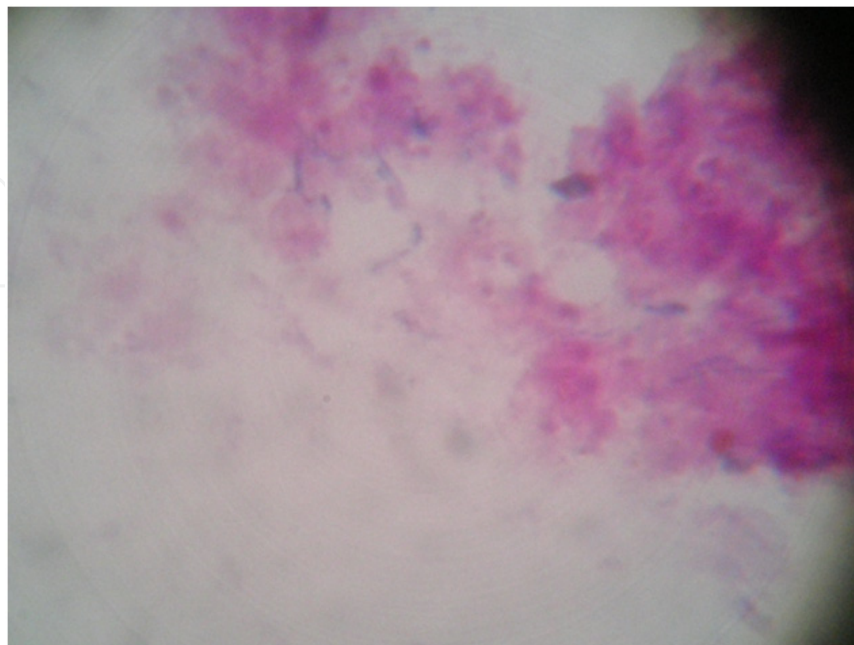


Figure 1. Gram positive filamentous bacteria showing branching, consistent with *N. brazilienses*

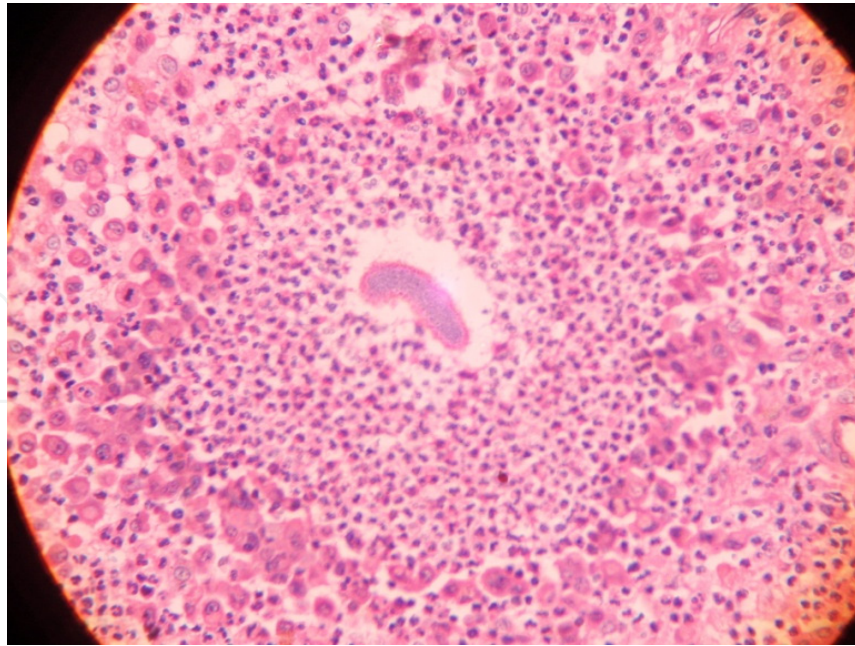


Figure 2. Histopathology of nocardiosis showing grains with neutrophils around it

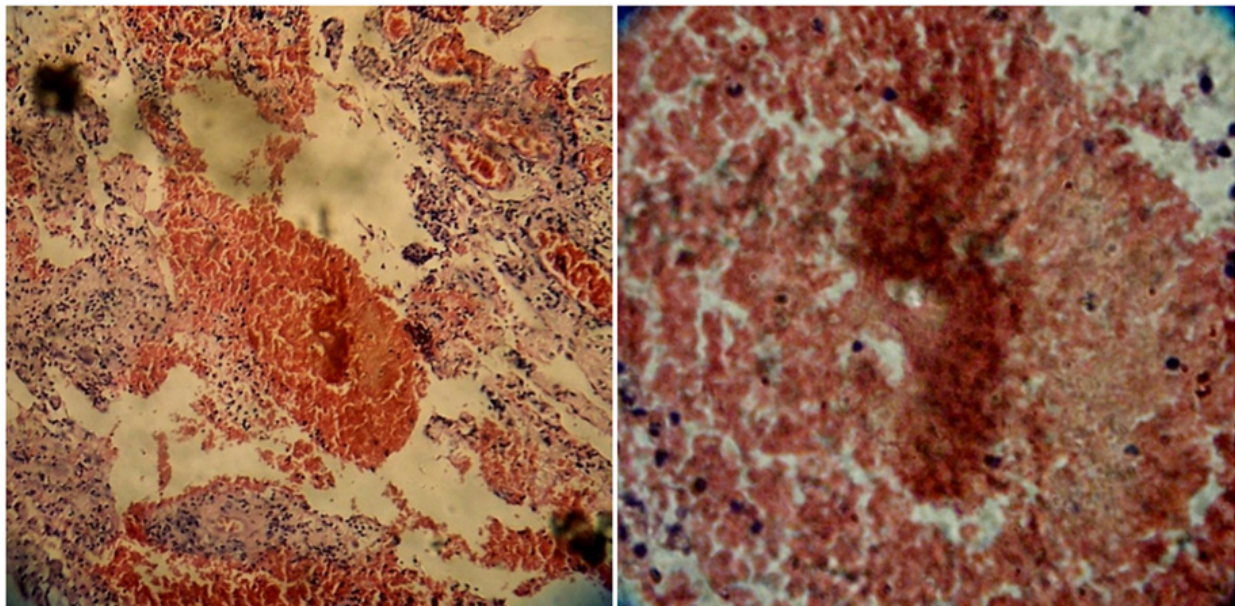


Figure 3. a. Histopathology of nocardiosis with inflammatory cells around it (10x)
b. 40x magnification showing irregularly staining granular structure surrounded by RBCs and necrotic tissue with few neutrophils disease

On blood agar, filamentous colonies have a chalky white or cotton-ball appearance. Unlike *Actinomadura*, and *Streptomyces* species the catalase-positive nocardiae grows in a nutrient broth. They grow readily over most of the simple media e.g. Sabouraud's glucose agar, blood agar, brain-heart infusion agar, and Lowenstein-Jensen agar¹⁵. More vigorous growth is achieved by adding 10% carbon dioxide. On agar, colonies are usually rough with velvety surface because of the aerial hyphae (Figure 4). Most of the primary isolates are white or light orange and have a characteristic moldy or earthy odour. Optimum temperature for

growth is 37°C but growth is slow and pure colonies are visible only after 48-72 hours of incubation. Before discarding, the culture should be observed for 2 weeks²⁸.

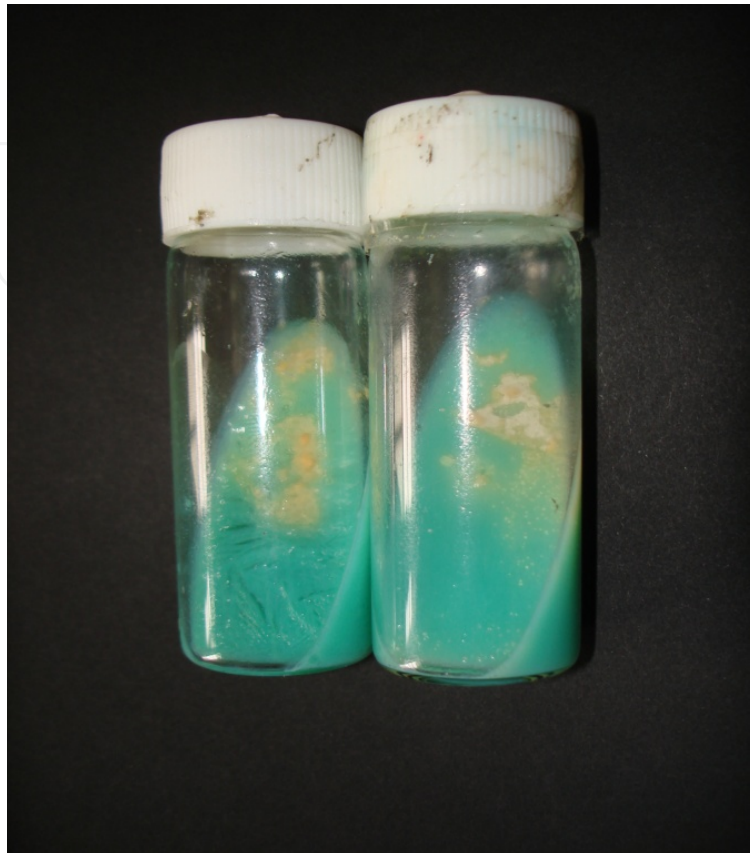

Figure 4. Powdery yellow colonies of *N. braziliensis* on LJ medium

Microscopic examination of gram-stained clinical specimens are thin, delicate, weakly to strongly gram-positive, irregularly stained or beaded branching filaments. A modified Ziehl-Neelsen stain, which decolorizes with 1% sulphuric acid instead of acid alcohol is the best technique for demonstrating nocardia¹⁷. There are multiple species, existing mainly in the soil, but human disease is mostly caused by *Nocardia asteroides* (so called because of star shaped colonies it produces in cultures). *Nocardia* are not visualized on hematoxylin and eosin stain of tissue or periodic acid-Schiff (PAS) stain for fungi. Methenamine silver preparations may reveal the organism in some instances. Routine blood cultures are not usually positive, but nocardia can be isolated from blood if biphasic blood culture systems are inoculated and incubated aerobically for up to 30 days^{15,17}. Blood specimens are processed by centrifugation. Exudate, joint, CSF specimen and homogenized tissue specimens should be inoculated directly into media such as thioglycollate broth, trypticase soy broth or chopped-meat glucose broth. Serological methods including hemagglutination, precipitin, and complement-fixing antibody testing have a limited value because of a high degree of shared antigens and serological cross-reactivity among the heterogeneous pathogenic *Nocardia* species and other actinomycetes, especially *Rhodococcus*, *Streptomyces*, and *Corynebacterium* species²⁹.

Other Biochemical and molecular methods: DNA probing, PCR, PCR-RFLP. PCR analysis of 16S rDNA is a useful tool to identify the species of nocardia. The application of this method has enabled the identification of nocardia in pathological specimens. It usually takes about 2 weeks for microbiological isolation and antibiotic susceptibility tests in cases of nocardiosis, but real-time PCR analysis of 16S rDNA can be completed in a few hours. This is relatively rapid, because amplification is carried out in capillary glass tubes, which are used only in the lightcycler instrument.

In RFLP analysis, the DNA sample is broken into pieces (digested) by restriction enzymes and the resulting *restriction fragments* are separated according to their lengths by gel electrophoresis. RFLP methodologies are a means for the rapid and accurate identification of clinical isolates of *Nocardia* species and far surpass the conventional biochemical methods in their discriminatory capabilities.

4. Pathogenesis

After entry of the organism response begins in the reticuloendothelial system with early mobilization of neutrophils, thus limiting the spread of infection³⁰. Later cell mediated immunity comes into a role and is triggered by activated macrophages, T cell population which causes direct lymphocyte-mediated toxicity to the organism. The interactions of phagocytic cells with nocardia depends on the virulence of the strain and with the growth phase of the nocardial cells. Virulent nocardia is attributed to complex cell wall glycolipids which inhibits phagosome - lysosome fusion and decreases lysosomal enzyme activity in macrophages, neutralizes phagosomal acidification, and even resists the oxidative killing mechanisms of phagocytes. In chronic granulomatous disease, neutrophils and macrophages fail to generate a burst of oxidative metabolism during phagocytosis, thus impairing the intracellular killing of catalase- positive bacteria such as *Nocardia* species³⁰. The host must ultimately mount a lymphocyte response and subsequently release antibody and/or lymphocyte signals enabling the phagocytic cells to kill *N asteroides*. Immune T cells effectively clear *Nocardia* species organisms from the lung and prevent extrapulmonary dissemination. Neutrophils predominate in the early lesions of nocardiosis, and infection progresses unless antimicrobial agents are given or CMI takes over.

5. Clinical features

5.1. Lung

Pulmonary nocardiosis is the most common clinical presentation of infection because inhalation is the primary route of bacterial exposure¹⁷. Occasionally the gastrointestinal tract is penetrated, especially the appendix³¹. Rarely, pulmonary infection follows a dental or periodontal infection due to ingestion of contaminated food or raw vegetable material. Infection occurs in persons of all ages, even neonates. Men are affected three times as commonly as women¹⁷. Patients on immunosuppressive drugs, chronic granulomatous disease^{32,33,34}, chronic alcoholism, diabetes mellitus, and human immunodeficiency virus

infection are also more susceptible to pulmonary infections with *Nocardia*. The onset of symptoms may be acute, subacute or chronic and untreated pulmonary nocardiosis can have several features similar to tuberculosis, including fever, weight loss, nonproductive cough, anorexia, night sweats, dyspnea, hemoptysis. Acute forms are particularly seen in the compromised host.

Patients can exhibit pneumonia, abscess formation, bronchopneumonia, total consolidation (lobar or even multilobar), pleural involvement or even empyema which has been seen in up to 25% of cases.

Pleural thickening or effusion can be seen radiologically. Pleural effusions can develop in up to one-third of patients. It can be very difficult clinically and radiographically to differentiate *Nocardia* from filamentous fungi (eg, aspergillosis, mucormycosis) or mycobacterial disease¹⁷. Chronic long standing lung lesions can lead to sinus formation. Chest X ray can also show cavitation, consolidation, abscess formation or even miliary lesions. Rarely, *Nocardia* species organisms invade preexisting lung cavities, producing a "fungus ball" appearance.

Tissues usually exhibit a mixed cellular response with polymorphonuclear leukocytes, macrophages, and lymphocytes. However, on occasion, tissue sections reveal a granulomatous reaction with central necrosis.

Other uncommon features include tracheitis, bronchitis, pleuropulmonary fistula, mediastinitis with superior vena cava syndrome and sinusitis.

6. Cutaneous involvement

Primary cutaneous and soft tissue nocardiosis can result from traumatic injury to the skin that involves contamination with soil³⁵. It can be clinically evident or self limiting. Many cases go underdiagnosed as gram stains and culture are not routinely done for most superficial skin infections. After skin inoculation, a superficial abscess, localized cellulitis, pustules, pyoderma, ulcerations or paronychia can develop healing with variable scarring (Figure 5a and 5b).

Cutaneous nocardiosis can resemble indolent soft tissue infections as caused by *Staphylococcus aureus* or streptococci. The infection can spread to the regional lymph nodes and produce a single or linear chain of nodular lesions resembling sporotrichosis. This lymphocutaneous nocardiosis is often called *sporotrichoid nocardiosis*. In more advanced cases, a mycetoma with a sinus tract development can occur. Mycetoma is a chronic, granulomatous, subcutaneous tissue infection caused by both bacteria (actinomycetoma) and fungi (eumycetoma). This chronic infection was termed Madura foot and eventually mycetoma, owing to its etiology. The hallmark triad of the disease includes tumefaction, fistulization of the abscess and extrusion of colored grains. The color of these extruded grains in the active phase of the disease offers a clue to diagnosis. The "dot-in-circle" sign has recently been proposed as a highly specific magnetic resonance imaging (MRI) and

ultrasonography (USG) sign of mycetoma, which may allow a noninvasive as well as early diagnosis. At least half of the mycetomas are caused by aerobic actinomycetes, mostly *Nocardia* species, whereas members of the genus *Actinomadura* are frequently recorded only in certain geographic locations¹⁵. *N. brasiliensis* is the most frequently recognized cause *Nocardia* induced mycetomas, but *N. asteroides*, *N. otitidiscaviarum*, and *N. transvalensis* can also be etiologic organisms.

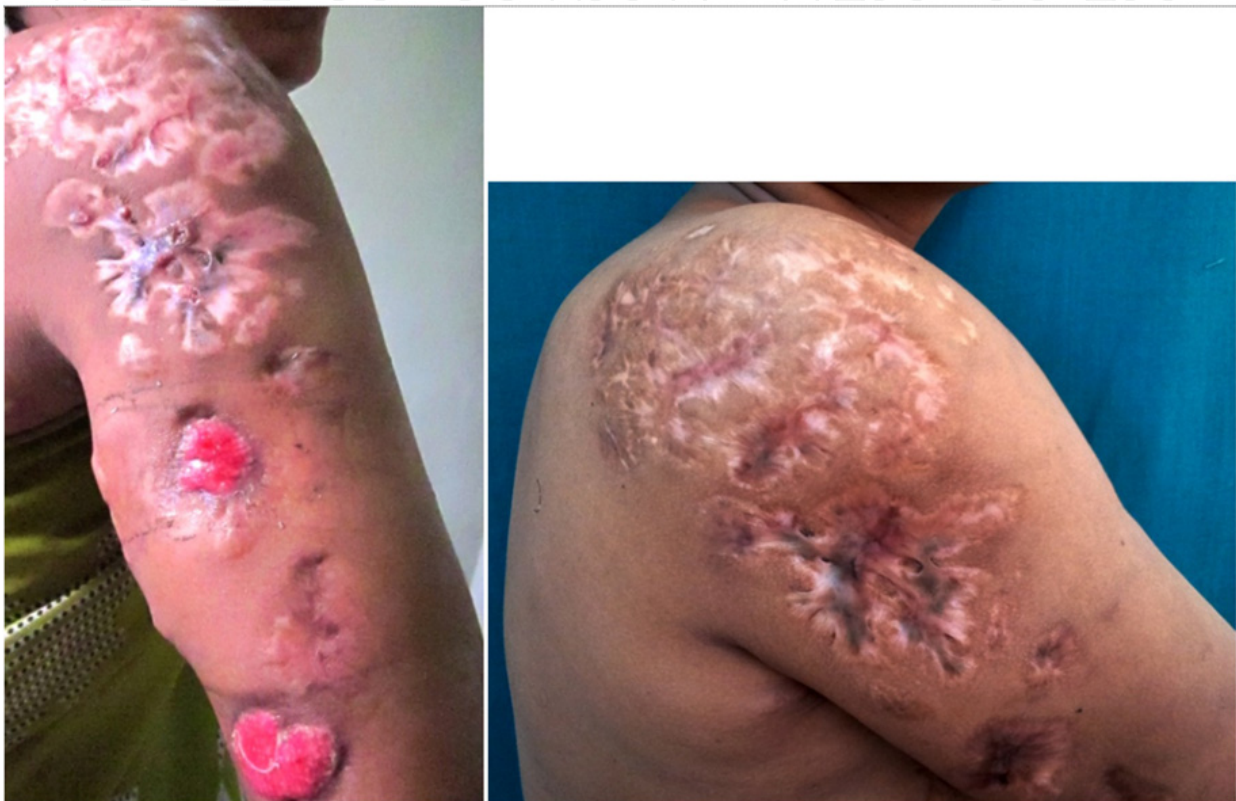

Figure 5. a. Primary cutaneous nocardiosis with ulcerated lesions and scarring
b. Photograph of the same patient with all lesions healing with scarring

Cutaneous nocardiosis is characterized by one of two manifestations: primary cutaneous infection or disseminated infection with skin involvement. The two forms have different microbiological, clinical and prognostic features which is illustrated in table number 1³⁶.

Nocardia bacteremia is not occasionally present but if occurs it can lead to infection in the eyes (keratitis), heart valves, liver, spleen, adrenal glands, thyroid gland, and other organ tissues. In a review of *Nocardia* bacteremia done in USA, 64% patients had concurrent pulmonary nocardiosis, 28% had concurrent cutaneous disease, and 19% had concurrent CNS disease and poor outcomes are correlated with acute onset of nocardiosis (duration less than 1 month), late identification of nocardia, involvement of more than 2 sites and lack of proper treatment.

Post traumatic keratitis and endophthalmitis with compound-fracture infection or poststernotomy mediastinitis and postoperative nosocomial *N. farcinica* wound infections following cardiac, blood vessel, or transplantation surgery have recently been described.

Rarely, *Nocardia* species organisms can be inoculated directly into the bloodstream during iv drug abuse or accidentally into a vein, producing local septic thrombophlebitis.

7. Systemic involvement

The most common sites for dissemination include the CNS (brain), skin and subcutaneous tissues, eyes (especially the retina), kidneys, joints, bones, and the heart. Unlike the primary pulmonary infection, lesions of disseminated or systemic nocardiosis progress unless treated. Self-limited or subclinical disease is not recognized frequently, although some CNS infections may evolve slowly over a period of many months or even years.

CNS – Central nervous system involvement is a well-described complication of nocardial infection³⁶. Most reviews of this problem have focused on nocardial brain abscess, whose typical clinical presentation is an intracranial space-occupying lesion. Recently, *Nocardia* has been cited as a cause of persistent neutrophilic pleocytosis resembling other subacute or chronic forms of meningitis in its clinical presentation and CSF findings. In a typical case of pyogenic brain abscess, headache is clearly the most common presenting complaint. The nature of the headache is characterized by dull aching that is poorly localized. Depression, schizophrenia, dyslexia and amnesia have also been recorded³⁷.

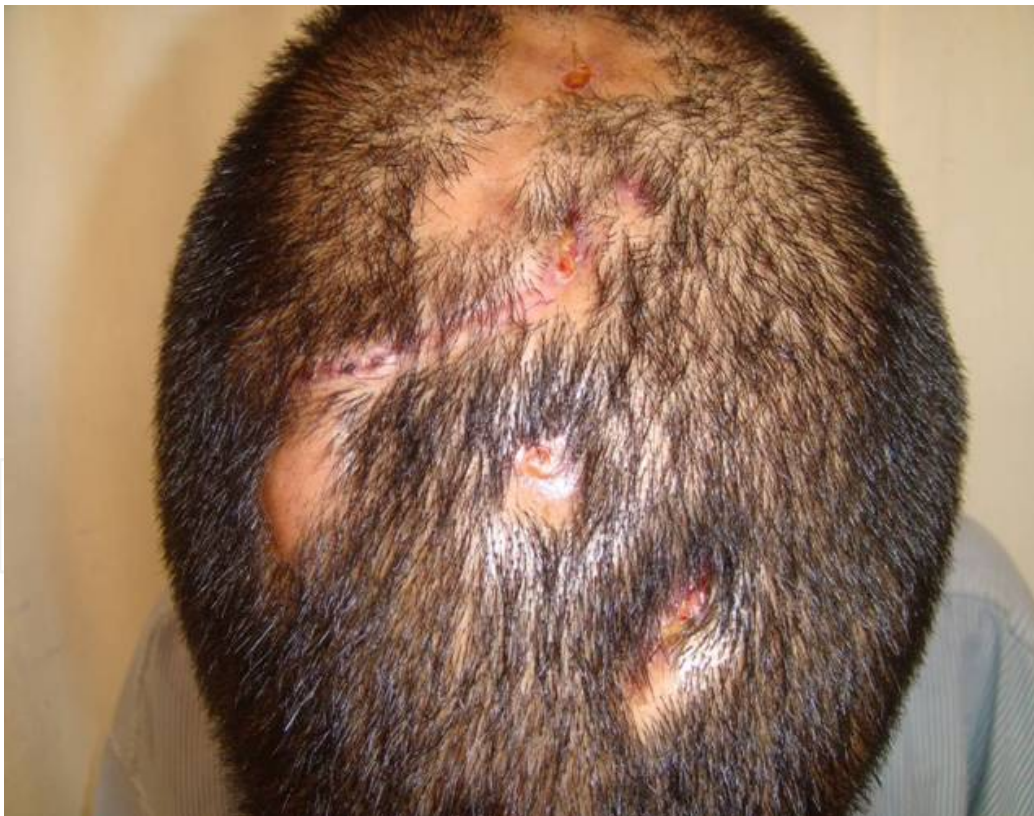

Figure 6. Primary cutaneous nocardiosis with cranial and cerebral extension

The most common source of microbial infection remains direct or indirect cranial infection (Figure 6) arising from the paranasal otogenic brain sinuses, middle ear, and teeth. Seeding

of the brain presumably occurs via transit of infecting bacteria through the valveless organ transplant. Although dental and sinus infections remain an important source of brain abscess. The typical presentation was subacute to chronic meningitis characterized by fever, stiff neck, and headache. CSF studies revealed neutrophilic pleocytosis, hypoglycorrhachia, and elevated protein level. CT and MRI scanning can help in diagnosis and management of brain abscess. CT scan with intravenous contrast of the brain with abscess will demonstrate ring-enhancing lesion. Needle aspiration or biopsy of a cerebral mass is not confirmatory for the diagnosis.

Cerebral nocardiosis commonly accompanies pulmonary disease, but isolated CNS disease may occur. In immunocompetent patients, cerebral nocardiosis is less common and may resemble a brain tumor or vascular infarct^{38,39}. Central nervous system imaging should be considered for patients with any adverse neurologic symptoms, severe pulmonary nocardiosis, or significant immunosuppression.

Other systemic involvement includes peritonitis, epididymo-orchitis, iliopsoas, ischioanal and perirectal abscess, hematogenous endophthalmitis and retinitis, pericarditis, endocarditis, aortitis, septic arthritis and bursitis, peritonitis in chronic peritoneal dialysis, osteomyelitis, and a disseminated miliary picture with diffuse organ abscesses.

Eye involvement like retinal infection or endophthalmitis, keratoconjunctivitis can occur.

8. Nocardiosis and HIV

Systemic *Nocardia* infections occur more frequently in immunocompromised patients. *Nocardia* species is recognized as an opportunistic pathogen for patients with impaired host defense mechanisms.

Lymphoreticular malignancies, organ transplantation, corticosteroid or other immunosuppressive therapy, and underlying pulmonary disease are important predisposing factors^{40,41,42}. Uttamchandani et al. found a strong association of *Nocardia* infection with injection drug use⁴³. Nocardiosis occurred among patients with advanced HIV disease. The clinical features of nocardiosis in these HIV-infected patients were similar to those described in other immunocompromised patients. The duration of illness was typically chronic, and the signs and symptoms reflected the sites involved. The lung was the most commonly affected site. The chest radiographic features were variable and not specific for nocardiosis. The diagnosis of nocardiosis is often delayed because none of the clinical, laboratory or radiographic features are pathognomonic. The diagnosis therefore relies on the isolation of *Nocardia* species, which can be difficult, particularly when the specimens are contaminated with other microorganisms. Nocardiosis caused or contributed to the death of two thirds of the patients. The high fatality rate could be attributed to three factors: dissemination of the infection due to delayed institution of therapy, relapse of nocardiosis due to discontinuation of treatment, and severe immune dysfunction of the host.

9. Treatment

Sulfonamides, including sulfadiazine and sulfisoxazole, have been the antimicrobials of choice to treat nocardiosis for the past 50 years despite bacteriostatic activity⁴⁴. Sulfadiazine can induce oliguria, azotemia, and crystalluria in patients who fail to maintain a high fluid intake. This complication can be prevented by alkalinizing the urine with oral sodium bicarbonate. Sulfisoxazole is equally effective and much less likely to cause oliguria.

Trimethoprim-sulfamethoxazole (TMP-SMZ) is now most frequently used to treat this infection. Divided doses of 5 to 10 mg/kg per day of the trimethoprim component or 25 to 50 mg/kg per day of sulfamethoxazole are recommended to produce sulfonamide serum concentrations between 100 and 150 g/mL. Adverse reactions to high-dose TMP-SMX therapy are frequent and include myelosuppression, hepatotoxicity, and renal insufficiency. Trimethoprim-sulfamethoxazole is active against most *Nocardia* species; however, *N. otitidiscaviarum* is commonly resistant to TMP-SMX⁴³. 90%-95% of pleuropulmonary infections respond favourably. However, in patients with disseminated disease, especially of the CNS, and/or patients with depressed CMI, certain factors may complicate the picture. Most important is the frequent occurrence of side effects in HIV-infected persons or organ transplant recipients: 44%-80% experience fever, skin rash, and/or neutropenia. HIV-infected patients require long-term maintenance suppressive therapy and are particularly intolerant of the TMP-SMZ combination, manifesting severe hypersensitivity reactions, hepatotoxicity, and/or prolonged myelosuppression. In organ transplantation patients treated with the anti rejection medication cyclosporine, TMP-SMZ may cause reversible cyclosporine-induced nephrotoxicity. Daily TMP-SMX prophylaxis most reliably prevents nocardiosis compared to intermittent therapy with oral TMP-SMX (2 double-strength tablets twice weekly or 1 single strength tablet 3 times weekly)⁴⁵. Non immunosuppressed patients with pulmonary or systemic nocardiosis (excluding CNS involvement) should be treated for a minimum of 6-12 months and those with CNS infection should be treated for 12 months. In one study of the efficacy of TMP-SMZ, relapse occurred rarely when patients received therapy for > 3 months⁴⁶. Parenteral therapy need not be continued beyond a period of 3-6 weeks, as determined by response in individual patients.

Alternatives to sulfonamides include amikacin, imipenem, meropenem, ceftriaxone, cefotaxime, minocycline, moxifloxacin, levofloxacin, linezolid, tigecycline, and amoxicillin - clavulanic acid^{47,48}.

Linezolid is an oxazolidinone that has activity against most gram-positive bacteria, including in vitro activity against all *Nocardia* species and strains^{49,50}. Linezolid binds to a site on the bacterial 23S rRNA of the 50S subunit and prevents the formation of a functional 70S-initiation complex, which is an essential component of the bacterial translation process. Dose is 600 mg orally or iv twice daily. CNS nocardiosis is associated with significant morbidity and mortality. A number of recent reports have highlighted the excellent penetration of the CSF by linezolid after intravenous administration of the drug every 12 h.

Tigecycline, a glycylicycline, appears to be active in vitro against most *Nocardia* species. Of the fluoroquinolones, moxifloxacin is fairly active in vitro against *asteroides* complex.

Combination therapy with imipenem and cefotaxime, amikacin and TMP-SMX, imipenem and TMP-SMX, amikacin and cefotaxime, or amikacin and imipenem may provide enhanced activity. Alternative oral drug therapy for nocardial infections theoretically might include dapsone because its mechanism of action (folate antagonism) is identical to that of the sulphonamides.

Surgical intervention can be advised for the drainage or excision of abscesses or an empyema.

	Primary Cutaneous	Disseminated with skin Involvement
Species	<i>N. brasiliensis</i>	<i>N. asteroides</i>
Risk Factors	Local trauma related to plants And soil	Immunosuppression
Primay site	Skin	Lung
Skin manifestations	Acute: Lymphocutaneous Superficial skin infections Chronic : Mycetoma	Pustules Nodules Abscesses
Diagnosis	Direct Smear: Gram and acid fast stainin. Culture: Standard or Special media. Biochemical and molecular methods: DNA probing, PCR, PCR-RFLP, Gene sequencing, ribotyping	
Treatment	TMP-SMX; alternatives are amikacin, minocycline, imipenem, 3 rd generation cephalosporins, linezolid	
Duration of treatment	Lymphocutaneous/ superficial: 2-4 months Mycetoma: 12 months	No CNS involvement or immuno- Suppression: 6-12 months CNS involvement or immuno- Suppression: 12 months
Prognosis	Good but can recur	Poor, mortality rate 44-85%

Table 1. PCR: polymerase chain reaction. RFLP- fragment length polymorphism, TMP-SMZ_X trimethoprim- sulphomethoxazole

10. Conclusion

The spectrum of subcutaneous and deep mycoses is a very wide one. Of these, nocardiosis is becoming increasingly important especially in the era of HIV infections. Nocardiosis can present in diverse clinical manifestations, including cutaneous nodules, ulcerations,

subcutaneous abscesses, pyoderma like lesions, lymphangitis (sporotrichoid pattern), mycetoma like lesions. Moreover, the systemic spectrum of nocardiosis is also wide, including, pulmonary, central nervous system, eye, bone, and solid organs. Hence, unless a high index of suspicion is kept, nocardiosis can be either underdiagnosed or misdiagnosed. The usual diagnostic methods are histopathology and culture, though the gold standard remains PCR. Clinico pathological correlation is important for diagnosis. The treatment of nocardiosis essentially involves long term administration of chemotherapeutic agents like sulphonamides, cotrimoxazole, linezolid and amikacin. Early initiation of chemotherapy can avoid surgical excision which may be required in late or complicated cases.

Author details

Sharmila P. Patil, Nitin J. Nadkarni and Nidhi R. Sharma
Dr. D.Y.Patil Medical College, Nerul, Navi Mumbai, Maharashtra, India

Acknowledgement

Acknowledgement to Dr. Vishalakshi Vishwanath, Head of department, Rajiv Gandhi Medical College and Hospital, Thane, Mumbai for histopathology photographs of Nocardiosis no. 6a and 6b.

11. References

- [1] Wilson JW .Nocardiosis: Updates and Clinical Overview. *Mayo Clin Proc.* 2012;87:403-407.
- [2] Corti ME, Fiotti, MFV. Nocardiosis: A review. *Int J Infect Dis* 2003;7: 243-250 .
- [3] Brown-Elliott BA et al. Clinical and Laboratory Features of the *Nocardia* spp. Based on Current Molecular Taxonomy. *Clin Microbiol Rev.* 2006;19: 259–282 .
- [4] Goodfellow, M., and T. Pirouz.. Numerical classification of sporoactinomycetes containing meso-diaminopimelic acid in the cell wall. *J. Gen. Microbiol.*1982; 128:503-507 .
- [5] Mordarska, H., M. Mordarski, and M. Goodfellow. Chemotaxonomic characters and classification of some nocardioform bacteria. *J. Gen. Microbiol.*1972; 71:77-86.
- [6] Pijper, A., and B. D. Pullinger. South African nocardioses. *J. Trop. Med. Hyg.* 1972; 30:153-156.
- [7] Wallace RJ Jr, Steele LC, Sumter G, Smith JM. Antimicrobial susceptibility patterns of *Nocardia asteroides*. *Antimicrob Agents Chemother.* 1988;32:1776-1779.
- [8] Schlager R, Huard RC, Della-Latta P. *Nocardia cyriacigeorgica*, an emerging pathogen in the United States. *J Clin Microbiol.* 2008;46:265-273.
- [9] Fergie, J. E., and K. Purcell. Nocardiosis in south Texas children. *Pediatr. Infect. Dis. J.* 2001; 20:711-714

- [10] Wallace RJ, Jr., Brown BA, Blacklock Z, Ulrich R, Jost K et al . New *Nocardia* taxon among isolates of *Nocardia brasiliensis* associated with invasive disease. *J. Clin. Microbiol.*1995; 33:1528-1533
- [11] Saubolle MA, and Sussland D. Nocardiosis: review of clinical and laboratory experience. *J. Clin. Microbiol.*2003;41:4497-4501.
- [12] Nocard E. Note sur la maladie des boeufs de la Gouadeloupe connue sous le nom de farcin. *Ann. Inst. Pasteur* 1888; 2:293-302.
- [13] Gordon, R. E., and J. M. Mihm. A comparative study of some strains received as nocardiae. *J. Bacteriol.* 1957; 73:15-27.
- [14] Gordon, R. E., and J. M. Mihm. The type species of the genus *Nocardia*. *J. Gen. Microbiol.* 1962;27:1-10.
- [15] McNeil MM, Brown JM. The medically important aerobic actinomycetes: epidemiology and microbiology. *Clin Microbiol Rev.* 1994;7:357-417.
- [16] Reed RC. Nocardiosis and actinomycosis. *Medicine* 2005;33: 114-115
- [17] Lerner PI. *Nocardia* species, in Manedll GL, Douglas RG Jr., Bennett GE, editors: Principles and practice of infectious diseases, New York, 1985, John Wiley & Sons, Inc. pp 1423-1427
- [18] Young LS, Rubin RH. Mycobacterial and nocardial diseases in the compromised host. In: Rubin RH, Young LS, eds. *A Clinical Approach to Infection in the Compromised Host*. 4th ed. New York, NY: Kluwer Academic; 2002:257-261.
- [19] Long PF. A retrospective study of *Nocardia* infections associated with the acquired immune deficiency syndrome (AIDS). *Infection.* 1994;22:362-364
- [20] Choucino C, Goodman SA, Greer JP, Stein RS, Wolff SN, Dummer JS. Nocardial infections in bone marrow transplant recipients. *Clin Infect Dis.* 1996;23:1012-1019.
- [21] Van Burik JA, Hackman RC, Nadeem SQ, et al. Nocardiosis after bone marrow transplantation: a retrospective study. *Clin Infect Dis.* 1997;24:1154-1160.
- [22] Forbes GM, Harvey FA, Philpott-Howard JN, et al. Nocardiosis in liver transplantation: variation in presentation, diagnosis and therapy. *J Infect.* 1990;20:11-19.
- [23] Wilson JP, Turner HR, Kirchner KA, Chapman SW. Nocardial infections in renal transplant recipients. *Medicine (Baltimore).* 1989;68:38-57.
- [24] Peleg AY, Husain S, Qureshi ZA, et al. Risk factors, clinical characteristics, and outcome of *Nocardia* infection in organ transplant recipients: a matched case-control study. *Clin Infect Dis.* 2007;44:1307-1314.
- [25] Arduino RC, Johnson PC, Miranda AG. Nocardiosis in renal transplant recipients undergoing immunosuppression with cyclosporine. *Clin Infect Dis.* 1993;16:505-512.
- [26] Roberts SA, Franklin JC, Mijch A, Spelman D. *Nocardia* infection in heart-lung transplant recipients at Alfred Hospital, Melbourne, Australia, 1989-1998. *Clin Infect Dis.* 2000;31:968-972.
- [27] Blumel J, Blumel E, Yasin AF, Schmidt-Rotte H, Sehaal KP. Typing of *Nocardia farcinica* by pulse field gel electrophoresis and randomly amplified polymorphic DNA PCR. *J Clin Microbiol* 1998; 36: 118-122
- [28] Curry WA. Human nocardiosis. A clinical review with selected case reports. *Arch Intern Med* 1980; 140: 818-826

- [29] Beaman BL, Boiron P, Beaman L, Brownell GH, Schaal K, Gombert ME. Nocardia and nocardiosis. *J Med Vet Mycol* 1992; 30(suppl1):317-31.
- [30] Beaman BL, Beaman L. Nocardia species: host-parasite relationships. *Clin Microbiol Rev* 1994;7:213-64.
- [31] Lerner PI. Nocardiosis. State-of-the-art clinical article. *Clin Infect Dis* .1996; 22:891-903
- [32] Chapman, S. W., and J. P. Wilson. 1990. Nocardiosis in transplant recipients. *Semin. Respir. Infect.* 5:74-79.
- [33] Jonsson, S., R. J. Wallace, Jr., S. I. Hull, and D. M. Musher. 1986. Recurrent Nocardia pneumonia in an adult with chronic granulomatous disease. *Am. Rev. Respir. Dis.* 133:932-934.
- [34] Lopes, J. O., S. H. Alves, J. P. Benevenga, A. Salla, and I. Tatsch. 1993. Nocardia asteroides peritonitis during continuous ambulatory peritoneal dialysis. *Rev. Inst. Med. Trop. Sao Paulo* 35:377-379.
- [35] Patil SP, Gautam MM, Sodha AA, Khan KJ. Primary cutaneous nocardiosis with craniocerebral extension: A case report *Dermatol Online J.* 2009; 15:8
- [36] Dodiuk-Gad R, Cohen E, Ziv M, Goldstein LH, et al. Cutaneous nocardiosis: report of two cases and review of literature. *Int J. Dermatol* 2010; 49: 1380-1385
- [37] Beaman BL, Beaman L, Kjelstrom JA, Ogata SA. Bacteria and neurodegeneration In: *CaIne D, ed. Neurodegenerative diseases.* Orlando, Florida: WB Saunders, 1994:319-38.
- [38] Borm W, Gleixner M. Nocardia brain abscess misinterpreted as cerebral infarction. *J Clin Neurosci.* 2003;10:130-132.
- [39] Menku A, Kurtsoy A, Tucer B, Yildiz O, Akdemir H. Nocardia brain abscess mimicking brain tumour in immunocompetent patients: report of two cases and review of the literature. *Acta Neurochir (Wien).* 2004;146:411-414
- [40] Murray JF. Finegold SM. Froman S. Will DW. The changing spectrum of nocardiosis: a review and presentation of nine cases. *Am Rev Respir Dis* 1961;83:315-30.
- [41] Frazier AR. Rosenow EC III. Roberts GD. Nocardiosis: a review of 25 cases occurring during 24 months. *Mayo Clin Proc* 1975;50:657-63.
- [42] Ambrosioni J, Lew D, Garbino J. Nocardiosis: Updated Clinical Review and Experience at a Tertiary Center. *Infection* 2010; 38: 89-97
- [43] Uttamchandani RB, Daikos GL, Reyes RR, Fischl MA et al. Nocardiosis in 30 patients with advanced human immunodeficiency virus infection: clinical features and outcome. *Clin Infect Dis.* 1994 Mar;18:348-53.
- [44] McNeil MM, Brown JM, Hutwagner LC, Schiff TA. Evaluation of therapy for Nocardia asteroides complex infection: CDN/NCID report. *Infect Dis Clin Pract.* 1995;4:287-292
- [45] Peterson PK, Ferguson R, Fryd DS, Balfour HH Jr, Rynasiewicz J, Simmons RL. Infectious diseases in hospitalized renal transplant recipients: a prospective study of a complex and evolving problem. *Medicine (Baltimore).* 1982;61:360-372.
- [46] Wallace RJ Jr, Septimus EJ, Williams TW Jr, et al. Use of trimethoprim-sulfamethoxazole for treatment of infections due to Nocardia. *Rev Infect Dis* 1982;4:315-25.
- [47] Garlando F, Bodmer T, Lee C, Zimmerli W, Pirovino M. Successful treatment of disseminated nocardiosis complicated by cerebral abscess with ceftriaxone and amikacin: case report. *Clin Infect Dis* 1992; 15: 1039-40.

- [48] Yew WW, Wong PC, Kwan SY, Chan CY, Li MS. Two cases of *Nocardia asteroides* sternotomy infection treated with ofloxacin and a review of other active antimicrobial agents. *J Infect* 1991; 23:297–302
- [49] Diekema DJ, Jones RN. Oxazolidinone antibiotics. *Lancet* 2001; 358: 1975–82.
- [50] Moylett EH, Pacheco SE, Brown-Elliott BA, et al. Clinical experience with linezolid for the treatment of *Nocardia* infection. *Clin Infect Dis*. 2003;36:313-318.

IntechOpen

IntechOpen