

# We are IntechOpen, the world's leading publisher of Open Access books Built by scientists, for scientists

**4,800**

Open access books available

**122,000**

International authors and editors

**135M**

Downloads

Our authors are among the

**154**

Countries delivered to

**TOP 1%**

most cited scientists

**12.2%**

Contributors from top 500 universities



**WEB OF SCIENCE™**

Selection of our books indexed in the Book Citation Index  
in Web of Science™ Core Collection (BKCI)

Interested in publishing with us?  
Contact [book.department@intechopen.com](mailto:book.department@intechopen.com)

Numbers displayed above are based on latest data collected.

For more information visit [www.intechopen.com](http://www.intechopen.com)



---

# Surgical Management of the Aortic Root

---

B. Goslin and R. Hooker

Additional information is available at the end of the chapter

<http://dx.doi.org/10.5772/51831>

---

## 1. Introduction

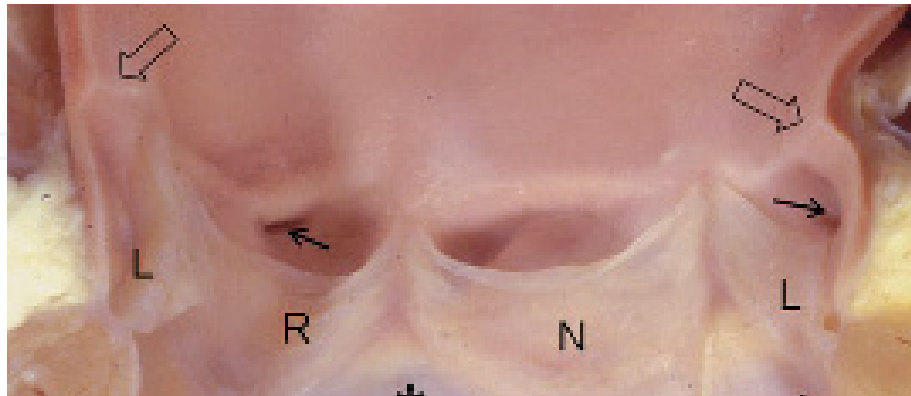
The surgical management of aortic root pathology is complicated and challenging. The dynamic structure of the root serves the purpose of being the outflow tract of the left ventricle, a conduit to coronary perfusion, and path for blood flow to the end-organs. The anatomy of the aortic root is the basis of what leads to complex problems needing surgical correction including aortic valve repair, aneurismal disease of the sinuses and root, dissection of the ascending aorta, in addition to other surgically correctable disorders. The anatomy, pathology, pathophysiology, and imaging, as well as the surgical management of the aortic root will be discussed.

## 2. Anatomy

The aortic root is proximally defined as the left ventricular outflow tract and distally defined as the ascending aorta at the sinotubular junction. (Figure 1) Critical structures of the root include; the aortic valve, sinuses of Valsalva, coronary ostia, and transition at the sinotubular junction into the ascending aorta.[1]

The leaflets of the aortic valve form a transient barrier between the left ventricular outflow tract and the lumen of the proximal aorta. Leaflets are individually suspended around the aortic annulus. [2] There is debate between surgeons and anatomists regarding the anatomy of the fibrous annulus. [1,2] Surgeons grossly perceive the annulus to be a circumferential fibrous structure while anatomists have identified individual histologic hinge points for each of the leaflets. All three leaflets have a rigid border (lunules) which lie adjacent to one another when the aortic valve is in the closed position.[1,3] The lunules of each triangular shaped leaflet convalesce at the apex of the leaflet to form the nodule of Arantius. While the leaflets are able to form a uniform barrier in the closed position along the commissures, they have separate dimensions which affect the flow dynamics and coronary perfusion during systole.[3] The superior side of each leaflet is basket-shaped (open to the aortic lumen) and

forms a raphe when closed. Each leaflet is named based upon the respective coronary artery and therefore they are termed the left, right, and non-coronary leaflets. The left coronary leaflet has a larger surface area than the right and non-coronary in the normal valve.[1]



**Figure 1.** Sectioned aortic root. Hollow arrows signify the sinotubular junction. L, R, and N correspond to the left, right and non-coronary sinuses. Solid black arrows identify the right and left coronary ostia that are located adjacent to their respective sinuses.<sup>1</sup>

In the space immediately superior to the leaflets are the sinuses of Valsalva. The most superior border of each sinus forms the sinotubular junction, a fibrous ridge on the luminal surface.[1,2] In vivo studies have shown that the sinuses not only collect blood during diastole, but dynamically dilate to potentiate flow to the coronary ostia.[4] During systole the leaflets project superiorly into the sinus allowing blood to pass into the aortic lumen.[1] Diameters of the sinotubular junction and aortic annulus as well as dimensions of the sinuses of Valsalva are critical in patients needing aortic root surgery, especially in cases of aortic root replacement. Each of these variables is dependent on individual patient characteristics such as age, body surface area, weight, height, and an individual's fitness. [5,6]

The most critical function of the aortic root is to perfuse the coronaries. Typically there are two coronary ostia that perfuse the left and right coronary arteries, respectively. Multiple ostia for both coronaries, however, is not rare and knowledge of ostia anatomical variation is crucial during an aortic root reconstruction and coronary angioplasty.[7,8] In a study by Pejkovic et al, ostia were located 2-10mm inferior to the sinotubular junction in 90% of cases. Additionally, separate conal ostia from the right sinus of Valsalva were found in 33% of cases. The pathologic significance of left and right coronary arteries originating from only one ostia (from either the left or right sinus of Valsalva) has a noted correlation with sudden death at a young age. This anomaly is exceedingly rare.[8]

Histologically, the aortic root is a significant point of transition with regard to supportive tissue. Proximally, collagenous fibers help support the annulus of the aortic valve. The majority of proximal root support, however, is composed of myocardial fibers with a superficial layer of endocardium. More distally, the sinuses of Valsalva has dense elastic fibers interspersed with regions of woven collagen forming the ridge of the sinotubular junction. In regard to the lining of the aortic root lumen, the leaflets are the transition point

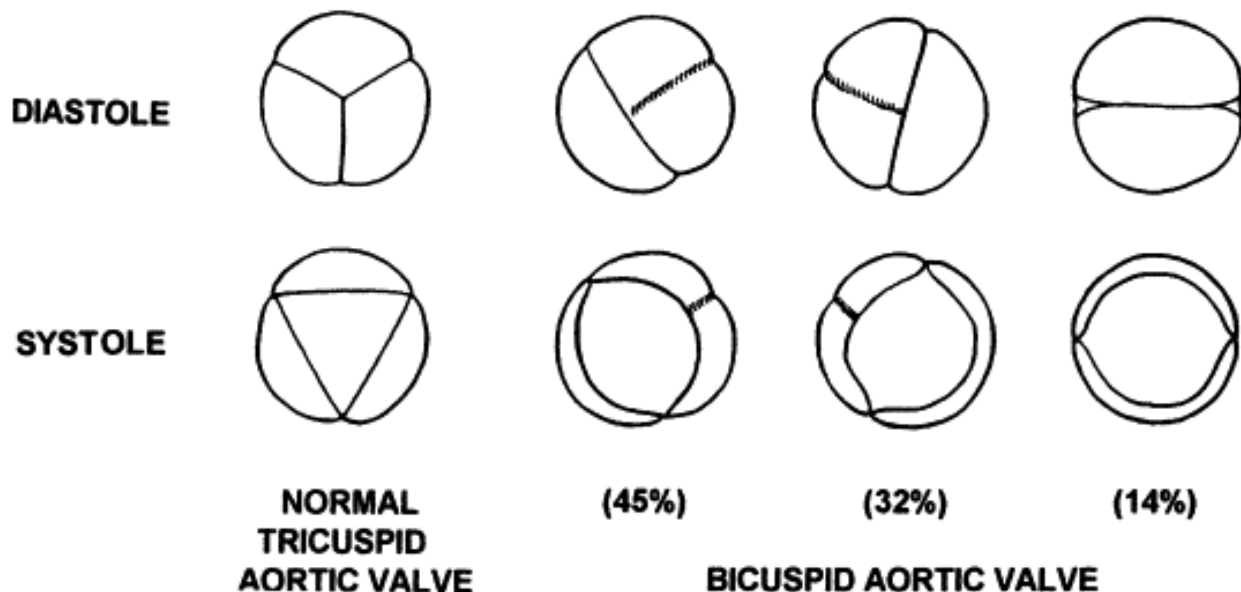
of for which endocardium lines the inferior surface of each leaflet while endothelium lines the superior surface.[2]

### 3. Pathology of the aortic root

#### 3.1. Aortic valve disorders

##### 3.1.1. Congenital

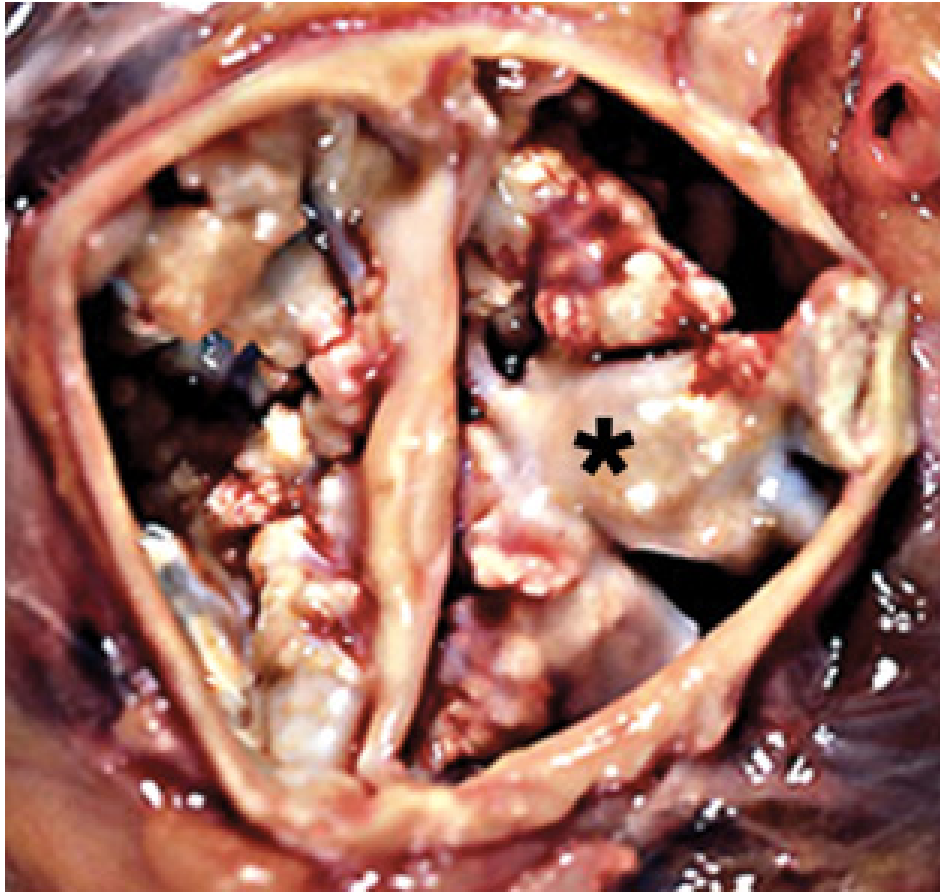Bicuspid aortic valves are present in approximately 0.5-2% of the population.[9] Rather than a simple failure of fusion of two cusps, embryology studies with animals portray a complex interaction between intracellular pathways and between individual stem cells.[9] Multiple formations of bicuspid valves have been described in addition to variable surface sizes (Figures 2 and 3). The most common bicuspid formation is anterior-posterior in nature with the left and right coronary ostia sharing the raphe of anterior sinus of Valsalva.[12] Bicuspid aortic valves, and the associated aortopathy, can lead to valvular stenosis and regurgitation, as well as ascending aneurysms and dissections. One-fourth of patients with bicuspid valves will have normal valvular function and, in one natural history study, required no medical or surgical intervention at 20 years of follow-up.[13,14]



**Figure 2.** A normal valve in the open and closed compared to a bicuspid valve. Fusion of two leaflets is noted in the closed bicuspid valve positions. The relative frequency of each morphological abnormal leaflet fusion is depicted.<sup>10</sup>

Unicuspid and quadricuspid valves also exist but are less common. Unicuspid valves occur in approximately 1 of 10,000 individuals and patients seem to have similar valve and aortic pathology as compared to patients with bicuspid valves.[15,16] The prevalence of unicuspid aortic valves are so rare that the risk of aortic root disease can not be quantified by clinical studies; only case reports and summaries exist. Likewise, quadracusp valves are rare

occurring in 1-10 patients per 100,000. It usually leads to insufficiency at an early age. [17] Anecdotally, authors recommend stress testing prior to undergoing valve replacement. [17]



**Figure 3.** Congenital bicuspid valve as seen from the root position, in vivo. Bulky calcifications cover the luminal surface of the valve. One such macrocalcification is identified by an asterisk.[11]

### 3.1.2. Acquired

The most common acquired condition of the aortic valve is calcific valvular disease.[18] This typically leads to aortic stenosis but can also cause a mixed pathology of both stenosis and regurgitation. During 2009 in the United States alone, over 40,000 patients underwent aortic valve replacement (AVR) with or without coronary artery bypass grafting.[19] Isolated infection of the leaflets typically leads to regurgitation. Usually both of these conditions are not considered “root” problems as they can be treated with surgical replacement of the aortic valve, however they can evolve into root problems when calcium deposition in the aortic wall becomes severe or the infection forms a root abscess, as will be discussed.

### 3.1.3. Aneurismal disease of the root

Since the ascending aorta begins at the level of the sinotubular junction it is frequently involved with any aneurismal root pathology. Hence, any discussion of root pathology often involves the ascending aorta as well. The ascending aorta is considered to be aneurysmal if

the diameter is greater than 3.5cm.[20] The aortic root, however, is not considered aneurismal until it is greater than 4cm.[21] Aneurysms of the root and ascending aorta have multiple etiologies including genetic, inflammatory, acquired and infectious. Disorders that cause degenerative changes in the root wall are most common. Aortic root aneurysms are common, accounting for roughly 70% of all thoracic aneurysms.[22] The risk of fatal complications of these aneurysms strongly correlates with aneurysm size. In one natural history study, the risk of death, dissection, or rupture in patients with aneurysms >6 cm had an incidence of 15% per year.[14] Reports on growth of the aorta are variable with some reports showing little growth while others report growth of up to 0.2 cm/year in patients with aortic stenosis and a bicuspid valve.[14]

#### 3.1.4. Genetic

Marfan's Syndrome, Loeys-Dietz syndrome, Ehlers-Danlos syndrome as well as others are known genetic causes of aneurismal dilatation.[23,24,25] These disorders cause deficits in the formation of the aortic wall during embryogenesis and lead to flow abnormalities. This eventually can result in aneurysm formation.

Marfan's syndrome is a well-characterized, autosomal-dominant disorder that causes cystic necrosis within the media layer of the aortic wall. These patients have mutations in a single fibrillin gene, FBN1. Prevalence of Marfan's ranges from 1 in 10,000 to 20,000 people.[26] Although aortic root problems have the most dramatic sequelae in patients, other systems are adversely affected by this single gene mutation including the lungs, bones, muscles, and the central nervous system. Aortic dissection and subsequent rupture is the most common cause of sudden death in Marfan patients.[27] Patients with Marfan's associated aortic root dilatation are recommended to undergo surgical repair if the diameter of the aorta is >4.5cm.[23] Diagnosis of the disorder at a young age is crucial to prevent catastrophic aortic complications, yet 24% have the initial operation in an emergency setting.[28]

Loeys-Dietz Syndrome is an autosomal-dominant disorder that became known for having an association with aortic root aneurysms. The disorder was first discovered in 2005.[29] The baseline aortic diameter in these individuals are small, yet have a tendency to dissect or become aneurismal at a young age. When ascending aneurysms are identified in these patients, one group of authors recommended fixation when the size reached 4.2 cm.[23]

Ehlers-Danlos Syndrome is an autosomal-dominant disorder with many subtypes and each subtype typically leads to specific end-organ pathology. Vascular type (Type 4) Ehlers-Danlos Syndrome is prone to cause dissection without aneurysm formation.[29,30] Surgical results in these patients have been poor.[30]

Patients with a bicuspid aortic valve are predisposed to root aneurysms because of the associated aortopathy. An exact inheritance pattern for bicuspid disease has not been determined, rather, it's believed that most cases of bicuspid valves are due to multiple genes that interact causing abnormal root structure.[31] Researchers believe that pooling the genetic and histologic changes identified in bicuspid valve patients ultimately leads to aortic

root dilatation. Root enlargement is described at a younger age in patients with bicuspid valves and therefore the risk of root disease is higher in these patients.[32] The development of root pathology in patients with bicuspid valves is described later in the chapter.

### 3.1.5. *Inflammatory*

A variety of inflammatory disorders affect aortic compliance leading to aneurysm formation and dissection, prompting the need for surgical repair.

Giant cell arteritis (GCA) causes inflammation of the endothelium typically involving the temporal arteries leading to malaise, frequent temporal headaches, fevers, and jaw claudication. Infrequently patients will have complete visual loss. The gold standard of diagnosis remains temporal artery biopsy. The temporal artery is found to be involved in approximately 50% of specimens while the proximal aorta and immediate branches have less frequent involvement, 10-15%.[33] In a study of autopsy specimens, 4 in 1000 specimens had giant cell arteritis while 1.5 per 1000 were found to have dissection.[34]

Takayasu's arteritis is a form of large vessel vasculitis characterized by granulomatous inflammation in the aortic wall leading to intimal fibrosis and narrowing. Early symptoms are non-specific including malaise, fevers and rigors while late phase symptoms are ischemic in nature consisting of syncope, angina, and visual disturbance.[35] In rare cases, rupture of the aorta and proximal branches is caused by aneurysmal disease of the vessels. Survival with rupture of a lesion due to Takayasu's disease is exceedingly rare. The mainstay of treatment is systemic corticosteroids.[36] In cases of aneurysm formation, surgical intervention should be delayed until the acute inflammatory phase has resolved.[37,38]

Other inflammatory disorders account for a minority of aortic root pathology. Reiter's syndrome is an autoimmune inflammatory disease that is characterized by reactive arthritis. There are rare cases of ascending aneurysms and severe aortic regurgitation in patient's with longstanding inflammatory responses in severe cases of Reiter's.[39] Ankylosing spondylitis is an inflammatory disease that has a strong association with HLA-B27 and is characterized by joint pain involving the axial skeleton. Nearly 20% of patients with ankylosing spondylitis required aortic valve replacement in one case control study.[40]

### 3.1.6. *Infectious*

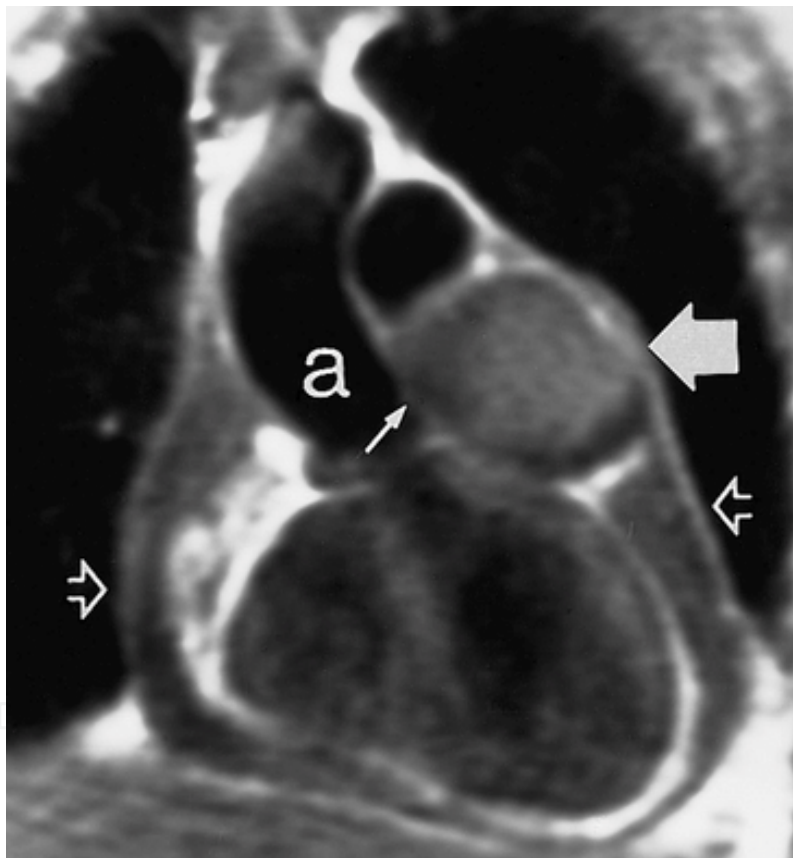
Infections of the aortic valve that are uncontrolled can lead to spread to contiguous structures, i.e. spread to the aortic wall causing dehiscence and formation of root abscesses. Left unchecked, the infection can erode further leading to involvement of the mitral and tricuspid valves as well as fistulization to atria and right ventricle.

Syphilis once had a significant impact on the cardiovascular morbidity of the United States population. The need for surgery in the management of cardiovascular complications of syphilis in the past fifty years has been exceedingly rare. Patients in need of surgery because of these complications are usually not diagnosed until after fixation. When surgical correction is required, ascending aortic involvement is diffuse, starting at the sinotubular

junction proximally and extending distal to the arch. Grossly and histologically the aortic wall is comparable to those patients with GCA or ankylosing spondylitis.[41]

### 3.1.7. Calcific atherosclerosis

Calcific atherosclerosis of the coronaries is well characterized in the literature. However, within the past decade implications of a heavily calcified aortic root have also become evident, especially in association with calcific aortic stenosis. This may make aortic valve replacement complicated and necessitate root replacement. Severe calcification of the aorta can also extend distally. Cardiac surgeons are aware of the consequences of negligent cross-clamping. Significant aortic calcification as assessed by an intraoperative ultrasound in patients undergoing cardiac surgery is an independent predictor of poor neurologic outcome and all-cause mortality.[42-44].



**Figure 4.** A large sinus of Valsalva aneurysm highlighted by the large bold arrow. A small solid arrow within the aortic lumen identifies the inflow tract to the aneurysm. A small pericardial effusion is associated with the aneurysm (hollow arrows).[41]

### 3.1.8. Sinuses of Valsalva aneurysms

Aneurismal disease of the sinuses of Valsalva occurs between the aortic valve annulus and the sinotubular junction (Figure 5). Relative to the spectrum of other aortic root pathology, sinus of Valsalva aneurysms are very rare. Studies of large patient series show that the rate



of these aneurysms found in all cardiac operations is roughly 0.5%, and more so in Eastern populations. Most have extended adjacent to the left ventricle by the time of surgery.[45,46] The sinus most commonly involved is the right coronary, followed by the non-coronary and left coronary sinus.[47] Indications for surgery include rupture, infection, and flow impedance of the coronary ostia. The goal of surgery, regardless of the specific technique, is to close the defect of the wall, resect the fistula if present, and resect the aneurysm sac.[50]

### 3.1.9. Aortic root trauma

Traumatic injury to the aortic root requiring operative management is rare, yet one needs to be aware of the injury pattern and understand indications for operative repair. Blunt thoracic aortic traumatic injury usually occurs at the level of the ligamentum arteriosum just distal to the branch point of the left subclavian artery.[49] A minority of injuries, <10%, occur at the level of the ascending aorta.[49] When aortic injuries are identified, surgery can often be delayed until other traumatic injuries are corrected according to Mattox et al.[50]

Those patients who are at highest suspicion of aortic injury need CT angiography. The sensitivity of CT is typically high enough to use for screening, however, the assessment of the aortic root is currently regarded as inadequate.[51] Well designed studies in the last two decades sought to provide evidence that transesophageal echocardiogram (TEE) was a reasonable screening test, however, it was no better than CT with regard to all thoracic injuries.[52-54] When sensitivity, cost utilization, and quality of life on follow-up are given equal consideration, it is advocated that chest radiograph and aortography continue to be the best diagnostic tools to assess for proximal aortic and root injury.[55]

Patients with root injuries often have other major injuries requiring management prior to the root and aorta.[56] When surgical repair is indicated it is frequently for contained rupture of the aortic wall. Because the injury is often distal to the sinotubular junction, surgical fixation is feasible.[57] Injuries to the aortic valve leaflets, sinuses, and coronary ostia have also been reported, but only in case reports due to the lack of prevalence.[58,59]

## 4. Pathophysiology and presentation of aortic root disease

### 4.1. Aortic stenosis

The etiology can be divided into three separate categories including postinflammatory scarring, senile calcific stenosis, and calcific stenosis of the congenitally deformed valve.[60] Rheumatic fever accounts for less than 10% of all cause aortic stenosis and continues to decline in modern society but is still very common in underdeveloped countries. Regardless of the etiology of aortic stenosis, all have the potential to progress to left heart failure if left untreated.

Grossly, calcific disease of the aortic valve is a heaped up mass of calcium that usually projects into the sinuses.[61] Only recently is this process of calcium deposition being understood as an active regulatory process rather than degenerative. Calcium deposition on

the valves is the result of a complex interaction between interstitial cells via paracrine signals.[62]

Valvular sclerosis eventually leads to a pressure gradient between the left ventricular outflow tract and aortic lumen. The left ventricle attempts to compensate and overcome this pressure gradient to maintain perfusion by concentric hypertrophy of the myocardium.[62] Clinically this corresponds to the three hallmarks of aortic stenosis including angina, congestive heart failure (CHF), and syncope. Symptom severity directly correlates with prognosis, as 50% of patients with CHF will die in 2 years without intervention.[63]

#### **4.2. Aortic regurgitation**

Regurgitation of flow into the left ventricle occurs during the diastolic phase. Causes of this reverse flow are numerous, however, the predominant causes of include calcific stenosis and a dilated aortic root.[61] Calcific stenosis leads to stiff leaflets that stay in a fixed open position, even in the diastolic phase, and this allows for reflux into the left ventricle.[61] Aortic root disease causing valvular regurgitation is due to tension on and retraction of the cusps. [14]

The Starling principle demonstrates the stretch of the myocardium is increased due to volume expansion from the regurgitant blood.[64] Cardiac contractility is increased due to an added volume at end diastole. This creates a vicious cycle of increased output due to contractility, yet there is also gradually increasing regurgitant flow as left ventricular output increases. Chronically, the forces of volume and pressure overload in addition to increased contractility lead to eccentric hypertrophy. Hypertrophy leads to increased myocardial wall tension causing to fibrosis and ischemia.[65] Chronic reflux of flow back into the left ventricle causes a combination of pressure and volume overload.[65]

Signs and symptoms are not noted until the patient develops congestive heart failure. Patients without significant predisposing factors (Marfan's or bicuspid valve) however may have progressive regurgitation for decades without symptoms.[66] The first symptoms to develop are disguised as primarily pulmonary complaints such as exertional and nocturnal dyspnea. Some patients complain of vague thoracic pain or headaches. Angina is a late finding that signifies end stage left ventricular function.[67]

#### **4.3. Type A dissection**

A dissection occurs when there is a tear of the intima and a tunneled pathway is made between the media and adventitia parallel to the lumen of the blood vessel. This dissection flap that is created diverts blood flow through true and false lumens with the false lumen created by the dissection.[68] Type A dissections are located in the ascending aorta and are known for having a high mortality.[69] With respect to the aortic root, patients with dissection can have dilated sinuses, aortic regurgitation, and acute pericardial tamponade and therefore repairing the dissection may also include root replacement or modification.

A number of factors predispose certain populations to getting Type A dissection including genetic and acquired diseases.[70] Once the dissection flap is made, the false lumen diameter expands and there is elongation of the false lumen. It is hypothesized that the false lumen enlarges and true lumen collapses over time for two reasons. First, the relative overabundance of elastin within the wall of the true lumen causes it to be more compliant and compressible. Second, the pressure within the false lumen is higher causing the dissection flap to collapse the true lumen.[70]

Symptomatically, Type A dissection is characterized by what is often described by patients as being “ripping” or “tearing” chest pain. Because dissections are known to travel retrograde, patients may have profound hypotension if the dissection involves the pericardium or aortic valve. Pericardial tamponade complicates approximately 20% of Type A dissections.[71]

#### **4.4. Ascending aorta & root aneurysms**

The majority of patients with ascending aneurysms have inherent tissue abnormalities that result in a weak aortic wall. The most well described disorders associated with proximal aortic aneurysms of patients with a bicuspid valve and Marfan’s. Both abnormalities cause cystic medial necrosis by replacement of normal elastic mesenchymal cells with mucoid degenerated cells.

Patients with Marfan’s and those with bicuspid aortic valves also have degenerative changes in the media.[72] The aortic roots have variable amounts of elastin and larger baseline aortic root diameters than the general population.[73-75] The underlying genetic association has yet to be determined.

### **5. Imaging of the aortic root**

Imaging modalities most readily available for assessment of aortic root pathology include, echocardiography, both, transthoracic (TTE) and transesophageal (TEE), computed tomography (CT), angiography, and magnetic resonance imaging (MR). Each has advantages and disadvantages when analyzing abnormalities and planning for surgical repair.

Echocardiography can assess aortic root and valve anatomy and function however, it does not give good views of the distal aorta. Echo is also very useful for imaging other heart valves and ventricular size and function, all important for operative planning. While TTE is known to give accurate measurements of aortic root structures, it is not able to adequately detect dissection locations or extent of dissection with accuracy.[76] TEE, has proven to be safe and effective in the pre and post-operative assessment of patients with aortic dissection.[77,78]

Computed tomography is an attractive means of assessing the ascending aorta when pathology such as dissection, aneurysm formation, ulceration, and intramural hematoma

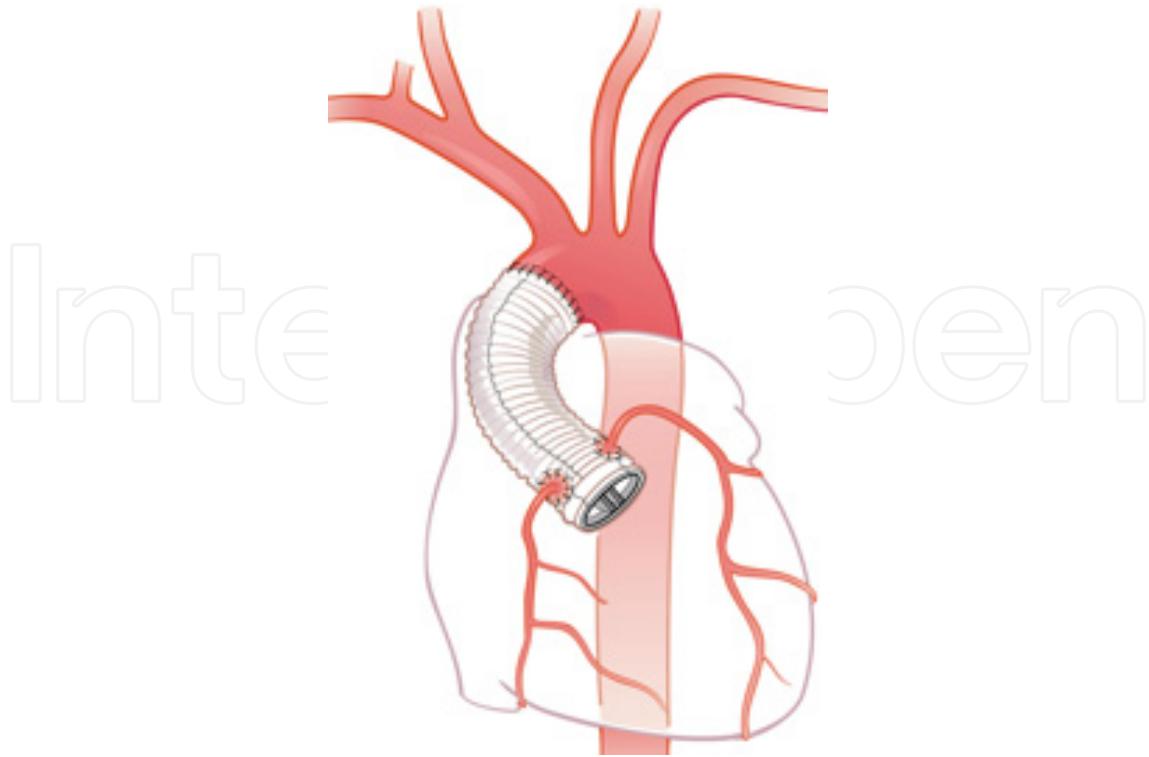
are suspected. Arterial wall enhancement with contrast is necessary for this technology to be utilized and patients with renal dysfunction or contrast allergy may have a contraindication. Low volume contrast studies have recently been used safely in patients with renal dysfunction.[80] Most series report the sensitivity for Type A dissection to be >90%.[81] Due to the varying degrees of signal enhancement, CT is able to distinguish between the false and true lumens in addition to the presence of thrombosis or communication of the false lumen. Similarly, the assessment of ascending aneurysms is accurate because of CT's ability to determine size, relative assessment of flow, and the aneurysms relationship to surrounding vital structures.[80] With regard to valve pathology, multidetector CT is able to provide an accurate depiction of aortic annulus size, valve calcification, and degree of stenosis as compared to preoperative TEE and MR.[82] CT scans may be used to image the coronary arteries, heart and other thoracic structures. Indeed, heart surgery has been done safely without coronary angiogram in patients with normal coronaries on CT angiogram.[83,84]

	Sensitivity	Specificity
Echo (TEE)	95-99%	92-97%
Helical CT	96-100%	87-99%
MRI	95-99%	95-100%

**Table 1.** Result of meta-analysis by Shiga et al describing the sensitivities and specificities of TEE, CT, and MRI for detecting thoracic aortic dissection.[79]

Use of MR angiography is typically an adjunct form of imaging used with echocardiography in patients with complex anatomy. At some institutions MR angiography is replacing CT as the primary imaging modality for assessment of diseases involving the thoracic aorta due to its decreased risk of radiation exposure. MR angiography (CE MR) provides improved diagnostic accuracy of thoracic vascular pathology when compared to other imaging. It has demonstrated a higher sensitivity and specificity than other forms of MR imaging and echocardiography.[85] Emergency use of MR is limited. Steady state free precession MR is a newer technology that allows for better visualization of structures by decreasing surrounding interference without the use of contrast.[83] This method has demonstrated success in the accurate visualization of diseases such as aneurysm, intramural hematoma, dissection, and ulceration of the native aorta as well as assessment of postoperative graft placement.[88] It is particularly attractive for patients who have a contrast allergy.

Coronary angiography remains the gold standard for evaluation of the coronary arteries. Aortography can demonstrate aortic insufficiency and enlargement of the aorta, although we use CT and echo as it is much more accurate and less invasive. Venticulography may also be done, however with severe aortic stenosis it may be difficult to cross the valve and may not be indicated because the risk of emboli.[87] Right and left heart pressures may also be obtained at the time of catheterization.



**Figure 5.** A graphic depiction of the modified-Bentall Procedure. A synthetic graft is identified in the native root position with implantation of both coronary arteries.[83]

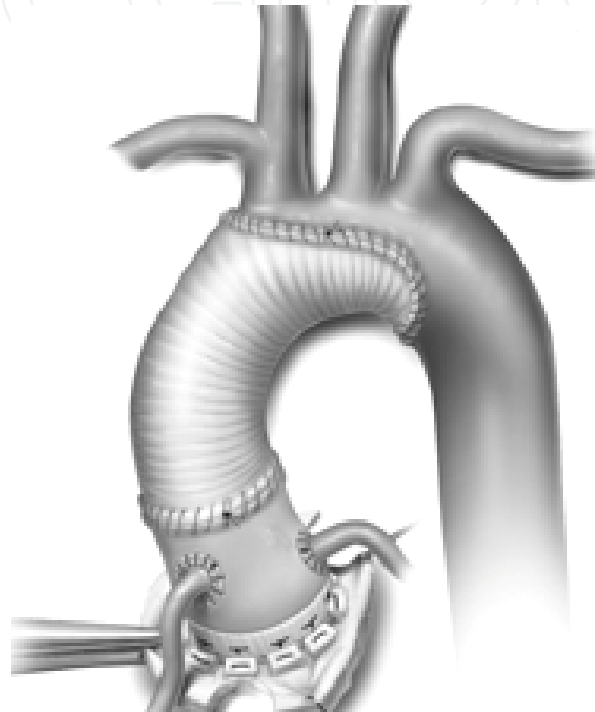
## 6. Surgery of the aortic root

In 1968, Bentall and Bono published the case of a patient with an ascending aortic aneurysm that involved the root and included coronary involvement.[88] In their case, a composite aortic graft was sewn to the annulus with a mechanical Starr valve. The coronaries were attached via an inclusion technique into the wall of the new prosthetic aortic root. Currently, the Kouchoukos modification with direct coronary button modification is the standard for root replacement today. Typically, the aortic valve tissue is removed, all abnormal aortic tissue in the sinuses and the ascending aorta is removed, and buttons of the right and left coronary artery are created. The root is then replaced with one of the following: a valved-conduit (either mechanical or biologic), a stentless valve as a root, a homograft, or a pulmonary autograft. There is a proximal suture line at the level of the left ventricular outflow tract, a distal suture line where the pathology of the aorta usually ends, and suture lines for reimplantation of both the coronary buttons. (Figure 5)

### 6.1. Biologic options for aortic root surgery

For patients who need aortic root surgery there is the option of using synthetic material (usually Dacron) versus a biologic prosthesis. Biologics are manufactured and treated in the form of xenografts or homografts. The major benefit with a biologic valve is that therapeutic anticoagulation is not required. In July of 1992 the FDA approved the use the first xenograft in the United States, the Medtronic Freestyle. This graft allows similar flow and velocity

measurements in addition to peri-operative morbidity and mortality to synthetic grafts.[90] In a prospective, randomized trial comparing homografts to Freestyle grafts, long-term survival was found to be the same for the groups. The main indication for root replacement was aortic valve disease associated with pathologic changes in the root. Homografts were found to have a higher likelihood to need a second operation and a higher rate of root degeneration and calcification.[91] Homografts are commonly indicated in patients with a history of endocarditis. The major factor that deters the use of biologics is long-term degeneration of the biologic material when compared synthetic grafts.



**Figure 6.** Hemi arch replacement with aortic root replacement using a porcine bioroot. Vertical mattress sutures are noted at the annular anastomosis. Both coronaries are reimplanted with their native peri-aortic tissue.[116]

## 6.2. Composite versus valve sparing root replacement

The question of to replace the aortic root with a composite graft or to perform a valve-sparing operation is dependent on multiple patient characteristics as well as the surgeon preference. Over the last decade surgeons have debated which technique provides the best peri-operative and long-term results. The major concern with complete root replacement is lifelong therapeutic anticoagulation. The etiology of the aortic root disease, as well as individual patient preferences, must be taken into account so the correct procedure is performed for each patient.

Patients who present with an ascending aneurysm or dissection involving the root have a variety of options for surgical reconstruction. Specific criteria are taken into account including the patient age and if there are early signs of co-morbid aortic valve pathology that may require replacement in the future. Patients with connective tissue disorders,

bicuspid valves, or history of valve infection may be best served with Bentall-type replacement rather than valve-sparing reconstruction.

Previous studies have attempted to stratify patients into composite replacement versus a valve-sparing techniques with a heterogeneous group of patients. One major study retrospectively examined patients who received root replacement at a single institution. Patients were therefore not prospectively stratified with respect to age, genetic basis of root replacement (patients with Marfan's or bicuspid valves), or additional comorbidities.[92]

Zehr et al reviewed the results at their institution comparing total replacement with valve-sparing techniques, an experience over a 30-year period that served to answer the question of which procedure had improved outcomes.[92] All patients in the study electively underwent a Bentall procedure or valve-sparing (Yacoub or David-type technique). Roughly 75% of the total 208 patients underwent composite root replacement while the remaining patients had valve-sparing operations. They concluded that patients undergoing a Bentall-type procedure have less risk of needing a second operation for aortic valve disease. There was no difference between long-term survival of the two groups which was 93%, 72%, and 59% at five, ten, and twenty years, respectively. However, 37% of the valve-sparing group needed reoperation due to additional valvular or aortic pathology in the follow-up period. Most procedures for reoperation in the valve-sparing patients were due to the need of aortic valve replacement for regurgitation or stenosis. The authors concluded that both types of procedures offered durable results in the peri-operative and long-term periods. This study tells us that, while both procedures are reasonable options, benefits are difficult to determine without patient specific treatment characteristics.

Other studies are published since the Zehr series that have attempted to give credence to either technique for more concentrated patient populations.[93-95] The results from previous large retrospective and prospective studies will be discussed at depth in the upcoming paragraphs. We will review the results of major studies and discuss aortic root reconstructive techniques stratified by disease etiology.

### **6.3. Aortic root surgery for patients with bicuspid valves- General recommendations and analysis of surgical outcomes**

There is strong consensus that patients with bicuspid valves and aortic root enlargement should be considered for replacement when the aneurysm is  $> 5.0\text{cm}$  or there is an increase in size of  $>0.5\text{cm}$  per year.[96,97] In 2007, guidelines were published by the European Society of Cardiology regarding replacement of the aortic root with respect to the aortic diameter, recommending replacement when the root diameter is  $>5.5\text{cm}$ .[98] Subsequently in 2008, the American Heart Association/American College of Cardiology guidelines found class IB evidence that root replacement should be considered when the diameter is  $>5\text{cm}$  or dilatation progresses at a rate  $>5\text{mm}$  per year.[99]

While the latest guidelines are straightforward, some controversy still exists with regard to the surgical management of patients who require aortic valve replacement (AVR) of a

degenerated bicuspid valve yet who do not have aneurysmal change of the ascending aorta or root. It is advocated by some institutions that patients who need aortic valve replacement should also undergo simultaneous replacement of the root and proximal ascending aorta.[100,101] McKellar et al examined outcomes at the Mayo Clinic in patients who had AVR without ascending aorta replacement. These patients did not have signs of root pathology at the time of operation. Analysis showed that patients who did not have aortic valve replacement had a low risk of having subsequent aortic root pathology on follow-up.[102] The most feared complication in the interim, Type A dissection, was very low in follow-up (1%) in patients with a normal size ascending aorta. Interestingly, the risk of aortic complications was the same for patients with and without aortic enlargement at the time of surgery. Median follow-up time was fifteen years. Mortality of aortic root replacement is low at 2-4%,[103] while in specific institutions AVR mortality rates are less than 1%, especially in low-moderate risk populations.[104] Thus we would advocate aortic valve replacement alone and close follow up of the remaining aorta with CT or MR.

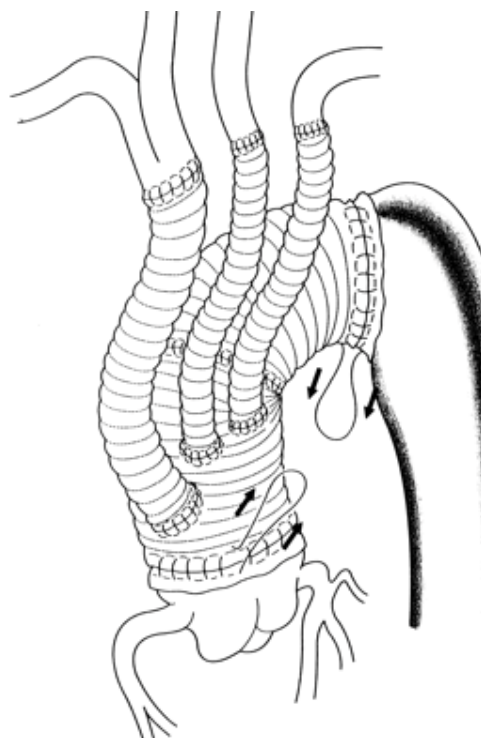
Choice of valve in aortic root replacement is also somewhat controversial. Data out of the Mayo Clinic has shown better long-term survival with mechanical aortic valve replacement.[92,105] Patient preference enters into the decision process as patients do not want to take Coumadin. Younger patients who choose a bioprosthesis may face reoperation. Re-operative mortality on a stentless valve has been reported over 10%.[106] Although homograft root replacement has traditionally been used for infectious reasons, it also has a high mortality when it is redone, primarily due to severe calcification of the walls.[107] Lastly, with regard to biologic roots made with a valve inside a tube graft, very little data exists regarding re-operative surgery. Intuitively it would seem to be a safer procedure, as surgery would involve replacing the valve inside the graft and leaving the graft alone. The Ross procedure has been abandoned for bicuspid valves as progression of aneurysmal dilatation over time leads to autograft dysfunction in a significant number of patients.[108]

Valve-sparing aortic root replacement in bicuspid aortic valve situations has been performed. Many fewer cases have been done than with a tricuspid valve. Results are not as good as with a tricuspid valve but nevertheless some have reported good long-term follow-up.[99]

Mortality in most series for root replacement is approximately 2-4% without comparison of independent risk stratification.[109,110] The risks for serious bleeding and stroke are 3.2% and 3.2%, respectively. Long-term survival is variable depending on the age and comorbidities of the patients undergoing replacement. Survival at 1, 3 and 5 years in a study by Ancheck et al was 84.7%, 78.3%, and 72.5%, respectively. The key to survival seems to be recognizing signs of aortic pathology related to the congenital disease and preventing morbidity and mortality of dissection and aneurysm with early root replacement. Van Putte et al. examined their long-term data of root replacement over a 25-year period with over 500 patients. Survival at 5, 10, and 25 years was 87%, 73%, and 29%, respectively. Peri-operative complication rates for myocardial infarction and stroke were 4.0 and 4.2%, respectively. Peri-operative rate for take back to the operating room for bleeding was 19%.[111] In sum, the results of root replacement are safe and are standing the test of time.



When aneurismal change is present, the root replacement may extend distally to include the remainder of the ascending aorta, aortic arch, and descending aorta. The most common operation in combination with the root replacement is hemi-arch replacement. Other operations combined with root replacement include aortic arch replacement and occasionally a frozen elephant trunk procedure. (Figures 6-8) With these more extensive procedures, mortality and morbidity understandably increases. Peri-operative mortality of the hemi arch and total arch procedures is 6.7% and 6.9%, respectively, with comparable morbidity.[115] With the elephant trunk procedure, the latest and best survival data are from Italy.[116] In 2010, Bartolomeo et al published their series of 67 patients who underwent the frozen elephant trunk over a two year period. Peri-operative mortality was 13.4%. Severe neurologic deficit occurred in 17%, although most patients had adequate outcomes with a 2 year survival 70%.[116]

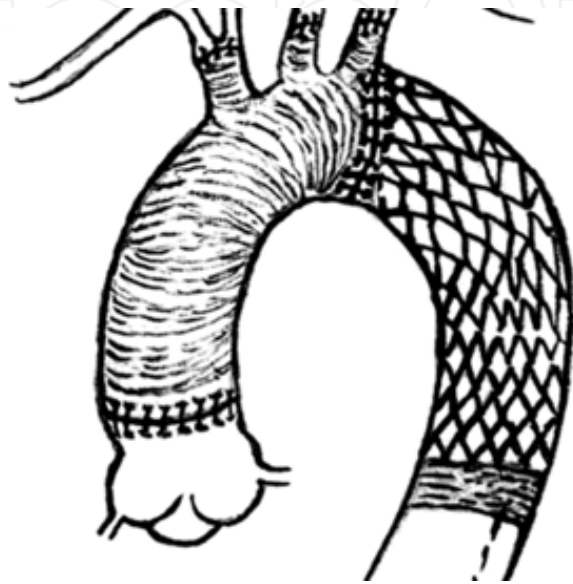


**Figure 7.** Aortic arch replacement via implantation and proximal grafting of the brachiocephalic, left carotid, and left subclavian arteries. Although not depicted in this image, root reconstruction via modified-Bentall technique can be performed during the same operation.[107]

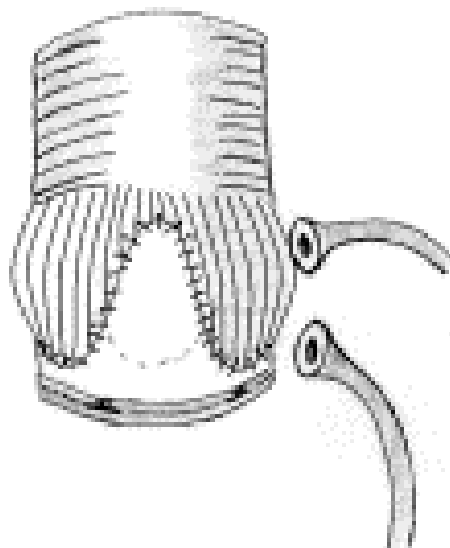
#### 6.4. Valve sparing aortic root replacement in patients with aneurysms

Aortic root reconstruction without valve replacement has come into popularity with cardiac surgeons because not all aortic root disease is accompanied with aortic valve dysfunction. Yacoub, in 1983,[117] and David, in 1991,[118] separately devised procedures that spare the native aortic valve, or so named, valve-sparing aortic root replacement. The Yacoub procedure is a “remodeling” procedure where the aortic graft is surgically attached to the aortic wall at the level of the commissures.[119] (Figure 9) A modification of the Yacoub procedure is the David, or “reimplantation” procedure. During the reimplantation

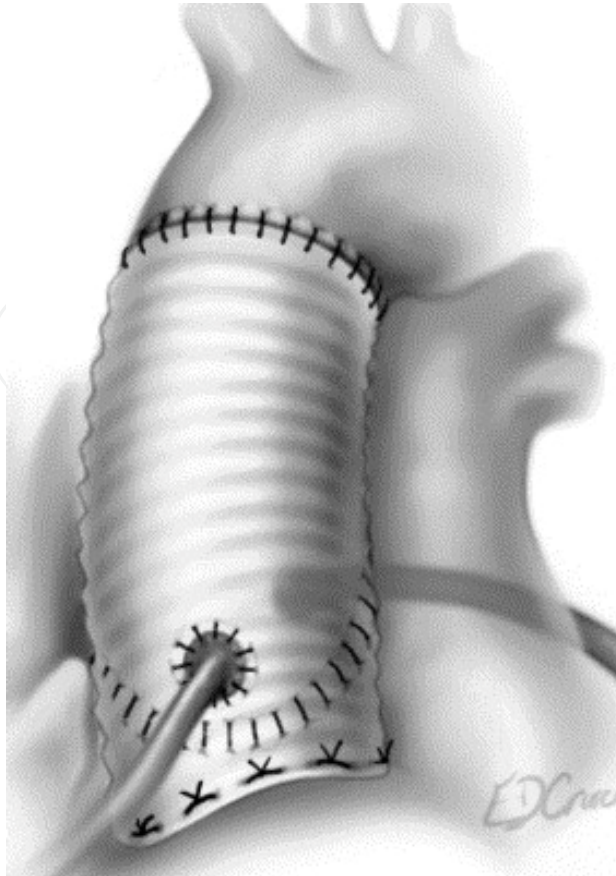
procedure, the graft is fixed at a level proximal to the annulus, to the tissue of the left ventricular outflow tract[120](Figure 10). Since the origin of the David procedure, there have been multiple modifications to the technique with the latest emphasizing restoration of the sinuses of Valsalva by the creation of neosinuses.[121] Special grafts with sinuses (Gelweave) are also available.



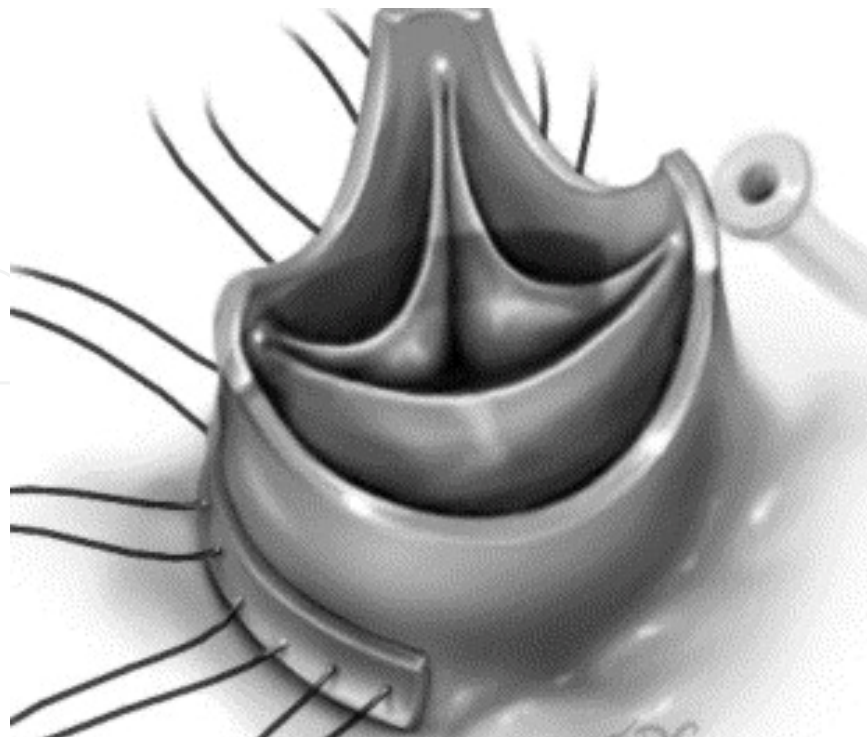
**Figure 8.** Frozen elephant trunk procedure in which a stent graft is deployed distally in the descending thoracic aorta. Debranching and anastomosis of the proximal arch branches, distal aortic arch, and proximal aorta are then carried out with a Dacron graft.[118]



**Figure 9.** Yacoub procedure. Root replacement by remodeling consists of placing subannular U-stitches, a scalloped Dacron graft attached above the commissural ring, and finally coronary ostia are reimplanted into the graft material.[113]



**Figure 10.** Modified David procedure where the graft is fixed to the level just proximal to the aortic annulus at the left ventricular outflow tract.[114]



**Figure 11.** Trimming of the aortic root during modified David Procedure.[121]

The surgical technique involves resecting all aortic tissue except for a 5mm rim of aorta just above the valve and creating buttons of the coronaries (Figure 11). Dissection is carried proximally below the level of the annulus. Great care must be taken during this portion of the procedure to avoid the RVOT and left atrium. Sutures are then placed from inside the LVOT to outside through the graft for the proximal suture line. The graft is seated and the leaflets are inside the graft. After securing the proximal suture line, the valve leaflets are carefully positioned inside the graft to allow coaptation in the same plane for all three leaflets. The leaflets are then sutured inside the graft by running a suture along the small piece of aortic wall and attaching it to the graft. The coronaries are reimplemented and the distal suture line is performed where appropriate. Echo confirms (Figure 12) good coaptation of the leaflets and no aortic insufficiency.

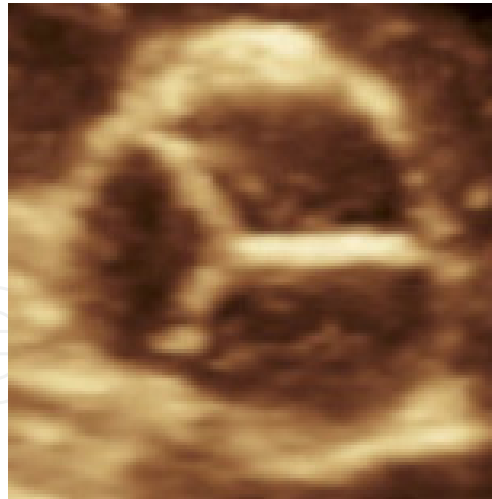Indications for a valve-sparing procedure are ascending and root aneurysms (>5cm or 4.5cm for patients with Marfan's) with normal aortic leaflets. Typically from sinotubular dilatation there is central aortic insufficiency which is easily corrected by this procedure. Asymmetric regurgitation may require leaflet repair. This is an excellent operation for patients with Marfan's, as it obviates the need for long-term anticoagulation. Recently it has been used in patients with acute Type A aortic dissection who require a root replacement.

Multiple studies are published since the advent of the David procedure that have attempted to give credence to the valve-sparing technique.[93-95] Long-term results of this have been excellent. A meta-analysis summarized the results and conclusions of 16 studies describing complete root replacement and valve-sparing techniques. Ten-year survival for patients undergoing valve-sparing techniques ranged from 82-97% in a heterogeneous group of patients.

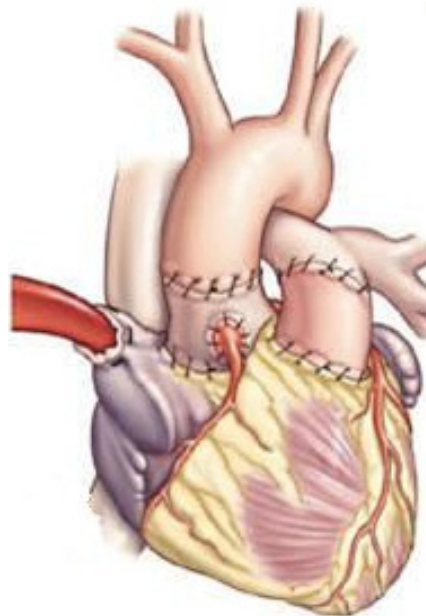
Subpopulations that have undergone valve-sparing technique include the elderly and those patients with Marfan's. One study in older patients (>60 years old) demonstrated less favorable, yet still good results.[123] The peri-operative mortality of 63 patients undergoing valve-sparing replacement was 1.4% with an overall 51 month survival of 84%. Immediate post-operative and long-term results for Marfan's patients are also excellent. Volguina et al analyzed the short-term results of 105 patients with Marfan's who underwent valve-sparing technique.[124] There were no inpatient mortalities and significant morbidity included 8% requiring re-exploration of the mediastinum while only 13% had a peri-operative arrhythmia. David et al analyzed the long-term results of their 103 person cohort.[125] Fifteen year survival was 87% and 89% of those alive at fifteen years and patients were free of clinically significant aortic regurgitation.

### **6.5. Aortic root replacement in patients with acute type A aortic dissection**

Patients who have an acute type A aortic dissection are a surgical emergency. Typically the ascending aorta is replaced with an open distal anastomosis such as a hemiarch with antegrade cerebral perfusion. The proximal anastomosis is then done at the sinotubular junction after removing all thrombus between the layers and gluing them together.



**Figure 12.** Echo demonstrating coaptation of aortic valve leaflets.[122]



**Figure 13.** Ross Procedure after reconstruction. The pulmonary allograft is implanted into the left ventricular outflow tract and the coronaries are reimplemented into the autograft. A synthetic valve/root component is then used for the new pulmonary artery and valve.

Approximately 31% of patients will require aortic root replacement as the dissection extends down into the sinuses and around the coronaries.[126] As mentioned earlier, if the valve leaflets are normal then a valve-sparing root replacement is an option. The downside is an extended length of time during this critical operation, however with the proximal suture line below the annulus it may prevent bleeding. This is a major problem in patients with dissection. Because root replacement must be done in a significant proportion of Type A dissections there is incentive to understand outcomes in composite grafts versus stentless grafts. Lai et al examined their experience with Type A dissection patients who had AI and were stratified by root replacement with composite graft and separate valve graft.[127] Composite grafts had slightly improved survival at long-term follow-up then did patients

with a separate valve graft. International Registry of Acute Aortic Dissection data should be used to examine this relationship in the future.

### **6.6. Aortic root replacement for infected endocarditis**

Endocarditis is a dangerous condition of the aortic valve that can rapidly spread beyond the leaflets into the tissue around the aortic root. This typically leads to an aortic root abscess. This can further erode into contiguous structures such as the mitral valve, left atrium, right atrium, tricuspid valve, and right ventricle. Surgical principle mandates debridement of all infected tissue. Other valves and chambers must be repaired, prior to the root replacement. In the past it was felt that homograft root replacement was the ideal operation. Indeed the graft was felt to be more resistant to infection and the homograft had the anterior leaflet still attached, which often aided in mitral valve involvement. Recently, the availability and quality of homografts has become less. Results of root replacement with material other than homograft are not substantially different. Jassar et al reviewed the results of root replacement at their institution in patients with active endocarditis.[128] Patients had root replacement with synthetic grafts, biologics, or homografts. There was no significant difference with regard to in hospital mortality or survival with a mean follow-up of 32 months. Five-year survival for the cohort was also similar between groups, ranging from 58-62%.[128] Long-term survival was analyzed in patients receiving homograft roots for endocarditis and results are quite promising.[129] Thirty day survival was 83% while 10-year survival was 47%. One year reoperation rate due to deterioration of the graft was 8.6%. We therefore advocate root replacement in this situation based on factors such as age and patient preference. The Ross procedure is also an option for root replacement in this condition. Excellent long term results have been reported and theoretically the pulmonary autograft may be more resistant to infection.[130]

### **6.7. Aortic root replacement for a calcific aortic root**

Patients who have severe aortic stenosis and a very calcified root may require aortic root replacement because of the difficulty inserting the valve from the distribution of calcium in the root. This can be a very dangerous operation because of the calcium extending into the coronary arteries. Indeed ligation of the coronaries may be required with the addition of bypass grafting. [131]

### **6.8. Surgery for sinus of valsalva aneurysms- general recommendations and analysis of surgical outcomes**

Although sinus of Valsalva aneurysms are rare, they frequently require prompt surgical repair to prevent life threatening complications. A majority of patients present with rupture of the aneurysm into a cardiac chamber, typically the right atrium or ventricle. Eastern cultures have a notable increased incidence when compared to Western cultures. The first aneurysms were treated successfully in the 1950s. A clear distinction in outcome can be seen in patients who have infected versus non-infected aneurysms.[132] Root replacement is

infrequently required for this condition, however when it is, the standard considerations about which type of valve to implant are used.

The largest series of patients was compiled by the Texas Heart Institute where the outcomes of 129 patients were analyzed over a 40-year period. Aortic root replacement was only necessary in 12% of patients, while the remaining patients were able to be treated with simple plication or a patch procedure.[132] Peri-operative mortality was 4% and complications included valve malfunction, endocarditis, and recurrence of the aneurysm in 3.9%, 2.6%, and 1.8%, respectively. Other recent retrospective trials have been published.[133,134] Again the vast majority of patients (>90%) were able to attain fixation with either direct closure or patch techniques. Approach for fixation was usually obtained through the chamber that rupture of the aneurysm occurred. Patients who had repair in the last decade demonstrated fewer days in the hospital and fewer peri-operative complications which included wound infection and arrhythmias. Over 90% of patients were alive after 5 years. The factor of highest prognostic significance with regard to long-term survival is time of onset and severity of aortic regurgitation.[135] Unfortunately there was no sub-analysis describing the results in those patients with root replacement.

### **6.9. The Ross procedure: indications and outcomes**

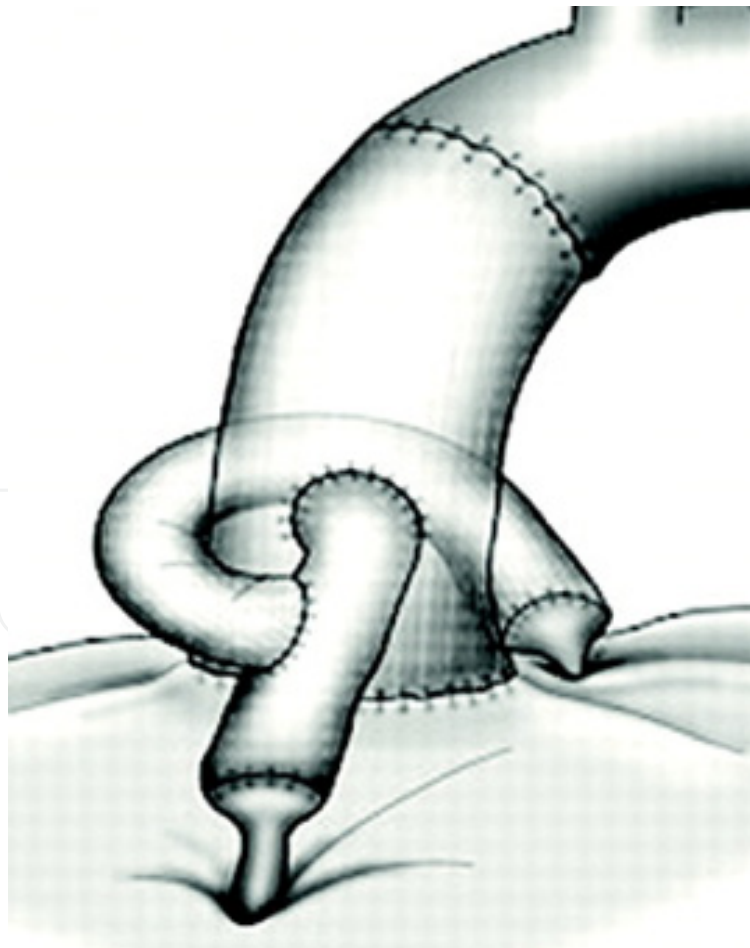The Ross procedure involves root replacement with the patients pulmonary valve harvested en-bloc as a cylinder from RVOT to distal pulmonary artery (Figure 13). The pulmonary valve is typically replaced with a porcine xenograft or homograft. Drawbacks of this operation include its complexity and it also involves double valve replacement for single valve pathology. Surgical results with the Ross procedure have been excellent except in the cases of bicuspid aortic valve.[136] In bicuspid cases the root undergoes dilatation, possibly from the same underlying abnormality that involved the native aorta of which the cause is not known.

While the procedure is technically very challenging, the peri-operative outcomes are adequate, yet long-term results are still debated.[137,138] One group out of Germany described their outcomes of 203 patients who were at least 10 years out from surgery with a mean follow-up of 12.3 years. Over 90% of patients did not need reoperation on either valve at 10 years of follow-up. They concluded that the Ross operation was safe, as long-term survival did not differ from the general population. Slight increases in the size of the aortic valve annulus and rate of insufficiency was observed.[137] In contrast, a meta-analysis was published in 2009 which summarized the results of Ross procedure outcomes and included 17 studies.[138] They concluded that the peri-operative and short-term outcomes is acceptable, however, there is significant graft durability limitation that is observed after the first decade, especially in younger patients. They concluded that further research to accomplish extended graft function would be helpful to limit possibility of long-term reoperation. It is now well established that patients with a bicuspid aortic valve should not have the Ross operation.

### 6.10. Reoperation of the aortic root

Structural failure of the root, pseudoaneurysms, or infection may necessitate redo aortic root replacement. This is an operation that typically carries a high risk of mortality and morbidity. Some special considerations when this very difficult operation is undertaken include: calcified homografts or stentless valves, coronary artery length, and infection.

In patients with a very calcified neo-aortic wall it is often extremely difficult to dissect out the wall and redo the root as it becomes very adherent to the adjacent structures and pulmonary artery and coronaries can be injured. Replacing just the aortic valve within the calcified root is an option. With the advent of trans aortic valve implantation (TAVI), this may be an excellent option in high risk patients. El-Hamamsy et al compared the Freestyle graft with homograft aortic root replacement in a prospective, randomized trial.[139] One-hundred sixty-six patients with an average age of 65 years had a mean follow-up of 7.6 years. Significant conclusions were made from this data including an improved age of survival (80 vs. 77 years), lower rate of reoperation (100% vs. 90%), and echocardiographically patients had less signs of valvular deterioration (86% vs. 30%) in the FreeStyle group.

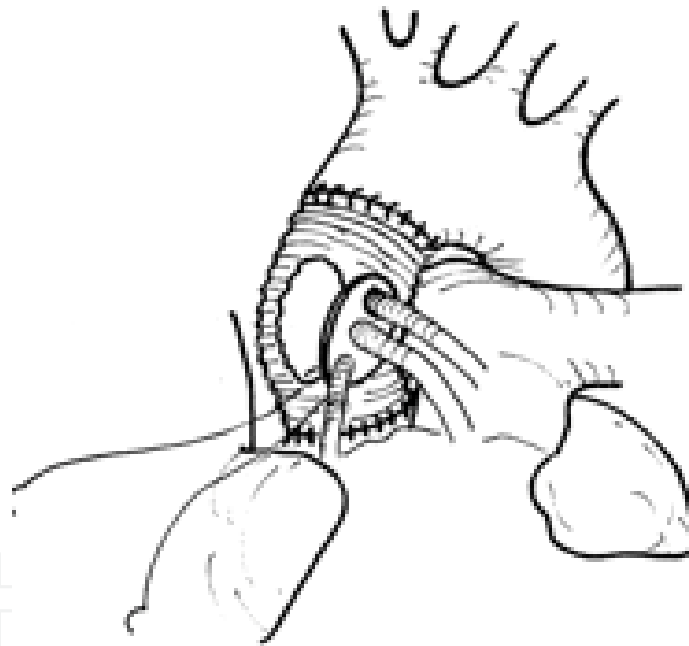


**Figure 14.** Aortic root replacement via the Cabrol technique. Coronary buttons are sutured side-to-side to a Dacron interposition graft during root replacement.[140]



There can be difficulty with mobilizing the coronary buttons and placing them into the new root or they can be damaged. The Cabrol technique should then be deployed, (Figure 14) where a graft is sutured end to end to both the right and left coronary buttons then sutured side to side to the aorta.[140] Results have been mixed,[141,142] which may be due to difficulty orienting the graft. A second option is to place an interposition vein graft (Figure 15) between the coronary buttons and the graft.[143] This is our preferred method as we find the grafting to be easier. Lastly bypass-grafting can be done with ligation of the coronary arteries. This is typically a last resort when bleeding and technical difficulties with the anastomosis are encountered.

Infected roots pose a major problem because of the amount of debridement and reconstruction that is required. The same surgical principles apply of removal of all infected and foreign tissue. Results have been promising using homograft replacements as demonstrated in peri-operative and with long-term follow-up studies.[128,129]



**Figure 15.** Vein graft interposition can be used as a conduit for coronary perfusion rather than using a Dacron interposition graft. This figure demonstrates venous conduits being sewn to the aortic root. 143

## 7. Conclusion

The anatomic complexity and serious pathology that affect the aortic root challenge the cardiac surgeon. Surgical procedures on the aortic root have drastically changed the lives of patients and extended their lifespan. Leaders in the field of cardiac surgery such as Bono, Bentall, Yacoub, and David have contributed greatly to our surgical armamentarium for treatment of aortic root pathology. These procedures will continue to evolve with improved graft material, improved valves, percutaneous approaches, and stem cell therapies.

## Author details

B. Goslin

*Grand Rapids Medical Education Partners, Michigan State University College of Human Medicine, USA*

R. Hooker

*Spectrum Health, Michigan State University, College of Human Medicine, West Michigan Cardiothoracic Surgeons, USA*

## 8. References

- [1] Ho, and Siew Yen. Structure and Anatomy of the Aortic Root. *Eur J Echocardiog* 2009;10(1):i3-i10.
- [2] Sutton III JP, Ho SY, and Anderson RH. The Forgotten Interleaflet Triangles: A Review of the Surgical Anatomy of the Aortic Valve. *Ann Thorac Surg* 1995;59(2):419-427.
- [3] Azadani AN, Chitsaz S, Matthews PB, et al. Comparison of Mechanical Properties of Human Ascending Aorta and Aortic Sinuses. *Ann Thorac Surg* 2012;93(1):87-94.
- [4] Blanchard C, Lalande A, Sliwa T et al. Automatic Evaluation of the Valsalva Sinuses From Cine-MRI. *Mag Reson Mater Phy* 2011;24(6):359-370.
- [5] Zhu D, and Zhao Q. Dynamic Normal Aortic Root Diameters: Implications for Aortic Root Reconstruction. *Ann Thorac Surg* 2011;91(2):485-489.
- [6] D'Andrea A, Cocchia R, Riegler L, et al. Aortic Stiffness and Dispensability in Top-Level Athletes. *J Am Soc Echocardiog*. Epub Jan 2012.
- [7] Rubinshtein R, Lerman A, Spoon DB, and Rihal CS. Anatomic Features of the Left Main Coronary Artery and Factors Associated with Its Bifurcation Angle: A 3-dimensional Quantitative Coronary Angiographic Study. *Catheter Cardio Inte* 2012:1-6.
- [8] PejkoVIC B, Krajnc I, and Anderhuber F. Anatomical Variations of Coronary Ostia, Aortocoronary Angles and Angles of Division of the Left Coronary Artery of the Human Heart. *J Int Med Res* 2008;36(5): 914-922.
- [9] Evangelista A. Bicuspid Aortic Valve and Aortic Root Disease. *Cur Cardiol Rep* 2011;13(3): 234-241.
- [10] Brandenburg RO, Tajik AJ, Edwards WD, et al. Accuracy of 2-dimensional echocardiographic diagnosis of congenitally bicuspid aortic valve: Echocardiographic-anatomic correlation in 115 patients. *Am J Cardiol* 1983;51:1469-1473.
- [11] Alkadhi H, et al. Cardiac CT for the Differentiation of Bicuspid and Tricuspid Aortic Valves: Comparison With Echocardiography and Surgery. *Am J Rad* 2011;195(4):900-908.
- [12] Davies MJ. Pathology of Cardiac Valves. London: Butterworths & Co; 1980. 51-61.
- [13] Michelena HI, Khanna AD, Mahoney D, et al. Incidence of Aortic Complications in Patients with Bicuspid Aortic Valves. *J Am Med Assoc* 2011;306(10):1104-1112.
- [14] Aldo C, Russo CF, and Vitali E. Bicuspid Aortic Valve: About Natural History of Ascending Aorta Aneurysms. *Ann Thorac Surg* 2008;85(1):362-363.

- [15] Sood N, and Taub C. Unicuspid Aortic Valve: An Interesting Presentation. *Eur Heart J* 2008;29(10):1295.
- [16] Mookadam F, Thota V, et al. Unicuspid aortic valve in children. *J Heart Valve Dis* 2010;19(6):678-683.
- [17] Di Pino A, Gitto P, Silvia A, and Bianca I. Congenital Quadricuspid Aortic Valve in Children. *Cardiology in the Young* 2008;18(3):324-327.
- [18] Rajamannan NM, Evans FJ, Aikawa E, et al. Calcific Aortic Valve Disease: Not Simply a Degenerative Process. *Circulation* 2011;124(16):1783-1791.
- [19] LaPar DJ, Ailawadi G, Bhamidipati CM, et al. Small Prosthesis Size in Aortic Valve Replacement Does Not Affect Mortality. *Ann Thorac Surg* 2011;92(3):880-888.
- [20] Davies RR, Kaple RK, Mandapati D, et al. Natural History of Ascending Aortic Aneurysms in the Setting of An Unreplaced Bicuspid Aortic Valve. *Ann Thorac Surg* 2007;83(4):1338-1344.
- [21] Kallenbach K, Leyh RG, Salcher R, et al. Acute Aortic Dissection Versus Aortic Root Aneurysm: Comparison of Indications for Valve Sparing Aortic Root Reconstruction. *Eur J Cardio-thorac Surg* 2004;25(5):663-670.
- [22] Davies, RR, Goldstein LJ, Coady MA, et al. Yearly Rupture or Dissection Rates for Thoracic Aortic Aneurysms: Simple Prediction Based on Size. *Ann Thorac Surg* 2002;73(1):17-28.
- [23] Cannata, Aldo, Russo CF, and Vitali E. Bicuspid Aortic Valve: About Natural History of Ascending Aorta Aneurysms. *Ann Thorac Surg* 2008;85(1):362-363.
- [24] David TE, Maganti M, and Armstrong S. Aortic Root Aneurysm: Principles of Repair and Long-term Follow-up. *J Thorac Cardiovasc Surg* 2010;140(6):S14-S19.
- [25] Augoustides, JGT, Plappert T, and Bavaria JE. Aortic Decision-making in the Loeys–Dietz Syndrome: Aortic Root Aneurysm and a Normal-caliber Ascending Aorta and Aortic Arch. *J Thorac Cardiovasc Surg* 2009;138(2):502-503.
- [26] Yuan SM, Jing H. Marfan’s Syndrome- an overview. *Soa Paulo Med J* 2010;128(6):360-366.
- [27] Keane MG, Pyeritz RE. Medical management of Marfan syndrome. *Circulation*. 2008;117:2802-2813.
- [28] Song HK, Kindem M, Bavaria JE, et al. Long-term Implications of Emergency Versus Elective Proximal Aortic Surgery in Patients with Marfan Syndrome in the Genetically Triggered Thoracic Aortic Aneurysms and Cardiovascular Conditions Consortium Registry. *J Thorac Cardiovasc Surg* 2012;143(2):282-286.
- [29] Loeys BL, Chen J, Neptune ER, et al. A syndrome of altered cardio-vascular, craniofacial, neurocognitive and skeletal development caused by mutations in TGFBR1 or TGFBR2. *Nat Genet* 2005;37(3):275-281.
- [30] Atzinger CL, Meyer RA, Khoury PR, et al. Cross-Sectional and Longitudinal Assessment of Aortic Root Dilation and Valvular Anomalies in Hypermobile and Classic Ehlers-Danlos Syndrome. *J Ped* 2011;158(5):826-830.
- [31] Siu SC, and Silversides CK. Bicuspid Aortic Valve Disease. *J Am Coll Cardiol* 2010;55(25):2789-2800.

- [32] Beroukhim RS, Kruzick TL, Taylor AL, Gao D, Yetman AT. Progression of aortic dilation in children with a functionally normal bicuspid aortic valve. *Am J Cardiol* 2006;98:828-830.
- [33] Liu G, Shupak R, and Chiu BY. Aortic Dissection in Giant-cell Arteritis. *Seminars in Arthritis and Rheumatism* 1995;25(3):160-171.
- [34] Ostberg G: On arteritis: with special reference to polymyalgia arteritica. *Acta Pathol Microbiol Immunol Scand* 1973;237:1-59, 1973.
- [35] Kerr GS, Hallahan CW, Giordano J, et al. Takayasu arteritis. *Ann Intern Med* 1994;120:919-929.
- [36] Robinson WP, Detterbeck FC, Hendren RL, and Keagy BA. Fulminant Development of Mega-aorta Due to Takayasu's Arteritis: Case Report and Review of the Literature. *Vascular* 2005;13(3):178-183.
- [37] Song M, Nakayama T, Hattori K, et al. Aortic Root Aneurysm in Takayasu Arteritis Syndrome: Exploration in Active Phase and Repair in Inactive Phase. *J Thorac Cardiovasc Surg* 2008;136(4):1084-1085.
- [38] O'Connor MB, Murphy E, O'Donovan E, et al. Takayasu's Arteritis Presenting As a Dissecting Aortic Aneurysm History: A Case Report. *Cases journal* 2008;1(1):52.
- [39] Paulus HE, Pearson CM, and Pitts W. Aortic Insufficiency in Five Patients with Reiter's Syndrome: A Detailed Clinical and Pathologic Study. *The American Journal of Medicine* 1972;53(4):464-472.
- [40] Roldan CA, Chavez J, Wiest PW, et al. Aortic Root Disease and Valve Disease Associated with Ankylosing Spondylitis. *J Am Coll Cardiol* 1998;32(5):1397-1404.
- [41] Bruckner BA, DiBardino DJ, Cumbie TC, et al. Critical Evaluation of Chest Computed Tomography Scans for Blunt Descending Thoracic Aortic Injury. *Ann Thorac Surg* 2006;81(4):1339-1346.
- [42] Dávila-Román VG, Murphy SF, Nickerson NJ, et al. Atherosclerosis of the Ascending Aorta Is An Independent Predictor of Long-term Neurologic Events and Mortality. *J Am Coll Cardiol* 1999;33(5):1308-1316.
- [43] Lee S, and Cho SH. Huge Ascending Aortic Pseudoaneurysm Caused by a Penetrating Atherosclerotic Ulcer. *Circulation. Cardiovasc Imag* 2008;1(3):e19-e20.
- [44] White CS, and Plotnick GD. Case 33: Sinus of Valsalva Aneurysm. *Radiology* 2001;219:82-85.
- [45] Takach TJ, Reul GJ, Duncan JM, et al: Sinus of Valsalva aneurysm or fistula: Management and outcome. *Ann Thorac Surg* 1999;68:1573-1577.
- [46] Chu SH, Hung CR, How SS, et al. Ruptured aneurysms of the sinus of Valsalva in Oriental patients. *J Thorac Cardiovasc Surg* 1999;99:288-298.
- [47] Shah, AJ, Pocock JM, Belham M, et al. Aneurysm of the Sinus of Valsalva. *Cardiology Journal* 2009;16(6):312-313.
- [48] Ott, David A. Aneurysm of the Sinus of Valsalva. *Seminars in Thoracic and Cardiovascular Surgery: Pediatric Cardiac Surgery Annual* 2006;9(1):165-176.

- [49] Pearson R, Philips N, Hancock R, et al. Regional Wall Mechanics and Blunt Traumatic Aortic Rupture at the Isthmus. *European journal of cardio-thoracic surgery* 2008;34(3):616-622.
- [50] Matthew JW, Tsai PI, Gilani R, and Mattox KL. Challenges in the Diagnosis and Management of Unusual Presentations of Blunt Injury to the Ascending Aorta and Aortic Sinuses. *J Surg Res* 2010;163(2):176-178.
- [51] Bruckner BA, DiBardino DJ, Cumbie TC, et al. Critical Evaluation of Chest Computed Tomography Scans for Blunt Descending Thoracic Aortic Injury. *Ann Thorac Surg* 2006;81(4):1339-1346.
- [52] Smith MD, Cassidy JM, Souther S, et al. Transesophageal echocardiography in the diagnosis of traumatic rupture of the aorta. *N Engl J Med*. 1995;332:356-362.
- [53] Saletta S, Lederman E, Fein S, and Fortune JB. Transesophageal echocardiography for the initial evaluation of the widened mediastinum in trauma patients. *J Trauma*. 1995;39:137-142.
- [54] Brooks SW, Young JC, Cmolik B, et al. The use of transesophageal echocardiography in the evaluation of chest trauma. *J Trauma*. 1992;32:761-768.
- [55] Brasel KJ, and Weigelt JA. Blunt Thoracic Aortic Trauma. A Cost-utility Approach for Injury Detection. *Arch Surg*. 1960;131(6): 619-625.
- [56] Symbas PJ, Horsley WS, and Symbas PN. Rupture of the Ascending Aorta Caused by Blunt Trauma. *Ann Thorac Surg* 1998;66(1):113-117.
- [57] Lewis JV, Dunn JA, Compton RP. Injuries of the ascending aorta. *S Tenn Med Assoc* 1993;86:399-400.
- [58] Mastroberto P, Mizio GD, Colosimo F, and Ricci P. Occlusion of Left and Right Coronary Arteries and Coronary Sinus Following Blunt Chest Trauma. *J Forens Sci* 2011;56(5):1349-1351.
- [59] Sandrelli L, Cavalotti C, Casati V, et al. Aortic valve repair for traumatic aortic insufficiency. *Ital Heart J* 2000;1(11):767-768.
- [60] Schoen FJ. Surgical pathology of removed natural and prosthetic valves. *Hum Pathol* 1987;18:558.
- [61] Robbins & Cotran, The Heart Chapter 12, p. 590.
- [62] Bostrom K, Watson KE, Stanford WP, and Demer LL. Atherosclerotic calcification: relation to developmental osteogenesis. *Am J Cardiol* 1995;75:88B-91B.
- [63] Carabello BA. Aortic Stenosis *N Engl J Med* 2002;346:677.
- [64] Lakier JB, Copans H, Rosman HS, et al. Idiopathic Degeneration of the Aortic Valve: A Common Cause of Isolated Aortic Regurgitation. *J Am Coll Cardiol* 1985;5(2):347-351.
- [65] Bermudez EA, Gaasch WH: Regurgitant lesions of the aortic and mitral valves: Considerations in determining the ideal timing of surgical intervention. *Heart Fail Clin* 2006; 2:473.
- [66] Tornos P, Bonow RO: *Aortic regurgitation*. In: Otto CM, Bonow RO, ed. *Valvular Heart Disease: A Companion to Braunwald's Heart Disease*, Philadelphia: Saunders/Elsevier; 2009:155-168.

- [67] Enriquez-Sarano M, Tajik AJ: Clinical practice. Aortic regurgitation. *N Engl J Med* 2004; 351:1539.
- [68] Williams DM, Lee DY, Hamilton BH, et al. The dissected aorta. III. Anatomy and radiologic diagnosis of branch-vessel compromise. *Radiol* 1997;203(1):37–44.
- [69] Hiratzka LF, Bakris GL, Beckman JA, et al. ACCF/AHA/AATS/ACR/ASA/SCA/SCAI/SIR/STS/SVM guidelines for the diagnosis and management of patients with Thoracic Aortic Disease: A report of the American College of Cardiology Foundation/American Heart Association Task Force on Practice Guidelines, American Association for Thoracic Surgery, American College of Radiology, American Stroke Association, Society of Cardiovascular Anesthesiologists, Society for Cardiovascular Angiography and Interventions, Society of Interventional Radiology, Society of Thoracic Surgeons, and Society for Vascular Medicine. *Circulation* 2010; 121:e266–e369.
- [70] Williams DM, LePage MA, Lee DY The dissected aorta. I. Early anatomic changes in an in vitro model. *Radiol* 1997;203(1):23–31.
- [71] Gilon D, Mehta RH, Oh JK, et al: Characteristics and in-hospital outcomes of patients with cardiac tamponade complicating type A acute aortic dissection. *Am J Cardiol* 2009; 103:1029.
- [72] Bonderman D, Gharehbaghi-Schnell E, Wollenek G et al. Mechanisms underlying aortic dilatation in congenital aortic valve malformation. *Circulation* 1999;99:2138–2143.
- [73] Nistri S, Grande-Allen J, Noale M et al. Aortic elasticity and size in bicuspid aortic valve syndrome. *Eur Heart J* 2008;29:472–479.
- [74] Aydin A, Mortensen K, Rybczynski M, et al. Central pulse pressure and augmentation index in asymptomatic bicuspid aortic valve disease. *Int J Cardiol* 2011;147:466–468.
- [75] Aydin A, Desai N, Bernhardt A, et al. Ascending aortic aneurysm and aortic valve dysfunction in bicuspid aortic valve disease. *Int J Cardiol* Epub, July 2011.
- [76] Penco M, Papanoni S, Dagianti A, et al. Usefulness of Transesophageal Echocardiography in the Assessment of Aortic Dissection. *Am J Cardiology* 2000;86(4):53–56.
- [77] Nienaber CA, Spielmann RP, Von Kodolisch Y, et al. Diagnosis of thoracic aortic dissection: magnetic resonance imaging versus transesophageal echocardiography. *Circulation* 1992;85:434–447.
- [78] Simon P, Owen AN, Havel M, et al. Transesophageal echocardiography in the emergency surgical management of patients with aortic dissection. *J Thorac Cardiovasc Surg* 1992;103:1113–1118.
- [79] Shiga T, Wajima Z, Apfel CC, Inoue T, and Ohe Y. Diagnostic Accuracy of Transesophageal Echocardiography, Helical Computed Tomography, and Magnetic Resonance Imaging for Suspected Thoracic Aortic Dissection: Systematic Review and Meta-analysis. *Arch Intern Med* 2006;166(13):1350–1356.
- [80] Takahashi K, and Stanford W. Multidetector CT of the Thoracic Aorta. *Int J Cardiovasc Imag* 2005;21(1):141–153.

- [81] LePage MA, Quint LE, Sonnad SS, et al. Aortic dissection: CT features that distinguish true lumen from false lumen. *Am J Roentgenol* 2001; 177: 207-211.
- [82] Pouleur A, le Polain J, Pasquet A, et al. Aortic Valve Area Assessment: Multidetector CT Compared with Cine MR Imaging and Transthoracic and Transesophageal Echocardiography. *Radiol* 2007;244(3):745-754.
- [83] Cornily J, Gilard M, Bezon E, et al. Cardiac Multislice Spiral Computed Tomography As An Alternative to Coronary Angiography in the Preoperative Assessment of Coronary Artery Disease Before Aortic Valve Surgery: A Management Outcome Study. *Arch Cardiovasc Dis* 2010;103(3):170-175
- [84] Gilard M, Cornily J, Pennec P, et al. Accuracy of Multislice Computed Tomography in the Preoperative Assessment of Coronary Disease in Patients with Aortic Valve Stenosis." *J Am Coll Cardiol* 2006;47(10):2020-2024.
- [85] Krishnam MS, Tomasian A, Malik S, et al. Image Quality and Diagnostic Accuracy of Unenhanced SSFP MR Angiography Compared with Conventional Contrast-enhanced MR Angiography for the Assessment of Thoracic Aortic Diseases. *Eur Radiol* 2010;20(6):1311-1320.
- [86] Gebker R, Gomaa O, Schnackenburg B, et al. Comparison of Different MRI Techniques for the Assessment of Thoracic Aortic Pathology: 3D Contrast Enhanced MR Angiography, Turbo Spin Echo and Balanced Steady State Free Precession. *Int J Cardiovasc Imag* 2007;23(6):747-756.
- [87] Hamon M, Baron J, Viader F, and Hamon M. Periprocedural Stroke and Cardiac Catheterization. *Circulation* 2008;118(6):678-683.
- [88] Bentall H, Bono A. A technique for complete replacement of the ascending aorta. *Thorax* 1968;23:338-339.
- [89] [http://www.destinationheart.com/ross\\_procedure.php](http://www.destinationheart.com/ross_procedure.php)
- [90] Cartier PC, Dumesnil JG, Métras J, et al. Clinical and hemodynamic performance of the freestyle aortic root bioprosthesis. *Ann Thoracic Surg* 1999;67:345-349.
- [91] El-Hamamsy I, Clark L, Stevens LM, et al. Late Outcomes Following Freestyle Versus Homograft Aortic Root Replacement. *J Am Coll Cardiol* 2010;55(4):368-376.
- [92] Zehr, KJ, Orszulak TA, Mullany CJ, et al. Surgery for Aneurysms of the Aortic Root. *Circulation* 2004;110(11):1364-1371
- [93] Tourmousoglou C, and Rokkas C. Is Aortic Valve-sparing Operation or Replacement with a Composite Graft the Best Option for Aortic Root and Ascending Aortic Aneurysm? *Interactive Cardiovascular and Thoracic Surgery* 2009;8(1):134-147.
- [94] David TE, Feindel CM, Webb GD, et al. Jack M Colman, Susan Armstrong, and Manjula Maganti. Long-term Results of Aortic Valve-sparing Operations for Aortic Root Aneurysm. *J Thorac Cardiovasc Surg* 2006;132(2):347-354.
- [95] Dias RR, Mejia OV, Carvalho EV, et al. Aortic Root Reconstruction Through Valve-sparing Operation: Critical Analysis of 11 Years of Follow-up. *Revista brasileira de cirurgia cardiovascular : órgão oficial da Sociedade Brasileira de Cirurgia Cardiovascular* 2005;25(1): 66-72.

- [96] Elefteriades JA. Indications for Aortic Replacement. *The Journal of Thoracic and Cardiovascular Surgery* 2010;140(6):s5-s9.
- [97] Guntheroth WG. A Critical Review of the American College of Cardiology/American Heart Association Practice Guidelines on Bicuspid Aortic Valve with Dilated Ascending Aorta. *Am J Cardio* 2008;102(1):107-110.
- [98] Vahanian A, Baumgartner H, Bax J, et al. Guidelines on the management of valvular heart disease: The Task Force on the Management of Valvular Heart Disease of the European Society of Cardiology. *Eur Heart J* 2007;28(2):230-268.
- [99] Warnes CA, Williams RG, Bashore TM, et al. ACC/AHA 2008 Guidelines for the Management of Adults with Congenital Heart Disease. *Circulation* 2008;118(23):e714-e833.
- [100] Etz CD, Homann TM, Silovitz D, et al. Long-Term Survival After the Bentall Procedure in 206 Patients with Bicuspid Aortic Valve. *Ann Thorac Surg* 2007;84(4):1186-1194.
- [101] Fazel SS, Mallidi HR, Lee RS, et al. The aortopathy of bicuspid aortic valve disease has distinctive patterns and usually involves the transverse aortic arch. *J Thorac Cardiovasc Surg* 2008;135:901-907.
- [102] McKellar SH, Michelena HI, Li Z, et al. Long-Term Risk of Aortic Events Following Aortic Valve Replacement in Patients with Bicuspid Aortic Valves. *The American Journal of Cardiology* 2010;106(11):1626-1633.
- [103] El-Hamamsy I, Ibrahim M, Stevens L, et al. Early and Long-term Results of Reoperative Total Aortic Root Replacement with Reimplantation of the Coronary Arteries. *The Journal of Thoracic and Cardiovascular Surgery* 2011;142(6):1473-1477.
- [104] Gaudino M, Anselmi A, Glieca F, et al. Contemporary Results for Isolated Aortic Valve Surgery. *Thorac Cardiovasc Surg* 2011; 59(4): 229-232.
- [105] Zehr KJ, Matloobi A, Connolly HM, et al. Surgical management of the aortic root in patients with Marfan syndrome. *J Heart Valve Dis* 2005;14(1):121-128.
- [106] Borger MA, Prasongsukarn K, Armstrong S, et al. Stentless Aortic Valve Reoperations: A Surgical Challenge. *Ann Thorac Surg* 2007;84(3):737-743.
- [107] Malvindi PG, van Putte BP, Leone A, et al. Aortic Reoperation After Freestanding Homograft and Pulmonary Autograft Root Replacement. *Ann Thorac Surg* 2011;91(4):1135-1140.
- [108] Luciani GB, Mazzucco A. Aortic root disease after the Ross procedure. *Curr Opin Cardiol* 2006;21(6):555-560.
- [109] Aicher D, Langer F, Kissinger A, Lausberg H, Fries R, Schafers HS. Valve-sparing aortic root replacement in bicuspid aortic valves: a reasonable option? *J Thorac Cardiovasc Surg* 2004;128:662-668.
- [110] Achneck HE, Rizzo JA, Tranquilli M, and Elefteriades JA. Safety of Thoracic Aortic Surgery in the Present Era. *Ann Thorac Surg* 2007;84(4):1180-1185.



- [111] van Putte BP, Ozturk S, Siddiqi S, et al. Early and Late Outcome After Aortic Root Replacement with a Mechanical Valve Prosthesis in a Series of 528 Patients. *Ann Thorac Surg* 2012;93(2):503-509.
- [112] LeMarie SA, Green SY, Sharma K, et al. Aortic Root Replacement with Stentless Porcine Xenografts: Early and Late Outcomes in 132 Patients. *Ann Thorac Surg* 2009;87(2):503-513.
- [113] Tanaka K, Makuuchi H, Naruse Y, et al. False Aneurysm Due to Suture Loosening After Aortic Arch Replacement. *Asian Cardiovasc Thorac Ann* 2002;10:346-348.
- [114] Chen X, Huang F, Xu M, et al. The stented elephant trunk procedure combined total arch replacement for DeBakey I aortic dissection: operative result and follow-up. *Interact CardioVasc Thorac Surg* 2010;11(5): 594-598.
- [115] Shiono M, Hata M, Sezai A, et al. Validity of a Limited Ascending and Hemiarch Replacement for Acute Type A Aortic Dissection. *The Annals of Thoracic Surgery* 2006;82(5):1665-1669.
- [116] Di Bartolomeo R, Pacini D, Savini C, et al. Complex Thoracic Aortic Disease: Single-stage Procedure with the Frozen Elephant Trunk Technique. *The Journal of Thoracic and Cardiovascular Surgery* 2010;140(6):S81-S91.
- [117] Yacoub MH, Fagan A, Stassano P, et al. Results of valve conserving operations for aortic regurgitation. *Circulation* 1983;68:311-312.
- [118] David T, Feindel C. An aortic valve-sparing operation for patients with aortic incompetence and aneurysm of the ascending aorta. *J Thorac Cardiovasc Surg* 1992;103(4):617-621
- [119] Lansac E, Di Cetta I, Varnous S, et al. External Aortic Annuloplasty Ring for Valve-Sparing Procedures. *Ann Thorac Surg* 2005;79(1):356-358.
- [120] Matalanis G. Valve Sparing Aortic Root Repairs—An Anatomical Approach. *Heart Lung Circ* 2004;13(3):S13-S18.
- [121] Kvitting JP, Ebbers T, Wigstrom L, et al. Flow patterns in the aortic root and the aorta studied with time-resolved, 3-dimensional, phase-contrast magnetic resonance imaging: implications for aortic valve-sparing surgery. *J Thorac Cardiovasc Surg* 2004; 127: 1602-1607.
- [122] Baird CW, Myers PO, Nido PJ. Aortic Valve Reconstruction in the Young Infants and Children. *Seminars in Thoracic and Cardiovascular Surgery: Pediatric Cardiac Surgery Annual* 2012;15(1):9-19.
- [123] Settepani F, Szeto WY, Bergonzini M, et al. Reimplantation Valve-sparing Aortic Root Replacement for Aortic Root Aneurysm in the Elderly: Are We Pushing the Limits? *J Cardiac Surg* 2010;25(1):56-61.
- [124] Volguina, IV, Miller DC, LeMaire SA, et al. Valve-sparing and Valve-replacing Techniques for Aortic Root Replacement in Patients with Marfan Syndrome: Analysis of Early Outcome. *J Thorac Cardiovasc Surg* 2009;137(3):641-649.

- [125] David TE, Armstrong S, Maganti M, et al. Long-term Results of Aortic Valve-sparing Operations in Patients with Marfan Syndrome. *J Thorac Cardiovasc Surg* 2009;138(4):859-864.
- [126] Trimarchi S, Nienaber CA, Rampoldi V, et al. Contemporary Results of Surgery in Acute Type A Aortic Dissection: The International Registry of Acute Aortic Dissection Experience. *J Thorac Cardiovasc Surg* 2005;129(1):112-122.
- [127] Lai DT, Miller DC, Mitchell RS, et al. Acute Type a Aortic Dissection Complicated by Aortic Regurgitation: Composite Valve Graft Versus Separate Valve Graft Versus Conservative Valve Repair. *J Thorac Cardiovasc Surg* 2003;126(6):1978-1985.
- [128] Jassar, A, Bavaria JE, Szeto WY, et al. Graft Selection for Aortic Root Replacement in Complex Active Endocarditis: Does It Matter? *Ann Thorac Surg* 2012;93(2):480-487.
- [129] Musci M, Weng Y, Hübler M, et al. Homograft Aortic Root Replacement in Native or Prosthetic Active Infective Endocarditis: Twenty-year Single-center Experience. *J Thorac Cardiovasc Surg* 139(3):665-673.
- [130] Oswald JD, Dewan SJ, Mueller MC, et al. Nelson S. Highlights of a ten-year experience with the Ross procedure. *Ann Thorac Surg*. 2001;71:S332-S335.
- [131] Dávila-Román VG, Murphy SF, Nickerson NJ, et al. Atherosclerosis of the Ascending Aorta Is An Independent Predictor of Long-term Neurologic Events and Mortality. *J Am Coll Cardio* 1999;33(5):1308-1316.
- [132] Takach TJ, Reul GJ, and Duncan JM. Sinus of valsalva aneurysm or fistula: management and outcome. *Ann Thorac Surg* 1999;68(5):1573-1577.
- [133] Wang Z, Zou C, Li D, et al. Surgical Repair of Sinus of Valsalva Aneurysm in Asian Patients. *Ann Thorac Surg* 2007;84(1):156-160.
- [134] Menon S, Kottayil B, Panicker V, et al. Ruptured Sinus of Valsalva Aneurysm: 10-year Indian Surgical Experience. *Asian Cardiovascular & Thoracic Annals* 2011;19(5):320.
- [135] Murashita T, Kubota T, Kamikubo Y, Shiiya N, Yasuda K. Long-term results of aortic valve regurgitation after repair of ruptured sinus of Valsalva aneurysms. *Ann Thorac Surg* 2002;73:1466 -71.
- [136] Stelzer, Paul. The Ross Procedure: State of the Art 2011. *Seminars in Thoracic and Cardiovascular Surgery* 2011;23(2):115-123.
- [137] Charitos EI, Stierle U, Hanke T, et al. Long-Term Results of 203 Young and Middle-Aged Patients with More Than 10 Years of Follow-Up After the Original Subcoronary Ross Operation. *Ann Thorac Surg* 2012;93(2):495-502.
- [138] Takkenberg, JJM, Zondervan PE, and van Herwerden LA. Progressive Pulmonary Autograft Root Dilatation and Failure After Ross Procedure. *Ann Thorac Surg* 1999;67(2):551-553.
- [139] El-Hamamsy I, Clark L, Stevens LM, et al. Late Outcomes Following Freestyle Versus Homograft Aortic Root Replacement: Results From a Prospective Randomized Trial. *Journal of the American College of Cardiology* 2010;55(4):368-376.

- [140] Kourliouros A, Grapsa J, Nihoyannopoulos P, and Athanasiou T. Modification of the Cabrol as a bailout procedure in complicated bicuspid valve aortopathy. *Interact Cardiovasc-Thorac Surg* 2011;12(2):199-201.
- [141] Gelsomino S, Frassani R, Da Col P, et al. A long-term experience with the Cabrol root replacement technique for the management of ascending aortic aneurysms and dissections. *Ann Thorac Surg*. 2003;75(1):126-131.
- [142] Garlicki M, Roguski K, Puchniewicz M, Ehrlich MP. Composite aortic root replacement using the classic or modified Cabrol coronary artery implantation technique. *Scand Cardiovasc J*. 2006;40(4):230-3.
- [143] Yaku H, Fermanis GG, Macauley RJ, and Horton DA. Dissection of the Ascending Aorta: A Late Complication of Coronary Artery Bypass Grafting. *Ann Thorac Surg*. 1996;62:1834-1835.