

# We are IntechOpen, the world's leading publisher of Open Access books Built by scientists, for scientists

**4,800**

Open access books available

**122,000**

International authors and editors

**135M**

Downloads

Our authors are among the

**154**

Countries delivered to

**TOP 1%**

most cited scientists

**12.2%**

Contributors from top 500 universities



**WEB OF SCIENCE™**

Selection of our books indexed in the Book Citation Index  
in Web of Science™ Core Collection (BKCI)

Interested in publishing with us?  
Contact [book.department@intechopen.com](mailto:book.department@intechopen.com)

Numbers displayed above are based on latest data collected.

For more information visit [www.intechopen.com](http://www.intechopen.com)



---

# Sex Steroid Production from Cryopreserved and Reimplanted Ovarian Tissue

---

Sanghoon Lee and Seung-Yup Ku

Additional information is available at the end of the chapter

<http://dx.doi.org/10.5772/53098>

---

## 1. Introduction

Fertility preservation is an emerging discipline that now has a key place in the care of reproductive-aged women with cancer. Because of improvement in diagnostic and therapeutic strategies, an increasingly larger number of women are surviving with cancer. In the US, more than 11 million are living with cancer and approximately 450,000 cancer survivors are of reproductive age. In addition, 4-5% of new cancer patients are younger than 35 years [1]. As a result, quality-of-life issues, including those involving fertility preservation, have gained a significant importance in the care of women with cancer.

Ovarian tissue cryopreservation and reimplantation is a main option to preserve their fertility in cancer patients who need cancer treatments without delay or do not want to undergo ovarian stimulation. For prepubertal girls with cancer, ovarian tissue freezing is the only option for fertility preservation. The first case of human ovarian tissue cryopreservation and auto-transplantation was reported in the year 2000 [2]. To date, a total of 17 babies from 12 patients have been born worldwide from ovarian tissue cryopreservation and reimplantation [3].

Even with remarkable advances in technology and increasing enthusiasm for clinical applications, human ovarian tissue transplantation is still considered as an investigational method. There are many uncertainties and unanswered questions including the restoration of ovarian function after transplantation. Thus, in this chapter, we would like to review the concepts and methods of fertility preservation, and endocrine function after ovarian transplantation in terms of sex steroid production from the cryopreserved and reimplanted ovary.

## 2. Gonadal damage

Chemotherapy and radiotherapy can cause severe gonadal damages resulting in amenorrhea with ovarian follicle loss in female and azoospermia in male. Adjuvant chemotherapy particularly with alkylating agents such as cyclophosphamide is gonadotoxic and induces premature ovarian failure. The drugs are generally classified as high risk (e.g. cyclophosphamide, chlorambucil, melphalan, busulfan, nitrogen mustard, and procarbazine), intermediate risk (e.g. cisplatin, and adriamycin), and low risk (e.g. methotrexate, 5-fluorouracil, vincristine, bleomycin, and actinomycin D) [4]. (Table 1) The degree of chemotherapy-induced ovarian damage is dependent on the patient's age, the drug used, and the dosage of the drugs. Since most cancer patients are treated with multi-agent chemotherapy protocols, it is not easy to assess the degree of gonadal damage caused by a single specific agent. Radiotherapy-induced follicular damage resulting in a high risk of prolonged amenorrhea in women can occur when exposed by pelvic or whole abdominal radiation dose  $\geq 6$  Gy in adult women,  $\geq 10$  Gy in postpubertal girls, and  $\geq 15$  Gy in prepubertal girls [5-9]. The radiation dose of concurrent chemoradiation therapy (CCRT) for patients with advanced stage cervical cancer is usually about 50 Gy. Thus gynecologic oncologists should consider a possibility of post-treatment infertility in patients who undergo CCRT.

High risk	Intermediate risk	Low risk
Cyclophosphamide	Cisplatin	Methotrexate
Chlorambucil	Adriamycin	5-Fluorouracil
Melphalan		Vincristine
Busulfan		Bleomycin
Nitrogen mustard		Actinomycin D
Procarbazine		

**Table 1.** The degree of gonadal damage by chemotherapy [4]

## 3. Candidates for and determinants of access to fertility preservation

Candidates for fertility preservation include patients with childhood cancers, breast cancers, gynecologic cancers, hematologic cancers such as leukemia and lymphoma, those who need hematopoietic stem cell transplantation or pelvic irradiation for other diseases, and those with a high risk of premature ovarian failure (or primary ovarian insufficiency). Since numerous departments are involved in fertility preservation treatment, collaborating as a team with several specialists who take part in the initial cancer diagnosis and treatment, including a mental health provider, is necessary to manage cancer patients.

Although under ideal circumstances patients should be referred to fertility preservation specialists before chemotherapy; however, many of those who do not have this opportunity

may develop infertility and may be referred for post-chemotherapy assisted reproduction [10]. Because the likelihood of the success of assisted reproductive techniques after chemotherapy is significantly diminished [11], it is extremely important to understand the factors that determine the access to fertility preservation and early referral. In a previous study, we evaluated the socioeconomic, demographic, and medical factors that influence early referral (before cancer treatment) to fertility preservation versus delayed referral to post-chemotherapy assisted reproduction in 314 women with breast cancer. Factors favoring referrals for fertility preservation were older age, early stage breast cancer, cancer care at an academic center, and family history of breast cancer [12]. This information has revealed the barriers against accessing early fertility preservation care.

#### **4. Importance of early referral to fertility preservation**

Oncologists should recognize the importance of fertility preservation and early referral to specialists. Both embryo and oocyte freezing for fertility preservation require ovarian stimulation with gonadotropins. Since ovarian stimulation must be started within the first four days of the menstrual cycle to be effective, and requires approximately two weeks for completion, early referral is crucial to avoid delay in chemotherapy. The author's previous study concluded that early referral prior to breast surgery enables women with breast cancer to initiate a fertility preservation cycle sooner and to undergo multiple cycles of oocyte or embryo freezing, when desired. Referral prior to breast surgery (n=35) results in the initiation of chemotherapy on average 3 weeks earlier in single fertility preservation cycles, as well as when the data from double cycles are included, compared to those referred after breast surgery (n=58). This additional time allows patients to undergo multiple cycles of fertility preservation (9/35 vs. 1/58). Women who can undergo multiple cycles are likely to be at an advantage for fertility preservation because of the additional number of eggs or embryos generated [13].

A recent study, however, indicated that still less than half of physicians routinely refer cancer patients of childbearing age to reproductive specialists [14]. Another recent study reported that while most oncologists recognize the importance of discussing infertility risks after cancer treatment, few actually discuss fertility preservation with their patients [15]. In addition, Armuand *et al.* [16] reported that there have been sex differences in access to fertility-related information and the use of fertility preservation treatment. Only half of the women had discussed fertility issues with a health care professional, although the majority of men had received information about fertility preservation such as sperm cryopreservation [16]. Potential explanations are that sperm banking for men is an easy and well established method, and that the delay is negligible compared to the required duration of ovarian stimulation for embryo or oocyte cryopreservation.

Oncologists play a key role in understanding patients' concerns regarding fertility. Fertility preservation specialists should make an effort to publicize the significance of fertility preservation for reproductive women with cancer and should provide appropriate education for

both associated physicians and cancer patients who wish to preserve their fertility. As important as it is to encourage oncologists to refer young people with cancer to fertility preservation counseling, it is just as important to emphasize referral as early in the process as possible to maximize the likelihood of success.

## 5. Standard methods for fertility preservation

The American Society of Clinical Oncology (ASCO) has issued practice guidelines for fertility preservation options in cancer patients [17]. Several well established methods of fertility preservation have been introduced, including embryo cryopreservation, gonadal shielding during radiotherapy, trachelectomy, and ovarian transposition. (Table 2)

Standard methods	Experimental methods
Embryo cryopreservation	Oocyte cryopreservation
Gonadal shielding during radiation therapy	Ovarian cryopreservation and transplantation
Ovarian transposition (oophoropexy)	Ovarian suppression with GnRH analogs or antagonists
Trachelectomy	
Other conservative gynecologic surgery	

**Table 2.** Fertility preservation options in females [17]

Embryo cryopreservation is a well-established technique and the current live-birth rate per transfer using frozen thawed embryos is 35.6% in US women under 35-year-old (<http://www.sart.org>, 2008). Embryo freezing should initially be considered for fertility preservation treatment if there is adequate time for ovarian stimulation and a partner or donor sperm.

Gonadal shielding during radiotherapy should be considered if radiotherapy is required for cancer treatment. For example, radiation plays an important role in the management of breast cancer, which can be classified into four categories: 1) Primary radiotherapy in breast-conserving treatment for early breast cancer, 2) Adjuvant radiotherapy after mastectomy for high-risk patients, 3) Radiotherapy after neo-adjuvant chemotherapy in locally-advanced breast cancers, and 4) Palliative radiotherapy for metastatic disease [18].

Trachelectomy is also an accepted method for the surgical management of early stage cervical cancer in women who wish to preserve their fertility. Cervical cancer is one of the most common cancers in women younger than 40 along with breast cancer, non-Hodgkin's lymphoma, and leukemia [19]. Indications for trachelectomy are described in Table 3.

- 
1. Women who desire to preserve fertility (age<40-45)
  2. Stage Ia1<sup>a</sup> (with lymph vascular space involvement), Ia2, Ib1
  3. Lesion size ≤2 cm
  4. Histologically squamous, adeno-, or adenosquamous carcinoma
  5. No upper cervical canal involvement of cancer
  6. No evidence of lymph node metastasis
- 

<sup>a</sup>Conization, Ia1 without lymph vascular space involvement

---

**Table 3.** Indications for trachelectomy in cervical cancer [20]

Plante *et al.* [20] reported their experience with 125 patients who underwent vaginal radical trachelectomy. The recurrence rate of cervical cancer after trachelectomy was less than 5% and the death rate was less than 2%. Having lesions sized >2 cm was a strong risk factor for recurrence. A total of 58 women out of 125 conceived a total of 106 pregnancies, and of those, 73% of pregnancies reached the third trimester, of which, in turn, 75% gave birth at term. Overall, 13.5% of patients were associated with fertility problems.

Ovarian transposition can be performed not only for preservation of fertility but also for prevention of premature ovarian failure in cervical cancer patients who require radiotherapy. It is necessary for gynecologic oncologists to understand the field of radiotherapy to prepare for ovarian transposition. Usually, standard fields are used with the upper field border on the fourth/fifth lumbar vertebra [21]. It is widely accepted that surgical transposition should be at least 3 cm above the upper border of the radiation field [22]. Hwang *et al.* [23] reported that a location for the transposed ovary higher than 1.5 cm above the iliac crest is recommended to avoid ovarian failure after primary or adjuvant pelvic radiotherapy in cervical cancer.

To date, the remaining methods are considered to be experimental, although the oocyte survival rate (81% vs. 68%) and live-birth rate per embryo transfer (34% vs. 14%) of oocyte cryopreservation with vitrification is significantly higher than with conventional slow freezing methods [24]. Noyes *et al.* [25] asked whether it is “time to remove the experimental label” of oocyte cryopreservation. Because of the improvements in advanced technologies including freezing-thawing methods, a new guideline is necessary to update fertility preservation specialists with the latest knowledge.

## 6. Ovarian cryopreservation and transplantation

The first ovarian transplant with cryopreserved ovarian tissue was performed by Dr. Kutluk Oktay in 1999 [25]. In 2004, Dr. Donnez reported the first successful birth from slow, or controlled rate, frozen ovarian tissue [26]. In 1997, samples of ovarian cortex were taken from a woman with Hodgkin’s lymphoma and cryo-preserved in a rate freezer and stored in liquid nitrogen. After chemotherapy the patient had premature ovarian failure. In 2003, after freeze-thawing, orthotopic autotransplantation of ovarian cortical tissue was done by lapa-



roscopy and five months after reimplantation signs indicated recovery of regular ovulatory cycles. A viable intrauterine pregnancy was confirmed eleven months after reimplantation that resulted in a live birth.

The first case report of nonautologous orthotopic transplantation of fresh ovarian tissue was from one monozygotic twin sister to the other, who had suffered from premature ovarian failure [27]. The procedure resulted in a live birth. These investigators have repeated this procedure in 10 sets of monozygotic twins [28], and successfully transplanted an intact fresh ovary [29]. Others have reported a live birth after allografting of ovarian cortex between monozygotic twins with Turner mosaic and discordant ovarian function [30].

Human ovarian tissues have been xenotransplanted to immunodeficient mice, with subsequent ovulation [31-33]; however, aberrant microtubule organization and chromatin patterns observed during the maturation process are of significant concern [34,35]. The risk of contamination with trans-species retroviral infections also needs to be addressed prior to testing this experimental approach clinically.

Successful pregnancies after ovarian tissue cryopreservation followed by transplantation have been reported in some human studies [36-39]. Transplantation of cryopreserved ovarian tissue has shown to be a potential method for recovery of ovarian function [2]. Advantages of ovarian tissue transplantation are not only preservation of fertility but also restoration of endocrine function in young women after cancer treatment.

Ovarian tissue cryopreservation and reimplantation is a main option for preserving the fertility of cancer patients who need cancer treatments without delay or do not want to undergo ovarian stimulation. For prepubertal girls diagnosed with cancer, ovarian tissue freezing is the only option for fertility preservation. To date, a total of 17 babies from 12 patients have been born worldwide from ovarian tissue cryopreservation and reimplantation [3]. Based on the site of reimplantation of cryopreserved ovarian tissue, transplantation can be classified into two different types: orthotopic (e.g. to remaining ovarian tissue or pelvic peritoneum) and heterotopic (e.g. in the abdominal wall, forearm, and chest wall) transplantation.

## **7. Sex steroid production from cryopreserved and reimplanted ovary**

### **7.1. Types of sex steroids**

Sex steroids or gonadal steroids are steroid hormones that interact with androgen or estrogen receptors [40]. Their effects are mediated by slow genomic mechanisms through nuclear receptors as well as by fast nongenomic mechanisms through membrane-associated receptors and signaling cascades [41]. The non-steroid hormones such as luteinizing hormone (LH), follicle-stimulating hormone (FSH) and gonadotropin-releasing hormone (GnRH) are usually not considered as sex hormones, even though they mainly play sex-related roles.

Natural sex steroids are produced by the gonads, adrenal glands, or conversion from other sex steroids in other tissues such as the liver or fat [42].

Two main classes of sex steroids are androgens and estrogens and their human derivatives are testosterone and estradiol, respectively. Progesterone is also regarded as a third class of sex steroids. Progesterone is the most important and only naturally-occurring human progestogen. In general, androgens are considered "male sex hormones", while estrogens and progestagens are considered as "female sex hormones".

Androgens	Estrogens	Progestogens
Anabolic steroids	Estradiol	Progesterone
Androstenedione	Estriol	
Dehydroepiandrosterone	Estrone	
Dihydrotestosterone		
Testosterone		

**Table 4.** Types of sex steroids [40,41]

Transplantation of cryopreserved ovarian tissue has shown to be a potential method for recovery of ovarian function [2]. Advantages of ovarian tissue transplantation are not only preserving fertility but also restoring endocrine function in young women after cancer treatment. In a review of successful orthotopic frozen-thawed ovarian reimplantation, restoration of ovarian activity was shown to be between 3.5 and 6.5 months after transplantation [43]. Oktay *et al.* [2,44] reported the first case of laparoscopic transplantation of frozen-thawed ovarian tissue into the pelvic sidewall with subsequent ovulation and subcutaneous ovarian transplantation to the forearm, which resulted in preserved endocrine function and follicular development. Approximately 10 weeks after ovarian transplantation to the forearm, endocrine function was restored with decreased FSH and LH levels, and cyclical variation of peripheral estradiol levels [44]. Silber reported the recovery of ovarian function in terms of recovery of menstrual cycles and hormone levels (FSH) approximately 80 to 140 days after reimplantation from their fresh and frozen transplant cases [3].

## 7.2. The longevity of ovarian transplantation

Dr. Kim reported the longevity of ovarian grafts in five cancer patients who underwent heterotopic autotransplantation of frozen-thawed ovarian tissue between 2001 and 2011 [45]. The age of patients at the time of ovarian transplantation was between 30 and 40. Cryopreserved ovarian tissue (for 1–10 years) was rapidly thawed and transplanted into the space between the rectus sheath and muscle. Endocrine function was measured by monthly blood tests (FSH, LH, E<sub>2</sub>, progesterone and testosterone) and ultrasound after transplantation. The monitoring was continued until the cessation of endocrine function had been confirmed by consecutive blood tests (E<sub>2</sub><20 pg/mL; FSH≥35 IU/L).

Endocrine function was restored in all patients between 12–20 weeks after ovarian tissue transplantation. Four patients required the second transplantation one to two years after the



first transplantation. The duration of endocrine function after the second transplantation was much longer (9–84 months). The longest duration of endocrine function was observed in a patient who underwent ovarian transplantation in 2003 and 2004 after radiotherapy for cervical cancer. Even for more than seven years after transplantation, endocrine function had not ceased (FSH 9.5 IU/L, E<sub>2</sub> 108 pg/mL). She underwent three IVF cycles which resulted in four embryos.

The longevity of grafted ovarian tissue has been debated for many years. The duration of endocrine function after frozen-thawed ovarian tissue transplantation is still uncertain. Dr. Kim described that the endocrine function lasting for seven years can be established with heterotopic transplantation of cryobanked human ovarian tissue. This information will benefit young cancer survivors with premature ovarian failure.

In the UK, researchers indicated that the duration of graft life is greater than 7 years [46]. Undoubtedly, the length of time the grafts function will depend on several factors [45, 46].

- 
1. Age at the time of cryopreservation
  2. Baseline ovarian reserve
  3. History of cancer treatment
  4. Techniques of ovarian tissue preparation
  5. Freezing-thawing protocols
  6. Number of cortical tissue grafted
  7. Techniques and sites of transplantation
  8. Degree of ischemia after transplantation
  9. Number of follicles in the ovarian grafts
- 

**Table 5.** Factors associated with the longevity of grafted ovarian tissue [45,46]

One of the most important factors may be the number of eggs' survival during the freezing-thawing and revascularization process. If one makes an assumption that one third of an ovary is transplanted into the patient (the proportion quoted in the linked report), and that during revascularization two thirds of the immature eggs are lost,[47,48] then we can calculate how many immature eggs are likely to survive the freeze/thaw and revascularization process to ensure that >1000 non-growing follicles are successfully transplanted (the number present at the menopause) [49,50]. It has been estimated that at age 36.9 years insufficient non-growing follicles will remain after cryopreservation to sustain ovarian function in 40% of the healthy population. At age 40 years we estimate that 60% of healthy women will be unlikely to benefit from ovarian cryopreservation.

We need to assess the indications and risk-benefit analysis carefully for future patients. The value of ovarian cryopreservation to preserve fertility for young cancer survivors may be proven, however the indications for those who should be offered this new technology are not yet established.

### 7.3. Ovarian function after isotransplantation

Dr. Silber reported his novel experience about the nine identical twin pairs discordant for premature ovarian failure that underwent their orthotopic ovarian isotransplantation between 2004 and 2008 [27]. All of these fresh ovary transplants were successful, resulting in 11 healthy babies in 7 of the 9 recipients. The same surgical techniques were then applied to 3 frozen ovary tissue transplants, up to 14 years after the ovary had been frozen, resulting in 3 more healthy babies [28,29].

Silber *et al* reported that the first rise in estradiol was observed 71 days after implantation of fresh tissue [27]. In their published series, the time to first menses after transplantation ranged between 65 to 93 days [28]. Recipients routinely resumed ovulatory menstrual cycles and normal Day 3 serum FSH levels by 4.5 months. Most conceived naturally (three of them twice or three times from the same graft). The duration of function of fresh ovarian grafts indicated minimal oocyte loss from ischemia period. Grafts of just modest portions of ovarian tissue have lasted >7 years. *In vitro* studies suggest that vitrification of ovarian tissue may be an improvement over the 70% oocyte viability loss from slow freeze [29].

This newly favorable experience is not limited just to one center [43]. Equally robust results are being experienced in Brussels, Paris, Spain, Denmark and Israel. Frozen ovarian grafts with the slow freeze technique in Denmark are lasting over 5 years and many spontaneous pregnancies have been reported without IVF techniques or other adjuvant treatment. To date, 28 healthy babies have been born from ovarian tissue grafting including fresh/frozen ovarian tissue transplantation, and most involved no IVF, and resulted from just regular intercourse without any other treatment [2].

### 7.4. Ovarian function after allogenic transplantation

Recently, autologous orthotopic transplantation of cryopreserved ovarian tissue has resulted in live births. Dr. Donnez reported three cases of ovarian transplantation between two genetically non-identical sisters in 2010 [51]. The three recipient patients presented with iatrogenic premature ovarian failure due to chemotherapy and radiotherapy. The recipients had all received bone marrow and ovarian tissue from their HLA-compatible sisters in each case.

None of the recipients were on any steroid or immunosuppressive therapy and all presented with documented premature ovarian failure. Their ovaries were atrophic and serial sections of biopsies failed to demonstrate the presence of any follicles. Premature ovarian failure was confirmed by very high FSH and LH levels, very low estradiol concentrations and the absence of follicles in large biopsies removed from the patients' atrophic ovaries during transplantation. For the first time, successful restoration of ovarian function after transplantation of ovarian cortex between genetically different sisters was reported.

The time interval between implantation of ovarian tissue and follicular development was found to be between 3.5 and 6 months, consistent with the previous study by Silber *et al* [27]. The time interval of 6 months observed in patients 1 was associated with a low follicular reserve in the donor (aged 32 years), and a delay for the primordial follicles development. In Patients 2 and 3, the follicular density of the donor ovarian specimen was high and recovery

of ovarian activity occurred 3.5 months after reimplantation, as observed in the series of Silber and Gosden [28], who also observed an interval of 3.5 months after reimplantation of fresh ovarian cortex between monozygotic twins. In addition, the ischemic period was recently estimated to be between 3 and 5 days by van Eyck *et al.* [52,53].

### 7.5. Endocrine function after upper extremity ovarian autotransplantation in girls

Upper-extremity ovarian autologous transplantation was used in three girls (ages 5, 2, and 1 year) diagnosed with Wilms tumor undergoing abdominal/pelvic radiation therapy at the tertiary pediatric medical center in the US [54]. Data were available for follow-up for 20-25 years.

Patients presented with Wilms tumor underwent surgical resection. Each patient underwent ovarian autotransplantation to upper extremity in order to move ovarian tissue out of the radiation field. Subjects 1 and 2 had thin slices from 1 ovary placed in the arm and subject 3 had a free transfer of the entire ovary into the axilla. Subjects 1 and 2 showed spontaneous follicular development of the autotransplanted ovarian tissue. They had fluctuating gonadotropin and estradiol levels until age 29 and 26, respectively; spontaneous menses until age 29 and 26; and cessation of spontaneous menses with elevated gonadotropins and low estradiol levels at age 30 and 26. Subject 3 had severe monthly axillary pain, and the ovary was transferred back into the pelvis. She then had ovarian dysfunction with intermittent spontaneous ovarian activity until age 25.

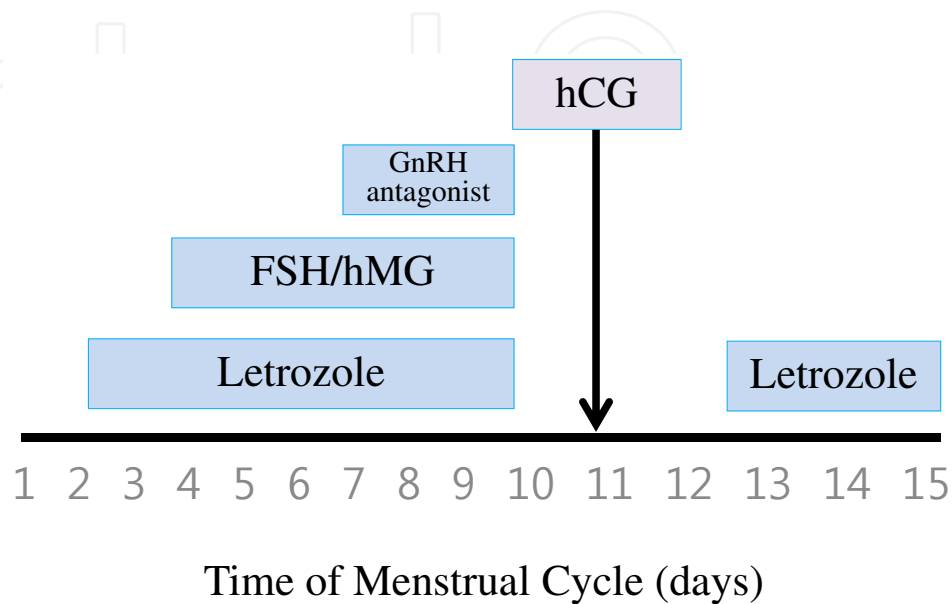
Ovarian autotransplantation to the upper extremity resulted in long-term sex steroid production for spontaneous puberty, menarche, follicular development, and menses with fluctuating gonadotropin and ovarian sex steroid levels and follicular activity that lasted for 13-15 years.

## 8. Breast cancer and sex steroid hormone

Breast cancer is the most common cancer in women of reproductive age in the US [55]. Most women with breast cancer require adjuvant chemotherapy including cyclophosphamide. At an average age of 40, administration of cyclophosphamide, methotrexate, and 5-Fluorouracil (CMF) or Adriamycin, cyclophosphamide and Taxol (AC+T) resulted in amenorrhea in 20% to 100% or 37% to 77% of patients followed up for 1 year after adjuvant chemotherapy, respectively [56].

For fertility preservation, ovarian stimulation with gonadotropins for embryo or oocyte cryopreservation results in excessive levels of estrogen production. To reduce estrogen exposure during ovarian stimulation in hormone-dependent cancer, a novel protocol using letrozole (a third generation aromatase inhibitor) and gonadotropins was developed by Dr. Oktay [57]. (Figure 1) Use of aromatase inhibitors became increasingly common in the treatment of breast cancer [58]. They have also recently been introduced for ovulation induction. When compared to clomiphene cycles, they produce comparable peak estradiol levels or

those even lower than the natural cycle. Because of their dual effects, they can be used in breast and endometrial cancer patients for ovulation induction. Tamoxifen cannot be used in those women during ovarian stimulation as it is antagonistic to the endometrium. Based on our unpublished data, long-term follow-up for up to 7 years, the letrozole protocol showed safe, efficient, and age-appropriate pregnancy success rates.



**Figure 1.** Protocol for ovarian stimulation with letrozole and gonadotropins in women with breast cancer [57]- NOTE TO TECH ED: please replace this figure with the one in zipped folder when formatting the chapter (Ana Pantar) and remove this comment

In North America, Europe, and other parts of the world, aromatase inhibitors are available for the treatment of postmenopausal breast cancer, but not for ovulation induction. Letrozole and anastrozole are triazole (antifungal) derivatives that are potent, reversible, competitive, nonsteroidal aromatase inhibitors [59,60]. These drugs inhibit estrogen levels by 97 to 99 percent at doses of 1 to 5 mg/day which result in estrogen concentrations below the level detected by most sensitive immunoassays. Nonsteroidal aromatase inhibitors are completely absorbed after oral administration and cleared mainly by the liver. Mean terminal half-life is approximately 45 hours (range 30 to 60 hours). Exemestane is a steroidal aromatase inhibitor and its circulating half-life is approximately nine hours, but the inhibitory effect is potentially much longer because its effect on aromatase is irreversible [61].

Aromatase inhibitors are generally well tolerated and known side effects are hot flashes, nausea/vomiting, headache, back pain, and leg cramps [60,62,63]. These adverse effects were reported in older breast cancer patients who were given the drugs on a daily basis over several months in Phase III trials. Very few withdrew from the trials because of drug-related adverse effects [64,65]. In the clinical experience, using a short course of aromatase inhibitor for induction of ovulation in young healthy women had fewer side effects than with clomiphene citrate [57,66].

Ovarian stimulation for embryo or oocyte cryopreservation should be started within the first four days of the menstrual cycle. Depending on whether the referral is made before or after breast surgery, usually no more than one or two cycles of ovarian stimulation can be performed without delaying chemotherapy in women with breast cancer [13]. This delay is generally acceptable as multiple studies have shown no effect on survival or recurrence in breast cancer patients if chemotherapy had been initiated as late as 12 weeks after breast surgery [67,68].

In fertility preservation cycles, since there is limited time available prior to the onset of chemotherapy in breast cancer patients [13], ovarian stimulation is often performed with higher doses of gonadotropins to maximize the number of embryos or oocytes cryopreserved, and to increase the likelihood of future pregnancies. In the previous study, we compared a low dose FSH start (=150 IU) with a high dose (>150 IU) in women with breast cancer undergoing fertility preservation with letrozole and found that the higher dose FSH stimulation in letrozole cycles did not improve pregnancy outcomes, and may be associated with a lower live birth rate [69]. Thus we concluded that higher dose FSH stimulation with letrozole in women with breast cancer did not improve reproductive outcomes and may be associated with lower live birth rates. In addition, it may increase estrogen exposure as well as the costs of fertility preservation.

## 9. Ovarian suppression using GnRH agonist or antagonist to prevent gonadal damage

Given the current evidence, both the efficacy and safety of the use of GnRH agonists or antagonists during chemotherapy for prevention of gonadal damage are controversial. Several studies have suggested a decreased incidence of amenorrhea with the use of GnRH agonists throughout chemotherapy; however, most have been non-randomized or small sample sized studies. Only five randomized trials have been completed.

Badawy *et al.* [70] and Del Mastro *et al.* [71] demonstrated the positive effect of GnRH agonists on the resumption of menses and ovulation; however, Leonard *et al.* [72], Gerber *et al.* [73], and Munster *et al.* [74] revealed that there was no impact of GnRH agonists on the prevention of early menopause or ovarian function.

Recently, Partidge [75] reported that women who are interested in future fertility and the providers who are assisting them should not depend on GnRH agonist treatment during chemotherapy for preservation of menstrual and ovarian function or fertility. There is one randomized ongoing study by the Southwest Oncology Group, called the Prevention of Early Menopause Study, a large international multicenter trial. This study will provide additional complementary information including biomarkers of ovarian reserve and rates of long-term amenorrhea or premature ovarian failure in women with or without ovarian suppression throughout treatment period.



## 10. Conclusions

Based on our review, we believe that ovarian cryopreservation and reimplantation in women diagnosed with cancer before cancer treatments is an effective option to preserve their fertility and to restore gonadal endocrine function. Restoration of ovarian activity in terms of sex steroid production was observed in almost all cases of ovarian reimplantation. All pregnancies were reported from the orthotopic autotransplantation, but none from the heterotopic autotransplantation. Restoration of endocrine function has been demonstrated consistently in both methods, although heterotopic sites may not provide an optimal environment for pregnancy. Physicians should consider the life span and the time period for the initiation of sex steroid production of transplanted ovarian tissue in order to provide an exact data, especially when counseling and making a treatment plan for cancer survivors.

## Author details

Sanghoon Lee<sup>1</sup> and Seung-Yup Ku<sup>2\*</sup>

\*Address all correspondence to: [jyhsyk@snu.ac.kr](mailto:jyhsyk@snu.ac.kr)

1 Department of Obstetrics and Gynecology, Korea University College of Medicine, Seoul, Korea

2 Department of Obstetrics and Gynecology, Seoul National University College of Medicine, Seoul, Korea

## References

- [1] Knapp CA, Quinn GP. Healthcare provider perspectives on fertility preservation for cancer patients. *Cancer Treat Res.* 2010;156:391–401.
- [2] Oktay K, Karlikaya G. Ovarian function after transplantation of frozen, banked autologous ovarian tissue. *NEngl J Med.* 2000;342:1919.
- [3] Sibling SJ. Ovarian cryopreservation and transplantation for fertility preservation. *Mol Hum Reprod* 2012;18:59-67.
- [4] Rodriguez-Wallberg KA, Oktay K. Options on fertility preservation in female cancer patients. *Cancer Treat Rev* 2012;38:354-61.
- [5] Sklar C. Maintenance of ovarian function and risk of premature menopause related to cancer treatment. *J Natl Cancer Inst Monogr* 2005:25-7.



- [6] Wallace WH, Thomson AB, Saran F, Kelsey TW. Predicting age of ovarian failure after radiation to a field that includes the ovaries. *Int J RadiatOncolBiolPhys* 2005;62:738-44.
- [7] Wo JY, Viswanathan AN. Impact of radiotherapy on fertility, pregnancy, and neonatal outcomes in female cancer patients. *Int J RadiatOncolBiolPhys* 2009;73:1304-12.
- [8] Green DM, Sklar CA, Boice JD Jr, Mulvihill JJ, Whitton JA, Stovall M, et al. Ovarian failure and reproductive outcomes after childhood cancer treatment: results from the Childhood Cancer Survivor Study. *J ClinOncol* 2009;27:2374-81.
- [9] Chemaitilly W, Mertens AC, Mitby P, Whitton J, Stovall M, Yasui Y, et al. Acute ovarian failure in the childhood cancer survivor study. *J ClinEndocrinolMetab* 2006;91:1723-8.
- [10] Oktem O, Oktay K. Fertility preservation for breast cancer patients. *SeminReprod Med* 2009;27:486-92.
- [11] Azim A, Rauch ER, Ravich M, Witkin S, Oktay K. Ovarian reserve is impaired in cancer patients with normal baseline FSH who previously received chemotherapy as determined by response to controlled ovarian stimulation and anti-mullerian hormone measurements: a controlled study. *FertilSteril* 2006;86 (Suppl 2):S123-S4.
- [12] Lee S, Heytens E, Moy F, Ozkavukcu S, Oktay K. Determinants of access to fertility preservation in women with breast cancer. *FertilSteril* 2011;95:1932-6.
- [13] Lee S, Ozkavukcu S, Heytens E, Moy F, Oktay K. Value of early referral to fertility preservation in young women with breast cancer. *J ClinOncol* 2010;28:4683-6.
- [14] Quinn GP, Vadaparampil ST, Lee JH, Jacobsen PB, Bepler G, Lancaster J, et al. Physician referral for fertility preservation in oncology patients: a national study of practice behaviors. *J ClinOncol* 2009;27:5952-7.
- [15] Forman EJ, Anders CK, Behera MA. Pilot survey of oncologists regarding treatment-related infertility and fertility preservation in female cancer patients. *J Reprod Med* 2009;54:203-7.
- [16] Arnuand GM, Rodriguez-Wallberg KA, Wettergren L, Ahlgren J, Enblad G, Høglund M, et al. Sex differences in fertility-related information received by young adult cancer survivors. *J ClinOncol* 2012;30:2147-53.
- [17] Lee SJ, Schover LR, Partridge AH, Patrizio P, Wallace WH, Haggerty K, et al. American Society of Clinical Oncology recommendations on fertility preservation in cancer patients. *J ClinOncol* 2006;24:2917-31.
- [18] Suh CO. Radiotherapy for breast cancer. *J Korean Med Assoc* 2003;46:503-11.
- [19] Jemal A, Murray T, Ward E, Samuels A, Tiwari RC, Ghafoor A, et al. Cancer statistics, 2005. *CA Cancer J Clin* 2005;55:10-30.

- [20] Plante M, Gregoire J, Renaud MC, Roy M. The vaginal radical trachelectomy: an update of a series of 125 cases and 106 pregnancies. *GynecolOncol* 2011;121:290-7.
- [21] Marnitz S, Kohler C, Schneider A, Seiler F, Hinkelbein W. Interindividual variability of lymph drainages in patients with cervical cancer. Implication on irradiation planning. *StrahlentherOnkol* 2006;182:80-5.
- [22] Martin JR, Kodaman P, Oktay K, Taylor HS. Ovarian cryopreservation with transposition of a contralateral ovary: a combined approach for fertility preservation in women receiving pelvic radiation. *FertilSteril* 2007;87:189 e5-7.
- [23] Hwang JH, Yoo HJ, Park SH, Lim MC, Seo SS, Kang S, et al. Association between the location of transposed ovary and ovarian function in patients with uterine cervical cancer treated with (postoperative or primary) pelvic radiotherapy. *FertilSteril* 2012;97:1387-93 e2.
- [24] Noyes N, Porcu E, Borini A. Over 900 oocyte cryopreservation babies born with no apparent increase in congenital anomalies. *Reprod Biomed Online* 2009;18:769-76.
- [25] Oktay K, Oktem O. Ovarian cryopreservation and transplantation for fertility preservation for medical indications: report of an ongoing experience. *FertilSteril*. 2008;93(3): 762-8.
- [26] Donnez J, Dolmans MM, Demylle D, et al. Livebirth after orthotopic transplantation of cryopreserved ovarian tissue. *Lancet* 2004;364:1405-10
- [27] Silber SJ, Lenahan KM, Levine DJ, et al. Ovarian transplantation between monozygotic twins discordant for premature ovarian failure. *N Engl J Med* 2005; 353:58.
- [28] Silber SJ, Gosden RG. Ovarian transplantation in a series of monozygotic twins discordant for ovarian failure. *N Engl J Med* 2007; 356:1382.
- [29] Silber SJ, Grudzinskas G, Gosden RG. Successful pregnancy after microsurgical transplantation of an intact ovary. *N Engl J Med* 2008; 359:2617.
- [30] Donnez J, Dolmans MM, Squifflet J, et al. Live birth after allografting of ovarian cortex between monozygotic twins with Turner syndrome (45,XO/46,XX mosaicism) and discordant ovarian function. *FertilSteril* 2011; 96:1407.
- [31] Oktay K, Newton H, Mullan J, Gosden RG. Development of human primordial follicles to antral stages in SCID/hpg mice stimulated with follicle stimulating hormone. *Hum Reprod* 1998; 13:1133.
- [32] Oktay K, Newton H, Gosden RG. Transplantation of cryopreserved human ovarian tissue results in follicle growth initiation in SCID mice. *FertilSteril* 2000;73:599.
- [33] Gook DA, McCully BA, Edgar DH, McBain JC. Development of antral follicles in human cryopreserved ovarian tissue following xenografting. *Hum Reprod* 2001; 16:417.
- [34] Lucifero D, Mertineit C, Clarke HJ, et al. Methylation dynamics of imprinted genes in mouse germ cells. *Genomics* 2002; 79:530.

- [35] Kim SS, Kang HG, Kim NH, et al. Assessment of the integrity of human oocytes retrieved from cryopreserved ovarian tissue after xenotransplantation. *Hum Reprod* 2005; 20:2502.
- [36] Donnez J, Dolmans MM, Demylle D, et al. Livebirth after orthotopic transplantation of cryopreserved ovarian tissue. *Lancet* 2004;364:1405-10
- [37] Meirow D, Levron J, Eldar-Geva T, et al. Pregnancy after transplantation of cryopreserved ovarian tissue in a patient with ovarian failure after chemotherapy. *N Engl J Med* 2005;353:318-21
- [38] Demeestere I, Simon P, Emiliani S, et al. Fertility preservation: successful transplantation of cryopreserved ovarian tissue in a young patient previously treated for Hodgkin's disease. *Oncologist* 2007;12:1437-42
- [39] Andersen CY, Rosendahl M, Byskov AG, et al. Two successful pregnancies following autotransplantation of frozen/thawed ovarian tissue. *Hum Reprod* 2008;23:2266-72
- [40] Guerriero G. Vertebrate sex steroid receptors: evolution, ligands, and neurodistribution. *Ann N Y Acad Sci.* 2009;1163:154-68.
- [41] Thakur MK, Paramanik V. Role of steroid hormone coregulators in health and disease. *Horm Res.* 2009;71(4):194-200.
- [42] Brook CG. Mechanism of puberty. *Horm Res.* 1999;51Suppl 3:52-4.
- [43] Donnez J, Silber S, Andersen CY, Demeestere I, Piver P, Meirow D, et al. Children born after autotransplantation of cryopreserved ovarian tissue. a review of 13 live births. *Ann Med* 2011;43:437-50.
- [44] Oktay K, Economos K, Kan M, Rucinski J, Veeck L, Rosenwaks Z. Endocrine function and oocyte retrieval after autologous transplantation of ovarian cortical strips to the forearm. *JAMA* 2001;286:1490-3.
- [45] Kim SS. Assessment of long term endocrine function after transplantation of frozen-thawed human ovarian tissue to the heterotopic site: 10 year longitudinal follow-up study. *J Assist Reprod Genet.* 2012;29:489-493
- [46] Wallace WH, Kelsey TW, Anderson RA. Ovarian cryopreservation: experimental or established and a cure for the menopause? *Reprod Biomed Online* 2012;25:93-95
- [47] Baird, D.T., Webb, R., Campbell, B.K., Harkness, L.M., Gosden, R.G. Long-term ovarian function in sheep after ovariectomy and transplantation of autografts stored at -196°C. *Endocrinology* 1999;140: 462-471.
- [48] Demirci, B., Lornage, J., Salle, B., Frappart, L., Franck, M., Guerin, J.F., 2001. Follicular viability and morphology of sheep ovaries after exposure to cryoprotectant and cryopreservation with different freezing protocols. *Fertil. Steril.* 2001;75:754-762.
- [49] Faddy, M.J., Gosden, R.G. A model conforming the decline in follicle numbers to the age of menopause in women. *Hum Reprod.* 1996;11:1484-1486.

- [50] Wallace, W.H., Kelsey, T.W. Human ovarian reserve from conception to the menopause. *PLoS One* 2010;5:e8772.
- [51] Donnez J, Squifflet J, Pirard C, Jadoul P, Dolmans MM. Restoration of ovarian function after allografting of ovarian cortex between genetically non-identical sisters. *Hum Reprod* 2010;25:2489-2495
- [52] Van Eyck AS, Jordan B, Gallez B, Heilier JF, Van Langendonck A, Donnez J. Electron paramagnetic resonance as a tool to evaluate human ovarian tissue reoxygenation after xenografting. *Fertil Steril* 2009;92:374-381.
- [53] Van Eyck AS, Bouzin C, Feron O, Romeu L, Van Langendonck A, Donnez J, Dolmans MM. Both host and graft vessels contribute to revascularization of xenografted human ovarian tissue in a murine model. *Fertil Steril* 2010;93:1676-1685.
- [54] Laufer MR, Upton J, Schuster SR, Grier H, Emans SJ, Diller L. Ovarian tissue autologous transplantation to the upper extremity for girls receiving abdominal/pelvic radiation: 20-year follow-up of reproductive endocrine function. *J Pediatr Adolesc Gynecol* 2010;23:107-110
- [55] American Cancer Society: Cancer Facts & Figures 2009. [Internet]. Atlanta: American Cancer Society Inc.; c2009 [2012 Jun 27]. Available from: <http://www.cancer.org/acs/groups/content/@nho/documents/document/500809webpdf.pdf>.
- [56] Sonmezer M, Oktay K. Fertility preservation in young women undergoing breast cancer therapy. *Oncologist* 2006;11:422-34.
- [57] Azim AA, Costantini-Ferrando M, Oktay K. Safety of fertility preservation by ovarian stimulation with letrozole and gonadotropins in patients with breast cancer: a prospective controlled study. *J Clin Oncol* 2008;26:2630-5
- [58] Goss PE, Ingle JN, Martino S, Robert NJ, Muss HB, Piccart MJ, et al. A randomized trial of letrozole in postmenopausal women after five years of tamoxifen therapy for early-stage breast cancer. *N Engl J Med* 2003;349:1793-802.
- [59] Buzdar A, Howell A. Advances in aromatase inhibition: clinical efficacy and tolerability in the treatment of breast cancer. *Clin Cancer Res* 2001; 7:2620-2635.
- [60] Winer EP, Hudis C, Burstein HJ, et al. American Society of Clinical Oncology technology assessment on the use of aromatase inhibitors as adjuvant therapy for women with hormone receptor-positive breast cancer: status report 2002. *J Clin Oncol* 2002; 20(15):3317-3327.
- [61] Mauras N, Lima J, Patel D, et al. Pharmacokinetics and dose finding of a potent aromatase inhibitor, aromasin (exemestane), in young males. *J Clin Endocrinol Metab* 2003; 88:5951-5956.
- [62] Buzdar A, Jonat W, Howell A, et al. Anastrozole, a potent and selective aromatase inhibitor, versus megestrol acetate in postmenopausal women with advanced breast

- cancer: results of overview analysis of two phase III trials. Arimidex Study Group. *J ClinOncol* 1996; 14:2000-2011.
- [63] Marty, M, Gershanovich, M, Campos, B, Romien, G, et al. Aromatase inhibitors, a new potent, selective aromatase inhibitor superior to aminoglutethimide in postmenopausal women with advanced breast cancer previously treated with antioestrogens. *Proc Am SocClinOncol* 1997; 16:156.
- [64] Hamilton A, Piccart M. The third-generation non-steroidal aromatase inhibitors: a review of their clinical benefits in the second-line hormonal treatment of advanced breast cancer. *Ann Oncol* 1999; 10:377-384.
- [65] Goss PE. Risks versus benefits in the clinical application of aromatase inhibitors. *EndocrRelat Cancer* 1999; 6:325-332.
- [66] Oktay K. Further evidence on the safety and success of ovarian stimulation with letrozole and tamoxifen in breast cancer patients undergoing in vitro fertilization to cryopreserve their embryos for fertility preservation. *J ClinOncol* 2005;23:3858-3859
- [67] Lohrisch C, Paltiel C, Gelmon K, Speers C, Taylor S, Barnett J, et al. Impact on survival of time from definitive surgery to initiation of adjuvant chemotherapy for early-stage breast cancer. *J ClinOncol* 2006;24:4888-94.
- [68] Cold S, Durning M, Ewertz M, Knoop A, Moller S. Does timing of adjuvant chemotherapy influence the prognosis after early breast cancer? Results of the Danish Breast Cancer Cooperative Group (DBCG). *Br J Cancer* 2005;93:627-32
- [69] Lee S, Oktay K. Does higher starting dose of FSH stimulation with letrozole improve fertility preservation outcomes in women with breast cancer. *FertilSteril* 2012 Jul 6. [Epub ahead of print]
- [70] Badawy A, Elnashar A, El-Ashry M, Shahat M. Gonadotropin-releasing hormone agonists for prevention of chemotherapy-induced ovarian damage: prospective randomized study. *FertilSteril* 2009;91:694-7.
- [71] Del Mastro L, Boni L, Michelotti A, Gamucci T, Olmeo N, Gori S, et al. Effect of the gonadotropin-releasing hormone analogue triptorelin on the occurrence of chemotherapy-induced early menopause in premenopausal women with breast cancer: a randomized trial. *JAMA* 2011;306:269-76.
- [72] Leonard RC, Adamson D, Anderson R, Ballinger R, Bertelli G, Coeman RE, et al. The OPTION trial of adjuvant ovarian protection by goserelin in adjuvant chemotherapy for early breast cancer [abstract 590]. *J ClinOncol* 2010;28 (Suppl 15):89s.
- [73] Gerber B, von Minckwitz G, Stehle H, Reimer T, Felberbaum R, Maass N, et al. Effect of luteinizing hormone-releasing hormone agonist on ovarian function after modern adjuvant breast cancer chemotherapy: the GBG 37 ZORO study. *J ClinOncol* 2011;29:2334-41.
- [74] Munster PN, Moore AP, Ismail-Khan R, Cox CE, Lacevic M, Gross-King M, et al. Randomized trial using gonadotropin-releasing hormone agonist triptorelin for the

preservation of ovarian function during (neo)adjuvant chemotherapy for breast cancer. *J ClinOncol* 2012;30:533-8.

- [75] Partridge AH. Ovarian suppression for prevention of premature menopause and infertility: empty promise or effective therapy? *J ClinOncol* 2012;30:479-81.

IntechOpen

IntechOpen



