

# We are IntechOpen, the world's leading publisher of Open Access books Built by scientists, for scientists

## 4,800

Open access books available

## 122,000

International authors and editors

## 135M

Downloads

Our authors are among the

## 154

Countries delivered to

## TOP 1%

most cited scientists

## 12.2%

Contributors from top 500 universities

**WEB OF SCIENCE™**Selection of our books indexed in the Book Citation Index  
in Web of Science™ Core Collection (BKCI)

Interested in publishing with us?  
Contact [book.department@intechopen.com](mailto:book.department@intechopen.com)

Numbers displayed above are based on latest data collected.

For more information visit [www.intechopen.com](http://www.intechopen.com)

---

# Total Joint Arthroplasty for Hemophilia

---

Hideyuki Takedani

Additional information is available at the end of the chapter

<http://dx.doi.org/10.5772/53232>

---

## 1. Introduction

Hemophilia is hereditary x-chromosomal recessive disorders. Hemophilia A is caused by deficiency or absence of coagulation factor VIII and hemophilia B is caused by that of coagulation factor IX. The prevalence is reported as one in 5000 in the male population and one in 10000 overall. These diseases are classified into three categories according to serum coagulation factor activity; severe (<1%), moderate (1-5%), or mild (>5%). The particular hemophilic manifestation is intra-articular bleeding. Intra-articular bleeding is usually occurred by trauma but also often spontaneously. Approximately 5% of first bleeding episodes in hemophilic boys are into a joint. The average age of first intra-articular bleeding is  $1.91 \pm 0.91$  years old and the median age of that is 1.63 years old [1]. A joint in which four or more recurrent bleedings have occurred in the prior 6 months is defined as target joint. In the United States, 2.3% of children 2-5 years of age enrolled in the Universal Data Collection Project have target joints [2]. Most of target joints have hemophilic synovitis, which is characterized by inflammation, angiogenesis and fibrosis [3] and develop hemophilic arthroplasty which is characterized by cartilage and bone destruction.

The average annual intra-articular bleeding number were higher in the episodic-therapy group than in the prophylaxis group and the relative risk of MRI-detected joint damage with the episodic was 6-fold greater compared with prophylactic group [4]. Therefore, it is a clear the relationship between intra-articular bleeding and hemophilic arthropathy. However, the number and volume of intra-articular bleedings which result in target joint and arthropathy is not understood. Experimental pathgenetic studies were reported and many points of the pathogenesis are still remained as poorly understood points [2,5,6].

As for radiological evaluation methods of hemophilic arthropathy, there are three major systems. De Palma classification is classical progressive system and popular in Japan. This system classified hemophilic arthropathy from grade 0 (normal) to grade IV (end-stage) [7].

Arnold-Hilgartner classification is also classical progressive system and classified from stage 0 (normal) to stage V (end-stage) [8]. Pettersson score is recommend additive scoring system by World Federation of Hemophilia (WFH) [9]. 8 categories in this system have 0 (normal) to 2 (worse) points and totally scored from 0 (normal) to 13 points (worst). There are classical and authorized good systems but it may need to improve them, because their inter-observer reliabilities were poor [10].

As for MRI evaluation methods, there were several reports since 2000 [11-13], and WFH recommended MRI scale and modified version were published from the international prophylaxis study group [14, 15].

The causative mechanism of hemophilia was recognized in the 1950s [16], and concentrates for coagulation factor replacement became generally available since 1960s, however the easy administration of the concentrates resulted in transmission of viral infection including hepatitis C (HCV) and Human immunodeficiency virus infection (HIV) during the 1980s [17]. Also, the appearance of allo-immune antibody (inhibitor) against deficient coagulation factor is severe adversity. Product development such as recombinant concentrates has especially improved therapeutic safety and availability [18], resulting in the possibility of performing elective orthopedic surgery and prevention of bleeding episodes. The routine administration of prophylactic treatment has undoubtedly resulted in a greatly improvement in the quality of life and life expectancy of hemophilic patients. However, many of young hemophilic adults still have severe destructive joints as a result of repeated intra-articular bleeding during their early years.

For hemophilic arthropathy, there are two major surgical options which are synovectomy for early stage (hemophilic synovitis) and total joint arthroplasty (TJA) for end stage. At progressive stage, there are not good surgical options so that several usual orthopedic options are tried: anti-inflammatory drugs, corticosteroids, joint infusion of hyaluronic acid or corticosteroids, braces and rehabilitation. However many of them are progressed to end-stage. Total joint arthroplasty (TJA) is effective procedure in the management of hemophilic arthropathy for them [19].

## 2. Major surgery for hemophilia

In our hospital, 126 major surgeries for 80 patients have been performed between June 2006 and June 2012 in which were 96 surgeries for 63 hemophilia A, 28 surgeries for 16 hemophilia B, and 2 surgeries for 2 other coagulation disorders. 18 surgeries with inhibitor were included. The average age at operation was 39.03 years (13 ~ 60 years). As for virus infection, HBs antigen positive ratio was 1.5% (2/126 surgeries), HCV antibody positive ratio was 89.7% (113/126), HIV antibody positive ratio was 33.3% (42/126) and both HCV and HIV antibody positive ratio was 31.7% (41/126).

Major surgery such as TJA is never easily undertaking in hemophilic patients. It required bleeding control at peri-operative periods, management for viral infection and inhibitor, and treatment for complication subsequently to bleeding.

As for bleeding control, guidelines were published [20, 21], in which the aim serum factor level at peri-operative period is explained clearly. However it is difficult without the support of hematologists so that major surgeries are usually performed at hemophilia centers.

As for HIV infection, CD4 cell counts had been important factor as major influence factor on bacterial infection in the early literatures [22-25]. HIV medical treatment has drastically improved during the last decade. In the recent literatures [26-29] and our experience, there was no evidence to suggest that bacterial deep infection at surgical site was influenced on the decline of CD4 cell counts. However HIV-positive patients whose CD4 cell counts is less than 50 cell/mm<sup>3</sup> have a considerable risk of the occurrence of opportunistic infection at peri-operative periods.

Most hemophilia adult patients infected hepatitis C virus at 1980s and long period of the virus carrier results in hepatic insufficiency and hepatoma. The treatment for chronic hepatitis has also improved, however it was not good enough to control it. According to our clinical experiences, severe hepatic insufficiency has been influenced on the fatal ratio after major surgery.

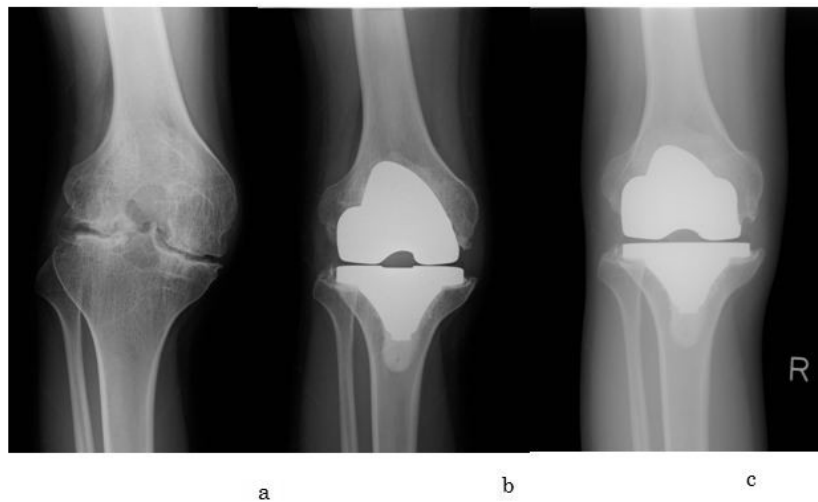
Between 10-30% of patients with hemophilia A and 2-5% of patients with hemophilia B develop an inhibitor to FVIII or FIX [30]. Intra-articular bleedings in inhibitor patients have a more negative impact on their joint function and daily life. They desire to reduce the pain and improve function at affected joint. However surgical treatments may be deferred until patients suffer from increasingly severe pain and progressive physical incapacity find no other options, due to the higher bleeding risks associated with surgery [31]. In fact, there are some surgical reports for inhibitors, but many of them are a few cases reports [32]. Guidelines for inhibitor [33] were also published, but bleeding control plan at peri-operative periods is not established. We believe surgical treatments for inhibitor should be performed at hemophilic center.

Delayed wound healing is the major complication subsequently to bleeding. In hemophilia B mice, dermal wound healing is delayed and can be treated with factor IX replacement therapy to restore thrombin generation. This delay is associated with bleeding into granulation tissue [34]. In our hospital, there were 3.3% delayed wound healings.

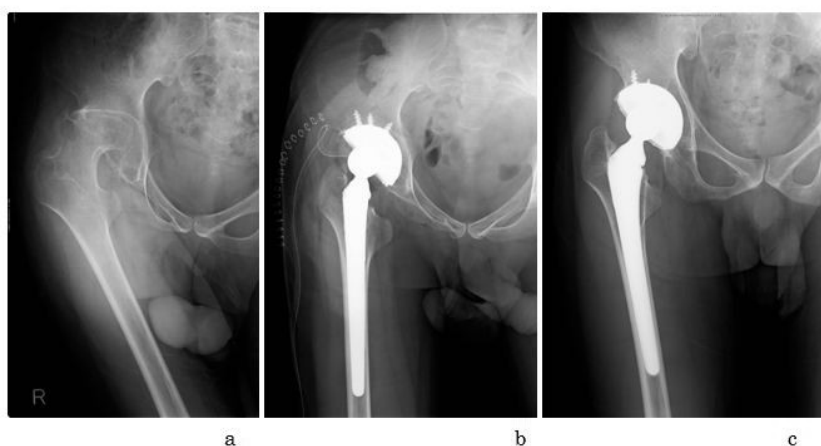
### **3. Total joint arthroplasty**

TJA has been available as a final option in the end-stage hemophilic arthropathy with significantly reduced quality of life. The major objectives of TJA are to reduce the pain in the affected joint and improve the joint function. These effects are influenced on the adjacent joints beneficially. In addition, the frequency and number of the intra-articular bleeding is significantly reduced. Thereby, their life-style and quality of life significantly improved. The indications are adult hemophilia patients with severe destructive arthropathy and subjective dysfunction. Adult means the patient's epiphyses are closed. We have performed total hip arthroplasty for 18 years boy. Their dysfunction have been started from childhood and

made worse gradually. They are satisfied to live on their ability even if they have severe destructive arthropathies. These cases are not indication subjectively. Total knee or hip arthroplasty (TKA, THA) are generally performed and total elbow and ankle arthroplasty (TEA, TAA) are rarely performed. However the most common affected joints are elbow, knee and ankle. The average of operation is around forty [35, 36]. In our hospital, 81 total joint arthroplasty were performed included 59 TKAs, 20 THAs, 1TEA and 1TAA and average age were 44.5. (figure 1, 2)



**Figure 1.** A 18-year-old hemophilia A patient without inhibitor. No virus infection. Severe hemophilic arthropathy of the right knee. His knee range of motion was improved at four years after surgery: extension was -30 degrees to 0 degrees and flexion was 90 degrees to 110 degrees. (a): pre-operative radiography; (b) at one month radiography (c) at four year radiography



**Figure 2.** A 23-year-old hemophilia A patient with inhibitor. HCV is positive. Severe hemophilic arthropathy of the right hip. His back pain and tilted pelvis are improved after surgery. (a): pre-operative radiography; (b) just operative radiography (c) at five year radiography

As for surgical technique, we believe orthopedic surgeons do not need special skills when deficient factor level is kept with concentrate adequately. However, there are some careful points on TJA for hemophilia, in addition to the aforementioned surgical risks for hemophilia, which are higher infection rate, higher revision rate or shorter durability (table 1), and the occurrence of deep venous thrombosis (DVT).

Authers	Year	Number of TJA	Average of Follow-up (years)	Infection rate (%)	Aseptic loosening rate (%)
Cohen et al	2000	21 TKAs	5.6	10	0
Norian et al	2002	53 TKAs	5	13.2	9.4
Sheth et al	2004	14 TKAs	6.4	0	0
Goddard et al	2010	70 TKAs	9.2	1.5	8.6
Habermann et al	2007	15 THAs	11	6.7	6.7
Miles et al	2008	34 THAs	6.3	3	9
Yoo et al	2009	23 THAs	7.7	0	4.8
Powell et al	2005	35 TKAs 16 THAs	6.9	TKA:14.3 THA:6.3	0
Wang et al	2012	40 TKAs 18 THAs	10.7	TKA:13 THA:0	TKA:2.5 THA:5.6

**Table 1.** Infection and aseptic loosening rate after TJA in hemophilia including current study [35-38,40-44]

As for the infection after TJA, most reports show a deep infection rate of 10-16% [35-41], and our result shows much lower infection rate of 2.5 (2/81). However, these rates are higher than infection rate of 1-2% consistently reported in the literatures in the general population [45]. HIV infection had been important factor as major influence factor on bacterial infection, however the recent clinical results suggest there is no difference in the infection rate between HIV positive and negative. It is unclear why the ratio after TJA for hemophilia is much higher than that for non-hemophilia. The hypothesis that much frequent venous self-infusion is influenced on highly infection rate [40] is one of possibilities, but there is no evidence as yet.

As for durability, there are a few long clinical reports. When revision for aseptic mechanical failure was considered as endpoint, the survival rate for 40 TKAs at 10 years was 93%. The survival rate for 18 THAs at 8.5 years was 89% [36]. According to clinical result for 60 TKAs at a mean follow-up of 9.2 years, Kaplan-Meier analysis using infection and aseptic loosening as endpoint showed the survival rate at 20 years to be 94.0% [35]. These survival rates were similar to that in young non-hemophilia patients [46,47], however we believe it is not good enough rate for young hemophilic patients who have multi-arthropathy.

Hemophilia patients are often considered that their risk of DVT is lower by virtue of their bleeding disorder. However, they have as same risk of DVT as non-hemophilic patients, because the coagulation factor level is normalized by administration of concentrates at peri-operative periods. In our hospital, all patients use compression devices and not administrate drugs such as heparin or aspirin. Thrombosis has been checked by ultrasound and not detected at pre- and post-operation. Subclinical DVT was observed in 10% of hemophilia patients undergoing major orthopedic surgery [48]. According to the simple questionnaires survey at hemophilia treatment center in the United States, 78% provided thrombo-prophylaxis to selected patients. Of those providing of thrombo-prophylaxis, 67% used compression stocking or devices, 24% used low molecular weight heparin, 1% fondaparinux, 3% unfractionated heparin, 4% warfarin and 1% aspirin [49].

Finally, the cost of hemophilia treatment is major economical concern. The concentrate cost is occupied of major part of TJA cost and it is depended on the patient body weight. And the price of concentrates and insurance situation are quite differences internationally, so that we introduced our situation in this chapter. The cost is too expensive to performed surgery without insurance coverage, however Japanese general health insurance is covered with most of the cost, fortunately. The cost of TJA at peri-operative periods about two weeks is forty to fifty thousand dollars for average Japanese hemophilic patients without inhibitor (50-70kg). The cost for inhibitor cases is about 5 to 10-folds.

Total joint arthroplasty for hemophilia is a challenging surgery and never a simple undertaking, however hemophilia patient need to improve their life style and release severe pain. We believe it is a safe and effective procedure in the management of hemophilic arthropathy at hemophilia centers.

## Author details

Hideyuki Takedani\*

Address all correspondence to: [takedani@ims.u-tokyo.ac.jp](mailto:takedani@ims.u-tokyo.ac.jp)

Department of Joint Surgery Research Hospital of the Institute of Medical Science The University of Tokyo 4-6-1 Shiroganedai, Minato-ku, Tokyo 108-8639, Japan

## References

- [1] Pollmann, H., Richter, H., Ringkamp, H., & Jurgens, H. (1999). When are children diagnosed as having severe haemophilia and when do they start to bleed? A 10 -year single-centre PUP study. *Eur J Pediatr.*, Dec, 158(3), S166-170.

- [2] Valentino, L. A., Hakobyan, N., Enockson, C., et al. (2012). Exploring the biological basis of haemophilic joint disease: experimental studies. *Haemophilia.*, May, 18(3), 310-318.
- [3] Stein, H., & Duthie, R. B. (1981). The pathogenesis of chronic haemophilic arthropathy. *J Bone Joint Surg Br*, 63B(4), 601-9.
- [4] Manco-Johnson, M. J., Abshire, T. C., Shapiro, A. D., et al. (2007). Prophylaxis versus episodic treatment to prevent joint disease in boys with severe hemophilia. *N Engl J Med*, Aug 9, 357(6), 535-544.
- [5] Valentino, L. A., Hakobyan, N., Rodriguez, N., & Hoots, W. K. (2007). Pathogenesis of haemophilic synovitis: experimental studies on blood-induced joint damage. *Haemophilia*, Nov, 13(3), 10-13.
- [6] Roosendaal, G., & Lafeber, F. P. (2006). Pathogenesis of haemophilic arthropathy. *Haemophilia*, Jul, 12(3), 117-121.
- [7] De Palma, A. F., & Cotler, J. M. (1956). Hemophilic arthropathy. *AMA Arch Surg*, Feb, 72(2), 247-250.
- [8] Arnold, W. D., & Hilgartner, M. W. (1977). Hemophilic arthropathy. Current concepts of pathogenesis and management. *J Bone Joint Surg Am*, Apr, 59(3), 287-305.
- [9] Pettersson, H., Ahlberg, A., & Nilsson, I. M. (1980). A radiologic classification of hemophilic arthropathy. *Clin Orthop Relat Res.* [149], Jun, 153-9.
- [10] Takedani, H., Fujii, T., Kobayashi, Y., Haga, N., Tatsunami, S., & Fujii, T. (2011). Inter-observer reliability of three different radiographic scores for adult haemophilia. *Haemophilia.*, Jan, 17(1), 134-138.
- [11] Nuss, R., Kilcoyne, R. F., Rivard, G. E., & Murphy, J. (2000). Late clinical, plain X-ray and magnetic resonance imaging findings in haemophilic joints treated with radiosynoviorthesis. *Haemophilia.*, Nov, 6(6), 658-663.
- [12] Funk, M. B., Schmidt, H., Becker, S., et al. (2002). Modified magnetic resonance imaging score compared with orthopaedic and radiological scores for the evaluation of haemophilic arthropathy. *Haemophilia.*, Mar, 8(2), 98-103.
- [13] Kilcoyne, R. F., & Nuss, R. (2003). Radiological assessment of haemophilic arthropathy with emphasis on MRI findings. *Haemophilia*, 9(1), 57-63, discussion 63-54.
- [14] Lundin, B., Babyn, P., Doria, AS, et al. (2005). Compatible scales for progressive and additive MRI assessments of haemophilic arthropathy. *Haemophilia*, Mar, 11(2), 109-115.
- [15] Lundin, B., Manco-Johnson, M. L., Ignas, D. M., et al. (2012). An MRI scale for assessment of haemophilic arthropathy from the International Prophylaxis Study Group. *Haemophilia*, Jul 5.



- [16] Biggs, R., Douglas, AS, Macfarlane, R. G., Dacie, J. V., & Merskey, Pitney W. R. (1952). Christmas disease: a condition previously mistaken for haemophilia. *Br Med J.*, Dec 27, 2(4799), 1378-1382.
- [17] Mannucci, P. M., & Tuddenham, E. G. (2001). The hemophilias--from royal genes to gene therapy. *N Engl J Med.*, Jun 7, 344(23), 1773-1779.
- [18] Key, N. S., & Negrier, C. (2007). Coagulation factor concentrates: past, present, and future. *Lancet.*, Aug 4, 370(9585), 439-448.
- [19] Takedani, H., Mikami, S., Abe, Y., Kin, H., & Kawasaki, N. (2000). [Total hip and knee arthroplasty for arthropathy in a hemophiliac]. *Rinsho Ketsueki.*, Feb,, 41(2), 97-102.
- [20] Kasper, C. K. (2000). Protocols for the treatment of haemophilia and von Willebrand disease. *Haemophilia.*, Jul,, 6(1), 84-93.
- [21] Guidelines for the management of hemophilia. (2005). Montreal: World Federation of Hemophilia.
- [22] Goddard, N. (2010). Joint replacement. In Lee CA, Berntop EE, Hoots WK. (ed.) *Textbook of Hemophilia second edition.* Cornwall: Wiley-Blackwell, 176-181.
- [23] Gregg-Smith, S. J., Pattison, R. M., Dodd, C. A., Giangrande, P. L., & Duthie, R. B. (1993). Septic arthritis in haemophilia. *J Bone Joint Surg Br.* May , 75(3), 368-370.
- [24] Wiedel, J. D., Luck, J. V., & Gilbert, M. S. (1989). Total knee arthroplasty in the patient with haemophilia; evaluation and long term results. *Gilbert MS, Greene WB. (ed.) Musculo-skletal problems in Hemophilia. New York National: Hemophilia foundation*, 152-157.
- [25] Ragni, M. V., Crossett, L. S., & Herndon, J. H. (1995). Postoperative infection following orthopaedic surgery in human immunodeficiency virus-infected hemophiliacs with CD4 counts  $\leq$  200/mm<sup>3</sup>. *J Arthroplasty.*, Dec, 10(6), 716-721.
- [26] Birch, N. C., Ribbans, W. J., Goldman, E., & Lee, CA. (1994). Knee replacement in haemophilia. *J Bone Joint Surg Br.*, Jan, 76(1), 165-166.
- [27] Phillips, A. M., Sabin, C. A., Ribbans, W. J., & Lee, C. A. (1997). Orthopaedic surgery in hemophilic patients with human immunodeficiency virus. *Clin Orthop Relat Res.* [343], Oct, 81-87.
- [28] Hicks, J. L., Ribbans, W. J., Buzzard, B., et al. (2001). Infected joint replacements in HIV-positive patients with haemophilia. *J Bone Joint Surg Br.*, Sep, 83(7), 1050-1054.
- [29] Rodriguez-Merchan, E. C., & Wiedel, J. D. (2002). Total knee arthroplasty in HIV-positive haemophilic patients. *Haemophilia.*, May, 8(3), 387-392.
- [30] Valentino, L. A., Cooper, D. L., & Goldstein, B. (2011). Surgical experience with rFVIIa (NovoSeven) in congenital haemophilia A and B patients with inhibitors to factors VIII or IX. *Haemophilia.*, Jul, 17(4), 579-589.

- [31] Jimenez-Yuste, V., Rodriguez-Merchan, E. C., Alvarez, M. T., Quintana, M., Fernandez, I., & Hernandez-Navarro, F. (2008). Controversies and challenges in elective orthopedic surgery in patients with hemophilia and inhibitors. *Semin Hematol.*, Apr, 45(2, 1), S64-67.
- [32] Takedani, H., Kawahara, H., & Kajiwara, M. (2010). Major orthopaedic surgeries for haemophilia with inhibitors using rFVIIa. *Haemophilia*, Mar, 16(2), 290-295.
- [33] Gringeri, A., & Mannucci, P. M. (2005). Italian guidelines for the diagnosis and treatment of patients with haemophilia and inhibitors. *Haemophilia*, Nov, 11(6), 611-619.
- [34] Monroe, D. M., Mackman, N., & Hoffman, M. (2010). Wound healing in hemophilia B mice and low tissue factor mice. *Thromb Res.*, Apr, 125(1), S74-77.
- [35] Goddard, N. J., Mann, H. A., & Lee, C. A. (2010). Total knee replacement in patients with end-stage haemophilic arthropathy: 25-year results. *J Bone Joint Surg Br.*, Aug, 92(8), 1085-1089.
- [36] Wang, K., Street, A., Dowrick, A., & Liew, S. (2012). Clinical outcomes and patient satisfaction following total joint replacement in haemophilia--23-year experience in knees, hips and elbows. *Haemophilia.*, Jan, 18(1), 86-93.
- [37] Cohen, I., Heim, M., Martinowitz, U., & Chechick, A. (2000). Orthopaedic outcome of total knee replacement in haemophilia A. *Haemophilia.*, Mar, 6(2), 104-109.
- [38] Powell, D. L., Whitener, C. J., Dye, C. E., Ballard, J. O., Shaffer, M. L., & Eyster, M. E. (2005). Knee and hip arthroplasty infection rates in persons with haemophilia: a 27 year single center experience during the HIV epidemic. *Haemophilia.*, May, 11(3), 233-239.
- [39] Silva, M., & Luck, J. V. Jr. (2005). Long-term results of primary total knee replacement in patients with hemophilia. *J Bone Joint Surg Am.*, Jan, 87(1), 85-91.
- [40] Sheth, DS, Oldfield, D., Ambrose, C., & Clyburn, T. (2004). Total knee arthroplasty in hemophilic arthropathy. *J Arthroplasty.*, Jan, 19(1), 56-60.
- [41] Norian, J. M., Ries, MD, Karp, S., & Hambleton, J. (2002). Total knee arthroplasty in hemophilic arthropathy. *J Bone Joint Surg Am.*, Jul, 84A(7), 1138-1141.
- [42] Habermann, B., Eberhardt, C., Hovy, L., Zichner, L., Scharrer, I., & Kurth, AA. (2007). Total hip replacement in patients with severe bleeding disorders A 30 years single center experience. *Int Orthop.*, Feb, 31(1), 17-21.
- [43] Miles, J., Rodriguez-Merchan, E. C., & Goddard, N. J. (2008). The impact of haemophilia on the success of total hip arthroplasty. *Haemophilia*, Jan, 14(1), 81-84.
- [44] Yoo, M. C., Cho, Y. J., Kim, K. I., Ramteke, A., & Chun, Y. S. (2009). The outcome of cementless total hip arthroplasty in haemophilic hip arthropathy. *Haemophilia*, May, 15(3), 766-773.

- [45] Bengtson, S., & Knutson, K. (1991). The infected knee arthroplasty. A 6-year follow-up of 357 cases. *Acta Orthop Scand.*, Aug, 62(4), 301-311.
- [46] Pospischill, M., & Knahr, K. (2005). Cementless total hip arthroplasty using a threaded cup and a rectangular tapered stem. Follow-up for ten to 17 years. *J Bone Joint Surg Br.*, Sep, 87(9), 1210-1215.
- [47] Seyler, T. M., Bonutti, P. M., Shen, J., Naughton, M., & Kester, M. (2006). Use of an alumina-on-alumina bearing system in total hip arthroplasty for osteonecrosis of the hip. *J Bone Joint Surg Am.*, Nov, 88(3), 116-125.
- [48] Hermans, C., Hammer, F., Lobet, S., & Lambert, C. (2010). Subclinical deep venous thrombosis observed in 10% of hemophilic patients undergoing major orthopedic surgery. May. *J Thromb Haemost.*, 8(5), 1138-1140.
- [49] Pradhan, S. M., Key, N. S., Boggio, L., & Pruthi, R. (2009). Venous thrombosis prophylaxis in haemophilics undergoing major orthopaedic surgery: a survey of haemophilia treatment centres. *Haemophilia.*, Nov, 15(6), 1337-1338.