

# We are IntechOpen, the world's leading publisher of Open Access books Built by scientists, for scientists

## 4,800

Open access books available

## 122,000

International authors and editors

## 135M

Downloads

Our authors are among the

## 154

Countries delivered to

## TOP 1%

most cited scientists

## 12.2%

Contributors from top 500 universities

**WEB OF SCIENCE™**Selection of our books indexed in the Book Citation Index  
in Web of Science™ Core Collection (BKCI)

## Interested in publishing with us? Contact [book.department@intechopen.com](mailto:book.department@intechopen.com)

Numbers displayed above are based on latest data collected.

For more information visit [www.intechopen.com](http://www.intechopen.com)

---

# Simultaneous Hybrid Revascularization by Carotid Stenting and Coronary Artery Bypass Grafting – The SHARP Study

---

Luigi Chiariello, Paolo Nardi and Francesco Versaci

Additional information is available at the end of the chapter

<http://dx.doi.org/10.5772/51731>

---

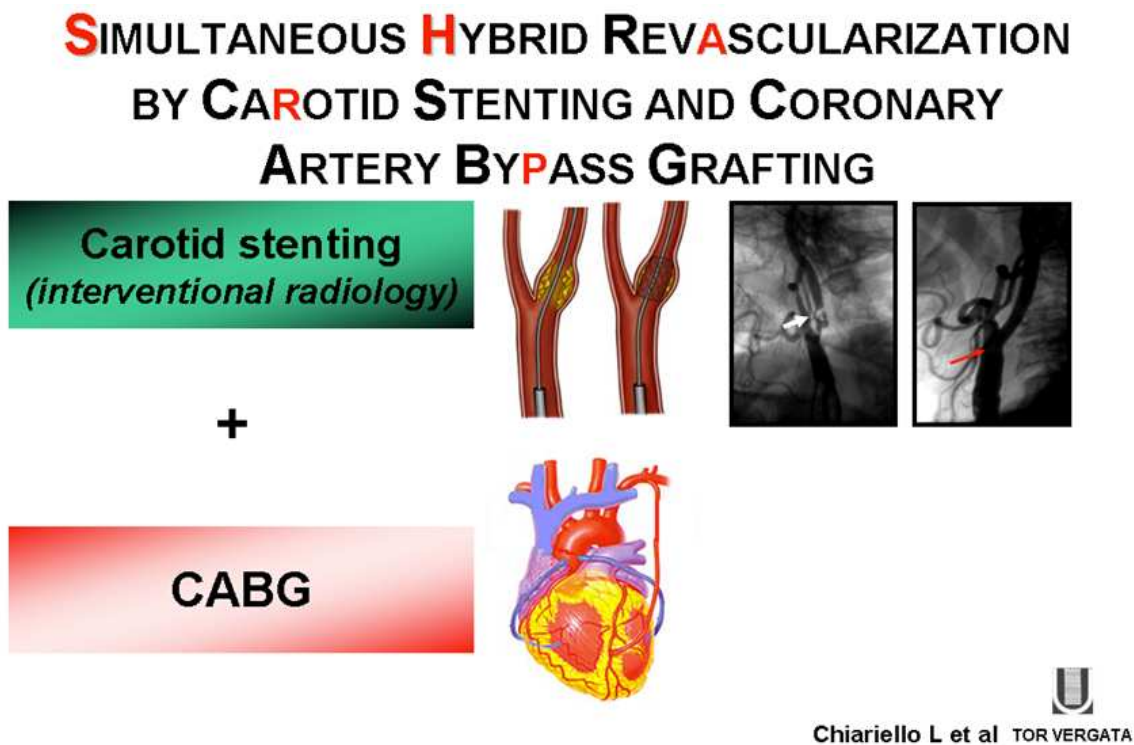
## 1. Introduction

Significant atherosclerotic disease affecting also the carotid artery system is encountered in a substantial number of patients undergoing coronary artery bypass grafting (CABG) [1]. The optimal surgical management to prevent stroke and cardiac events in this subset of patients remains unclear [2-5]. Among patients undergoing carotid endarterectomy (CEA) procedure in the Veterans Affairs Cooperative Study and in the Asymptomatic Carotid Atherosclerosis Study, respectively 20% and 49% of deaths were related to cardiac causes [4]. Similarly, the incidence of perioperative stroke in patients undergoing CABG is high in those affected by concomitant significant carotid disease [2-4]. The combined surgical approach is associated with an increased risk for mortality and morbidity [5]. In the staged surgical approach which addresses the carotid artery lesion with carotid endarterectomy first, followed several days to several weeks by CABG, incidence of perioperative stroke during CABG is reduced. However, the risk of myocardial infarction (MI) during the CEA procedure and in the period preceding CABG remains high (6%) [6]. Carotid artery stenting (CAS) using cerebral protection devices is rapidly evolving as an alternative to carotid endarterectomy [7], mainly for patients with severe carotid artery stenosis at high surgical risk [8], such as patients with coronary artery disease. A staged CAS-CABG approach has been recently proposed, but the need of a dual anti-platelet aggregation therapy lasting 3-4 weeks after stenting may represent a limitation for CABG [9].

## 2. Clinical experience

In our Institution in 2005 we introduced a new therapeutic strategy consisting of a simultaneous hybrid revascularization by CAS, immediately followed by CABG and cases

have been collected in the SHARP study (“Simultaneous hybrid revascularization by carotid artery stenting and coronary artery bypass grafting”) (Figure 1).



**Figure 1.**

As compared to the combined or staged surgical strategy currently adopted, the new hybrid approach CAS-CABG can reduce the incidence of serious perioperative adverse events and minimize surgical trauma. Surgical time and surgical trauma are shorter and less extensive as compared to combined CEA and CABG. Risk of MI is expected to be reduced, by shortening the interval between the two procedures [10, 11].

*Eligible criteria* for the enrolment: 1) concomitant critical carotid and coronary disease with coronary arteries suitable for CABG; 2) EuroSCORE  $\geq 5$ ; 3) a carotid artery stenosis  $\geq 50\%$  in the symptomatic disease or  $\geq 80\%$  in asymptomatic disease, as determined by the North American Symptomatic Carotid Endarterectomy Trial (NASCET) criteria [2]. The presence of carotid artery stenosis was evidenced by eco duplex scanning, then confirmed by catheter angiography and either magnetic resonance angiography or computed tomography (CT) scan angiography. A CT scan with or without angiographic dye, depending on preprocedural serum levels of creatinine, was performed in all patients to provide the maximum information regarding the aortic arch, the extent of aortic disease and the brain. In case of bilateral carotid artery stenosis the choice of the carotid artery to treat was made according to clinical criteria or to the severity and morphology of plaque in case of asymptomatic patients. In a very few instances of bilateral subocclusive carotid stenosis, successful bilateral CAS has been performed, immediately followed by CABG.

CAS procedures were performed under local anaesthesia through a percutaneous transfemoral access with the use of stents and protection devices. An introducer sheath was positioned in the

femoral artery, and heparin (1 mg /kg) was administered intra-arterially as a bolus. Then a guiding catheter was placed in the common carotid artery, proximally to the bifurcation. A distal filter protection was used in all patients. At the end of the procedure, patients were transferred directly to the operating room; CABG procedure was performed by means of normothermic cardiopulmonary bypass in the majority patients; in few cases off-pump CABG procedure was performed according with the choice of surgeon and comorbidity of patient.

### 2.1. Periprocedural pharmacological protocol

Aspirin 100 mg daily was started at least 2 days before CAS and daily after combined procedure was performed. Heparin was administered 1 mg /Kg as a bolus intra-arterially immediately before the stent implantation procedure and in the operating room before the cardiopulmonary bypass 2 mg/Kg as a bolus. Activated clotting time was checked every 30 minutes and was constantly maintained  $\geq 250$  sec. until the CABG procedure and  $\geq 480$  seconds until the end of the cardiopulmonary bypass. Tranexamic acid 2 g in bolus was administered as an antifibrinolytic agent over 20 minutes before sternotomy and then as endovenous infusion (0.5 g/h) until the patient was admitted to the postoperative intensive care unit in most of cases. Clopidogrel, 300 mg as a loading dose, followed by 75 mg per day for 1 month was started in the intensive care unit via a nasogastric tube 6 hours after the end of CABG surgery, providing that surgical bleeding from the thoracic drains had either stopped, or when it was less than 50 mL/hr for 3 consecutive hours from the sixth postoperative hour on (Figure 2).

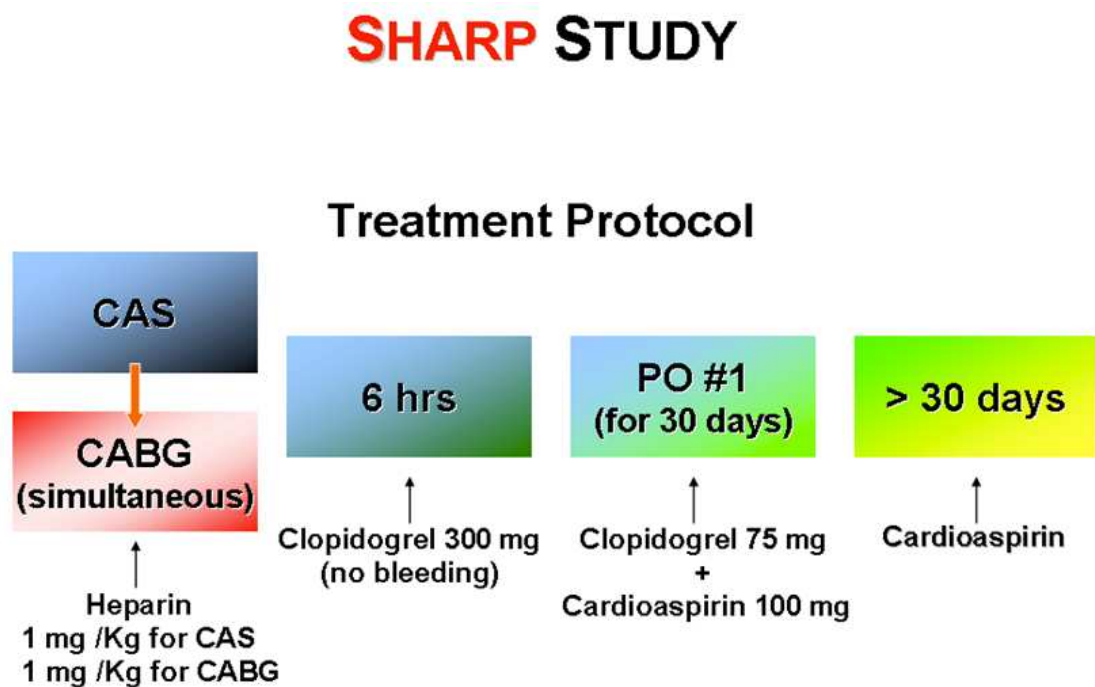


Figure 2.

The primary end points analyzed were the incidence of stroke, MI or death at 30 days after CAS-CABG and at a mid-term follow-up.

## 2.2. In-hospital and follow-up results

One-hundred and forty eight consecutive patients between January 2005 and November 2011 underwent CAS-CABG treatment. Mean age of patients was  $68 \pm 8$  years, means EuroSCORE  $8.6 \pm 2.5$ ; 22 patients (14.8%) were affected by symptomatic carotid disease; 67 (45%) had bilateral carotid stenosis. Left internal mammary artery was used as graft to the left anterior descending artery in all patients, bilateral mammary artery in 20 cases (13.5%). (Table 1).

Variable	Value
Number of patients	148
Age - years *	$68 \pm 8$
Male - n. † (%)	118 (79)
CCS pre-op - mean *	$2.7 \pm 1$
CCS class III/IV ‡ - n. (%)	93 (63)
Instable Angina- n. (%)	34 (23)
NYHA – mean *	$2.2 \pm 1$
Bilateral carotid stenosis- n. (%)	67 (45)
Previous Stroke o TIA - n. (%)	22 (14,8)
Surgical Risk**	$8.6 \pm 2.5$
Doppler velocity of internal carotid artery. - mean *	$325 \pm 40$ cm/sec

\*  $\pm$  DS

† n. = number

‡ Following classification of Canadian Cardiovascular Society (CCS).

§ Serum creatinin concentration  $>1,5$  mg/dl and clearance of creatinin  $<50$  ml/min.

\*\* Surgical Risk as EuroSCORE I (Eur J Cardiothor Surg 1999; 15:816-823).

MI= myocardial infarction; LVEF =Left ventricular ejection fraction.

**Table 1.** Preoperative details of patients.

*Clinical major outcomes* at 48 months are reported in Table 2

Operative mortality	1.3%
Periprocedural Stroke	1.3%
Perioperative MI	0
Re-exploration for bleeding	2.0%
Stroke, MI or death within 48 months	6.1%

MI = myocardial infarction

**Table 2.** Incidence of Clinical Events up to 48 months

In the first one hundred patients we report a mean follow-up of  $40 \pm 25$  months, 97% complete. In these patients we found at the end of follow-up 9 deaths whit a cumulative survival rate of 89%; furthermore we observed a very low mortality rate for cardiac late death ( $97 \pm 2\%$ ) and an high rate of freedom from fatal stroke (we registered just one case of fatal stroke during follow-up) ( $98 \pm 2\%$ ), MI ( $96 \pm 3\%$ ), and cerebrovascular events ( $90 \pm 6\%$ ). (Figure 3-6)

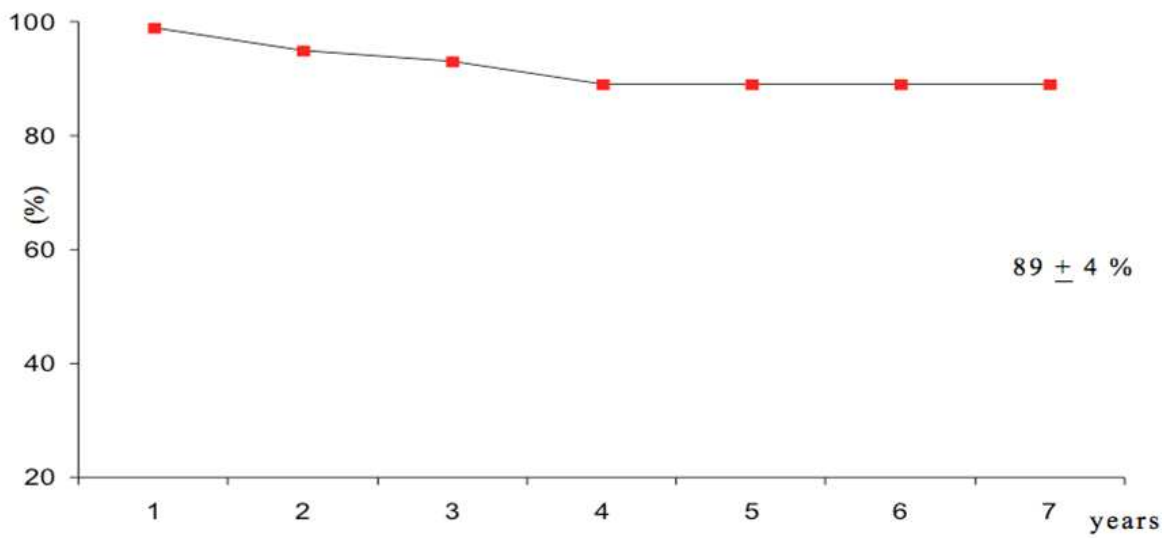


Figure 3. Survival rate at follow-up

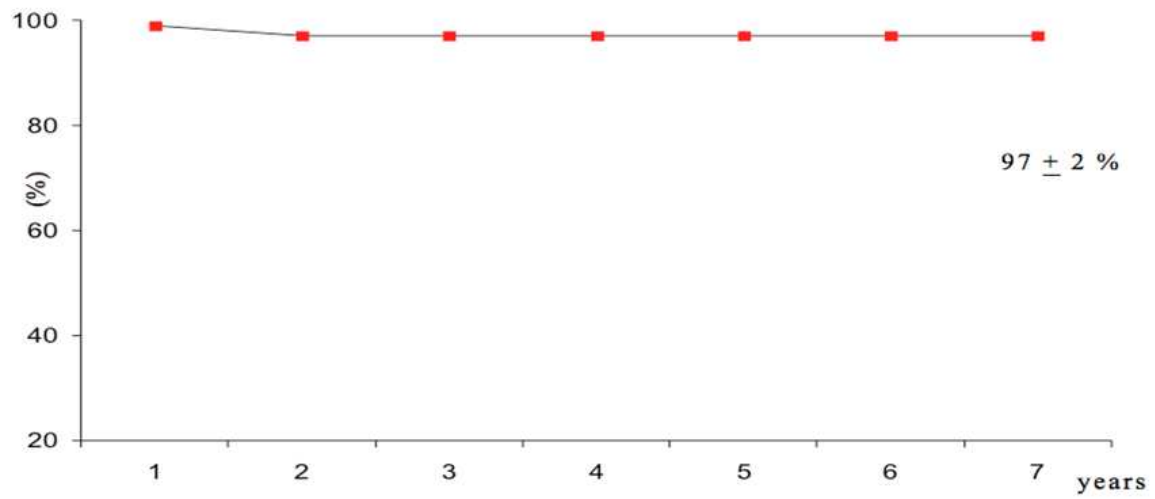


Figure 4. Kaplan Meier: Freedom from cardiac late death.

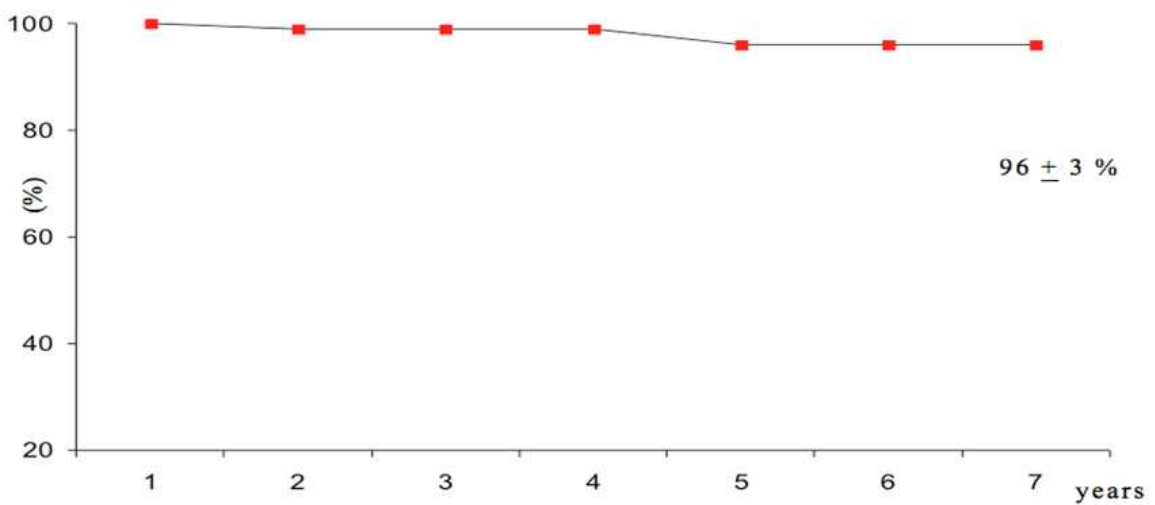
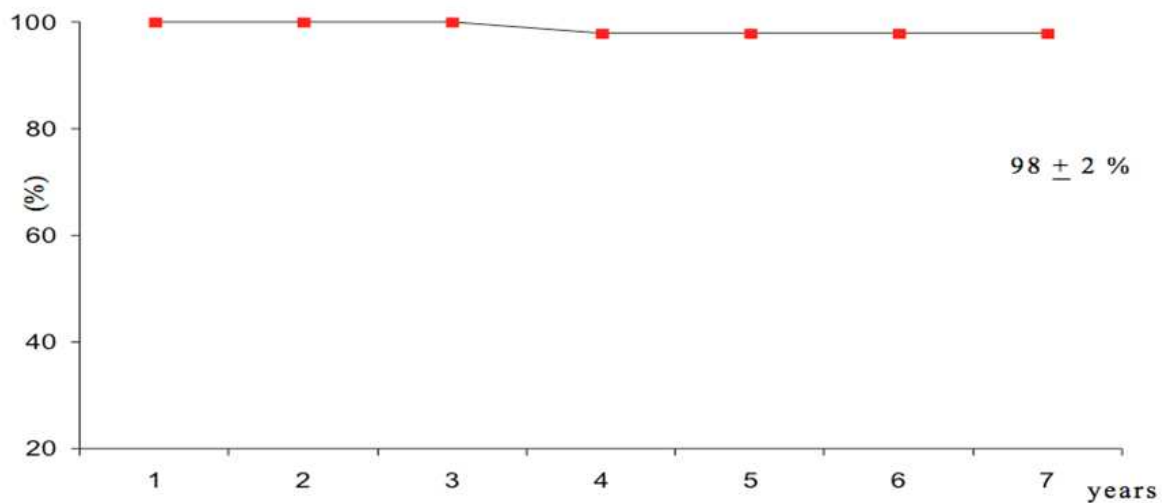


Figure 5. Kaplan Meier: Freedom from myocardial infarction.



**Figure 6.** Kaplan Meier: freedom from fatal stroke.

Internal carotid artery systolic blood flow during follow-up, showed significant improvement as compared to preoperative mean value. ( $67 \pm 10$  cm/sec vs.  $325 \pm 40$  cm/sec,  $P < .001$ ).

### 3. Comments

Neurological complications are relatively common after CABG, especially in high-risk patients. Carotid artery disease is significantly associated with a type I adverse neurological outcome (i.e., death due to stroke or hypoxic encephalopathy, nonfatal stroke, TIA, stupor, or coma at the time of discharge). Significant carotid artery stenoses are associated with up to 30% of early postoperative strokes following CABG. Preventing stroke and cardiovascular events after CABG is an important and complex issue. Concomitant carotid artery disease might be a major factor contributing to the occurrence of postoperative stroke. Moreover, carotid artery disease might be a marker of diffuse atherosclerosis, affecting also aortic arch, arch vessels, and intracranial vessels. In this high risk population, a simplified operative management like hybrid revascularization by CAS and CABG can minimize the negative impact of diffuse atherosclerotic disease. In fact, our findings indicate that, in patients with combined carotid artery disease and coronary artery disease, the proposed hybrid approach is a feasible therapeutic option with good immediate and short-term clinical results. The recently reported incidence of perioperative stroke and mortality following CEA and CABG is not negligible, ranging between 8.3% to 10.3% [12]. According to these results, in a previous series of 100 consecutive patients undergoing combined surgical revascularization at our Institution between 1991 and 2002, the 30-day mortality and stroke rate was 10% and 1.1%, respectively, with a mortality rate of 14.5% when the standard EuroSCORE was  $\geq 6$ , and 3.4% when it was lower than 6. These high-risk patients could be treated by an alternative strategy such as the hybrid approach proposed in this study. As compared with combined surgical revascularization, the hybrid strategy requires a shorter surgical time and less extensive surgical trauma, thus reducing cofactors known to increase morbidity and mortality. In particular, in high-risk patients for CEA, mainly due to severe CAD, the SAPPHIRE (Stenting and Angioplasty with Protection in Patients at High

Risk for Endarterectomy) trial showed that CAS was safer than carotid endarterectomy, because it had a lower postprocedural risk of myocardial infarction at 30 days as compared with surgery. This is likely to be the case mainly in patients with elevated surgical risk, such as the patients involved in the SHARP study. In particular, when the standard EuroSCORE is 8, as it is in our study, the surgical mortality rate might be greater than 10-12%. In this high-risk subset of patients, specific surgical complications are also increased up to 55% [13]. When both internal carotid arteries have significant stenosis, the risk of stroke after cardiac surgery is particularly high (25%). With the percutaneous hybrid approach, in our study the stroke rate was only 1.3%, considering that 45% of our patients had bilateral internal carotid artery disease. Potential adjunctive advantage of the simultaneous hybrid approach as compared with a combined surgical approach is that during the CAS procedure the patient is awake and the neurological outcome will be known instantly rather than after the patient emerges from general anaesthesia. Another most important finding of our study was the absence of periprocedural rate of MI. By observing the proposed protocol, the risk of MI, especially during carotid surgery or in the time elapsing between the two procedures (CEA or CAS and CABG after 3-4 weeks from carotid procedure), is virtually eliminated. In the two-stage procedure, the rate of MI when the patient is waiting for CABG after carotid artery procedure is about 5-6%. Finally our study also demonstrated safety of the pharmacological protocol and the timing of antiplatelet administration proposed: the bleeding rate after surgical intervention was low.

The proposed hybrid approach conferred an operative mortality rate comparable to that of isolated CABG.

In conclusions, the new hybrid approach is aiming to reduce risk of myocardial infarction, of bleeding after CABG and risk of death and major cerebrovascular complications. Reduced mortality and morbidity are expected to reduce also in-hospital stay and costs. Therefore, in patients with combined carotid artery and coronary artery disease at higher surgical risk, the proposed hybrid approach seems to be a possible, advantageous and safe alternative therapeutic strategy.

At a mid-term period, a high rate of event-free survival and freedom from cerebrovascular events can be expected.

### **Author details**

Luigi Chiariello\*, Paolo Nardi and Francesco Versaci  
*Cardiac Surgery Unit, Fondazione Policlinico Università Tor Vergata, Rome, Italy*

### **4. References**

- [1] Alboyans V, Lacroix P. Indications for carotid screening in patients with carotid artery disease. *Presse Med* 2009;38(6):977-86

---

\* Corresponding Author



- [2] Mackey WC, O'Donnell TF, Callow AD. Cardiac risk in patients undergoing carotid endarterectomy: impact on perioperative and long-term mortality. *J Vasc Surg* 1990;11:226-33.
- [3] North American Symptomatic Carotid Endarterectomy Trial Collaborators. Beneficial effect of carotid endarterectomy in symptomatic patients with high-grade of carotid stenosis. *N Engl J Med* 1991;325:445-53.
- [4] European Carotid Surgery Trialist' Collaborative Group. MRC European Carotid Surgical Trial: interim results for symptomatic patients with severe (70-99%) or with mild (0-29%) carotid stenosis. *Lancet* 1991;337:1235-43.
- [5] Executive committee for the asymptomatic carotid atherosclerosis study: Endarterectomy for Asymptomatic Carotid Atherosclerosis Study. *JAMA* 1995;273:1421-8.
- [6] Naylor AR, Cuffe RL, Rothwell PM, Bell PR. A systematic review of outcomes following staged and synchronous carotid endarterectomy and coronary artery bypass. *Eur J Vasc Endovasc Surg* 2003;25(5):380-9.
- [7] Brott TG, Hobson RW 2<sup>nd</sup>, Howard G et al. Stenting versus endarterectomy for treatment of carotid artery stenosis. *N Engl J Med* 2010;363(1):11-23.
- [8] Gum HS, Yadav JS, Fayad P et al. Long term results of carotid stenting versus endarterectomy in high risk patients. *N Engl J Med* 2008;358(15):1572-9.
- [9] Lopes DK, Mericle RA, Lanzino G et al. Stent placement for the treatment of occlusive atherosclerotic carotid artery disease in patients with concomitant coronary artery disease. *J Neurosurg* 2002; 96(3): 490-6.
- [10] Yadav JS, Wholey MH, Kuntz RE, Fayad P, Katzen BT, Mishkel GJ, Bajwa TK, Whitlow P, Strickman NE, Jaff MR, Popma JJ, Snead DB, Cutlip DE, Firth BG, Ouriel K; Stenting and Angioplasty with Protection in Patients at High Risk for Endarterectomy Investigators. Protected carotid-artery stenting versus endarterectomy in high-risk patients. *N Engl J Med* 2004;351:1493-501.
- [11] Chiariello L, Tomai F, Zeitani J, Versaci F. Simultaneous hybrid revascularization by carotid stenting and coronary artery bypass grafting. *Ann Thorac Surg* 2006;81:1833-5.
- [12] Versaci F, Del Giudice C, Scafuri A, Zeitani J, Gandini R, Nardi P, Salvati A, Pampana E, Sebastiano F, Romagnoli A, Simonetti G, Chiariello L. Sequential hybrid carotid and coronary artery revascularization: immediate and mid-term results. *Ann Thorac Surg* 2007;84:1508-14.
- [13] Hertze NR, Mascha EJ. A personal experience with coronary artery bypass grafting, carotid patching, and other factors influencing the outcome of carotid endarterectomy. *J Vasc Surg* 2006;43:959-68.
- [14] Fukuda M, Takagi Y. Application of preoperative risk severity evaluation system (EuroSCORE, European system for cardiac operative risk evaluation) for cardiac operative patients). *Masui* 2004;53:1149-54.