

We are IntechOpen, the world's leading publisher of Open Access books Built by scientists, for scientists

4,800

Open access books available

122,000

International authors and editors

135M

Downloads

Our authors are among the

154

Countries delivered to

TOP 1%

most cited scientists

12.2%

Contributors from top 500 universities



WEB OF SCIENCE™

Selection of our books indexed in the Book Citation Index
in Web of Science™ Core Collection (BKCI)

Interested in publishing with us?
Contact book.department@intechopen.com

Numbers displayed above are based on latest data collected.
For more information visit www.intechopen.com



A Novel Treatment Strategy for Infected Abdominal Aortic Aneurysms

Osamu Yamashita, Koichi Yoshimura,
Noriyasu Morikage, Akira Furutani and
Kimikazu Hamano

Additional information is available at the end of the chapter

<http://dx.doi.org/10.5772/52813>

1. Introduction

Infected abdominal aortic aneurysms are rare, but the symptoms are prone to become severe during the clinical course, and the prognosis is poor, with a high rate of rupture [1]. There are 2 objectives in the treatment of infected aortic aneurysms: prevention of aneurysm rupture and infection control. However, it is not easy to achieve both. No guideline has been established yet, and many issues such as diagnostic method, the method of administering antibiotics before and after operation, timing of the operation, and operative procedure remain to be improved. Regarding operative procedures, approaches such as the use of a rifampicin-soaked prosthetic graft, covering the prosthetic graft with the greater omentum, and anatomical reconstruction have been reported in recent years [1]. Nevertheless, postoperative infection control is never easy, and the treatment results of infected aneurysms are still unsatisfactory. Therefore, we have devised a treatment policy to control local infection in a stricter manner by introducing the pulse-irrigation method that uses a pulsatile irrigation device and a temporary abdominal wall closure method that uses the vacuum-assisted closure (VAC) technique in patients with strong intraperitoneal contamination in addition to conventional operative procedures. In this study, we retrospectively verified the usefulness of our unique treatment strategy featuring the addition of these 2 new ideas using the treatment results of infected abdominal aortic aneurysms from the past 10 years.

2. Patients and methods

The subjects were 12 patients who had been treated for infected abdominal aortic aneurysms in our institution between January 2002 and December 2011. In total, 390 patients underwent the abdominal aortic aneurysm operation during the same period, and these 12 subjects accounted for 3.1% of them.

Patient	Age/Sex	Symptom	CRP (mg/dL) on admission	Risk factor
1	66/M	Fever	40.2	Untreated DM
2	84/F	Fever, pain	14.2	Malnutrition
3	64/M	Fever, pain	14.2	Untreated DM
4	74/M	Fever, pain	14.9	Colon cancer
5	52/F	Fever, pain	20.0	-
6	65/M	Fever, pain	8.3	-
7	71/M	Fever, pain	13.5	Alcoholic LC
8	80/M	Fever, pain	7.1	Alcoholic LC
9	66/M	-	0.0	-
10	60/M	Fever, pain	6.5	-
11	64/M	Fever, pain	8.8	-
12	60/M	Fever	26.9	Steroid therapy

Table 1. Patient characteristics. CRP, C-reactive protein; DM, diabetes mellitus; LC, liver cirrhosis

The subjects were 10 men and 2 women who were 52–84 years of age (mean, 67.1 ± 8.9 years) (Table 1). In accordance with a report by Hsu et al. [2], patients with abdominal aortic aneurysm were diagnosed with infected abdominal aortic aneurysm when they exhibited physical symptoms such as abdominal pain and back pain, inflammatory findings such as fever and increased white blood cell count and C-reactive protein (CRP), rapid enlargement of the aneurysm by contrast-enhanced computed tomography (CT), formation of pseudo-, saccular, or lobular aneurysms, or periaortic stranding [3]. For patients whose diagnoses were difficult, fluorodeoxyglucose-positron emission tomography/CT (FDG-PET/CT) was performed to aid diagnosis. The basic treatment policy dictated that patients were considered to have infected aortic aneurysm if they had any of the abovementioned physical symptoms, inflammatory findings, or CT findings in addition to the presence of an aneurysm, following which treatment with antibiotics was immediately started, and surgical procedures were performed after the inflammatory findings improved, in principle. On the other hand, emergency surgery was selected for patients who continued to exhibit symptoms or inflammato-

ry findings even after antibiotic treatment, or who were suspected of having aneurysm rupture or impending rupture.

In principle, the operative procedure involved the following 5 steps.

1. Total resection of the aneurysm wall and surrounding infected tissue by laparotomy;
2. sufficient pulse irrigation with 10 L or more saline using a pulsatile irrigation device (SurgiLav® Plus Irrigation System, Stryker);
3. anatomical reconstruction using a gelatin-coated Dacron graft (Gelweave™, Terumo) soaked in 0.5% rifampicin (Sandoz) [4]; and
4. covering the prosthetic graft with the pedicled omental flap. Furthermore,
5. for patients with severe intraperitoneal contamination, temporary abdominal wall closure using the VAC technique was performed.

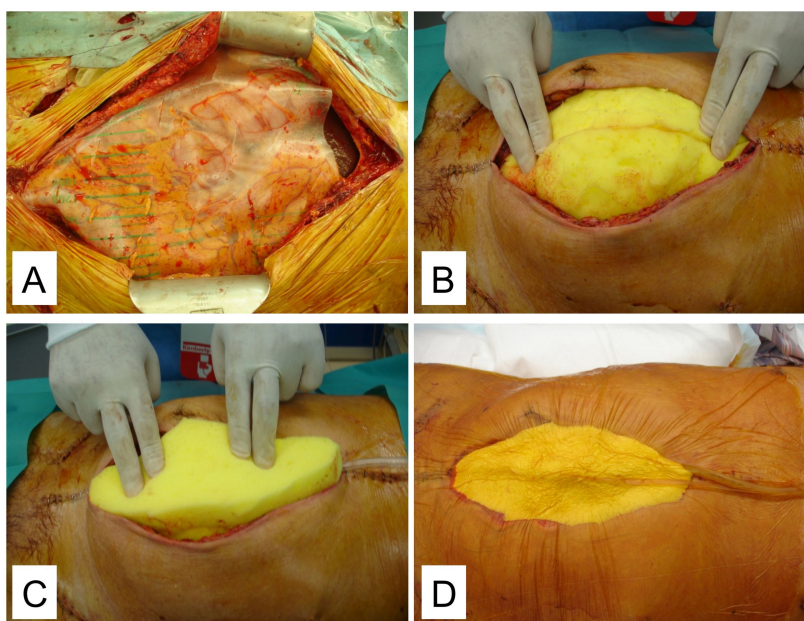


Figure 1. Temporary abdominal wall closure using the vacuum-assisted closure (VAC) technique. A, Placement of a vinyl sheet with slits in the abdominal cavity. B, Placement of polyurethane foam sponges over the sheet. C, Placement of a drainage tube on the sponges and coverage with other sponges. D, Draping and suction. (Modified from [7])

In this study, the amounts of bacteria in the operative fields were measured before and after the pulse irrigation and were used to verify the efficacy of the pulse-irrigation method. More specifically, the operative surface was wiped with sterilized cotton swabs before resection of the aneurysm wall and surrounding tissue, and was wiped with sterilized cotton swabs again after resection and irrigation. We then performed bacteria culture tests using these sterilized cotton swabs as samples. Regarding temporary abdominal wall closure using the VAC technique after abdominal aortic aneurysm resection, others and we have reported its use in preventing abdominal compartment syndrome in patients with non-infected aneurysm rupture [5-7]. Pursuant to our previous method [7], we performed temporary abdomi-

nal wall closure using the VAC technique to drain infectious peritoneal effusion. More specifically, a vinyl chloride sheet with slits of ca. 2-cm long at 1- to 2-cm intervals was placed directly in the abdominal cavity, after which sterilized polyurethane foam sponges were placed over the sheet and a drainage tube was placed on them, which was again covered with sponges and draped (Ioban™ 2 Special Incise Draip, 3M Healthcare) (Figure 1). The drainage tube was continuously suctioned using 140–150 mmHg suction pressure. The sponges were changed every 2 days, and secondary abdominal wall closure was performed after negative bacteria cultures of these sponges were confirmed twice.

After the operation, antibiotics were administered until inflammatory findings became negative. Even in early disappearance of inflammatory findings, intravenous injection was administered for a minimum of 14 days, in principle, followed by a minimum 14-day oral administration.

3. Results

The physical symptoms observed at the time of hospital visit were 11 cases of fever, 9 cases of abdominal pain or back pain, and 1 case of diarrhea (Table 1). All but 1 patient exhibited high CRP values. For risk factors of infection, 2 patients had untreated diabetes, 2 patients had alcoholic liver cirrhosis, 1 patient was malnourished, 1 patient had cancer, and 1 patient was undergoing steroid therapy. Blood cultures were performed for all but 1 patient, and only 2 patients (18%) were positive (Table 2). The possible source of infection was identified in 6 patients: fasciitis of the leg, intraperitoneal abscess, radicular abscess, bacterial endocarditis, bacterial enteritis, and multiple iliopsoas abscesses with infectious spondylitis.

Patient	Blood culture	Infection source	Bacteria cultured from blood or specimen
1	ND	Fasciitis of the leg	Group A <i>Streptococcus</i>
2	Negative	Unknown	-
3	Positive	Unknown	<i>Listeria</i>
4	Negative	Abdominal abscess	<i>Enterococcus</i>
5	Negative	Unknown	<i>Salmonella</i>
6	Negative	Unknown	Group A <i>Streptococcus</i>
7	Negative	Unknown	-
8	Negative	Unknown	<i>Listeria</i>
9	Negative	Radicular abscess	-
10	Negative	Bacterial endocarditis	-
11	Negative	Bacterial enteritis	-
12	Positive	Multiple abscess	MRSA

Table 2. Infection sources and pathogenic bacteria. ND, not done; MRSA, methicillin-resistant *Staphylococcus aureus*

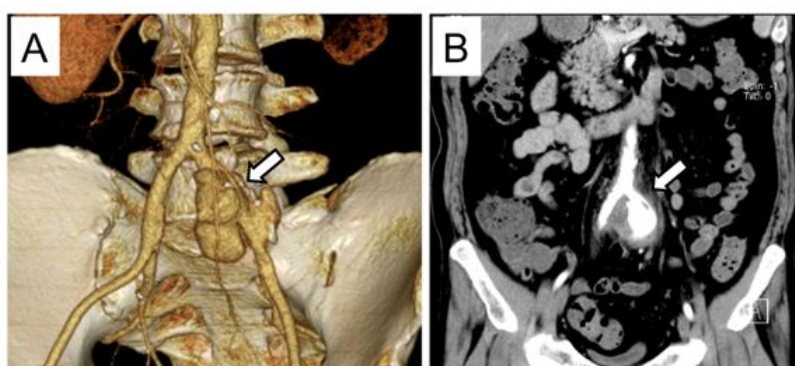


Figure 2. Reconstructed and coronal images of contrast-enhanced computed tomography (CT). A, Volume-rendering CT image of the left common iliac artery revealing a saccular and lobular aneurysm (arrow). B, Coronal CT image of the left common iliac artery revealing an aneurysm with periaortic infiltration and stranding (arrow). (Modified from [18])

Contrast-enhanced CT revealed rupture in 2 patients, while 8 patients had saccular or lobular aneurysms. Of these, 7 had increased tissue concentration surrounding the aneurysm (periaortic stranding) (Figure 2). Two patients had their CT images captured multiple times during the course, and rapid enlargement of the aneurysm was observed in both. As a result of the FDG-PET/CT being performed in 4 patients, their maximum standard uptake value (SUVmax) was found to exceed 5.0, proving that FDG-PET/CT is useful in aiding the diagnosis of infected aortic aneurysm (Figure 3).

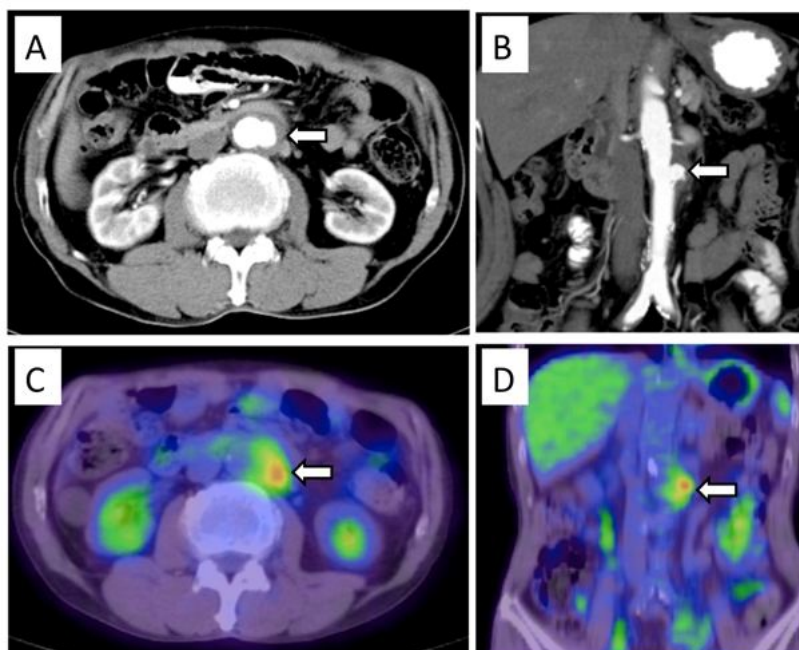


Figure 3. Images of contrast-enhanced computed tomography (CT) and fluorodeoxyglucose-positron emission tomography (FDG-PET)/CT. A and B, Axial and coronal CT images of the infrarenal aorta revealing a sacular aneurysm (arrows). C and D, Axial and coronal FDG-PET/CT images revealing abnormal FDG hypermetabolism with maximum standard uptake value (SUVmax) of 6.2 in the abdominal aorta wall and periaortic space (arrows). (Modified from [18])

Patient	Period from admission to operation (days)	Surgical procedure	Postoperative administration of antibiotics, div/po (days)	Period from operation to discharge (days)	Outcome (months)
1	26	R, O	23/60	30	Alive (105)
2	0	V, O	20/14	20	Dead (6)
3	1	R, O	19/14	26	Alive (68)
4	0	R, V, O	20/14	23	Alive (66)
5	0	R, O	14/14	25	Alive (61)
6	2	R, O	41/14	46	Alive (47)
7	0	O	14/14	38	Alive (47)
8	4	R	42/14	43	Alive (43)
9	8	R, O	14/14	15	Alive (26)
10	8	R, O	14/150	41	Alive (26)
11	10	R, O	14/14	14	Alive (24)
12	48	R, O	14/14	35	Alive (23)

Table 3. Surgical procedures and results. R, rifampicin-soaked graft; V, vacuum-assisted closure technique; O, wrapping by omental flap; div, drip infusion of vein; po, per os

Regarding operation timing, 4 patients were each diagnosed with rupture or impending rupture, and they underwent emergency surgery (Table 3). Three patients who maintained their physical conditions without improvement underwent urgent surgery, and the remaining 5 patients underwent elective surgery after the inflammatory symptoms improved. The mean period from admission to surgery was 8.9 ± 14.3 days (0–48 days).

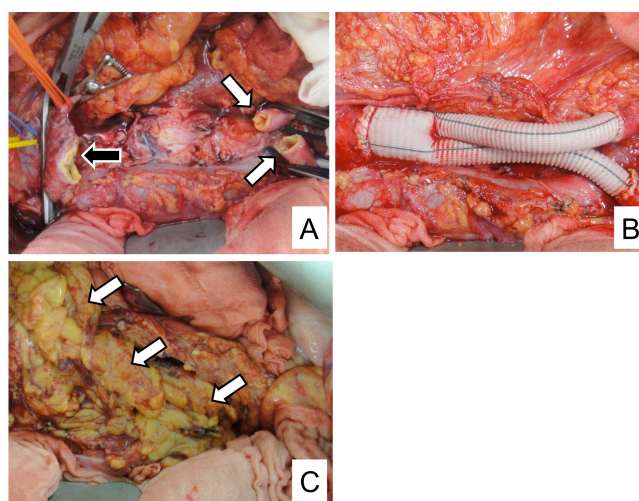


Figure 4. Conventional operative procedures. A, Operative photograph after resection of the aneurysm wall and surrounding infected tissue. Black and white arrows indicate the aortic stump and the common iliac artery stumps, respectively. B, Anatomical reconstruction using rifampicin-soaked Dacron graft. C, Pedicled omental flap wrapping the graft (arrows).

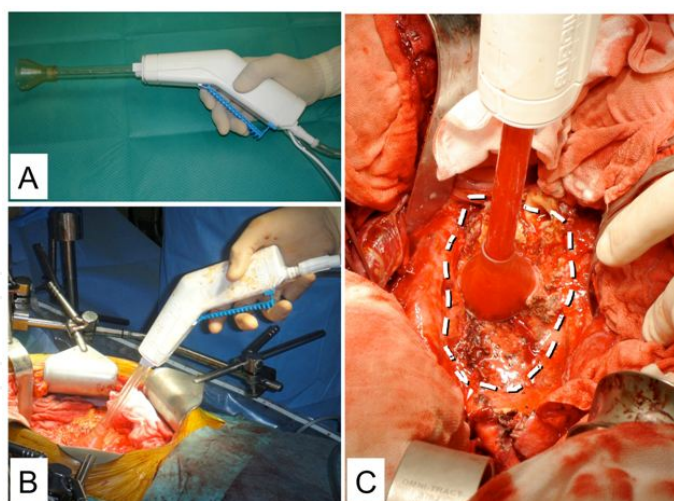


Figure 5. Pulse irrigation using the pulsatile irrigation device. A, SurgiLav® Plus Irrigation System (Stryker), comprising a handpiece assembly with irrigation tubing and a multi-orifice tip with soft cone splash shield. B and C, Operative photographs demonstrating the use of the pulsatile irrigation device, which enables users to clean contaminated areas using high-pressure pulsatile lavage. White dotted line indicates the area from which the aneurysm wall and surrounding infected tissue have been removed.

Regarding operative procedure, infected tissue, including the aneurysm wall, was wholly removed from all patients (Figure 4A), and followed by pulse irrigation using the pulsatile irrigation device (Figure 5) and anatomical reconstruction (Figure 4B). Regarding the grafts, rifampicin-soaked grafts were used in 10 patients, whereas rifampicin could not be prepared for 2 patients due to emergency surgery (Table 3). In the patient with concurrent colon cancer with formation of intraperitoneal abscess and the patient with aneurysm rupture who had widely extended retroperitoneal hemorrhage, the abdominal wall was temporarily closed using the VAC technique before it was closed in a secondary operation after intraperitoneal infection was controlled. In 11 patients in whom the greater omentum could be used, the graft was covered using the pedicled omental flap (Figure 4C, Table 3). Of the 12 patients in this study, pathogenic bacteria were identified in the operative field in 5 patients before irrigation. By contrast, the amount of bacteria in these patients was markedly reduced after the pulse irrigation (Table 4). In addition, pathogenic bacteria were eventually identified in 7 of the 12 patients: group A *Streptococcus* in 2 patients, *Listeria* in 2 patients, *Enterococcus* in 1 patient, *Salmonella* in 1 patient, and methicillin-resistant *Staphylococcus aureus* (MRSA) in 1 patient (Table 2).

The mean period of postoperative intravenous antibiotics administration was 20.7 ± 10.1 days and the mean period of oral administration was 29.1 ± 40.2 days (Table 3). It was noteworthy that in 10 of 12 patients (83.3%), antibiotics administration was ended relatively early, i.e., after 14 days. The mean period of hospitalization from surgery until discharge was 33.8 ± 10.8 days. For postoperative complications, ileus and sepsis resulting from urinary tract infection were observed each in 1 patient. However, both improved within a short time. Eleven patients were discharged and sent home, and the remaining patient was transferred to another hospital for rehabilitation, meaning no patient died during hospitalization

(Table 3). Although 1 patient died from an unrelated cause 6 months after operation, the remaining 11 patients had no reinfection until now and are still alive.

Patient	Bacteria cultured from aneurysm	Bacterial volume, pre-/post-irrigation
1	Group A <i>Streptococcus</i>	+/-
2	-	
3	<i>Listeria</i>	+++/Few
4	<i>Enterococcus</i>	+++/Few
5	<i>Salmonella</i>	+/-
6	Group A <i>Streptococcus</i>	+/-
7	-	
8	-	
9	-	
10	-	
11	-	
12	-	

Table 4. Effect of pulse irrigation. +++, Bacteria were detected throughout the whole medium; +, Bacteria were detected in only part of the smear; Few, Less than 5 bacteria colonies were detected; -, Bacteria were not detected

4. Discussion

Infected abdominal aortic aneurysm is a rare disease, and its incidence is said to be 0.6%–3.0% [2,8-10]. Despite the advances in antibiotics and surgical materials, mortality is reported to be 11%–36%, and the prognosis of the disease is still poor [2,8,11,12]. Reduced immunity of the patient is considered a risk factor for infected aneurysm. Specifically, diabetes, malignant tumors, immunodeficiency, trauma, alcohol poisoning, and steroid administration have been reported [8,10,12]. Seven of our 12 patients had these risk factors. Moreover, Oderich et al. reported that 93% of 43 patients with infected aneurysm were symptomatic, and fever and pain were observed in 77% and 65% of patients, respectively [12]. As most of our patients were also symptomatic, patients with abdominal aortic aneurysm that exhibit inflammatory symptoms should be managed based on the suspicion of infected aneurysm.

Traditionally, diagnosis of infected aortic aneurysm dictated that patients must have bacteria detected from the aortic aneurysm wall, surrounding tissue, or blood, as well as clinical findings associated with inflammation [8]. However, in not a few patients who were given antibiotics by former physicians, pathogenic bacteria could not be detected or inflammatory findings were poor. In fact, the probability of detecting bacteria in the wall of the aneurysm

or in blood culture has been reported to be around 10%–40% [10,13], and the positive rate for preoperative blood culture in this study was only 18.1%. Practically, it is difficult to detect bacteria from blood culture before operation in many cases, especially in patients with rupture or impending rupture, as there is insufficient time for bacteria detection. Meanwhile, a potent basis for diagnosis should be considered when contrast-enhanced CT reveals characteristic findings such as multilobular or saccular aneurysms and increased concentration in the surrounding tissue, or aneurysm diameter that rapidly enlarges in a short time. Macedo et al. reported that the CT findings of infected aneurysms most commonly revealed saccular and lobular aneurysms, accounting for 93% of all cases, followed by increased concentration in the tissue surrounding the aneurysm accounting for 48% of cases [3]. Considering the results of this study, in which physical symptoms, inflammatory findings, and characteristic CT findings were observed in 92%, 92%, and 100% of patients, respectively, infected aneurysm is a reasonable diagnosis if a patient exhibits the physical or inflammatory symptoms along with characteristic findings by contrast-enhanced CT [2,14].

However, it may be difficult to arrive at a diagnosis of infected aneurysm if patients are asymptomatic, have poor inflammatory findings, or have concurrent infection at other sites in addition to an uninfected aneurysm. The usefulness of FDG PET/CT has recently been reported as a diagnostic aid in such patients [15-17]. The patient in Figure 3 exhibited no physical symptoms or inflammatory findings during the course, only revealing a rapidly enlarging saccular aneurysm that was not present 1 year ago. We then performed FDG-PET/CT in this patient under the suspicion of infected aneurysm from the CT findings and observed FDG accumulation (SUVmax, 6.2) conforming to the aneurysm. Therefore, treatment for infected aneurysm was started immediately, producing favorable results. This patient was eventually diagnosed with infected aneurysm by a postoperative pathological test of the aneurysm wall. Recently, we evaluated the usefulness of FDG-PET/CT diagnosis in 4 patients with infected aneurysm against 8 patients as control, and reported 100% sensitivity and 100% specificity at an SUVmax cutoff value of 3.97 [18]. Although our previous report represents a preliminary evaluation involving a small number of patients, FDG-PET/CT could be a useful test for the diagnosis of infected aortic aneurysm through the evaluation of many patients and for the definition of an appropriate SUVmax cutoff value.

Regarding operation timing, onset is acute and the risk of rupture is high, thus it is considered desirable to perform the operation as early as possible, whereas some are of the opinion that the operation should be performed after the infection is resolved with antibiotics [2,9]. The biggest and potentially fatal postoperative complication is infection of the graft, and its prevention can influence the outcome [9]. More specifically, emergency surgery without promising infection control will never achieve good results. Therefore, our policy is to treat the patient with antibiotics as adequately as possible preoperatively and improve physical symptoms and inflammatory findings before performing the operation. Of course, prompt surgery should be considered for patients with rupture or continuous pain, or if the form of an aneurysm changes rapidly on imaging. However, in principle, it is recommended that surgery be performed after infection is controlled as much as possible.

Regarding operative procedure, non-anatomical bypass surgery in a clean operative field was once recommended after resection of the infected aneurysm wall and debridement of the surrounding tissue [19]. In contrast, many have reported that favorable results were obtained with in situ anatomical reconstruction [12,20,21]. In fact, the mortality of non-anatomical reconstruction is reported to be 25%–42%, whereas that of anatomical reconstruction is around 10%–33%, which still indicates high mortality even though anatomical reconstruction appears to be a superior method of reconstruction [8,9,12]. As mentioned earlier, the prevention of graft infection is considered important for improving the surgical results of infected aortic aneurysm, thus ideas such as the use of rifampicin-soaked grafts and covering the graft with the greater omentum have been implemented. Despite this, mortality remains considerably high; therefore, further ideas are required. Although endovascular treatment using a stent-graft has been reported [22,23], the premise for endovascular treatment is the remnant of aneurysm tissue. Even though its usefulness in patients in whom preoperative infection control was favorable has been reported, an important issue remains regarding its application to patients in whom infection control by antibiotics cannot be expected [24].

Graft infection is a rare complication in aneurysm operations in non-infected patients, where graft replacement is performed in a clean field. This means that the key to preventing graft infection in an infected aneurysm must be complete removal of infected tissue from the operative field and in close proximity to a clean field. As infected tissue is strongly adhered to its surroundings, it is very difficult to remove it completely by conventional dissection or resection. Therefore, the role of the irrigation procedure, which is to dilute the remaining bacteria in the operative field as much as possible and to reduce the opportunities for infection, is considered important. In this study, we performed pulse irrigation using a pulsatile irrigation device to remove the bacteria remaining after resection of the aneurysm and surrounding tissue. Pulse irrigation can aid in cleaning contaminated areas with high water pressure and high water volume using irrigation solutions such as saline. As a result, contaminants can be removed in a short time by thorough irrigation as compared with conventional irrigation using a syringe, etc. Currently, this pulse-irrigation method is used in the field of orthopedic surgery [25]. Hargrove et al. reported that it was useful in preventing artificial joint infection after artificial hip joint replacement [26]. However, no report to date has described the usefulness of pulse irrigation in the field of vascular surgery, including in infected aneurysm. In this study, we evaluated the changes in the amounts of bacteria before and after irrigation, and clearly demonstrated that the amount of bacteria in all patients markedly decreased after pulse irrigation. Although a comparison of the surgical outcomes between before and after the introduction of pulse irrigation has not been performed, none of the 12 patients who underwent pulse irrigation had postoperative reinfection, indicating that the pulse irrigation method is highly useful in the elimination of bacteria. Of the several pulse irrigation systems that are currently available, we used the SurgiLav® Plus Irrigation System (Stryker) in this study. This model has a built-in battery, thus can be used as is without requiring a connection to a power source. In addition, the hand-control set contains an outflow nozzle and a suction tube for irrigation solutions, making it possible to perform irrigation and suction simultaneously. With several nozzle tips to choose from, the outflow nozzle can be changed depending on the irrigation site and purpose. As the amount of irri-

gation increases, there will be substantial splashing of the discharged irrigation solution. Therefore, tips that are better for local irrigation should be used to prevent bacteria from scattering. The maximum perfusion volume of this model is ca. 1500 mL/min, permitting large-volume irrigation in a short time; thus, we believe that it could lead to reductions in aortic clamp time and surgical time.

As far as ideas for the treatment of infected aortic aneurysm go, measures such as the type of antibiotics and the period of use, the use of antibiotic-bonded grafts, and reconstruction methods have been considered. Nevertheless, discussions on irrigation methods have been limited so far. In practice, there remains room for discussion of the amount and content of irrigation solutions. However, based on the results of this study, we consider pulse irrigation an indispensable technique in the operative procedure for infected aneurysm, and it should be highly recommended. We also believe that there are many areas where it can be useful, i.e., not only in infected aneurysm, but also in peripheral artery bypass surgery in contaminated operative fields, graft infection, etc.

In infected abdominal aortic aneurysms, there have been cases where the entire abdominal cavity was contaminated, such as in patients with concurrent intraperitoneal abscess and rupture. As we acknowledge that infection cannot be controlled sufficiently in such patients even if pulse irrigation were used, we carried out temporary abdominal wall closure using the VAC technique in this study. The use of the VAC technique not only permits the drainage of bacteria that cannot be eliminated by retroperitoneum pulse irrigation and thus are spread in the abdominal cavity, but is also expected to prevent abdominal compartment syndrome in patients with rupture [5-7]. In fact, the VAC technique of our group has already produced favorable therapeutic results in patients with mediastinitis after cardiovascular surgery [27]. Taken together, and despite the small number of patients in this study, we believe that the VAC technique is useful in controlling infection spread in the entire abdominal cavity.

There is no definite view as yet regarding postoperative administration of antimicrobial agents. Some have reported that the administration period is 6 or 8 weeks [2,11,19], while others have reported lifetime administration [8,28]. In principle, we administer antibiotics intravenously until postoperative inflammatory findings (fever, white blood cell count, and CRP) improve, followed by the minimum 14-day oral antibiotics administration. As a result, oral administration ended within 14 days in 10 of 12 patients; furthermore, no patient has had recurrence of infection thus far. This period of antibiotics administration appears brief in comparison with that of previous reports [2,8,11,19,28], and this may be the benefit of successful infection control resulting from the efficient reduction of bacteria by intraoperative pulse irrigation and the VAC technique.

5. Conclusions

This study is the first report demonstrating the usefulness of pulse irrigation and the VAC technique in patients with infected abdominal aortic aneurysm. To treat patients with infect-

ed aortic aneurysm, we have introduced the pulse-irrigation method using a pulsatile irrigation device into the conventional surgical procedures, which include resection of the aneurysm wall and infected tissue, anatomical reconstruction using a rifampicin-soaked graft, and covering the graft with a pedicled omental flap. Furthermore, we performed temporary abdominal wall closure using the VAC technique concurrently in patients with severe intraperitoneal contamination. As a result of the introduction of these new methods to enhance intra- and postoperative infection control, the lives of all 12 patients were successfully saved. Consequently, this novel treatment strategy for infected abdominal aortic aneurysms is likely to be useful and can be recommended.

Acknowledgements

This work was supported by a Grant-in-Aid for Scientific Research (KAKENHI) from the Japan Society for the Promotion of Science (to K.Y.), the Takeda Science Foundation (to K.Y.), and the SENSHIN Medical Research Foundation (to K.Y.).

Author details

Osamu Yamashita, Koichi Yoshimura*, Noriyasu Morikage, Akira Furutani and Kimikazu Hamano

*Address all correspondence to: yoshimko@yamaguchi-u.ac.jp

Department of Surgery and Clinical Science, Yamaguchi University Graduate School of Medicine, Ube, Japan

References

- [1] Weaver, M. R., & Reddy, D. J. (2010). Infected Aneurysm. In: Cronenwett J.L., Johnston K.W. (eds.) *Vascular Surgery*. Philadelphia: Saunders, 2156-2167.
- [2] Hsu, R. B., Chen, R. J., Wang, S. S., & Chu, S. H. (2004). Infected aortic aneurysms: clinical outcome and risk factor analysis. *Journal of Vascular Surgery*, 40(1), 30-35.
- [3] Macedo, T. A., Stanson, A. W., Oderich, G. S., Johnson, C. M., Panneton, J. M., & Tie, M. L. (2004). Infected aortic aneurysms: imaging findings. *Radiology*, 231(1), 250-257.
- [4] Chaikof, E. L., Brewster, D. C., Dalman, R. L., Makaroun, M. S., Illig, K. A., Sicard, G. A., et al. (2009). The care of patients with an abdominal aortic aneurysm: the Society for Vascular Surgery practice guidelines. *Journal of Vascular Surgery*, 50(4), S2-S49.
- [5] Rasmussen, T. E., Hallett, J. W. Jr, Noel, AA, Jenkins, G., Bower, T. C., Cherry, K. J. Jr, et al. (2002). Early abdominal closure with mesh reduces multiple organ failure after

ruptured abdominal aortic aneurysm repair: guidelines from a 10-year case-control study. *Journal of Vascular Surgery*, 35(2), 246-253.

- [6] Mayer, D., Rancic, Z., Meier, C., Pfammatter, T., Veith, F. J., & Lachat, M. (2009). Open abdomen treatment following endovascular repair of ruptured abdominal aortic aneurysms. *Journal of Vascular Surgery*, 50(1), 1-7.
- [7] Morikage, N., Onoda, M., Nomura, S., Yoshimura, K., Furutani, A., & Hamano, K. (2009). Surgical strategy for ruptured abdominal aortic aneurysms in cases of severe shock. *Japanese Journal of Vascular Surgery (in Japanese)*, 18(1), 1-8.
- [8] Muller, B. T., Wegener, O. R., Grabitz, K., Pillny, M., Thomas, L., & Sandmann, W. (2001). Mycotic aneurysms of the thoracic and abdominal aorta and iliac arteries: experience with anatomic and extra-anatomic repair in 33 cases. *Journal of Vascular Surgery*, 33(1), 106-113.
- [9] Sessa, C., Farah, I., Voirin, L., Magne, J. L., Brion, J. P., & Guidicelli, H. (1997). Infected aneurysms of the infrarenal abdominal aorta: diagnostic criteria and therapeutic strategy. *Annals of Vascular Surgery*, 11(5), 453-463.
- [10] Gomes, M. N., Choyke, P. L., & Wallace, R. B. (1992). Infected aortic aneurysms. A changing entity. *Annals of Surgery*, 215(5), 435-442.
- [11] Moneta, G. L., Taylor, L. M. Jr, Yeager, R. A., Edwards, J. M., Nicoloff, A. D., McConnell, D. B., et al. (1998). Surgical treatment of infected aortic aneurysm. *American Journal of Surgery*, 175(5), 396-369.
- [12] Oderich, G. S., Panneton, J. M., Bower, T. C., Cherry, K. J. Jr, Rowland, C. M., Noel, A. A., et al. (2001). Infected aortic aneurysms: aggressive presentation, complicated early outcome, but durable results. *Journal of Vascular Surgery*, 34(5), 900-908.
- [13] Ernst, C. B., Campbell, H. C. Jr, Daugherty, ME, Sachatello, C. R., & Griffen, W. O. Jr. (1977). Incidence and significance of intra-operative bacterial cultures during abdominal aortic aneurysmectomy. *Annals of Surgery*, 185(6), 626-633.
- [14] Maeda, H., Umezawa, H., Goshima, M., Hattori, T., Nakamura, T., Umeda, T., et al. (2011). Primary infected abdominal aortic aneurysm: surgical procedures, early mortality rates, and a survey of the prevalence of infectious organisms over a 30-year period. *Surgery Today*, 41(3), 346-351.
- [15] van der Vaart, M. G., Meerwaldt, R., Slart, R. H., van Dam, G. M., Tio, R. A., & Zeebregts, C. J. (2008). Application of PET/SPECT imaging in vascular disease. *European Journal of Vascular and Endovascular Surgery*, 35(5), 507-513.
- [16] Choi, S.J, Lee, J.S, Cheong, M.H, Byun, S.S, & Hyun, I.Y. (2008). F-18 FDG PET/CT in the management of infected abdominal aortic aneurysm due to Salmonella. *Clinical Nuclear Medicine*, 33(7), 492-495.

- [17] Davison, J. M., Montilla-Soler, J. L., Broussard, E., Wilson, R., Cap, A., & Allen, T. (2005). F-18 FDG PET-CT imaging of a mycotic aneurysm. *Clinical Nuclear Medicine*, 30(7), 483-487.
- [18] Yamashita, O., Morikage, N., Okazaki, Y., Suehiro, K., Yoshimura, K., Suga, K., et al. (2011). Positron emission tomography and computed tomography in the diagnosis of an infected aneurysm. *The Journal of Japanese College of Angiology (in Japanese)*, 51(4), 473-479.
- [19] Takano, H., Taniguchi, K., Kuki, S., Nakamura, T., Miyagawa, S., & Masai, T. (2003). Mycotic aneurysm of the infrarenal abdominal aorta infected by *Clostridium septicum*: a case report of surgical management and review of the literature. *Journal of Vascular Surgery*, 38(4), 847-851.
- [20] Hsu, R. B., Tsay, Y. G., Wang, S. S., & Chu, S. H. (2002). Surgical treatment for primary infected aneurysm of the descending thoracic aorta, abdominal aorta, and iliac arteries. *Journal of Vascular Surgery*, 36(4), 746-750.
- [21] Robinson, J. A., & Johansen, K. (1991). Aortic sepsis: is there a role for in situ graft reconstruction? *Journal of Vascular Surgery discussion* 82-84., 13(5), 677-682.
- [22] Lee, K. H., Won, J. Y., Lee, do Y., Choi, D., Shim, W. H., Chang, B. C., et al. (2006). Stent-graft treatment of infected aortic and arterial aneurysms. *Journal of Endovascular Therapy*, 13(3), 338-345.
- [23] Hartman, V., Jiang, H., & Thomas, B. (2009). Successful [Successful] endovascular repair of an abdominal mycotic aneurysm. A case report. *Acta Chirurgica Belgica*, 109(6), 788-790.
- [24] Kan, C. D., Yen, H. T., Kan, C. B., & Yang, Y. J. (2012). The feasibility of endovascular aortic repair strategy in treating infected aortic aneurysms. *Journal of Vascular Surgery*, 55(1), 55-60.
- [25] Flow-Investigators. (2010). Fluid lavage of open wounds (FLOW): design and rationale for a large, multicenter collaborative 2 x 3 factorial trial of irrigating pressures and solutions in patients with open fractures. *BMC Musculoskeletal Disorders*, 85 EOF, <http://www.biomedcentral.com/1471-2474/11/85>, (accessed 04 May 2012).
- [26] Hargrove, R., Ridgeway, S., Russell, R., Norris, M., Packham, I., & Levy, B. (2006). Does pulse lavage reduce hip hemiarthroplasty infection rates? *The Journal of Hospital Infection*, 62(4), 446-449.
- [27] Kobayashi, T., Mikamo, A., Kurazumi, H., Suzuki, R., Shirasawa, B., & Hamano, K. (2011). Secondary omental and pectoralis major double flap reconstruction following aggressive sternectomy for deep sternal wound infections after cardiac surgery. *Journal of Cardiothoracic Surgery*, 6, 56.
- [28] Abdel, Azim. T. A. (2005). Infected aortic aneurysms. *Acta Chirurgica Belgica*, 105(5), 482-486.