

We are IntechOpen, the world's leading publisher of Open Access books Built by scientists, for scientists

4,800

Open access books available

122,000

International authors and editors

135M

Downloads

Our authors are among the

154

Countries delivered to

TOP 1%

most cited scientists

12.2%

Contributors from top 500 universities



WEB OF SCIENCE™

Selection of our books indexed in the Book Citation Index
in Web of Science™ Core Collection (BKCI)

Interested in publishing with us?
Contact book.department@intechopen.com

Numbers displayed above are based on latest data collected.

For more information visit www.intechopen.com



Use of Optoelectronic Plethysmography in Pulmonary Rehabilitation and Thoracic Surgery

Giulia Innocenti Bruni, Francesco Gigliotti and
Giorgio Scano

Additional information is available at the end of the chapter

<http://dx.doi.org/10.5772/53039>

1. Introduction

1.1. Methods

OEP system is an optoelectronic device able to track the three-dimensional co-ordinates of a number of reflecting markers placed non-invasively on the skin of the subject [1-4]. A variable number of markers (89 in the model used for respiratory acquisition in seated position) is placed on the thoraco-abdominal surface; each marker is a half plastic sphere coated with a reflective paper. Two TV Sensors 2008, cameras are needed to reconstruct the X-Y-Z co-ordinates of each marker, so for the seated position six cameras are required. Each camera is equipped with an infra-red ring flash. This source of illumination, which is not visible, is not disturbing and lets the system also operate in the dark. The infra-red beam, emitted by the flashes, is reflected by each marker and acquired by the cameras with a maximal sampling rate of 100 Hz. The signal is then processed by a PC board able to combine the signal coming from the cameras and to return, frame by frame, the three-dimensional co-ordinates of each marker. The process is simultaneously carried out for the six TV cameras needed for the seated respiratory model. Acquired data need a further operation called 'tracking' that is necessary to exclude possible phantom reflections and/or to reconstruct possible lost markers (this could happens sometimes during very fast manoeuvres such exercise); at this time the obtained files contain the X-Y-Z co-ordinates of each marker during the recorded manoeuvre, then data are stored on the PC hard disk. The spatial accuracy for each marker's position is about 0.2 mm [1]. Volumes for each compartment is calculated by constructing a triangulation over the surface obtained volume from the X-Y-Z co-ordinates of the markers and then using Gauss's theorem to convert the volume integral to an integral over this sur-

face [2]. The number and the position of used markers depends on the thoraco-abdominal model chosen. As proposed by Ward & Macklem [5] we use a three compartment chest wall model: the upper rib cage, lower rib cage and abdomen. Due to the fact that the upper portion of the rib cage is exposed to pleural pressure whereas the lower portion is affected by abdominal pressure, a model able to dynamically return changes in volume of each compartment and, as a sum, of the entire chest wall has been developed [2]. The number of used markers is 89, 42 placed on the front and 47 on the back of the subject.

To measure the volume of chest wall compartments from surface markers we define: 1) the boundaries of the upper rib cage as extending from the clavicles to a line extending transversely around the thorax at the level of the xiphoid process (corresponding to the top of the area of the apposition of the diaphragm to the rib cage at end expiratory lung volume in sitting posture, confirmed by percussion); 2) the boundaries of lower rib cage as extending from this line to the costal margin anteriorly down from the xiphosternum, and to the level of the lowest point of the lower costal margin posteriorly; and 3) the boundaries of abdomen as extending caudally from the lower rib cage to the level of the anterior superior iliac crest. The markers are placed circumferentially in seven horizontal rows between the clavicles and the anterior superior iliac spine. Along the horizontal rows the markers are arranged anteriorly and posteriorly in five vertical rows, and there is an additional bilateral row in the mid-axillary line. The anatomical landmarks for the horizontal rows are: 1) the clavicular line; 2) the manubrio-sternal joint; 3) the nipples (~ 5 ribs); 4) the xiphoid process; 5) the lower costal margin (10th rib in the midaxillary line); 6) umbilicus; 7) anterior superior iliac spine. The landmarks for the vertical rows are: 1) the midlines; 2) both anterior and posterior axillary lines; 3) the midpoint of the interval between the midline and the anterior axillary line, and the midpoint of the interval between the midline and the posterior axillary line; 4) the mid-axillary lines. An extra marker is added bilaterally at the midpoint between the xiphoid and the most lateral portion of the 10th rib to provide better detail of the costal margin; two markers are added in the region overlying the lung-apposed rib cage and in the corresponding posterior position. This marker configuration has previously been validated in normal subjects, along with a sensitivity analysis which assesses accuracy in estimating change in lung volume as a function of marker number and position [2]. When compared with the gold standard (water sealed spirometer) the accuracy in the volume change measurements of the 89 markers model is very high, showing volume differences smaller than 5% [2].

2. Exercise limitation and breathlessness in patients with Chronic Obstructive Pulmonary Disease (COPD)

Dynamic hyperinflation (DH) is supposed to be the most important factor limiting exercise and contributing to dyspnea by restrictive constraints to volume expansion in patients with COPD [6]. Indirect evidence of the importance of DH has been provided by studies that have demonstrated that pharmacological treatment [7,8], and lung volume reduction sur-

gery [9] explain in part the improvement in exercise performance and dyspnea by reducing DH in these patients. It has recently been found, however, that different patterns of chest wall kinematics may or may not be associated with different exercise performance in COPD patients [10,11]. There is little data available indicating that these patients may dynamically hyperinflate or deflate chest wall compartments during cycling while breathing air [10,12] or with oxygen supplementation [11]. As yet the contribution of reducing lung volume to dyspnea relief remains uncertain [11,13-15] in exercising COPD patients. It also remains to be determined whether changes in operational chest wall volumes substantially affect the response to endurance exercise rehabilitation programs. It should be remembered that (i) an increase in end-expiratory-volume of the chest wall constrains the potential for the tidal volume to increase; thus exacerbating the sensation of dyspnea; (ii) on the other hand, shifting abdominal volumes towards a lower operational point might not be able to reduce restrictive constraints on volume displacement if the rib cage dynamically hyperinflates. Arguably, rib cage hyperinflation would result in a higher volumetric load to the intercostal inspiratory muscles [16] and a higher sensory perception of dyspnea [17]; (iii) the possibility that abdominal deflation contributes *per se* to dyspnea should not be disregarded [16]. Evidence has indeed been provided that a decrease in abdominal volume resulting from increased abdominal muscle activity as soon as exercise starts even at minimal work rate [4] may contribute *per se* to increasing the work of breathing [10] and breathlessness [16], to reducing venous return and cardiac output [18], and to decreasing exercise capacity [4] in patients with COPD.

Dyspneic patients with COPD who are markedly hyperinflated are considered especially likely to display abnormalities in rib cage motion such as a paradoxical (inward) inspiratory movement of their lower rib cage [19-22]. Studies in healthy humans have led to the hypothesis that the primary mechanism of abnormal chest wall motion in patients with COPD is probably an abnormal alteration of forces applied to chest wall compartments [3,23] and an increase in airway resistance [24]. Chihara *et al.* [23] have speculated that when rib cage distortion is present, greater degree of recruitment of inspiratory rib cage muscles and greater predisposition to dyspnea for a given load and strength do occur. On the other hand, the role of hyperinflation on abnormal chest movement is questionable in healthy subjects [24]. Accordingly, it has recently been shown that paradoxical movement of the lower rib cage cannot be fully explained by static lung hyperinflation [19] or dynamic rib cage hyperinflation [25] in patients with COPD. By contrast, Aliverti *et al.* [26] have shown that lower rib cage paradox results in an early onset of dynamic hyperinflation as a likely explanation for the increased exertional breathlessness in these patients. Nonetheless, the link between changes in operational lung volumes and exertional breathlessness has not been definitely established in normoxic COPD patients [13,14,27].

Now the questions arise: does exercise reconditioning reduce rib cage distortion, and, if any, does rib cage distortion contribute to restoring exercise capacity and to relieving breathlessness? Does exercise reconditioning relieve dyspnea regardless of whether compartmental chest wall volumes are shifted toward upper or lower operational points?

3. How Optoelectronic Plethysmography (OEP) can help answer the above questions

The use of Optoelectronic Plethysmography (OEP) has allowed us to understand some of the mechanisms underlying the efficacy of rehabilitative treatment in patients with COPD. Rehabilitation interventions such as oxygen supplementation reduce ventilation and the rate of dynamic hyperinflation, but whether and to what extent reduction in lung volume contributes to dyspnea relief remains uncertain in these patients [13,14,27]. Innocenti Bruni *et al.* [11] tried to (i) determine whether and how hyperoxia would affect exercise dyspnea, chest wall dynamic hyperinflation, and rib cage distortion in normoxic COPD patients, and (ii) investigate whether these phenomena are interrelated. It was speculated that they are not, based on the following observations: (i) significant dyspnea relief and improvement in exercise endurance can occur even in the absence of an effect on dynamic lung hyperinflation [27]; (ii) externally imposed expiratory flow limitation is associated with no rib cage distortion during strenuous incremental exercise, with indexes of hyperinflation not being correlated with dyspnea [16]; (iii) end-expiratory-chest wall-volume may either increase or decrease during exercise in patients with COPD, with those who hyperinflate being as breathless as those who do not [10]; (iv) a similar level of dyspnea is associated with different increases in chest wall dynamic hyperinflation at the limits of exercise tolerance [28]. The volume of chest wall (V_{cw}) and its compartments: the upper rib cage (V_{rcp}), lower rib cage (V_{rca}), and abdomen (V_{ab}) were evaluated by OEP in 16 patients breathing either room air or 50% supplemental O_2 at 75% of peak exercise in randomized order; rib cage distortion was assessed by measuring the phase angle shift between V_{rcp} and V_{rca} . Ten patients increased end-expiratory V_{cw} ($V_{cw,ee}$) on air. In 7 *hyperinflators* and 3 *non-hyperinflators* the lower rib cage paradoxed inward during inspiration with a phase angle of 63.4° (30.7) compared with a normal phase angle of 16.1° (2.3) recorded in patients without rib cage distortion. Dyspnea by a modified Borg scale from zero (no dyspnea), to ten (maximum dyspnea) averaged 8.2 and 9 at end-exercise on air in patients with and without rib cage distortion, respectively. At iso-time during exercise with oxygen, dyspnea relief was associated with a decrease in ventilation regardless of whether patients distorted the rib cage, dynamically hyperinflated or deflated the chest wall. (Fig 1).

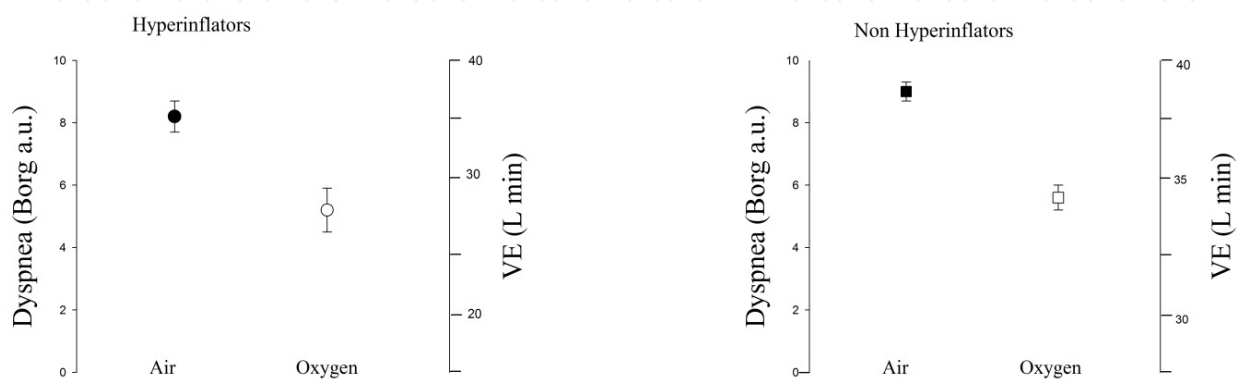


Figure 1. Oxygen supplementation decreases ventilation and dyspnea at isotime during constant load cycling exercise.

OEP allows us to demonstrate that dyspnea, chest wall dynamic hyperinflation, and rib cage distortion are not interrelated phenomena.

Georgiadou *et al.* [12] studied the effect of pulmonary rehabilitation on the regulation of total chest wall and compartmental volumes during exercise in patients with COPD. Twenty patients undertook high-intensity exercise 3 days week⁻¹ for 12 weeks. Before and after rehabilitation, the changes in chest wall (cw) volumes at the end of expiration (V_{cw,ee}) and inspiration (V_{cw,ei}) were computed by OEP during incremental exercise to the limit of tolerance (W_{peak}). Rehabilitation significantly improved W_{peak}. In the post-rehabilitation period and at identical work rates, significant reductions were observed in minute ventilation, breathing frequency and V_{cw,ee} and V_{cw,ei}. Inspiratory reserve volume was significantly increased. Volume reductions were attributed to significant changes in abdominal V_{cw,ee} and V_{cw,ei}. The improvement in W_{peak} was similar in patients who progressively hyperinflated during exercise and those who did not. The authors concluded that pulmonary rehabilitation lowers chest wall volumes during exercise by decreasing the abdominal volumes.

The study indicates that improvement in exercise capacity following rehabilitation is independent of the pattern of exercise-induced dynamic hyperinflation.

Preliminary laboratory data indicate that OEP substantially assists in clarifying the link between chest wall dynamic hyperinflation and breathlessness following pulmonary rehabilitation. The volume of the chest wall and its compartments were evaluated in 14 patients by OEP during constant load cycle exercise before and after pulmonary rehabilitation. Prior to rehabilitation exercise increased end-expiratory chest wall volumes in eight patients, but deflated the chest wall in six [11]. Rehabilitation increased exercise endurance. Relief in both dyspnea and leg effort at iso-time were associated with a decrease in ventilation regardless of whether patients hyperinflated or not. Also, the effect of pulmonary rehabilitation on rib cage distortion and dyspnea were independent of each other (Fig 2).

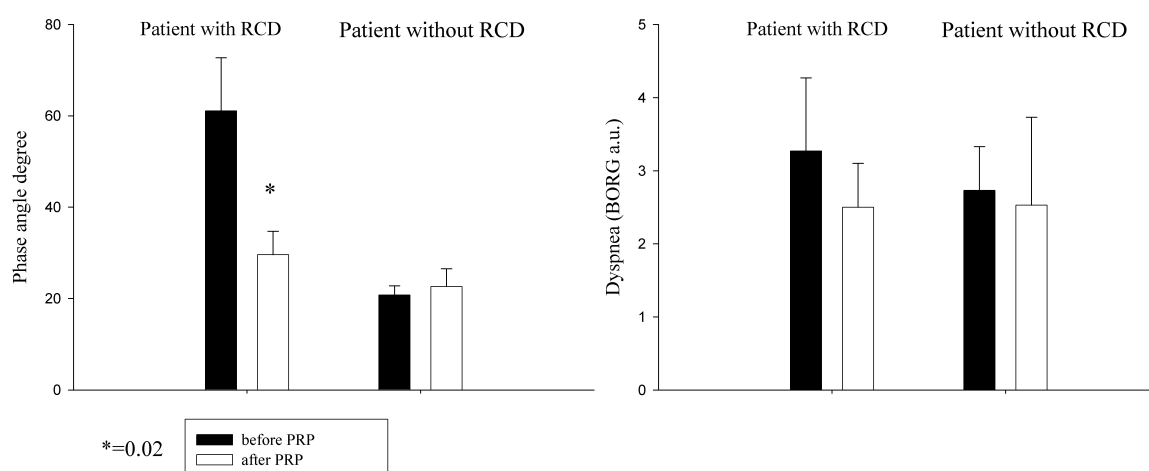


Figure 2. Effect of pulmonary rehabilitation (PRP) on phase angle and dyspnea in patients with and without ribcage distortion (RCD).

These data suggest that pulmonary rehabilitation reduces dyspnea regardless of rib cage distortion and dynamic chest wall hyperinflation.

Many COPD patients complain of severe dyspnea while performing simple daily-life activities using their arms. The increased demand during simple arm elevation may play a role in the development of dyspnea and in the limitation that is frequently reported by these patients when performing activities involving their arms [29,30]. Unsupported arm exercise training (UAET) is increasingly recognized as an important component of pulmonary rehabilitation in these patients [31]. Although some studies have demonstrated improvement in unsupported arm exercise after UAET [32-34], suggesting that the test can be sensitive to changes in arm exercise capacity, the impact of upper extremity training on arm exercise related-dyspnea and fatigue remains unclear [35-38] or undemonstrated [32,38-40]. Surprisingly, few studies [32,35,37-39] have investigated the effect of upper extremity training on ratings of perceived dyspnea by applying psychophysical methods, that is, the quantitative study of the relationship between stimuli and evoked conscious sensory responses. On this basis we have recently demonstrated that neither chest wall dynamic hyperinflation nor dyssynchronous breathing *per se* are the major contributors to dyspnea during unsupported arm exercise in COPD patients [25]. Using the same approach we have recently tried to document the impact of arm training on arm exercise-related perceptions. The finding that before rehabilitation patients stop arm exercise namely because of arm symptoms, makes a case for the excessive effort felt by subjects being elicited by arm/torso afferent information (from the muscles performing the excessive effort) conveyed to the motor-sensory cortex [25].

These findings may explain why even a very small decrease in ventilatory demand, reflective of a decrease in central motor output to ribcage/torso muscles, has a salutary effect on arm symptoms during arm training in patients with COPD [41].

OEP has also helped to clarify mechanisms by which some techniques of pulmonary rehabilitation such as breathing retraining, namely "pursed lip breathing" (PLB), act in reducing the sensation of dyspnea. Bianchi *et al.* [42] hypothesized that the effect of PLB on breathlessness relies on its deflationary effects on the chest wall. They found that patients exhibited a significant reduction in end-expiratory volume of the chest wall ($V_{cw,ee}$) and a significant increase in end-inspiratory volume of the chest wall in comparison with spontaneous breathing. In a stepwise multiple regression analysis, a decrease in end expiratory volume of the chest wall accounted for 27% of the variability in the Borg score.

These data indicate that by lengthening the expiratory time, PLB deflates the chest wall and reduces dyspnea.

In a further paper Bianchi *et al.* [43] identified the reasons why some patients benefit from PLB while others do not. The OEP analysis of chest wall kinematics shows why not all patients with COPD obtain symptom relief from PLB at rest. The most severely affected patients who deflate the chest wall during volitional PLB reported improvement in their sensation of breathlessness. This was not the case in the group who hyperinflated during PLB.

4. Comparing OEP with spirometric operational volumes

OEP may provide complementary information on operational volumes to that provided by spirometry. Vogiatzis *et al.* [28] found a good relationship between changes in inspiratory capacity (ΔIC_{pn}) and changes in end expiratory chest wall volume ($\Delta V_{cw,ee}$). By contrast we have not found any significant relationship between the two measurements (Fig 3).

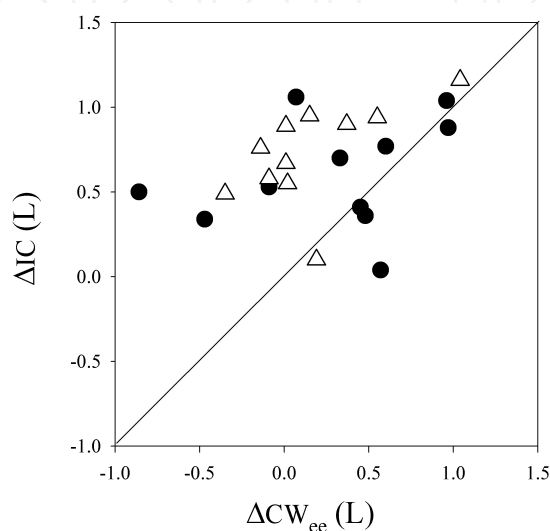


Figure 3. Plots of change in inspiratory capacity (IC) vs change in end-expiratory-chest wall-volumes (CW_{ee}) from rest to end exercise, before (closed circles) and after (triangles) pulmonary rehabilitation. Continuous line is the identity line.

The decrease in IC_{pn} is much greater than the increase in $V_{cw,ee}$ in most patients. The reasons for this discrepancy are probably due to: i) error measurements with the pneumotachograph possibly linked to leakage and elevation of temperature in the system, and to spirometric drift resulting in spurious increments or decrements in volume measurements; ii) spirometry measures the volume of the gas entering or leaving the lungs at the mouth, while OEP measures the volume of the trunk which includes changes in gas volume, gas compression and blood volume shifts [16]. Arguably, activity of the abdominal muscles producing various amounts of gas compression and blood shifts might account for the prevalence of one method over the other. For instance, high gas compression and blood shift would result in a greater decrease in $V_{cw,ee}$ than an increase in the next IC_{pn} manoeuvre [44]. It has been postulated that OEP would not detect 89% of the reduction in inspiratory capacity measured with spirometry in some conditions [44].

5. OEP and reparative deformity of the rib cage

Pectus excavatum, the most common congenital chest wall deformity, is characterized by a depression of the anterior chest wall and sternum. Some patients will develop cardiopulmo-

nary symptoms for the first time as adolescents while others will experience a worsening of the symptoms they have endured for years. A minimally invasive technique for repair described by Nuss *et al.* [45,46] involves the placement of substernal concave bar(s) that will be rotated to elevate the sternum outward. The bar is left in place for 2-3 years while the anterior chest wall remodels. The chest wall is primarily involved when there are respiratory abnormalities, so the effect of repair should be assessed mainly by observing chest wall kinematics and possibly chest wall mechanics in pectus excavatum patients. A previous study carried out in adolescents with mild restrictive defect has shown that abnormalities in chest wall kinematics during maximal voluntary ventilation are not correlated with the computed tomography scan severity index, indicating the contribution of chest wall kinematics to clinical evaluation of pectus excavatum patients [47]. Should we wait 2-3 years before assessing repair effects (if any) on chest wall kinematics? Can the Nuss procedure influence timing, and kinematics of the chest wall and rib cage configuration in otherwise healthy subjects? Binazzi *et al.* [48] postulated that the repair effect based on increased chest wall end expiratory volume does not affect chest wall displacement and dynamic configuration of the rib cage. By using OEP they provided a quantitative description of chest wall kinematics before and 6 months after the Nuss procedure at rest and during maximal voluntary ventilation in 13 subjects with pectus excavatum. An average 11% increase in chest wall volume was accommodated within the upper rib cage and to a lesser extent within the abdomen and lower rib cage. Tidal volumes did not significantly change during the study period. The repair effect on chest wall kinematics did not correlate with the Haller index of deformity at baseline.

These data indicate that six months of the Nuss procedure do increase chest wall volume without affecting chest wall displacement and rib cage configuration.

6. Conclusion

In conclusion, we and others have shown that use of OEP can demonstrate the following: (i) dynamic hyperinflation of the chest wall may not necessarily be the principal reason for exercising limitation and breathlessness in COPD patients; (ii) pulmonary rehabilitation improves COPD patients' endurance and exercise-related perceptions regardless of changes in chest wall kinematics; (iii) in contrast with what is commonly believed, chest wall dynamic hyperinflation may have a salutary mechanical effect in patients with expiratory flow limitation and dynamic hyperinflation, who increase functional residual capacity because of achieving more tidal expiratory flow; (iv) OEP provides complementary information on operational volumes to that provided by spirometry.

Finally, there are very few reports on the use of OEP in pulmonary rehabilitation and thoracic surgery in patients with chronic respiratory disease other than COPD. We hope that the results presented here will stimulate new contributions on this topic.

Author details

Giulia Innocenti Bruni¹, Francesco Gigliotti¹ and Giorgio Scano^{1,2}

1 Section of Respiratory Rehabilitation, Fondazione Don C. Gnocchi, Florence, Italy

2 Department of Internal Medicine, Section of Immunology and Respiratory Medicine, University of Florence, Florence, Italy

References

- [1] Pedotti A, Ferrigno G. Opto-electronics based systems. In *Three-Dimensional Analysis of Human Movement, Human Kinetics*, 1st Ed.; Allard P, Stokes IA, Bianchi JP. Eds.; Human Kinetics Publishers: Champaign, USA, 1995; pp. 57-78.
- [2] Cala SJ, Kenyon C.M, Ferrigno G, Carnevali P, Aliverti A, Pedotti A, Macklem PT, Rochester DF. Chest wall and lung volume estimation by optical reflectance motion analysis. *Journal of applied Physiology*. 1996; 81:2680-2689.
- [3] Kenyon CM, Cala SJ, Yan S, et al. Rib cage mechanics during quiet breathing and exercise in humans. *Journal of Applied Physiology*. 1997;83:1242-55.
- [4] Aliverti A, Cala SJ, Duranti R, Ferrigno G, Kenyon CM, Pedotti A, Scano G, Sliwinski P, Macklem PT, Yan S. Human respiratory muscle action and control during exercise. *Journal of Applied Physiology* 1997;83:1256-1269
- [5] Ward ME, Ward JW, Macklem PT. Analysis of human chest wall motion using a two compartment rib-cage model. *Journal of Applied Physiology* . 1992; 72:1338-1347.
- [6] O' Donnell DE, Revill SM, Webb KA. Dynamic hyperinflation and exercise intolerance in COPD. *American Journal of Respiratory and Critic Care Medicine* 2001;164:770-777.
- [7] O'Donnell DE, Voduc N, Fitzpatrick M, Webb KA. Effect of salmeterol on the ventilatory response to exercise in chronic obstructive disease. *European Respiratory Journal* 2004;24:86-94.
- [8] Belman MJ, Botnick WC, Shin JW. Inhaled bronchodilators reduce dynamic hyperinflation during exercise in patients with chronic obstructive pulmonary disease. *American Journal of Respiratory and Critic Care Medicine* 1996;153:967-975.
- [9] Martinez FJ, de Oca MM, Whyte RI, Stetz J, Gay SE, Celli BR. Lung-volume reduction improves dyspnea, dynamic hyperinflation, and respiratory muscle function. *American Journal of Respiratory and Critic Care Medicine* 1997;155(6):1984-90.

- [10] Aliverti A, Stevenson N, Dellacà RL, Lo Mauro A, Pedotti A, Calverley PMA. Regional chest wall volumes during exercise in chronic obstructive pulmonary disease. *Thorax* 2004;59:210-216.
- [11] Innocenti Bruni G, Gigliotti F, Binazzi B, Romagnoli I, Duranti R, Scano G. Dyspnea, chest wall hyperinflation, rib cage distortion in exercising COPD patients. *Medicine and Science in Sport & Exercise* 2012. DOI:10.1249
- [12] Georgiadou O, Vogiatzis I, Stratakos G, Koutsoukou A, Golemati S, Aliverti A, Rousos C, Zakyntinos S. Effects of rehabilitation on chest wall volume regulation during exercise in COPD patients. *European Respiratory Journal* 2007; 29:284-291.
- [13] O'Donnell DE, Bain DJ, Webb K. Factors contributing to relief of exertional breathlessness during hyperoxia in chronic air flow limitation. *American Journal of Respiratory and Critic Care Medicine* 1997;155:530-535.
- [14] Somfay A, Porszasz J, Lee SM, Casaburi R. Dose-response effect of oxygen on hyperinflation and exercise endurance in non hypoxaemic COPD patients. *European Respiratory Journal* 2001;18:77-84.
- [15] Gigliotti F, Coli C, Bianchi R, Romagnoli I, Lanini B, Binazzi B, Scano G. Exercise training improves exertional dyspnea in patients with COPD: evidence of the role of mechanical factors. *Chest* 2003;123:1794-1802.
- [16] Iandelli I, Aliverti A, Kayser B, Dellacà R, Cala SJ, Duranti R, Kelly S, Scano G, Sliwinski P, Yan S, Macklem PT, Pedotti A. Determinants of exercise performance in normal men with externally imposed expiratory flow limitation. *Journal of Applied Physiology* 2002;92:1943-1952.
- [17] Ward ME, Eidelman D, Stubbing DG, Bellemare F, Macklem PT. Respiratory sensation and pattern of respiratory muscle activation during diaphragm fatigue. *Journal of Applied Physiology* 1988;65:2181-2189.
- [18] Potter WA, Olafsson S, Hyatt RE. Ventilatory mechanics and expiratory flow limitation during exercise in patients with obstructive lung disease. *Journal of Clinical Investigation* 1971;50:910-919.
- [19] Binazzi B, Bianchi R, Romagnoli I, Lanini B, Stendardi L, Gigliotti F, Scano G. Chest wall kinematics and Hoover's sign. *Respiratory Physiology and Neurobiology*. 2008;160:325-333.
- [20] Garcia-Pachon, E. Paradoxical movement of the lateral rib margin (Hoover Sign) for detecting obstructive airway disease. *Chest*. 2002;122,651-655.
- [21] Gilmartin JJ, Gibson GJ. Abnormalities of chest wall motion in patients with chronic airflow obstruction. *Thorax*. 1984;39,264-271.

- [22] Gilmartin, JJ, Gibson GJ. Mechanisms of paradoxical rib cage motion in patients with chronic pulmonary disease. *American Review of Respiratory Diseases*. 1986;134:683–687.
- [23] Chihara K, Kenyon CM, Macklem PT. Human rib cage distortability. *Journal of Applied Physiology*. 1996;81:437-447.
- [24] Jubran A, Tobin MJ. The effect of hyperinflation on rib cage-abdominal motion. *American Review of Respiratory Diseases*. 1992;146:1378–1382.
- [25] Romagnoli I, Gigliotti F, Lanini B, Innocenti Bruni G, Coli C, Binazzi B, Stendardi L, Scano G. Chest wall kinematics and breathlessness during unsupported arm exercise in COPD patients. *Respiratory Physiology and Neurobiology* 2011;178:242-9.
- [26] Aliverti A, Quaranta M, Chakrabarti B, Albuquerque AL, Calverley PM. Paradoxical movement of the lower ribcage at rest and during exercise in COPD patients. *European Respiratory Journal* 2009;33:49-60.
- [27] Peters MM, Webb KA, O'Donnell DE. Combined physiological effects of bronchodilators and hyperoxia on exertional dyspnoea in normoxic COPD. *Thorax* 2006;61:559-67.
- [28] Vogiatzis I, Georgiadou O, Golemati S, Aliverti A, Kosmas E, Kastanakis E, Geladas N, Koutsoukou A, Nanas S, Zakynthinos S, Roussos C. Patterns of dynamic hyperinflation during exercise and recovery in patients with severe chronic obstructive pulmonary disease. *Thorax* 2005;60(9):723-9.
- [29] Tangri S, Wolf CR., The breathing pattern in chronic obstructive lung disease during the performance of some common daily activities. *Chest* 1973; 63:126-127.
- [30] Celli BR, Rassulo J, Make BJ. Dyssynchronous breathing during arm but not leg exercise in patients with chronic airflow obstruction. *New England Journal of Medicine*. 1986;314:1485-1490.
- [31] Ries AL, Bauldoff GS, Carlin BW, Casaburi R, Emery CF, Mahler DA, Make B, Rochester CL, Zuwallack R, Herrerias C. Pulmonary Rehabilitation: Joint ACCP/AACVPR Evidence-Based Clinical Practice Guidelines. *Chest* 2007;131:4S-42S.
- [32] Janaudis-Ferreira T, Hill K, Goldstein RS, Robles-Ribeiro P, Beauchamp MK, Doldmage TE, Wadell K, Brooks D. Resistance arm training in patients with COPD: a randomized controlled trial. *Chest* 2011;139:151-158.
- [33] McKeough ZJ, Alison JA, Bayfield MS, Bye PT. Supported and unsupported arm exercise capacity following lung volume reduction surgery: a pilot study. *Chronic Respiratory Disease* 2005;2:59-65.
- [34] Holland AE, Hill CJ, Nehez E, Ntoumenopoulos G. Does unsupported upper limb exercise training improve symptoms and quality of life for patients with chronic obstructive pulmonary disease? *J Cardiopulmonary Rehabilitation* 2004;24:422-427.

- [35] Ries AL, Ellis B, Hawkins RW. Upper extremity exercise training in chronic obstructive pulmonary disease. *Chest* 1988 ;93:688-692.
- [36] Neiderman MS, Clemente PH, Fein AM, Feinsilver SH, Robinson DA, Ilowite JS, et al. Benefits of a pulmonary rehabilitation program: improvements are independent of lung function. *Chest* 1991;99:7989-7804.
- [37] Martinez FJ, Vogel PD, Dupont DN, Stanopoulos I, Gray A, Beamis JF. Supported arm exercise vs unsupported arm exercise in the rehabilitation of patients with severe chronic airflow obstruction. *Chest* 1993;103(5):1397-402.
- [38] Costi S, Crisafulli E, Antoni FD, Beneventi C, Fabbri LM, Clini EM. Effects of unsupported upper extremity exercise training in patients with COPD: a randomized clinical trial. *Chest* 2009;136:87-395.
- [39] Couser JI Jr, Martinez FJ, Celli BR. Pulmonary rehabilitation that includes arm exercise reduces metabolic and ventilatory requirements for simple arm elevation. *Chest* 1993;103:37-41.
- [40] Lake FR, Henderson K, Briffa T, Openshaw J, Musk AW. Upper-limb and lower-limb exercise training in patients with chronic airflow obstruction. *Chest* 1990;97:1077-1082.
- [41] Romagnoli I, Scano G, Binazzi B, Coli C, Innocenti Bruni G, Stendardi L, Gigliotti F. Effect of arm training on unsupported arm exercise-related perception in COPD patients. Under revision in *Respiratory Physiology and Neurobiology*
- [42] Bianchi R, Gigliotti F, Romagnoli I, Lanini B, Castellani C, Grazzini M, Scano G. Chest wall kinematics and breathlessness during pursed-lip breathing in patients with COPD. *Chest* 2004;125(2):459-65.
- [43] Bianchi R, Gigliotti F, Romagnoli I, Lanini B, Castellani C, Binazzi B, Stendardi L, Grazzini M, Scano G. Patterns of chest wall kinematics during volitional pursed-lip breathing in COPD at rest. *Respiratory Medicine* 2007;101:1412–1418.
- [44] Macklem PT. Exercise in COPD: damned if you do and damned if you don't. *Thorax* 2005;60:887-888.
- [45] Nuss D, Kelly RE, Croitoru DP, Kats ME, A 10-year review of a minimally invasive technique for the correction of pectus excavatum. *Journal of Pediatric Surgery* 1998;33:545–552.
- [46] Nuss D, Minimally invasive surgical repair of pectus excavatum. *Seminars in Pediatric Surgery* 2008;17:209–217.
- [47] Binazzi B, Innocenti Bruni G, Coli C, Romagnoli I, Messineo A, Lo Piccolo R, Scano G, Gigliotti F. Chest wall kinematics in young subjects with pectus excavatum. *Respiratory Physiology and Neurobiology* 2012;180:211–217.
- [48] Binazzi B, Innocenti Bruni G, Gigliotti F, Coli C, Romagnoli I, Messineo A, Lo Piccolo R, Scano G. Effects of the Nuss procedure on chest wall kinematics in adolescents

with pectus excavatum. In press in *Respiratory Physiology and Neurobiology*. DOI:
10.1016/j.resp.2012.05.015

IntechOpen

IntechOpen

