

We are IntechOpen, the world's leading publisher of Open Access books Built by scientists, for scientists

4,800

Open access books available

122,000

International authors and editors

135M

Downloads

Our authors are among the

154

Countries delivered to

TOP 1%

most cited scientists

12.2%

Contributors from top 500 universities



WEB OF SCIENCE™

Selection of our books indexed in the Book Citation Index
in Web of Science™ Core Collection (BKCI)

Interested in publishing with us?
Contact book.department@intechopen.com

Numbers displayed above are based on latest data collected.

For more information visit www.intechopen.com



Intravascular Lead Extractions: Tips and Tricks

Spyridon Koulouris and Sofia Metaxa

Additional information is available at the end of the chapter

<http://dx.doi.org/10.5772/48496>

1. Introduction

The transvenous insertion of implantable pacemaker (PM) and implantable cardioverter defibrillator (ICD) leads was a major milestone in antiarrhythmic therapy with the use of cardiac devices. Indeed, based on data published over the last decade the indications for ICD therapy have further expanded [1,2] while cardiac resynchronization therapy (CRT) through bi-ventricular pacing has significantly improved mortality and quality of life in patients with heart failure and ventricular dyssynchrony [3,4,5]. Unfortunately, this exponential increase in the implantation rate of cardiac devices has been accompanied by a parallel increase in the need for explanting some of those [6]. This has been mainly attributed to the so called “increased total lead exposure time” resulting from the expanding indications for device treatments, the implantation of more leads per patient and the longer average life expectancy of device-recipients [7]. Lead removal has been performed only in limited centers from physicians with some expertise in this subject. The volume of procedures in these centers has also been increasing in a continuous manner and the techniques applied have become more and more sophisticated and effective. Indeed, the options for lead extraction were initially very limited and dedicated tools were not available. Life threatening situations such as infection with sepsis were the only reason to attempt a lead removal with these highly morbid and often ineffective techniques [8]. As a necessity to overcome these limitations a significant evolution in lead extraction technology occurred over the past 30 years. More simple, safe and efficacious techniques are nowadays widely used in clinical practice [9].

Dealing with a possible lead extraction, the main technical problems that have to be taken into consideration are: the endovascular reaction surrounding the intravenous lead, the physical characteristics of the lead affecting its removability and the lack of direct visualization along the intravascular route. Fibrotic scar tissue develops at areas of endothelial contact and engulfs the leads. This process begins with thrombus development along the lead at the time of implantation. Fibrosis of the thrombus occurs next resulting in

almost complete encapsulation of the lead with a fibrin sheath within 4-5 days post implant [10,11]. Calcification of the fibrous tissue may even occur over time especially in young patients [12]. The most common adhesion sites include the venous entry site, the superior vena cava and the electrode-endocardial interface [13]. (Figure 1). In the majority of patients multiple areas of scar tissue are found. This scar resists against lead explantation and specific manipulations are needed to overcome this particular obstacle. In addition, lead to lead interaction and binding in the case of multiple leads as well as along each of the shocking coils of the ICD leads may happen, which may pose further limitations in the extraction procedure (Figure 2).

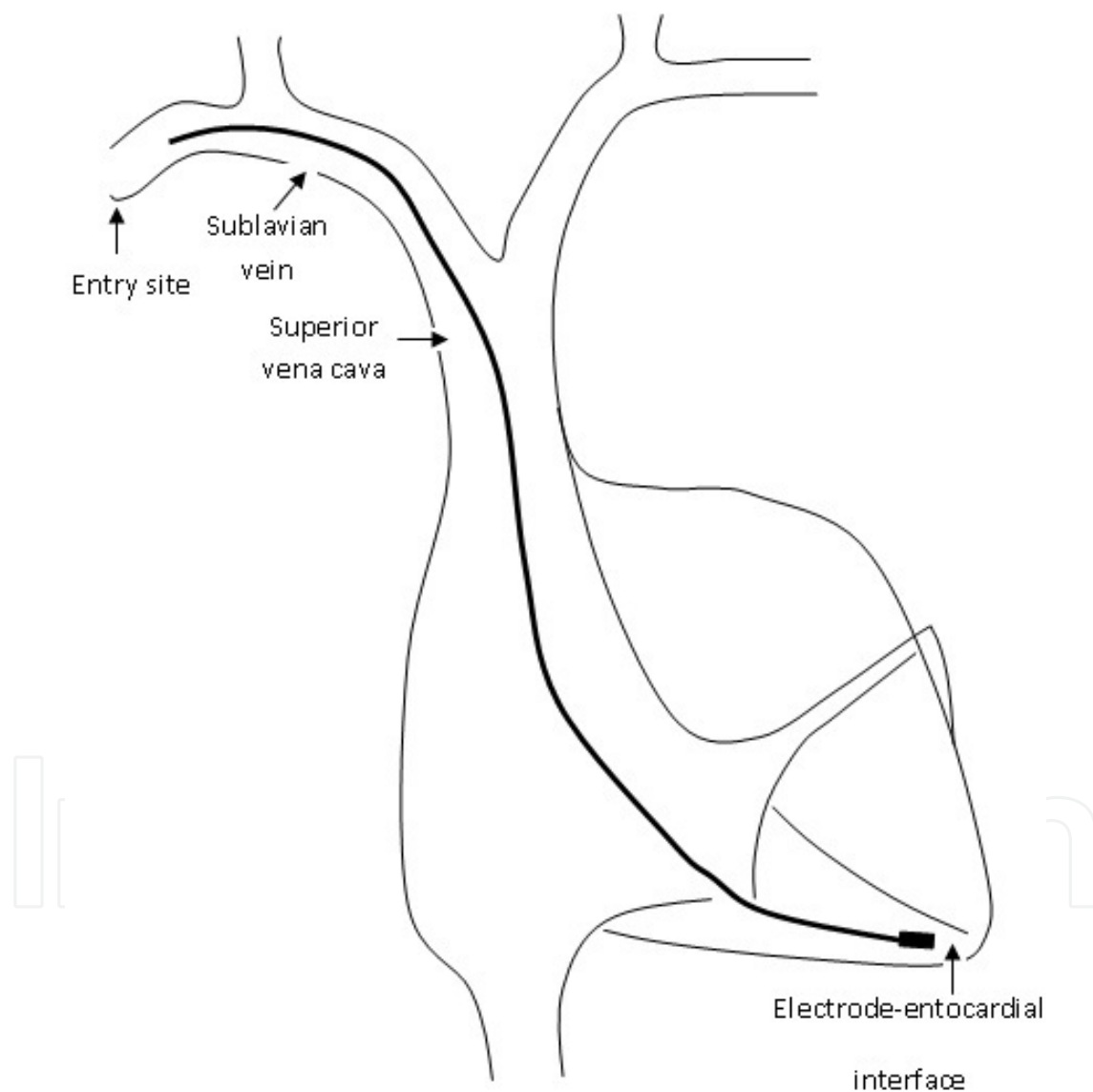


Figure 1. Location of areas of lead adherence.

On the other hand, the material and construction of the lead may promote or resist the development of scar tissue and may also largely affect the lead removability through its specific tensile strength characteristics. To combat the formation of fibrous connections,

manufacturers have recently attempted to produce ICD coils coated with expanded polytetrafluoroethylene (ePTFE) or back-filled with medical adhesive (MABF). Both have been shown to be easier to extract due to decreased incidence of fibrosis on and around the filters of the coils [14]. Finally, the indirect control on the procedure from the operator due to the lack of direct visualization urges the outmost care and experience in order to avoid any major or even life-threatening consequences. Because lead extraction is not frequently performed, few high-volume centers can provide the best patient care along with opportunities for adequate physician training in this field. Both European and American Societies of Electrophysiology have set standards for training and accreditation in order to overcome these limitations. Generally, a minimum of 40 lead extractions as the primary operator is required to be considered fully trained, and 20 leads per year is needed to maintain competency [6,15].



Figure 2. Extensive scarring over an extracted ICD lead.

2. Indications for lead extraction

Indications for device removal can be divided in two categories: *infectious* and *non-infectious*. Non-infectious indications include malfunctioning leads or leads which through their presence can cause harm to the patient (for example thrombosis of the superior vena), as well as leads that have to be removed in order to upgrade a device. In all published reports,

infection seems to be the most common indication for lead extraction (54-60% of all extraction procedures)[16,17].

Previous reports have indicated an overall rise in the rate of device infection which might have been attributed to the wider implantation of ICDs for primary prevention of sudden cardiac death in a population whose health status is by definition relatively poor (patients post myocardial infarction with low ejection fraction and clinical signs of heart failure). Another reason could have been the subsequent generator changes whose rate has been following the increasing rate of initial implantation. Both ICD implantation and generator replacement have been clearly associated with a higher rate of device infections [18,19]. On the other hand, others have more recently reported that referrals for extraction for infection and upgrade of the device have remained relatively stable in contrast to the incidence of lead failure which seems to have decreased over the last decade (Figure 3) [20].

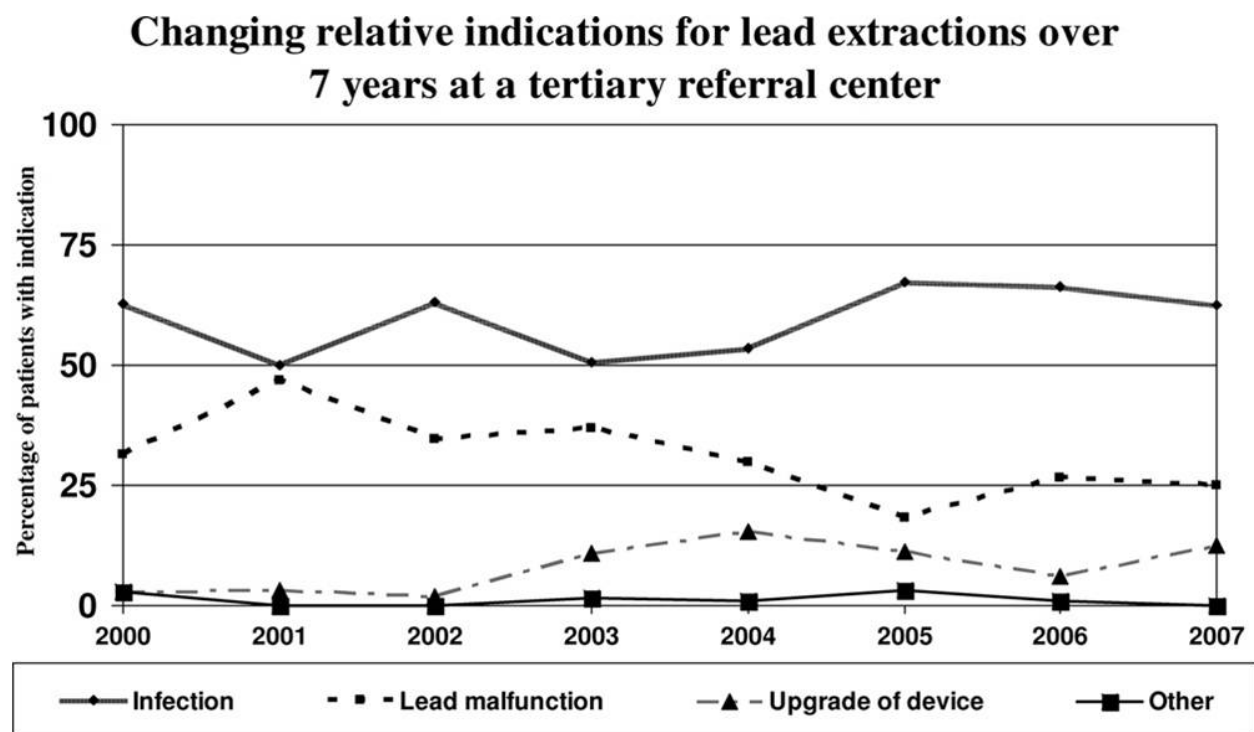


Figure 3. Indications for lead extraction in a cohort of 498 patients. There is a clear trend in the decreasing indication for lead removal due to malfunction. Referrals for extraction for infection and upgrade of the device have remained relatively stable over time (From: Jones SO, et al. Large, single-center, single-operator experience with transvenous lead extraction: Outcomes and changing indications. *Heart Rhythm* 2008;5:520-525, with permission)

The indication to remove a lead in all the above circumstances is largely dependent on patient's age, general condition, the potential of future problems, the risk to extract and the potential harmful circumstances associated with the lead presence such as subclavian or superior vena cava thrombosis. However, infection of the device regardless of its presentation makes the removal of the whole system unavoidable. This has been shown to be the only effective way to totally resolve this potentially life-threatening health problem. Staphylococcal infections dominate the responsible flora. In a recent survey Methicillin-sensitive *S. aureus* was found in 25% Methicillin-resistant *S. aureus* was found in 34% and Coagulase-negative *S. species* were found in 14% of the cases of pacemaker endocarditis [21]. It should be noted that even if the infection is by clinical examination found to be confined to the pocket of the device, complete removal of the system including the leads has to be performed in order to avoid future relapse of the disease in the form of endocarditis. Studies have shown that leads not thought to be infected may in fact be heavily colonized by bacteria entering the systemic circulation at the pocket site [22,23]. Indeed, the majority of extraction procedures are currently performed for infections localized to the device pocket. Nevertheless, a more widespread infection is not uncommon. In a recent review of 189 patient admitted in a single tertiary center with device infection, pocket infection was present in 52% of them while 17% had evidence of pocket infection with blood stream infection and 23% had developed device-related endocarditis [24] Finally, even in patients presenting with an erosion of the pocket, as a consequence of infection or mechanical pressure or both, the system should be considered contaminated and has to be completely removed. Of note, adherence of the generator or leads to the skin often proceeds erosion and is an indication for extraction too (Figure 4) [6,15]. Nevertheless, a few authors may still advocate a conservative approach with debridement and chronic antibiotic administration in elderly, infirm patients with a limited life expectancy [25].

Controversy continues to exist regarding the other indications for lead removal. The risk posed by abandoned leads is relatively low. Thus many physicians would recommend simply abandoning malfunctioning leads. The opposite is however true as well. In most of the series the attempts to remove abandoned leads has been associated with a relatively low risk of complications. Accordingly, in the hands of more experienced operators non-functioning leads may become a challenge for an extraction attempt [26]. Moreover, the risk of venous obstruction seems to increase proportionally to the number of leads and this has raised some additional concerns regarding the safety of leaving "orphan" leads in place. Accordingly, the decision of explanting a non-infected lead needs to be individualized in most of the cases. The cause of malfunction is insulation defect in the majority of pacemaker lead failures [27]. In the case of ICDs, high-voltage coil failures and disruption of the polyurethane inner insulators represent the most common reason that may lead to a lead replacement. Of note, ICD lead failure rate is not at all negligible. In a recent survey failure rate reached 20% in 10-year-old leads [28].

A comprehensive list of lead removal indications has been recently published in Heart Rhythm Society expert Consensus Statement (Table 1). Nevertheless, it is important to

remember that selection of the patients for lead extraction should be done on an individual case-by-case basis taking always into account the patient's clinical picture and general health status, the lead characteristics and the operator's experience along with the availability of the specific facilities and tools. Only in the case that the risk of extraction is lower in comparison to the risk of lead abandonment a procedure should be attempted.

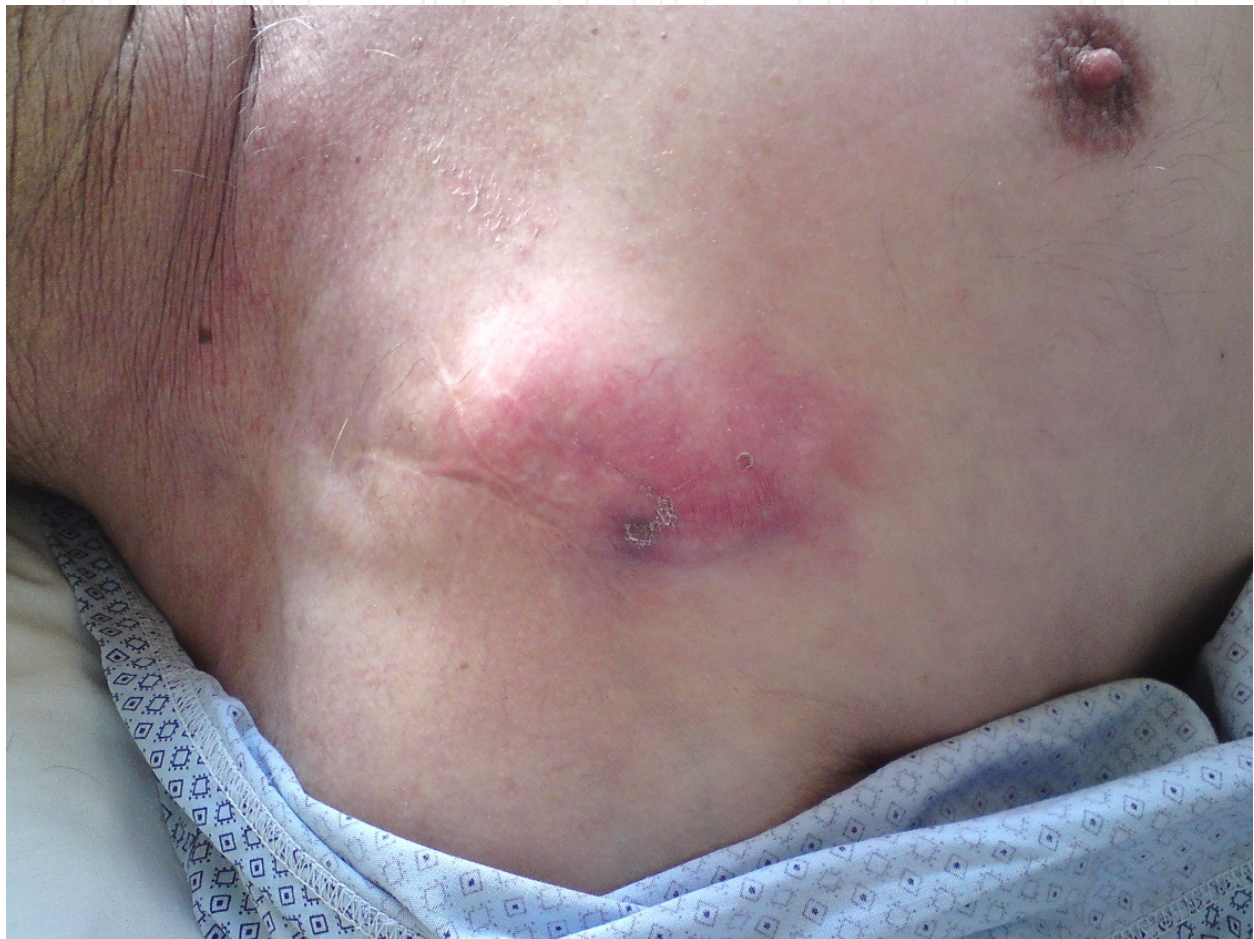

Figure 4. Device adherence to the overlying skin with initiation of erosion

3. The extraction procedure

The goal of extraction techniques of chronic pacemaker and defibrillator leads is to present an approach that is successful in extracting all leads and minimizes or eliminates complications. Separating the lead from the encapsulating inflammatory tissue is the most crucial step in this process. However, regardless of the technique that will be used, clinicians must be prepared to deal with the fact that this procedure may vary from a simple to an extremely complicated one. Thus, careful planning of the procedure along with meticulous patient preparation seems mandatory.

Indication	Class I Procedure should be performed	Class IIa Reasonable to perform procedure	Class IIb Procedure may be considered	Class III Procedure should not be performed
Infection	1. Definite infection of CIED e.g. device endocarditis or sepsis (LOE: B) 2. CIED pocket infection e.g. abscess, erosion or chronic draining sinus (LOE: B) 3. Valvular endocarditis w/o definite lead and/or device involvement (LOE: B) 4. Occult gram-positive bacteraemia (LOE: B)	Persistent occult gram-negative bacteraemia (LOE:B)		1. Superficial or incisional infection w/o involvement of device/leads (LOE: C) 2. Chronic bacteraemia due to a source other than CIED when long term suppressive antibiotics are required (LOE: C)
Thrombosis or venous stenosis	1. Clinically significant TE events associated with thrombus on lead or fragment (LOE: C) 2. Bilateral SCV or SVC occlusion precluding implant of needed TV lead (LOE: C) 3. Planned stent deployment in vein with TV lead already to avoid entrapment (LOE: C) 4. Symptomatic SVC stenosis/occlusion (LOE: C) 5. Ipsilateral venous occlusion precluding implant of additional lead when contralateral implant contraindicated (AVF, shunt or vascular access port, mastectomy) (LOE: C)	Ipsilateral venous occlusion precluding ipsilateral implant of additional lead w/o contraindication to contralateral implant (LOE: C)		

Indication	Class I Procedure should be performed	Class IIa Reasonable to perform procedure	Class IIb Procedure may be considered	Class III Procedure should not be performed
Functional leads	1. Life threatening arrhythmias due to retained leads (LOE: B) 2. Leads, due to design or failure, may pose immediate threat if left in place (LOE: B) 3. Leads that interfere with CIED function (LOE: B) 4. Leads that interfere with treatment of malignancy (radiation, surgery) (LOE: C)		1. Leads w/potential interference with CIED function (LOE: C) 2. Leads, due to design or failure, with potential threat if left in place (LOE: C) 3. Abandoned leads (LOE: C) 4. Need for MRI imaging w/o alternative (LOE: C) 5. Need for MRI conditional CIED system (LOE: C)	1. Redundant leads with <1 year life expectancy (LOE: C) 2. Known anomalous lead placement (SCA, Ao, pleura, etc) or through a systemic atrium or ventricle* (LOE: C) 3. *Can be considered w/surgical backup
Non-functional leads		1. Leads, due to design or failure, with potential threat if left in place (LOE: C) 2. CIED implant would yield >4 leads on one side or >5 leads through SVC (LOE: C) 3. Need for MRI imaging w/o alternative (LOE: C)	1. At time of indicated CIED procedure w/o contraindication to TLE (LOE: C) 2. Need for MRI conditional CIED system (LOE: C)	1. Redundant leads with <1 year life expectancy (LOE: C) 2. Known anomalous lead placement (SCA, Ao, pleura, etc) or through a systemic atrium or ventricle* (LOE: C) 3. *Can be considered w/surgical backup
Chronic pain		Severe chronic pain at device or lead insertion site with significant discomfort not manageable by medical or surgical techniques and w/o acceptable alternative (LOE: C)		

Table 1. Indications for transvenous lead extraction

Ao, aorta; CIED, cardiovascular implantable electronic device; DRE, device related endocarditis; LOE, level of evidence; SCA, subclavian artery; SCV, subclavian vein; SVC, superior vena cava; TE, thromboembolic; TLE, transvenous lead extraction; TV, transvenous; w/, with; w/o, without.

3.1. Pre-procedural and patient preparation

Extractions can be performed either in the electrophysiology / catheterization laboratory or in the operating room. The site varies according to the preference and the availability of each center [29]. In any case, a cardiothoracic surgical back up should be always immediately available to intervene in case of life threatening complications. In the presence of such a team, safety is comparable in both settings [30]. In addition to the stand-by surgeon, the required personnel include the physician performing the procedure, a "scrubbed" and a "non-scrubbed" assistant, a third "outside the door" assistant to provide equipment and assist in an emergency, anesthesia support and an x-ray technician or other personnel to operate the fluoroscopy. Regarding the instrumentation, a full range of extraction tools should be available. Additional emergency equipment that should be present in the room or immediately available includes sets for pericardiocentesis, chest drainage, vascular repair, thoracotomy, sternotomy and cardio-pulmonary bypass. In addition, equipments for transthoracic and transesophageal echocardiography, temporary pacing and general anesthesia as well as vasopressors and other emergency medications should also be available [15].

A detailed patient history should be obtained and a complete physical examination should be performed before the patient arrives to the interventional suite. Co-morbidities (anticoagulation therapy, renal impairment, allergies and antibiotic resistance) should be carefully taken into account when planning the procedure. Details about prior implantations and about the hardware in place are also mandatory. Technical characteristics of the lead should be known in advance. The vascular route has to be also explored in advance. Chest fluoroscopy can define the number, type and location of leads. Extravascular coursing can be detected through chest computed tomography [31]. Venography may be useful in case that a vascular access problem is anticipated. A transesophageal echocardiogram should be performed in all infected patients to check for vegetations. The size, shape and friability of vegetations may preclude transvenous extraction and support the decision to take the patient to the operating room. Although a clear cut-off point for the vegetation size has not been defined, many physicians would advocate surgical removal of leads of infected leads with large vegetations (>1-1,5 cm) [32],[33]. More recent evidence, however, suggests that even larger vegetations can be safely removed percutaneously [21]. Laboratory examinations should include: blood typing and crossmatch, a full blood count, coagulation profile, electrolytes, renal and liver function tests, virology screen (Hep B, C and HIV), C-reactive protein and erythrocyte sedimentation rate. A pregnancy test for young females should not be omitted [15] Finally, the patient preparation concludes with the obtaining of written informed consent.

The day of the procedure 4 packs of red blood cells should be immediately available. The patient is prepared with chlorhexidine or povidone iodine and wrapped in a way to allow access ipsilaterally and contralaterally to the site of implantation, as well as to permit emergent pericardiocentesis, thoracentesis, thoracotomy, sternotomy or cardiopulmonary

bypass. Large bore iv. cannulae in peripheral veins are placed bilaterally to allow for rapid fluid infusion. A percutaneous arterial line is placed for direct blood pressure monitoring. Non-invasive automated blood pressure measurements, electrocardiographic monitoring and pulse oximetry are also available throughout the procedure. Femoral venous access is obtained for possible rapid fluid administration, for potential upgrade to a transfemoral approach or to facilitate the placement of a temporary pacing electrode. For patients who are pacemaker dependent, a temporary pacemaker lead inserted via the internal jugular or the femoral vein is adequate if the system is not infected and will be immediately replaced. In the case of infected leads several strategies of inserting a longer lasting temporary lead have been described (for example placing an active fixation permanent lead through the internal jugular vein) in order to permit for an adequate lead-free interval of antibiotic administration before the permanent system will be re-implanted. The externalized pulse generator after it has been cleaned and sterilized has been successfully used for temporary pacing in some centers [34]. In patients with ICDs tachycardia therapies should be switched off in order to prevent inappropriate shocks.

3.2. Techniques and tools

Generally speaking, leads can be removed with one of the following techniques:

- a. Manual traction without tools
- b. Traction mediated by some sort of weight or by application of a clamp to the stretched lead
- c. Mechanical sheaths, with or without the use of a locking stylet
- d. Laser-assisted lead extraction, with or without the use of a locking stylet
- e. Open chest extraction, with or without transvenous extraction tools
- f. Thransthoracic extraction using a paraternal, subxyphoid or intercostals approach [7].

If a decision has been made to proceed via the transvenous route after the device has been opened, the pulse generator is removed and the leads to the vascular entrance are freed through careful dissection usually with the aid of electrocautery. The incision is usually performed at the site of the initial one, although some physicians make a second incision over the venous entry site of the leads. Infected pockets should undergo thorough revision and microbial cultures of the tissue should be obtained. Irrigation with hydrogen peroxide or chlorexidine and meticulous removal of all infected tissue must follow. It is not clear if a complete capsulectomy needs to be done, although this is dictated by common sense in the case an ipsilateral implantation is planned. After the leads have been dissected all the way down to the venous entry site, the anchor sleeves are removed along with any suture remnants. It is essential that the leads be completely freed and remain intact. Damaged leads can be hard to extract. When using cautery it should be kept instead that polyurethane insulation is more heat sensitive than silicone [7]. Back bleeding issues may arise when dissecting at the venous entry site. A 2-0 suture placed as a snare in the surrounding tissues may help to solve this problem.

At this stage transvenous extraction can be successfully performed in one of the following ways applied commonly in a steward fashion:

Simple traction after the insertion of a regular stylet can be sufficient for recently implanted leads. Some experts advocate the gain of ipsilateral venous access through the introduction of a thin (i.e. 5 French) dilator and a guide wire prior to the traction attempt [3]. We do not routinely follow this practice. We simply place moderate traction on the free part of the lead trying to avoid stretching of the insulation or the induction of ectopy in the electrocardiogram. Unfortunately, there is not a priori certainty which lead will be successfully removed through this simple procedure. With traction, fibrous encapsulation often provides sufficient friction to prevent the force applied from being transmitted to the tip of the lead. When more force is needed, the tensile strength of the insulation or the conductor can be exceeded resulting in stretching or rupture. The lead may become irreversibly damaged complicating the extraction process and even leaving part of it indwelling in the venous circulation. Thus, it is of paramount importance for the lead to be removed in one piece. This can happen only if the operator has control of the body lead throughout the procedure binding the elements of the lead together. In that case, the exposed part of the lead can be used as a handle to remove its endovascular segments which will not be the case if the lead becomes distorted or elongated. Although it may be possible to snare fragments of the lead that have remained intravascularly after the main body of the lead has been removed, this may become increasingly hard at times.

Regarding the type of the lead which can be extracted by simple traction, there is always a better chance for recently implanted and active fixation than passive fixation leads, especially if they are isodiametric and can be unscrewed before extraction. Sometimes this is not feasible because the mechanism is damaged or tissue is plugging the helix. In that case manual counterclockwise rotation of the lead body may unscrew the lead. However, to achieve this, the lead body must be free of adhesions in its entire course. In the case of atrial leads, where the helix has often extended through the thin atrial wall, failure to retract the helix makes traction particularly dangerous in removing a plug of atrial tissue with subsequent tamponade. As a rule, traction should not be placed on a lead not fully unscrewed unless a cardiac surgeon is present and the operating room is ready to accept the patient.

In general, invagination of the myocardium may complicate any case of unopposed traction. Arrhythmias and hypotension can be the result of myocardial rupture, avulsion of a tricuspid valve leaflet or rupture of the superior vena cava or the subclavian veins. To avoid these complications, prolonged graded traction has been introduced. Historically speaking Bilgutay et al [35] created a graded weight and pulley system to deliver gentle traction on the externalized portion of the lead. This system required prolonged hospitalization with bed rest, increased the risk of infection and was proven frequently unsuccessful. This technique has been totally replaced nowadays from the use of locking stylets.

Traction via a locking stylet is directly applied at the tip, bypassing the conductor and the insulation. If manual traction is unsuccessful, the inner lumen is reamed with a conventional stylet to remove debris and the lead is cut approximately 5 cm from the vascular entry with a sharp scissor to maintain the shape of the spiral conductors. Care must be taken not to damage the distal lead, which should be firmly held by the assistant with his fingers or with a soft clamp if available. The central lumen of the lead is then identified and a locking stylet is inserted through it. To avoid pulling out the core and leaving the outer insulation in place, a ligature is used to tie down the insulation with the rest of the lead components and with the locking stylet. To choose the locking stylet of the appropriate size, the inner lumen diameter has to initially be measured with the insertion of a series of gauze pins. A locking stylet of a size corresponding to the largest pin was chosen. This is no longer necessary since most of the contemporary stylets are designed to accommodate a wide range of conductor coil diameters. Locking stylets consist of a straight non-expandable wire that can be locked into the coil close to the tip of the lead. This specific design permits to focus the force of traction as close to the lead tip as possible. As a consequence, the risk of lead disruption is reduced and the likelihood of complete removal of the lead is increased [36],[37]. Several types of stylets with different locking exist. The most commonly used are: the Liberator (Cook Medical, Bloomington, Indiana, USA), the Lead Locking Device (LLD) EZ (Spectranetics, Colorado Springs, Colorado, USA) and the Extor Set (VascoMed, Binzen, Germany) (Figure 5).

The locking mechanisms of the Liberator and the Extor Set are at the distal tip of the stylet providing focal traction at the tip of the lead, whereas the LLD EZ stylet grabs the lead in multiple areas and delivers stable traction along the entire lead length. An additional advantage of both the Extor and the LLD is that they provide the ability to unlock and reposition after initial deployment. This can facilitate the advancement of the locking stylet to the lead tip in cases the later is very tortuous or has sharp bends. In that case, the clinician can advance the stylet to the obstruction, lock the stylet, free the lead at that point, unlock the stylet and advance it to the next obstruction point, repeat the maneuver and manage to reach the lead tip at the end. The Bulldog Lead Extender (Cook Medical) is a tool that can be useful if a lead cannot receive a locking stylet due to extensive damage or a solid core design. It consists of a wire with a threadable handle through which the lead is passed and secured, thereby locking the insulation and conductor to the extender. This way the exposed part of the lead is securely grasped and extended to a workable length allowing a potentially more effective direct traction.

There are still limitations to the use of a locking stylet. If the conductor is broken or distorted, e.g. with subclavian crush syndrome, it is not possible to introduce the stylet. It can also lack grip and dislocate during traction or too much force can damage the delicate locking mechanism. Further, as traction is still exerted via the distal conductor coil, this can unwind or disconnect from the electrode. As with direct traction, there is risk of invagination of the myocardium.




Figure 5. Various types of locking stylets. (A) The Liberator Locking Stylet (Cook Medical, Bloomington, Indiana, USA). (B) The Lead Locking Device (LLD) EZ (Spectranetics, Colorado Springs, Colorado, USA). In contrast to the Liberator locking stylet, the LLD locking stylet has a braided mesh over the entire length of a solid lead that expands when deployed. (C) The Extor Set (VascoMed, Binzen, Germany) (from *Maytine et al. The challenges of transvenous lead extraction. Heart* 2011;97:425-434, modified with permission)

Counter-pressure and Counter-traction: to overcome the limitations of a locking stylet, telescoping sheaths can be advanced over the lead with alternating counterclockwise and clockwise motions with moderate pressure. Fibrous bindings can be mechanically disrupted (*counter-pressure*). The outer sheath also functions as a guiding catheter facilitating the movement of inner sheath and alignment of the inner sheath and the lead. It is of paramount importance to use a locking stylet at the same time, as the leads are often too fragile to withstand the traction necessary to counter the forces applied to advance the sheath. Once the distal electrode is reached, the outer sheath can be positioned against the myocardium to prevent inversion (*counter-traction*). By pulling on the locking stylet, for several minutes if necessary, the tip of the lead is pulled inside the outer sheath. The force is thus concentrated at a small area of the scar tissue and the myocardium without gross displacement of the myocardium (Figure 6).

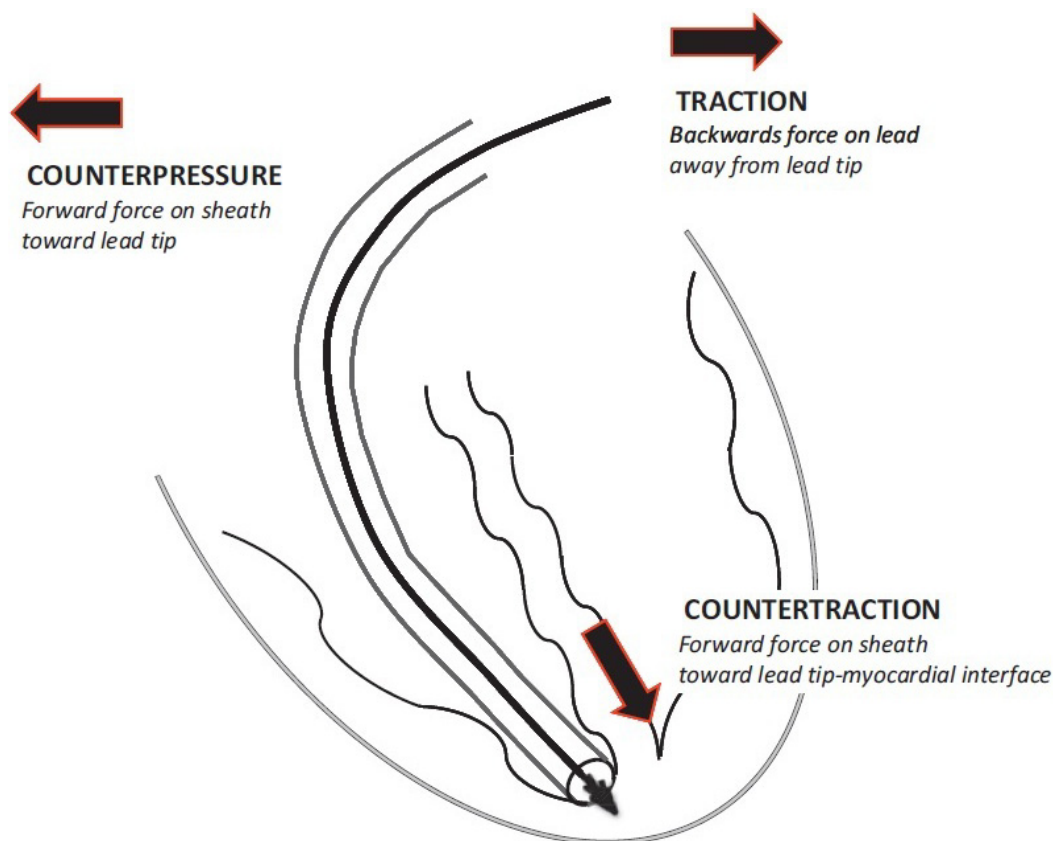


Figure 6. Schematic representation of the forces of counterpressure, traction, and countertraction. (from Maytine et al. The challenges of transvenous lead extraction. *Heart* 2011;97:425-434, with permission)

Telescopic sheaths are made of different materials (stainless steel, Teflon, and polypropylene) and are available in various sizes (7-16 French) (Figure 7). Sheath selection is determined by the clinical situation and the operator's preference and experience. Teflon is soft and flexible but is unable to cut through dense scar tissue, while polypropylene is stiffer and better at disrupting encapsulating scar but must be used with caution so as to avoid vascular injury. Stainless steel sheaths are employed only to deal with dense and calcified fibrosis. If despite the use of a stainless steel sheath, tight adhesions prevent further

advancement to reach the tip, changing to a power sheath and/or upsizing to a larger sheath may solve the problem.



Figure 7. Various types of telescopic sheaths (from Maytine et al. The challenges of transvenous lead extraction. *Heart* 2011;97:425-434, with permission)

Even the removal of large vegetations (up to 4 cm) has been successfully attempted by very experienced operators with the use of 16 French sheaths [7]. Although counter-traction prevents invagination of the myocardium and diminishes the chance of rupture, perforation of the myocardium is still possible, especially in the thin-walled atrium.

Powered sheath assisted extraction: If lead removal still proves unsuccessful, a powered sheath can be used as an alternative. Powered sheaths use a source of energy to make the dissection of encapsulating fibrous tissue easier and more efficient, thus enabling the advancement of the sheath along the lead with reduced countertraction and counterpressure forces. One such powered sheath is the Excimer Laser System (Spectranetics). It consists of optic fibers spirally warped between the inner and outer tubing of the sheath. At the tip of the device the fibers are arranged in a ring. Pulsed laser light is emitted from the fibers to ablate the tissue. The device is connected to a 308 nm XeCl excimer laser (Spectranetics CVX-300), which delivers pulsed light. As the penetration depth of 308 nm light in vascular tissue is $\sim 100 \mu$, it is completely absorbed in the tissue immediately in front of the tip. This results in an ablation depth, depending on the applied force, between 2 and 15 μ per pulse in the experimental setting. The influence of force is explained by increasing the mechanical effect of the micro-bubbles entrapped beneath the tip of the device in creating microscopic tears [38]. The sheath is advanced under fluoroscopic guidance over the lead body utilising the standard techniques of counterpressure and countertraction, and laser energy is delivered when encapsulating fibrous tissue halts sheath advancement. Tissue in direct contact with the sheath tip is ablated to a depth of 50 mm until the distal electrode is reached. It should be kept in mind that countertraction is still necessary to dislocate the lead tip. Great care must be paid to proper traction/countertraction techniques to prevent complications. Loss of coaxial orientation of the sheath and the lead can result in vascular injury. The leading edge of the bevel of the laser sheath should be oriented away from the vessel wall and the laser energy should be stopped before the lead tip is reached. Care must also be taken to avoid

damage of the tricuspid valve. The ablation results in a shearing of the fibrous bindings, often leaving a rim of scar tissue around the lead. Compared with mechanical telescoping sheaths, laser assisted extraction results in more frequent complete lead removal and shortened extraction times without an increase in procedural risk [39]. [40].

The Perfecta Electrosurgical Dissection Sheath (Cook Medical) represents another type of powered sheath. The electrosurgical dissection sheath consists of an inner polytetrafluoroethylene (PTFE) sheath with bipolar tungsten electrodes exposed at the distal tip and an outer sheath for counterpressure and countertraction. Radiofrequency energy is delivered between the bipoles to dissect through fibrous binding sites, much like a surgical cautery tool, although the lead tip must be liberated with countertraction. In contrast to the Excimer Laser Sheath, the Electrosurgical Dissection Sheath permits a localised application of radiofrequency energy with linear rather than circumferential dissection of the encapsulating fibrous tissue. The focused and steerable dissection plane offers the potential advantages of improved precision.

However, the sheath may have to be repositioned repeatedly as a result. The Electrosurgical Dissection Sheath offers a cost effective alternative to the Excimer Laser System without compromising safety or efficacy [41].

Finally, the Evolution and Evolution Shortie Mechanical Dilator Sheaths (Cook Medical) are 'hand powered' mechanical sheaths that consist of a flexible, braided stainless steel sheath with a stainless steel spiral cut dissection tip. The sheath is attached to a trigger activation handle that rotates the sheath and allows the threaded metal end to bore through calcified and dense adhesions [42].

An inferior vena cava or transfemoral approach also named as "the inferior approach" has been developed as the alternative mode to be used often only after the approach via the implant vein ("superior approach") has failed. It is also the procedure of choice for removal of broken or cut lead with free-floating ends. This technique is an old one [43] and over the years the following tools have been developed to assist in the extraction of leads by the femoral vein:

1. The Byrd Femoral Work Station (Cook Vascular Inc, Leechburg, PA)
2. The Dotter retriever Snare
3. The Curry Loop Snare
4. The Amplatz Snares 25 mm, 25 mm (Microvena Corp)
5. The Needls Eye Snares (Cook Vascular Corp) [44] (Figure 8)

Virtually all the femoral extraction techniques use some form of snaring. Two fundamental techniques have evolved. The first uses the combination of a wire loop and catheter to snare free ends or free-floating leads. The other creates a loop around the lead to be removed when there is no free end available for simple snaring. In any case, a long sheath is introduced via the femoral vein and positioned close to the lead. Then, a retriever is inserted through the sheath to grab and secure the lead close to the tip. The isodiametric proximal part of the lead (with the connector cut off) is pulled down through

the fibrous scar tissue. The outer sheath is then advanced over the doubled up lead to disrupt the scar tissue, while the lead is kept under tension by the retriever. When the sheath reaches the tip, counter-traction is applied. In comparison with the superior approach, only a short distance of scar tissue needs to be disrupted as the proximal isodiametric part of the lead can be simply pulled down. Therefore, even if no locking stylet has been used to reinforce the lead, the shorter distance to cover decreases the chance of elongating the lead. "Reversibility" is one of the most important principles to be followed with snaring techniques since the process of grasping a lead must be totally reversed and the lead freed again if necessary. If this situation cannot be reversed thoracotomy remains the only solution.

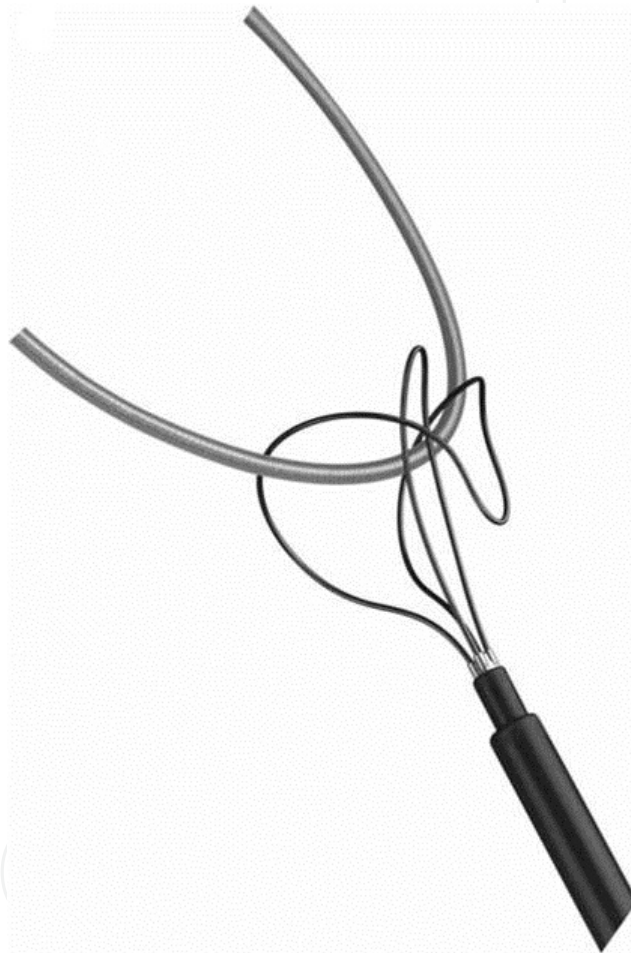


Figure 8. The Needle's Eye snaring tool

Beyond that, the main challenge of femoral retrieval remains manipulating the tools and snaring the lead in three dimensions under the guidance of two dimensional fluoroscopic imaging. The recent description of a novel technology to facilitate extraction and the maintenance of vascular access proposed a hybrid superior and inferior approach, with femoral snaring of the lead to stabilise the lead while countertraction and counterpressure are used through the right jugular vein to free the lead, reiterating the clinical importance of femoral retrieval [45],[46].

4. Complications

The major risks of transvenous lead extraction include: cardiac perforation (1-4%), emergency cardiac surgery (1-2%) and death (0.4-0.8%).³⁴ (Table 2). However, the risk of an individual varies according to the presence or absence of the following factors:

- Age of the patient (risk increase with advanced age)
- Gender of the patient (risk higher in female patients)
- Comorbidities
- Presence of calcifications on the leads
- Presence and size of vegetations
- Duration of implant
- Physical characteristics of the lead (fragility, condition)
- Presence of multiple leads
- Presence of ICD leads, especially with a superior vena cava coil

Major complications	Minor complications
Death	Pericardial effusion not requiring intervention
Cardiac avulsion requiring intervention (percutaneous or surgical)	Haemothorax not requiring intervention
Vascular injury requiring intervention (percutaneous or surgical)	Pocket haematoma requiring reoperation
Pulmonary embolism requiring surgical intervention	Upper extremity thrombosis resulting in medical treatment
Respiratory arrest/anesthesia related complication prolonging hospitalization	Vascular repair near implant site or venous entry site
Stroke	Hemodynamically significant air embolism
Cardiovascular implantable electronic device infection at previously non-infected site	Migrated lead fragment without sequelae
	Blood transfusion as a result of intraoperative blood loss
	Pneumothorax requiring a chest tube
	Pulmonary embolism not requiring surgical intervention

Table 2. Potential complications of transvenous lead extraction.

Complications result primarily from forces applied to separate leads from fibrous connections within the large vessels and the heart. Disruption of the superior vena cava or brachiocephalic vein is the most devastating complication of lead extraction, as it results in swift exsanguination in the thoracic cavity and is very difficult for the surgeon to control or repair. The superior vena cava has a wall thickness of sometimes <1 mm and is

vulnerable for damage by the sheaths. Of note, the pathway of least resistance is the vessel wall rather than the scar. Of course, damage to the superior vena cava and its branches veins may be minimized with a femoral approach. Some have suggested the use of a large balloon to tamponade bleed from the superior vena cava until the surgeon arrives. Death can occur or emergency surgery may be needed due the above complication but also due to cardiac tamponade from cardiac rupture or due pulmonary embolism from the dislodgment of large lead vegetations. Infection with re-implantation is another potential problem to consider. Proper care of the infected pocket is essential to prevent recurrent infection. Some operators elect to leave the wound open to heal by secondary intention while others prefer tight suturing of tissues to eliminate any residual cavity. As a rule, a new device should never be placed in a previous infected pocket. However, the most important principle in preventing lead extraction complications is to avoid lead extraction by meticulous operative technique at the time of the initial implantation and by early recognition of potential problems in the immediate post-operative period [47].

5. Lead extraction success rate

The Expert Consensus of the Hearth Rhythm Society has defined the success of the lead extraction procedure in two different ways [6]: **Complete Procedural Success** has been considered the removal of all targeted leads and all lead material from the vascular space, with the absence of any permanently disabling complication or procedure related death. On the other hand as **Clinical Success** has been defined the removal of all targeted leads and lead material from the vascular space, or retention of a small portion of the lead that does not negatively impact the outcome goals of the procedure. This may be the tip of the lead or a small part of the lead (conductor coil, insulation, or the latter two combined) when the residual part does not increase the risk of perforation, embolic events, perpetuation of infection or cause any undesired outcome. Finally, the Committee defined as **Failure** the inability to achieve either complete procedural or clinical success, or the development of any permanently disabling complication or procedure related death.

Results of transvenous extraction have been repeatedly reported as associated with a high success rate of complete (>90%) or partial (>95%) removal with a concomitant low rate of complications in experienced centers [48],[49],[50]. The use of extraction sheaths ranged from 60-80% in these studies. Nevertheless, the success rate of manual only traction alone or with the use of locking stylets is not negligible ranging form 15-30% in recent studies. More recently, de Bie et al [51] reported a substantially higher clinical success rate of ~85% in >250 removal procedures with the use of manual traction without the assistance of extraction sheaths. This finding was particularly true for leads implanted > 2.6 years. Since it is not clearly defined when an attempt should be considered unsuccessful, the efficacy of these simpler techniques seem to be largely dependent of the availability of the more complex

ones (i.e. telescopic or laser sheaths). That means that if an operator has a wide range of tools available, he will give up more easily on a resistant to traction lead, moving to more sophisticated techniques and strategies [51].

6. Removal of left ventricular pacing leads

Nowadays CRT is considered a standard therapy used to improve symptoms and prognosis in heart failure. Increasing evidence confirming the benefits of CRT has led to widespread implantation of CRT devices with technically challenging procedures, followed by frequent dislodgement of the coronary sinus (CS) lead or infections and requirement for extraction and re-implantation of the device. During the last decade, evolutionary changes have emerged in CS lead technology and techniques to optimize CRT function during implantation and permit the removal of left ventricular (LV) pacing leads with minor complications.

Coronary sinus lead implantation is a complex procedure with several limitations and hazards. According to several studies, the procedure is usually time consuming with long fluoroscopy times and the implantation success rate is reduced compared to conventional procedures (estimated between 90% to 97%) [52-56]. With the introduction of special delivery sheaths and the so-called 'over the wire technology' the breakthrough of LV pacing became reality in the early 2000s, yet lead stability remains problematic mainly due to different coronary sinus anatomies [57-58]. Because no muscular trabeculae is found in the CS for anchoring of the lead, the tip has to be pushed as distal as possible in a wedge position in a lateral or a postero-lateral CS branch and is typically non-actively fixated. Such an ideal position of the LV lead cannot be reached in several cases owing to small and tortuous venous anatomy, phrenic nerve stimulation or sub-optimal hemodynamics due to close proximity to the right ventricular lead. As a result, detectable CS lead dislodgement has been observed in about 4-8.6% of patients during follow-up, accompanied by loss of capture and need for repositioning [52,59,60]. To overcome these limitations, pre-shaped leads (curved in one or more dimensions) have been developed to offer stability even in proximal positions and in larger veins. Coronary sinus side branch stenting has also been performed in several occasions [61-62]. Finally, the development of an active fixation CS lead (Attain StarFix 4195, Medtronic) has also been achieved [63]. This lead body has a 55D polyurethane coating that expands into pleated loops near the electrode tip to increase its diameter and promote fixation (practically reaching stability of 100%), along with a small amount of steroid at the electrode tip to reduce inflammation in the surrounding tissue [64] (Figure 9).

In parallel to the rapid growing experience with the implantation of CS leads, a new and interesting field relating to LV pacing lead extraction and subsequent re-implantation has been developed. It should be noted, however, that in comparison to the extensive data available on conventional pacing and ICD lead extraction, the experience with LV leads is still limited. Similarly to conventional devices, infection seems to be the primary

indication for removal in the case of CRT devices too. On the other hand, it might be expected that removing leads from fragile and tortuous CS vein tributaries, especially with the use of larger-bore sheaths (mechanical or laser) which may not fit into the distal branches, would lend itself to a higher risk of complications. Indeed, the high rate of hemopericardium and dense scar tissue in-growth or vein occlusion in animal models [65,66] were early findings suggesting the need for extreme care in the removal of CS leads and for detailed preoperative knowledge of the CS anatomy. Nevertheless, published data so far suggest that CS leads can be safely and successfully removed percutaneously and that CS lead extraction is not more hazardous than conventional PM/ICD lead extraction (Table 3), although post-extraction complete occlusion of the branch vein previously implanted with an LV lead followed by re-implantation complications may become a particular problem occasionally [67]. It appears that CS leads implanted for <2 years are amenable to manual traction [68] and even extraction of active fixation CS leads has been reported due to prolonged manual traction alone or careful use of a laser sheath within the CS. [69],[70],[71].



Figure 9. Medtronic Attain StarFix 4195 Coronary Sinus Lead at four stages of deployment.

All the previously mentioned techniques have been successfully used for the removal of CS infected or malfunctioning leads. Tyers et al [72] reported a series of 14 left ventricular lead extractions, all successfully removed with the use of locking stylets and powered sheaths. Bongiorno et al [73] have reported one of the earlier and larger single centre experiences on extraction of LV pacing leads: manual traction using a standard stylet only was effective in the majority of cases (73%) and mechanical dilation with polypropylene sheaths was necessary (27%) when tight adherence was found along the catheter course.

In particular, adherence in CS lead extraction was located more commonly in the systemic veins (subclavian vein 60%, innominate vein 30%, superior vena cava 20%, right atrium 20%) rather than inside the CS (10%). When areas of adherence were found inside the CS (never in its branches), dissection through a transfemoral approach was chosen and no major complications were seen. Safety and efficacy of transvenous CS lead removal was also confirmed by Di Cori et al [74] in a large, single-center experience involving extraction of 147 CS pacing leads. Nearly one-third of procedures were resistant to manual traction and thus required mechanical dilation or transfemoral approach. Complications were rare, there was no predictable pattern among manual traction or mechanical dilation removal techniques and fibrous adherence sites were also found mainly in non-CS locations (subclavian vein 66%, innominate vein 48%, superior vena cava 32%, right atrium 20% and CS 14%). Most recently, Williams et al [75] confirmed their high procedural success of 10-year experience regarding percutaneous removal of CS leads. Among 71 patients they explanted 60 CS leads and 143 non-CS leads: CS extraction had 0% operative mortality - 2.8% postprocedural mortality (in hospital <30 days) - minor complication rates 5.6% and major complication rates 1.4%. The majority of CS leads were extracted using manual traction and laser sheath dissection was required in 10% (laser was used within the CS only in two cases).

In conclusion, extensive data are available on conventional pacing and ICD lead extraction but only limited experience with LV leads exists. The LV pacing leads may be removed easily by manual traction in a large number of cases, but coronary sinus (CS) adherences may complicate extraction requiring mechanical dilation or ablative extraction techniques. In addition to CS remnant adherences, post-extraction venous occlusion might complicate the eventual re-implantation. Nevertheless, CS lead extraction seems to be not more hazardous than conventional pacemaker and defibrillator lead extraction. The evolving use of CRT in current clinical practice, is expected to improve the techniques and provide us with more data regarding the feasibility and safety of LV lead removal.

Author	CS leads extracted	infection	sepsis	malfunction	time from implant (months)	manual traction	mechanical dilation	major complications	success rate
Bongiorni et al ⁷³	37	43.3%	29.7%	27%	19.5 ± 16.5	73%	27%	0%	100%
Williams et al ⁷⁵	60	31%	31%	38%	35.8	90%	10% (laser)	1.4%	98%
Di Cori et al ⁷⁴	147	56%	24%	20%	29±25	70%	30%	0.7%	99%
De Martino et al ⁷⁷	12	58%		42%	13.9±11.7	100%		0%	100%
Hamid et al ⁶⁸	32	56.2		43.8%	26.5±28.7	87.5%	12.5% (laser)	0%	100%
Tyers et al ⁷²	14				not available			7%	100%
Kasravi et al ⁷⁶	14				17.4±12.2			0%	100%

Table 3. Coronary sinus lead extraction: differences and similarities between reports

Author details

Spyridon Koulouris and Sofia Metaxa

1st Cardiology Department, Evangelismos Hospital, Athens, Greece

7. References

- [1] Bardy GH, Lee KL, Mark DB, et al. Amiodarone or implantable cardioverter-defibrillator for congestive heart failure. *N Engl J Med* 2005;352:225-237
- [2] Moss AJ, Zareba W, Hall WJ, et al. Prophylactic implantation of a defibrillator in patients with myocardial infarction and reduced ejection fraction. *N Engl J Med* 2002;346:877-883
- [3] Abraham WT, Fischer WG, Smith AL, et al. Cardiac resynchronization therapy in chronic heart failure. *N Engl J Med* 2002;346:1845-1853
- [4] Bristow MR, Saxon LA, Boehmer J, et al. Cardiac-resynchronization therapy with or without an implantable defibrillator in advanced chronic heart failure. *N Engl J Med* 2004;350:2140-2150
- [5] Tang AS, Wells GA, Talajic M, et al, the Resynchronization–Defibrillation for Ambulatory Heart Failure Trial (RAFT) Investigators. Cardiac-resynchronization therapy for mild-to-moderate heart failure. *N Engl J Med* 2010;363:2385-2399
- [6] Wilkoff BL, Love CI, Byrd BL, et al. Transvenous lead extraction: Heart Rhythm Society expert consensus on facilities, training, indications and patient management: this document was endorsed by the American Heart Association (AHA). *Heart Rhythm* 2009;6:1085-1104
- [7] Kennergren C. A European perspective on lead extraction: Part I. *Heart Rhythm* 2008;5:160-162
- [8] Madigan NP, Curtis JJ, Sanfelippo JF, et al. Difficulty of extraction of chronically implanted tined ventricular endocardial leads. *J Am Coll Cardiol* 1984;3:724-731
- [9] Farooqi FM, Talsania S, Hamid S, et al. Extraction of cardiac rhythm devices: indications, techniques and outcomes for the removal of pacemaker and defibrillator leads. *Int J Clin Pract* 2010;64:1140-1147
- [10] Robboy SJ, Harthorne JW, Leinbach RC, et al. Autopsy findings with permanent percutaneous pacemakers. *Circulation* 1969;39:495-501
- [11] Huang TY, Baba N. Cardiac pathology of transvenous pacemakers. *Am Heart J* 1971;83:469-474
- [12] Cooper JM, Stephenson EA, Berul CI, et al. Implantable cardioverter defibrillator lead complications and laser extraction in children and young adults with congenital heart disease: implications for implantation and management. *J Cardiovasc Electrophysiol* 2003;14:344-349
- [13] Smith HJ, Fearnot NE, Byrd CL, et al. Five-years experience with intravascular lead extraction. *Pacing Clin Electrophysiol* 1994;17:2016-2020

- [14] Hackler JW, Sun Z, Lindsay BD, et al. Effectiveness of implantable cardioverter-defibrillator lead coil treatments in facilitating ease of extraction. *Heart Rhythm* 2010;7:890-897
- [15] Deharo JC, Bongiorni MG, Rozkovec A, et al. Pathways for training and accreditation for transvenous lead extraction: a European Heart Rhythm Association position paper. *Europace* 2012;14:124-134
- [16] Smith HJ, Fearnot NE, Byrd CL, et al. Five-years experience with intravascular lead extraction. U.S. Lead Extraction Database. *Pacing Clin Electrophysiol* 1994;17:2016-2020
- [17] Roux JF, Page P, Dubuc M, et al. Laser lead extraction: predictors of success and complications. *Pacing Clin Electrophysiol* 2007;30:214-20
- [18] Cabell CH, Heidehreich PA, Chu VH, et al. Increasing rates of cardiac device infections among Medicare beneficiaries: 1990-1999. *Am Heart J* 2004;147:582-586
- [19] Voigt A, Shalaby A, Saha S. Rising rates of cardiac rhythm management device infection in the United States:1996 through 2003. *J Am Coll Cardiol* 2006;48:590-591
- [20] Jones SO, Eckart RE, Albert CM, Epstein L. Large, single-center, single-operator experience with transvenous lead extraction: Outcomes and changing indications. *Heart Rhythm* 2008;5:520-525
- [21] Grammes JA, Schulze CM, Al-Bataineh M, et al. Percutaneous pacemaker and implantable cardioverter-defibrillator lead extraction in 100 patients with intracardiac vegetations defined by transesophageal echocardiography. *J Am Coll Cardiol* 2010; 55:886-894
- [22] Klug D, Wallet F, Lacroix D, et al. Local symptoms at the site of pacemaker implantation indicate latent systemic infection. *Heart* 2004;90:882-886
- [23] Baddour LM, Epstein AE, Erickson CC, et al. Update on cardiovascular electronic device infections and their management: a scientific statement from the American Heart Association. *Circulation* 2010;121:458-477
- [24] Sohail MR, Uslan DZ, Khan AH, et al. Management and outcome of permanent pacemaker and implantable cardioverter-defibrillator infections. *J Am Coll Cardiol* 2007;49:1851-1859
- [25] Field M, Jones S, Epstein L. How to select patients for lead extraction. *Heart Rhythm* 2007;4:978-985
- [26] Bracke FA, Meijer A, Van Gelder B. Pacemaker lead complications: when is extraction appropriate and what can we learn from published data? *Heart* 2001;85:254-259
- [27] Hauser RG, Hayes DL, Kallinen LM, et al. Clinical experience with pacemaker pulse generators and transvenous leads: an 8-year prospective multicenter study. *Heart Rhythm* 2007;4:154-160
- [28] Kleemann T, Becker T, Doenges K, et al. Annual rate of transvenous defibrillation lead defects in implantable cardioverter- defibrillators over a period of >10 years. *Circulation* 2007;115:2474-2490
- [29] Henrickson CA, Zhang K, Brinker JA. A survey of the practice of lead extraction in the United States. *Pacing Clin Electrophysiol* 2010;33:721-726

- [30] Franceschi F, Dubuc M, Deharo JC, et al. Extraction of transvenous leads in the operating room versus electrophysiology laboratory: a comparative study. *Heart Rhythm* 2011;8:1001-1005
- [31] Hirschl DA, Jain VR, Spindola-Franco H, et al. Prevalence and characterization of asymptomatic pacemaker and ICD lead perforation on CT. *Pacing Clin Electrophysiol* 2007;30:28-32
- [32] Chiu WS, Nguyen D. Pacemaker lead extraction in pacemaker endocarditis with lead vegetation: usefulness of transesophageal echocardiography. *Can J Cardiol* 1998;14:87-9
- [33] Sohail MR, Uslan DZ, Khan AH, et al. Infective endocarditis complicating permanent pacemaker and implantable cardioverterdefibrillator infection. *Mayo Clin Proc* 2008;83:46-53
- [34] Henrikson CA, Brikner JA. How to prevent, recognize and manage complications of lead extraction. Part III: Procedural factors. *Heart Rhythm* 2008;5:1352-1354
- [35] Bilgutay AM, Jensen NK, Schmidt WR, et al., Incarceration of transvenous pacemaker electrode. Removal by traction, *Am Heart J* 1969;77:377-9
- [36] Fearnot NE, Smith HJ, Goode LB, et al. Intravascular lead extraction using locking stylets, sheaths, and other techniques. *Pacing Clin Electrophysiol* 1990;13:1864-1870
- [37] Goode LB, Byrd CL, Wilkoff BL, et al. Development of a new technique for explantation of chronic transvenous pacemaker leads: five initial case studies. *Biomed Instrum Technol* 1991;25:50-53
- [38] Gijsbers GH, van den Broecke DG, Sprangers RL, et al. Effect of force on ablation depth for a XeCl excimer laser beam delivered by an optical fiber in contact with arterial tissue under saline. *Lasers Surg Med* 1992;12:576-584
- [39] Wilkoff BL, Byrd CL, Love CJ, et al. Pacemaker lead extraction with the laser sheath: results of the pacing lead extraction with the excimer sheath (PLEXES) trial. *J Am Coll Cardiol* 1999;33:1671-1676
- [40] Byrd CL, Wilkoff BL, Love CJ, et al. Clinical study of the laser sheath for lead extraction: the total experience in the United States. *Pacing Clin Electrophysiol* 2002;25:804-808
- [41] Neuzil P, Taborsky M, Rezek Z, et al. Pacemaker and ICD lead extraction with electrosurgical dissection sheaths and standard transvenous extraction systems: results of a randomized trial. *Europace* 2007;9:98-104
- [42] Dello Russo A, Biddau R, Pelargonio G, et al. Lead extraction: a new effective tool to overcome fibrous binding sites. *J Interv Card Electrophysiol* 2009;24:147-150
- [43] Massumi RA, Ross AN. Atraumatic nonsurgical technique for removal of broken catheters from the cardiac cavities. *New Engl J Med* 1967;227:195
- [44] Belott PH. Lead extraction using the femoral vein. *Heart Rhythm* 2007;4:1102-1107
- [45] Fischer A, Love B, Hansalia R, et al. Transfemoral snaring and stabilization of pacemaker and defibrillator leads to maintain vascular access during lead extraction. *Pacing Clin Electrophysiol* 2009;32:336-339

- [46] Bongiorni MG, Soldati E, Arena G, et al. Transvenous removal of difficult pacing and ICD leads: a new technique through the internal jugular vein. *Pacing Clin Electrophysiol* 2000;23:696
- [47] Henrikson CA, Brikner JA. How to prevent, recognize and manage complications of lead extraction. Part I: Avoiding lead extraction – Infectious issues. *Heart Rhythm* 2008;5:1083-1087
- [48] Kennergren C, Bjurman C, Wiklund R, Gabel J. A single-centre experience of over one thousand lead extractions. *Europace* 2009;11:612–617
- [49] Bongiorni MG, Soldati E, Zucchelli G, et al. Transvenous removal of pacing and implantable cardiac defibrillating leads using single sheath mechanical dilatation and multiple venous approaches: high success rate and safety in more than 2000 leads. *Eur Heart J* 2008;29:2886–2893
- [50] Wazni O, Epstein LM, Carrillo RG, et al. Lead extraction in the contemporary setting: the LexIcon Study. An observational retrospective study of consecutive laser lead extractions. *J Am Coll Cardiol* 2010;55:579–586
- [51] de Bie M, Fouad D, Borleffs JW, et al. Trans-venous lead removal without the use of extraction sheaths, results of >250 removal procedures. *Europace* 2012; 14: 112–116
- [52] Abraham WT, Fisher WG, Smith AL et al for the MIRACLE Study Group. Cardiac resynchronization in chronic heart failure. *N Engl J Med* 2002; 346: 1845-1853.
- [53] Bristow MR, Saxon LA, Boehmer J et al. Comparison of Medical Therapy, Pacing and Defibrillation in Heart Failure (COMPANION) Investigators. Cardiac resynchronization therapy with or without an implantable defibrillator in advanced chronic heart failure. *N Engl J Med* 2004; 350: 2140-2150.
- [54] Cazeau S, Leclercq C, Lavergne T et al. Multisite Stimulation In Cardiomyopathies (MUSTIC) Study Investigators. Effects of multisite biventricular pacing in patients with heart failure and intraventricular conduction delay. *N Engl J Med* 2001; 344: 873-880.
- [55] Cleland JG, Daubert JC, Erdmann E et al. Cardiac Resynchronization – Heart Failure (CARE-HF) Study Investigators. The effect of cardiac resynchronization on morbidity and mortality in heart failure. *N Engl J Med* 2005; 352: 1539-1549.
- [56] Azizi M, Castel MA, Behrens S, et al. Experience with coronary sinus lead implantations for cardiac resynchronization therapy in 244 patients. *Herzschr Elektrophys* 2006; 17: 13-18.
- [57] Purerfellner H, Nesser HJ, Winter S, et al. EASYTRAK Clinical Investigation Study Group; European EASYTRAK Registry. Transvenous left ventricular lead implantation with the EASYTRAK lead system: the European experience. *Am J Cardiol* 2000; 86: 157K-164K.
- [58] Sack S, Heinzel F, Dagues N et al. Stimulation of the left ventricle through the coronary sinus with a newly developed ‘over the wire’ lead system – early experiences with lead handling and positioning. *Europace* 2001; 3: 317-323.
- [59] Leon AR, Abraham WT, Curtis AB et al. MIRACLE Study Program. Safety of transvenous cardiac resynchronization system implantation in patients with chronic

- heart failure: combined results over 2000 patients from a multicenter study program. *J Am Coll Cardiol* 2005; 46: 2348-2356.
- [60] Bulava A, Lukl J. Single-centre experience with coronary sinus lead stability and long-term pacing parameters. *Europace* 2007; 9: 523-527.
- [61] Szilagyi S, Merkely B, Zima E et al. Minimal invasive coronary sinus lead reposition technique for the treatment of phrenic nerve stimulation. *Europace* 2008; 10: 1157-1160.
- [62] Szilagyi S, Merkely B, Roka A et al. Stabilization of the coronary sinus electrode position with coronary stent implantation to prevent and treat dislocation. *J Cardiovasc Electrophysiol* 2007; 18: 303-307.
- [63] Nagele H, Azizi M, Hashagen S, et al. First experience with a new active fixation coronary sinus lead. *Europace* 2007; 9: 437-441.
- [64] Baranowski B, Yerkey M, Dresing T, et al. Fibrotic tissue growth into the extendable lobes of an active fixation coronary sinus lead can complicate extraction. *PACE* 2011; 34: e64-e65.
- [65] Tacker WA, Vanvleet JF, Shoenlein WE, et al. Post mortem changes after lead extraction from the ovine coronary sinus and great cardiac vein. *PACE* 1998; 21: 296-298.
- [66] Wilkoff BL, Belott P, Scheiner A, et al. Extractibility of coronary sinus defibrillation leads improves with ePTFE and medical adhesive coatings. *PACE* 2001; 24: 560
- [67] Burke MC, Morton J, Lin AC, et al. Implications and outcome of permanent coronary sinus lead extraction and reimplantation. *J Cardiovasc Electrophysiol* 2005; 16: 830-837.
- [68] Hamid S, Arujna A, Khan S et al. Extraction of chronic pacemaker and defibrillator leads from the coronary sinus: laser infrequently used but required. *Europace* 2009; 11: 213-215.
- [69] Baranowski B, Yerkey M, Dresing T, et al. Fibrotic tissue growth into the extendable lobes of an active fixation coronary sinus lead can complicate extraction. *Pacing Clin Electrophysiol* 2011; 34: e64-e65.
- [70] Hamid S, Arujuna A, Rinaldi CA. A shocking lead in the coronary sinus. *Europace* 2009; 11: 833-834.
- [71] Curnis A, Bontempi L, Coppola G et al. Active-fixation coronary sinus pacing lead extraction: a hybrid approach. *Int J Cardiol* 2011; Sep 8 {Epub ahead of print}
- [72] Tyers GF, Clark J, Wang Y, Mills P, Bashir J. Coronary sinus lead extraction. *Pacing Clin Electrophysiol* 2003; 26: 524-526.
- [73] Bongiorni MG, Zucchelli G, Soldati E et al. Usefulness of mechanical transvenous dilation and location of areas of adherence in patients undergoing coronary sinus lead extraction. *Europace* 2007; 9: 69-73.
- [74] Di Cori A, Bongiorni MG, Zucchelli G et al. Large, single-center experience in transvenous coronary sinus lead extraction: procedural outcomes and predictors for mechanical dilatation. *Pacing Clin Electrophysiol* 2012; 35: 215-222.
- [75] Williams SE, Arujuna A, Whitaker J et al. Percutaneous lead and system extraction in patients with cardiac resynchronization therapy (CRT) devices and coronary sinus leads. *Pacing Clin Electrophysiol* 2011; 34: 1209-1216.

- [76] Kasravi B, Tobias S, Barnes MJ, et al. Coronary sinus lead extraction in the era of cardiac resynchronization therapy: single center experience. *Pacing Clin Electrophysiol* 2005; 28: 51-53.
- [77] De Martino G, Orazi S, Bisignani G et al. Safety and feasibility of coronary sinus left ventricular leads extraction: a preliminary report. *J Interv Card Electrophysiol* 2005; 13: 35-38.

IntechOpen

IntechOpen