

We are IntechOpen, the world's leading publisher of Open Access books Built by scientists, for scientists

4,800

Open access books available

122,000

International authors and editors

135M

Downloads

Our authors are among the

154

Countries delivered to

TOP 1%

most cited scientists

12.2%

Contributors from top 500 universities



WEB OF SCIENCE™

Selection of our books indexed in the Book Citation Index
in Web of Science™ Core Collection (BKCI)

Interested in publishing with us?
Contact book.department@intechopen.com

Numbers displayed above are based on latest data collected.

For more information visit www.intechopen.com



Immunohistochemistry of Neuronal Apoptosis in Fatal Traumas: The Contribution of Forensic Molecular Pathology in Medical Science

Qi Wang, Tomomi Michiue and Hitoshi Maeda

Additional information is available at the end of the chapter

<http://dx.doi.org/10.5772/50225>

1. Introduction

The most important part of forensic pathology is investigation of the cause and process of death, especially in violent and unexpected sudden deaths, which involve social and medicolegal issues of ultimate, personal and public concern. Forensic pathologists are expected to respond to social requests by reliable interpretation of these issues in routine casework on the basis of research activities to develop, improve and sophisticate the procedures as well as to establish an autopsy database within the framework of social and legal systems. Systematic investigations are needed for comprehensive assessment of pathological findings, making full use of the available procedures; while classical morphology remains a core procedure to investigate deaths in forensic pathology, a spectrum of ancillary procedures has been developed and incorporated to detail the pathology. In addition to postmortem biochemistry, experimental and practical investigations using molecular biological procedures in the context of forensic pathology (molecular forensic pathology) have suggested the usefulness of detecting dynamic functional changes involved in the dying process that cannot be detected by morphology (pathophysiological vital reactions) (Maeda et al., 2010; Maeda et al., 2011). These procedures may effectively be included in routine casework as part of forensic laboratory investigations (forensic molecular pathology). The purpose of forensic molecular pathology is to provide a general explanation of the process or pathophysiology of human death caused by insults involving forensic issues as well as the assessment of individual deaths on the basis of biological molecular evidence; in forensic investigation of death, the genetic background, dynamics of gene expression (up-/down-regulation), and vital phenomena, involving biological mediators and degenerative products, are detected by DNA analysis, relative quantification of mRNA transcripts using real-time reverse transcription-PCR (RT-

PCR), and immunohisto-/immunocytochemistry combined with biochemistry, respectively. These observations will also contribute to understanding life-threatening events after traumas in the clinical management of critical patients.

In forensic and clinical medicine, head injury is a major trauma, and primary or secondary brain damage, e.g. due to ischemic, hypoxic and toxic insults, is involved in most fatal traumas and diseases; thus, the investigation of brain damage after such insults is essential to assess the etiology and evaluate the severity of brain impairment relevant to central nervous system (CNS) dysfunction (Oehmichen et al., 2006). Necrosis and apoptosis are involved in morphological deterioration of the brain, involving cell and tissue decay (Fawthrop et al., 1991). Neuronal apoptosis is involved in both early and delayed responses after insults; however, this type of neuronal degeneration and cell death is of greater importance in connection with delayed or intermittent CNS dysfunction (Martin et al., 1998). This chapter reviews neuronal apoptosis and related pathologies in the brain after fatal traumas and diseases as demonstrated in forensic autopsy casework, summarizing previous observations (Michiue et al., 2008; Wang et al., 2011a; Wang et al., 2012a; Wang et al., 2012b).

2. Brain neuronal apoptosis in human death

Apoptosis is programmed cell death, regulated by specific 'death genes.' The process involves active protein synthesis, initiated by changes in the microenvironment and impaired metabolic and tropic supply (Alison & Sarraf, 1992), with the participation of immediate early gene transcription factors (e.g. c-jun, jun-B, jun-D, c-fos, AP-1, ATF and nuclear factor (NF)- κ B), proteases (e.g. calpains and caspases), and glutamate-mediate toxicity, including free radicals, protein kinases, Ca²⁺ homeostasis, and second messenger systems (Vaux & Strasser, 1996). It is known that microglial cells have an anti-apoptotic function to protect neurons from apoptotic death (Polazzi et al., 2001). Mechanical brain injury is accompanied by the apoptosis of neurons and glial cells surrounding the site of contusion and hemorrhage, which undergoes cell degeneration and necrosis (Oehmichen et al., 2006). Apoptosis begins hours after a traumatic event, and remains demonstrable for about 3 days (Yakovlev & Faden, 2001). These survival time-dependent changes are useful for timing brain contusions and hemorrhages in forensic pathology (Hausmann et al., 2004); however, apoptosis has been detected in the white matter as long as 1 year after injury (Williams et al., 2001). Apoptosis is also induced by other insults, including cerebral ischemia and hypoxia/asphyxia (Rosenblum, 1997), carbon monoxide (CO) intoxication (Piantadosi et al., 1997) and drug toxicity (Cadet & Krasnova, 2009). It is of particular importance that apoptosis may be involved in delayed neuronal loss (Becker & Bonni, 2004), which may contribute to delayed death or posttraumatic neurological disorders and sequelae.

Neuronal apoptosis is usually detected by *in situ* labeling of DNA fragments, e.g. terminal deoxynucleotidyl-transferase-mediated dUDP nick end-labeling (TUNEL) or *in situ* nick translation (ISNT) (Clark et al., 2001; Gavrieli et al., 1992; Rink et al., 1995). However, experimental studies have shown that single-stranded DNA (ssDNA) degradation precedes

DNA double-strand breaks (DNAds_b) during a delayed neuronal death process caused by reperfusion after transient brain ischemia or intracerebral hemorrhage, possibly due to oxidative stress (Chen et al., 1997; Gong et al., 2001; Love, 1999; Nakamura et al., 2005). Thus, ssDNA can be used as an earlier marker of apoptosis and programmed cell death, which causes neuronal loss (Chen et al., 1997; Frankfurt et al., 1996; Michiue, 2008). This marker may contribute to the investigation of neuronal damage in acute death and also the timing of brain injury in the early phase (Chen et al., 1997; Hausmann et al., 2004).

Animal experimentation has shown that ssDNA positivity could be detected after as little as 1 min of reperfusion following transient brain ischemia, showing a progressive increase, and exclusively in neurons exhibiting normal nuclear morphology within the first hour of reperfusion before the appearance of DNAds_b, whereas DNAds_b was first detected after 1 h of reperfusion. Thereafter, at 16–72 h of reperfusion, both ssDNA and DNAds_b positivity were found in many neurons and astrocytes, showing morphological changes consistent with apoptosis (Chen et al., 1997). Alternatively, ssDNA-positive neurons may be decreased after several hours of reperfusion, possibly due to active DNA repair. These findings suggest that damage to nuclear DNA is an early event after neuronal ischemia and that the accumulation of unrepaired DNA single-strand breaks due to oxidative stress may contribute to delayed ischemic neuronal death by triggering apoptosis. Other experimental studies have suggested that oxidative stress contributes to DNA damage and brain injury after intracerebral hemorrhage (Gong et al., 2001; Nakamura et al., 2005). These observations indicate that neuronal ssDNA positivity can be a marker of early brain damage, possibly within the first hour after an insult involving oxidative stress, including reperfusion and hemorrhage (Michiue et al., 2008). The detection of neuronal ssDNA may depend on the cause of death and survival time after a fatal insult. Brain reperfusion during cardiopulmonary resuscitation (CPR) may also contribute to positivity.

Astrocytes are essential for the structural integrity of neurons and also for maintaining their physiological environment, involving electrolyte and water homeostasis, pH and osmotic regulation, and elimination of transmitter amino acids and plasma proteins, as well as the control of vascular tone and intercellular transport of molecules from the vessel to the neuron, supporting the blood-brain barrier (BBB) (Nag, 2011). In forensic neuropathology, glial fibrillary acidic protein (GFAP) and S100 β , as specific markers of differentiated astrocytes in the brain, are used to detect their morphological and functional alterations involved in brain damage (Liedtke et al., 1996; Stroick et al., 2006). GFAP is normally detected in fibrous astrocytes in the white matter and molecular layer of the cerebral cortex, but is usually not detectable in protoplasmic astrocytes in the cerebral cortex by a routine immunohistochemical procedure (Li et al., 2009b; Oehmichen et al., 2006). GFAP is essential for fibrous astrocyte functions, including maintenance of the integrity of CNS white matter and the blood-brain barrier (Liedtke et al., 1996), and can therefore be used to detect the morphological and functional alterations of astrocytes due to brain damage; the decrease of white matter GFAP immunopositivity indicates the disruption of astrocytes, while reactive astrogliosis involves an increase in the gray matter (Wang et al., 2011a; Wang et al., 2012a). S100 β is a calcium-binding peptide and is used as a clinical parameter of glial activation

and/or death in a spectrum of CNS disorders (Stroick et al., 2006); S100 β levels in serum and cerebrospinal fluid (CSF) can be used as a marker of brain damage in clinical and postmortem investigations (Korfias et al., 2006; Li et al., 2006a; Li et al., 2009a). Basic fibroblast growth factor (bFGF) is closely involved in neuronal protection and repair after ischemic, metabolic or traumatic brain injury, and has emerged as a central player in acute brain damage (Bikfalvi et al., 1997); the increase of glial bFGF positivity indicates a self-protective response (Wang et al., 2011a; Wang et al., 2012a; Wang et al., 2012b). Thus, bFGF can be used to monitor the self-protective capacity of the brain after injury.

Previous studies of neuronal apoptosis in forensic pathology have mostly focused on the healing process at the site of brain injury for wound timing in the forensic context (Hausmann et al., 2004; Tao et al., 2006); however, it is of great forensic and clinical importance to investigate overall brain damage to evaluate the severity of insults. Immunohistochemistry of neuronal apoptosis and related molecular pathology using biological markers, including ssDNA, bFGF, GFAP and S100 β , demonstrated various type of brain damage due to head injury, ischemia/hypoxia or asphyxia, intoxication, burns, and extreme ambient temperatures (hyperthermia and hypothermia) (Wang et al., 2011a; Wang et al., 2012a; Wang et al., 2012b). Details are described below.

3. Brain injury

3.1. General considerations

Mechanical brain injury is a major trauma in both forensic and clinical medicine and is caused by various insults, resulting in various types of brain damage, often accompanied by secondary brain dysfunction, involving brain edema, swelling and compression; these are subdivided into focal and diffuse brain injury (Greenfield & Ellison, 2008; Knight & Saukko, 2004; Oehmichen et al., 2006). Classic concepts of CNS dysfunction due to mechanical brain injury comprise the disruption of brain structures by laceration and contusion, subarachnoid hemorrhage (SAH), compression by space-occupying intracranial hematoma or increased intracranial pressure due to edema, axonal injury, ischemic brain damage and primary acute brain swelling, especially in infancy. Brain compression or swelling accompanied by increased intracranial pressure is critical for survival in the early phase after brain injury in most cases. Previous studies have made great strides in investigating the morphology and causal mechanism of brain injury and dysfunction; forensic neuropathological case studies have demonstrated findings useful for establishing practical investigation procedures. Estimation of the age of brain injury and hematomas at the site or in the area adjacent to the injury has especially important criminological implications (Bratzke, 2004; Dressler et al., 2007; Hausmann & Betz, 2001; Hausmann et al., 1999; Hausmann et al., 2000; Oehmichen et al., 2003; Takamiya et al., 2007); however, some patients may survive for months or years after severe brain injury, while it may be difficult to explain the causal relationship between a focal brain injury and death in some fatalities. Cerebral edema/swelling alone may be a distinct finding of brain injury at autopsy, with mild or even no other structural lesions, to explain the cause of death, involving increased intracranial pressure affecting vital centers in

the brainstem. Animal experiments have demonstrated the rapid onset of brain edema following injury (Byard et al., 2009). Considering the anatomical and metabolic species differences, however, it is necessary to investigate human materials. Moreover, human brain injury is rarely as simple as in experimental models; thus, the changes to the whole human brain after injury should be clarified to establish the relationship to death. Brain damage to a part distant from primary lesions may provide more significant information about the whole brain condition. In particular, the evaluation of human brain damage with regard to parahippocampal herniation or secondary brainstem hemorrhage of Duret as a macroscopic sign of brain swelling and compression is important since they are believed to be closely related to a fatal outcome, causing brainstem dysfunction.

Immunohistochemical investigation of the expressions of bFGF and GFAP in glial cells as well as ssDNA positivity in the neurons as a sign of neuronal apoptosis at sites distant from the primary injury to detect survival time-dependent changes in forensic autopsy cases of fatal mechanical brain injury demonstrated characteristic posttraumatic glial and neuronal changes in regions that were not involved in the primary injury, with regard to the influence of brain swelling and compression (Fig. 1 and Table 1). These changes involved early glial changes in peracute to subacute death with survival time within 12 h and neuronal loss in prolonged death after 3 days, which depended on brain swelling and compression, irrespective of the type of primary brain injury, as follows.

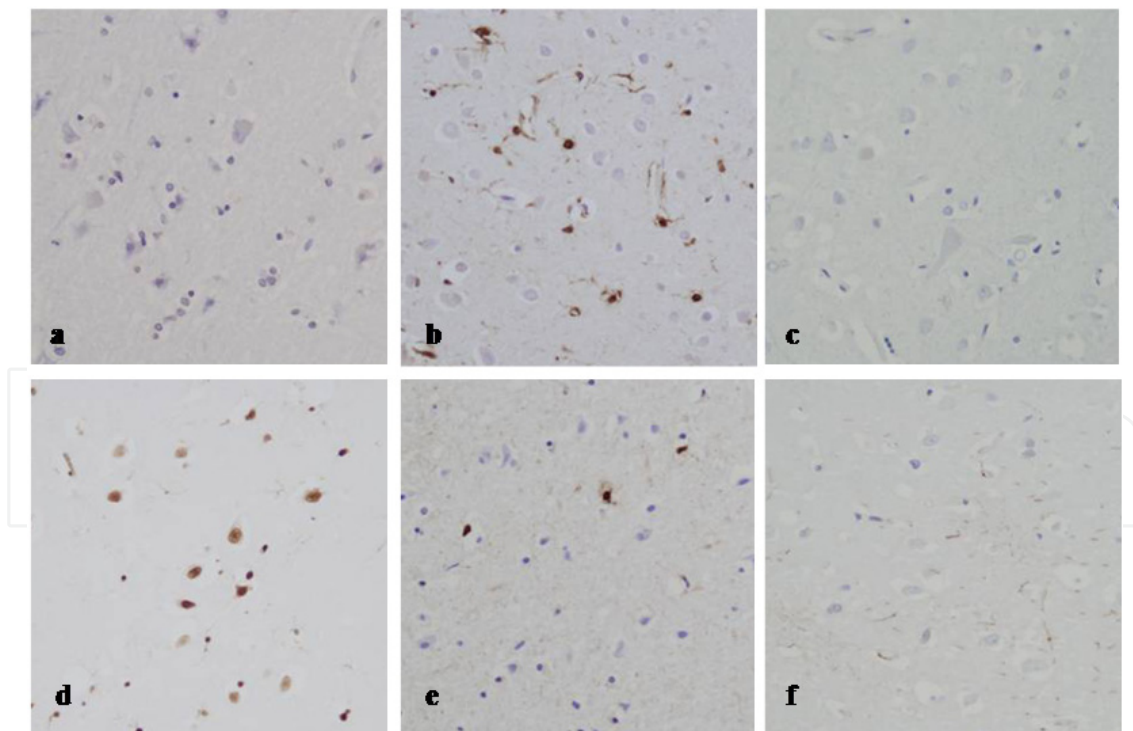


Figure 1. Immunohistochemistry of single-stranded DNA (ssDNA), basic fibroblast growth factor (bFGF) and glial fibrillary acidic protein (GFAP) in the parietal cortex of mechanical brain injury cases: 1) early death without Duret hemorrhage (2-day survival), showing low ssDNA (a) and high bFGF (b) positivity with unaffected GFAP positivity (c); 2) prolonged death with Duret hemorrhage (9 days survival), showing high ssDNA (d), and low bFGF (e) and GFAP (f) positivity

Macropathology	Peracute death ST, minutes	Acute death ST <0.5 h	Subacute death ST, 0.5–12 h	Early death ST, 12 h–3 days	Prolonged death ST >3 days
Open skull fractures with brain lacerations	Decreased white matter astrocyte GFAP positivity				
Brain contusions/SAH/SDH without brain swelling or compression sign		Decreased white matter astrocyte GFAP positivity	→-----→-----→	Increased cortical and white matter bFGF positivity with hippocampal involvement	→-----→----- + partial cortical neuronal loss
Brain contusions/SAH/SDH with brain swelling and compression sign without craniotomy		Increased cortical astrocyte bFGF positivity	Increased cortical and white matter astrocyte bFGF positivity	→-----→-----→ + hippocampal involvement and partly low GFAP positivity	Diffuse astrocyte loss with decreased GFAP positivity and neuronal loss with increased ssDNA positivity
Brain contusions/SAH/SDH with brain swelling and compression sign with craniotomy				Cortical and white matter astrocyte loss with decreased GFAP positivity and neuronal loss with increased ssDNA positivity	

ST, survival time; SAH, subarachnoid hemorrhage; SDH, subdural hemorrhage or hematoma; ssDNA, single-stranded DNA, bFGF, basic fibroblast growth factor; GFAP, glial fibrillary acidic protein

Table 1. Immunohistochemical findings of apoptosis-related biomarkers in mechanical brain injury with regard to the survival time

3.2. Diffuse brain injury

Diffuse mechanical brain injury clinically involves primary and secondary CNS dysfunction, which may result in permanent disability or fatal outcome. This type of mechanical brain injury is morphologically associated with specific white matter injury, usually termed diffuse axonal injury (DAI); however, other non-specific factors, including disrupted BBB, ischemia and vascular injury, also contribute to posttraumatic CNS dysfunction (Oehmichen et al., 2006). The macro pathology may present with brain swelling and hemorrhages in the deep part of white matter, for which histology often involves focal edema and demyelination, accompanied by axonal injury, along the junction of gray and white matter, but these findings cannot be detected in very short survival cases. In such cases of peracute or instantaneous death within minutes, involving severe open head injury and apparently fatal structural brain damage, immunohistochemistry detected decreased glial GFAP positivity in the parietal white matter without glial or neuronal loss; however, this finding was not evident in the cerebral cortex (Wang et al., 2012b). GFAP as a marker of fibrous astrocytes in the white matter and molecular layer of the cerebral cortex is usually not detectable in protoplasmic astrocytes or neurons in the cerebral cortex by routine immunohistochemistry (Li et al., 2009b). An increase in GFAP immunoreactivity in the cerebral cortex may be detected in classic astrocytic activation or astrogliosis; however, GFAP immunopositivity in the cerebral cortex showed no difference among all mechanical brain injury and control groups, irrespective of survival times, indicating a morphologically intact cerebral cortex. In peracute death, however, a significant decrease of white matter GFAP immunopositivity indicated the immediate, diffuse disruption of brain white matter; such findings were not detected in the hippocampus. Similar findings were detected in acute and subacute deaths (survival time <12 h) due to closed head injury without parahippocampal hernia as a brain compression sign, irrespective of the type of brain injury. This glial change in the parietal white matter may represent damage to the whole brain white matter immediately due to mechanical brain injury, suggesting fatal CNS dysfunction without brain swelling (Graham et al., 1988).

3.3. Brain swelling and compression

Brain swelling and compression, which cause brainstem dysfunction, are critically life-threatening events in clinical trauma care. In patients with a brain compression sign, accompanied by increased brain weight, glial bFGF positivity in the parietal cerebral cortex was increased in acute death (survival time <0.5 h), followed by an increase of glial bFGF positivity in the parietal white matter in subacute death (survival time of 6–8 h). Such a finding was not detected in the hippocampus in acute–subacute deaths. The bFGF has been well documented as a neuroprotective and neurotrophic factor, both *in vitro* and *in vivo* (Bikfalvi et al., 1997; Dietrich et al., 1996; Louis et al., 1993); thus, the increase of glial bFGF positivity in these cases suggests a self-protective response to maintain BBB function in the early phase of brain swelling after trauma (Deguchi et al., 2002), which may start in the cerebral cortex and spread into the white matter, despite the fatal brain compression, as

suggested by parahippocampal herniation. However, in some cases of acute death with or without the brain compression sign, the above-mentioned findings were not detected, suggesting other mechanisms of acute death, including rapid cardiorespiratory failure induced by SAH around the brainstem (Macmillan et al., 2002).

In early and prolonged death cases (survival time >12 h), parahippocampal hernia may not be identified because of brain softening (encephalomalacia) around the hippocampus, but Duret hemorrhage in the brainstem as a sign of advanced descending transtentorial herniation can be used as an indicator of fatally severe high intracranial pressure (Graham et al., 1987; Parizel et al., 2002). In early deaths (survival time of 12 h–3 days), cases without Duret hemorrhage, irrespective of craniotomy, as well as those with Duret hemorrhage without decompressive craniotomy had increased glial bFGF positivity in the parietal cortex and white matter as well as the hippocampus, without significant glial loss; however, GFAP positivity in parietal white matter began to decrease in cases with the sign of brain compression (Fig. 1) (Wang et al., 2012b). The up-regulation of bFGF in these cases may reflect the self-protective responses of the brain after brain injury. Furthermore, the bFGF may be involved in the anti-apoptosis pathways; exogenous application of bFGF could prevent apoptosis (Ay et al., 2001; Tamatani et al., 1998). In these early death cases, mostly involving subdural hemorrhage/hematoma (SDH), high glial bFGF positivity accompanied by low neuronal ssDNA expression is consistent with the function of endogenous bFGF as an anti-apoptosis factor in traumatized brains (Wang et al., 2011a); self-protective activity in the cerebrum is maintained despite a fatal outcome, even in patients with Duret hemorrhage as a sign of fatal brainstem compression. In patients without such a brain compression sign, death may be attributed to overall brain damage without brain swelling, accompanied by SDH (Graham et al., 1988).

Early deaths with Duret hemorrhage and decompressive craniectomy (survival time of 12–60 h), often involving massive contusions, presented quite different findings, involving glial and neuronal losses in the parietal cortex and/or hippocampus, accompanied by decreased glial GFAP positivity in the parietal white matter and hippocampus, with overall low glial bFGF positivity and high neuronal ssDNA positivity (Fig. 1) (Wang et al., 2012b). These findings suggest that the brain failed to generate sufficient bFGF to prevent apoptosis as a consequence of serious brain damage involving uncontrollable progressive brain edema and swelling, which developed fatal brainstem compression and Duret hemorrhage.

In prolonged deaths (survival time >3 days), patients without Duret hemorrhage as a brain compression sign, irrespective of craniotomy, had increased glial bFGF positivity in the parietal cortex and white matter as well as the hippocampus without glial loss; however, neuronal loss without a significant increase of neuronal ssDNA positivity was detected in the parietal cortex, showing no neuronal loss in the hippocampus. This suggests gradual cortical neurodegeneration after trauma despite anti-apoptotic neuroprotective activity, as indicated by increased glial bFGF positivity, and different mechanisms of cell death involved in mechanical brain injury besides apoptosis (Castejon & Arismendi, 2006; Stoica & Faden, 2010). The fatal complication of secondary pneumonia was more frequent in these cases than in deaths with Duret hemorrhage; secondary complications may play an

important role in patients without a brain compression sign. Prolonged deaths with Duret hemorrhage, however, showed advanced glial and neuronal losses in the parietal cortex and hippocampus, accompanied by decreased GFAP positivity in the parietal white matter and hippocampus, overall low glial bFGF positivity, and high neuronal ssDNA positivity in the parietal cortex and hippocampus, which were more evident than in the early deaths with Duret hemorrhage and decompressive craniectomy described above. These findings suggested fatal CNS dysfunction due to posttraumatic progressive deterioration of whole brain involving the hippocampus, lacking glial bFGF and GFAP activation for neuroprotection and repair, as a consequence of unimproved brain swelling.

Of note, there were significantly different findings depending on the survival time in cases of brain compression, as mentioned above. Acute and subacute death cases (survival time <12 h) as well as early death cases without decompressive craniectomy had higher glial bFGF and GFAP, and lower neuronal ssDNA positivity without glial and neuronal losses, whereas glial and neuronal losses, accompanied by lower glial bFGF and GFAP, and higher neuronal ssDNA positivity, were evident in early death despite decompressive craniectomy and prolonged death, suggesting different pathologies and mechanisms of brain edema/swelling, depending on the time after brain injury (Wang et al., 2012b). In a classic concept, brain edema is divided into two types based on its pathogenesis (Klatzo, 1994; Unterberg et al., 2004): a) 'vasogenic (extracellular)' edema due to BBB disruption, resulting in extracellular water accumulation, and b) 'cytotoxic (intracellular)' edema due to sustained intracellular water collection. However, brain edema after mechanical brain injury is considered to be a mixed form; vasogenic edema may be predominant in the acute phase, followed by prolonged cytotoxic edema (Barzo et al., 1997). In acute and subacute phases, the mechanical/physical impact on the brain may injure blood vessels with subsequent disruption of endothelial membranes (Hellal et al., 2004) and minor damage to astrocytes, leading to BBB opening. Thereafter, in longer survival cases, increased intracranial pressure may be involved with diffuse cytotoxic brain edema (Marmarou et al., 2000; Unterberg et al., 2004), in which glial swelling is a major mediator (Kimelberg, 1995). The activation of glial bFGF in acute and subacute death cases and decreased glial GFAP positivity in longer survival cases with brain swelling suggest a self-protective response to maintain BBB function in the early phase after mechanical brain injury and the structural damage of astrocytes caused by cytotoxic edema, respectively. Furthermore, astrocyte damage can in turn deteriorate the extracellular microenvironment (e.g. persistent increase of extracellular glutamate levels), which causes both glial and neuronal damage (Barbeito et al., 2004; Matute et al., 2006).

To summarize, characteristic immunohistochemical findings were detected with regard to the influence of cerebral compression and survival time in mechanical brain injury (Table 1) (Wang et al., 2012b). Peracute deaths with severe open head injury without brain swelling presented with glial injury in the parietal white matter. Other fatalities without a brain compression sign did not show a significant loss of glial cells; however, glial injury in the parietal white matter was seen during a survival time of <12 h, while glial responses involving bFGF positivity were detected overall after 12 h–3-day survival, and delayed neuronal loss

without an increase of neuronal ssDNA positivity was seen after 3 days at the time of death, mostly due to complications. Fatalities with signs of brain swelling and compression showed gradual losses of glial cells and neurons with an early increase of glial bFGF positivity in the parietal cerebral cortex, which was followed by an increase of glial bFGF positivity in the parietal white matter and hippocampus, and final decreases of glial bFGF and GFAP positivity with increased neuronal ssDNA positivity in the parietal lobe and hippocampus, suggesting the involvement of neuronal apoptosis in progressive brain damage after injury. Such findings were detected earlier in death despite decompression craniotomy. These observations suggested different mechanisms of whole brain damage in the death process, depending on the severity of brain compression. ssDNA, bFGF and GFAP immunohistochemistry is useful to investigate such different death processes after brain injury with regard to the survival time. These findings may also contribute to wound timing when the pathology of the primary injury involving brain contusion and hematoma is considered.

4. Cerebral ischemia and hypoxia/asphyxia

4.1. General considerations

Ischemia implies a local loss of blood supply due to arterial occlusion/disruption or vasoconstriction, or as part of systemic circulatory insufficiency or blood loss, resulting in a lack of oxygen (ischemic hypoxia), while other causes are also involved in hypoxia (oxygen deficiency), for which ischemic hypoxia is the simplest model (Table 2). Brain ischemia and hypoxia are common consequences of trauma or disease involving severe cardiac and peripheral vascular injury; the brain is more susceptible to ischemia/hypoxia than other viscera. Asphyxia in the forensic context implies systemic hypoxia associated with carbon dioxide retention due to a mechanical insult, causing acidosis, which aggravates tissue damage involving the brain; however, a lack of atmospheric oxygen (suffocation) is also included. Susceptibility of neurons in the brain to oxygen deficiency depends on the vasculature and the vulnerability of individual neurons; ischemic hypoxia first affects the watershed/arterial border zone of the frontal gyri, the globus pallidus, the Ammon horn (hippocampus), and the cerebral cortex (Oehmichen et al., 2006). These site-dependent susceptibilities of the brain to ischemia/hypoxia present with various pathologies of neurons and glial cells following cardiac arrest and asphyxia, depending on the survival time.

4.2. Cerebral ischemia

It is known that transient cerebral ischemia induces neuronal apoptosis (Chan, 2004); however, the usual feature of global ischemia involves neuronal necrosis in the cerebral cortex (watershed/arterial border zone of the frontal gyri), the globus pallidus, the hippocampus and the cerebellar Purkinje cells. Immunohistochemistry detected no evident changes of the brain in sudden death due to acute heart attack (simple cerebral ischemia); however, prolonged deaths under intensive medical care, possibly involving reperfusion,

showed higher parietal glial bFGF positivity and neuronal loss with low ssDNA positivity, indicating incomplete necrosis or selective neuronal necrosis without positive evidence of apoptosis (Table 3) (Wang et al., 2011a).

I Hypoxia:	<ol style="list-style-type: none"> 1. Ischemic hypoxia – diminished blood supply 2. Hypoxic hypoxia – reduced blood oxygenation in the lung 3. Others: e.g. anemic, stagnant, oxygen affinity and histotoxic hypoxia
II Asphyxia:	<ol style="list-style-type: none"> 1. Neck compression – hanging and ligature/manual strangulation 2. Smothering – obstruction of the airway orifices (nose and mouth) 3. Choking – foreign body in the airway 4. Suffocation – lack of atmospheric oxygen

Table 2. Major causes of hypoxia and asphyxia in the forensic context

4.3. Cerebral hypoxia – Asphyxia

The classification of asphyxia in the forensic context is not uniform (Byard, 2011; Sauvageau & Boghossian, 2010). From a practical point of view, however, the causes of mechanical asphyxia can grossly be divided into types with and without neck compression; the former (strangulation) involves lethal factors including brain ischemia/congestion due to closure of the blood vessels and/or air passages of the neck, whereas the latter (choking and smothering) causes hypoxia due to obstruction of the air passages. In addition, neurogenic cardiac suppression may be involved in both types (Oehmichen et al., 2006). The diagnosis of mechanical asphyxia as a cause of death is one of the most difficult tasks in forensic pathology, especially in cases lacking significant pathological evidence, even when ‘classic signs of asphyxia’ are apparent; for example, a very careful examination is needed to discriminate between smothering and sudden cardiac attack in cases without bruises or abrasions around the nose and mouth. The diagnosis of choking may also be obstructed when a foreign body has been removed in resuscitation measures. Furthermore, it is difficult to determine whether a food bolus in the air passages was the cause of death or a result of agonal or postmortem spillage; therefore, various procedures have been developed to detect and explain the pathophysiology of asphyxial death (Ishida et al., 2002; Zhu et al., 2000). In prolonged death cases, however, it is difficult to differentiate asphyxia from heart attack. With respect to this, immunohistochemistry of the brain detected no specific findings in acute asphyxial death, compared with sudden cardiac death; however, prolonged asphyxial death showed lower parietal glial GFAP positivity and neuronal loss with increased ssDNA positivity as a sign of apoptosis following advanced brain hypoxia, which was usually not detected in cardiac death (Table 3) (Wang et al., 2011a).

Traumatic insult	Acute/subacute death	Prolonged death
Asphyxia	Poor glial and neuronal changes in acute death	Low parietal glial bFGF positivity and neuronal loss with high ssDNA positivity
Fire fatality Burns	High parietal neuronal ssDNA Positivity	Parietal neuronal loss and increased glial cells with increased cortical and white matter bFGF positivity, and higher cortical GFAP and lower white matter GFAP positivity; overall low neuronal ssDNA positivity
CO intoxication	High parietal neuronal ssDNA Positivity	Parietal neuronal loss without glial activation; overall low glial bFGF and GFAP positivities; high neuronal ssDNA positivity
CO intoxication	High neuronal ssDNA positivity in the pallidum	
Drug abuse	High neuronal ssDNA positivity in the cerebral cortex, pallidum and midbrain substantia nigra	
Hypothermia (cold exposure)	Increased glial bFGF positivity in the cerebral cortex and white matter, and high S100 β positivity in the cerebral cortex	
Hyperthermia (heatstroke)	Low glial GFAP and S100 β positivities in the white matter, and high neuronal ssDNA positivity in the cerebral cortex and hippocampus, with high glial bFGF and S100 β positivities in the cerebral cortex	
Cardiac attack	Poor glial and neuronal changes in acute death	Increased parietal glial bFGF positivity and neuronal loss with low ssDNA positivity

CO, carbon monoxide; ssDNA, single-stranded DNA, bFGF, basic fibroblast growth factor; GFAP, glial fibrillary acidic protein

Table 3. Immunohistochemical findings of apoptosis-related biomarkers in non-injury traumas with regard to the survival time

5. Intoxication

5.1. General considerations

Numerous chemical substances are involved in accidental, suicidal and even homicidal intoxication; it is a very difficult task to screen and identify individual intoxication in forensic and clinical routine work, especially in cases where anamnesis or circumstantial evidence is obscure or absent, since intoxication often presents with non-specific signs and symptoms, or poor morphological findings. It is also important for forensic pathologists to discriminate other insults as the cause of death or contributory factor even when drugs or poisons are detected. Previous studies showed systemic deterioration in fatal intoxication, involving CNS, using biochemical markers (Maeda et al., 2011). Some drugs and poisons primarily affect the nervous system, and secondary brain damage is almost inevitable in any kind of intoxication; however, CO intoxication and drug abuse are most frequent in forensic routine work.

5.2. Carbon monoxide

The histo-/cytotoxicity of CO is due to its high affinity to iron-containing structures such as hemoglobin and myoglobin, as well as to specific sites of the brain, including the globus pallidus and the midbrain substantia nigra, which is different from cyanide, sulfide and azide (Knight & Saukko, 2004; Oehmichen et al., 2006). CO also depresses myocardial function, resulting in severe hypotension and subsequent global cerebral ischemia and hypoxia. Bilateral necrosis of the globus pallidus and the pars reticulata of the midbrain substantia nigra are known as non-specific alterations (Oehmichen et al., 2006); however, neuronal apoptosis in the pallidum has been suggested as an early change due to CO intoxication in an animal experiment (Piantadosi et al., 1997). With respect to this, immunohistochemistry of ssDNA demonstrated high positivity as a sign of apoptosis in the pallidum of the human brain in fatal CO intoxication (Table 3) (Michiue et al., 2008; Wang et al., 2011a). Similar findings were detected in acute and delayed fire fatalities having a fatal level of blood carboxyhemoglobin (COHb) saturation, different from those with lower COHb level, as described below. These findings indicate the specific neurotoxicity of CO to the pallidum.

5.3. Drug abuse

A variety of psychostimulants, narcotics and hallucinogens are involved in drug abuse, which results in brain damage and functional impairment. Among these drugs, animal experiments have shown that amphetamine and its derivatives, such as methamphetamine and ecstasy, induce apoptosis of cortical and striatal neurons, and cerebellar granular cells via various pathways (Cunha-Oliveira et al., 2008). Neuronal apoptosis has also been suggested with cocaine and opiates (Cunha-Oliveira et al., 2008). In forensic autopsy materials, immunohistochemistry also detected high neuronal ssDNA positivity as a sign of apoptosis in the cerebral cortex, pallidum and substantia nigra in fatal abuse of sedative hypnotics as well as methamphetamine, suggesting selective neuronal damage (Table 3) (Michiue et al., 2008).

5.4. Others

Very little knowledge is available with regard to the contribution of apoptosis to the neurotoxicity of other drugs and poisons at present; however, drug-related hyperthermia may induce neuronal apoptosis in a similar manner to that in heatstroke, described below. Various chemicals that trigger oxidative stress can induce neuronal apoptosis. Animal experiments showed that organophosphorus compounds caused acute necrosis of neurons in the brain at toxic doses, but induced apoptotic neuronal death at sublethal doses (Abou-Donia, 2003).

6. Fire fatality

6.1. General considerations

Fire fatality involves complex causes of death; major lethal factors involved in fire death are burns and inhalation of toxic gases, including CO and cyanide, which are produced by combustion, accompanied by smoke and ambient oxygen depletion (Stefanidou et al., 2008). Despite recent advances in clinical burn and CO intoxication care measures (Ipaktchi & Arbabi, 2006; Prockop & Chichkova, 2007), most fire victims are found dead, and in those found alive, severe burns or brain damage from CO intoxication can cause death despite intensive clinical care. In such cases, it is necessary to clarify the cause and process of death in a fire. In forensic casework, however, it may be difficult to determine the predominant cause of death due to fire or to exclude other causes of death, for which acute heart attack and asphyxiation are of particular interest, especially when clinical toxicological data are not available in cases of prolonged death without severe burns. In this respect, previous studies showed pulmonary pathology, and systemic hematological and biochemical disorders due to burns (Zhu et al., 2001a; Zhu et al., 2001b), while brain immunohistochemistry suggested specific findings of CO intoxication (Michiue et al., 2008). Thus, immunohistochemical markers in the brain that are involved in neuronal damage, apoptosis, degeneration and repair, including ssDNA, GFAP and bFGF, are useful to detect the specific neuropathology of CO intoxication for differentiation from fatal burns as well as other fatal insults.

6.2. Burns

Severe burns in a fire cause systemic disorders involving hypovolemic shock accompanied by hypoalbuminemia (burn shock), and hemolysis and skeletal muscle injury due to deep burns, followed by systemic inflammatory responses and hypoxia (Jeschke et al., 2008), which are usually detected by pathomorphology and biochemistry in postmortem investigation (Bohnert et al., 2010; Quan et al., 2009; Zhu et al., 2001b). Macro- and microscopic signs of vitality in fire death include soot deposits and thermal injury in the upper airways, but these findings may partly be sparse or even absent, especially in peracute deaths, making the diagnosis difficult (Bohnert et al., 2003). Recent immunohistochemical studies of the respiratory tract and lungs demonstrated intravital reactions in fatal burns (Boehm et al., 2010; Bohnert et al., 2010; Marschall et al., 2006);

however, the pathophysiological process leading to death is still unclear. In particular, the influences of toxic gases usually do not leave significant pathology that is detectable after death, except that bilateral pallidum necrosis is occasionally seen in CO intoxication. With respect to this, previous studies detected specific neuronal damage in the pallidum due to CO intoxication by immunohistochemistry (Michiue et al., 2008; Piantadosi et al., 1997); immunohistochemical markers in the brain may be used to differentiate pathological conditions of the neurons and glial cells due to ischemic, metabolic, toxic and traumatic brain injury (Chen et al., 1997; Piantadosi et al., 1997; Zhang et al., 2010).

In acute fire fatality, immunohistochemistry demonstrated higher neuronal ssDNA immunopositivity in the parietal cortex than in acute cardiac and asphyxial deaths, suggesting the induction of neuronal apoptosis, irrespective of the blood COHb level; however, such findings were not seen in cases of postmortem burns (Wang et al., 2011a). These suggest that brain damage due to a fire is not simply caused by ischemia or hypoxia, but also involves cytotoxic factors, including massive thermal tissue injury and hemolysis, which can induce systemic oxidative stress involving the brain (Gatson et al., 2009). However, neuronal ssDNA immunopositivity in the pallidum was lower in cases of a low level of blood COHb saturation than in those with a fatal level of blood COHb saturation (>60%). Therefore, increased neuronal ssDNA immunopositivity in the parietal cortex and pallidum can be used as a vitality finding in acute fire deaths, with consideration of other pathological findings; these findings can be used to interpret death due to burns or CO intoxication in a fire. Furthermore, the topographical distribution of neuronal ssDNA immunopositivity in the brain may be helpful for determining the immediate cause of death in cases of other potentially fatal traumas or diseases, e.g. strangulation, drug abuse and acute cardiac attack. However, higher neuronal ssDNA immunopositivity was sporadically detected in other cases, suggesting the partial contribution of unspecific neuronal damage due to reperfusion, possibly involved with cardiopulmonary resuscitation measures (Li et al., 2010); this should be carefully considered when determining the cause of death, especially in cases where the vitality findings are sparse.

In prolonged deaths, the macro- and microscopic signs of vitality in fire death, described above, may become obscure, making the pathological diagnosis quite difficult. In immunohistochemical study of the brain, however, there were significant differences between fatal burns and CO intoxication in prolonged fire deaths under critical clinical care (Fig. 2). Neuronal loss was seen in those with burns and CO intoxication as well as in patients with a fatal ischemic heart attack and prolonged asphyxial deaths, while glial cells were increased in burns and heart attack; the glial cell number was larger in fatality due to burns than in CO intoxication and asphyxiation, regardless of temporary cardiopulmonary arrest (CPA) after insult, suggesting glial activation. The increase in glial cells in cases of fatal burns was accompanied by higher glial bFGF immunopositivity in the parietal cortex and white matter, and higher and lower glial GFAP immunopositivity in the cortex and white matter, respectively, showing low neuronal ssDNA immunopositivity. The above-mentioned findings differed from those in prolonged death due to heart attack or mechanical asphyxiation involving simple cerebral ischemia or hypoxia, regardless of

temporary CPA after insult. These observations suggest neuronal loss accompanied by active glial responses after severe burns regardless of CPA after insult. Lower glial GFAP immunopositivity in the white matter in prolonged deaths due to burns may be related to BBB damage, as discussed below.

Both *in vitro* and *in vivo*, bFGF has been well established as a neuroprotective and neurotrophic factor (Dietrich et al., 1996; Louis et al., 1993). Severe trauma, including burn injury, can result in whole body tissue damage, for which an important early sign is systemic inflammatory response syndrome (SIRS), which may lead to multiple organ dysfunction syndrome (MODS). The early appearance of inflammatory cytokines in the systemic circulation has been demonstrated following thermal injury both in humans (Cannon et al., 1992) and animals (Kataranovski et al., 1999). Systemic inflammatory responses also develop in the brain (Reyes et al., 2006), which may induce, enhance or accompany astrogliosis (Balasingam et al., 1994). Thus, the up-regulation of bFGF and GFAP as well as increased numbers of glial cells in the parietal cerebral cortex in prolonged death due to burns may reflect self-protective responses of the brain. In acute death, such glial responses may not be apparent due to the shorter survival time. Furthermore, bFGF may be involved in anti-apoptotic pathways; the exogenous application of bFGF prevented apoptosis in both *in vitro* and *in vivo* studies (Ay et al., 2001; Tamatani et al., 1998). High cerebral cortex glial bFGF immunopositivity accompanied by low neuronal ssDNA expression suggests that endogenous bFGF is an anti-apoptosis factor in the brain.

The BBB between systemic circulation and the cerebral parenchyma is composed of interendothelial tight junctions, basal lamina and perivascular astrocytes, and may also be damaged by severe burns; thus, BBB permeability can be increased, causing advanced brain edema (Reyes et al., 2009). Low glial GFAP immunopositivity in the white matter in prolonged deaths due to severe burns suggests astrocyte damage related to BBB dysfunction. In addition, systemic inflammatory responses followed by hyperthermia may also induce BBB dysfunction, which is characterized by vasogenic brain edema (Sharma, 2006). Further investigation is needed to clarify the mechanism of BBB dysfunction in prolonged deaths due to severe burns. Meanwhile, high bFGF positivity in the white matter, which was detected in prolonged deaths due to severe burns, suggests that the self-protective system involving bFGF is activated to maintain BBB function (Deguchi et al., 2002); the damaged brain does not lose its self-protective capacity after severe burns.

To summarize, typical pathologies in the brain after fatal burns are: 1) in acute deaths, increased neuronal ssDNA immunopositivity in the cerebral cortex, irrespective of the severity of the burns and CO intoxication; 2) neuronal loss in prolonged death; 3) increase in glial cells in prolonged death, accompanied by higher glial bFGF immunopositivity in the cerebral cortex and white matter, higher and lower glial GFAP immunopositivity in the cortex and white matter, respectively, with low neuronal ssDNA immunopositivity (Table 3) (Wang et al., 2011a). These findings suggest that: 1) increased neuronal ssDNA positivity, together with other pathological findings, can be used as a vitality finding in acute fire death; 2) the brain retained self-protective response capacity in fire victims who died due to

severe burns. However, progressive systemic deterioration after severe burns, accompanied by preexisting disorders or physical predispositions, can cause fatality due to respiratory failure, hypoxic brain damage, hypovolemic shock and secondary infection involving sepsis, even under critical life support care (Barber et al., 2007; Williams et al., 2009). These death processes should be assessed based on individual evidence.

6.3. Toxic gases

A spectrum of toxic or asphyxiating gases produced by combustion, including CO, cyanide and carbon dioxide, can contribute to death in a fire. CO has histo-/cytotoxicity due to its high affinity to specific sites of the brain, including the globus pallidus and the midbrain substantia nigra, but cyanide did not have such neurotoxicity (Oehmichen et al., 2006). In fire fatality with a fatal level of blood COHb saturation (>60%), immunohistochemistry detected higher neuronal ssDNA immunopositivity in the pallidum than in cases of a lower COHb level (<60%), as described above, suggesting CO-specific neuronal damage (Michiue et al., 2008; Tofighi et al., 2006; Wang et al., 2011a). Cyanide did not appear to contribute to neuronal ssDNA immunopositivity.

In prolonged deaths, neuron and glial cell number was decreased in CO intoxication as well as asphyxiation, regardless of temporary CPA after insult, suggesting reduced glial reactivity due to CO intoxication and asphyxiation. Glial bFGF and GFAP immunopositivity was low at each site, but neuronal ssDNA immunopositivity was high in prolonged deaths due to CO intoxication (Fig. 2) (Wang et al., 2011a). These findings differed from those in prolonged death due to heart attack or mechanical asphyxiation involving simple cerebral ischemia or hypoxia regardless of temporary CPA after insult. These observations suggest neuronal loss and progressive apoptosis without glial responses after CO intoxication. When the crucial functions of glial bFGF and GFAP in the self-protective responses of the brain are considered, high neuronal ssDNA immunopositivity accompanied by low glial bFGF and GFAP expressions in prolonged deaths due to CO intoxication, as indicated above, suggests that the brain has failed to generate sufficient bFGF to prevent apoptosis, which may indicate serious damage to the brain due to CO intoxication; CO can exert direct damage on cells by inducing apoptosis (Tofighi et al., 2006). Low bFGF and GFAP positivity in the white matter in prolonged death due to CO intoxication suggests delayed effects of CO, characterized by bilateral, confluent lesions that reflect diffuse demyelination (Lo et al., 2007). Such injury may also be caused by slowly progressive cytotoxic edema related to the direct toxic effect of CO. These findings suggest persistent and irreversible damage to the brain white matter due to CO intoxication. Similar findings suggesting damage to the BBB in the white matter were partly seen in prolonged asphyxial deaths, but were milder in ischemic heart attack. Such white matter damage may be responsible for delayed CNS deterioration due to CO intoxication and asphyxiation (Lo et al., 2007; Strackx et al., 2008).

To summarize, typical pathologies in the brain of fire fatality with a fatal level of blood COHb saturation are: 1) in acute deaths, increased neuronal ssDNA immunopositivity in the cerebral cortex, irrespective of the severity of CO intoxication, and higher neuronal ssDNA

positivity in the pallidum due to CO intoxication; 2) neuronal loss in prolonged death; 3) overall low glial bFGF and GFAP immunopositivities with high neuronal ssDNA immunopositivity in prolonged death due to CO intoxication (Table 3) (Wang et al., 2011a). These findings suggest neuronal loss and progressive apoptosis without glial responses after CO intoxication; the brain sustained serious damage involving the loss of self-protective capacity in CO intoxication, thus causing delayed death.

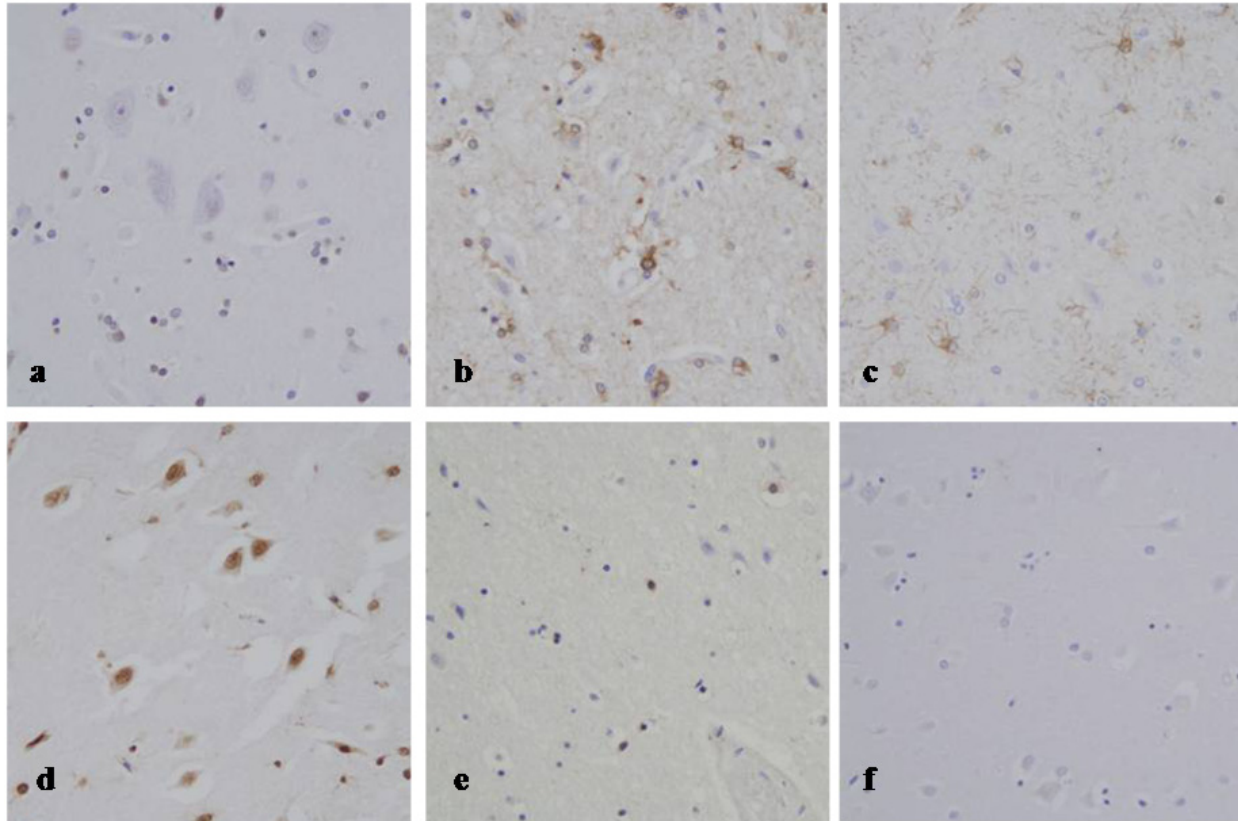


Figure 2. Immunohistochemistry of single-stranded DNA (ssDNA), basic fibroblast growth factor (bFGF) and glial fibrillary acidic protein (GFAP) in the parietal cortex of prolonged fire death cases: 1) a case of fatal burns and low blood carboxyhemoglobin (COHb) saturation (72 h survival), showing low ssDNA (a), and high bFGF (b) and GFAP (c) positivity; 2) a case of a fatal level of blood COHb saturation (48 h survival), showing high ssDNA (d), and low bFGF (e) and GFAP (f) positivity

7. Extreme ambient temperature

7.1. General considerations

In forensic practice, the diagnosis of death due to extreme environmental temperatures involving hypothermia (cold exposure) and hyperthermia (heat stroke) is often difficult because of poor or nonspecific gross and microscopic findings, although hypothermia may present with typical pathologies, including frost erythema and hemorrhagic gastric erosions (Wischnewski spots) (Green et al., 2001; Nixdorf-Miller et al., 2006; Schuliar et al., 2001; Turk, 2010). Besides diagnosis by exclusion, histology, immunohistochemistry, biochemistry and molecular biology can be used for detailed investigation of functional deaths (Madea &

Saukko, 2010; Madea et al., 2010); previous studies have suggested that postmortem biochemistry, immunohistochemistry and molecular biology can detect systemic functional alterations in these fatalities (Fineschi et al., 2005; Ishikawa et al., 2008; Jakubeniene et al., 2009; Maeda et al., 2011; Yoshida et al., 2011). Immunohistochemistry of the brain using ssDNA, bFGF, GFAP and S100 can also demonstrate functional alterations in fatalities due to extreme ambient temperature, involving glial responses and neuronal apoptosis (Wang et al., 2012a).

7.2. Hypothermia (Cold exposure)

When the human body cannot compensate for heat loss in an extremely cold environment, the body temperature decreases progressively, resulting in cerebral and cardiorespiratory dysfunction, and finally fatal arrhythmia and asystole. Metabolic deterioration involves dehydration, acidosis, azotemia and enhanced fat metabolism with ketonemia/ketouria, but myocardial and brain tissue damage are usually mild (Maeda et al., 2011).

In immunohistochemical investigation of the brain, hypothermia cases showed higher glial bFGF immunopositivity in the cerebral cortex and white matter, and higher S100 β immunopositivity in the cerebral cortex with a lower CSF S100 β concentration, without glial or neuronal loss (Fig. 3 and Table 3) (Wang et al., 2012a). The up-regulation of glial bFGF and S100 β in the cerebral cortex suggests the self-protective responses of the brain and possible neurotrophic properties, respectively (Gomide & Chadi, 1999). Furthermore, since bFGF may be involved in the anti-apoptotic pathways (Ay et al., 2001; Tamatani et al., 1998), high glial bFGF immunopositivity accompanied by low neuronal ssDNA expression in hypothermia cases can indicate the activation of endogenous bFGF as an anti-apoptosis factor in the brain, which is similar to previous findings in prolonged fire fatality due to burns (Wang et al., 2011a). As above, the brain may retain self-protective response capacity without marked glial or neuronal damage in fatal hypothermia. The mechanism of death may mainly involve cardiac dysfunction, including ventricular fibrillation or asystole, resulting from myocardial ischemia, hypoxia, electrolyte abnormalities and elevated catecholamine levels (Turk, 2010), although there have been few postmortem investigations (Ishikawa et al., 2010; Wang et al., 2011b). To summarize, fatal hypothermia cases showed neuroprotective glial responses without marked neuronal or glial damage, which can serve as a condition for possible recovery and survival by means of adequate resuscitation and life-supporting measures.

7.3. Hyperthermia (Heatstroke)

A high ambient temperature in combination with predisposing factors and individual susceptibility ultimately impairs thermoregulation, and the body temperature rises precipitously; the main pathophysiology of heatstroke consists of hyperpyrexia involving impaired thermoregulation, accompanied by dehydration and profound systemic hypoxia, which is followed by further complications of pulmonary edema, renal tubular necrosis, adrenal hemorrhage, hepatic necrosis, myocardial necrosis, rhabdomyolysis,

systemic inflammatory response syndrome (SIRS), disseminated intravascular coagulation (DIC), and ultimately MODS. Clinical diagnosis of heatstroke and related syndromes is usually not difficult, considering hyperpyrexia and laboratory findings, and excluding other causes of hyperpyrexia; however, postmortem diagnosis is obstructed by a lack of specific findings. The diagnosis should be established by collecting pathological findings compatible with heatstroke, related to the predisposition, drug abuse, and physical abuse or neglect, and to differentiate other insults, in combination with toxicology and biochemistry (Maeda et al., 2011). Circumstantial evidence may also be considered when available.

In immunohistochemical investigation of the brain, characteristic findings in hyperthermia cases were lower glial GFAP and S100 β immunopositivity in the white matter, and higher neuronal ssDNA immunopositivity in the cerebral cortex and hippocampus, accompanied by high glial bFGF and S100 β immunopositivity in the cerebral cortex, without glial or neuronal loss (Fig. 3 and Table 3) (Wang et al., 2012a). Survival in hospital for days under a clinical diagnosis of heatstroke showed similar findings. Increased cortical glial bFGF and S100 β may indicate self-protective responses of the brain, as described above for hypothermia; however, these findings were milder in hyperthermia than in hypothermia, involving neuronal and glial damage described below, and may also be related to the initiation of inflammatory processes involved in the systemic inflammatory response leading to MODS, in which encephalopathy predominates (Bouchama & Knochel, 2002).

Hyperthermia can exert direct damage on tissue cells by inducing apoptosis (Basile et al., 2008; Vogel et al., 1997); increased neuronal ssDNA expression can be used as evidence of brain dysfunction involving apoptosis as part of MODS from hyperthermia. These observations suggest diffuse neuronal apoptosis despite initiation of neuroprotective cortical astrocyte reactions in hyperthermia. Furthermore, the BBB, composed of endothelial tight junctions, basal lamina and perivascular astrocytes, may be damaged by hyperthermia, characterized by vasogenic brain edema (Sharma, 2006; Sharma & Hoopes, 2003). Low glial GFAP and S100 β immunopositivity in the white matter in hyperthermia cases suggests that astrocyte damage may be involved in BBB dysfunction. In addition, low bFGF immunopositivity in the white matter in hyperthermia cases indicates that white matter loses the capacity for a compensatory response.

These observations suggest characteristic brain responses in the death process due to an extreme environmental temperature; hyperthermia as well as hypothermia involved higher glial bFGF positivity in the cerebral cortex, indicating activation of neuroprotective processes. To summarize, fatal hyperthermia cases showed diffuse neuronal apoptosis despite the initiation of neuroprotective cortical astrocyte responses, accompanied by glial damage in the white matter; diffuse neuronal and glial deterioration in the brain may lead to a fatal outcome even under critical medical care. Further investigation is needed to clarify the underlying mechanisms.

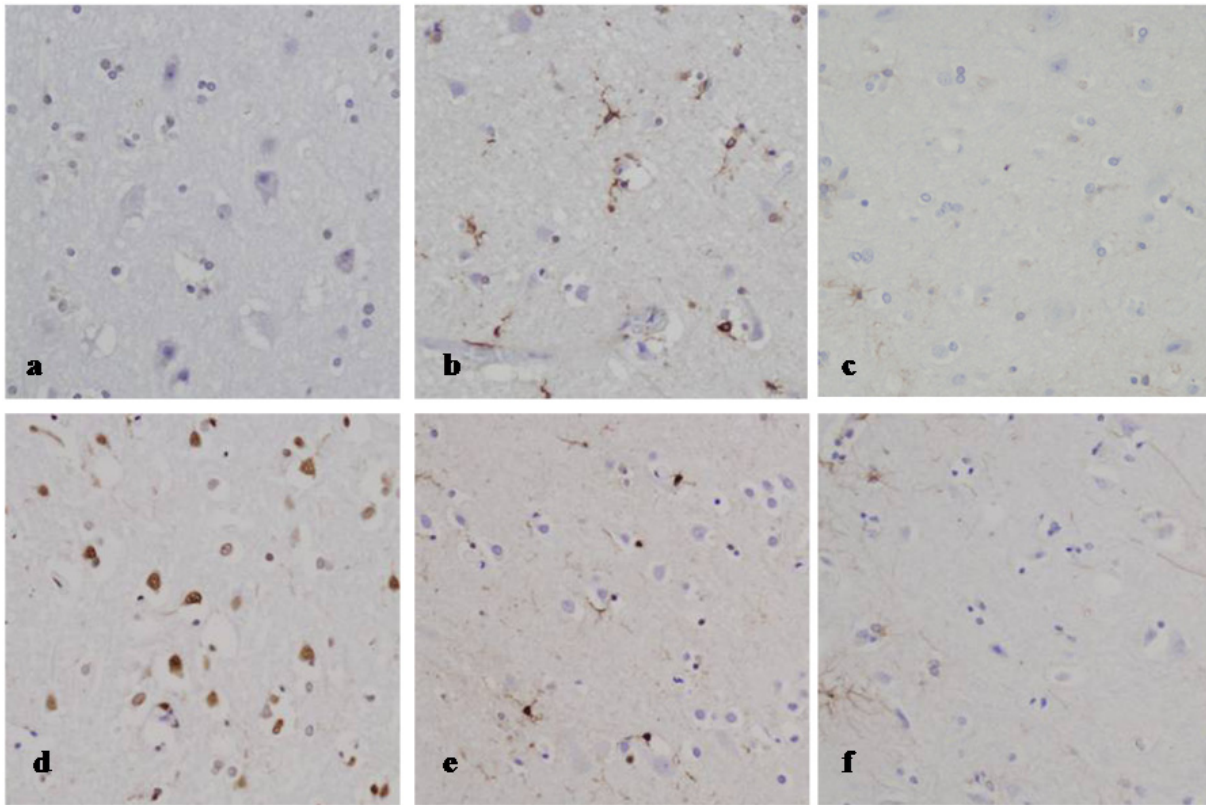


Figure 3. Immunohistochemistry of single-stranded DNA (ssDNA), basic fibroblast growth factor (bFGF) and glial fibrillary acidic protein (GFAP) in the parietal cerebral cortex in fatalities due to extreme ambient temperatures: 1) hypothermia (cold exposure), showing low ssDNA (a) and high bFGF (b) positivity with unaffected GFAP positivity (c); 2) hyperthermia (heatstroke), showing high ssDNA (d) and bFGF (e) positivity with unaffected GFAP positivity (f)

8. Limitations and outlook

Different from animal experimentation, forensic and clinical materials are not homogenous owing to the complexity of insults and the consequent brain damage, varied susceptibility of subjects, and intensive clinical intervention. In addition, forensic autopsy materials partly include cases where the estimated survival time and/or postmortem interval depend on obscure circumstantial evidence. Therefore, it is difficult to elucidate the time course of cellular responses after individual specified insults in detail. It is important, however, to collect postmortem human data involving the whole brain pathology, which are not clinically or experimentally available. Further investigation is needed, including other markers involved in apoptotic pathways as well as in water homeostasis, BBB integrity and inflammatory responses, combined with the systematic analysis of related gene expressions.

9. Conclusion

A serial study of forensic autopsy cases suggested the involvement of neuronal apoptosis at specific sites of the brain, possibly contributing to CNS damage and dysfunction, which was characteristic of traumatic insults, including progressive or delayed brain damage due to

mechanical head injury, involving brain swelling and compression, as well as due to asphyxia, CO intoxication, fire fatality, and hyperthermia (heatstroke). Molecular pathological investigation of neuronal apoptosis and related biological responses in forensic materials can provide specific information in medical science for understanding the death process after traumatic insults. These studies will contribute not only in forensic casework but also to the clinical management of critically traumatized patients.

Author details

Qi Wang, Tomomi Michiue and Hitoshi Maeda

Department of Legal Medicine, Osaka City University Medical School, Abeno, Osaka, Japan

Acknowledgement

Serial studies by the authors and coworkers were supported in part by Grants-in-Aid for Scientific Research from the Japan Society for the Promotion of Science and the Ministry of Education, Culture, Sports, Science and Technology, Japan (Grant Nos. 11670425, 12470109, 08307006, 15390217, 15590585, 21790612 and 22590642).

10. References

- Abou-Donia, M. B. (2003). Organophosphorus ester-induced chronic neurotoxicity. *Archives of Environmental Health*, 58(8), pp. 484-497.
- Alison, M. R. & Sarraf, C. E. (1992). Apoptosis: a gene-directed programme of cell death. *Journal of the Royal College of Physicians of London*, 26(1), pp. 25-35.
- Ay, I., Sugimori, H. & Finklestein, S. P. (2001). Intravenous basic fibroblast growth factor (bFGF) decreases DNA fragmentation and prevents downregulation of Bcl-2 expression in the ischemic brain following middle cerebral artery occlusion in rats. *Brain Research. Molecular Brain Research*, 87(1), pp. 71-80.
- Balasingam, V., Tejada-Berges, T., Wright, E., Bouckova, R. & Yong, V. W. (1994). Reactive astrogliosis in the neonatal mouse brain and its modulation by cytokines. *Journal of Neuroscience*, 14(2), pp. 846-856.
- Barbeito, L. H., Pehar, M., Cassina, P., Vargas, M. R., Peluffo, H., Viera, L., Estevez, A. G. & Beckman, J. S. (2004). A role for astrocytes in motor neuron loss in amyotrophic lateral sclerosis. *Brain Research. Brain Research Reviews*, 47(1-3), pp. 263-274.
- Barber, R. C., Aragaki, C. C., Chang, L. Y., Purdue, G. F., Hunt, J. L., Arnoldo, B. D. & Horton, J. W. (2007). CD14-159 C allele is associated with increased risk of mortality after burn injury. *Shock*, 27(3), pp. 232-237.
- Barzo, P., Marmarou, A., Fatouros, P., Hayasaki, K. & Corwin, F. (1997). Contribution of vasogenic and cellular edema to traumatic brain swelling measured by diffusion-weighted imaging. *Journal of Neurosurgery*, 87(6), pp. 900-907.
- Basile, A., Biziato, D., Sherbet, G. V., Comi, P. & Cajone, F. (2008). Hyperthermia inhibits cell proliferation and induces apoptosis: relative signaling status of P53, S100A4, and Notch

- in heat sensitive and resistant cell lines. *Journal of Cellular Biochemistry*, 103(1), pp. 212-220.
- Becker, E. B. & Bonni, A. (2004). Cell cycle regulation of neuronal apoptosis in development and disease. *Progress in Neurobiology*, 72(1), pp. 1-25.
- Bikfalvi, A., Klein, S., Pintucci, G. & Rifkin, D. B. (1997). Biological roles of fibroblast growth factor-2. *Endocrine Reviews*, 18(1), pp. 26-45.
- Boehm, J., Fischer, K. & Bohnert, M. (2010). Putative role of TNF-alpha, interleukin-8 and ICAM-1 as indicators of an early inflammatory reaction after burn: a morphological and immunohistochemical study of lung tissue of fire victims. *Journal of Clinical Pathology*, 63(11), pp. 967-971.
- Bohnert, M., Werner, C. R. & Pollak, S. (2003). Problems associated with the diagnosis of vitality in burned bodies. *Forensic Science International*, 135(3), pp. 197-205.
- Bohnert, M., Anderson, J., Rothschild, M. A. & Bohm, J. (2010). Immunohistochemical expression of fibronectin in the lungs of fire victims proves intravital reaction in fatal burns. *International Journal of Legal Medicine*, 124(6), pp. 583-588.
- Bouchama, A. & Knochel, J. P. (2002). Heat stroke. *New England Journal of Medicine*, 346(25), pp. 1978-1988.
- Bratzke, H. (2004). Research in forensic neurotraumatology. *Forensic Science International*, 144(2-3), pp. 157-165.
- Byard, R. W., Bhatia, K. D., Reilly, P. L. & Vink, R. (2009). How rapidly does cerebral swelling follow trauma? Observations using an animal model and possible implications in infancy. *Legal Medicine (Tokyo)*, 11 Suppl 1, pp. S128-131.
- Byard, R. W. (2011). Commentary on: Sauvageau A, Boghossian E. Classification of asphyxia: the need for standardization. *Journal of Forensic Sciences*, 56(1), pp. 264.
- Cadet, J. L. & Krasnova, I. N. (2009). Molecular bases of methamphetamine-induced neurodegeneration. *International Review of Neurobiology*, 88, pp. 101-119.
- Cannon, J. G., Friedberg, J. S., Gelfand, J. A., Tompkins, R. G., Burke, J. F. & Dinarello, C. A. (1992). Circulating interleukin-1 beta and tumor necrosis factor-alpha concentrations after burn injury in humans. *Critical Care Medicine*, 20(10), pp. 1414-1419.
- Castejon, O. J. & Arismendi, G. J. (2006). Nerve cell death types in the edematous human cerebral cortex. *Journal of Submicroscopic Cytology and Pathology*, 38(1), pp. 21-36.
- Chan, P. H. (2004). Mitochondria and neuronal death/survival signaling pathways in cerebral ischemia. *Neurochemical Research*, 29(11), pp. 1943-1949.
- Chen, J., Jin, K., Chen, M., Pei, W., Kawaguchi, K., Greenberg, D. A. & Simon, R. P. (1997). Early detection of DNA strand breaks in the brain after transient focal ischemia: implications for the role of DNA damage in apoptosis and neuronal cell death. *Journal of Neurochemistry*, 69(1), pp. 232-245.
- Clark, R. S. B., Chen, M., Kochanek, P. M., Watkins, S. C., Jin, K. L., Draviam, R., Nathaniel, P. D., Pinto, R., Marion, D. W. & Graham, S. H. (2001). Detection of single- and double-strand DNA breaks after traumatic brain injury in rats: comparison of in situ labeling techniques using DNA polymerase I, the Klenow fragment of DNA polymerase I, and terminal deoxynucleotidyl transferase. *Journal of Neurotrauma*, 18(7), pp. 675-689.

- Cunha-Oliveira, T., Rego, A. C. & Oliveira, C. R. (2008). Cellular and molecular mechanisms involved in the neurotoxicity of opioid and psychostimulant drugs. *Brain Research Reviews*, 58(1), pp. 192-208.
- Deguchi, Y., Okutsu, H., Okura, T., Yamada, S., Kimura, R., Yuge, T., Furukawa, A., Morimoto, K., Tachikawa, M., Ohtsuki, S., Hosoya, K. & Terasaki, T. (2002). Internalization of basic fibroblast growth factor at the mouse blood-brain barrier involves perlecan, a heparan sulfate proteoglycan. *Journal of Neurochemistry*, 83(2), pp. 381-389.
- Dietrich, W. D., Alonso, O., Busto, R. & Finklestein, S. P. (1996). Posttreatment with intravenous basic fibroblast growth factor reduces histopathological damage following fluid-percussion brain injury in rats. *Journal of Neurotrauma*, 13(6), pp. 309-316.
- Dressler, J., Hanisch, U., Kuhlisch, E. & Geiger, K. D. (2007). Neuronal and glial apoptosis in human traumatic brain injury. *International Journal of Legal Medicine*, 121(5), pp. 365-375.
- Fawthrop, D. J., Boobis, A. R. & Davies, D. S. (1991). Mechanisms of cell death. *Archives of Toxicology*, 65(6), pp. 437-444.
- Fineschi, V., D'Errico, S., Neri, M., Panarese, F., Ricci, P. A. & Turillazzi, E. (2005). Heat stroke in an incubator: an immunohistochemical study in a fatal case. *International Journal of Legal Medicine*, 119(2), pp. 94-97.
- Frankfurt, O. S., Robb, J. A., Sugarbaker, E. V. & Villa, L. (1996). Monoclonal antibody to single-stranded DNA is a specific and sensitive cellular marker of apoptosis. *Experimental Cell Research*, 226(2), pp. 387-397.
- Gatson, J. W., Maass, D. L., Simpkins, J. W., Idris, A. H., Minei, J. P. & Wigginton, J. G. (2009). Estrogen treatment following severe burn injury reduces brain inflammation and apoptotic signaling. *Journal of Neuroinflammation*, 22(6), pp. 30.
- Gavrieli, Y., Sherman, Y. & Ben-Sasson, S. A. (1992). Identification of programmed cell death in situ via specific labeling of nuclear DNA fragmentation. *Journal of Cell Biology*, 119(3), pp. 493-501.
- Gomide, V. C. & Chadi, G. (1999). The trophic factors S-100beta and basic fibroblast growth factor are increased in the forebrain reactive astrocytes of adult callosotomized rat. *Brain Research*, 835(2), pp. 162-174.
- Gong, C., Boulis, N., Qian, J., Turner, D. E., Hoff, J. T. & Keep, R. F. (2001). Intracerebral hemorrhage-induced neuronal death. *Neurosurgery*, 48(4), pp. 875-883.
- Graham, D. I., Lawrence, A. E., Adams, J. H., Doyle, D. & McLellan, D. R. (1987). Brain damage in non-missile head injury secondary to high intracranial pressure. *Neuropathology and Applied Neurobiology*, 13(3), pp. 209-217.
- Graham, D. I., Lawrence, A. E., Adams, J. H., Doyle, D. & McLellan, D. R. (1988). Brain damage in fatal non-missile head injury without high intracranial pressure. *Journal of Clinical Pathology*, 41(1), pp. 34-37.
- Green, H., Gilbert, J., James, R. & Byard, R. W. (2001). An analysis of factors contributing to a series of deaths caused by exposure to high environmental temperatures. *American Journal of Forensic Medicine and Pathology*, 22(2), pp. 196-199.
- Greenfield, J. G. & Ellison, D. (2008). *Greenfield's neuropathology*. Hodder Arnold.

- Hausmann, R., Kaiser, A., Lang, C., Bohnert, M. & Betz, P. (1999). A quantitative immunohistochemical study on the time-dependent course of acute inflammatory cellular response to human brain injury. *International Journal of Legal Medicine*, 112(4), pp. 227-232.
- Hausmann, R., Riess, R., Fieguth, A. & Betz, P. (2000). Immunohistochemical investigations on the course of astroglial GFAP expression following human brain injury. *International Journal of Legal Medicine*, 113(2), pp. 70-75.
- Hausmann, R. & Betz, P. (2001). Course of glial immunoreactivity for vimentin, tenascin and alpha1-antichymotrypsin after traumatic injury to human brain. *International Journal of Legal Medicine*, 114(6), pp. 338-342.
- Hausmann, R., Biermann, T., Wiest, I., Tubel, J. & Betz, P. (2004). Neuronal apoptosis following human brain injury. *International Journal of Legal Medicine*, 118(1), pp. 32-36.
- Hellal, F., Bonnefont-Rousselot, D., Croci, N., Palmier, B., Plotkine, M. & Marchand-Verrecchia, C. (2004). Pattern of cerebral edema and hemorrhage in a mice model of diffuse brain injury. *Neuroscience Letters*, 357(1), pp. 21-24.
- Ipaktchi, K. & Arbabi, S. (2006). Advances in burn critical care. *Critical Care Medicine*, 34(9 Suppl), pp. S239-244.
- Ishida, K., Zhu, B. L. & Maeda, H. (2002). A quantitative RT-PCR assay of surfactant-associated protein A1 and A2 mRNA transcripts as a diagnostic tool for acute asphyxial death. *Legal Medicine (Tokyo)*, 4(1), pp. 7-12.
- Ishikawa, T., Quan, L., Li, D. R., Zhao, D., Michiue, T., Hamel, M. & Maeda, H. (2008). Postmortem biochemistry and immunohistochemistry of adrenocorticotrophic hormone with special regard to fatal hypothermia. *Forensic Science International*, 179(2-3), pp. 147-151.
- Ishikawa, T., Yoshida, C., Michiue, T., Perdekamp, M. G., Pollak, S. & Maeda, H. (2010). Immunohistochemistry of catecholamines in the hypothalamic-pituitary-adrenal system with special regard to fatal hypothermia and hyperthermia. *Legal Medicine (Tokyo)*, 12(3), pp. 121-127.
- Jakubeniene, M., Irnius, A., Chaker, G. A., Paliulis, J. M. & Bechelis, A. (2009). Post-mortem investigation of calcium content in liver, heart, and skeletal muscle in accidental hypothermia cases. *Forensic Science International*, 190(1-3), pp. 87-90.
- Jeschke, M. G., Chinkes, D. L., Finnerty, C. C., Kulp, G., Suman, O. E., Norbury, W. B., Branski, L. K., Gauglitz, G. G., Mlcak, R. P. & Herndon, D. N. (2008). Pathophysiologic response to severe burn injury. *Annals of Surgery*, 248(3), pp. 387-401.
- Kataranovski, M., Magic, Z. & Pejnovic, N. (1999). Early inflammatory cytokine and acute phase protein response under the stress of thermal injury in rats. *Physiological Research*, 48(6), pp. 473-482.
- Kimelberg, H. K. (1995). Current concepts of brain edema. Review of laboratory investigations. *Journal of Neurosurgery*, 83(6), pp. 1051-1059.
- Klatzo, I. (1994). Evolution of brain edema concepts. *Acta Neurochirurgica. Supplementum*, 60, pp. 3-6.
- Knight, B. & Saukko, P. J. (2004). *Knight's Forensic pathology* (3rd ed.). Arnold.

- Korfias, S., Stranjalis, G., Papadimitriou, A., Psachoulia, C., Daskalakis, G., Antsaklis, A. & Sakas, D. E. (2006). Serum S-100B protein as a biochemical marker of brain injury: a review of current concepts. *Current Medicinal Chemistry*, 13(30), pp. 3719-3731.
- Li, D. R., Zhu, B. L., Ishikawa, T., Zhao, D., Michiue, T. & Maeda, H. (2006a). Postmortem serum protein S100B levels with regard to the cause of death involving brain damage in medicolegal autopsy cases. *Legal Medicine (Tokyo)*, 8(2), pp. 71-77.
- Li, D. R., Zhu, B. L., Ishikawa, T., Zhao, D., Michiue, T. & Maeda, H. (2006b). Immunohistochemical distribution of S-100 protein in the cerebral cortex with regard to the cause of death in forensic autopsy. *Legal Medicine (Tokyo)*, 8(2), pp. 78-85.
- Li, D. R., Michiue, T., Zhu, B. L., Ishikawa, T., Quan, L., Zhao, D., Yoshida, C., Chen, J. H., Wang, Q., Komatsu, A., Azuma, Y. & Maeda, H. (2009a). Evaluation of postmortem S100B levels in the cerebrospinal fluid with regard to the cause of death in medicolegal autopsy. *Legal Medicine (Tokyo)*, 11 Suppl 1, pp. S273-275.
- Li, D. R., Ishikawa, T., Zhao, D., Michiue, T., Quan, L., Zhu, B. L. & Maeda, H. (2009b). Histopathological changes of the hippocampus neurons in brain injury. *Histology and Histopathology*, 24(9), pp. 1113-1120.
- Li, J., Han, B., Ma, X. & Qi, S. (2010). The effects of propofol on hippocampal caspase-3 and Bcl-2 expression following forebrain ischemia-reperfusion in rats. *Brain Research*, 1356, pp. 11-23.
- Liedtke, W., Edelmann, W., Bieri, P. L., Chiu, F. C., Cowan, N. J., Kucherlapati, R. & Raine, C. S. (1996). GFAP is necessary for the integrity of CNS white matter architecture and long-term maintenance of myelination. *Neuron*, 17(4), pp. 607-615.
- Lo, C. P., Chen, S. Y., Lee, K. W., Chen, W. L., Chen, C. Y., Hsueh, C. J. & Huang, G. S. (2007). Brain injury after acute carbon monoxide poisoning: early and late complications. *American Journal of Roentgenology*, 189(4), pp. W205-211.
- Louis, J. C., Magal, E., Gerdes, W. & Seifert, W. (1993). Survival-promoting and protein kinase C-regulating roles of basic FGF for hippocampal neurons exposed to phorbol ester, glutamate and ischaemia-like conditions. *European Journal of Neuroscience*, 5(12), pp. 1610-1621.
- Love, S. (1999). Oxidative stress in brain ischemia. *Brain Pathology*, 9(1), pp. 119-131.
- Macmillan, C. S., Grant, I. S. & Andrews, P. J. (2002). Pulmonary and cardiac sequelae of subarachnoid haemorrhage: time for active management? *Intensive Care Medicine*, 28(8), pp. 1012-1023.
- Madea, B. & Saukko, P. (2010). Molecular pathology in forensic medicine. Preface. *Forensic Science International*, 203(1-3), pp. 1-2.
- Madea, B., Saukko, P., Oliva, A. & Musshoff, F. (2010). Molecular pathology in forensic medicine--Introduction. *Forensic Science International*, 203(1-3), pp. 3-14.
- Maeda, H., Zhu, B. L., Ishikawa, T. & Michiue, T. (2010). Forensic molecular pathology of violent deaths. *Forensic Science International*, 203(1-3), pp. 83-92.
- Maeda, H., Ishikawa, T. & Michiue, T. (2011). Forensic biochemistry for functional investigation of death: concept and practical application. *Legal Medicine (Tokyo)*, 13(2), pp. 55-67.

- Marmarou, A., Fatouros, P. P., Barzo, P., Portella, G., Yoshihara, M., Tsuji, O., Yamamoto, T., Laine, F., Signoretti, S., Ward, J. D., Bullock, M. R. & Young, H. F. (2000). Contribution of edema and cerebral blood volume to traumatic brain swelling in head-injured patients. *Journal of Neurosurgery*, 93(2), pp. 183-193.
- Marschall, S., Rothschild, M. A. & Bohnert, M. (2006). Expression of heat-shock protein 70 (Hsp70) in the respiratory tract and lungs of fire victims. *International Journal of Legal Medicine*, 120(6), pp. 355-359.
- Martin, L. J., Al-Abdulla, N. A., Brambrink, A. M., Kirsch, J. R., Sieber, F. E. & Portera-Cailliau, C. (1998). Neurodegeneration in excitotoxicity, global cerebral ischemia, and target deprivation: A perspective on the contributions of apoptosis and necrosis. *Brain Research Bulletin*, 46(4), pp. 281-309.
- Matute, C., Domercq, M. & Sanchez-Gomez, M. V. (2006). Glutamate-mediated glial injury: mechanisms and clinical importance. *Glia*, 53(2), pp. 212-224.
- Michiue, T., Ishikawa, T., Quan, L., Li, D. R., Zhao, D., Komatsu, A., Zhu, B. L. & Maeda, H. (2008). Single-stranded DNA as an immunohistochemical marker of neuronal damage in human brain: an analysis of autopsy material with regard to the cause of death. *Forensic Science International*, 178(2-3), pp. 185-191.
- Nag, S. (2011). Morphology and properties of astrocytes. *Methods in Molecular Biology*, 686, pp. 69-100.
- Nakamura, T., Keep, R. F., Hua, Y., Hoff, J. T. & Xi, G. (2005). Oxidative DNA injury after experimental intracerebral hemorrhage. *Brain Research*, 1039(1-2), pp. 30-36.
- Nixdorf-Miller, A., Hunsaker, D. M. & Hunsaker, J. C., 3rd. (2006). Hypothermia and hyperthermia medicolegal investigation of morbidity and mortality from exposure to environmental temperature extremes. *Archives of Pathology and Laboratory Medicine*, 130(9), pp. 1297-1304.
- Oehmichen, M., Walter, T., Meissner, C. & Friedrich, H. J. (2003). Time course of cortical hemorrhages after closed traumatic brain injury: statistical analysis of posttraumatic histomorphological alterations. *Journal of Neurotrauma*, 20(1), pp. 87-103.
- Oehmichen, M., Auer, R. N. & König, H. G. (2006). *Forensic neuropathology and associated neurology*. Springer Verlag.
- Parizel, P. M., Makkat, S., Jorens, P. G., Ozsarlak, O., Cras, P., Van Goethem, J. W., van den Hauwe, L., Verlooy, J. & De Schepper, A. M. (2002). Brainstem hemorrhage in descending transtentorial herniation (Duret hemorrhage). *Intensive Care Medicine*, 28(1), pp. 85-88.
- Piantadosi, C. A., Zhang, J., Levin, E. D., Folz, R. J. & Schmechel, D. E. (1997). Apoptosis and delayed neuronal damage after carbon monoxide poisoning in the rat. *Experimental Neurology*, 147(1), pp. 103-114.
- Polazzi, E., Gianni, T. & Contestabile, A. (2001). Microglial cells protect cerebellar granule neurons from apoptosis: evidence for reciprocal signaling. *Glia*, 36(3), pp. 271-280.
- Prockop, L. D. & Chichkova, R. I. (2007). Carbon monoxide intoxication: an updated review. *Journal of the Neurological Sciences*, 262(1-2), pp. 122-130.
- Quan, L., Ishikawa, T., Michiue, T., Li, D. R., Zhao, D., Yoshida, C., Chen, J. H., Komatsu, A., Azuma, Y., Sakoda, S., Zhu, B. L. & Maeda, H. (2009). Analyses of cardiac blood cells

- and serum proteins with regard to cause of death in forensic autopsy cases. *Legal Medicine (Tokyo)*, 11 Suppl 1, pp. S297-300.
- Reyes, R., Guo, M., Swann, K., Shetgeri, S. U., Sprague, S. M., Jimenez, D. F., Barone, C. M. & Ding, Y. (2009). Role of tumor necrosis factor-alpha and matrix metalloproteinase-9 in blood-brain barrier disruption after peripheral thermal injury in rats. *Journal of Neurosurgery*, 110(6), pp. 1218-1226.
- Reyes, R., Jr., Wu, Y., Lai, Q., Mrizek, M., Berger, J., Jimenez, D. F., Barone, C. M. & Ding, Y. (2006). Early inflammatory response in rat brain after peripheral thermal injury. *Neuroscience Letters*, 407(1), pp. 11-15.
- Rink, A., Fung, K. M., Trojanowski, J. Q., Lee, V. M., Neugebauer, E. & McIntosh, T. K. (1995). Evidence of apoptotic cell death after experimental traumatic brain injury in the rat. *American Journal of Pathology*, 147(6), pp. 1575-1583.
- Rosenblum, W. I. (1997). Histopathologic clues to the pathways of neuronal death following ischemia/hypoxia. *Journal of Neurotrauma*, 14(5), pp. 313-326.
- Sauvageau, A. & Boghossian, E. (2010). Classification of asphyxia: the need for standardization. *Journal of Forensic Sciences*, 55(5), pp. 1259-1267.
- Schuliar, Y., Savourey, G., Besnard, Y. & Launey, J. C. (2001). Diagnosis of heat stroke in forensic medicine. Contribution of thermophysiology. *Forensic Science International*, 124(2-3), pp. 205-208.
- Sharma, H. S. & Hoopes, P. J. (2003). Hyperthermia induced pathophysiology of the central nervous system. *International Journal of Hyperthermia*, 19(3), pp. 325-354.
- Sharma, H. S. (2006). Hyperthermia induced brain oedema: current status and future perspectives. *Indian Journal of Medical Research*, 123(5), pp. 629-652.
- Stefanidou, M., Athanaselis, S. & Spiliopoulou, C. (2008). Health impacts of fire smoke inhalation. *Inhalation Toxicology*, 20(8), pp. 761-766.
- Stoica, B. A. & Faden, A. I. (2010). Cell death mechanisms and modulation in traumatic brain injury. *Neurotherapeutics*, 7(1), pp. 3-12.
- Strackx, E., Van den Hove, D. L., Steinbusch, H. P., Steinbusch, H. W., Vles, J. S., Blanco, C. E. & Gavilanes, A. W. (2008). A combined behavioral and morphological study on the effects of fetal asphyxia on the nigrostriatal dopaminergic system in adult rats. *Experimental Neurology*, 211(2), pp. 413-422.
- Stroick, M., Fatar, M., Ragoschke-Schumm, A., Fassbender, K., Bertsch, T. & Hennerici, M. G. (2006). Protein S-100B--a prognostic marker for cerebral damage. *Current Medicinal Chemistry*, 13(25), pp. 3053-3060.
- Takamiya, M., Fujita, S., Saigusa, K. & Aoki, Y. (2007). Simultaneous detections of 27 cytokines during cerebral wound healing by multiplexed bead-based immunoassay for wound age estimation. *Journal of Neurotrauma*, 24(12), pp. 1833-1844.
- Tamatani, M., Ogawa, S., Nunez, G. & Tohyama, M. (1998). Growth factors prevent changes in Bcl-2 and Bax expression and neuronal apoptosis induced by nitric oxide. *Cell Death and Differentiation*, 5(10), pp. 911-919.
- Tao, L., Chen, X., Qin, Z. & Bian, S. (2006). Could NF-kappaB and caspase-3 be markers for estimation of post-interval of human traumatic brain injury? *Forensic Science International*, 162(1-3), pp. 174-177.

- Tofighi, R., Tillmark, N., Dare, E., Aberg, A. M., Larsson, J. E. & Ceccatelli, S. (2006). Hypoxia-independent apoptosis in neural cells exposed to carbon monoxide in vitro. *Brain Research*, 1098(1), pp. 1-8.
- Turk, E. E. (2010). Hypothermia. *Forensic Sci Med Pathol*, 6(2), pp. 106-115.
- Unterberg, A. W., Stover, J., Kress, B. & Kiening, K. L. (2004). Edema and brain trauma. *Neuroscience*, 129(4), pp. 1021-1029.
- Vaux, D. L. & Strasser, A. (1996). The molecular biology of apoptosis. *Proceedings of the National Academy of Sciences of the United States of America*, 93(6), pp. 2239-2244.
- Vogel, P., Dux, E. & Wiessner, C. (1997). Evidence of apoptosis in primary neuronal cultures after heat shock. *Brain Research*, 764(1-2), pp. 205-213.
- Wang, Q., Ishikawa, T., Michiue, T., Zhu, B. L. & Maeda, H. (2011a). Evaluation of human brain damage in fire fatality by quantification of basic fibroblast growth factor (bFGF), glial fibrillary acidic protein (GFAP) and single-stranded DNA (ssDNA) immunoreactivities. *Forensic Science International*, 211(1-3), pp. 19-26.
- Wang, Q., Michiue, T., Ishikawa, T., Zhu, B. L. & Maeda, H. (2011b). Combined analyses of creatine kinase MB, cardiac troponin I and myoglobin in pericardial and cerebrospinal fluids to investigate myocardial and skeletal muscle injury in medicolegal autopsy cases. *Legal Medicine (Tokyo)*, 13(5), pp. 226-232.
- Wang, Q., Ishikawa, T., Michiue, T., Zhu, B. L., Guan, D. W. & Maeda, H. (2012a). Evaluation of human brain damage in fatalities due to extreme environmental temperature by quantification of basic fibroblast growth factor (bFGF), glial fibrillary acidic protein (GFAP), S100beta and single-stranded DNA (ssDNA) immunoreactivities. *Forensic Science International*, doi:10.1016/j.forsciint.2012.01.015
- Wang, Q., Ishikawa, T., Michiue, T., Zhu, B. L., Guan, D. W. & Maeda, H. (2012b). Quantitative immunohistochemical analysis of human brain basic fibroblast growth factor, glial fibrillary acidic protein and single-stranded DNA expressions following traumatic brain injury. *Forensic Science International*, doi:10.1016/j.forsciint.2012.04.025.
- Williams, F. N., Herndon, D. N., Hawkins, H. K., Lee, J. O., Cox, R. A., Kulp, G. A., Finnerty, C. C., Chinkes, D. L. & Jeschke, M. G. (2009). The leading causes of death after burn injury in a single pediatric burn center. *Critical Care*, 13(6), pp. R183.
- Williams, S., Raghupathi, R., MacKinnon, M. A., McIntosh, T. K., Saatman, K. E. & Graham, D. I. (2001). In situ DNA fragmentation occurs in white matter up to 12 months after head injury in man. *Acta Neuropathologica*, 102(6), pp. 581-590.
- Yakovlev, A. G. & Faden, A. I. (2001). Caspase-dependent apoptotic pathways in CNS injury. *Molecular Neurobiology*, 24(1-3), pp. 131-144.
- Yoshida, C., Ishikawa, T., Michiue, T., Quan, L. & Maeda, H. (2011). Postmortem biochemistry and immunohistochemistry of chromogranin A as a stress marker with special regard to fatal hypothermia and hyperthermia. *International Journal of Legal Medicine*, 125(1), pp. 11-20.
- Zhang, D., Hu, X., Qian, L., O'Callaghan, J. P. & Hong, J. S. (2010). Astrogliosis in CNS pathologies: is there a role for microglia? *Molecular Neurobiology*, 41(2-3), pp. 232-241.

- Zhu, B. L., Ishida, K., Fujita, M. Q. & Maeda, H. (2000). Immunohistochemical investigation of a pulmonary surfactant in fatal mechanical asphyxia. *International Journal of Legal Medicine*, 113(5), pp. 268-271.
- Zhu, B. L., Ishida, K., Oritani, S., Quan, L., Taniguchi, M., Li, D. R., Fujita, M. Q. & Maeda, H. (2001a). Immunohistochemical investigation of pulmonary surfactant-associated protein A in fire victims. *Legal Medicine (Tokyo)*, 3(1), pp. 23-28.
- Zhu, B. L., Ishida, K., Quan, L., Taniguchi, M., Oritani, S., Kamikodai, Y., Fujita, M. Q. & Maeda, H. (2001b). Post-mortem urinary myoglobin levels with reference to the causes of death. *Forensic Science International*, 115(3), pp. 183-188.