

# We are IntechOpen, the world's leading publisher of Open Access books Built by scientists, for scientists

4,800

Open access books available

122,000

International authors and editors

135M

Downloads

Our authors are among the

154

Countries delivered to

TOP 1%

most cited scientists

12.2%

Contributors from top 500 universities



WEB OF SCIENCE™

Selection of our books indexed in the Book Citation Index  
in Web of Science™ Core Collection (BKCI)

Interested in publishing with us?  
Contact [book.department@intechopen.com](mailto:book.department@intechopen.com)

Numbers displayed above are based on latest data collected.

For more information visit [www.intechopen.com](http://www.intechopen.com)



# Interstitial Pneumonia in Dermatomyositis

Tohru Takeuchi, Takuya Kotani and Shigeki Makino

*Osaka Medical College*

*Japan*

## 1. Introduction

Dermatomyositis (DM) and polymyositis (PM) are types of autoimmune inflammatory muscle disease that mainly damage proximal limb muscles, with DM involving characteristic skin findings such as Gottron's sign and heliotrope eruption (Bohan & Peter, 1975a, 1975b). Interstitial pneumonia (IP) is often associated with DM/PM and is one of the important prognostic factors. Above all, rapidly progressive IP (RPIP), which has the worst prognosis, is resistant to corticosteroid drugs and is strongly associated with clinical amyopathic DM (CADM), which is unlikely to show myositis (Kameda & Takeuchi, 2006). In response, combination therapies of corticosteroid drugs and immunosuppressive drugs have recently been administered early in the onset of IP, and outcomes have been improved. Here, we review the pathogenesis, the clinical and laboratory findings, and treatment of IP associated with DM/PM.

## 2. IP Associated with DM/PM

IP occurs in association with DM/PM in 40-50% of patients and is an important prognostic factor of DM/PM (Hidano, 1992, Marie, 2002, Fathi, 2004). In 2002, the American Thoracic Society and the European Respiratory Society jointly advocated classifying idiopathic IP into 7 types (American Thoracic Society & European Respiratory Society, 2002), which are applied to IP associated with connective tissue disease. Many cases of IP associated with DM/PM comprise one of 3 types: nonspecific interstitial pneumonia (NSIP), cryptogenic organizing pneumonia (COP), or diffuse alveolar damage (DAD) (Douglas, 2001, Fujisawa, 2005). Prognoses vary according to these types: cases of DAD are the most critical, but some cases of NSIP and COP also progress to unfortunate outcomes. IP is classified according to clinical course into 1 of 3 groups: acute/subacute IP (A/SIP) with rapidly progression over several weeks or months, chronic IP (CIP) with slowly progression over years, and asymptomatic type with only minor abnormalities on chest CT or in respiratory function tests (Frazier & Miller, 1974).

The histological features of muscle biopsies in DM and PM are different, as are the pathological features of the IP associated with each disease. PM mainly is associated with slowly progressive CIP, which histologically presents as fibrotic NSIP and which responds to corticosteroids. A/SIP also is associated with COP or cellular NSIP and shows good response to corticosteroids in many cases. In contrast, almost 50% of DM cases are associated with A/SIP, which histologically presents as fibrotic NSIP or DAD (Hirakata &

Nagai, 2000). It often evolves into corticosteroid-resistant RPIP, often progressing to acute or subacute disease in several weeks or months, and many patients die in spite of strong immunosuppressive therapies. There are many unclear points as to how certain cases evolve into RPIP. Some cases that were identified histologically as NSIP change to DAD. In addition, pathological findings can be mixed within the same patient, and the histological picture may vary according to the site of tissue sampling.

### **3. Laboratory findings**

#### **3.1 Pulmonary function tests**

Pulmonary function tests (PFT) provide objective evaluation of respiratory symptoms and are important in determining the disease activity and therapeutic effects. However, in patients with severe respiratory failure such as that in RPIP, the tests cannot be performed or the results are not determined. Typically, a restrictive ventilatory impairment is present, and total lung capacity (TLC), vital capacity (VC), forced vital capacity (FVC), and the diffusing capacity for carbon monoxide (DLco) are decreased (Fathi, 2008). A decrease in DLco is one of the most sensitive indices showing a decrease in gas exchange. These abnormalities are improved by treatment. In cases without IP but with decreased FVC, it is necessary to also consider a decrease in ventilatory muscle strength.

#### **3.2 Diagnostic Imaging**

For imaging assessment of IP, the sensitivity of the chest X-ray is lower than that of high-resolution CT (HRCT) using less than 3-mm slices (Figure 1). When PM/DM or IP associated with PM/DM is suspected, the lung should be assessed by HRCT. However, because the chest X-ray is easy to use and radiation exposure is low, it is useful for following the course of the disease and for diagnosing complications such as infection.

HRCT findings observed in PM/DM are diverse. The most frequently observed findings are reticular opacity or ground-glass opacity with subpleural curvilinear shadow that is predominantly distributed just below the bilateral dorsal regions of the lungs, and the findings sometimes accompany consolidation (Mino, 1997, Douglas, 2001, Arakawa, 2003, Bonnefoy, 2004, Hayashi, 2008). Ground-glass opacity and consolidation are improved by treatment. The decreased lung volume and traction bronchiectasis (TBE) are sometimes observed, but patients with honeycomb lung are rare. It is difficult to predict the prognosis of IP associated with DM/PM and to select treatment based only on HRCT findings. However, HRCT are useful for the assessment of disease activity and therapeutic effect. IP that is distributed through a wide area of the lungs and accompanies TBE at the early onset or exacerbation has a poor prognosis.

#### **3.3 Biomarkers of IP**

Autoantibodies to various cell components are detected in 50 to 80% of PM/DM patients (Reichlin & Arnett, 1984, Love 1991). Myositis-specific autoantibodies such as anti-aminoacyl transfer RNA synthetase (ARS) antibody and anti-signal recognition particle (SRP) antibody are specifically detected in PM/DM, and myositis-related antigens, such as anti-Ku antibody and anti-U1-RNP antibody, are also detected in connective tissue diseases other

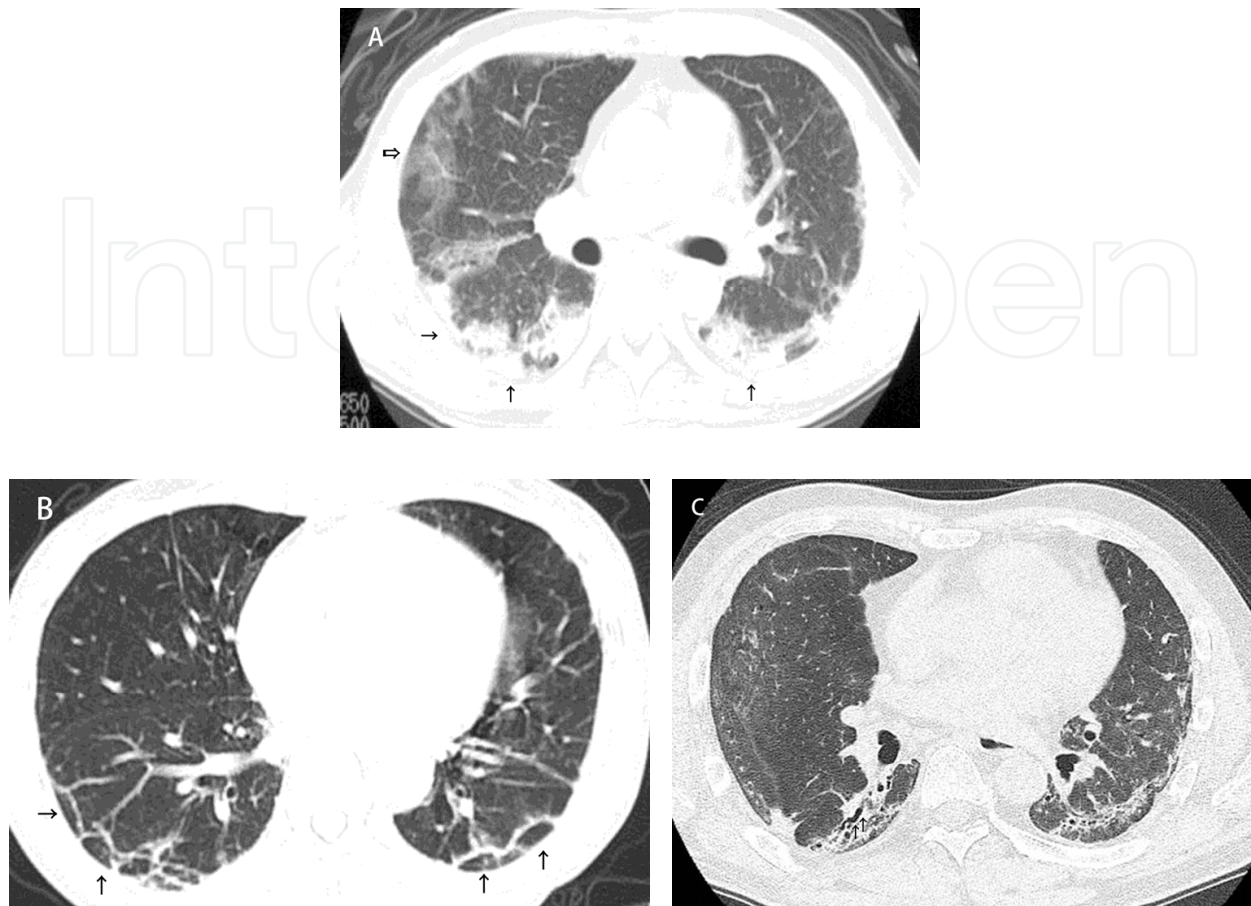


Fig. 1. Chest HRCT of IP associated with DM. (A) ground-glass opacity (open arrow) and consolidation (arrow); (B) subpleural curvilinear shadow (arrow); (C) Traction bronchiectasis.

than PM/DM. Patients from whom these autoantibodies are detected have respective clinical characteristics. Anti-ARS antibodies are detected in 25 to 30% of PM/DM patients, and of these anti-ARS antibodies, anti-Jo-1 antibody is most frequently detected and is closely related with myositis. Antibodies related to IP include anti-PL-12 antibody and anti-KS antibody (Friedman, 1996, Hirakata, 2007). Patients who test positive for anti-SRP antibody are considered to have fewer complications from IP (Targoff, 1990). Patients with CADM frequently complicate RPIP with poor prognosis and have been found to frequently test negative for antinuclear antibody. Recently, anti-CADM-140 (mda-5) antibody has been detected in the serum of patients with CADM (Sato, 2005). In the future, if a relation between this antibody and pathogenesis/clinical presentation is revealed, selection of treatment and prognosis are expected to improve.

Krebs von den Lungen-6 (KL-6) and surfactant D (SpD), which are produced and secreted on the epithelial surface by alveolar type II cells and bronchial epithelial cells, are useful markers for IP. These markers increase in the serum of patients with IP associated with PM/DM. The levels of these markers are inversely correlated with DLco and are useful in judging therapeutic effect (Kubo, 2000, Bandoh, 2000, Ihn, 2002). Not all patients with IP associated with PM/DM show increases in KL-6 and SpD, and there are patients without increased levels of KL-6 and SpD, especially in the acute phase.

Ferritin is the major molecule of iron storage, and it was reported that serum ferritin level increases in A/SIP associated with DM (Gono, 2010). Serum ferritin level is also useful as a predictive factor for onset of A/SIP and is related to its prognosis. Although it is not altogether clear why serum ferritin increases in A/SIP, it is considered to be related to activation of alveolar macrophages.

#### **4. Treatment of IP**

Therapy with massive doses of corticosteroids is used in the treatment of DM/PM-complicated IP. Although it is often effective in PM, IP associated with DM, especially in the initial treatment of RPIP, is often refractory to corticosteroid therapy. Nawata et al. reported on the prognosis of the treatment of IP in 31 cases of DM/PM using corticosteroid drugs along with pulse therapy (Nawata, 1999). The first-year survival rate after beginning the treatment was 50% in 20 patients with DM and 90% in 11 patients with PM. In addition, in all patients who died, death occurred within 12 weeks and was due to an exacerbation of IP or infection. Fujisawa et al. reported initial survival rates in 12 patients with DM and 16 patients with PM of 58% and 81%, respectively, when combining corticosteroids with an immunosuppressive agent such as cyclophosphamide (Fujisawa, 2005).

The combination of corticosteroids with immunosuppressive agents is currently the preferred method of treatment of DM/PM-complicated IP, especially in the early treatment of RPIP. Nagasawa et al. surveyed 32 facilities nationwide that specialize in the treatment of connective tissue diseases. The group analyzed clinical data from 38 patients with acute IP in DM/PM who were treated for 2 or more weeks with cyclosporine (Nagasawa, 2003). Among 25 patients who were initially treated for 2 weeks or longer using only corticosteroids following the addition of cyclosporine, the 2-year survival rate was 32%. Among the other 13 patients who were treated with cyclosporine within 2 weeks of starting corticosteroid treatment, the average survival rate 2 years later was 69%. Takada et al. reported that when comparing the results from 20 active cases of DM/PM-complicated IP, in which only additional immunosuppressive agents were added if corticosteroid alone did not result in a favorable response, with 14 additional cases in which immunosuppressive agents were combined with corticosteroids, the combination therapy led to a higher survival rate (Takada, 2007). Other clinical trials reported similar results (Yamasaki, 2007, Kotani, 2008). These reports indicate that early combined therapy is more effective than combining additional agents at a later time; as a result, this maximizes the effectiveness of the immunosuppressant.

##### **4.1 Immunosuppressants available for DM/PM-complicated IP**

Currently, positive clinical trials are going forward for the following immunosuppressive drugs used in the treatment of DM/PM-complicated IP: cyclophosphamide, cyclosporine, and tacrolimus, amongst others. It is important to introduce treatment with the immunosuppressive agent at an early stage before remodeling the lung tissues, and the dosage and the mode of administration can also greatly influence the therapeutic effect. In addition, because of possible side effects, it is necessary to monitor renal function and carefully consider the dosages and effects of possible drug combinations. Specifically,



infectious diseases are a critical side effect of each type of medicine. As reported by Kameda et al. and Kotani et al., through careful monitoring and early detection of infection, preventative treatments can be administered at an early stage leading to a decreased number of deaths due to infectious diseases (Kameda 2006, Kotani, 2008). In our facility, factors such as leukocyte count (lymphocyte count), CRP, IgG,  $\beta$ -D-glucan, CMV-C7-HRP, procalcitonin, are regularly measured, and Trimethoprim-sulfamethoxazole is administered to prevent *Pneumocystis jiroveci*.

#### 4.2 Cyclosporine

Cyclosporine is a metabolic product of fungi and a hydrophobic cyclic polypeptide. When it is incorporated into T-lymphocytes, it binds to cyclophilin to form a complex, and when this complex inhibits the activity of calcineurin, expression of cytokine genes such as IL-2 and early activation genes is down-regulated. In DM/PM-complicated IP, because involvement of T-lymphocytes has been suggested from the lung biopsy and lymphocyte subset analysis of bronchoalveolar lavage fluid, concomitant therapy with steroids and cyclosporine has been conducted and has been shown to be efficacious (Nawata, 1999, Nagasawa, 2003, Kameda, 2005, Kotani, 2008). However, these various reports indicate variability in therapeutic effect as the reported survival rates range from 42 to 78%.

Cyclosporine is likely to be affected by food and the amount of bile acid secreted, and the absorbed amount of cyclosporine varies within and between individuals. Because the therapeutic efficacy of cyclosporine depends on the concentration of the drug in the body and not on the dose, therapeutic drug monitoring (TDM) to determine the method of administration based on the concentration of the drug in the blood of individual patients has been recommended. In the treatment of DM/PM-complicated IP, cyclosporine has been administered at doses between 100 and 300 g/day (3 to 5 mg/kg/day) and at a serum trough concentration (C<sub>0</sub>) between 150 and 250 ng/mL, but there are no specific guidelines.

Recently, Nagai et al. conducted and reported on TDM in 15 IP patients complicated with DM to determine the optimal method of cyclosporine administration (Nagai, 2010). It is known from organ transplantation that the immunosuppressive effect of cyclosporine correlates best with the area under the blood concentration curve (AUC), but this is not so suitable for use in daily management because frequent blood sampling is required. Therefore, the concentration of cyclosporine in the blood was determined before and after administration to determine which concentration correlates best with the AUC. As a result, the blood concentration at 2 hours after administration (C<sub>2</sub>) was the highest among all the patients, correlated best with AUC, and was considered to be an index of immunosuppressive effect (Figure 2). However, C<sub>0</sub> did not correlate with the AUC. Moreover, when comparing between two postprandial doses and one preprandial dose, there was no difference in C<sub>2</sub>, but C<sub>0</sub> was significantly lower when cyclosporine was administered once daily breakfast (Figure 3). Because the incidence of adverse events with cyclosporine increases when cyclosporine is used for a long time at a C<sub>0</sub> of 200 ng/mL or higher (Min, 1998), the utility of the administration of one preprandial dose has been reported.

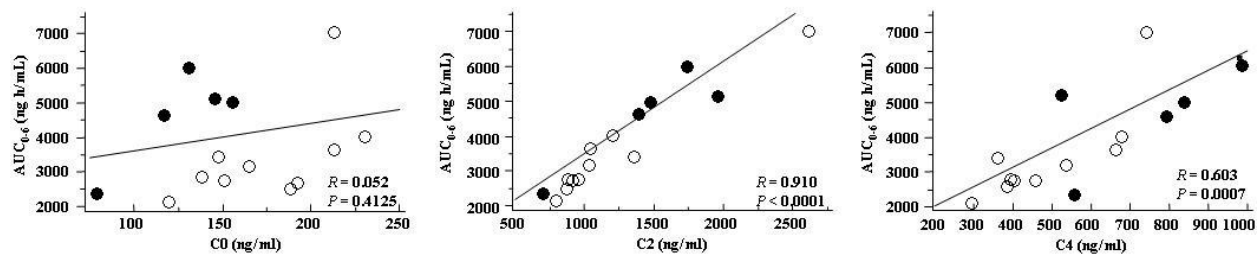


Fig. 2. Correlation of AUC0-6 with C0, C2 and C4 of cyclosporine. C0 presents the serum trough concentration. C2 and C4 present the blood concentration at 2 and 4 hours after administration, respectively. Closed and Open circles represent patients with preprandial and postprandial administration, respectively. Reproduced with permission from Nagai K, et al., Therapeutic drug monitoring of cyclosporine microemulsion in interstitial pneumonia with dermatomyositis. *Mod Rheumatol*, 2010 (21): 32-36.

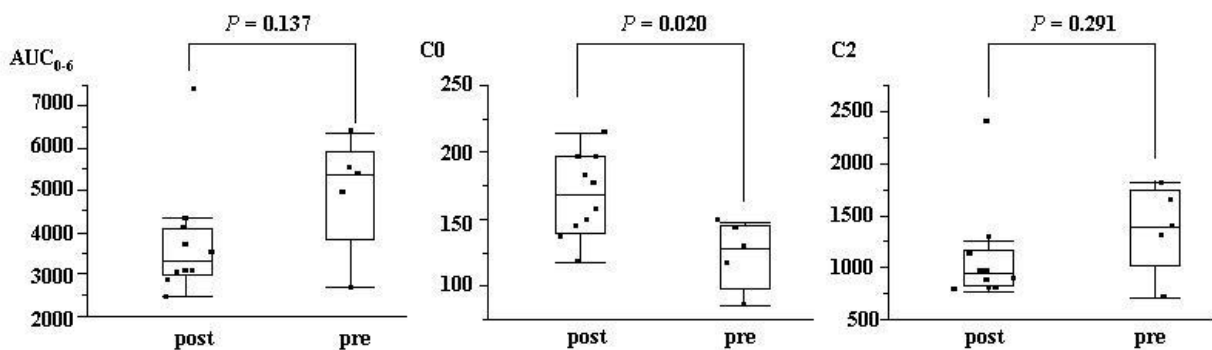


Fig. 3. Comparison of blood cyclosporine level between postprandial daily administration in two doses and preprandial, once daily administration; *Pre* preprandial, once daily before breakfast in a single dose; *Post* postprandial, twice daily in a divided dose. Reproduced with permission from Nagai K, et al., Therapeutic drug monitoring of cyclosporine microemulsion in interstitial pneumonia with dermatomyositis. *Mod Rheumatol*, 2010 (21): 32-36.

Adverse events to cyclosporine include infection as well as renal disorders, hypertension, diabetes mellitus, and hepatic disorders. Because the onset of adverse events is concentration-dependent, the dose is adjusted so that the C0 is 200 ng/mL or less, but it may be impossible to reduce the dose because of the high activity of IP. Nagai et al. reported that when the C2 was  $1222.6 \pm 523.8$  ng/mL, the C0 was  $157.3 \pm 41.4$  ng/mL (Nagai, 2010), so cyclosporine can be used relatively safely if the C2 is maintained at about 1200 ng/mL. If cyclosporine is used for a long time, however, the serum creatinine value gradually increases. Thus, monitoring of both C2 and C0 are required for the assessment of immunosuppressive effects and adverse events. Moreover, because cyclosporine is metabolized at cytochrome P450 (CYP) 3A4, concomitant use with tacrolimus, bosentan, pitavastatin, and rosuvastatin is contraindicated, and it is also necessary to pay attention to concomitant use with aminoglycoside antibiotics and amphotericin B, which have been known to induce renal disorders.

It has been reported that the immunosuppressive effect of cyclosporine reaches its maximum effects if the C2 exceeds 1000 ng/mL. The ideal dose of cyclosporine in the treatment of DM/PM-complicated IP has not been established yet. The dose is reported to be variable, which may affect its therapeutic effect. In the future, it will be necessary to evaluate not only dosage and C0 but also C2. Recently, Kotani et al. reported that the C2 of cyclosporine correlated with the HRCT findings and improvement of respiratory function instead of C0 (Kotani, 2011).

### 4.3 Tacrolimus

Tacrolimus is a metabolic product of an actinobacteria, *Streptomyces tsukubaensis*, and has a macrolide skeleton. When it is incorporated into T-lymphocytes, it forms a complex with the FK506-binding protein. As a cyclosporine, this complex shows immunosuppressive effects by inhibiting the activity of calcineurin. The activity of tacrolimus is 30- to 100-times higher than that of cyclosporine *in vitro*, and it inhibits mixed lymphocyte culture reaction, production of IL-2, expression of IL-2 receptor, and production of IFN- $\gamma$ . Clinically, tacrolimus is used for inhibition of rejection after transplantation of kidneys, liver, heart, lung and pancreas and in rheumatic diseases such as systemic lupus erythematosus, rheumatoid arthritis, Behçet's disease, and myasthenia gravis.

Oddis et al. reported the utility of tacrolimus in 8 patients with refractory PM associated with IP (Oddis, 1999). When tacrolimus was orally administered to maintain the C0 at 5 to 20 ng/mL, recovery of muscle strength was observed in all 8 patients, and among 5 patients complicated with IP, 3 showed improvement, and 1 was stabilized. Thereafter, Wilkes et al. reported 13 patients with anti-tRNA synthase antibody-positive refractory DM/PM who were treated with tacrolimus (Wilkes, 2005). It was possible to rescue all the patients, to improve respiratory function, and to reduce the dose of corticosteroids administered. Takada et al. retrospectively examined the clinical effects of tacrolimus in 5 IP patients complicated with refractory DM/PM (Takada, 2005). As a result, they reported that all 5 patients could be rescued and that in 4 patients who could be evaluated by PFT before and after treatment, the PFT values were improved.

The treatment of DM/PM-complicated IP is conducted at a tacrolimus dose of 4 to 6 mg/day and a C0 of 5 to 10 ng/mL. Tacrolimus is also likely to be affected by food, and it is known that the AUC and the maximum blood concentration (Cmax) decrease with postprandial administration. For cyclosporine, C2 monitoring is required to evaluate immunosuppressive effects, but for tacrolimus, since both the blood concentrations before and at 0 to 7 hours after administration correlate well with the AUC, it is better to monitor C0 only. (Figure 4)

The adverse events of tacrolimus are infection as well as renal disorders, hypertension, diabetes mellitus, and hyperkalemia. The onset of adverse events depends on the concentration, and if the C0 is as high as 20 ng/mL for a long time, adverse reactions increase. Similar to cyclosporine, because tacrolimus is metabolized at CYP3A4, it is necessary to pay attention to concomitant drug use. Moreover, because hyperkalemia can be observed, attention must be paid to administration of potassium-conserving diuretics such as spironolactone and eplerenone.



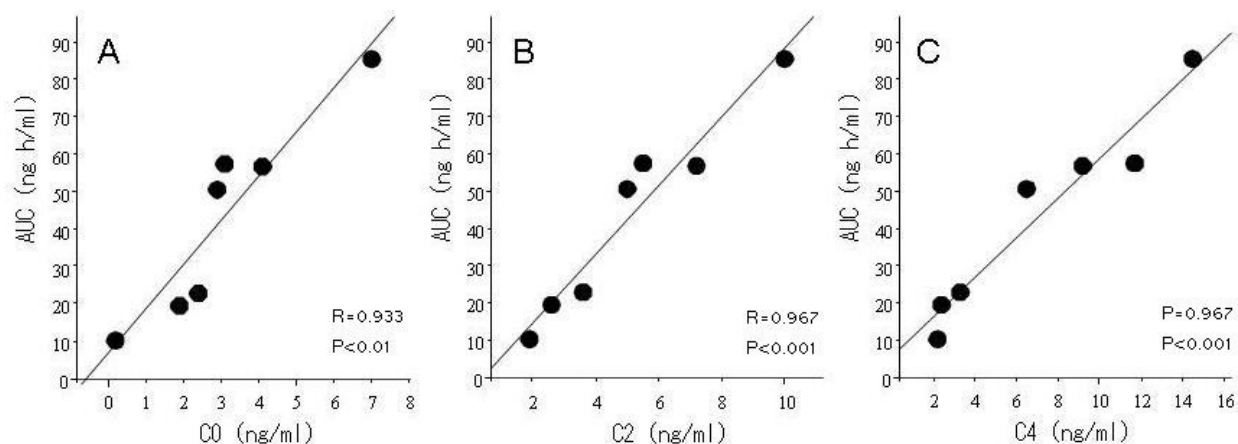


Fig. 4. Correlation of AUC<sub>0-6</sub> with C<sub>0</sub>, C<sub>2</sub> and C<sub>4</sub> of Tacrolimus. C<sub>0</sub> presents the serum trough concentration. C<sub>2</sub> and C<sub>4</sub> present the blood concentration at 2 and 4 hours after administration, respectively.

#### 4.4 Cyclophosphamide

Cyclophosphamide is an alkylating agent that is used to inhibit rejection after renal transplantation and for the treatment of malignant tumors. Cyclophosphamide itself has no alkylating effect, but many of its metabolites have activities that alkylate guanine and inhibit replication of DNA chains and transcription to mRNA. To exert their immunosuppressive effects, these metabolites inhibit differentiation and proliferation of T-cells and B-cells and suppress antigen processes of antigen-presenting cells such as macrophages.

DM/PM-complicated IP is treated by pulse intravenous infusion of cyclophosphamide (IV-CY, 500 to 2,000 mg) in combination with corticosteroids. In the initial case reports, the effects of IV-CY were variable. Yamasaki et al. administered IV-CY at doses of 300 to 800 mg/m<sup>2</sup> 6 times every 4 weeks in addition to steroids to 17 patients with DM/PM-complicated IP (Yamasaki, 2007). Dyspnea improved in 11 patients, %VC improved by 10% or more in 8 patients, and the chest CT score improved in 9 patients. Moreover, the number of days from the start of initial treatment and the rate of improvement in %VC showed a negative correlation, indicating the utility of early concomitant treatment.

Cyclophosphamide exerts strong immunosuppressive effects but is also accompanied by a number of adverse events including myelosuppression and following infections, hemorrhagic cystitis, ovarian insufficiency, azoospermia, and secondary carcinogenesis. It is therefore problematic whether cyclophosphamide may be used continuously for a long time in relapsed patients after remission induction or in patients with chronic advanced disease. It is considered useful to conduct initial treatment with concomitant use of corticosteroids and cyclophosphamide and then to switch to other immunosuppressive drugs, but this requires further evaluation. A prospective comparative study in which corticosteroids and IV-CY were administered 6 times every 4 weeks and then switched to azathioprine (2.5 mg/kg/day) was conducted in IP patients complicated with scleroderma<sup>17)</sup>, which may be helpful for the treatment of DM/PM-complicated IP.

## 5. Conclusion

There are limitations in the treatment of DM/PM-complicated IP, and particularly RRIP, with corticosteroids alone; thus, immunosuppressive drugs should be introduced early and aggressively before remodeling of the lung tissues. Many challenges remain in determining what treatment should be started for which patient, how to perform maintenance therapy, and how to switch between immunosuppressive drugs. At this time, prospective clinical studies of various immunosuppressive drugs are ongoing, and the results are eagerly anticipated.

## 6. References

- American Thoracic Society & European Respiratory Society. (2002) American Thoracic Society/ European Respiratory Society International Multidisciplinary Consensus Classification of the Idiopathic Interstitial Pneumonias. *Am J Respir Crit Care Med*, Vol. 165, No. 2, (Jan 2002), pp. 277-304, ISSN 1073-449X.
- Arakawa H, Yamada H, Kurihara Y, Nakajima Y, Takeda A, Fukushima Y, Fujioka M. (2003). Nonspecific interstitial pneumonia associated with polymyositis and dermatomyositis. *Chest*, Vol. 123, No.4, (Apr 2003), pp.1096-1103, ISSN 0012-3692.
- Bandoh S, Fujita J, Ohtsuki Y, Ueda Y, Hojo S, Tokuda M, Dobashi H, Kurata N, Yoshinouchi T, Kohno N, Takahara J. (2000). Sequential changes of KL-6 in sera of patients with interstitial pneumonia associated with polymyositis/dermatomyositis. *Ann Rheum Dis*, Vol.59, No. 4, (Apr 2000), pp.257-262, ISSN 0003-4967.
- Bohan A & Peter JB. (1975a). Polymyositis and dermatomyositis (first of two parts). *N Engl J Med*, Vol. 292, No. 7, (Feb 1975), pp. 344-347, ISSN 1533-4406.
- Bohan A & Peter JB. (1975b). Polymyositis and dermatomyositis (second of two parts). *N Engl J Med*, Vol. 292, No. 8, (Feb 1975), pp. 403-407, ISSN 1533-4406.
- Bonnefoy O, Ferreti G, Calaque O, Coulomb M, Begueret H, Beylot-Barry M, Laurent F. (2004). Serial chest CT findings in interstitial lung disease associated with polymyositis-dermatomyositis. *Eur J Radiol*, Vol. 49, No. 3, (Mar 2004), pp. 235-244, ISSN 0720-048X.
- Danko K, Ponyi A, Costantin T, Borgulya G, Szegedi G. (2004) Long-term survival of patients with idiopathic inflammatory myopathies according to clinical features: a longitudinal study of 162 cases. *Medicine (Baltimore)*, Vol. 83, No. 1, (Jan 2004), pp. 35-42, ISSN 0025-7974.
- Douglas WW, Tazellar HD, Hartman TE, Hartman RE, Decker PA, Schroeder DR, Ryu JH. (2001). Polymyositis-dermatomyositis associated interstitial lung disease. *Am J Respir Crit Care Med*, Vol. 164, No. 7, (Oct 2001), pp.1182-1185, ISSN 1073-449X.
- Fathi M, Dastmalchi M, Rasmussen E, Lundberg IE, Tornling. (2004). Interstitial lung disease, a common manifestation of newly diagnosed polymyositis and dermatomyositis. *Ann Rheum Dis*, Vol. 63, No. 3, (Mar 2004), pp. 297-301, ISSN 0003-4967
- Fathi M, Vikgren J, Boijesen M, Tylen U, Jorfeldt L, Tornling G, Lundberg IE. (2008). Interstitial lung disease in polymyositis and dermatomyositis: longitudinal evaluation by pulmonary function and radiology. *Arthritis Rheum*, Vol. 59, No. 5, (Mar 2008), pp.677-685, ISSN 0004-3591.

- Frazier AR & Miller RD. (1974). Interstitial pneumonitis in association with polymyositis and dermatomyositis. *Chest*, Vol. 65, No.4, (Apr 1974), pp. 403-407, ISSN 0012-3692.
- Friedman AW, Targoff IN, Arnett FC. (1996). Interstitial lung disease with autoantibodies against aminoacyl-tRNA synthetase in the absence of clinically apparent myositis. *Semin Arthritis Rheum*, Vol. 26, No.1, (Aug 1996), pp. 459-467, ISSN 0004-3591.
- Fujisawa T, Suda T, Nakamura Y, Enomoto N, Ide K, Toyoshima M, Uchiyama H, Tamura R, Ida M, Yagi T, Yasuda K, Genma H, Hayakawa H, Chida K, Nakamura H. (2005) Differences in clinical features and prognosis of interstitial lung disease between polymyositis and dermatomyositis. *J Rheumatol*, Vol. 32, No. 1, (Jan 2005), pp. 58-64, ISSN 0315-162X.
- Gono T, Kawaguchi Y, Hara M, Masuda I, Katsumata Y, Shinozaki M, Ota Y, Ozeki E, Yamanaka H. (2010). Increased ferritin predicts development and severity of acute interstitial lung disease as a complication of dermatomyositis. *Rheumatol (Oxford)*, Vol. 49, No. 7, (Apr 2010), pp. 1354-1360, ISSN 1462-0324.
- Hayashi S, Tanaka M, Kobayashi H, Nakazono T, Satoh T, Fukuno Y, Aragane N, Tada Y, Koarada S, Ohta A, Nagasawa K.. (2008). High-resolution computed tomography characterization of interstitial lung diseases in polymyositis/ dermatomyositis. *J Rheumatol*, Vol. 35, No.2, (Dec 2007), pp.260-269, ISSN 0315-162X.
- Hidano A, Torikai S, Uemura T, Shimizu S. (1992). Malignancy and interstitial pneumonia as fatal complications in dermatomyositis. *J Dermatol*, Vol. 19, No. 3, (Mar 1992), 153-160, ISSN 0385-2407.
- Hirakata M & Nagai S. (2000) Interstitial lung disease in polymyositis and dermatomyositis. *Curr Opin Rheumatol*, Vol. 12, No. 6, (Nov 2000), pp. 501-508, ISSN 1040-8711.
- Hirakata M, Suwa A, Takada T, Sato S, Nagai S, Genth E, Song YW, Mimori T, Targoff IN. (2007). Clinical and immunogenetic features of patients with autoantibodies to asparaginyl-transfer RNA synthetase. *Arthritis Rheum*, Vol.56, No. 4, (Apr 2007), pp. 1295-1303, ISSN 0004-3591.
- Hoyle RK, Ellis RW, Wellsbury J, Lees B, Newlands P, Goh NS, Roberts C, Desai S, Herrick AL, McHugh NJ, Foley NM, Pearson SB, Emery P, Veale DJ, Denton CP, Wells AU, Black CM, du Bois RM. (2006). A multicenter, prospective, randomized, double-blind, placebo-controlled, trial of corticosteroids and intravenous cyclophosphamide followed by oral azathioprine for the treatment of pulmonary fibrosis in scleroderma. *Arthritis Rheum*, Vol. 54, No.12, (Dec 2006), pp. 3962-3970, ISSN 0004-3591.
- Ihn H, Asano Y, Kubo M, Yamane K, Jinnin M, Yazawa N, Fujimoto M, Tamaki K.(2002). Clinical significance of serum surfactant protein D (Sp-D) in patients with polymyositis/dermatomyositis: correlation with interstitial lung disease. *Rheumatology (Oxford)*, Vol. 41, No. 11, (Nov 2002), pp.1268-1272, ISSN 1462-0324.
- Kameda H, Nagasawa H, Ogawa H, Sekiguchi N, Takei H, Tokuhira M, Amano K, Takeuchi T. (2005). Combination therapy with corticosteroids, cyclosporine A, and intravenous cyclophosphamide for acute/ subacute interstitial pneumonia in patients with dermatomyositis. *J Rheumatol*, Vol. 32, No. 9, (Sep 2005), pp. 1719-1726,ISSN 0315-162X.
- Kameda H & Takeuchi T. (2006) Recent advances in the treatment of interstitial lung disease in patients with polymyositis/dermatomyositis. *Endocr Metab Immune Disord Drug Targets*, Vol. 6, No. 4, (Dec 2006), pp. 409-415, ISSN 1871-5303.

- Kotani T, Makino S, Takeuchi T, Kagitani M, Shoda T, Hata A, Tabushi Y, Hanafusa T. (2008). Early intervention with corticosteroids and cyclosporine A and 2-hour postdose blood concentration monitoring improves the prognosis of acute/subacute interstitial pneumonia in dermatomyositis. *J Rheumatol*, Vol. 35, No. 2, (Dec 2007), pp.254-259, ISSN 0315-162X.
- Kotani T, Takeuchi T, Makino S, Hata K, Yoshida S, Nagai K, Wakura D, Shoda T, Hanafusa T. (2011). Combination with corticosteroids and cyclosporine-A improves pulmonary function test results and chest HRCT findings in dermatomyositis patients with acute/subacute interstitial pneumonia. *Clin Rheumatol*, Vol. 30, No. 8, (Aug 2011), pp.1021-1028, ISSN 0770-3198.
- Kubo M, Ihn H, Yamane K, Kikuchi K, Yazawa N, Soma Y, Tamaki K. (2000). Serum KL-6 in adult patients with polymyositis and dermatomyositis. *Rheumatology (Oxford)*, Vol. 39, No. 6, (Jan 2000), pp.632-636, ISSN 1462-0324.
- Love LA, Leff RL, Fraser DD, Targoff IN, Dalakas M, Plotz PH, Miller FW. (1991). A new approach to the classification of idiopathic inflammatory myopathy: Myositis-specific autoantibodies define useful homogeneous patient groups. *Medicine (Baltimore)*, Vol. 70, No. 6, (Nov 1991), 360-374, ISSN 0025-7974.
- Marie I, Hachulla E, Cherin P, Dominique S, Hatron PY, Hellot MF, Devulder B, Herson S, Levesque H, Courtois H. (2002). Interstitial lung disease in polymyositis and dermatomyositis. *Arthritis Rheum*, Vol. 47, No. 6, (Dec 2002), pp.614-622, ISSN 0004-3591.
- Min DI, Perry PJ, Chen HY, Hunsicker LG. (1998). Cyclosporine trough concentrations in predicting allograft rejection and renal toxicity up to 12 months after renal transplantation. *Pharmacotherapy*, Vol. 18, No. 2, (Mar 1998), pp. 282-287, ISSN 0277-0008.
- Mino M, Noma S, Taguchi Y, Tomii K, Kohri Y, Oida K. (1997). Pulmonary involvement in polymyositis and dermatomyositis: sequential evaluation with CT. *Am J Rhoentgenol*, Vol.169, No. 1, (Jul 1997), pp. 83-87, ISSN 0361-803X.
- Nagai K, Takeuchi T, Kotani T, Hata K, Yoshida S, Isoda K, Fujiki Y, Shiba H, Makino S, Hanafusa T. (2011). Therapeutic drug monitoring of cyclosporine microemulsion in interstitial pneumonia with dermatomyositis. *Mod Rheumatol*, Vol. 21, No. 1, (Jan 2011), pp. 32-36, ISSN 1439-7595.
- Nagasawa K, Harigai M, Tateishi M, Hara M, Yoshizawa Y, Koike T, Miyasaka N. (2003). Efficacy of combination treatment with cyclosporin A and corticosteroids for acute interstitial pneumonitis associated with dermatomyositis. *Mod Rheumatol*, Vol. 13, No. 3, (Sep 2003), pp. 231-238, ISSN 1439-7595.
- Nawata Y, Kurasawa K, Takabayashi, Miike S, Watanabe N, Hiraguri M, Kita Y, Kawai M, Saito Y, Iwamoto I. (1999) Corticosteroid resistant interstitial pneumonitis in dermatomyositis/ polymyositis: prediction and treatment with cyclosporine. *J Rheumatol*, Vol. 26, No. 7, (Jul 1999), pp. 1527-1533, ISSN 0315-162X.
- Oddis CV, Sciurba FC, Elmagd KA, Starzl TE. (1999). Tacrolimus in refractory polymyositis with interstitial lung disease. *Lancet*, Vol. 353, No. 9166, (May 1999), pp. 1762-1763, ISSN 0140-6736.
- Reichlin M & Arnett FC. (1984). Multiplicity of antibodies in myositis sera. *Arthritis Rheum*, Vol. 27, No. 10, (Oct 1984), pp. 1150-1156, ISSN 0004-3591.

- Sato S, Hirakata M, Kuwana M, Suwa A, Inada S, Mimori T, Nishikawa T, Oddis CV, Ikeda Y. (2005). Autoantibodies to a 140-kd polypeptide, CADM-140, in Japanese patients with clinically amyopathic dermatomyositis. *Arthritis Rheum*, Vol.52, No. 5, (May 2005), pp.1571-1576, ISSN 0004-3591.
- Tagoff IN, Johnson AE, Miller FW. (1990). Antibody to signal recognition particle in polymyositis. *Arthritis Rheum*, Vol. 33, No. 9, (Sep 1990), pp.1361-1370, ISSN 0004-3591.
- Takada K, Nagasaka K, Miyasaka N. (2005). Polymyositis / dermatomyositis and interstitial lung disease: a new therapeutic approach with T-cell-specific immunosuppressants. *Autoimmunity*, Vol. 38, No. 5, (Aug 2005), pp. 383-392, ISSN 0891-6934.
- Takada K, Kishi J, Miyasaka N. (2007). Step-up versus primary intensive approach to the treatment of interstitial pneumonia associated with dermatomyositis/ polymyositis: a retrospective study. *Mod Rheumatol*, Vol. 17, No. 2, (Apr 2007), pp. 123-130, ISSN 1439-7595.
- Wilkes MR, Sereika SM, Fertig N, Lucas MR, Oddis CV. (2005). Treatment of antisynthetase-associated interstitial lung disease with tacrolimus. *Arthritis Rheum*, Vol. 52, No. 8, (Aug 2005), pp. 2439-2446, ISSN 0004-3591.
- Yamasaki Y, Yamada H, Yamasaki M, Ohkubo M, Azuma K, Matsuoka S, Kurihara Y, Osada H, Satoh M, Ozaki S. (2007) Intravenous cyclophosphamide therapy for progressive interstitial pneumonia in patients with polymyositis/ dermatomyositis. *Rheumatol (Oxford)*, Vol. 46, No. 1, (Jun 2006), pp. 124-130, ISSN 1462-0324.



© 2012 The Author(s). Licensee IntechOpen. This is an open access article distributed under the terms of the [Creative Commons Attribution 3.0 License](#), which permits unrestricted use, distribution, and reproduction in any medium, provided the original work is properly cited.

IntechOpen

IntechOpen