

We are IntechOpen, the world's leading publisher of Open Access books Built by scientists, for scientists

4,800

Open access books available

122,000

International authors and editors

135M

Downloads

Our authors are among the

154

Countries delivered to

TOP 1%

most cited scientists

12.2%

Contributors from top 500 universities

**WEB OF SCIENCE™**Selection of our books indexed in the Book Citation Index
in Web of Science™ Core Collection (BKCI)

Interested in publishing with us?
Contact book.department@intechopen.com

Numbers displayed above are based on latest data collected.

For more information visit www.intechopen.com

Fetal Therapy: Where Do We Stand

Sebastian Illanes and Javier Caradeux

*Fetal Medicine Unit, Department of Obstetrics & Gynaecology and
Laboratory of Reproductive Biology, Universidad de los Andes
Chile*

1. Introduction

The last three decades have seen enormous scientific and technological advances, which have allowed the emergence of fetal medicine as a discipline and the possibility of fetal therapy. The development of different tools such as ultrasound, allows inspection and examination of the fetus, and a wide range of invasive procedures can be used for diagnostic and therapeutic purposes.

The value of a fetal therapy relates to the balance between benefits and risks of the in-uterus intervention, contrasted with the natural history and prognosis of each pathological condition. Several studies have shown that any problem diagnosed prenatally, usually has a worse prognosis than when the diagnosis is made postnatally. This improvement of prognosis with time relates to the gestational age at diagnosis, because of early detection of the most severe cases. It also relates to complications occurring during the pregnancy such as the emergence of associated genetic syndromes resulting in the worst prognosis cases being excluded by for example miscarriage. Therefore we should be very cautious about counselling a pregnant woman based on neonatal data and we need to adjust the prognosis given depending on the gestational age of the pregnancy.

We have classified the possible antenatal therapeutic interventions as transplacental treatment, invasive procedures, including transfusion and fetal surgery and future perspectives which we consider in an experimental stage but with clear possibilities of success.

2. Transplacental therapy: Fetal pharmacotherapy

Pharmacological therapy can be used to treat fetal disorders or improve the ability of the fetus to adapt to extra-uterine life. The transplacental route is the most commonly used way to administer drugs. However, transfer can be poor either because of the nature of the drug itself (e.g. digoxin) or if the condition requiring treatment reduces placental function (e.g. a hydropic placenta). Other approaches to drug therapy include direct fetal administration by the intra-amniotic route but these have a very limited role at present because of the invasive nature of the procedures and because very little is known regarding the effects of fetal physiology on fetal drug distribution and effects (*Koren G. 2002 - Thein AT. 1998*).

2.1 Therapies to improve the ability of the fetus to adapt to extra-uterine life

Several methods have been used to accelerate fetal maturation in fetuses at risk of preterm delivery, and the example most extensively studied and used is corticosteroids for lung maturity. Liggins was the first to describe this effect in 1969 (*Liggins GC. 1969*), and 40 years later the administration of these drugs remain the most important step to prevent respiratory distress syndrome and intraventricular haemorrhage in preterm infants (*Crowley P. 2004 – Onland W 2011*). The effect of treatment is optimal if the baby is delivered more than 24 hours and less than seven days after the start of treatment (*Crowley. 2004 – Bronwnfoot FC. 2008*). Use of repeat corticosteroid courses is at the moment under review. Some studies have shown a potential benefit of weekly repeat courses of antenatal corticosteroids in the occurrence and severity of neonatal respiratory disease but the short-term benefits are associated with a reduction in weight and head circumference, by the moment weekly repeated courses of steroids are not recommended (*Bevilacqua E. 2010 - ACOG Committee Opinion. No. 402 – RCOG Guideline No. 7*). More studies are needed to assess the long term effect of repeated steroid exposure on the developing human brain (*Bevilacqua E. 2010 - ACOG Committee Opinion. No. 402 – RCOG Guideline No. 7 – Lamer P. 2002 – Crowther CA. 2004*). Some authors have suggested a role for corticosteroids in elective term cesarean in order to reduce the higher incidence of respiratory distress presented by this group compared with vaginal term deliveries; however more studies are needed to recommend this approach (*Sotiriadis A. 2009*).

2.2 Preventative therapies

A number of modalities have been studied over the years to try to prevent fetal serious disease that can lead to fetal death or serious long-term sequel in the child. An example of this strategy is the prevention of neural tube defects (NTDs). These conditions include open spina bifida, anencephaly and encephalocele, and complicate 1 or 2 every 1000 pregnancies in the UK (*Abramsky L. 1999*), and can be prevented by the administration of folic acid during pregnancy (*MRC. 1991 - Czeizel AE. 1992*). This is the first congenital malformation to be primarily prevented by pharmacological fetal therapy (*RCOG 2003*). In 1996, the US Food and Drug Administration, initiated folic acid fortification of flour and mean folate levels in the population improved with substantial decrease in the risk of NTDs (*Koren G. 2002*), this policy have been implemented in many countries (*RCOG 2003*). Recent studies demonstrate this protective role of folate for NTDs, showing a protective effect of daily folic acid supplementation in preventing the disease (RR 0.28, 95% CI 0.15 to 0.52), with a significant protective effect for recurrence (RR 0.32, 95% CI 0.17 to 0.60) (*De-Regil LM. 2010*).

Another successful strategy is the maternal administration of IVIg and/or corticosteroids to the mother to prevent severe fetomaternal alloimmune thrombocytopenia (FMAIT). This pathology occurs when a woman becomes alloimmunised against fetal platelet antigens inherited from the father of the baby which are absent from the maternal platelets. The most common of them is anti-HPA-1 (*Kaplan C. 2002*). This condition is more frequent than is often realised since it occurs in about 1 in 1200 births (*Mueller EC. 1985 - Blanchette VS 1990 – Kaplan C. 1994*). The main complication of this disease is bleeding which may have severe consequences such as fetal intracranial haemorrhage (ICH) resulting in death or long-term disability (*Montemagno R. 1994*). Unlike red cell alloimmunisation, this disease often affects the first pregnancy, possibly due to the presence of the antigens in the trophoblast. The risk

of recurrence in subsequent pregnancies with increasing severity is very high being 50-100% depending on the zygosity of the father for the relevant antigen (*Murphy MF. 2000*). Bussel (*Bussel JB. 1996*) demonstrated that treatment with IVIg produced an increase in the platelet count of fetuses with alloimmune thrombocytopenia and observational studies have suggested an improvement in clinical outcome and reduction in the risk for intracranial haemorrhage when IVIg is administered to the mother throughout pregnancy (*Rayment R. 2005*). Maternal therapy with IVIg may result in a fetal platelet count exceeding $50 \times 10^9/l$ in 67% of pregnancies with a history of sibling affected by FMAIT (*Birchall JE. 2003*), reducing the need of FBS and transfusions avoiding the complications of this technique. Although, the optimal management of FMAIT remains unclear and further trials would be required to determine optimal treatment for this condition. (*Rayment R.2011*)

In recent years, observational studies have indicated a relationship between antenatal treatment with magnesium sulfate in preeclampsia and preterm deliveries, and a consequent decrease in cerebral palsy in preterm infants with low birth weight (*Nelson KB. 1995 - Hirtz DG. 1998*). Many randomized controlled trials have been conducted to examine this association. Recent meta-analysis conclude that the use of magnesium sulfate administered to patients at risk of preterm delivery before 34 weeks reduces the risk of cerebral palsy and gross motor dysfunction, without increase in pediatric mortality (*Costantine M. 2009 - Conde-Agudelo A. 2009 - Doyle LW. 2009*).

2.3 Therapy for fetal disease

Fetal arrhythmias are good examples of pathologies which can be treated by therapeutic fetal drug administration. Although tachycardia (fetal ventricular heart rate faster than 180 bpm.) is sometimes intermittent, the chance of hemodynamic complications and development of fetal hydrops remains high (*Yasuki M. 2009*). The indications for therapy may depend on its etiology, fetal age and disease severity (*McElhinney DB. 2010 - Strasburger JF 2010*). For intermittent tachycardia, treatment is generally unnecessary, unless hydrops or cardiac dysfunction is evident. In preterm fetuses, sustained tachycardia should probably be treated regardless of cardiac dysfunction or hydrops, because these sequelae can develop rapidly (*McElhinney DB. 2010*). When the patient presents with hydrops most arrhythmias can often be controlled with transplacental treatment, but the mortality in this group remains quite high (*Conde-Agudelo A. 2009*).

Over the years, most antiarrhythmic agents have been used to treat fetal supraventricular tachycardia (*McElhinney DB. 2010*) and most fetuses are successfully treated in utero by transplacental administration of antiarrhythmic drugs (*Yasuki M. 2009*). Digoxin is widely accepted as a first-line antiarrhythmic drug. Sotalol, flecainide and amiodarone are used as second-line drugs when digoxin fails to achieve conversion to sinus rhythm (*Yasuki M. 2009 - McElhinney DB. 2010*). For fetuses with hydrops, digoxin is rarely effective (*Yasuki M. 2009 - McElhinney DB. 2010 - Strasburger JF 2010*) because the placental transfer of the digoxin is limited. Hence, sotalol or flecainide, which have good placental transfer ability, should be used from the beginning of fetal treatment for hydrops. (*Yasuki M. 2009 - McElhinney DB. 2010 - Strasburger JF 2010*)

The safety of the mother is of great concern when managing fetal tachycardia, even after some studies didn't find any serious effects in the mother (*Simpson JM. 1998*).

Administration of antiarrhythmic drugs for intrauterine treatment may cause proarrhythmia and threaten the mother. So ECG monitoring is recommended during dosage increase (Yasuki M. 2009). However, these complications are generally tolerable and reversible (Strasburger JF 2010).

Although intrauterine treatment is very effective in fetuses with tachycardia, treatment after delivery is also very effective. Hence, decisions for which cases are treated in utero or postnatally is often difficult. So, it is important not to select postnatal treatment too quickly in premature gestation, even when the fetus has already developed hydrops (Yasuki M. 2009). Once the tachycardia is converted to sinus rhythm, the hydrops will recover and the fetus can be delivered at term by vaginal birth. However, when the hydrops continues for more than 2 weeks without conversion of tachycardia, postnatal treatment is recommended (Yasuki M. 2009).

The efficacy of prenatal treatment for fetal bradycardia (fetal ventricular heart rate is less than 100 bpm) is limited compared with treatment for fetal tachycardia. Approximately half of all cases are caused by associated congenital heart disease, and the remaining cases that have normal cardiac structure are often caused by maternal SS-A antibody (Yasuki M. 2009). Beta stimulants and steroids have been reported as effective transplacental treatments for fetal AV block (Yasuki M. 2009). But the utility of these drugs still controversial (McElhinney DB. 2010 - Strasburger JF 2010). Work is being done to develop leads and devices to improve fetal pacing (Strasburger JF 2010).

3. Invasive procedure

3.1 Transfusion therapy

3.1.1 Red cell isoimmunisation

Haemolytic disease of the fetus and newborn (HDFN) is due to maternal alloantibodies directed against paternally inherited antigens on fetal red cells and was a significant cause of fetal and neonatal morbidity and mortality until the introduction of anti-D immunoglobulin during pregnancy and shortly after delivery. However, it is still a major problem in affected pregnancies (Illanes S. 2008).

Intrauterine blood transfusion of anaemic fetuses represents one of the great successes of fetal therapy. The first approach was intraperitoneal blood transfusion introduced in 1963 by Liley (Liley AW. 1963). Subsequently Rodeck (Rodeck CH. 1981) described intravascular fetal blood transfusion (IVT) by needling of the chorionic plate or umbilical cord vessels under direct vision by fetoscopy. In 1982 Bang in Denmark (Bang J. 1982) started IVT by umbilical cord puncture under ultrasound guidance which is now widely used by an increasingly large number of centres. IVT has produced a marked improvement in survival of the anaemic hydropic fetus and can also prevent this complication from developing by treating anaemic non-hydropic fetuses where moderate or severe anaemia is detected noninvasively by Doppler ultrasonography on the basis of an increase in the peak velocity of systolic blood flow or time-averaged mean velocity in the middle cerebral artery (Mari G. 2000 - Abdel-Fattah SA. 2002).

The emphasis of current clinical management of HDFN is a non-invasive approach. This applies to the detection of fetuses at risk of HDFN with the use of cell-free fetal DNA in the

plasma of pregnant women for the determination of fetal RhD genotype which is now available as a service world-wide. In addition when a fetus is antigen positive, the follow-up of these fetuses is for the detection of moderate or severe anaemia non-invasively by Doppler ultrasonography. When anaemia is suspected, an invasive approach is required in order to perform an IVT which should only be attempted when the fetus needs transfusion. This approach reduces the iatrogenic conversion of mild to severe disease which occurred as a result of the previous management approaches and this change represents one of the genuine successes of fetal therapy (Illanes S. 2008).

3.1.2 Transient aplastic anaemia (parvovirus)

Parvovirus B19 accounts for about 25% of cases of nonimmune hydrops fetalis in anatomically normal fetuses (Hall J. 1994) as a result of fetal anaemia following tropism of B19 virus for erythroid precursor cells and the massive destruction of the infected erythroid cells and possibly myocarditis resulting in cardiac failure (Yaegashi N. 1999 - Von Kaisenberg CS. 2001). The mean gestational age of presentation of hydrops is 22 weeks but there are some reports of earlier presentation which might often be undiagnosed (Yaegashi N. 1998 - Sohan K. 2000).

Also some have suggested it may be a cause of apparently unexplained late still birth (Norbeck O. 2002). The highest risk for a fetus developing hydrops is when maternal infection is before 20 weeks gestation probably due to the rapidly increasing red cell mass and short half-life of fetal red cells (Thein AT. 1998). Diagnostic techniques aim at detecting maternal antibodies or either viral particles or DNA by PCR in maternal serum, amniotic fluid or fetal blood (Von Kaisenberg CS. 2001).

The fetal loss rate following maternal parvovirus infection is about 10% (PHLS. 1990) but this is much higher when hydrops develops, so management is by FBS for diagnosis of anaemia followed by transfusion if necessary (Soothill P. 1990). In fact, the rates of death among those who receive an intrauterine transfusion are significantly lower than among those who did not (Von Kaisenberg CS. 2001 - Fairley CK. 1995). However, consideration should be given to the high fetal loss rate in cases of hydrops after fetal blood sampling (Maxwell DJ. 1991). Fetal blood results in these cases show a negative Coomb's test, anaemia, thrombocytopenia, and low reticulocyte count (Thein AT. 1998). If the reticulocyte count is high at the first transfusion this may indicate recovery already occurring and so a second transfusion may not be necessary. Usually FBS is repeated if hydrops returns or more recently when Doppler studies suggest worsening anaemia.

In spite of some reports of hydrops due to fetal parvovirus infection resolving without treatment (Pryde PG. 1992 - Rodis JF. 1998), in our view if non-immune hydrops presents without obvious fetal malformations and anaemia is expected from the Doppler results, even if the mother does not give a clear history of parvovirus exposure, FBS should still be done urgently without waiting for maternal confirmatory tests and intra-uterine transfusion be done if there is evidence of severe fetal anaemia.

In contrast with other causes of fetal anaemia and hydrops, fetal complications caused by hPV B19 have the potential to resolve as the fetus mounts its own immune response (Lamont R. 2011). So if other signs of fetal well-being are present, it might be possible to continue with conservative measurements (Lamont R. 2011).

3.2 Amniotic fluid management

Amniotic fluid surrounds the fetus in intrauterine life providing a protected, low-resistance space suitable for fetal movements, growth and development. Disturbance of the balance between amniotic fluid production and consumption leads to oligo- or polyhydramnios, both of which are associated with poor perinatal outcome related to the degree of fluid volume change (Chamberlain PF. 1984).

Severe polyhydroamnios can cause maternal abdominal discomfort, respiratory embarrassment and preterm delivery (Kyle PM. 1997 - Phelan JP. 1990). Amniotic fluid reduction can relieve maternal symptoms with severe polyhydramnios and prolong the gestation in both singleton and multiple pregnancies and is one of the possible treatments for TTTS (Kyle PM. 1997 - Wee LY. 2002). Abruptio can be a complication of removal of large volumes of amniotic fluid and this risk has been estimated at about 3-4% (Leung WC. 2004). Common criteria for amniotic fluid drainage are AFI > 40 cm or the deepest single pool of >12 cm but many prefer to make the decision mostly on maternal discomfort (Thein AT. 1998). Removal of a small volume can rapidly reduce amniotic fluid pressure but it usually re-accumulates quickly and approximately 1 litre needs to be removed for every 10cm the AFI is elevated (Kyle PM. 1997 - Abdel-Fattah SA. 1999). The procedure often has to be repeated in order to prolong gestational age until maturity allows delivery. The insertion of a tube to achieve chronic long-term drainage has been tried in the past but there is a high risk of infection and no evidence supporting this approach.

Oligohydramnios is found in 3-5% of pregnancies in the third trimester, but severe cases relating to impaired outcome are less common (Kyle PM. 1997). The significance of this finding relates mostly to the underlying cause, so the prognosis and the possibility of treatment depends on the aetiology. Attempts at therapy focus on restoring the amniotic fluid to allow continue development of the lungs during the canalicular phase. Quintero et al (Quintero RA. 1999) described effective resealing in cases of iatrogenic previable PPRM by intra-amniotic injection of platelets and cryoprecipitate although this approach has not been reported to work after spontaneous membrane rupture. Some reports have also shown that in pregnancies with preterm premature rupture of membranes (PPROM) with oligohydramnios at <26 weeks' gestation, serial amnioinfusions improve the perinatal outcome when compared to those with persistent oligohydramnios (Locatelli A. 2000 - De Santis M. 2003). Fisk et al have recently described an amnioinfusion test procedure to try and pre-select cases of midtrimester PPRM which may benefit from serial amnioinfusion. A quarter of patients who retained infused fluid went on to subsequent serial amnioinfusion and prolongation of pregnancy with decrease in the risk of pulmonary hypoplasia (Tan LK. 2003). However, there are risks of procedure related complications such as chorioamnionitis, placental abruption and extreme prematurity, so ideally a large series in a prospectively randomised trial would be needed to assess the benefits.

Amnioinfusion has also been used to prevent or relieve variable decelerations from umbilical cord compression in cases of rupture of membranes and to dilute meconium when present in the amniotic fluid and so reduce the risk of meconium aspiration during labour. A Cochrane review found that amnioinfusion for oligohydramnios helps when the baby shows signs of distress. If the baby shows no signs of distress from oligohydramnios, then amnioinfusion is not helpful. So there is no role for prophylactic amnioinfusion (Novikova N. 1996). Another studies shows improvements in perinatal outcome when it is used to dilute

meconium, only in settings where facilities for perinatal surveillance are limited (*Xu H. 2007 - Hofmeyr GJ. 2010*).

3.3 Shunting

3.3.1 Pleuro-amniotic shunting

A pleural effusion may be an isolated finding or may occur in association with hydrops fetalis. When severe, this condition can produce hydrops, pulmonary hypoplasia by lung compression and polyhydramnios with secondary risks of preterm delivery (*Phelan JP. 1990*). When due to a reversible cause such as chylothorax, the treatment of this condition by pleuro-amniotic shunting can be a very effective method (*Sohan K. 2001*) and can reverse the complications and prevent death. However, drainage does not help cases in which the pleural effusion is caused by an underlying progressive disease, or when the effusions are mild and so will not produce secondary effects or when the problem is diagnosed so late that pulmonary hypoplasia has already occurred and is irreversible.

When making the difficult decision of whether or not to shunt, the risks of thoracoamniotic shunting must be considered. The recommendation is that large pleural effusions, especially those with hydropic changes, should be seen urgently in a center that can offer tertiary level ultrasound examination, aspiration and shunting because, with appropriate treatment, 50% of fetuses survive (*Smith RP. 2005*). Recently Yinon et al. conducted a retrospective study of 88 fetuses with large pleural effusions who underwent pleuroamniotic shunting, to evaluate perinatal outcome associated to the procedure. They concluded that carefully selected fetuses with primary pleural effusions can benefit from pleuroamniotic shunting, allowing hydrops to resolve with a survival rate of almost 60% (*Yinon Y. 2010*).

Another approach for management of fetal chylothorax that is under evaluation is the use of pleurodesis with OK-432. First case-reports about its utility were published in 2001 revealing rapid and effective control of pleural effusion (*Tanemura M. 2001 - Okawa T 2001*). A posterior review conducted by Chen et al. pooled a total of 9 cases, concluding that the success of the procedure depends on the complete aspiration of the pleural cavity and the demonstration of adhesions by ultrasonography following the procedure (*Chen M. 2005*). A recent report published last year, that included a total of 45 cases show that this treatment is only useful in those cases without hydrops, converting the use of OK-432 pleurodesis in a plausible alternative to the classic management with thoracoamniotic shunting (*Yang YS. 2011*).

3.3.2 Vesico-amniotic shunting

Lower urinary tract obstruction has a significant impact on perinatal morbidity and mortality, related principally to pulmonary hypoplasia and renal impairment that produce at least a 40% of mortality (*Nakayama DK. 1986 - Freedman AL. 1996*). Animal models of releasing obstruction have been very successful but these models are often different from human congenital urinary tract obstruction (*Agarwal SK. 2001*). The insertion of a double pig-tailed vesico-amniotic catheter is the most commonly used method to relieve this obstruction in vivo but complications are quite common, including failure of drainage or migration of the shunt, premature labour, urinary ascites, chorioamnionitis and iatrogenic gastroschisis (*Coplen DE. 1997*). The main concern about vesico-amniotic shunting is that by the time severe obstructive uropathy is detected, renal function may be already severely and

irreversibly damaged (*Freedman AL. 1996*). Needle drainage has been used to obtain an assessment of renal function and helping to identifying fetuses with potential to benefit from in utero surgical intervention (*Agarwal SK. 2001*). Sometimes needle aspiration can appear to be therapeutic for megacystis in very early in the second trimester perhaps as a result of releasing urethral oedema secondary to pressure (*Carroll SG. 2001*).

Recent data about antenatal bladder drainage appears to improve perinatal survival in cases of congenital lower urinary tract obstruction, but may confer a high residual risk of poor postnatal renal function, based on observational studies (*Morris RK. 2010*). Currently, a clinical trial (PLUTO trial) comparing conservative management to vesicoamniotic shunting in singleton fetuses below 28 weeks gestation with isolated bladder outflow obstruction is at development (*PLUTO trial. 2007*).

3.4 Laser treatment

Monochorionic (MC) twins account for 20% of spontaneous twin pregnancies and almost 5% occur as a result of medically assisted reproduction (*Chalouhi GE. 2011*). Twin-twin transfusion syndrome (TTTS) affects 10% to 15% of monozygous twin pregnancies with monochorionic placentation (*Chalouhi GE. 2011 - Sebire NJ. 1997 - Carroll SG. 2002*).

Without treatment, there is a very high risk of perinatal mortality and perinatal morbidity due to preterm delivery but also as a result of acquired brain injury in utero (*Denbow ML. 1998*). When TTTS is of early onset, the prognosis is even worse and interruption of the vascular anastomosis by fetoscopic laser ablation is a sensible treatment that has been used since the beginning of the 1990s (*De Lia JE 1990*). TTTS management has encompassed non-specific, sometimes symptomatic, treatments including amnioreduction, septostomy and even expectant management. To date, the only treatment addressing the pathophysiology of the syndrome is fetoscopic selective laser coagulation of placental vessels (SLCPV) (*Chalouhi GE. 2011*).

With this treatment, in a third of pregnancies both twins survive, in another third one twin survives and in the remaining third both twins die (*Ville Y. 1995*). The recently published Eurofetus study showed that laser therapy is associated with improved perinatal outcome compared with amnioreduction in women presenting with TTTS before 26 weeks' gestation (*Senat MV. 2004*). To improve these results we need better ways of identifying all arterial-venous (A-V) anastomoses before ablation, which will enable a true rendering into a DC placenta with minimal destruction of viable placental territory. There have been some attempts of delineating placental vascular anatomy in utero with contrast agents and power Doppler but without clear success (*Denbow ML. 2000*).

Laser ablation has also been used successfully to treat acardiac twin pregnancies that complicate 1% of monozygous twin pregnancies with monochorionic placentation (*Moore TR. 1990*) and are associated with congestive cardiac failure in the pump twin leading to polyhydramnios and preterm delivery with a reported perinatal mortality in untreated cases as high as 55% (*Tan TY. 2003*). Laser or diathermy ablation is used to occlude the cord or the pelvic vessels within the abdomen of the acardiac twin (*Rodeck C. 1998 - Soothill P. 2002*). A recent review suggests that intrafetal ablation is the treatment of choice for acardiac twins because it is simpler, safer and more effective when compared with the cord occlusion techniques (*Soothill P. 2002*).

3.5 Fetoscopic / Open fetal surgery

Although most malformations diagnosed prenatally are best managed after birth, a few severe ones may be better treated before birth. The fetal malformations that warrant consideration for open surgical correction in uterus are those that interfere with normal growth, development and are life-threatening, so that correction of the defect may prevent these effects. At present, only a few malformations have been successfully corrected, including fetal myelomeningocele (MMC) and congenital diaphragmatic hernia (CDH).

3.5.1 Hydrocephaly and neural tube defects

Fetal MMC can produce (Johnson MP. 2003) obstructive hydrocephalus in up to 85% of cases requiring ventriculoperitoneal shunting. MMC can have other long term sequelae such as motor impairment of the legs and loss of bowel and bladder control. The damage may be due to the defect in the bony spinal column exposing the spinal cord to the trauma from the amniotic fluid and the uterine environment (Evans MI. 2002) raising the possibility of covering the spinal cord in the uterus to avoid the damage. The accumulated experience with fetal MMC repair has been encouraging and suggests a decreased need for ventriculoperitoneal shunting, arrest or slowing of progressive ventriculomegaly, and consistent resolution of hindbrain herniation in the short term follow up (Johnson MP. 2003). However, further long-term follow-up is needed to evaluate neurodevelopment and bladder and bowel function. Since 2003 the MOMS trial is recruiting patients to assess the better management for these cases. So most centres still await for result before recommend the clinical intervention (Luks FI. 2011).

3.5.2 Congenital diaphragmatic hernia

Congenital diaphragmatic hernia has a high mortality rate, and many clinical and experimental efforts have been made in order to reduce it. Open fetal repair of the diaphragmatic defect was attempted but with an unacceptable high mortality rate and so has been abandoned (Evans MI. 2002). Fetoscopic temporary tracheal occlusion, have emerge as an alternative to open fetal surgery on the basis that the accumulation of lung fluid secretions can expand the lungs and so reduce the herniated viscera and avoid pulmonary hypoplasia. This approach may improve lung growth and development (Sydorak RM. 2003); however, complications related to tracheal dissection, premature delivery and late morbidity are significant (Deprest J. 2004). New techniques have been proven in experimental stage with less invasive approach but most studies have felt to prove any improvement of survival or morbidity rates when compared intrauterine fetal endoscopic tracheal occlusion approach with optimal postnatal care. However, there is a small group of extremely severe cases that could benefit from prenatal intervention (Luks FI. 2011).

The exact definition of this subgroup of patients is still being debated. In 2003 Harrison *et al.* Correlated survival rates with lung-to-head ratio (LHR). Using this ratio good prognosis (100% survival) was associated with an LHR > 1.4. Poor prognosis (less than 30% survival) was associated with an LHR < 1.0 (Harrison MR. 2003).

Actually, a RCT of Luks *et al.* is recruiting patients to evaluate the benefits of fetal tracheal occlusion with a detachable balloon for an LHR < 0.9 (Luks FI. 2008).

4. Interventions in experimental stages

4.1 Ablation of tumours

Some tumours may grow to massive proportion in uterus, inducing high-output failure leading to fetal hydrops that end most uniformly in fetal demise. Fetal sacrococcygeal teratoma is a good example of this and surgery may have a role before the onset of hydrops in order to avoid this complication or after in order to resolve it (*Luks FI. 2011*). Ablation of the majority of the tumour tissue is not usually necessary and perhaps only ligation or coagulation of the vascular steal can reverse or avoid the high-output fetal heart failure (*Paek BW. 2001*). Open fetal surgery with a high incidence of technique related complications has been moving to less invasive approach such as radiofrequency ablation and fetoscopic resection (*Hirose S. 2003*) but more studies are needed to assess the impact of these types of managements and what groups of fetus benefit from them. With cervical teratomas another possibility for tracheal obstruction can be the EXIT procedure where the fetus is partially delivered, maintaining the uteroplacental circulation in order to perform the surgery and achieve adequate ventilation (*Murphy DJ. 2001*).

4.2 Stem cell transplantation

At the present time, the most likely and eminent application of stem cell therapy to the fetus is in utero hematopoietic stem cell transplantation (*Matthew T. 2009*). Bone marrow transplantation of normal haematopoietic stem cells can sustain normal haemopoiesis and be an alternative in treatment of lethal haematological disease. In the case of congenital disease like haemoglobinopathies, immunodeficiency disorders and inborn errors of metabolism that can be diagnosed prenatally and cured or improved by the engraftment of normal stem cells are theoretically an attractive alternative for the in utero transplantation of stem cells (*Evans MI. 2002*). The unique characteristic of the hematologic and immunologic system in the human fetus, could circumvent the postnatal problems of transplantation, such as graft-versus-host disease, and the remarkable ability of stem cells to proliferate, differentiate and become tolerant to host antigens are encouraging. However, most research on stem cell therapy to date has focused on disorders of old age that are not genetic. So, very little is known about the disorders that can occur in utero and how stem cells might be of benefit (*Mummery C. 2011*). Finally, there is a small amount of evidence about safety and effectiveness in animals for transfer of treatment to fetuses at the present time (*Mummery C. 2011*).

4.3 Gene therapy

The goal of gene therapy is to treat disease before damage secondary to the gene pathology is produced. Fetal gene therapy for many disorders already has been demonstrated in rodent and large animal models (*Matthew T. 2009*). Some reports show that using a percutaneous ultrasound-guided injection of gene transfers in the airway or in the amniotic cavity in animal, provided levels of gene expression in lung and intestine that could be relevant for a therapeutic application (*David A. 2003 - Garrett DJ. 2003*). In spite of the large amount of experimentation already made in this field, today we are still unsure whether or not this technique will provide the desired therapeutic effect and whether expression of the transferred genes will provide real clinical benefit (*Matthew T. 2009*). Safety concerns need to

be investigated extensively in appropriate preclinical animal models before application in humans. The ethics of fetal gene therapy also need to be considered.

5. Conclusions

Much has been achieved in the prevention, diagnosis and management of fetal pathology. This has allowed the development of interventions that have proven to be beneficial and safe for both fetus and mother. However, much remains to be investigated. The rapid progress in molecular and genetic research continues to be promising. However, the ethical and moral implications associated constitute a very important point that should not be omitted.

This article is a review of the evidence available at the time of publication and at no stage intended to be the basis for decision making and behaviours in particular cases, were different variables have to be pondered that exceed the scope of this chapter. It is the duty of the specialists to inform their patients and taking into account all the edges and risk for each management.

6. References

- Abdel-Fattah SA, Carroll SG, Kyle PM, Soothill PW. *Amnioreduction: how much to drain?* Fetal Diagn Ther. 1999 Sep-Oct; 14(5): 279-82
- Abdel-Fattah SA, Soothill PW, Carroll SG, Kyle PM. Middle cerebral artery Doppler for the prediction of fetal anaemia in cases without hydrops: a practical approach. Br J Radiol. 2002 Sep; 75 (897):726-30.
- Abramsky L, Botting B, Chapple J, Stone D. *Has advice on periconceptional folate supplementation reduced neural-tube defects?* Lancet 1999;354:998-9.
- Agarwal SK, Fisk NM. *In utero therapy for lower urinary tract obstruction.* Prenat Diagn. 2001 Nov;21(11):970-6.
- Agustín Conde-Agudelo, MD, MPH; Roberto Romero, MD. *Antenatal magnesium sulfate for the prevention of cerebral palsy in preterm infants less than 34 weeks' gestation: a systematic review and metaanalysis.* American Journal of Obstetrics & Gynecology 2009 JUNE; 595-609
- American College of Obstetricians and Gynecologists. Committee on Obstetric Practice. *ACOG Committee Opinion. No. 402: Antenatal corticosteroid therapy for fetal maturation.* Obstet Gynecol 2008;111:805-7.
- Bang J, Bock JE, Trolle D Ultrasound guided fetal intravenous transfusion for severe rehus haemolytic disease. BMJ 1982; 284: 373-374.
- Bevilacqua E, Brunelli R, Anceschi MM. *Review and meta-analysis: Benefits and risks of multiple courses of antenatal corticosteroids.* J Matern Fetal Neonatal Med. 2010 Apr;23(4):244-60
- Birchall JE, Murphy MF, Kaplan C, Kroll H; European Fetomaternal Alloimmune Thrombocytopenia Study Group. *European collaborative study of the antenatal management of feto-maternal alloimmune thrombocytopenia.* Br J Haematol. 2003 Jul; 122(2): 275-88.

- Blanchette VS, Chen L, de Friedberg ZS, Hogan VA, Trudel E, Decary F. *Alloimmunization to the PLA1 platelet antigen: results of a prospective study*. British Journal of Haematology 1990; 74:209-15.
- Brownfoot FC, Crowther CA, Middleton P. *Different corticosteroids and regimens for accelerating fetal lung maturation for women at risk of preterm birth*. Cochrane Database Syst Rev. 2008 Oct 8;(4):CD006764.
- J. B. Bussel, R. L. Berkowitz, L. Lynch, M. L. Lesser, M. J. Paidas, C. L. Huang and J. G. McFarland. *Antenatal management of alloimmune thrombocytopenia with intravenous gamma-globulin: a randomized trial of the addition of low-dose steroid to intravenous gamma-globulin*. Am J Obstet Gynecol 174 1996, pp. 1414-1423.
- Carroll SG, Soothill PW, Abdel-Fattah SA, Porter H, Montague I, Kyle PM. *Prediction of chorionicity in twin pregnancies at 10-14 weeks of gestation*. BJOG. 2002 Feb; 109(2):182-6.
- Carroll SG, Soothill PW, Tizard J, Kyle PM. *Vesicocentesis at 10-14 weeks of gestation for treatment of fetal megacystis*. Ultrasound Obstet Gynecol. 2001 Oct;18(4):366-70.
- Chamberlain PF, Manning FA, Morrison I, Harman CR, Lange IR. *Ultrasound evaluation of amniotic fluid volume. I. The relationship of marginal and decreased amniotic fluid volumes to perinatal outcome*. Am J Obstet Gynecol. 1984 Oct 1; 150(3): 245-9.
- Chamberlain PF, Manning FA, Morrison I, Harman CR, Lange IR. *Ultrasound evaluation of amniotic fluid volume. II. The relationship of increased amniotic fluid volume to perinatal outcome*. Am J Obstet Gynecol. 1984 Oct 1; 150(3): 250-4.
- Coplen DE. *Prenatal intervention for hydronephrosis*. J Urol. 1997 Jun; 157(6):2270-7.
- Costantine MM, Weiner SJ; Eunice Kennedy Shriver. *Effects of antenatal exposure to magnesium sulfate on neuroprotection and mortality in preterm infants: a meta-analysis*. National Institute of Child Health and Human Development Maternal-Fetal Medicine Units Network. Obstet Gynecol. 2009 Aug;114(2 Pt 1):354-64.
- Crowley P. *Prophylactic corticosteroids for preterm birth (Cochrane Review)*. In: *The Cochrane Library*, Issue 1, 2004.
- Crowther CA, Alfirevic Z, Haslam RR. *Prenatal thyrotropin-releasing hormone for preterm birth (Cochrane Review)*. In: *The Cochrane Library*, Issue 1, 2004.
- Czeizel AE, Dudas I. *Prevention of the first occurrence of neural-tube defects by periconceptional vitamin supplementation*. N Engl J Med 1992;327:1832-5.
- Christine Mummery, Magnus Westgren² and Karen Sermon. *“Current controversies in prenatal diagnosis 1: is stem cell therapy ready for human fetuses?”* Prenat Diagn 2011; 31: 228-230.
- David A, Cook T, Waddington S, Peebles D, Nivsarkar M, Knapton H, Miah M, Dahse T, Noakes D, Schneider H, Rodeck C, Coutelle C, Themis M. *Ultrasound-guided percutaneous delivery of adenoviral vectors encoding the beta-galactosidase and human factor IX genes to early gestation fetal sheep in utero*. Hum Gene Ther. 2003 Mar 1; 14(4):353-64.
- De-Regil LM, Fernández-Gaxiola AC, Dowswell T, Peña-Rosas JP. *Effects and safety of periconceptional folate supplementation for preventing birth defects*. Cochrane Database Syst Rev. 2010 Oct 6;(10):CD007950.

- Deprest J, Gratacos E, Nicolaides KH; FETO Task Group. *Fetoscopic tracheal occlusion (FETO) for severe congenital diaphragmatic hernia: evolution of a technique and preliminary results*. *Ultrasound Obstet Gynecol*. 2004 Aug; 24(2):121-6
- Denbow ML, Eckersley R, Welsh AW, Taylor MJ, Carter RC, Cosgrove DO, Fisk NM. *Ex vivo delineation of placental angioarchitecture with the microbubble contrast agent Levovist*. *Am J Obstet Gynecol*. 2000 Apr; 182(4):966-71.
- Denbow ML, Battin MR, Cowan F, Assopardi D, Edwards AD, Fisk NM. *Neonatal cranial ultrasonographic findings in preterm twins complicated by severe fetofetal transfusion syndrome*. *Am Obstet Gynecol* 1998; 178:479-83.
- De Lia JE, Cruikshank DP, Keye WR (1990) *Fetoscopic neodymium:YAG laser occlusion of placental vessels in severe twin-twin transfusion syndrome*. *Obstet Gynaecol* 75:1046-1053.
- De Santis M, Scavo M, Noia G, Masini L, Piersigilli F, Romagnoli C, Caruso A. *Transabdominal amnioinfusion treatment of severe oligohydramnios in preterm premature rupture of membranes at less than 26 gestational weeks*. *Fetal Diagn Ther*. 2003 Nov-Dec; 18(6): 412-7.
- Doyle LW, Crowther CA, Middleton P, Marret S. *Antenatal magnesium sulfate and neurologic outcome in preterm infants: a systematic review*. *Obstet Gynecol*. 2009 Jun;113(6):1327-33
- Evans MI, Harrison MR, Flake AW, Johnson MP. *Fetal therapy*. *Best Pract Res Clin Obstet Gynaecol*. 2002 Oct; 16(5):671-83.
- Fairley CK, Smoleniec JS, Caul OE, Miller E. *Observational study of effect of intrauterine transfusions on outcome of fetal hydrops after parvovirus B19 infection*. *Lancet*. 1995 Nov 18; 346(8986): 1335-7.
- Freedman AL, Bukowski TP, Smith CA, Evans MI, Johnson MP, Gonzales R. 1996. *Fetal therapy for obstructive uropathy: specific outcome diagnosis*. *J Urol* 156: 720.
- Garrett DJ, Larson JE, Dunn D, Marrero L, Cohen JC. *In utero recombinant adeno-associated virus gene transfer in mice, rats, and primates*. *BMC Biotechnol*. 2003 Sep 30; 3(1):16.
- G. E. Chalouhi, M. Essaoui, J. Stirnemann, T. Quibel, B. Deloison, L. Salomon and Y. Ville. *Laser therapy for twin-to-twin transfusion syndrome (TTTS) Review*. *Prenat Diagn* 2011; 31: 637-646.
- Hall J. *Parvovirus B19 infection in pregnancy*. *Arch Dis Child Fetal Neonatal Ed* 1994; 71: F4-5
- Harrison MR, Keller RL, Hawgood SB, Kitterman JA, Sandberg PL, Farmer DL, Lee H, Filly RA, Farrell JA, Albanese CT. *A randomized trial of fetal endoscopic tracheal occlusion for severe fetal congenital diaphragmatic hernia*. *N Engl J Med*. 2003 Nov 13;349(20):1916-24.
- Hirose S, Farmer DL. *Fetal surgery for sacrococcygeal teratoma*. *Clin Perinatol*. 2003 Sep; 30(3):493-506.
- Hirtz DG, Nelson KN. *Magnesium sulfate and cerebral palsy in premature infants*. *Curr Opin Pediatr* 1998;10:131-7.
- Hofmeyr GJ, Xu H. *Amnioinfusion for meconium-stained liquor in labour*. *Cochrane Database Syst Rev*. 2010 Jan 20;(1):CD000014.

- S. Illanes, P. Soothill. *Current aspects of the clinical management of haemolytic disease of the newborn and fetus*. Hematology Education: the education program for the annual congress of the European Hematology Association 2008; 2:175-178
- Johnson MP, Sutton LN, Rintoul N, Crombleholme TM, Flake AW, Howell LJ, Hedrick HL, Wilson RD, Adzick NS. *Fetal myelomeningocele repair: short-term clinical outcomes*. Am J Obstet Gynecol. 2003 Aug;189(2):482-7
- Kaplan C. *Alloimmune thrombocytopenia of the fetus and neonate: prospective antenatal screening*. In: Third European Symposium on Platelet and Granulocyte Immunobiology. Cambridge, UK, 1994.
- Kaplan C. *Alloimmune thrombocytopenia of the fetus and the newborn*. Blood Rev. 2002 Mar; 16(1): 69-72.
- Koren G, Klinger G, Ohlsson A. *Fetal pharmacotherapy*. Drugs. 2002; 62(5):757-73.
- Kyle PM, Fisk NM (1997) *Oligohydramnios and polyhydramnios*. In: Fisk NM, Moise KJ Jr (eds) Fetal therapy, invasive and transplacental. Cambridge University Press, Cambridge, pp 203–217
- Lamer P. *Current controversies surrounding the use of repeated courses of antenatal steroids*. Adv Neonatal Care. 2002 Dec;2(6):290-300
- Lamont R, Sobel J, Vaisbuch E, Kusanovic J, Mazaki-Tovi S, Kim S, Uldbjerg N, Romero R. *Parvovirus B19 infection in human pregnancy*. BJOG 2011;118:175–186.
- Leung WC, Jouannic JM, Hyett J, Rodeck C, Jauniaux E. *Procedure-related complications of rapid amniodrainage in the treatment of polyhydramnios*. Ultrasound Obstet Gynecol. 2004 Feb;23(2):154-8
- Liggins GC. *Premature delivery of fetal lambs infused with glucocorticoids*. J Endocrinol 1969; 45: 515-23.
- Liley AW *Intrauterine transfusion of fetus in haemolytic disease*. BMJ II 1963: 1107–1109.
- Locatelli A, Vergani P, Di Pirro G, Doria V, Biffi A, Ghidini A. *Role of amnioinfusion in the management of premature rupture of the membranes at <26 weeks' gestation*. Am J Obstet Gynecol. 2000 Oct; 183(4): 878-82.
- Luks FI. *New and/or improved aspects of fetal surgery*. Prenat Diagn. 2011 Mar;31(3):252-8. doi: 10.1002/pd.2706. Epub 2011 Feb 4.
- Luks FI. 2008. *Fetal tracheal balloon study in diaphragmatic hernia*. <http://clinicaltrials.gov/ct2/show/NCT00966823?term=luks&rank=1>
- Mari G, Deter RL, Carpenter RL, Rahman F, Zimmerman R, Moise KJ Jr, Dorman KF, Ludomirsky A, Gonzalez R, Gomez R, Oz U, Detti L, Copel JA, Bahado-Singh R, Berry S, Martinez-Poyer J, Blackwell SC. *Noninvasive diagnosis by Doppler ultrasonography of fetal anemia due to maternal red-cell alloimmunization*. Collaborative Group for Doppler Assessment of the Blood Velocity in Anemic Fetuses. N Engl J Med. 2000 Jan 6; 342 (1):9-14.
- Matthew T. Santore, Jessica L. Roybal, Alan W. Flake. *Prenatal Stem Cell Transplantation and Gene Therapy*. Clin Perinatol 36 (2009) 451–471
- Maxwell DJ, Johnson P, Hurley P, Neales K, Allan L, Knott P. *Fetal blood sampling and pregnancy loss in relation to indication*. Br J Obstet Gynaecol. 1991 Sep; 98(9): 892-7.
- McElhinney DB, Tworetzky W, Lock JE. *Current status of fetal cardiac intervention*. Circulation. 2010 Mar 16;121(10):1256-63.

- M. Chen, J.C. Schin, B.T. Wang, C.P. Chen and C.L. Yu. *Fetal OK-432 pleurodesis: complete or incomplete?*. Letters to the Editor. *Ultrasound Obstet Gynecol* 2005; 26: 789–796
- Montemagno R, Soothill PW, Scarcelli M, O'Brien P, Rodeck CH. *Detection of alloimmune thrombocytopenia as cause of isolated hydrocephalus by fetal blood sampling*. *Lancet*. 1994 May 21; 343(8908): 1300-1.
- Morris RK, Malin GL, Khan KS, Kilby MD. *Systematic review of the effectiveness of antenatal intervention for the treatment of congenital lower urinary tract obstruction*. *BJOG*. 2010 Mar;117(4):382-90.
- MRC, *Prevention of neural tube defects: results of the Medical Research Council Vitamin Study*. MRC Vitamin Study Research Group. *Lancet* 1991;338:131-7.
- Mueller Eckhardt C, Mueller Eckhardt G, Willen-Ohff H, Horz A, Kuenzlen E, O'Neill GJ et al. *Immunogenicity of and immune response to the human platelet antigen Zwa is strongly associated with HLAB8 and DR3*. *Tissue Antigens* 1985;26: 71-6.
- Murphy DJ, Kyle PM, Cairns P, Weir P, Cusick E, Soothill PW. *Ex-utero intrapartum treatment for cervical teratoma*. *BJOG*. 2001 Apr;108(4):429-30
- Murphy MF, Williamson LM. *Antenatal screening for fetomaternal alloimmune thrombocytopenia: an evaluation using the criteria of the UK National Screening Committee*. *Br J Haematol*. 2000 Dec; 111(3):726-32.
- Nakayama DK, Harrison MR, de Lorimier AA. 1986. *Prognosis posterior urethral valves presenting at birth*. *J Pediatr Surg* 43–45.
- Nelson KB, Grether JK. *Can magnesium sulfate reduce the risk of cerebral palsy in very low birthweight infants?* *Pediatrics* 1995;95:263-9.
- Norbeck O, Papadogiannakis N, Petersson K, Hirbod T, Broliden K, Tolfvenstam T. *Revised clinical presentation of parvovirus B19-associated intrauterine fetal death*. *Clin Infect Dis*. 2002 Nov 1;35(9):1032-8.
- Novikova N, Hofmeyr GJ, Essilfie-Appiah G. *Prophylactic versus therapeutic amnioinfusion for oligohydramnios in labour*. *Cochrane Database of Systematic Reviews* 1996, Issue 1. Art. No.: CD000176. DOI: 10.1002/14651858.CD000176.
- T. Okawa, Y. Takano, K. Fujimori, K. Yanagida and A. Sato. *A new fetal therapy for chylothorax: pleurodesis with OK-432*. *Ultrasound Obstet Gynecol*. 2001; 18: 376-377.
- Onland W, de Laat MW, Mol BW, Offringa M. *Effects of antenatal corticosteroids given prior to 26 weeks' gestation: a systematic review of randomized controlled trials*. *Am J Perinatol*. 2011 Jan;28(1):33-44. Epub 2010 Jul 20.
- Paek BW, Jennings RW, Harrison MR, Filly RA, Tacy TA, Farmer DL, Albanese CT. *Radiofrequency ablation of human fetal sacrococcygeal teratoma*. *Am J Obstet Gynecol*. 2001 Feb; 184(3):503-7.
- Phelan JP, Park YW, Ahn MO, Rutherford SE. *Polyhydramnios and perinatal outcome*. *J Perinatol* 1990;10:347-50.
- Pluto Collaborative Study Group. *"PLUTO trial protocol: percutaneous shunting for lower urinary tract obstruction randomised controlled trial"*. *BJOG*. 2007;114(7):904.

- Pryde PG, Nugent CE, Pridjian G, Barr M, Faix RG. *Spontaneous resolution of nonimmune hydrops fetalis secondary to human parvovirus B19 infection*. *Obstet Gynaecol* 1992; 79:859–861
- Prospective study of human parvovirus (B19) infection in pregnancy*. Public Health Laboratory Service Working Party on Fifth Disease. *BMJ*. 1990 May 5; 300(6733): 1166-70.
- Quintero RA, Morales WJ, Allen M, Bornick PW, Arroyo J, LeParc G: *Treatment of iatrogenic pre-viable premature rupture of membranes with intra-amniotic injection of platelets and cryoprecipitate (amniopatch): preliminary experience*. *Am J Obstet Gynecol* 1999; 181:744–749.
- Rayment R, Brunskill SJ, Stanworth S, Soothill PW, Roberts DJ, Murphy MF. *Antenatal interventions for fetomaternal alloimmune thrombocytopenia*. *Cochrane Database Syst Rev*. 2005 Jan 25;(1):CD004226
- Rayment R, Brunskill SJ, Soothill PW, Roberts DJ, Bussel JB, Murphy MF *Antenatal interventions for fetomaternal alloimmune thrombocytopenia..* *Cochrane Database Syst Rev*. 2011 May 11;5: CD004226.
- Rodeck C, Deans A, Jauniaux E. *Thermocoagulation for the early treatment of pregnancy with an acardiac twin*. *N Engl J Med*. 1998 Oct 29; 339(18):1293-5.
- Rodeck CH, Kemp JR, Holman CA, Whitmore CA, Karnicki J, Austin MA. *Direct intravascular fetal blood transfusion by fetoscopy in severe Rhesus isoimmunisation*. *Lancet I* 1981:625– 627.
- Rodis JF, Borgida AF, Wilson M, Egan JF, Leo MV, Odibo AO, Campbell WA. *Management of parvovirus infection in pregnancy and outcomes of hydrops: a survey of members of the Society of Perinatal Obstetricians*. *Am J Obstet Gynecol*. 1998 Oct; 179(4): 985-8.
- Royal College of Obstetrician and Gynaecologist (RCOG). *Antenatal Corticosteroids to Reduce Neonatal Morbidity and Mortality*. Guideline No. 7; Oct. 2010
- Royal College of Obstetrician and Gynaecologist. *Periconceptional Folic Acid and Food Fortification in the Prevention of Neural Tube Defects*. Scientific Advisory Committee Opinion Paper 4 . April 2003.
- Sebire NJ, Snijders RJ, Hughes K, Sepulveda W, Nicolaides KH. *The hidden mortality of monozygotic twin pregnancies*. *Br J Obstet Gynaecol* 1997; 104:1203-7.
- Senat MV, Deprest J, Boulvain M, Paupe A, Winer N, Ville Y. *Endoscopic laser surgery versus serial amnioreduction for severe twin-to-twin transfusion syndrome*. *N Engl J Med* 2004;351:136-44
- Simpson JM, Sharland GK. *Fetal tachycardias: management and outcome of 127 consecutive cases*. *Heart*. 1998 Jun; 79(6):576-81.
- Smith RP, Illanes S, Denbow ML, Soothill PW. *Outcome of fetal pleural effusions treated by thoracoamniotic shunting*. *Ultrasound Obstet Gynecol*. 2005 Jul;26(1):63-6
- Sohan K, Carroll S, Byrne D, Ashworth M, Soothill P. *Parvovirus as a differential diagnosis of hydrops fetalis in the first trimester*. *Fetal Diagn Ther*. 2000 Jul-Aug; 15 (4): 234-6.
- Sohan K, Carroll SG, De La Fuente S, Soothill P, Kyle P. *Analysis of outcome in hydrops fetalis in relation to gestational age at diagnosis, cause and treatment*. *Acta Obstet Gynecol Scand*. 2001 Aug; 80(8):726-30.

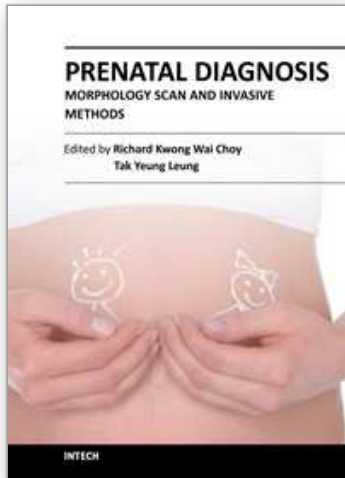
- Soothill P. *Intrauterine blood transfusion for non-immune hydrops fetalis due to parvovirus B19 infection*. Lancet. 1990 Jul 14; 336(8707): 121-2.
- Soothill P, Sohan K, Carroll S, Kyle P. *Ultrasound-guided, intra-abdominal laser to treat acardiac pregnancies*. BJOG. 2002 Mar;109(3):352-4
- Sotiriadis A, Makrydimas G, Papatheodorou S, Ioannidis JP. *Corticosteroids for preventing neonatal respiratory morbidity after elective caesarean section at term*. Cochrane Database Syst Rev. 2009 Oct 7;(4):CD006614.
- Strasburger JF, Wakai RT. *Fetal cardiac arrhythmia detection and in utero therapy*. Nat Rev Cardiol. 2010 May;7(5):277-90.
- Sydorak RM, Harrison MR. *Congenital diaphragmatic hernia: advances in prenatal therapy*. Clin Perinatol. 2003 Sep; 30(3):465-79.
- Tan LK, Kumar S, Jolly M, Gleeson C, Johnson P, Fisk NM. *Test amnioinfusion to determine suitability for serial therapeutic amnioinfusion in midtrimester premature rupture of membranes*. Fetal Diagn Ther. 2003 May-Jun; 18(3): 183-9.
- Tan TY, Sepulveda W. *Acardiac twin: a systematic review of minimally invasive treatment modalities*. Ultrasound Obstet Gynecol. 2003 Oct; 22(4):409-19.
- M. Tanemura, N. Nishikawa, K. Kojima, Y. Suzuki and K. Suzumori. *A case of successful fetal therapy for congenital chylothorax by intrapleural injection of OK-432*. Ultrasound Obstet Gynecol. 2001; 18: 371-375.
- Thein AT, Soothill P. *Antenatal invasive therapy*. Eur J Pediatr. 1998 Jan; 157 Suppl 1: S2-6.
- TR Moore, S Gale and K Benirschke. *Perinatal outcome of forty-nine pregnancies complicated by acardiac twinning*. Am J Obstet Gynecol 163 1990, pp. 907-912
- Ville Y, Hyett J, Hecher K, Nicolaides KH (1995) *Preliminary experience with endoscopic laser surgery for severe twin-twin transfusion syndrome*. N Engl J Med 332:224-227.
- Von Kaisenberg CS, Jonat W. *Fetal parvovirus B19 infection*. Ultrasound Obstet Gynecol. 2001 Sep; 18(3): 280-8.
- Wee LY, Fisk NM. *The twin-twin transfusion syndrome*. Semin Neonatol. 2002 Jun; 7(3): 187-202.
- Xu H, Hofmeyr J, Roy C, Fraser W D. *Intrapartum amnioinfusion for meconium-stained amniotic fluid: a systematic review of randomised controlled trials*. BJOG. An International Journal of Obstetrics and Gynaecology 2007 114(4):383-390
- Yaegashi N, Niinuma T, Chisaka H, Uehara S, Moffatt S, Tada K, Iwabuchi M, Matsunaga Y, Nakayama M, Yutani C, Osamura Y, Hirayama E, Okamura K, Sugamura K, Yajima A. *Parvovirus B19 infection induces apoptosis of erythroid cells in vitro and in vivo*. J Infect. 1999 Jul; 39(1): 68-76
- Yaegashi N, Niinuma T, Chisaka H, Watanabe T, Uehara S, Okamura K, Moffatt S, Sugamura K, Yajima A. *The incidence of, and factors leading to, parvovirus B19-related hydrops fetalis following maternal infection; report of 10 cases and meta-analysis*. J Infect. 1998 Jul; 37(1): 28-35.
- Yang YS, Ma GC, Shih JC, Chen CP, Chou CH, Yeh KT, Kuo SJ, Chen TH, Hwu WL, Lee TH, Chen M. *Experimental treatment of bilateral fetal chylothorax using in utero pleurodesis*. Ultrasound Obstet Gynecol. 2011 May 16.

Yasuki Maeno¹, Akiko Hirose¹, Taro Kanbe¹ and Daizo Hori. *“Fetal arrhythmia: Prenatal diagnosis and perinatal management”*. J. Obstet. Gynaecol. Res. Vol. 35, No. 4: 623-629, August 2009.

Yinon Y, Grisaru-Granovsky S, Chaddha V, Windrim R, Seaward PG, Kelly EN, Beresovska O, Ryan G *Perinatal outcome following fetal chest shunt insertion for pleural effusion*. Ultrasound Obstet Gynecol. 2010 Jul;36(1):58-64.

IntechOpen

IntechOpen



Prenatal Diagnosis - Morphology Scan and Invasive Methods

Edited by Dr. Richard Choy

ISBN 978-953-51-0614-2

Hard cover, 210 pages

Publisher InTech

Published online 29, June, 2012

Published in print edition June, 2012

This book provides detailed and comprehensive coverage on various aspects of prenatal diagnosis-with particular emphasis on sonographic and molecular diagnostic issues. It features sections dedicated to fundamentals of clinical, ultrasound and genetics diagnosis of human diseases, as well as current and future health strategies related to prenatal diagnosis. This book highlights the importance of utilizing fetal ultrasound/clinical/genetics knowledge to promote and achieve optimal health in fetal medicine. It will be a very useful resource to practitioners and scientists in fetal medicine.

How to reference

In order to correctly reference this scholarly work, feel free to copy and paste the following:

Sebastian Illanes and Javier Caradeux (2012). Fetal Therapy: Where Do We Stand, Prenatal Diagnosis - Morphology Scan and Invasive Methods, Dr. Richard Choy (Ed.), ISBN: 978-953-51-0614-2, InTech, Available from: <http://www.intechopen.com/books/prenatal-diagnosis-morphology-scan-and-invasive-methods/fetal-therapy>

INTECH
open science | open minds

InTech Europe

University Campus STeP Ri
Slavka Krautzeka 83/A
51000 Rijeka, Croatia
Phone: +385 (51) 770 447
Fax: +385 (51) 686 166
www.intechopen.com

InTech China

Unit 405, Office Block, Hotel Equatorial Shanghai
No.65, Yan An Road (West), Shanghai, 200040, China
中国上海市延安西路65号上海国际贵都大饭店办公楼405单元
Phone: +86-21-62489820
Fax: +86-21-62489821

© 2012 The Author(s). Licensee IntechOpen. This is an open access article distributed under the terms of the [Creative Commons Attribution 3.0 License](#), which permits unrestricted use, distribution, and reproduction in any medium, provided the original work is properly cited.

IntechOpen

IntechOpen