

We are IntechOpen, the world's leading publisher of Open Access books Built by scientists, for scientists

4,800

Open access books available

122,000

International authors and editors

135M

Downloads

Our authors are among the

154

Countries delivered to

TOP 1%

most cited scientists

12.2%

Contributors from top 500 universities



WEB OF SCIENCE™

Selection of our books indexed in the Book Citation Index
in Web of Science™ Core Collection (BKCI)

Interested in publishing with us?
Contact book.department@intechopen.com

Numbers displayed above are based on latest data collected.
For more information visit www.intechopen.com



Manual Jet Ventilation Using Manujet III for Bronchoscopic Airway Foreign Body Removal in Children

Shaoqing Li, Yuqi Liu and Fang Tan
*The Eye, Ear, Nose and Throat Hospital, Fudan University, Shanghai
China*

1. Introduction

Aspiration of a foreign body (FB) into the airway was often a life-threatening event in children. A particular challenge to anesthesiologists was that the airway must be shared with the surgeon during FB removal. It was difficult to maintain adequate ventilation, oxygenation and anesthetic depth without disturbing the operation. Also, the methods of anesthetic management and modes of ventilation during bronchoscopic FB removal varied greatly among institutions and anesthesiologists.

Since the introduction of the rigid bronchoscope, the rate of successful removal of FB has increased dramatically and the safety of the operation has improved. However, Intraoperative or postoperative hypoxemia was still found to be the most frequent adverse event, and it could lead to a life-threatening outcome if not promptly treated. The occurrence of hypoxemia may depend on a variety of factors including the property of the FB, the surgeon's experience, anesthetic method, and patient's condition. Our study identified five factors that strongly correlated with increased rate of intraoperative hypoxemia: age of patient, plant seeds as FB, pneumonia before procedure, long duration of FB removal surgery, and ventilation mode.

Of all the factors related to hypoxemia or other complications in our study, ventilation mode was strongly associated with intraoperative hypoxemia. An extensive medical literature search revealed that the optimal ventilation mode during rigid bronchoscopy for FB removal is still actively controversial. In general, spontaneous ventilation(SV) was more popular and was advocated before the mid 1990s, whereas more recently reports in favor of control ventilation(CV) have appeared. In a review by Farrell, the advantages and disadvantages of SV and CV were discussed; however, no personal preference was suggested. Jet ventilation in rigid bronchoscopy was first introduced by Sanders in 1967. Since then, it has been modified and widely used in suspended laryngoscopy. Its use in pediatric FB removal has not been widely advocated. In our study, we developed a MJV method using Manujet III in which a small catheter was placed transnasally into the trachea for oxygen delivery. This technique produced fewer episodes of intraoperative hypoxemia than any other ventilation mode. The value of MJV became more pronounced when the bronchoscope had to be inserted distal to the FB. In this instance, ventilation became limited

to the lung distal to the FB. In this situation, MJV became advantageous over the other ventilation modes, because MJV provided continuous ventilation in the noninvolved lung with a catheter separated from the bronchoscope. Thus, compared to other modes of ventilation, MJV significantly reduces the risk of hypoxemia.

This chapter was to narrate The Application and Possible Complications of manual jet ventilation using Manujet device for bronchoscopic removal of airway FBs in children, and discuss in detail the application and possible complication.

2. Manujet III

The Manujet III (VBM Medizintechnik GmbH, Germany, Figure 1) is a portable and easily regulated device that can be used for manual jet ventilation with a low volume of mechanical dead space, is specially made for Jet Ventilation in circumstances of problem airways and can be used in areas that have a high pressure oxygen air outlet. If there is an acute obstruction of the upper airway, the Manujet, in connection with a Jet Ventilation catheter acc. Ravussin or the Endojet adaptor, allows the patient to be ventilated.




Fig. 1. The Manujet III device (from VBM medical, INC.)

the Manujet Includes:

- Case with 4 m pressure hose
- Luer lock connecting tube

- Bronchoscope adaptor
- Endojet adaptor with Endojet catheter
- One of each Jet Ventilation catheter acc. to Ravussin for infant, child and adult(13G, 14G, 16G)

Connecting Tube – 100cm long with Luer Lock

Endojet Adaptor – for connection to the Endotracheal Tube, 15mm

Bronchoscope Adapter – for connection to the rigid bronchoscope, 15mm

Endojet Adaptor – The Endojet adaptor allows jet ventilation on the endotracheal tube, laryngeal mask or face mask. The catheter can be pushed forward through the endotracheal tube or laryngeal mask as far as required and can be fastened with the screw.

The features of Manujet III are: faster and simple, lightweight, portable and immediately ready for use.

3. Manual Jet Ventilation (MJV)

Since jet ventilation was first used in endolaryngeal procedures in 1971, there have been many improvements based on Sanders' ventilation technique. Based on the position of the catheter, jet ventilation can be categorized as follows: supraglottic jet ventilation, subglottic jet ventilation and percutaneous transtracheal jet ventilation. Based on the frequency, jet ventilation is also classified as low-frequency jet ventilation (LFJV that is administered at <60 times/minute) and high-frequency jet ventilation (HFJV that is administered at >60 times/minute). Because it can provide ventilation at low peak airway pressure, HFJV plays an important role in both airway surgeires and pulmonary protective ventilation, while LFJV is easily to be performed manually using a manual jet ventilator. This article reviews the application of manual jet ventilation (MJV) in airway surgeries.

Gas entrainment as a result of the “Venturi effect” is described in medical textbooks as the basis of jet ventilation. It is thought that the high-speed stream of gas directed into the airway by the jet nozzle causes a pressure gradient between the surrounding atmosphere and the gas stream, this pressure gradient drives the entrainment of the air in the surrounding atmosphere into the airway. However, Dr Ihra G believed that there was no “Venturi effect” in jet ventilation, because during jet application, positive pressures can be measured inside the jet stream and inside the injector. Other consideration involves that the pressurized jet stream causes an acceleration of the quiescent air, as a consequence the viscosity and friction between the moving and static layers of the air increases, thus drawing the surrounding air into the airway, resulting in the always larger actual tidal volume than the set shooting volume.

MJV has several advantages over HFJV. MJV can be more easily performed as the MJV device and oxygen source are the only equipment required. The pressure and frequency of ventilation can be easily and instantaneously adjusted according to actual situation during the procedure. Another advantage of the MJV is that the frequency and inspiration/expiration ratio are both similar to physiological conditions, so that carbon dioxide expiration is easier. While, in HFJV, the positive end expiratory pressure (PEEP) caused by this technique benefits oxygenation but makes carbon dioxide expiration more

difficult. In some cases, the increase in respiratory frequency may result in a decrease in alveolar ventilation. Vourc'h, et al made a comparison of MJV (20 times/minute) with HFJV (300 times/minute) which were used in tracheobronchial stenosis patients who received laser surgery under general anesthesia. Within the first 10 minutes of the operation, there was no significant difference between the two ventilation techniques as determined by blood gas analysis. However, those patients who received HFJV suffered from mild hypercapnia. It was thought that MJV is suitable better choice for patients who had tracheobronchial stenosis.

3.1 The application of MJV using Manujet III in rigid bronchoscopy for FB removal

MJV has been rarely reported to be used in airway foreign body removal. In our hospital, MJV using Manujet III has been applied in tracheobronchial foreign body removal in more than 2000 cases with satisfactory results since 2004. Our latest report concluded that, in addition to the fact that MJV provided a good condition for bronchoscopic manipulation, the occurrence of hypoxia during the operation was decreased. This conclusion was drawn after a comparison of the three ventilation techniques in 360 cases had been made; the techniques studied included spontaneous respiration, mechanically controlled ventilation and MJV. The effectiveness of the above three techniques were compared in the study with additional information including compliance to bronchoscope placement, successful rate of foreign body removal, occurrence of hypoxia and etc. From another study done by our group involving 384 patients, we concluded that the ventilation method was one of the risk factors in causing intraoperative hypoxemia. Specifically, spontaneous respiration tended to increase the occurrence of hypoxemia, while MJV decreased the occurrence. To perform this ventilation technique, a catheter (1.5 mm in I.D.) was placed transnasally into the trachea under the guidance of a laryngoscope and connected to the Manu-jet device (Figure 2) after anesthesia induction. Jet ventilation was manually controlled throughout the operation with the driving pressure of 15 psi in children aged less than 12 months or 15–35 psi (usually less than 25 psi) in children aged more than 1 year at a frequency of 20–35 times/minute. One outstanding advantage of this ventilation method is that the ventilation route is separate from the route used for bronchoscopy. This method can provide a steady oxygen supply

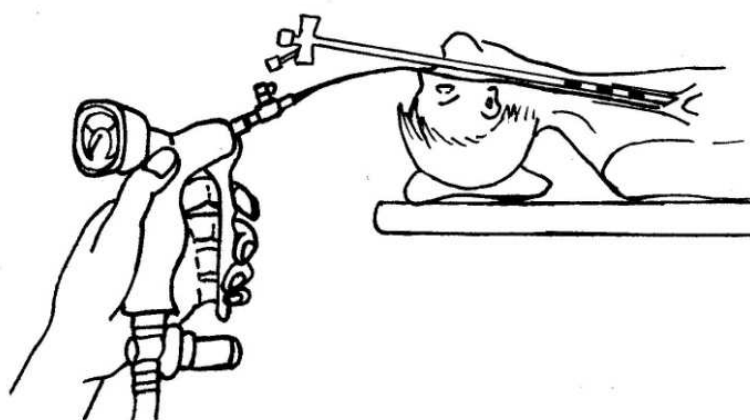


Fig. 2. Manual jet ventilation during FB removal: a small catheter (ID=1.5mm) was inserted transnasally into the trachea and connected to Manu-jet device during rigid bronchoscopy.

during the process of bronchoscope placement, which provides surgeons with ease in placing the bronchoscope. Constant and steady ventilation can also be achieved in the non-involved lung via a catheter separated from the bronchoscope when it is inserted into the distal side of bronchi of the involved lung. Even after the bronchoscope is removed, this technique can still provide jet ventilation until spontaneous respiration is restored in these patients.

3.1.1 Efficacy of manual jet ventilation using Manujet III for bronchoscopic airway foreign body removal in children

3.1.1.1 Patients and methods

Approval was obtained from the hospital's Human Research Committee prior to the study. The study was carried out from February of 2005 to June of 2009. A total of 360 children, ASA I or II, aged from 10 months to 12 years, weighing 8 - 35 kg, who required removal of an airway FB were enrolled in the study. All surgical manipulations were performed with Karl-Storz rigid bronchoscopes under general anesthesia. Informed consent was obtained from parents or legal guardians before the initiation of anesthetic and surgical procedure. Exclusion criteria included: (1) inability to obtain parental consent, (2) no foreign body found by bronchoscopy, and (3) absence of spontaneous breathing, cyanosis, or SpO₂ <90% was detected prior to the operation. The presence of a supraglottic/glottic foreign body suggested by clinical symptoms and chest radiography findings or confirmed by laryngoscopy was also excluded from the study. The data were collected in the operating room and ward. Each outcome was observed under the same set of conditions and recorded at same time to avoid bias. Participants were blinded, observers were partially blinded, while surgeons and anesthesiologists were not blinded in the study.

3.1.1.2 Management of anesthesia and ventilation

Atropine (0.01 mg/kg) and methylprednisolone (2 mg/kg) was given intravenously to all patients before anesthetic induction. Patients were randomly divided into three groups (n = 120). In group S, anesthesia was induced with propofol (2 mg/kg) and glyoxybutyrate sodium (70 mg/kg) and maintained by bolus administration of 1 - 2 mg/kg propofol as needed. The patient was allowed to breathe spontaneously at this level of anesthesia. Following successful insertion of a rigid bronchoscope, pure oxygen was delivered at a flow rate of 8 L/min by connecting the respiratory circuit to the side arm of the bronchoscope.

In Group P, anesthesia was induced with propofol (4 - 5 mg/kg), fentanyl (1 - 2 mg/kg) and succinylcholine (2 mg/kg) and maintained by bolus administration of 1 - 2 mg/kg propofol and 2 mg/kg succinylcholine as needed. The respiratory circuit was connected to the side arm of the bronchoscope and manual intermittent positive pressure ventilation (IPPV) was performed at the rate of 16 - 35 ventilations/min. A larger than normal tidal volume was delivered to offset the leakage of oxygen through the open eye piece of bronchoscope. The chest wall movement of the patients was closely observed to assure adequate ventilation.

In group J, patients received the same anesthetic protocol as in Group P. A small catheter was inserted transnasally into the trachea under the guidance of a laryngoscope and connected to the Manujet III device. Jet ventilation was manually controlled throughout the operation with

the driving pressure of 0.6 – 1 bar in children aged less than 12 months or 1 – 2.5 bar in children aged more than 1 year (1 bar = 105 Pa) at a frequency of 20 – 35 ventilations/min. The effectiveness of ventilation was assessed by degree of chest excursion. After the FB removal, spontaneous respiration or assisted ventilation was maintained through a facemask in Groups S and P. In Group J, the jet catheter was kept in the trachea and jet ventilation was continued until spontaneous respiration resumed.

Prior to the start of the insertion of bronchoscope, 1% lidocaine aerosol was sprayed over the epiglottis using laryngoscopic guidance in all groups of patients.

3.1.1.3 Measurements

The condition for insertion of bronchoscope was regarded as satisfactory when the bronchoscope was inserted successfully on the first attempt with a clear view of the glottis and without patient's body movement or bucking. Hypoxemia was defined as a decrease in pulse oxygen saturation (SpO₂) < 90% for >5 s.

Beside the baseline medical conditions and condition that required the procedure, the following information was recorded for each patient: successful insertion of bronchoscope on the first attempt, occurrence of hypoxemia during bronchoscopy and after withdrawing the bronchoscope, successful rate of FB removal, the duration of the operation, the time of emergence and recovery from anesthesia, and perioperative side effects including laryngospasm, arrhythmias, breath holding, and post-op restlessness. Patients were discharged from this study if no foreign body was found during the operation. If the presence of a foreign body was confirmed but could not be removed in the first attempt of bronchoscopy, a second attempt was made 3 – 5 days later, and a thoracotomy should be taken after two times of unsuccessful bronchoscopy. The ventilation mode and anesthetic technique for the second bronchoscopy were chosen based on the anesthetist's preference, and, in some cases, on the surgeon's preference. In those cases, only the first attempt was included in the study and was classified as unsuccessful foreign body removal. Whether the second attempt was successful or not, the patient was not included in the study. No thoracotomy was performed in the study.

3.1.1.4 Results

The data structure of each group was identical, and demographic and epidemiologic data were comparable among the three groups (Table 1). Table 2 presents the clinical and surgical data for the three groups. Compared with group S, groups P and J showed significantly higher success rates of bronchoscope insertion on the first attempt, lower rates of intra- and post-operative hypoxemia, lower rates of perioperative complications, shorter durations of operation, and faster recoveries and emergence from anesthesia ($P < 0.05$). The incidences of hypoxemia were lower in Group J compared with that in Group P (2.5% versus 16.7%, $P < 0.05$). There were no significant differences among groups for the other data that were collected.

3.1.1.5 Discussion

In the current study, three types of ventilation methods were compared in patients undergoing rigid bronchoscopy for airway FB removal. We found that the patients with spontaneous breathing during the procedure had lower success rates for bronchoscope

	Group S	Group P	Group J
Sex (male/female)	81/39	74/46	83/37
Age (months)	17 (22–36)	17 (14–24)	20 (14–24)
Weight (kg)	14±3	13±4	14±4
Duration of foreign body in the airway (days)	3 (1–11)	3 (1–9)	3 (1–7)
Location of the foreign body (n)			
main	9	13	11
left	53	51	49
right	57	53	58
both	1	3	2

Table 1. Clinical characteristics of the patients (n = 120 per group). Parameters presented as mean±SD. Data structure of each group was identical; demographic and epidemiologic data were comparable among the three groups.

	Group S	Group P	Group J
Successful bronchoscope insertion (%)	70.8	97.5*	98.3*
Duration of operation (min)	29.1±6.2	16.7±2.1*	15.2±2.2*
Duration of emergence from anesthesia (min)	32.7±6.8	9.1±2.4*	9.2±2.0*
Percentage of cases with foreign body removal (%)	90.8	92.5	96.7
Intraoperative hypoxemia (%)	40.8	16.7*	2.5*†
Postoperative hypoxemia (%)	19.2	6.7*	4.2*
Body movement during operation (%)	73.3	17.5	10.8*
Perioperative side effects (%)	34.2	10.8*	9.2*
Laryngospasm(cases)	5	1	1
Arrhythmia(cases)	3	2	0
Breath holding(cases)	21	11	9
Restlessness(cases)	13	8	9
other(cases)	7	4	3

*P<0.05 versus Group S; †P<0.05 versus Group P.

Table 2. Clinical characteristics of surgery for the three groups (n = 120 per group). Parameters presented as mean±SD.

insertions, higher incidences of hypoxemia and perioperative adverse events and a longer operation times. We speculated that the cause for these findings was due to an inadequate depth of anesthesia in group S. Lighter anesthesia would make a patient's airway more sensitive and reactive to the presence of the bronchoscope, frequently leading to

bronchospasm, breath-holding and bucking. Deeper anesthesia increases the risk of inhibiting respiration or causing shallow respiration. All of these factors may have contributed to the higher incidence of hypoxemia in group S. The duration of the operation was also significantly longer in group S because extra time was needed for frequent adjustment of the depth of anesthesia or management of complications. In contrast, the controlled ventilation techniques used in groups P and J provided a good anesthetic status for surgery, and the muscle relaxation caused by succinylcholine gave a further advantage for bronchoscope manipulation. Therefore, decreased rate of complications and reduced duration of operation were observed in both groups P and J.

Jet ventilation during rigid bronchoscopy was first introduced by Sanders. Since then, it has been modified and is now widely used in suspension laryngoscopy. The route used for jet ventilation can be classified as either intratracheal jet ventilation (ITJV) or supraglottic jet ventilation (SJV). Both have a low incidence of complications when compared with traditional jet ventilation. Neither ITJV nor SJV are widely advocated in pediatric airway FB removal. From a practical point of view, SJV is unlikely to be attached to a rigid bronchoscope because of the incompatibility of the instruments. ITJV can be performed through the lateral aperture of the rigid bronchoscope by propelling air through the lumen of the bronchoscope. In the case, however, that the bronchoscope must be inserted distally to the FB, ventilation through the bronchoscope becomes limited to the bronchus, which is actually obstructed by the FB. In this situation, jet ventilation via the bronchoscope will be much less efficient and hypoventilation may occur quickly. To circumvent this problem in this study, we used a modified catheter that was connected directly to Manujet III, and was placed transnasally into the trachea; therefore, the jet ventilation and the bronchoscopic procedures were performed separately. This design made continuous ventilation to the nonobstructed lung or both lungs possible because the tip of the catheter was placed in the trachea, and did not interfere with bronchoscopic operation. The advantage of this method is that it can provide continuous ventilation to the clear lung with a catheter separate from the bronchoscope. This was confirmed by results from the present study in which the incidence of hypoxemia was lower in Group J than in Group P. Another advantage of the MJV is that it can offer unhurried conditions for bronchoscope insertion while continuous ventilation takes place through the transnasal catheter. This method appears superior to the IPPV method, in which the delay in initiating artificial ventilation is likely to be too long to maintain adequate oxygen saturation if the bronchoscope is not inserted successfully on the first or second attempt.

The use of transtracheal manual jet ventilation has been suggested for emergent airway management in the "can't intubate, can't ventilate" scenario described in the "Failed Ventilation Guidelines" formulated by "The Difficult Airway Society" Manujet III is a device widely used in emergency departments, intensive care units, recovery rooms and operating rooms for patients needing emergency ventilation. We utilize this kind of device for bronchoscopic foreign body removal. The device sprays hyperbaric oxygen into the airway through the jet catheter, and at the same time, air around the jet oxygen flow is also driven into the airway because of the "Venturi" effect. The final tidal volume is composed of the jet oxygen flow and its surrounding air flow. The highest oxygen pressure designed for this device can reach to 3 bar (300kPa). The driving pressure of the jet flow can be regulated as needed. The recommended driving pressure is dependent on the age of the patient: 0.1 - 1 bar for infants, 1 - 2.5 bar for children and 2.5 - 3.5 bar for adults.

Barotrauma is the most severe complication associated with jet ventilation. Blockage of airway outflow and trauma on the tracheal mucosa are the two most common causes of barotraumas. In the current study, no cases of barotrauma were observed when Manujet III was used. However, Manujet III has the potential to aggravate an existing pneumothorax because of the high pressure of airflow; the patient should be closely monitored and the necessary preventive strategies should be applied. First, a smaller jet catheter should be used to avoid blocking the airway outflow and disturbing the surgical procedure. Second, the location and position of catheter should be checked frequently to prevent it from slipping deeper, and preventing air accumulation caused by severe bronchotracheal occlusion. Third, the jet of the Manujet should be manipulated by the Manujet operator in a pattern of slow jetting-quick release using a high frequency and a low driving pressure. Finally, successful jet ventilation is highly operator-dependent and should be done by experienced attendant anesthesiologists or residents under the guidance of attendants.

Manual jet ventilation with Manujet III has become the standard technique in our hospital for FB removal by rigid bronchoscopy. There are several advantages in using this device: (1) it provides continuous ventilation during all steps of the procedure; (2) it avoids inadequate ventilation to unilateral lung when the bronchoscope is inserted distal to the FB; (3) it shortens the duration of operation and emergence from anesthesia; (4) spontaneous respiration is possible because of the minimal stimulation by a small transnasal catheter and a manually controlled ventilation mode adaptable to patients' status of respiration; and (5) it minimizes the post-operative hypoxemia by decreasing bucking, coughing, or laryngospasm induced by oral secretions accumulated under the glottis if ventilated through mask during the emergence from anesthesia. In cases with a supraglottic/glottic foreign body, manual jet ventilation is not suggested, while in cases with bilateral bronchus obstruction, jet ventilation should be cautiously used while keeping the catheter in the main tracheal airway. Although it is impossible to detect the end tidal CO₂ levels in an open airway during rigid bronchoscopy, CO₂ retention has not been a problem according to our previous study using jet ventilation with a frequency of 20 - 60 ventilations/min in suspension laryngoscopy.

In conclusion, manual jet ventilation using Manujet III is a safe and effective technique for airway FB removal by rigid bronchoscopy in children. It offers more favorable outcomes when compared with spontaneous respiration. Attention should be paid to carefully observe the chest excursion of the patients for the assessment of the efficiency of jet ventilation and to check the location of the catheter to avoid barotrauma caused by bronchotracheal occlusion.

3.1.2 MJV using Manujet III to removal long retained airway FB

Delayed diagnosis in AFB aspiration in children leads to prolonged foreign body retention in the bronchus, causing pathological changes in the lungs, such as pneumonia, bronchitis, emphysema, breathing difficulties, asthma, choking, etc. The longer the foreign body retention, the more the respiratory problems and aggravated pathological changes, which have increased the risk of foreign body removal surgery, particularly the incidence of intraoperative hypoxia

3.1.2.1 Materials and method

We reviewed the records of all children who underwent the removal of airway foreign bodies (FBs) using rigid bronchoscopy in our Eye and ENT hospital between June 2004 and

September 2008. The patients whose time from FBs aspiration to retrieval exceed 30 days were admitted into our study. The subjects who underwent MJV using Manujet III constituted for Group m, and those who underwent ventilation through lateral aperture of rigid bronchoscopy were Group n, and the narcotic drugs must be identical in Group m and Group n. To analyze the distribution of patients and complications before operation, to analyze the incidence of hypoxemia during and after the operation, to analyze the rate of success of FB removal, to analyze the duration of operation and emergence from anesthesia and the other perioperative side effects.

3.1.2.2 Results

From June 2004 to September 2008, there were 1263 patients who were subjected to FB removal. Among them, 67 children (5.30%) accorded to our study qualification, age ranging from 9 months to 131 months (median 25 months), weight ranging 9~33kg (median 13kg), ASA I~III, The duration of FB aspiration was 30days to 370 days (median 87days). 46 children (68.66%) with no FB history, in others 21 (31.34%) cases with positive clinical history(but not chest film findings, or not early symptoms or negative bronchoscopy findings). There was no signification difference between Group m and Group n about the distribution of patients and complications before operation, The incidence of hypoxemia during operation was lower in Group m than in Group n ($P<0.05$), and the duration of operation and emergence from anesthesia were shorter in Group m than in Group n ($P<0.05$). There was no significant difference in other compared factors ($P>0.05$) (see Table 3,4,5).

Complaints before operation

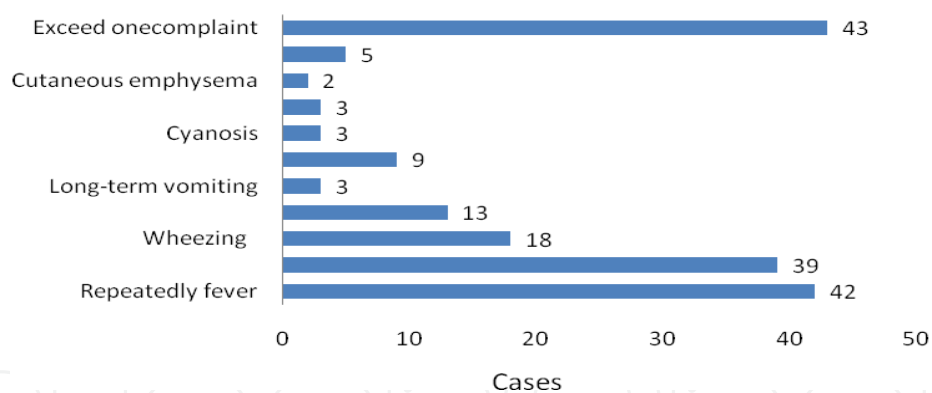

Fig. 3. Complaints before operation

Radiological findings before operation

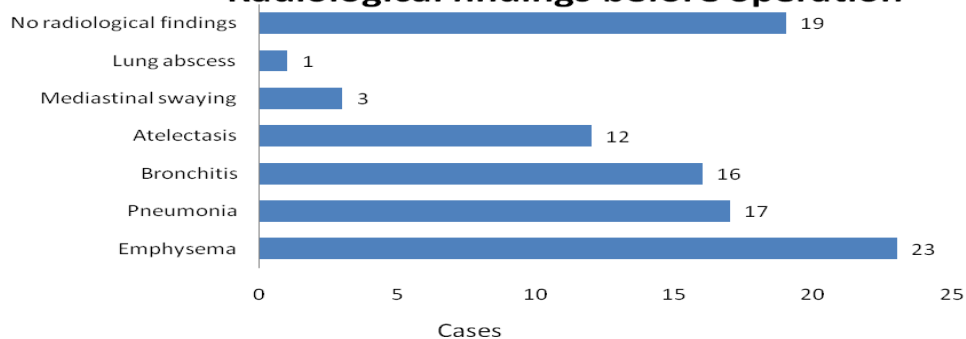

Fig. 4. Radiological findings before operation

	Number(cases)	percentage
Exceed 30 days	67	
From rural	56	83.58%
From urban	11	16.42%
No FB history	46	68.66%
FB history	21	31.34%
Organic FB	57	85.07%
Left	36	53.73%
Right	31	46.27%

Table 3. Distribution of patients

	Number(cases)	Percentage
Complaints		
Repeatedly fever	42	62.69%
Chronic cough	39	58.21%
wheezing	18	26.87%
appetite depress	13	19.40%
long-term vomiting	3	4.48%
dyspnea	9	13.43%
cyanosis	3	4.48%
vomica	3	4.48%
cutaneous emphysema	2	2.99%
no complaint	5	7.46%
exceed onecomplaint	43	64.18%
Radiological findings		
emphysema	23	34.33%
pneumonia	17	25.37%
bronchitis	16	23.88%
atelectasis	12	17.91%
mediastinal swaying	3	4.48%
lung abscess	1	1.49%
No radiological findings	19	28.36%

Table 4. Complaints and radiological findings before operation

Compared items	Group m (cases and percentage)	Group n (cases and percentage)
patients studied (cases)	40(59.70%)	27(40.30%)
hypoxia during perform	7(17.5%) [●]	11(40.74%) [●] P=0.035 $\chi=4.431$
hypoxia postoperation	5(12.5%)	4(14.81%) P=0.785 $\chi=0.074$
Time of perform(minutes)	21.3 ± 3.7 [◆]	37.2 ± 6.3 [◆] P=0.031 $\chi=5.016$
Time of analepsia (minutes)	16.2 ± 4.1 [■]	19.1 ± 4.3 [■] P=0.043 $\chi=3.426$
extracted FB(cases)	39(97.5%)	27 (100%) P=0.145 $\chi=2.219$
respiratory tract obstruction postoperation(cases)	3(7.5%)	3(11.11%) P=0.612 $\chi=0.258$
recover from chronic respiration symptoms(cases)	33(82.5%)	22(81.48%) P=0.915 $\chi=0.011$
remain respiration symptoms(cases)	7(17.5%)	5(18.52%) P=0.915 $\chi=0.011$

●◆■ (P<0.05)

Table 5. Comparison between Group m and Group n

3.1.2.3 Discussion

Airway foreign bodies often occur in 8 months to 3 years old children. However, in many children, there was no clear history of FB or lacked of self-reported or parent-witnessed events. As a result, diagnosis of FBA was often delayed. In addition, medical imaging sensitivity and specificity in the diagnosis of airway FB was low. If lack of obvious early respired symptoms, often led to prolonged FB retention. Although fiberoptic bronchoscopy approach is a highly successful diagnosis approach, in our country, many doctors lack of AFB consciousness, and they seldom give a suggestion of taking fiberoptic bronchoscopy. In our study, organic FBs accounted for 85.07%. The most important feature of organic FBs (such as plant seeds) was that they contain unsaturated fatty acids, which may release arachidonic acid and plant protein. These molecules trigger a inflammatory response that involves the release of inflammatory chemokines, and other substances, causing inflammation of tracheal mucosa, resulting in mucosal swelling and congestion, bronchitis, pneumonia, wheezing, airway obstruction, etc. In addition, the plant seeds are rich with in protein and sugar, with affinity to water, thus the longer the retention time, the softer and more swollen the mucous membrane, exacerbating bronchial obstruction. Consequently, pulmonary secretions can not be discharged in time, increasing the risk of lung infections and "asthma syndrome". Lan F.T found that lung extracellular matrix remodeling, and triggered a series of lung pathological changes in the long FB retained children.

FB removal in the children with complicated lung pathological changes is a high risk procedure. The risks were ventilate disorder and hypoxemia with the most severe life-threatening, and the most commonest risk being a high incidence of intraoperative hypoxia. So the appropriate ventilation mode was important. We had tried a variety ways of anesthesia ventilation, every method had themselves advantages and disadvantages. In the manual jet ventilation method by Manujet III, a small catheter was inserted transnasally into

the trachea and connected to the Manujet III device, that take up airway as little as possible, and provide more space for hard-placed laryngoscopy. Manual jet ventilation can give adequate ventilation and less carbon dioxide retention. In our this retrospective study, manual jet ventilation using Manujet III significantly reduced the occurrence of hypoxia and shorten the operation time. Why was Manujet III manual jet ventilation more adequate? Probably because the jet tube was in main airway, ventilated through bilateral lung, when rigid bronchoscopy into the side of the bronchial airway, the other side of the pulmonary could be ventilated; the ventilated method through lateral aperture of rigid bronchoscopy, when rigid bronchoscopy into the side of the bronchial airway, the other side of the pulmonary could't be ventilated well, If rigid bronchoscopy into the "disease lung" side, that became "disease lung" ventilation and "healthy lung" no ventilation, so the ventilation is inadequate. Manujet III manual jet ventilation in children with complete muscle relaxation can be fixed, good ventilation and good operating vision, can creating favorable conditions for removal of foreign body, reduce operation time.

But Manujet III manual jet ventilation is a positive pressure ventilation, need to pay attention to the outlet of gas and muscle relaxation, the pressure should be appropriate (the baby was 0 ~ 1bar, children 1 ~ 2.5bar, adult 2.5 ~ 3.5bar), the chest wall motion should be closely observed to estimate the efficacy of ventilation. Therefore, we recommend the users were to be well trained before used Manujet III. Furthermore, characteristics of the air flow dynamics of manual jet ventilation using Manujet III was not clear, the potential risks need further study.

This retrospective study confirmed that MJV using Manujet III in FB removal can offer sufficient ventilation and shorten operation time and fasten analepsia, and prove the advantages in FB removal surgery in the children with a long retained airway foreign body.

Manual jet ventilation using Manujet III has many, it should be recommended, but for the possible adverse events, the operator should be well trained in advance.

3.2 Main complications relevant to MJV

3.2.1 Pneumothorax

A Pneumothorax is the most serious complication associated with MJV. Reports of the occurrence of this complication vary in the literature. A retrospective review, which covered 942 laryngeal jet ventilation cases (via suspension laryngoscope) collected for as long as 10 years, revealed that pneumothoraces were reported in 4 patients. It is thought that two factors accounted for the pneumothoraces; these were airway damage and high airway pressures. Leemann, et al reported one case involving a combined pneumothorax and subcutaneous emphysema that was caused by airway mucosal damage after laser surgery. In a discussion of this case presented by Sosis, it was regarded that once the pneumothorax and subcutaneous emphysema were observed in the first surgery, jet ventilation should not have been used in the second surgery, because the highly pressurized air flow could pass through the injured mucosal into the pleural and subcutaneous tissues and resulted in the pneumothorax and subcutaneous emphysema. Airway pressure has always been one of the most conspicuous causes of mucosal injury seen in clinical practice. But according to the opinion provided by Bourgain, et al., the occurrence of complications such as pneumothoraces could not be reduced even when pressure-controlled jet ventilation device was used. It is also regarded that the degree of airway pressure after initiation of jet

ventilation depends on not only the rate of aspirating gas stream and diameter of the catheter but also the size of the environment around the aspirating gas stream, such as, diameter of the airway, cross sectional area of the trachea and the distance from distal end of the catheter to glottis vera. When driving pressure is fixed, the obstruction of airway outflow is the main reason for increased airway pressure and occurrence of pneumothoraces. In upper airway surgeries, possible reasons for airway outflow obstruction include, but are not limited to, severe laryngotracheal stenosis, upper airway blocked by a neoplasm, aggravated airway mucosal edema caused by the operation procedures, and a totally blocked airway possibly due to the surgical procedure or position of surgical devices. Baer pointed out that the monitoring of airway pressure curve has prevented the occurrence of pressure relevant damages, such as pneumothoraces, from happening since this practice was in use for nearly 20 years. Rezaie-Majd also speculated that the most important measure in preventing pressure related damages was to ensure there was no outflow obstruction. The advantage in using the Manujet is that the ventilation device has a pressure-controlling design that can keep gas pressure within the prescribed safety ranges. The ventilation frequency can be adjusted manually by operators. Therefore, this ventilation technique, adopted during surgery, facilitates the cooperation between anesthesiologists and surgeons, and ensures good oxygen supply as well as an unobstructed airway outflow to patients throughout operations. In our hospital, more than 2000 airway foreign body removals were finished under the ventilation model of MJV since 2007, 7 cases of pneumothorax occurred. There was no evidence that could indicate MJV was associated with higher rate of pneumothoraces than any other ventilation models. So, we consider that MJV can play a safe part in the airway foreign body removal when correctly used.

3.2.2 Hypoxemia

Although most of the literatures indicate that jet ventilation can provide adequate oxygen supply, hypoxemia is still the most commonly observed complication. Most of the upper airway surgeries were taken in an open airway under suspension laryngoscope or rigid bronchoscope, and jet-propelled entrainment of atmosphere into the airway causes an atmospheric inhaled gas that occupies 25–60% of the tidal volume, attributing to a fraction of inspired oxygen of 32–42% .

3.2.3 Carbon dioxide retention

Carbon dioxide retention is another complication associated with jet ventilation, especially when the operation is prolonged. This complication is more commonly observed during HFJV and may be attributed to low tidal volume and inhalation of the expiratory gas. In low frequency MJV, the incidence of carbon dioxide retention is low, the elimination of carbon dioxide was mainly influenced by the compliance of thorax.

4. Experiences for the application of MJV using Manujet III device for FB removal

4.1 Driving pressure level, frequency and inspiration/expiration ratio

In jet ventilation, gas flow volume is proportional to driving pressure. Therefore, with an increase in driving pressure, tidal volume will increase linearly and PaCO₂ will decrease.

However, if tidal volume is to be increased by raising the driving pressure, the barotrauma risk will be increased as a result of high airway pressure. With the increase in frequency, there is a corresponding decrease in tidal volume; the contraflow effect of intrapulmonary gas also becomes weak, and the eliminating rate of carbon dioxide decreases proportionally. The ideal ratio of inspiration to whole respiration period is 20–30%. According to our clinical experience, when performing Manu-jet, the driving pressure should be set less than 15 psi in infants, and between 15–35 psi in children (usually less than 25 psi), and 35–59 psi in adults with a frequency of 15–30 times/minute in children and 12–20 times/minute in adults.

4.2 Maintaining adequate depth of anesthesia and degree of muscle relaxation

When the depth of anesthesia is not adequate or the degree of muscle relaxation is not enough, the glottis vera will close due to the contraction of laryngeal muscles and gas expiration will be inhibited; this creates turbulent air flow which is indicated by a sound of whistle. Therefore, to avoid barotraumas, MJV has to be stopped immediately when a whistle is heard until adequate anesthesia and muscle relaxation are attained.

4.3 Attending chest visualization and auscultation

During ventilation, it is very necessary to closely observe the chest excursions and listen to the sound of gas flow passing in and out of airway. By doing this, airway obstruction can be found immediately if it occurs. The surgical manipulation in the airway may dislodge the jet catheter, so it is important to frequently check the location of the catheter by lung auscultation.

5. Conclusions

Manual jet ventilation using Manujet III is a safe and effective technique for airway FB removal by rigid bronchoscopy in children. It offers more favorable outcomes compared with spontaneous respiration. But attention should be paid to closely observe the chest excursion of the patients for the assessment of the efficiency of jet ventilation and to check the location of the catheter to avoid barotrauma caused by bronchotracheal occlusion.

However, the time of MJV with Manujet III wasn't long, its mechanism of airflow dynamics isn't clear enough. the advanced research will focus on the mechanism which can make us use Manujet better.

6. Acknowledgment

The authors acknowledge Dr. Wu, an anesthesiologist in Cincinnati Children's Medical Center, USA. for the helps in English language; Dr. TianYu Zhang, a rhinolaryngologist in Eye and ENT hospital, China, for the co-operation in foreign body removal; Dr. Dan Chen, an anesthesiologist in Eye and ENT hospital, China, for recording clinical documents; others are YaoZhen, YeMing, et al.

7. References

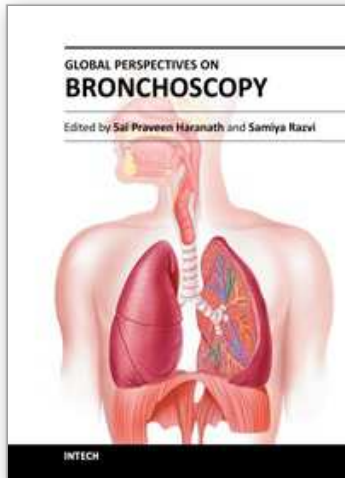
Baer GA. (2000). No need for claims: facts rule performance of jet ventilation. *Anesth Analg*, Vol.91, No.4, (October 2000) , pp.1040-1041, ISSN 0003-2999

- Bourgain J.; Desruennes E. & Fischler M.(2001).Transtracheal high frequency jet ventilation for endoscopic airway surgery: a multicenter study. *Br J Anaesth*,Vol.87,(August, 2001),pp.870-5, ISSN 0007-0912
- Brown R.; Greenberg R. & Wagner E.(2001). Efficacy of propofol to prevent bronchoconstriction. *Anesthesiology*,Vol. 94,(May 2001),pp. 851-855, ISSN 0003-3022
- Chen L.; Zhang X. & Li S.;et al.(2009). The risk factors for hypoxemia in children younger than 5 years old undergoing rigid bronchoscopy for foreign body removal. *Anesth Analg*,Vol.109,No.4,(October 2009),pp.1079-1084, ISSN 0003-2999
- Chih-Yung C.; Kin-Sun W. & Shen-Hao L.;et al.(2005). Factors Predicting Early Diagnosis of Foreign Body Aspiration in Children. *Pediatric Emergency Care*, Vol.21, No. 3, (March 2005), pp.161-164, ISSN: 0749-5161
- D'Haese J. ; Camu F. & Noppen M.(1996). Total intravenous anesthesia and high-frequency jet ventilation during transthoracic endoscopic sympathectomy for treatment of essential hyperhidrosis palmaris: A new approach. *J Cardiothorac Vasc Anesth*,Vol. 10,No.6, (October 1996), pp.767-771, ISSN 1053-0770
- Divisi, D.; Tommaso, S. & Garramone, M.(2007).Foreign bodies aspirated in children: role of bronchoscopy. *Thorac. Cardiovasc. Surg.*, Vol.55, No.4,(June 2007), pp. 249-252, ISSN 0022-5223
- Farrell PT. (2004).Rigid bronchoscopy for foreign body removal: anaesthesia and ventilation. *Pediatr Anesth*,Vol.14, (January 2004),pp.84-9, ISSN 1155-5645
- Gree G. ; Bauman N. & Smith R.(2000). Pathogenesis and treatment of juvenile onset recurrent respiratory papillomatosis. *Otolaryngol Clin North Am*,Vol. 33,No.1,pp. 187-207, ISSN 0030-6665
- Ihra G. & Aloy A. (2000).On the use of Venturi's principle to describe entrainment during jet-ventilation. *J Clin Anesth*, Vol. 12,No.5, (Aug. 2000),pp.417-419, ISSN 0952-8180
- Ihra G.; Hieber C. & Schabernig C.;et al. (1999). Supralaryngeal tubeless combined high-frequency jet ventilation for laser surgery of the larynx and trachea. *Br J Anaesth*, Vol. 83,no.6,(June 1999),pp.940-942, ISSN 0007-0912
- Jaquet Y. ; Monnier P. & Van Melle G. ; et al. (2006).Complications of different ventilation strategies in endoscopic laryngeal surgery: a 10-year review. *Anesthesiology*,Vol. 104,No.1,(January 2006),pp. 52-59,ISSN 0003-3022
- Karakoc F.; Cakir E. & Ersu R.;et.al. (2007). Late diagnosis of foreign body aspiration in children with chronic respiratory symptoms. *Int.J Pediatric Oto*,Vol. 71,No.2, (February 2007),pp. 241-246, ISSN 0165-5876
- Karen B. & Ronald S.(2009). Pediatric airway foreign body retrieval: surgical and anesthetic perspectives. *Pediatric Anesthesia*, Vol. 19, No.(Suppl. 1),(July 2009),pp.109-117, ISSN:1155-5645
- Kugelman R.; Shaoul M. & Goldsher I. (2006). Persistent cough and failure to thrive: a presentation of foreign body aspiration in a child with asthma. *Pediatrics*, Vol.117,No.5,(May 2006),pp.1057-1060, ISSN 00314005
- Leemann B.; Heidegger T. & Grossenbacher R.; et al.(2004). A severe complication after laser-induced damage to a transtracheal catheter during endoscopic laryngeal surgery. *Anesth Analg*,Vol. 98,No.6,(June 2004),pp.1807-1808, ISSN 0003-2999

- Lev S.; Salim M. & Yosef R.; et al. (2010). Foreign body aspiration in children: the effects of delayed diagnosis. *Am J Otolaryngol*, Vol.31, No.5, (September-October 2010),pp.320-4, ISSN: 0196-0709
- Li S.; Liu Y. & Tan F.(2010). Efficacy of manual jet ventilation using Manujet III for bronchoscopic airway foreign body removal in children. *Int J Pediatr Otorhinolaryngol*, Vol. 74, No.12, (December 2010),pp.1401-1404, ISSN 0165-5876
- Mallick M.; Khan A. & Al-Bassam A. (2005). Late presentation of tracheobronchial foreign body aspiration in children. *J. Trop. Pediatr*, Vol.51, No.3, (June 2005), pp. 145-148, ISSN 0142-6338
- Metrangolo S.; Monetti C. & Meneghini L. (1999).Eight years' experience with foreign-body aspiration in children: what is really important for a timely diagnosis. *J Pediatr Surg*, Vol.34, No.8, (August 1999), pp.1229-31, ISSN 0939-7248
- Mu L.; He P. & Sun D.(1991). The causes and complications of late diagnosis of foreign body aspiration in children. *Arch Otolaryngol. Head Neck Surg*, Vol.117, No.8, (August 1991),pp. 876-879, ISSN 0886-4470
- Nouraei S.; Giussani D. & Howard D.; et al.(2008). Physiological comparison of spontaneous and positive-pressure ventilation in laryngotracheal stenosis. *Br J Anaesth*, Vol. 101, No.3, (June 2008), pp. 419-423, ISSN 0007-0912
- Paola Z.; Amulya K. & Saxena. (2009). Management Strategies in Foreign-Body Aspiration. *Indian J Pediatr*, Vol. 76, No.2, (February 2009), pp. 157-161, ISSN: 0019-5456
- Patel R.(1999). Percutaneous transtracheal jet ventilation. A safe, quick and temporary way to provide oxygenation and ventilation when conventional methods are unsuccessful. *Chest*, Vol. 116, No.6, (December 1999), pp.1689-1694, ISSN 0012-3692
- Peng S.; Xia S. & Zhong L.; et al.(1997). Clinical research on the normal pressure and frequency jet ventilation during suspension laryngoscopy. *Chi J Anesth*, Vol.17, No.7, pp.407-410
- Perrin G.; Colt H. & Martin C.; et al.(1992). Safety of interventional rigid bronchoscopy using intravenous anaesthesia and spontaneous assisted ventilation, a prospective study. *Chest*, Vol.102, No.5, (November 1992), pp.1526-30, ISSN 0012-3692
- Perry RH. Ejector performance. In: Perry RH, Chilton CH, eds. *Chemical Engineer's Handbook*. New York, NY: McGraw-Hill, 1973:29-32, ISBN/ISSN 0070494797
- Rezaie-Majd A.; Bigenzahn W. & Denk D.; et al. (2006). Superimposed high-frequency jet ventilation (SHFJV) for endoscopic laryngotracheal surgery in more than 1500 patients. *Br J Anaesth*, Vol.96, No.5, (March 2006), pp.650-9, ISSN 0007-0912
- Richards SD, Kaushik V, Rothera MP et al.(2005). A tubeless anaesthetic technique for paediatric laryngeal laser surgery. *Int J Pediatr Otorhinolaryngol*, Vol.69, No.4, (April 2005), pp. 513-516, ISSN:0165-5876
- Sameh I., Usama A., Wael A. (2005). Inhaled foreign bodies: management according to early or late presentation. *European Journal of Cardio-thoracic Surgery*, Vol. 28, No.3, (September 2005), pp.369-374, ISSN 1010-7940
- Shikowitz M.; Abramson A. & Liberatore L.(1991). Endolaryngeal jet ventilation: a 10- year review. *Laryngoscope*, Vol.101, No.5, (May 1991), pp.455-461, ISSN 0023-852X
- Sırmalı M.; Türüt , H. & Kısacık E. et al.(2005). The Relationship between Time of Admittance and Complications in Paediatric Tracheobronchial Foreign Body Aspiration. *Acta chir belg*, Vol.105, pp. 631-634, ISSN:0001-5458

- Soodan A.; Pawar D. & Subramaniam R. (2004). Anaesthesia for removal of inhaled foreign bodies in children. *Pediatr Anaesth*, Vol.14, No.11, (November 2004), pp.947-52, ISSN 1155-5645
- Sosis M. (2004). Should CO2 laser jet ventilation be abandoned? *Anesth Analg*, Vol. 99, No.6, (December 2004), pp.1882, ISSN 0003-2999
- Spoerel W.; Narayanan P. & Singh N. (1971). Transtracheal ventilation. *Br J Anesth*, Vol. 43, No.10, pp.932-939, ISSN 0007-0912
- Spoerel W. & Greenway R. (1973). Technique of ventilation during endolaryngeal surgery under general anaesthesia. *Can Anaesth Soc J*, Vol. 20, No.3, pp.369-377, ISSN 0008-2856
- Su-Mi S.; Woo S. & Jung E. et al. (2008). CT in Children With Suspected Residual Foreign Body in Airway After Bronchoscopy. *AJR*, vol.192, (September 2008.), pp.1744 - 1751, ISSN 0361-803X
- The Difficult Airway Society. Failed ventilation guidelines. 18.12.2010, Available from <http://www.das.uk.com/guidelines/cvci.html>
- Theroux M.; Grodecki V. & Reilly J.; et al. (1998). Juvenile laryngeal papillomatosis: scary anaesthesia. *Paediatr Anaesth*, Vol. 8, No.4, (July 1998), pp. 357-361, ISSN 1155-5645
- Tremblay L. & Slutsky A. (2000). Continuous gas flow and high frequency ventilation. In: Shoemaker WC, ed. *Textbook of Critical Care*, 4th edn. Philadelphia, PA: W.B. Saunders Company, pp.1297-1298, ISSN 0279-5442
- Vourc'h G.; Fischler M. & Michon F.; et al. (1983). Manual jet ventilation v. high frequency jet ventilation during laser resection of tracheo-bronchial stenosis. *Br J Anaesth*, Vol. 55, No.10, (October 1983), pp.973-975, ISSN 0007-0912
- Weisberger E. & Emhardt J. (1996). Apneic anesthesia with intermittent ventilation for microsurgery of the upper airway. *Laryngoscope*, Vol. 106, No.9, (September 1996), pp. 1099-1102, ISSN 0023-852X
- Yadav, S.; Singh, J. & Aggarwal, N.; et al. (2007). Airway foreign bodies in children: experience of 132 cases. *Singapore Med. J.*, Vol.48, No.9, (September 2007), pp. 850-853, ISSN 0037-5675

IntechOpen



Global Perspectives on Bronchoscopy

Edited by Dr. Sai P. Haranath

ISBN 978-953-51-0642-5

Hard cover, 240 pages

Publisher InTech

Published online 13, June, 2012

Published in print edition June, 2012

Bronchoscopy has become an essential part of modern medicine . Recent advances in technology have allowed integration of ultrasound with this tool. The use of lasers along with bronchoscopes has increased the therapeutic utility of this device. Globally an increasing number of pulmonary specialists, anaesthesiologists and thoracic surgeons are using the bronchoscope to expedite diagnosis and treatment. The current volume on bronchoscopy adds to the vast body of knowledge on this topic. The democratic online access to this body of knowledge will greatly increase the ease with which both trainees and expert bronchoscopists can learn more .The contributions from around the world cover the breadth of this field and includes cutting edge uses as well as a section on pediatric bronchoscopy . The book has been an effort by excellent authors and editors and will surely be a often reviewed addition to your digital bookshelf. . In summary, this book is a great testament to the power of collaboration and is a superb resource for doctors in training, ancillary team members as well as practicing healthcare providers who have to perform or arrange for bronchoscopy or the associated procedures.

How to reference

In order to correctly reference this scholarly work, feel free to copy and paste the following:

Shaoqing Li, Yuqi Liu and Fang Tan (2012). Manual Jet Ventilation Using Manujet III for Bronchoscopic Airway Foreign Body Removal in Children, Global Perspectives on Bronchoscopy, Dr. Sai P. Haranath (Ed.), ISBN: 978-953-51-0642-5, InTech, Available from: <http://www.intechopen.com/books/global-perspectives-on-bronchoscopy/manual-jet-ventilation-using-manujet-iii-for-bronchoscopic-airway-foreign-body-removal-in-childr>

INTECH
open science | open minds

InTech Europe

University Campus STeP Ri
Slavka Krautzeka 83/A
51000 Rijeka, Croatia
Phone: +385 (51) 770 447
Fax: +385 (51) 686 166
www.intechopen.com

InTech China

Unit 405, Office Block, Hotel Equatorial Shanghai
No.65, Yan An Road (West), Shanghai, 200040, China
中国上海市延安西路65号上海国际贵都大饭店办公楼405单元
Phone: +86-21-62489820
Fax: +86-21-62489821

© 2012 The Author(s). Licensee IntechOpen. This is an open access article distributed under the terms of the [Creative Commons Attribution 3.0 License](#), which permits unrestricted use, distribution, and reproduction in any medium, provided the original work is properly cited.

IntechOpen

IntechOpen