

# We are IntechOpen, the world's leading publisher of Open Access books Built by scientists, for scientists

4,800

Open access books available

122,000

International authors and editors

135M

Downloads

Our authors are among the

154

Countries delivered to

TOP 1%

most cited scientists

12.2%

Contributors from top 500 universities



WEB OF SCIENCE™

Selection of our books indexed in the Book Citation Index  
in Web of Science™ Core Collection (BKCI)

Interested in publishing with us?  
Contact [book.department@intechopen.com](mailto:book.department@intechopen.com)

Numbers displayed above are based on latest data collected.  
For more information visit [www.intechopen.com](http://www.intechopen.com)



# Cognitive Disturbances in Sneddon and Antiphospholipid Syndromes

M. Rahmani, M. El Alaoui Faris, M. Benabdeljlil and S. Aidi  
*Department of Neurology A and Neuropsychology  
Hôpital des Spécialités, University Mohammed V Souissi, Rabat,  
Morocco*

## 1. Introduction

Sneddon's syndrome is a rare disease defined by generalised livedo racemosa of the skin and recurrent stroke. It was first described in a patient in 1960 by Champion and Rook (Champion and Rook, 1960), and five years later Sneddon IB suggested the association of livedo and stroke in six new cases (Sneddon, 1965). Sneddon's syndrome may be differentiated according to the presence or absence of circulating antiphospholipid (aPL) antibodies: aPL-positive Sneddon's syndrome and aPL-negative or seronegative Sneddon's syndrome (Ulukaya et al, 2008). Approximately 40% of Sneddon's syndrome patients have aPL antibodies, raising the question of whether Sneddon's syndrome overlaps with primary antiphospholipid antibody syndrome (APS) and systemic lupus erythromatosis (SLE) (Geschwind et al, 1995). APS or Hughes syndrome is a systemic autoimmune disease consisting of thrombosis (venous and/or arterial) and/or pregnancy failure in association with persistent production of aPL antibodies (aPL): anticardiolipin antibodies (aCL) of immunoglobulin G (IgG) and IgM class, lupus anticoagulant (LA) causing prolongation of activated partial thromboplastin time, and/or B2 glycoprotein I antibodies of IgG and IgM class. Although there are overlapping manifestations between Sneddon's syndrome and APS, namely livedo and recurrent thrombotic events, their relationship remains controversial (Francès et al, 1999). Some authors consider aPL-positive Sneddon's syndrome as a primary APS while others support the idea that aPL antibodies are involved in the pathogenesis of Sneddon's syndrome (Fetoni et al, 2000; Hannon et al, 2010; Kalashnikova et al, 1990; Luvisotto Marinho et al, 2007; Sumi et al, 1999). In this article, we will review the clinical and neuropsychological features of Sneddon's syndrome and APS and focus on the seronegative Sneddon's syndrome although the majority of the published data does not make a distinction between seronegative and aPLpositive Sneddon's syndrome.

## 2. Sneddon's syndrome

Sneddon's syndrome occurs usually among women in their third decade. Most cases are sporadic, but some rare familial cases have been reported (Petee et al, 1994; Rebollo et al, 1983; Scott et al, 1986). Both autosomal dominant and recessive transmissions were noted (Mascarenhas et al, 2003). Livedo racemosa, introduced for the first time in 1907 by Ehrmann, is characterized by a striking violaceous netlike patterning of the skin similar to

the familiar livedo reticularis, from which it differs by its location (more generalized and widespread, non-infiltrated, found not only on the limbs but also on the trunk and/or buttocks), its shape (irregular, broken, circular segments) and its persistence with variation of ambient temperature (Uthman and Khamashta, 2006).

The pathogenesis of Sneddon's syndrome remains unclear and the proposed etiology varies from a hypercoagulate state to a primary inflammatory vasculopathy (De Reuck, 2009). The etiology of Sneddon's syndrome is not completely understood. Skin biopsies often fail to yield diagnostic arterial lesions. Selection of the correct biopsy site (seemingly uninvolved skin at the center of a livedo racemosa area), adequate biopsy size (1 to 2 cm), and serial sections are essential for detection of relevant vascular pathology (Zelger et al, 1992). Sensitivity of these biopsies increased from 27% with one biopsy to 80% with 3 biopsies (Wohlrab et al, 2001). Sepp et al, (1995) studied skin specimens of 18 patients with Sneddon's syndrome, and reported that CD3+, UCHL-1+ (ubiquitin carboxy-terminal hydroxylase L1) and HLA-DR+ cells constituted a significant proportion of the inflammatory infiltrate in the early stages, whereas in later stages, endothelial cells and leukocytes were scarce. These data confirmed the hypothesis that Sneddon's syndrome starts as an inflammatory and possibly immunologically mediated disorder, leading to a migration and proliferation of smooth cells of small arteries, resulting in a partial or complete narrowing of the vessel. Others studies did not find inflammatory abnormalities at skin biopsies (Wohlrab et al, 2001). In few studies, brain biopsies have not shown vasculitic or thrombotic changes (Boortz-Marx et al, 1995; Devuyst et al, 1996; Geschwind et al, 1995). The small number of pathological studies makes it difficult to determine whether Sneddon's syndrome is inherently an inflammatory vasculitic or occlusive thrombotic disease (Hannon et al, 2010).

Diagnosis of Sneddon's syndrome is based on the presence of skin livedo and neurological symptoms related to stroke. Neurological manifestations of Sneddon's syndrome range from motor deficit, aphasia, headache, vertigo and seizures (table 1) (Fetoni et al, 2000; Stockhammer et al, 1993; Tourbah et al, 1997). Intracerebral, subarachnoid and intraventricular hemorrhages have also been reported (Bayrakli et al, 2010; Kraemer et Berlitz, 2008; Luvisotto Marinho et al, 2007). Few case reports have described seronegative Sneddon's syndrome (Duval et al, 2009; Hanon et al, 2010; Luvisotto Marinho et al, 2007). To our knowledge, only two series have analyzed both patients suffering from Sneddon's syndrome with and without aPL (Francès et al, 1999; Tourbah et al, 1997). No correlation was noted between severity of neurological outcome and the positivity of aPL (Tourbah et al, 1997). No difference between these two subgroups concerning the mean age at first clinical cerebral event was observed (Francès et al, 1999). Seronegative Sneddon's syndrome seems to have larger fishnet pattern of livedo racemosa, less frequent seizures and slower progression (Francès et al, 1999; Hannon et al, 2010).

Sneddon's syndrome is a progressive condition, and the long-term functional status is usually related to the cumulative burden of repeated ischemic infarcts leading to mental deterioration and dementia. Prognosis of untreated Sneddon's syndrome is poor, and about half of the patients suffer long-term disability (Francès et al, 1999; Tourbah et al, 1997). The differential diagnosis should include other neurological diseases associating cutaneous alterations of vascular origin and stroke. One of these rare entities has been described by Divry and Van Bogaert in 1946 and called diffuse leptomenigeal angiomatosis. Divry Van Bogaert's syndrome (DVB) is characterised by recurrent strokes in young patients especially children,

preceded by livedo localized mainly on the face and distal extremities. Skin biopsies show no vasculitis, but an increased number of dermal vessels with smooth muscles fibers disposed around them is seen. Cerebral CT scan and MRI in DVB syndrome can be identical to Sneddon's syndrome. Cerebral angiography showing corticomeningeal angiomas with collateral vascular anastomosis and narrow and helicine vessels in the midcerebral arteries confirms the diagnostic of Divry Van Bogaert's disease (Guillot et al, 1994). Dego's disease also known as malignant atrophic papulosis, first described in 1942 by Degos, is an another rare syndrome, very similar to Sneddon's syndrome and characterised by thrombo-occlusive vasculopathy affecting the skin and various internal organs. In the skin, Dego's disease initially manifests with erythematous, pink or red papules. These papules heal to leave scars with pathognomonic, central, porcelain white atrophic centers and a peripheral telangiectatic rim leading to atrophy and ulcers of the skin. In the systemic form, gastrointestinal and central nervous system involvements are the most frequent complications (Jura et al, 1994).

Neurological signs	Stockhammer et al, 1995 17 cases	Tourbah et al, 1997 26 cases	Fetoni et al, 2000 9 cases
Motor deficit	70 %	73%	66%
Aphasia	35%	50%	-
Cognitives disorders	-	27%	11%
Neuro-ophtalmic signs	29%	30%	22%
Sensitives signs	76%	19%	-
Seizures	17%	19%	11%
Headache	82%	38%	-
Vertigo	47%	11%	11%
Pseudo-bulbar syndrome	11%	11%	-

Table 1. Neurological features of Sneddon's syndrome in different series

Limited data are available concerning cognitive dysfunction in Sneddon's syndrome. After several years of evolution, 77% of patients with Sneddon's syndrome exhibit signs of mild cognitive vascular impairment with loss of concentration ability, memory disturbances and/or frontal type of behavioral changes (De Reuck, 2009). To date, only three reports have mentioned a detailed psychometric study showing marked deficits in the tests of memory, concentration, attention, visual perception and visuo-spatial construction (Hannon et al, 2010; Montagné de la Roque and al, 2006; Weissenborn et al., 1996). Cognitive disorders especially impairments in concentration and memory are often observed in Sneddon's syndrome without any history of cerebral stroke (Adair et al, 2001; Maamar et al, 2007; Weissenborn et al, 1996; Wohlrab et al, 2006). Evolution of Sneddon's syndrome includes continued cognitive decline and progression of leukoencephalopathy, causing subcortical vascular dementia in 23% of cases and resulting often in disability to get a correct employment (kalashnikova et al, 1990; Kraemer et al, 2008; Maamar et al, 2007; Rebollo et al, 1983; Stephen et Ferguson, 1982; Stockhammer et al, 1993; Weissenborn et al, 1996). In 2003, Boesch et al, did not find this classical pattern of Sneddon's syndrome in a prospective six year follow up study. Results of their study suggest in contrast a low incidence of territorial stroke and dementia but outline progressive leucoencephalopathy. Dementia is caused by the recurrence of ischemic, rarely

hemorrhagic stroke and it is preceded in half of cases by a transient ischemic attack. The process that leads to neurological dysfunction seems to be both structurally destructive and functionally impairing with neuronal loss (Liberato and Levy, 2007). Rarely, dementia represents the initial symptom of Sneddon's syndrome (Flöel et al, 2002; Maamar et al, 2007).

In Sneddon's syndrome, stroke affects mainly medium-sized arteries and are seen particularly in the territory of the middle and posterior cerebral artery (Maamar et al, 2007; Stockhammer et al, 1993). Infarct of the vertebral basilar territory was present in 47% of cases among 17 patients described by Stockhammer et al in 1993. Basal ganglia are usually normal (Tourbah et al, 1997). Leucoencephalopathy constitutes a classical MRI finding in the evolution of Sneddon's syndrome, localized usually in the posterior subcortical white matter (Boesch et al, 2003; Tourbah et al, 1997). As reported by Tourbah et al in 1997 and Weissenborn et al in 1996, the extent of cerebral infarcts is significantly correlated with the severity of cognitive disorders. The progressive cognitive impairment in Sneddon's syndrome is also, correlated to the degree of white matter changes and the presence of lacunar infarcts (De Reuck, 2009). Moreover the cognitive dysfunction score is related to the brain atrophy score (Weissenborn et al, 1996) and the degree of physical impairment (Tourbah et al, 1997; Weissenborn et al, 1996). In contrast, the duration of the disease seems to have no influence on the degree of cognitive dysfunction (Weissenborn et al, 1996).

There is no current therapeutic consensus well established in the management of Sneddon's syndrome. In the absence of controlled studies, treatment of Sneddon's syndrome remains empirical. Antiplatelets agents and anti-coagulant treatment are most often used. Corticosteroids, azathioprine and cyclophosphamid were administered by some with little success (Zelger et al, 1993). Few reports noted potential therapeutic options for cognitive disorder in Sneddon's syndrome patients, but generally, these studies did not demonstrate objective improvements on neuropsychological evaluation. Kume et al (1996) treated a 24-year-old man using cyclophosphamide, prednisolone with improvement of psychiatric symptoms and a decreased anticardiolipin level. However, mental abilities remained subnormal. No objective neuropsychological testing was performed. Flöel et al (2002) also reported a 29-year-old woman with Sneddon's syndrome who continued to decline cognitively when treated with steroids, azathioprine and aspirin. The therapy was switched to aspirin plus clopidogrel and the regimen stabilized cognitive function on neuropsychological tests. One other study confirmed subsequent improvement in subjective and objective memory and emotional status in a 46 years old woman suffering from seronegative Sneddon's syndrome using a treatment with cyclophosphamide during 8 months. Authors have suggested therefore that cyclophosphamide should be considered among first line treatment options for patients with Sneddon's syndrome and cognitive impairment (Hannon et al, 2010).

### **3. Antiphospholipid antibody syndrome**

APS is an autoimmune disorder in which autoantibody production can lead to a hypercoagulable state, pregnancy failure and/or a multitude of other systemic manifestations. APS has previously been divided into primary and secondary forms, these last are associated with other connective tissue diseases, mainly SLE. However, this distinction was abandoned in the new classification (The 2006 Sydney Revised Classification Criteria based on the preliminary international Sapporo 1999) (table 2).



<p>Diagnostic criteria for antiphospholipid syndrome</p> <p>Clinical criteria</p> <ul style="list-style-type: none"> <li>- Vascular thrombosis: one or more episodes of arterial, venous or small vessel thrombosis in any tissue or organ (confirmed by imaging or histopathology)</li> <li>- Recurrent pregnancy loss (1 &gt; 10 weeks' gestation, or 3 &lt; 10 weeks' gestation) or one or more premature births due to pregnancy complications</li> </ul> <p>Laboratory criteria</p> <ul style="list-style-type: none"> <li>- Lupus anticoagulant in plasma on two occasions at least 12 weeks apart</li> <li>- Anticardiolipin antibodies of IgG and/or IgM isotype on two occasions at least 12 weeks apart</li> <li>- Anti-b2-GPI antibody of IgG or IgM isotype on two occasions at least 12 weeks apart</li> </ul> <p>Antiphospholipid syndrome is considered to be definitely present when at least one clinical criterion and one laboratory criterion are met. Ig: immunoglobulin; GPI: glycoprotein-I.</p>
---

Table 2. Diagnostic criteria for APS based on the 2006 Sydney update of the 1999 Sapporo classification (Austin and Cohen, 2010)

In addition to peripheral thrombosis affecting any size of vessels, a variety of clinical manifestations is reported: skin disease, cardiac, pulmonary and renal involvement, haematologic manifestations and wide spectrum of neurological disorders (Mayer et al, 2010). Thrombocytopenia is variably present. Neurological features of APS are dominated by the presence of ischaemic stroke which is the most common neurological manifestation (>50% of CNS complications). Other reported neurological manifestations include cerebral venous thrombosis, migraines, seizures, chorea, transverse myelitis and multiple sclerosis like syndrome (Austin and Cohen, 2010). Two clinical subgroup of APS are now identified. Catastrophic APS is characterized by life-threatening acute multiple organ failure from extensive microvascular thrombosis ('thrombotic storm'). Laboratory evidence of disseminated intravascular coagulation can occur. Suggested precipitants of this syndrome include infection, oral contraceptives, surgery and withdrawal of anticoagulation. The mortality rate is approximately 50%. The second subset is called Seronegative APS which includes patients exhibiting clinical manifestations of APS, without any recognized aPL. Subsequent repeat aPL testing can be positive (Austin and Cohen, 2010).

Several studies suggest an association between aPL and cognitive dysfunction based on microthrombotic events or vasculopathy. The underlying mechanism of cognitive deficits is not clear. Hypothesis of recurrent cerebral ischemia or a direct effect of aPL disrupting neuronal function, like it is shown in experimental studies on animal models has been issued (Katzav et al, 2001).

The majority of studies concerning cognition in APS patients included also cases of SLE with aPL. Although there have been no studies to date that have accurately identified the frequency of neuropsychological manifestations in APS, studies in SLE patients with or without aPL provide excellent models for the analysis of neurocognitive dysfunction (Erkan et al, 2011).

Results of several series indicated that a majority of patients with APS (combined primary and SLE-related APS) had cognitive deficits affecting like in Sneddon's syndrome, mainly memory, concentration, complex attention and verbal fluency (Tektonidou et al, 2006).

Two studies have examined the cognitive function in primary APS patients compared to controls or other patient groups. Jacobson et al (1999) examined neuropsychological functioning in 27 young patients with elevated levels (>10 IU) of aCL IgG. Compared with 27 age and education-matched controls, there were group differences in domain scores of working memory, executive functions, verbal learning, memory and visuospatial functioning. The overall frequency of impaired neuropsychological performance was greater among individuals with aPL than controls (33% versus 4% respectively) suggesting subtle neurological involvement. Tektonidou et al (2006), examined 39 patients with primary APS, 21 patients with SLE-related APS and 60 healthy controls using a neuropsychological battery measuring attention, learning, memory, executive functions and visuospatial skills and depression. Results indicated that 42% of the 60 patients with APS (combined primary and SLE-related APS) had cognitive deficits compared with 18% of healthy controls with deficits most common in complex attention and verbal fluency. There was no difference in cognitive performance between patients with primary APS and those with SLE-associated APS (Erkan et al, 2011). Maeshima et al (1992) analyzed 21 SLE patients with aPL and noted abnormal findings in verbal learning and visuoconstructive skills in 72% of patients. Otherwise, LA positive patients had poor results in verbal memory, attention, cognitive flexibility and psychomotor speed tests in comparison with LA negative patients (Denburg et al, 1997; Leritz et al, 2000; Menon et al, 1999). Positive LA test has been found to be more frequent (15,7%) in SLE patients with cognitive disorder compared to the SLE patients without cognitive impairment (Sanna et al, 2003). Hanley et al (2004) reported also that patients with persistently elevated IgG aCL had a significant decline in psychomotor speed, while those with persistently elevated IgA aCL had decline in conceptual reasoning and executive ability.

Chapman et al (2002) studied 23 patients with primary APS and found that 13 (56%) fulfilled criteria for vascular dementia. Patients with dementia were older, had more CT scan abnormalities and more electroencephalography changes than those without dementia. The "Euro-Phospholipid consortium", did not find the same results in their cohort of 1000 APS patients, only 25 cases (2,5%) had vascular dementia.

Other studies of primary APS or asymptomatic aPLpositive patients have shown that cognitive deficits may be present independent of any history of known central nervous system involvement. These patients may complain of difficulty with memory, attention, and concentration; or the dysfunction may be subclinical and apparent only with neuropsychological testing (Austin and Cohen, 2010; Erkan et al, 2011). Erkan et al, (2010) in a 10-years follow-up study of 66 patients with primary APS, found that 3 patients (<30 years old) developed dementia, independently of the presence of cerebrovascular accidents. In a recent study of 25 patients with APS followed between 1983 and 2003, previous history of stroke and/or transient ischemic stroke was present respectively in only 11 and 2 patients, whereas, silent brain infarcts were present in 14 (47%) patients. Dementia was the presenting manifestation of the APS in 11 (37%) patients (Gomez-Puerta et al, 2005).

Although relatively few studies have been conducted, neuroimaging abnormalities have been reported in primary APS patients presenting with high levels of overt clinical

neurological and psychiatric syndromes. Infarcts and hyperintense white matter foci are the most common abnormalities seen on cerebral CT scan or MRI in APS patients. However, most neuroimaging studies reported include patients with both APS and lupus (Erkan et al, 2011).

Cortical and subcortical infarcts are the most frequent findings. Gomez-Puerta et al (2005) studied neuroimaging findings in combined lupus/APS group of 30 patients and reported cortical infarcts in 63% of patients, subcortical infarcts in 30%, basal ganglia infarcts in 23% and signs of cerebral atrophy in 37%. Other ischaemic lesions such as lacunar and periventricular infarcts are not uncommon. Cerebral atrophy and white matter lesions (leukoaraiosis), similar to the lesions found in Binswanger's disease, are often seen, especially in elderly APS patients (Gomez-Puerta et al, 2005). Chapman et al (2002) reported that only half of their demented APS patients had abnormal CT scans and suggested that the demented APS patients with normal CT scans may have micro-lesions. Of those with dementia, six had generalized atrophy and seven of the scans had focal lesions consistent with vascular pathology.

Only one study of primary APS patients has investigated MRI abnormalities and their relation to cognitive dysfunction. Significant correlation between cognitive dysfunction and the presence of white matter lesions was reported in APS patients with and without central nervous system involvement. In 23 APS patients with central nervous system involvement, 12 patients (52%) had white matter lesions with 100% in the periventricular area. Of the 36 APS patients without central nervous system involvement, 8 (22%) of the patients had white matter lesions with 88% in the periventricular location. Cognitive deficits were identified in 7 of those patients. A significant correlation was reported between cognitive deficits and white matter lesions across the two groups (Tektonidou et al, 2006). MRI spectroscopy is a predictive tool when compared to conventional parenchymal MRI in patients with APS, cognitive decline and normal brain MRI. These results corroborate the impression of subclinical neuronal damage induced by disease activity. When multimodal imaging techniques are used assessing not only neurometabolic patterns (MR spectroscopy), but also perfusion (SPECT) and morphological abnormalities (conventional MRI), the predictive power seems to be increased (Liberato and Levy, 2007). Kao et al (1999) studied 22 patients with primary APS with only mild neuropsychiatric manifestations (headache, depression, personality disorders, memory loss and cognitive function deficits) and normal brain MRI. They found that 16 (73%) of the patients had abnormal SPECT findings, mainly diffuse hypoperfusion lesions in cerebral cortex.

Management of APS consists of initial therapy with low molecular weight heparin followed by oral anticoagulation. The duration of therapy depends on any additional risk factors, the location, severity, patient age and the relative risk of further thrombosis versus haemorrhage due to anticoagulation. Several strategies have been suggested for the treatment of dementia in APS patients. The management of atherogenic risk factors (i.e. diabetes, hypertension, hyperlipidaemia) is crucial. However, there is still no evidence that aspirin alone is effective in treating patients with a diagnosis of dementia. Some findings of improvement of cognitive function in the APS patients who underwent anticoagulation therapy have been reported (Hughes et al, 2001). In dementia associated with APS, anticoagulant treatment is recommended. Furthermore, the compliance of demented patients is usually poor, which requires special thought and attention (Gomez-Puerta et al, 2005).



In conclusion, seronegative Sneddon's syndrome should be distinguished from Sneddon's syndrome with aPL which should be considered as a subgroup of APS. Cognitive disorders in both Sneddon's syndrome and APS seem to be similar affecting mainly memory, attention and concentration functions. They represent sometimes the inaugural symptom in a patient without any history of known ischemic stroke. Recurrent stroke may lead to multi-infarct dementia and early retirement in young people. Prognosis depends on early diagnosis. More subtle cognitive dysfunction can be shown. These troubles are related to posterior cortical infarcts or to leucoencephalopathy. Treatment should be aggressive in case of cognitive disturbances in Sneddon's syndrome or APS.

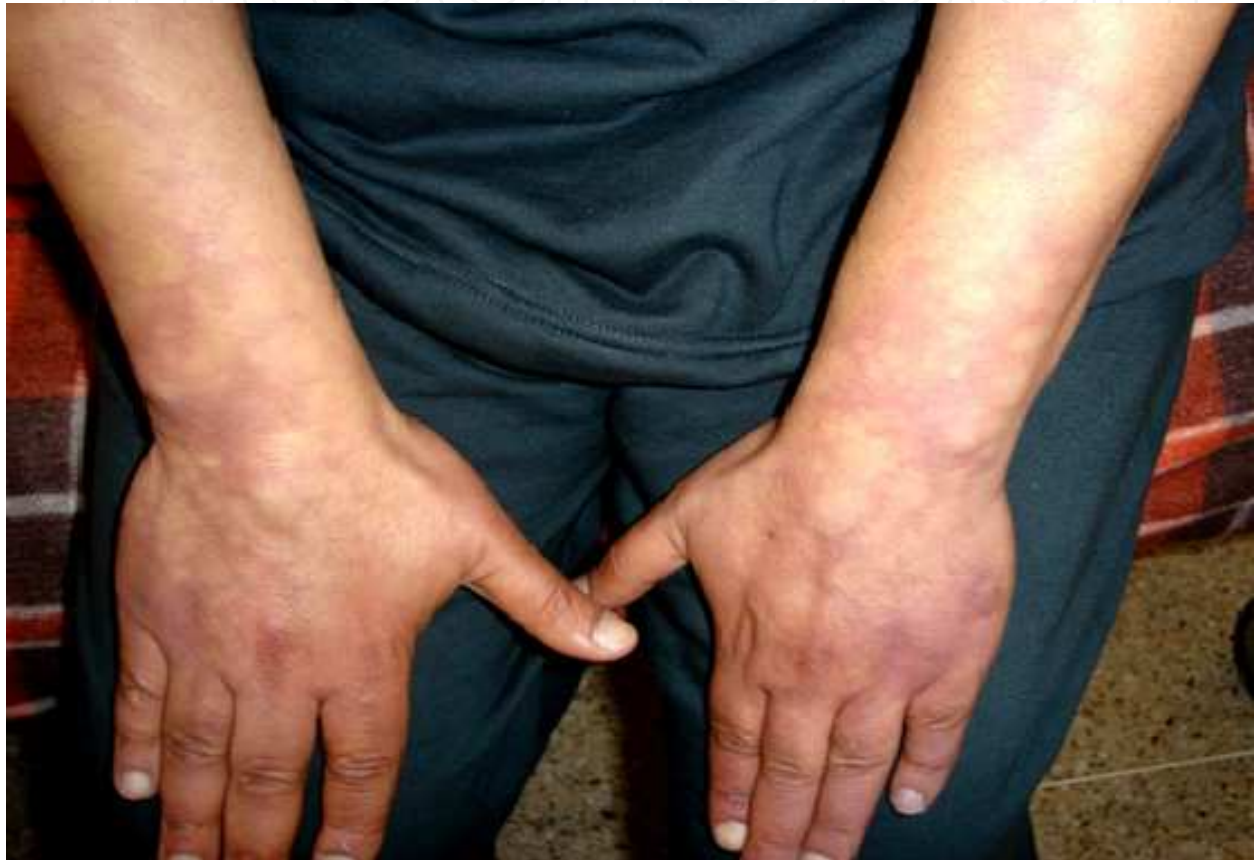

Fig. 1. Livedo racemosa affecting upper limbs in a patient with Sneddon's syndrome (personal figure)

#### 4. References

- Adair JC, Digre KB, Swanda RM, Hartshorne MF, Lee RR, Constantino TM, et al. Sneddon syndrome: a cause of cognitive decline in young adults. *Neuropsychiatry, Neuropsychology, and Behavioral Neurology* (2001);14:197-204.
- Austin S and Cohen H. Antiphospholipid syndrome. *Medicine* (2010); 38,2:101-104.
- Bayrakli F, Erkek E, Kurtuncu M, Ozgen S. Intraventricular Hemorrhage as an Unusual Presenting Form of Sneddon Syndrome. *World Neurosurg* (2010) 73, 4:411-413.

- Boesch SM, P Plörer AL, Auer AJ J and al. The natural course of Sneddon's syndrome: clinical and magnetic resonance imaging findings in a prospective six year observation study. *J Neurol Neurosurg Psychiatry* (2003); 74:5 42-5 44.
- Boortz-Marx RL, Clark HB, Taylor S, Wesa KM, Anderson DC. Sneddon's syndrome with granulomatous leptomeningeal infiltration. *Stroke* (1995);26:492-5.
- Champion RH, Rook A. Livedo reticularis. *Proc R Soc Med* (1960);53:961-962.
- Chapman J, Abu-Katash M, Inzelberg R et al. Prevalence and clinical features of dementia associated with the antiphospholipid syndrome and circulating anticoagulants. *J Neurol Sci* (2002); 203 - 204:81 - 4.
- Denburg SD, Carbotte RM, Denburg JA. Psychological aspects of systemic lupus erythematosus: cognitive function, mood, and self-report. *J. Rheumatol.* 24 (1997) 998-1003.
- De Reuck J.L. Sneddon's syndrome. *Journal of the Neurological Sciences* 283 (2009) 240-320.
- Devuyt G, Sindic C, Laterre E. Neuropathological findings of a Sneddon's syndrome presenting with dementia not preceded by clinical cerebrovascular events. *Stroke* (1996);27:1008-9.
- Duval A, Darnige L, Glowacki F, Copin MC, Martin De Lassalle E, Delaporte E and Eric Auxenfants E. Livedo, dementia, thrombocytopenia, and endotheliitis without antiphospholipid antibodies: Seronegative antiphospholipid-like syndrome. *J Am Acad Dermatol*, (2009) 61, 6: 1076-1078.
- Erkan D, Kozora E, Lockshin MD. Cognitive dysfunction and white matter abnormalities in antiphospholipid syndrome. *Pathophysiology* 18 (2011) 93-102.
- Ehrmann S. Ein Gefaessprozess Bei Lues. *Wien Med Wochenschr* (1907); 57:777-82.
- Fetoni V, Grisoli M M, S Salmaggi A, Carriero R, Girotti F. Clinical and neuroradiological aspects of Sneddon's syndrome and primary antiphospholipid antibody syndrome: a follow-up study. *Neurol S Sci* (2000); 21: 157-164.
- Flöel A, Imai T, Lohmann H, Bethke F, Sunderkötter C, Droste DW. Therapy of Sneddon's syndrome. *Eur Neurol* (2002);48: 126- 132.
- Francès C, Papo T, Wechsler B, Laporte JL, Biousse V, Piette JC. Sneddon syndrome with or without antiphospholipid antibodies. A comparative study in 46 patients. *Medicine* (1999);78:209-19.
- Geschwind DH, FitzPatrick M, Mischel PS, Cummings JL. Sneddon's syndrome is a thrombotic vasculopathy: neuropathologic and neuroradiologic evidence. *Neurology* (1995);45:557-60.
- Gomez-Puerta JA, Cervera R, Calvo LM, Gomez-Anson B, Espinosa G. Dementia associated with the antiphospholipid syndrome: clinical and radiological characteristics of 30 patients. *Rheumatology (Oxford)* 44 (2005) 95-99.
- Guillot D, Salamand P, Tomasini P, Briant JF, Brosset C. Accidents vasculaires cérébraux ischémiques du sujet jeune et livedo réticulaire. A propos d'un cas de syndrome de Sneddon ou de Divry-Van Bogaert. *Annales de Radiologie* (1994); 37: 281-5.
- Hanly JG, McCurdy G, Fougere L, Douglas J, Thompson K. Neuropsychiatric events in systemic lupus erythematosus: attribution and clinical significance. *J Rheumatol* (2004); 31:2156-62.

- Hannon PM, Kuo SH, Strutt AM, York MK, Kass JS. Improvement of neurological symptoms and memory and emotional status in a case of seronegative Sneddon syndrome with cyclophosphamide. *Clinical Neurology and Neurosurgery* 112 (2010) 544-547.
- Hughes GR, Cuadrado MJ, Khamashta MA, Sanna G. Headache and memory loss: rapid response to heparin in the antiphospholipid syndrome. *Lupus* (2001);10:778.
- Jacobson MW, Rapport LJ, Keenan PA, Coleman RD, Tietjen GE. Neuropsychological deficits associated with antiphospholipid antibodies. *J. Clin. Exp. Neuropsychol.* (1999) 21: 251-264.
- Jura E, Palasik W, Meurer M, Palester-Chlebowczyk M, Czlonkowska A. Sneddon's syndrome (livedo reticularis and cerebrovascular lesions) with antiphospholipid antibodies and severe dementia in a young man: a case report. *Acta Neurol Scand* (1994), 89: 143-146.
- Kalashnikova LA, Nasonov EL, Kushekbaeva AE, Gracheva LA. Anticardiolipin antibodies in Sneddon's syndrome. *Neurology* (1990);40(3 Pt 1): 464-467.
- Kao CH, Lan JL, Hsieh JF and al. Evaluation of regional cerebral blood flow with 99mTc-HMPAO in primary antiphospholipid antibody syndrome. *J Nucl Med* (1999);40:1446 - 50.
- Katzav A, Pick CG, Korczyn AD, Oest E, Blank M, Shoenfeld Y, Chapman J. Hyperactivity in a mouse model of the antiphospholipid syndrome. *Lupus* 10 (2001) 496-499.
- Kraemer M and Berlitz P. Cerebral haemorrhage as the presenting form of Sneddon's syndrome. *Clinical Neurology and Neurosurgery* (2008) 110 : 532-533.
- Kume M, Imai H, Motegi M, Miura AB, Namura I. Sneddon's syndrome (livedo racemosa and cerebral infarction) presenting psychiatric disturbance and shortening of fingers and toes. *Internal Medicine* (1996);35:668-73.
- Leritz E, Brandt J, Minor M, Reis-Jensen F, Petri M. Subcortical cognitive impairment in patients with systemic lupus erythematosus. *J.Int. Neuropsychol. Soc.* (2000) 6: 821-825.
- Liberato B and Levy RA. Antiphospholipid Syndrome and Cognition. *Clinic Rev Allerg Immunol* (2007) 32:188-191.
- Luvisotto Marinho J, Juliato Piovesan E, Pereira Leite Neto M, Kotze LR, De Noronha L, Twardowschy CA, Lange MC, Scola RH, Flumignan Zétola VH, NÓvak EM, Werneck LC. Clinical, neurovascular and neuropathological features in Sneddon's syndrome. *Arq Neuropsiquiatr* (2007);65(2-B):390-395.
- Maamar M, Rahmani M, Aidi S, Benabdeljlil M, El Hassani My R, Jiddane M, Hicham CH, El Alaoui-Faris M. Sneddon's syndrome: study of 15 cases with cerebral arteriography. *Rev Neurol (Paris)* 2007; 163 : 8-9, 809-816.
- Maeshima E, Yamada Y, Yukawa S, Nomoto H. Higher cortical dysfunction, antiphospholipid antibodies, and neuroradiological examinations in systemic lupus Erythematosus. *Intern. Med.* (1992) 31:1169-1174.
- Mascarenhas R, Santo G, Gonçalo M, Ferro Ma,Tellechea O, Figueiredo A. Familial Sneddon's syndrome. *Eur J Dermatol* (2003); 13: 283-7.
- Mayer M, Ceroveca M, Rados M, Cikes N. Antiphospholipid syndrome and central nervous system. *Clinical Neurology and Neurosurgery* (2010)112: 602-608.


- Menon S, Jameson-Shortall E, Newman SP, Hall-Craggs MR, Chinn R, Isenberg DA. A longitudinal study of anticardiolipin antibody levels and cognitive functioning in systemic lupus erythematosus. *Arthritis Rheum* (1999); 42:735-41.
- Montané de la Roque P, Michard JF, Pinganaud-Shrestha C, About I, Campistron E, Malick-Loiseau C, Bories L, Rochet N, Denat S. Dementia revealing a Sneddon's syndrome. *Rev Med Interne*. (2006); 27(2):162-4. Epub 2005 Nov 10.
- Pettee AD, Wasserman BA, Adams NL, McMullen W, Smith HR, Woods SL, Ratnoff OD. Familial Sneddon's syndrome: clinical, hematologic and radiographic findings in two brothers. *Neurology* (1994); 44: 399-405.
- Rebollo M, Val JF, Garijo F, Quintana F, Berciano J. Livedo reticularis and cerebrovascular lesions (Sneddon's Syndrome). *Brain* (1983), 106: 965-979.
- Sanna G, Bertolaccini ML, Cuadrado MJ, Liang H, Khamashta MA. Neuropsychiatric manifestations in systemic lupus erythematosus: prevalence and association with antiphospholipid antibodies. *J. Rheumatol.* (2003)30: 985-992.
- Scott IA, Boyle RS. Sneddon's syndrome. *Aust NZ J Med* (1986); 16: 799-802.
- Sepp N, Zelger B, Schuler G, Romani N, Fritsch P. Sneddon's syndrome-an inflammatory disorder of small arteries followed by smooth muscle proliferation. Immunohistochemical and ultrastructural evidence. *Am J Surg Pathol* (1995);19:448-53.
- Sneddon IB. Cerebrovascular lesions and livedo reticularis. *Br J Dermatol* (1965);77:180-185.
- Stephens WP, Ferguson JT. Livedo reticularis and cerebrovascular disease. *Postgrad Med J* (1982), 58: 70-73.
- Stockhammer G, Felber SR, Zelger B et al. Sneddon's syndrome: diagnosis by skin biopsy and MRI in 17 patients. *Stroke* (1993); 24:6 85-690.
- Sumi Y, Ozaki Y, Itoh S, Katayama H, Tanaka S. Cerebral blood flow-SPECT in a patient with Sneddon's syndrome. *Ann Nucl M Med* (1999); 13: 109- 112.
- Tektonidou MG, Varsou N, Kotoulas G, Antoniou A, Moutsopoulos HM. Cognitive deficits in patients with antiphospholipid syndrome: association with clinical, laboratory, and brain magnetic resonance imaging findings. *Arch. Intern. Med.* (2006) 166: 2278-2284.
- Tourbah A, Piette JC, Benoît N, Iba-Zizen MT, Lyon-Caen O, Francès C. Clinical, biological and neuroradiological aspects of Sneddon's syndrome: 26 cases. *Rev Neurol (Paris)*. (1997) Nov;153(11):652-8.
- Ulukaya S, Makay O, Icoz G, Demir F, Sezer T. Perioperative management of Sneddon syndrome during thyroidectomy. *Journal of Clinical Anesthesia* (2008) 20, 458-461.
- Uthman IW and Khamashta MA. Livedo Racemosa: A Striking Dermatological Sign for the Antiphospholipid Syndrome. *The Journal of Rheumatology* (2006); 33:12.
- Weissenborn K, Rückert N, Ehrenheim C, Schellong S, Goetz C, Lubach D. Neuropsychological deficits in patients with Sneddon's syndrome. *J Neurol.* (1996); 243(4):357-63.
- Wohlrab J, Fischer M, Wolter M, Marsch WC. Diagnostic impact and sensitivity of skin biopsies in Sneddon's syndrome. A report of 15 cases. *Br J Dermatol* (2001); 145:285-8.

- Wohlrab J, Francès C, Sullivan KE. Strange symptoms in Sneddon's syndrome. *Clin Immunol.* 2006;119(1):13-5. Epub 2005 Nov 28.
- Zelger B, Sepp N, Schmid KW, Hintner H, Klein G, Fritsch PO. Life history of cutaneous vascular lesions in Sneddon's syndrome. *Hum Pathol* (1992); 23:668-75.

IntechOpen

IntechOpen





## **Neuroscience**

Edited by Dr. Thomas Heinbockel

ISBN 978-953-51-0617-3

Hard cover, 138 pages

**Publisher** InTech

**Published online** 23, May, 2012

**Published in print edition** May, 2012

If one asks what neuroscience is, the answer can be found in this book. Neuroscience embraces not only anatomical and physiological studies but also cell biology, computer science, and biochemistry. Equally important for neuroscientific research are other disciplines, such as psychology, psychiatry, neurology and additional recent ones, such as neuroeconomics and social neuroscience. This book comprises chapters on diverse topics in neuroscience ranging from cellular, computational, cognitive, and clinical neuroscience. Individual chapters focus on recent advances in specific areas including social neuroscience, which is a relatively new field that studies the neural basis of social interactions. Other chapters focus on technological developments such as optical tools to study the function of the brain. All chapters represent recent contributions to the rapidly developing field of neuroscience and illustrate the range of research conducted under the umbrella of the truly interdisciplinary neurosciences.

### **How to reference**

In order to correctly reference this scholarly work, feel free to copy and paste the following:

M. Rahmani, M. El Alaoui Faris, M. Benabdeljilil and S. Aidi (2012). Cognitive Disturbances in Sneddon and Antiphospholipid Syndromes, *Neuroscience*, Dr. Thomas Heinbockel (Ed.), ISBN: 978-953-51-0617-3, InTech, Available from: <http://www.intechopen.com/books/neuroscience/cognitive-disturbances-in-sneddon-and-antiphospholipid-syndromes>

**INTECH**  
open science | open minds

#### **InTech Europe**

University Campus STeP Ri  
Slavka Krautzeka 83/A  
51000 Rijeka, Croatia  
Phone: +385 (51) 770 447  
Fax: +385 (51) 686 166  
[www.intechopen.com](http://www.intechopen.com)

#### **InTech China**

Unit 405, Office Block, Hotel Equatorial Shanghai  
No.65, Yan An Road (West), Shanghai, 200040, China  
中国上海市延安西路65号上海国际贵都大饭店办公楼405单元  
Phone: +86-21-62489820  
Fax: +86-21-62489821

© 2012 The Author(s). Licensee IntechOpen. This is an open access article distributed under the terms of the [Creative Commons Attribution 3.0 License](#), which permits unrestricted use, distribution, and reproduction in any medium, provided the original work is properly cited.

IntechOpen

IntechOpen