

We are IntechOpen, the world's leading publisher of Open Access books Built by scientists, for scientists

4,800

Open access books available

122,000

International authors and editors

135M

Downloads

Our authors are among the

154

Countries delivered to

TOP 1%

most cited scientists

12.2%

Contributors from top 500 universities



WEB OF SCIENCE™

Selection of our books indexed in the Book Citation Index
in Web of Science™ Core Collection (BKCI)

Interested in publishing with us?
Contact book.department@intechopen.com

Numbers displayed above are based on latest data collected.

For more information visit www.intechopen.com



Balloon-Kyphoplasty for Vertebral Compression Fractures

Luca Arpino and Pierpaolo Nina

*Department of Neurosurgery, San Giovanni Bosco Hospital, Naples
Italy*

1. Introduction

1.1 Overview

A Vertebral Compression Fracture (VCF) is a collapse of one or more vertebrae. This usually results from a combination of bending forward and downward pressure on the spine. These fractures happen most commonly in the thoraco-lumbar spine, particularly in the lower vertebrae of the thoracic spine.

1.2 Causes

In relation to etiopathogenesis, VCFs may be divided into:

- pathologic fractures, as for:
 - *osteoporosis* (the most common cause: about 750,000 people per year in United States): in people with severe osteoporosis, a VCF may be caused by simple daily activities, such as stepping out of the shower, sneezing vigorously or lifting a light object;
 - *metastatic tumors*;
 - *multiple myeloma*;
 - *vertebral hemangiomas*;
- traumatic fractures, which can occur with a fall on the feet or buttocks, a forceful jump, a car accident or any event that stresses the spine past its breaking point.

1.3 Symptoms

VCFs may occur suddenly, causing severe back pain, generally referred to mid or lower part of the spine; this pain is most commonly described as “knifelike” and usually disabling. Clinical examination usually shows tenderness to the touch over the affected vertebra/vertebrae.

If the VCF is severe, the nerves and spinal cord can be affected, which can lead to nerve irritation and inflammation.

1.4 Imaging

While a diagnosis can usually be made through history and a clinical examination, X-ray and CT-scan (as first-step diagnosis in Emergency Room) or MRI and bone densitometry

can help in confirming diagnosis, predicting prognosis, and determining the best treatment option for this patient.

1.5 Balloon-kyphoplasty (BKP) technique

BKP is a percutaneous vertebral augmentation technique initially developed to treat osteoporotic VCFs. It is a minimally invasive procedure: a small incision is made in the back through which the surgeon places a hollow tube called *trocar*. Using fluoroscopy to guide it to the correct position, the trocar creates a path into the fractured area through the pedicle of the involved vertebrae (*fig1*):

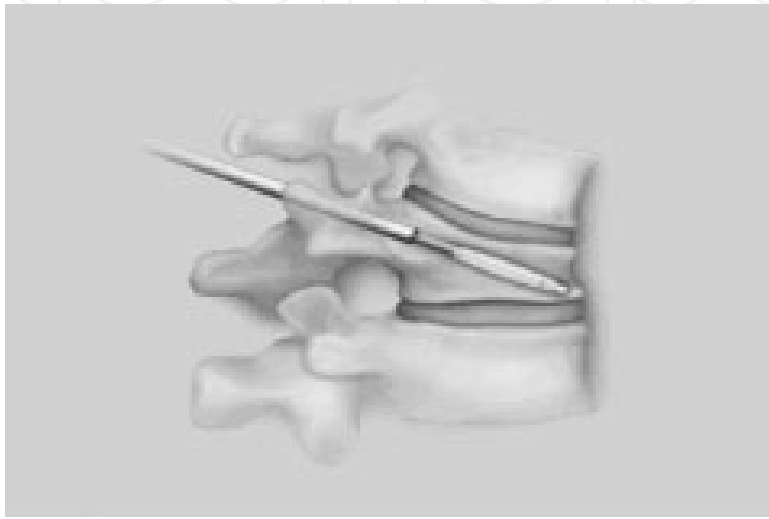


Fig. 1. Trocar insertion

Then a special balloon is inserted through the trocar into the vertebra and it is gently inflated by the surgeon (*fig2*):

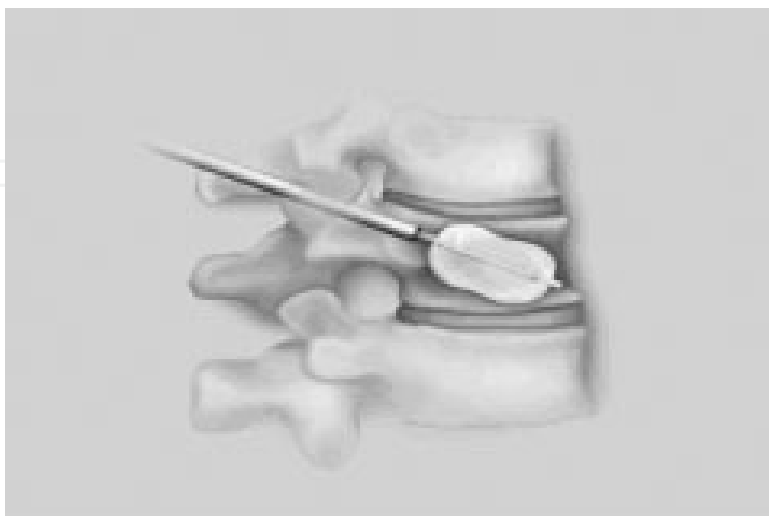

Fig. 2. Balloon inflation

As the balloon inflates, fractured vertebra is elevated while its inner cortical bone is compacted: so a cavity into the vertebra is created (*fig3*):

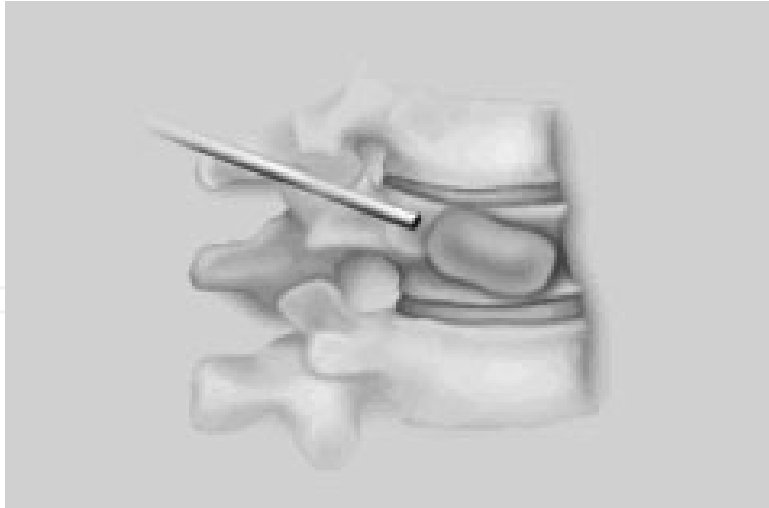


Fig. 3. Void filling by bone cement

Finally, the balloon is removed and the surgeon fills the cavity with bone cement in order to achieve fracture stabilization and body height restoration (*fig4*):

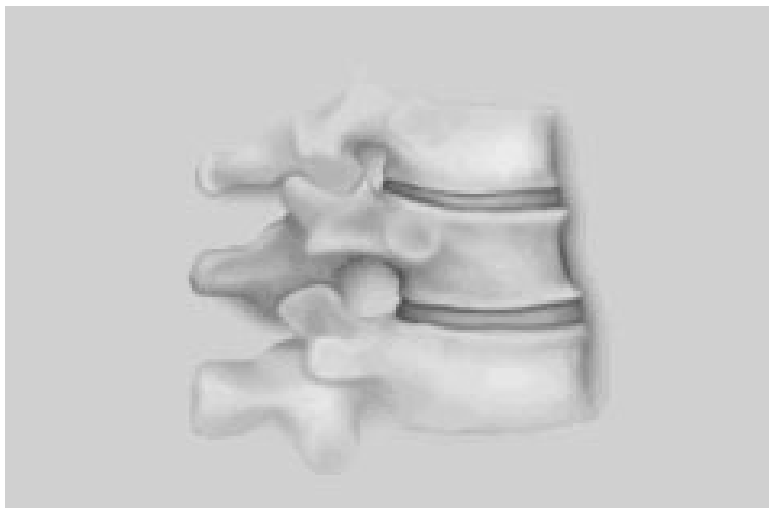


Fig. 4. Fracture stabilization

2. Alternative procedures

According to kind of VCF, related symptoms and health conditions, there are many ways to treat these fractures.

When permitted by a doctor, self-care at home, taking rest, with a back brace and/or using medications (nonsteroidal anti-inflammatories, narcotics or muscle relaxants) may be enough in case where pain is not so severe, neurological examination is negative and radiological tests show minor VCF.

On the other hand, admission to the hospital is necessary when pain or symptoms are severe. Surgery (major or mini-invasive spinal surgery depending on VCF degree) may be required to prevent the spine from pressing on the spinal cord or to stabilize the vertebra adjacent to the fracture site. When spinal cord compression is not a risk and neurological

examination is negative instead, percutaneous techniques such as vertebroplasty or *vertebral augmentation techniques* such as BKP or stentoplasty are enough.

Unlike BKP, in **vertebroplasty** bone cement is injected into the vertebra at high pressure and *free*: so cement-leakage rate is higher, especially if there are many fracture cracks, such as for traumatic VCFs [Schmelzer et al, 2009]. In his meta-analysis on 69 clinical studies, Hulme [Hulme et al, 2006] reported leakage rates in 41% of cases during vertebroplasty and in 9% of cases during BKP. While most leaks were clinically asymptomatic, clinical complications (i.e. major complications) occurred in 3.9% and 2.2% of the vertebroplasty and kyphoplasty cases, of which pulmonary emboli accounted for 0.6% and 0.01%, respectively.

Vertebral body stenting (VBS), also known as **stentoplasty**, is a further adaptation of vertebroplasty and BKP. It is a new technique, recently developed, that involves placing a metal stent (cage) within the collapsed vertebral body and then expanding this to try and enable some height restoration before filling that cavity created with cement. The main advantage of VBS over BKP is that the height gain after balloon inflation can be maintained whereas with BKP alone it is well-known that in many cases significant height loss occurs during balloon deflation. However, after this procedure, stent remains into the vertebral body to keep vertebral body height restoration; furthermore the stent does not represent a *closed system* like the balloon: so cement-leakage rate is most likely higher than BKP, even though there are not longer follow-up studies for VBS.

3. Indications and contraindications of BKP

BKP is a broadly used method for the management of VCFs [Molina et al, 2011]. Originally introduced for osteoporotic fractures, surgical indications for this percutaneous vertebral augmentation technique were extended to vertebral fractures resulting from multiple myeloma [Zou et al, 2010], spinal metastases [Dalbayrak et al, 2010], vertebral hemangiomas [Jones et al, 2009] and trauma [Doria et al, 2010; Costa et al, 2009; de Falco et al, 2005].

In a recent study, Rollingshof et al. [Rollingshof et al, 2010] reported on a multiple choice questionnaire submitted to 580 clinics registered to practice BKP in Germany. For most participants (95,4% of the users), the main clinical indication was permanent back pain at the fractured level with an average VAS of 5. Although there is no common agreement about the etiopathogenetic and neuroradiological types of VCF to treat with kyphoplasty [Movrin et al, 2010, Bula et al, 2010, Dashti et al, 2005], over 80% of the users regarded A1.1, A1.2, and A3.1 fractures as main indications for kyphoplasty while for more than 60%, osteoporotic A1.1 fracture constituted the main indication for vertebroplasty [Rollingshof et al, 2010]. Although gradual pain resolution following these fractures is the expected natural history, pain can persist and or resolve slowly with conservative management. While patients may be not responsive to non-surgical therapies [Nairn et al, 2011]. Furthermore – especially in osteoporotic patients – VCFs can be complicated by deformity, loss of stature, impairment of pulmonary function and (considering that most VCFs will heal in 8 - 10 weeks with rest, bracing, and pain medications[Klazen et al, 2010]) the attendant risks of poor mobility/immobilisation in the elderly, such as venous thrombo-embolism or discomfort. Whereas BKP could allow rapid pain relief, as well as improved physical function and quality of life [Ledlie et al, 2006].

Obvious contraindications to BKP are pregnancy, congenital or acquired coagulopathies (warfarin, ASA), pain unrelated to vertebral collapse, fractured pedicles, solid tumors, osteomyelitis, contrast allergy (balloons are filled with contrast that can extravasate if they rupture), complete loss of vertebral height (vertebra plana).

4. Preoperative planning

A plain X-ray of the spine is generally enough to make the radiographic diagnosis of VCF (*fig5*):

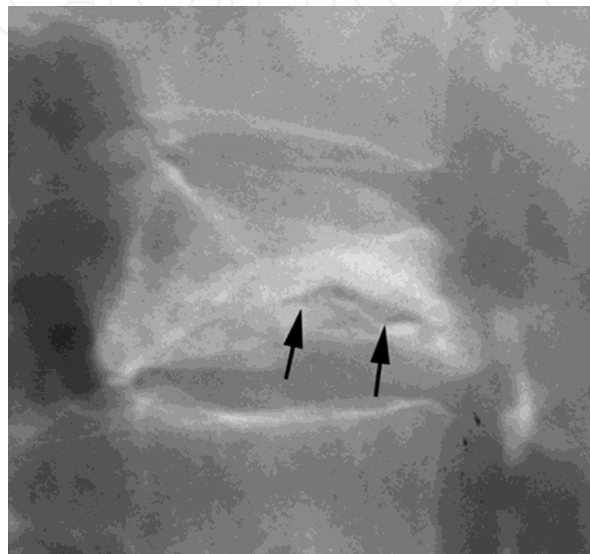


Fig. 5. 71-year-old woman with traumatic VCF. Lateral radiographs of lumbar spine show loss of vertebral body height and linear well-demarcated radiolucency characteristic of intravertebral fracture cleft (arrows).

CT is the most sensitive means to evaluate the location, severity, and extension of the collapsed vertebra, as well as to ascertain the visibility of the vertebral pedicles and the integrity of the posterior wall [Masala et al, 2004] (*fig6*):

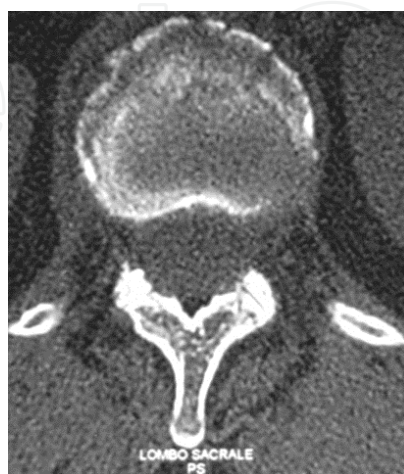

Fig. 6. 52-year-old woman with traumatic VCF of L1. Axial CT scan showing Magerl A1.2 type fracture of the vertebra.

Furthermore, CT scan of the spine allows multi-planar reconstructions, very useful to classify a traumatic VCF according to AO-Magerl classification (fig7-8) [Magerl et al, 1994]:

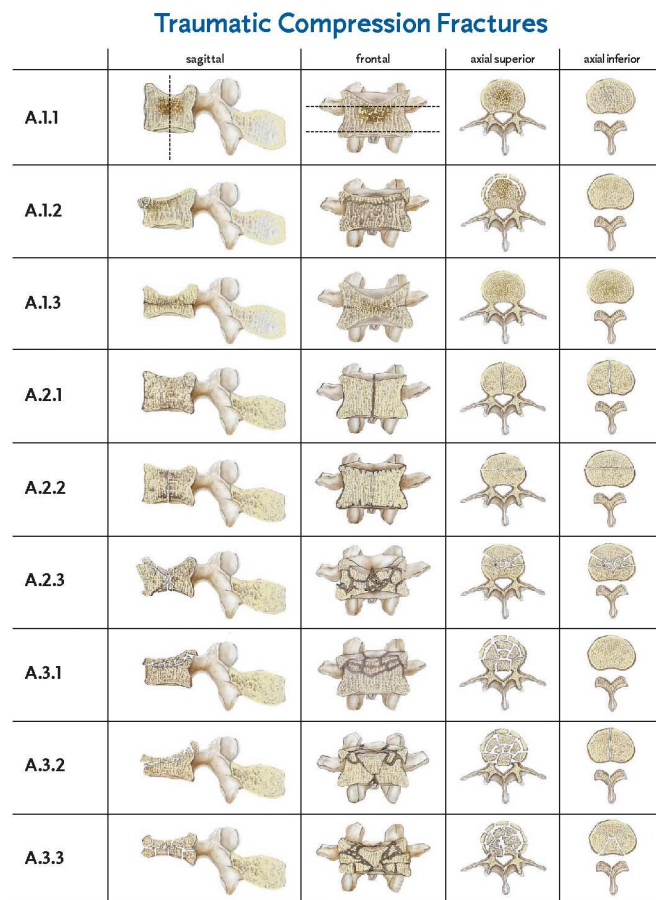


Fig. 7. AO-Magerl classification for type-A fractures

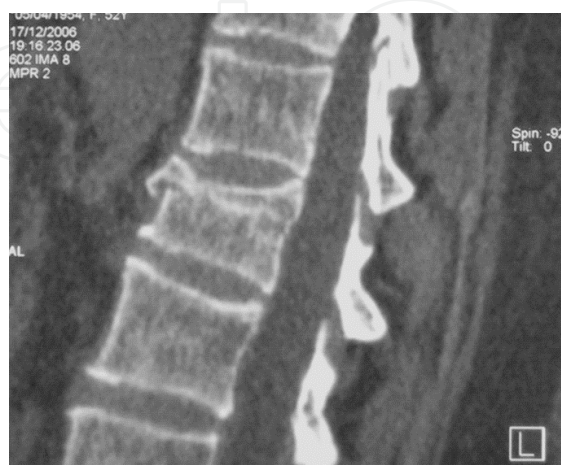

Fig. 8. 52-year-old woman with traumatic VCF of L1. Sagittal CT reconstruction of the previous fracture.

MRI is essential in identifying cord compression as consequence of a posteriorly displaced bone fragment, especially at levels where spinal cord is present (e.g. from the cervical spine to second lumbar vertebra) (*fig9*):

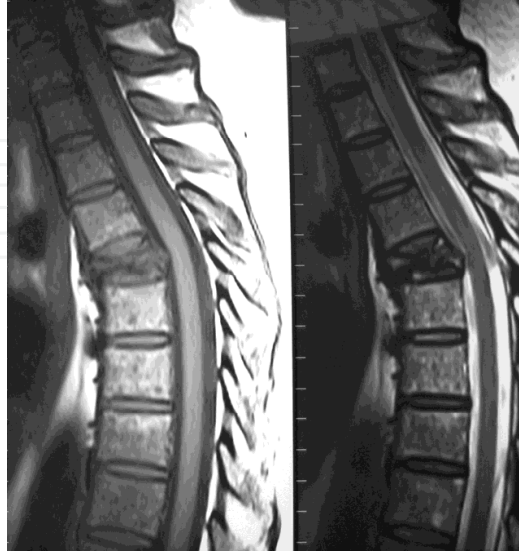

Fig. 9. 49-year-old woman with pathologic (myeloma) VCF. Sagittal MRI of the spine showing mild cord compression at T6 level by a displaced bone fragment.

When there is no data about the timing of fracture, it is important to perform a specific sequence MRI (e.g. STIR, *Short Tau Inversion Recovery*) scan before a kyphoplasty or vertebroplasty procedure is carried out, since it is impossible to distinguish between an old, healed fracture and a new fracture on X-rays or a CT scan. STIR MRI, in fact, is an inversion recovery pulse sequence with specific timing so as to suppress the signal from fat; in this way, the focal hyperintensity (bone marrow edema) that lasts for 2-4 months after fracture can be distinguished from fat signal, suggesting an acute or subacute VCF [Masala et al, 2004].

Finally, bone scintigraphy is helpful in assessing metastatic disease and when pain is elicited on palpation at levels other than where a fracture is radiographically identified (*fig10*):

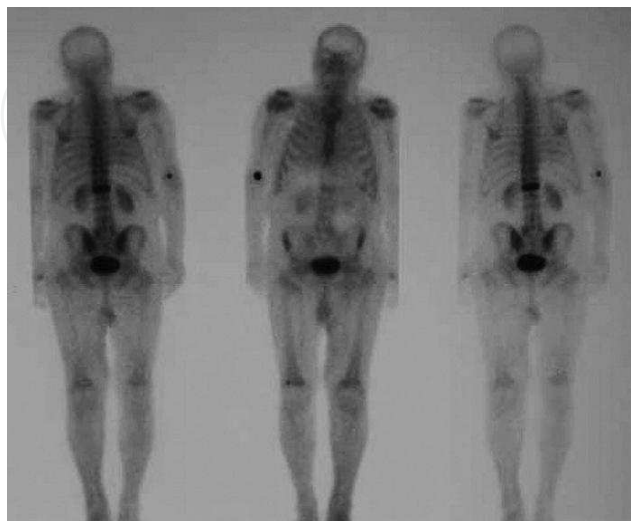


Fig. 10. Bone scan showing an acute vertebral fracture.

5. Key steps of the procedure

As is done in many surgical procedures, prophylactic antibiotics are administered to the patient approximately 30 minutes before the actual procedure; however, the efficacy of this practice in preventing infection has never been affirmed by controlled study [Mathis et al, 2001].

BKP is usually not painful and requires only intravenous mild sedation and local anesthesia. The local anesthetic is injected in to the skin, subcutaneous tissues, and periosteum of the vertebra. General anesthesia is another possible choice, especially for lengthy cases involving numerous levels of vertebral fractures; but local anesthesia with sedation is generally enough, especially when general anesthesia is contraindicated by patient's health conditions (e.g. pathologic VCFs in tumors, myeloma, etc.) [Lavelle et al, 2007].

Prone positioning is achieved and a C-arm is provided; biplane fluoroscopy will allow simultaneous visualization in two projections during injection of bone cement. It allows the procedure to be performed more rapidly [Wehrli et al, 1995] and is often chosen when the procedure is performed in a radiology department because of equipment availability and familiarity.

After fluoroscopic localization, a small incision is made and a thin cannulated trocar with bone biopsy needle is advanced to the antero-posterior radiographic projection of the pedicle. Then the cannula is passed through the pedicle into the vertebral body being treated. Both lateral and antero-posterior projections provide necessary visualization of the path of the needle. An alternative approach is the extrapedicular. This is most often used to access the upper thoracic spine, where pedicles are smaller than in the lumbar tract. The extrapedicular approach involves inserting the cannula between the lateral margin of the pedicle of thoracic vertebrae and the rib head [Hide et al, 2004]. When fracture fragments are reached, the needle is removed and a drill bit is inserted into the cannula; so a passage to the anterior part of the vertebral body is created. Then a void is created within the cancellous bone by an inflatable bone tamp prior to cement delivery (*fig1 and 2*): in this way, bone cement is not *free*, cement-leakage rate is considerably lower than vertebroplasty and a lower pressure is needed to inject bone cement into the vertebra (*fig3*). Occasionally patients report pain when a tool is removed too quickly from the cannula, reasonably due to the sudden negative pressure. This procedure takes about one hour or less for each vertebra involved.

Sometimes kyphoplasty allows achieving height restoration of the fractured vertebral body, thus preventing kyphosis – therefore *kyphoplasty* (*fig4*).

6. Postoperative care

Recovery from a kyphoplasty is relatively quick. In our experience, patients feel almost immediate pain relief after the surgery. Most patients can go home on the day of the procedure; however we prefer to discharge the patient the day after, so he/she may obtain adequate information from our staff about post operative care at home. During hospitalization, in fact, the nurse staff will provide the patient with medication for pain and will encourage him/her to get up, and move around, as soon as possible after the surgery. Bending or sitting should be avoided for an hour or more. Most patients are very satisfied with the procedure

and are able to gradually resume activity once discharged from the hospital. Once at home, patients may resume their activities of daily living as soon as they are able. The bandages may be removed two or three days after they return home from the hospital; the incision on the back should require very little care: keeping it clean and dry is the best. Showering is allowed after only one day, but the patient should not take a bath or go swimming for three weeks. Driving or lifting of heavy objects is forbidden until after about two weeks.

Postoperative bracing is unnecessary, because bone cement hardens during the procedure (PMMA) or within one hour after it (CPC): in fact, the resistance to compressive forces of CPC has been demonstrated not to differ significantly from PMMA after *in vitro* vertebroplasty in human cadavers [Bai et al, 1999] while another *in vitro* study reported that CPC can attain compressive strength comparable to that of an intact vertebral body within 15-20 minutes after implantation: thus, the biomaterial is sufficiently strong for safe transfer of the patient within a reasonable time, following setting (bed-rest for 24h after BKP with CPC is suggested by this study: that's what we do) [Schwardt et al, 2006].

An appointment for radiological and clinical follow-up is scheduled a month after discharge: patients will come to hospital with a plain X-ray of the spine and blood tests (looking for indicators of an acute phase response).

7. Complications

The most commonly described complication is an extravertebral leakage of bone cement [Groen et al, 2004], more likely in traumatic VCFs compared to pathologic VCFs due to more fracture cracks in traumatic fracture [Schmelzer-Schmied et al, 2009]. The systematic review of the literature by Hulme found rates of cement leakage in vertebroplasty of 41% (n = 2283 levels) and in kyphoplasty of 9% (n = 1486 levels) of treated vertebrae. This can lead to spinal stenosis or to pulmonary cement embolism [Choe et al, 2004]. But most leaks were clinically asymptomatic: consider that leaks-distribution is mainly paraspinal (48%) and intradiscal (38%), then epidural (11%) and finally pulmonary (1.5%) and foraminal (1.5%) [Hulme et al, 2009]. In our series, there is a 33% of asymptomatic cement-leakage rate.

In addition, systemic allergic or toxic reactions to bone cement have been described [Kalteis et al, 2004]. New fractures of adjacent vertebrae occurred for both procedures at rates that are higher than the general osteoporotic population but approximately equivalent to the general osteoporotic population that had a previous vertebral fracture [Hulme et al, 2009].

8. Clinical series and outcome

In his systematic review of 69 clinical studies, Hulme compared outcomes from vertebroplasty and kyphoplasty [Hulme et al, 2009]: in both case a large proportion of subjects had some pain relief independent of the type of procedure (87% vertebroplasty, 92% kyphoplasty). Visual analog pain scores (VAS) (normalized to 10-point scale) were reduced from an average of 7.15 to 3.4 for BKP while only two kyphoplasty studies reported on improvement in physical function [Ghros et al, 2006; Gaitains et al, 2005]: this suggests that reporting improvements in physical function appears to be of secondary importance to the investigators; therefore, measurement scales used are inconsistent and scores cannot be pooled [Hulme et al, 2009]. The pain relief experienced by patients appears to be promising for both BKP and vertebroplasty in the short-term (<1 year) whereas it appears that pain

relief is durable: in fact, little change was noted between postoperative scores and long-term. [Hulme et al, 2009, Zoarski et al, 2002]. However, note that long-term follow-up results were not as frequently reported [Hulme et al, 2009]

A qualitative examination of the data collected by Hulme indicates that vertebral height restoration is similar both for vertebroplasty and BKP (mean 6.6°). However, interstudy comparisons are further complicated by the use of different methods for percentage height restoration and reduction of kyphosis angle calculation [Hulme et al, 2009, McKiernan et al, 2003]. As described in the section above, cement leaks occurred for 41% and 9% of treated vertebrae for vertebroplasty and kyphoplasty respectively, while adjacent level fracture rates are similar between both procedures and approximately equivalent to the general osteoporotic population that had a previous vertebral fracture. Furthermore, the stabilization of a specific fracture level by kyphoplasty may lead to secondary fractures of adjacent vertebrae due to the changed biomechanics of the spine [Baroud et al, 2006, Berlemann et al, 2002]. However, these studies refer to osteoporotic VCFs, so the adjacent vertebral fractures are related to a low bone density [Tseng et al, 2009].

8.1 Our series

From March 2005 to March 2011, 137 hospitalized patients underwent BKP for VCF at our Department. Among these, 76 patients (55,5%) fulfilled the criteria set at our Institution to be offered BKP after having suffered traumatic VCF (*tab1*):

Parameters	N = 76
Gender (M)	40 (52.6%)
Level (>=2)	2 (2.6%)
Magerl	
A 1.2	31 (43.0%)
A 1.3	14 (19.4%)
A 3.1	27 (37.5%)
Age	53±15
VAS pre	8.8±1.1
VAS post	3.0±2.0
DeltaVAS	67±21

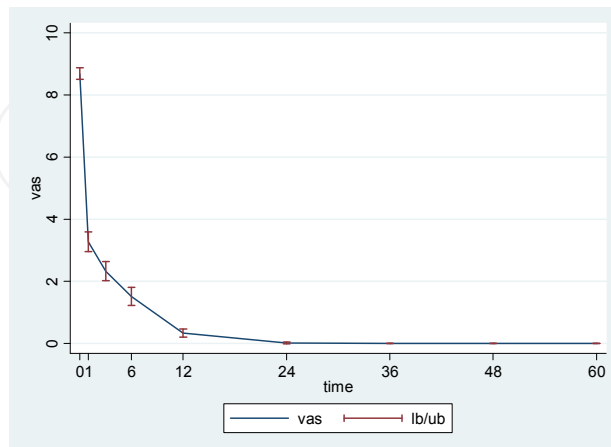
Table 1. Demographic and clinical characteristics; DeltaVAS = (VAS pre-VAS post)/VAS pre)*100

Inclusion criteria were:

1. no neurological deficits;
2. one or, at most, two vertebral body injuries involving the spine from T5 through L4 or, when feasible, L5;
3. no radiological evidence of mechanical instability;
4. Magerl nonsurgical and stable fractures, that are - in our opinion - A1.2 (wedge impaction) (N=31), A1.3 (vertebral body collapse) (N=14) and A3.1 (incomplete burst

fracture) types without retro-pulsed fragment. We exclude A2.1 to A2.3 types because there is always a split of the vertebral body that could allow cement leakage.

Mean age was 53 ± 15 years and 53% males. Mean preoperative VAS was 8.7 ± 1.1 while Post-operative VAS was 3.0 ± 2.0 significantly lower with $p\text{-value} < 0.0001$. As reported in *graph1*:



Graph. 1. Outcome: pain-relief during follow-ups; lb = lower bund, ub = upper bund

VAS decreased significantly after surgery while complete pain relief was obtained at 2-year follow-up for 42 patients; this result is durable for 8 patients with 6-year follow-up. We believe that, unlike patients with pathologic VCFs, in traumatic patients healthy conditions are good (no osteoporosis, tumors or myeloma): so a complete pain relief is a possible goal after BKP.

Early mobilization (i.e., within 24-48h from BKP) was obtained in all cases. Because our philosophy is to not overfill traumatic fractured vertebra, height restoration is not our target for this kind of VCFs. So we didn't take any measurement of Cobb angle. In 23 subjects (30%) asymptomatic cement leakages occurred.

9. Traumatic VCFs: Tips and tricks

Because we work closely with our Emergency Department, more than 50% of our cases are traumatic VCFs

One of the most controversial issues millitating against BKP in traumatic VCFs relates to the main bone cement used in this procedure (i.e. poly-methyl-metacrylate, PMMA), which cannot integrate into bone and can not allow for bone-healing.

On the contrary, we prefer to use PMMA because the potential local reaction to PMMA (incidental to the exothermic reaction that occurs while the PMMA bone cement is hardening *in situ*) brings fibrous tissue formation at the interface between bone and bone cement [Kalteis et al, 2004], which may be a serious disadvantage for a joint (e.g. hip) but seems not to be significant for a non-articulating bone such as the vertebral body.

However, we suggest some care in performing BKP in traumatic VCF:

1. In traumatic factures there is much higher rate of cement leakage compared to non-traumatic VCF; this is due to the nature of these traumatic fractures: the cement can leak

- through the many fracture cracks [Schmeizler-Schmied et al, 2009]. So we prefer to not overfill the fractured vertebra with cement because an excessive amount of bone cement could lead to a higher rate of leakage. This also explains why we mainly prefer kyphoplasty over vertebroplasty, which needs a much higher pressure.
2. Unlike osteoporotic VCFs, it's very difficult to achieve height restoration in traumatic fractures because these patients have a normal bone density [Schmeizler-Schmied et al, 2009]: so over-inflating the balloon seems to be unnecessary. Higher rates of cement leakage and/or balloon burst are present.
 3. Because a low risk of adjacent vertebral fractures is described for vertebral augmentation techniques (generally for vertebroplasty) with PMMA cement [Gerztbein et al, 1994; Kalteis et al, 2004; Tseng et al, 2009], we prefer to not overfill the fractured vertebra keeping this risk to the minimum: reported clinical studies have shown that even "insufficient" filling of vertebral bodies during a vertebroplasty can lead to a successful outcomes in pain reduction, and stiffening and stabilizing of the fractured vertebrae [Luo et al, 2007; Furtado et al, 2007; Oakland et al, 2009]. The mechanism for adjacent vertebral fractures is still unclear, but from experimental and computational studies, it appears that vertebroplasty changes the mechanical loading in adjacent vertebrae because of excessive cement rigidity of treated vertebra [Baroud et al, 2006; Berlemann et al, 2002]. However, it is noted that these studies refer to VCF from osteoporosis, so the adjacent vertebral fractures are related to a low bone density. In fact, Tseng concluded that older patient ages, lower baseline BMD, and more pre-existing vertebral fractures were found to be risk factors for multiple vertebral compression fractures [Tseng et al, 2009].
 4. Inflammatory response to PMMA exothermic reaction could lead to bone resorption all around this cement. Although this is a serious disadvantage for prostheses integration into the bone (a common technique to aid in implant fixation into surrounding bone is to inject bone cement into the space between the implant and surrounding bone [Kuhn et al, 2000]), this seems not to be very significant for a non-articulating bone, as represented by a vertebral body, especially if we consider that some authors successfully treated intravertebral pseudarthroses (whose neuroradiological findings are the rare and, so-called, *intravertebral vacuum phenomenon* [Van Eenenaan et al, 1993]) by BKP with PMMA [Ghros et al, 2006]. Furthermore, Aebli has shown that temperature levels after usage of intravertebral PMMA cement may be sufficient to cause intravertebral thermal necrosis, but that heat levels outside the vertebral body (e.g. at the intervertebral discs and vertebral endplates) are unlikely to cause thermal injury [Aebli et al, 2006]. However, we prefer to keep to a minimum the amount of cement in order to avoid local bone resorption.
 5. Finally, we agree with de Falco [de Falco et al, 2005] about the opportunity to use bioactive cement in patients under 50 years. In fact, although the use of PMMA cement in vertebroplasty is widespread, no data on the long-term behaviour of the material for spinal applications has been published. So, because the majority of patients with traumatic vertebral fractures are aged less than 50 years and the PMMA material remains inside the vertebral body for life, the use of more biocompatible bone cement is preferred [Verlaan et al, 2002]. Thus, the usage of calcium phosphate cement (CPC), which hardens by crystallization at body temperature, avoids thermal injury, whereby it is unclear whether thermal necrosis actually contributes to the fibrous tissue layer around PMMA implants [Libicher et al, 2006]. However, we have to take into

consideration the fact that bioactive cements are much more expensive than PMMA. Therefore, it may be that the use of very expensive bone cement is deemed inappropriate for elderly patients.

10. Explicative cases

We present two illustrative cases about among our procedures.

10.1 Case 1

52-year-old female, L1 traumatic A1.2 vertebral compression fracture (*fig. 11*):

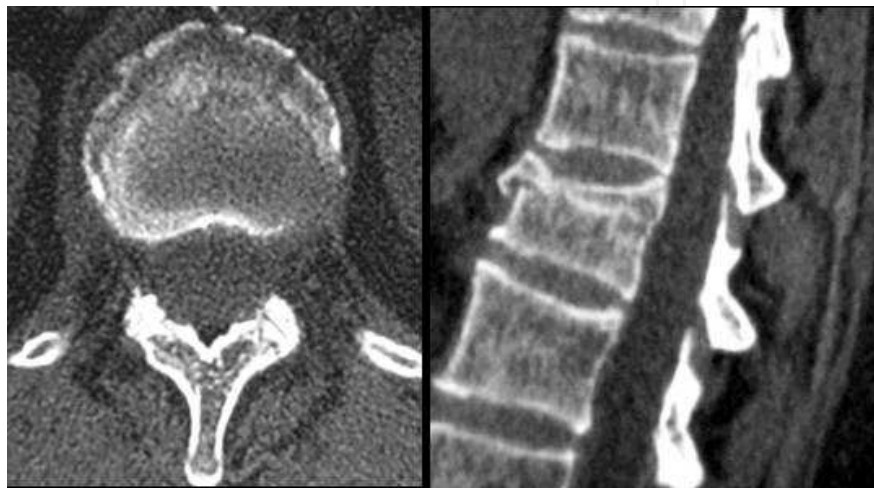


Fig. 11. Case 1. Axial (right) and sagittal MPR (left) CT scan of L1 traumatic A1.2 VCF. Posterior vertebral wall is untouched.

As you can see in the postoperative CT scan (*fig. 12*):

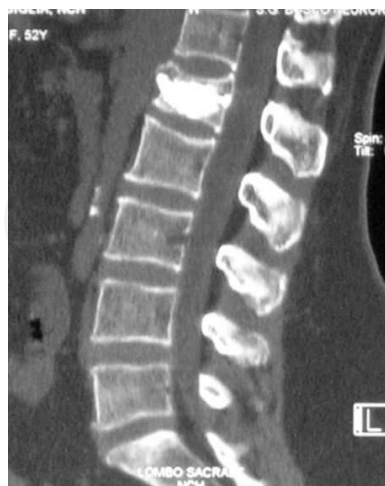

Fig. 12. Case 1. Postoperative CT scan (sagittal MPR)

L1 body was not overfilled by bone cement (PMMA), because our target for traumatic VCFs is stabilization *not* augmentation. X-ray follow-up at 2 (*fig. 13*) and 5 years (*fig. 14*) are showed:

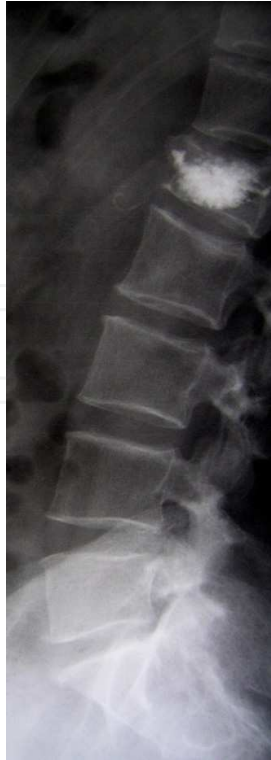

Fig. 13. Case 1. X-ray follow-up (2 years)

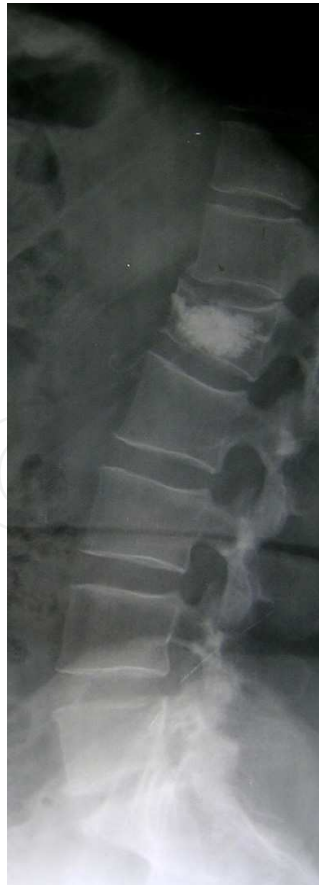


Fig. 14. Case 1. X-ray follow-up (5 years)

Stabilization was held, no further collapse of the kyphoplastied vertebra or adjacent fractures were seen at long-term follow-up. Preoperative VAS was 7 while postoperative VAS became 0 since three months after BKP; this clinical goal was kept at 5 years follow-up.

10.2 Case 2

This is one of first case of our series. 53-year-old male, T12 traumatic A3.1 vertebral compression fracture (*fig. 15*):

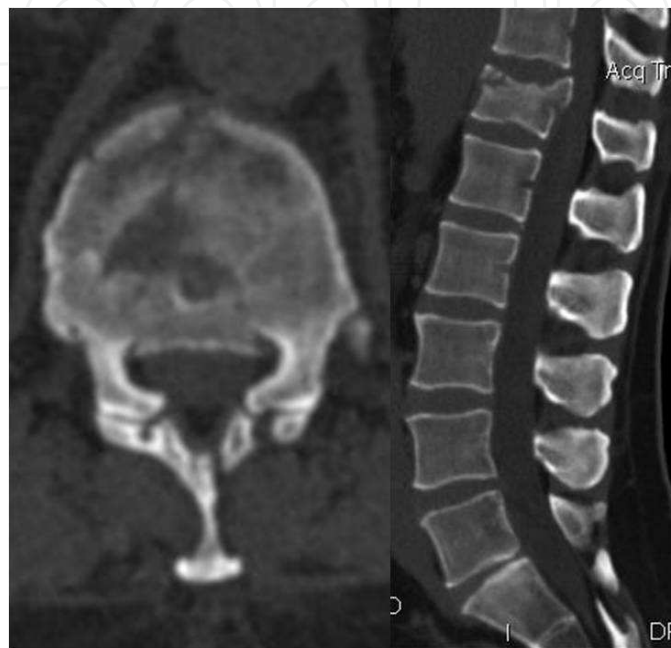

Fig. 15. Case 2. Axial (right) and sagittal MPR (left) CT scan of T12 traumatic A3.1 VCF. Intact pedicles are clearly visible in axial scan. Non-significant retropulsed fragment is present.

As you can see in post-operative CT-scan (*fig16*):

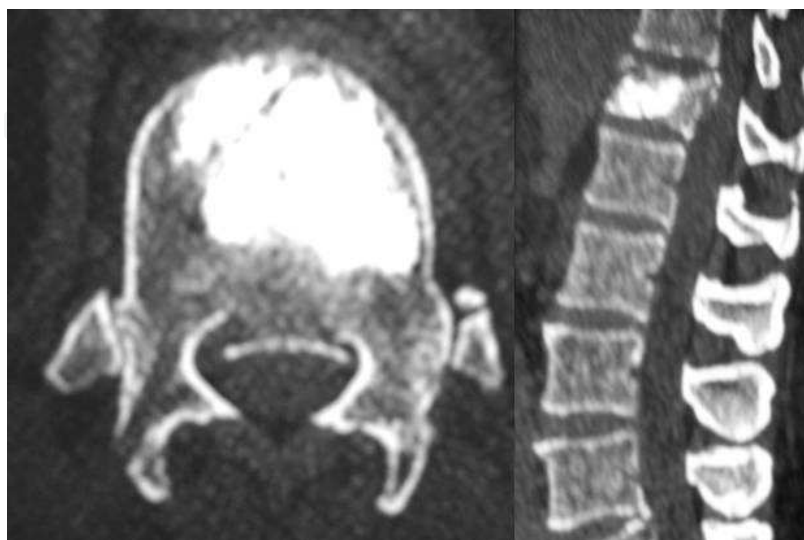

Fig. 16. Case 2. Axial (right) and sagittal MPR (left) CT scan of D12 traumatic A3.1 VCF after BKP. Vertebral body was not overfilled while retropulsed fragment wasn't touched.

we used a little amount of bone cement to fill the vertebral body: stabilization was achieved while vertebral body augmentation was poor; this “undercharging” philosophy was also useful in not touching the retropulsed fragment.

This radiographic result was held after 6-years follow-up (fig17):

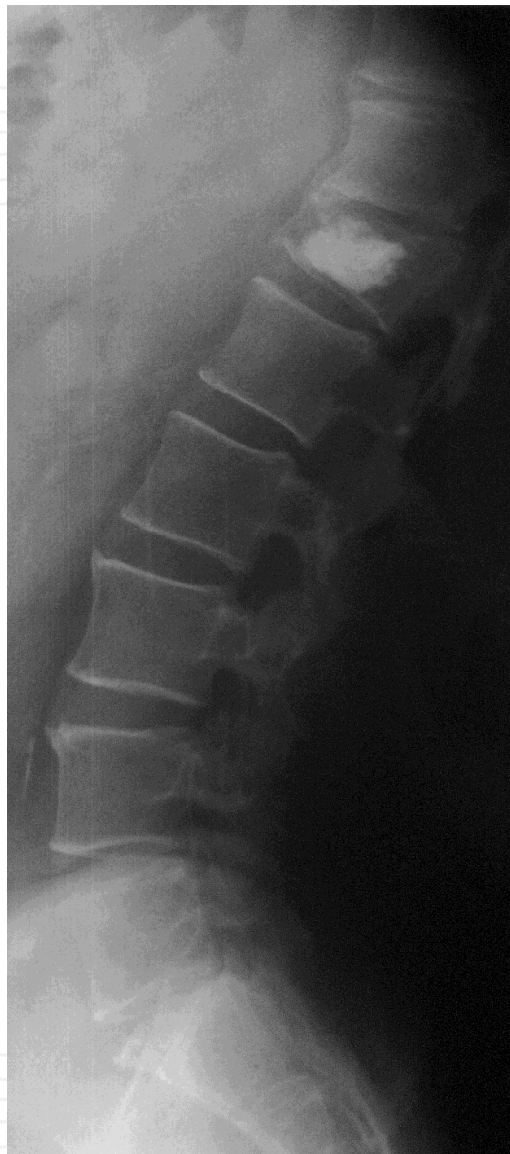

Fig. 17. Case 2. X-ray follow-up (6 years)

Pre-operative VAS was 8 while post-operative VAS significantly improved to 2; complete absence of pain was achieved 6 months after BKP, and this score was held at 6-years follow-up-

11. Conclusion

In our experience, BKP is a safe and effective procedure to treat nonsurgical and stable traumatic VCF compared to conservative therapy and to other percutaneous augmentation technique such as vertebroplasty.

Although long-term studies about effectiveness of BKP for traumatic VCFs are unsatisfactory, our 6-years follow-up suggests that this vertebral-augmentation technique represent a very attractive, easy and fully adequate solution to treat this kind of traumatic fractures.

12. Acknowledgments

Special thanks to Chris Johnson for correcting English usage in my paper

13. References


- Aebli N, Goss BG, Thorpe P, Williams R, Krebs J. In vivo temperature profile of intervertebral discs and vertebral endplates during vertebroplasty: an experimental study in sheep. *Spine (Phila Pa 1976)*. 2006 Jul 1;31(15):1674-8; discussion 1679.
- Bai B, Jazrawi LM, Kummer FJ, Spivak JM. The use of an injectable, biodegradable calcium phosphate bone substitute for the prophylactic augmentation of osteoporotic vertebrae and the management of vertebral compression fractures. *Spine (Phila Pa 1976)*. 1999 Aug 1;24(15):1521-6.
- Baroud G, Vant C, Wilcox R. Long-term effects of vertebroplasty: adjacent vertebral fractures. *J Long Term Eff Med Implants*. 2006;16(4):265-80.
- Berlemann U, Ferguson SJ, Nolte LP, Heini PF. Adjacent vertebral failure after vertebroplasty. A biomechanical investigation. *J Bone Joint Surg Br*. 2002 Jul;84(5):748-52.
- Bula P, Lein T, Straßberger C, Bonnaire F. Balloon Kyphoplasty in the Treatment of Osteoporotic Vertebral Fractures: Indications - Treatment Strategy - Complications. *Z Orthop Unfall*. 2010 Nov 15. [Epub ahead of print]
- Choe DH, Marom EM, Ahrar K, Truong MT, Madewell JE. Pulmonary embolism of polymethyl methacrylate during percutaneous vertebroplasty and kyphoplasty. *AJR Am J Roentgenol*. 2004 Oct;183(4):1097-102.
- Costa F, Ortolina A, Cardia A, Sassi M, De Santis A, Borroni M, Savoia G, Fornari M. Efficacy of treatment with percutaneous vertebroplasty and kyphoplasty for traumatic fracture of thoracolumbar junction. *J Neurosurg Sci*. 2009 Mar;53(1):13-7.
- Costa F, Ortolina A, Cardia A, Sassi M, De Santis A, Borroni M, Savoia G, Fornari M. Efficacy of treatment with percutaneous vertebroplasty and kyphoplasty for traumatic fracture of thoracolumbar junction. *J Neurosurg Sci*. 2009 Mar;53(1):13-7.
- Dalbayrak S, Onen MR, Yilmaz M, Naderi S. Clinical and radiographic results of balloon kyphoplasty for treatment of vertebral body metastases and multiple myelomas. *J Clin Neurosci*. 2010 Feb;17(2):219-24. Epub 2009 Dec 5.
- Dashti H, Lee HC, Karaikovic EE, Gaines Jr RW. Decision making in thoracolumbar fractures. *Neurol India* 2005;53:534-41.
- de Falco R, Scarano E, Di Celmo D, Grasso U, Guarnieri L. Balloon kyphoplasty in traumatic fractures of the thoracolumbar junction. Preliminary experience in 12 cases. *J Neurosurg Sci*. 2005 Dec;49(4):147-53.
- Doria C, Tranquilli Leali P. Percutaneous techniques in the treatment of osteoporotic, traumatic and neoplastic fractures of thoraco-lumbar spine: our institutional experience. *Injury*. 2010 Nov;41(11):1136-9. Epub 2010 Oct 16

- Furtado N, Oakland RJ, Wilcox RK, Hall RM. A biomechanical investigation of vertebroplasty in osteoporotic compression fractures and in prophylactic vertebral reinforcement. *Spine (Phila Pa 1976)*. 2007 Aug 1;32(17):E480-7.
- Gaitanis IN, Hadjipavlou AG, Katonis PG, Tzermiadianos MN, Pasku DS, Patwardhan AG. Balloon kyphoplasty for the treatment of pathological vertebral compressive fractures. *Eur Spine J*. 2005 Apr;14(3):250-60. Epub 2004 Oct 8.
- Gaitanis IN, Hadjipavlou AG, Katonis PG, Tzermiadianos MN, Pasku DS, Patwardhan AG. Balloon kyphoplasty for the treatment of pathological vertebral compressive fractures. *Eur Spine J*. 2005 Apr;14(3):250-60. Epub 2004 Oct 8.
- Gertzbein SD. Neurologic deterioration in patients with thoracic and lumbar fractures after admission to the hospital. *Spine* 1994;19:1723-5.
- Greene DL, Isaac R, Neuwirth M, Bitan FD. The eggshell technique for prevention of cement leakage during kyphoplasty. *J Spinal Disord Tech*. 2007 May;20(3):229-32.
- Groen RJ, du Toit DF, Phillips FM, Hoogland PV, Kuizenga K, Coppes MH, Muller CJ, Grobbelaar M, Mattyssen J. Anatomical and pathological considerations in percutaneous vertebroplasty and kyphoplasty: a reappraisal of the vertebral venous system. *Spine (Phila Pa 1976)*. 2004 Jul 1;29(13):1465-71.
- Grohs JG, Matzner M, Trieb K, Krepler P. Treatment of intravertebral pseudarthroses by balloon kyphoplasty. *J Spinal Disord Tech*. 2006 Dec;19(8):560-5.
- Hide IG, Gangi A. Percutaneous vertebroplasty: history, technique and current perspectives. *Clin Radiol* 2004;59:461-7.
- Hulme PA, Krebs J, Ferguson SJ, Berlemann U. Vertebroplasty and kyphoplasty: a systematic review of 69 clinical studies. *Spine (Phila Pa 1976)*. 2006 Aug 1;31(17):1983-2001.
- Jones JO, Bruel BM, Vattam SR. Management of painful vertebral hemangiomas with kyphoplasty: a report of two cases and a literature review. *Pain Physician*. 2009 Jul-Aug;12(4):E297-303.
- Kalteis T, Lüring C, Gugler G, Zysk S, Caro W, Handel M, Grifka J. Acute tissue toxicity of PMMA bone cements. *Z Orthop Ihre Grenzgeb*. 2004 Nov-Dec;142(6):666-72.
- Kalteis T, Lüring C, Gugler G, Zysk S, Caro W, Handel M, Grifka J. Acute tissue toxicity of PMMA bone cements. *Z Orthop Ihre Grenzgeb*. 2004 Nov-Dec;142(6):666-72.
- Klazen CA, Lohle PN, de Vries J, Jansen FH, Tielbeek AV, Blonk MC, Venmans A, van Rooij WJ, Schoemaker MC, Juttman JR, Lo TH, Verhaar HJ, van der Graaf Y, van Everdingen KJ, Muller AF, Elgersma OE, Halkema DR, Franssen H, Janssens X, Buskens E, Mali WP. Vertebroplasty versus conservative treatment in acute osteoporotic vertebral compression fractures (Vertos II): an open-label randomised trial. *Lancet*. 2010 Sep 25;376(9746):1085-92.
- Kühn K-D. Bone Cements, Up-to-Date Comparison of Physical and Chemical Properties of Commercial Materials. 2000 Springer Verlag: Berlin, pp. 12-20.
- Lavelle W, Carl A, Lavelle ED, Khaleel MA. Vertebroplasty and kyphoplasty. *Anesthesiol Clin*. 2007 Dec;25(4):913-28.
- Ledlie JT, Renfro MB. Kyphoplasty treatment of vertebral fractures: 2-year outcomes show sustained benefits. *Spine (Phila Pa 1976)*. 2006 Jan 1;31(1):57-64.
- Libicher M, Hillmeier J, Liegibel U, Sommer U, Pyerin W, Vetter M, Meinzer HP, Grafe I, Meeder P, Nöldge G, Nawroth P, Kasperk C. Osseous integration of calcium phosphate in osteoporotic vertebral fractures after kyphoplasty: initial results from

- a clinical and experimental pilot study. *Osteoporos Int.* 2006;17(8):1208-15. Epub 2006 Jun 8.
- Luo J, Skrzypiec DM, Pollintine P, Adams MA, Annesley-Williams DJ, Dolan P. Mechanical efficacy of vertebroplasty: influence of cement type, BMD, fracture severity, and disc degeneration. *Bone.* 2007 Apr;40(4):1110-9. Epub 2007 Jan 16.
- Magerl F, Aebi M, Gertzbein SD, Harms J, Nazarian S. A comprehensive classification of thoracic and lumbar injuries. *Eur Spine J.* 1994; 3(4):184-201.
- Masala S, Fiori R, Massari F, Cantonetti M, Postorino M, Simonetti G. Percutaneous kyphoplasty: indications and technique in the treatment of vertebral fractures from myeloma. *Tumori.* 2004 Jan-Feb;90(1):22-6.
- Mathis JM, Barr JD, Belkoff SM, et al. Percutaneous vertebroplasty: a developing standard of care for vertebral compression fractures. *AJNR Am J Neuroradiol* 2001;22(2):373-81
- McKiernan F, Faciszewski T, Jensen R. Reporting height restoration in vertebral compression fractures. *Spine (Phila Pa 1976).* 2003 Nov 15;28(22):2517-21; discussion 3.
- Molina GS, Campero A, Feito R, Pombo S. Kyphoplasty in the Treatment of Osteoporotic Vertebral Compression Fractures (VCF) : Procedure Description and Analysis of the Outcomes in 128 Patients. *Acta Neurochir Suppl.* 2011;108:163-170.
- Movrin I, Vengust R, Komadina R. Adjacent vertebral fractures after percutaneous vertebral augmentation of osteoporotic vertebral compression fracture: a comparison of balloon kyphoplasty and vertebroplasty. *Arch Orthop Trauma Surg.* 2010 Sep;130(9):1157-66. Epub 2010 May 7.
- Nairn RJ, Binkhamis S, Sheikh A. Current Perspectives on Percutaneous Vertebroplasty: Current Evidence/Controversies, Patient Selection and Assessment, and Technique and Complications. *Radiology Research and Practice*, vol. 2011, Article ID 175079, 10 pages, 2011. doi:10.1155/2011/175079
- Oakland RJ, Furtado NR, Wilcox RK, Timothy J, Hall RM. Preliminary biomechanical evaluation of prophylactic vertebral reinforcement adjacent to vertebroplasty under cyclic loading. *Spine J.* 2009 Feb;9(2):174-81. Epub 2008 Jul 21.
- Röllinghoff M, Zarghooni K, Schlüter-Brust K, Sobottke R, Schlegel U, Eysel P, Delank KS. Indications and contraindications for vertebroplasty and kyphoplasty. *Arch Orthop Trauma Surg.* 2010 Jun;130(6):765-74. Epub 2010 Mar 11.
- Schmelzer-Schmied N, Cartens C, Meeder PJ, Dafonseca K. Comparison of kyphoplasty with use of a calcium phosphate cement and non-operative therapy in patients with traumatic non-osteoporotic vertebral fractures. *Eur Spine J.* 2009 May;18(5):624-9. Epub 2009 Jan 23.
- Schwardt J, Slater T, Lee S, Meyer J, Wenz R. KyphOs FSTTM Calcium Phosphate for Balloon Kyphoplasty: Verification of Compressive Strength and Instructions for Use. *European Cells and Materials Vol. 11. Suppl. 1, 2006 (page 28).*
- Tseng YY, Yang TC, Tu PH, Lo YL, Yang ST. Repeated and multiple new vertebral compression fractures after percutaneous transpedicular vertebroplasty. *Spine (Phila Pa 1976).* 2009 Aug 15;34(18):1917-22.
- Van Eenenaam DP, el-Khoury GY. Delayed post-traumatic vertebral collapse (Kummell's disease): case report with serial radiographs, computed tomographic scans, and bone scans. *Spine (Phila Pa 1976).* 1993 Jul;18(9):1236-41.

- Verlaan JJ, van Helden WH, Oner FC, Verbout AJ, Dhert WJ. Balloon vertebroplasty with calcium phosphate cement augmentation for direct restoration of traumatic thoracolumbar vertebral fractures. *Spine (Phila Pa 1976)*. 2002 Mar 1;27(5):543-8.
- Wehrli FW, Ford JC, Haddad JG. Osteoporosis: clinical assessment with quantitative MR imaging in diagnosis. *Radiology* 1995;196(3):631-41.
- Zoarski GH, Snow P, Olan WJ, Stallmeyer MJ, Dick BW, Hebel JR, De Deyne M. Percutaneous vertebroplasty for osteoporotic compression fractures: quantitative prospective evaluation of long-term outcomes. *J Vasc Interv Radiol*. 2002 Feb;13(2 Pt 1):139-48.
- Zou J, Mei X, Gan M, Yang H. Kyphoplasty for spinal fractures from multiple myeloma. *J Surg Oncol*. 2010 Jul 1;102(1):43-7.

IntechOpen



Explicative Cases of Controversial Issues in Neurosurgery

Edited by Dr. Francesco Signorelli

ISBN 978-953-51-0623-4

Hard cover, 534 pages

Publisher InTech

Published online 23, May, 2012

Published in print edition May, 2012

Neurosurgery is a rapidly developing field of medicine. Therefore, staying keeping track of the advancements in the field is paramount for trainees as well as fully trained neurosurgeons. This book, fully available online, is a part of our effort of improving availability of medical information for anyone who needs to keep up-to-date.

How to reference

In order to correctly reference this scholarly work, feel free to copy and paste the following:

Luca Arpino and Pierpaolo Nina (2012). Balloon-Kyphoplasty for Vertebral Compression Fractures, Explicative Cases of Controversial Issues in Neurosurgery, Dr. Francesco Signorelli (Ed.), ISBN: 978-953-51-0623-4, InTech, Available from: <http://www.intechopen.com/books/explicative-cases-of-controversial-issues-in-neurosurgery/balloon-kyphoplasty-for-vertebral-compression-fractures>

INTECH

open science | open minds

InTech Europe

University Campus STeP Ri
Slavka Krautzeka 83/A
51000 Rijeka, Croatia
Phone: +385 (51) 770 447
Fax: +385 (51) 686 166
www.intechopen.com

InTech China

Unit 405, Office Block, Hotel Equatorial Shanghai
No.65, Yan An Road (West), Shanghai, 200040, China
中国上海市延安西路65号上海国际贵都大饭店办公楼405单元
Phone: +86-21-62489820
Fax: +86-21-62489821

© 2012 The Author(s). Licensee IntechOpen. This is an open access article distributed under the terms of the [Creative Commons Attribution 3.0 License](#), which permits unrestricted use, distribution, and reproduction in any medium, provided the original work is properly cited.

IntechOpen

IntechOpen