

# We are IntechOpen, the world's leading publisher of Open Access books Built by scientists, for scientists

**4,800**

Open access books available

**122,000**

International authors and editors

**135M**

Downloads

Our authors are among the

**154**

Countries delivered to

**TOP 1%**

most cited scientists

**12.2%**

Contributors from top 500 universities



**WEB OF SCIENCE™**

Selection of our books indexed in the Book Citation Index  
in Web of Science™ Core Collection (BKCI)

Interested in publishing with us?  
Contact [book.department@intechopen.com](mailto:book.department@intechopen.com)

Numbers displayed above are based on latest data collected.

For more information visit [www.intechopen.com](http://www.intechopen.com)



# Acute Kidney Injury Induced by Snake and Arthropod Venoms

Markus Berger<sup>1</sup>, Maria Aparecida Ribeiro Vieira<sup>2</sup>  
and Jorge Almeida Guimarães<sup>1</sup>

<sup>1</sup>Center of Biotechnology, Department of Molecular Biology and Biotechnology,  
Federal University of Rio Grande do Sul (UFRGS), Porto Alegre,

<sup>2</sup>Institute of Biological Sciences, Department of Fisiology and Biology,  
Federal University of Minas Gerais (UFMG)  
Brazil

## 1. Introduction

Snakebites and accidents caused by venomous arthropods (mainly spiders, scorpions, bees, wasps and caterpillars) are important public health problem. Despite of this, public health authorities, nationally and internationally, have given little attention to this problem worldwide (Warrell, 2010; Williams et al., 2010). As a consequence, the morbidity and mortality associated with snake and arthropod envenoming produce a great impact on the population and on the health-care systems. One of the most important and lethal effect of these animal venoms is nephrotoxicity (Sitprija, 2006). Specifically in South America and Brazil, the main snakes responsible for cases of acute kidney injury (AKI) are those from *Bothrops* and *Crotalus* genus. Among venomous arthropods, AKI has been reported after accidents with bees, spiders of the genus *Loxosceles* and caterpillars of the genus *Lonomia*.

Taking in account the importance of accidents with these venomous animals, in this chapter we reviewed the main mechanisms that play a role in AKI induced by the most common snakes and arthropods found in South America. The following key aspects are addressed: Epidemiology, clinical renal manifestations, renal pathophysiology, diagnosis, clinical management of AKI and the currently experimental models used to study the venom-induced AKI.

## 2. Epidemiology and prevalence of venomous snakes and arthropods in South America

Given the wide distribution of venomous animals, particularly in tropical and subtropical regions, the extensive number of accidents and the complexity of the clinical conditions it causes, the distinct types of envenomation can be considered a global problem because they assume great public health importance, especially in the poorest areas of the world (World Health Organization [WHO], 2007). This environmental and occupational disease affects mainly agricultural workers and their children in some of the most impoverished rural

communities of developing countries in Africa, Asia, Latin America and Oceania. Populations in these regions experience high morbidity and mortality because of the poor access to health services, which are often suboptimal, and, in some instances, a scarcity of antivenom, which is the only specific treatment so far technically possible to be available. A large number of victims survive with permanent physical and psychological sequelae (Gutiérrez et al., 2010; Kasturiratne et al., 2008; Warrell, 2010).

A group of venomous animals is responsible for medically important accidents: snakes, scorpions, spiders, caterpillars, bees and wasps. Global epidemiological data on accidents with these different types of animals are scarce and often depend on the existence of country-specific estimates based on hospital admissions data and community-based population surveys. Unfortunately, in the low-income countries, where most accidents occur, there is not such a well organized health systems in order to correctly report the envenomation cases (Kasturiratne et al., 2008; Williams et al., 2010). Nevertheless, after the incorporation of snakebite envenomations on the World Health Organization list of neglected tropical diseases in 2009 ([www.who.int/neglected\\_diseases/diseases/snakebites/en/](http://www.who.int/neglected_diseases/diseases/snakebites/en/)), more attention has been given to the lack of information on the true epidemiological impact of accidents, especially in the cases of snakebites. Current data indicate that 5.4 to 5.5 million people are bitten by snakes each year, resulting in near 400,000 amputations, and between 20,000 to 125,000 deaths (Chippaux, 1998, Kasturiratne et al., 2008; Williams et al., 2010). The highest burden of snakebite was identified in South and Southeast Asia, sub-Saharan Africa and Central and South America. Annually, Asia and Africa have incidence rates of 1.2 million and 1 million bites with 60,000 and 20,000 deaths, respectively. In Central and South America, epidemiological data indicate the occurrence of 300,000 snakebites per year which result in 4,000 deaths and approximately 12,000 cases of physical sequelae (Chippaux, 2011; Gutiérrez et al., 2010).

Specifically in Brazil, data from the System of Health Surveillance of the Ministry of Health indicate the occurrence of 107,364 accidents with venomous animals in the year of 2009 (including cases of snake, scorpion, spider, caterpillar and bee envenomations) which resulted in 290 deaths. When compared to the 2008 year there were an increase of 12 % and 16 % in the total number of accidents and deaths, respectively (Boletim eletrônico epidemiológico, 2010). The majority of reported cases was caused by snakes and scorpions, which were also responsible for the highest rates of lethality (Table 1). Most snakebite (53 %) occurred from January to May, which reflect the influence of seasonal factors, such as an increase in temperature and humidity associated with the rainy season in some regions of Brazil. Human agricultural activities were also associated with envenomations, since 78 % of accidents occurred in rural areas. Snakes of *Bothrops* genus (Lance-headed pit vipers) were responsible for 90.5 % of the accidents while snakes of *Crotalus* genus (South American rattlesnakes) accounted for 7.7 % of total cases, showing however, a much higher lethality index (1.25 %) than that for *Bothrops* snakes (0.35 %) (Ministério da Saúde, 2001). Analysing the different regions of Brazil, the highest proportion of snakebites in relation to the population is localized in the North Region (Amazon Forest) with 53.9 accidents/100,000 inhabitants, probably due to the difficulty of patients to access health services and/or to the delay in the administration of antivenom (Table 1). Among all venomous animals, the scorpion stands out for its high and growing number of accidents in Brazil. Compared to the 2008 year, there was an increase of 7,050 cases in 2009 (45,721 *versus* 38,671 cases in 2008).

According to Chippaux and Goyffon (2008), scorpions are responsible annually for 1.2 million accidents and for about 3,250 deaths in the world. In Brazil, the increased number of scorpion accidents has been attributed to its adaptation to urban and domiciliar areas (Ministério da Saúde, 2001). In this case, the highest incidence was registered in the Northeast Region (Table 1). In contrast, accidents with spiders, caterpillars and bees are a growing problem in states of Southern Brazil. Specifically in the state of Paraná the brown spider (*Loxosceles* genus) is the most important venomous animal responsible for the high incidence of spider envenomation in the whole South Region (da Silva et al., 2004). In contrast, in the states of Rio Grande do Sul and Santa Catarina the caterpillar *Lonomia obliqua*, also called *taturana* (from the American-Indian Tupi-Guarani *tatá*, which means fire, and *raná*, similar to), has been associated with severe cases of hemorrhagic syndrome (Veiga et al., 2009). In this case, although accidents may occur throughout the year, 80 % of cases were reported during summer, when the animal is in the larval stage of its life cycle. Between 1997 and 2005 there were 984 accidents only in the state of Rio Grande do Sul, resulting in a mortality rate of 0.5 % (Abella et al., 2006). Currently, the therapeutic use of specific antivenom (antilonomic serum) has decreased the number of deaths (Table 1). Among bee accidents, the most dangerous are caused by *Apis mellifera* (Africanized bees). In these cases the high number of deaths (30 in 2009) has been associated mainly with the absence of a specific antivenom and the occurrence of allergic reactions (Boletim eletrônico epidemiológico, 2010).

ACCIDENTS WITH VENOMOUS ANIMALS IN BRAZIL. REPORTED DATA: YEAR 2009 *.					
	Snakes	Spiders	Scorpions	Caterpillars	Bees
Total number of accidents	27,655	23,515	45,721	4,028	6,445
Incidence per 100,000 inhabitants	14.4	12.3	24	2.1	3.4
Number of deaths	125	26	104	5	30
Lethality (%)	0.45	0.11	0.23	0.13	0.05
Brazilian Regions	Incidence per 100,000 inhabitants				
North	53.9	3.6	16.2	1.7	1.9
Northeast	14.6	1.3	39.6	0.4	2.5
Midwest	20	2.6	13.3	0.7	2.2
Southeast	7.4	7.1	23.7	1.7	3.2
South	10.1	58.5	3.5	7.3	7

\* Data from Brazilian Ministry of Health, 2010 (Boletim Eletrônico Epidemiológico, April 2010).

Table 1. Epidemiological data of accidents with venomous animals in Brazil.

### 3. Clinical renal manifestations due to snake and arthropod envenomation

A broad clinical spectrum of renal function impairment has been reported in snake and arthropod envenomations (Sitprija, 2006). As the kidneys are highly vascularized organs and have the ability to concentrate substances into the urine they are particularly susceptible

to venom toxins. The most common clinical renal manifestations seen in human patients is acute tubular necrosis, but all renal structures may be involved. Thus, the occurrence of acute tubulointerstitial nephritis, renal cortical necrosis, mesangiolytic, vasculitis, glomerulonephritis, proteinuria, haematuria and myoglobinuria have also been described (Sitprija, 2006).

In this subsection, we reviewed the clinical characteristics of human accidents with snakes and arthropods that cause AKI which are highly prevalent in Brazil and other regions of Latin America. Envenomations by the following animals were analysed: *Bothrops* and *Crotalus* snakes, the brown spider *Loxosceles*, africanized bees, wasps and the caterpillars of genus *Lonomia*. Despite the significant number of accidents with scorpions (Table 1), cases of AKI have not been associated to them. In fact, it is known that the main target of scorpion venom is the nervous and cardiac systems (Cologna et al., 2009).

### 3.1 Snakebite envenomation

Envenomation by snakebite, independently of the species responsible for the bite, enforces medical emergencies since different organs and tissues can be affected at the same time. In Brazil, most severe cases result from bites by snakes of the family Viperidae (pit vipers and true vipers). Within this family are the *Bothrops* and *Crotalus* snakes. Specifically in the *Bothrops* genus there are more than 30 species distributed from southern Mexico to Argentina, including Brazil. The most important species are *Bothrops asper*, *B. jararaca*, *B. atrox*, *B. moojeni*, *B. jararacussu* and *B. alternatus*. *Bothrops* snakes preferentially inhabit rural areas and moist forest environments. But these snakes also invade cultivated areas and ambients with rodents' proliferation. *Bothrops* snakes have nocturnal habits and an aggressive defensive behavior and its venom present proteolytic, coagulant and hemorrhagic active principles that are directly or indirectly implicated in the local and systemic effects observed upon envenoming accidents (Warrel, 2010). Local effects due to the envenoming by these snakes are characterized by bleeding, swelling, pain and sometimes blisters, and can be frequently complicated by the development of local abscesses and necrosis. Occasionally, compartmental syndrome may develop, which results in functional or anatomic loss of the bitten limb (Gutiérrez et al., 2006). Signs of systemic envenoming include gingival hemorrhage, microscopic hematuria, ecchymosis and consumption coagulopathy and, more rarely, epistaxis, hemoptosis, menorrhagia and hematemesis (Gutiérrez et al., 2006; Otero et al., 2002). Disturbances of hemostasis also include severe afibrinogenemia, thrombocytopenia and platelet aggregation dysfunction (Santoro and Sano-Martins, 2004). Deaths are usually attributed to renal injury, shock, severe bleeding, and complicating sepsis.

Renal dysfunction can occur early in the human bothropic envenomation which often induces oliguria and is accompanied by an increase in the plasma creatinine concentration. The need for dialysis ranges from 33 % to 75 % of cases (Pinho et al., 2008). AKI is mainly due to acute tubular necrosis and acute cortical necrosis and occasionally glomerulonephritis (Table 2) (Rodrigues-Sgrignolli et al., 2011). These renal pathological alterations have been attributed mainly to hemodynamic changes in response to envenomation, hemoglobinuria, intravascular clot formation and direct venom nephrotoxicity.

By analyzing a series of retrospective studies, Pinho et al. (2008) reported that the prevalence of AKI after *Bothrops* envenomation ranges from 1.6 % to 38.5 %. In most of these reports AKI diagnosis was based on the increase in the plasma creatinine and/or blood nitrogen urea being, the creatinine *clearance* barely estimated. The main reported factors influencing AKI prevalence upon such envenomation are: the patient's age (children under 10 year of age have been shown to be more susceptible to develop AKI); the snake's age (venom composition can vary even within the same species, according to the snake's age); bite site and amount of inoculated venom; and the time elapsed until antivenom treatment. Moreover, pre-existing diseases such as hypertension, diabetes or previous nephropathies may become patients more vulnerable to the effects of venom (Rodrigues-Sgrignolli et al., 2011; Zelanis et al., 2010). Taking in consideration all the above factors, the mortality rate of *Bothrops* venom-induced AKI range from 13 % to 19 %.

Other snakes well known for their nephrotoxicity are the South American rattlesnakes (*Crotalus* snakes). In Brazil, the *Crotalus* genus is represented by a single specie, *Crotalus durissus*, that is composed of six subspecies: *Crotalus durissus terrificus*, *C. d. collilineatus*, *C. d. cascavella*, *C. d. ruruima*, *C. d. marajoensis* and *C. d. trigonicus*. Besides sharing some common characteristics with other venomous snakes, the *Crotalus* genus presents a rattle at the end of its tail, which is a particular characteristic of these snakes making easier their identification. In general the *Crotalus* snakes are found in rocky and drier regions. They are rarely found in humid forests and feed mainly of small rodents. They are robust (may reach 1 meter in length) and are less aggressive than *Bothrops* snakes (Ministério da Saúde, 2001).

Among the six different subspecies, *C. d. terrificus* is the most frequently implicated in envenomation cases registered in Brazil. The venom has neurotoxic, myotoxic, and nephrotoxic activities (Table 2). In neuromuscular junctions, the venom leads to a powerful presynaptic inhibition of acetylcholine release, which is responsible for the neuromuscular blockade and progressive flaccid paralysis of variable degrees. Eyelid ptosis, blurred and/or double vision, ophthalmoplegia and facial muscle paralysis are common manifestations of venom neurotoxicity. The myotoxic activity of the venom also produces severe skeletal muscle injury leading to myalgia and rhabdomyolysis with the subsequent release of myoglobin from damaged skeletal muscle into serum and urine (Azevedo-Marques et al., 1987). Indeed, the serum creatine kinase (CK) levels are significantly higher (260-folds that of normal values) in patients who develop AKI after a *Crotalus* bite. Other markers of rhabdomyolysis, such as aspartate aminotransferase (AST), alanine aminotransferase (ALT) and lactate dehydrogenase (LDH) are also increased in patients with AKI (Pinho et al., 2005). High serum and urine levels of myoglobin are potentially nephrotoxic, leading to acute tubular necrosis, which is the primary and most serious complication of human crotalid envenomation. Tissue damage at the site of the bite has been reported to be minimal or absent, a feature that differentiates the South American rattlesnake from other species of *Crotalus* and from *Bothrops* envenomations. Spontaneous bleeding has only been rarely observed in human patients, despite the presence of blood incoagulability in some cases (Jorge & Ribeiro, 1992). AKI is the main cause of death among patients surviving to the early effects of *Crotalus* snakebites.

In a study of 100 cases of *Crotalus* bites, Pinho et al. (2005) showed that AKI develops within the first 24 to 48 hours after envenomation. Envenomed patients presented a significant

reduction in glomerular filtration rate (estimated by the creatinine *clearance*). AKI patients also presented dark-brown urine and a fractional excretion of sodium significantly higher than the normal (Pinho et al., 2005). The major kidney pathological alteration is acute tubular necrosis, although interstitial nephritis has also been observed (Amaral et al., 1986; Azevedo-Marques et al., 1985) (Table 2). In this type of envenomation the occurrence of severe rhabdomyolysis is one of the more accepted explanations for the acute tubular necrosis. Other factors potentially associated with venom-induced AKI such as shock, hypotension and hemolysis are present in some cases, but have not been confirmed in *Crotalus* envenomation (Azevedo-Marques et al., 1987; Pinho et al., 2008). Despite of *in vitro* hemolytic activity of *Crotalus* venom, it was confirmed that *in vivo* *C.d. terrificus* envenomation causes myolysis rather than intravascular hemolysis (Azevedo-Marques et al., 1987).

The prevalence of AKI associated with Crotalid envenomation ranges from 10 to 29 % and 68 to 77 % of AKI patients require dialysis treatment. The mortality rate of *Crotalus* venom-induced AKI ranges from 8 to 17 % (Amaral et al., 1986; Pinho et al., 2008; Silveira & Nishioka, 1992). Although most risk factors for AKI are very similar to those described for bothropic envenomation it was reported that early after *Crotalus* snakebite the plasma levels of CK (higher than 2,000 U/L) were associated with a 12-fold increase in the risk of developing AKI (Pinho et al., 2005).

### 3.2 Brown spider envenomation

Among arthropods, spider and scorpion bites are the most frequent and of medical care importance. Although the number of accidents with scorpions often overcome those with spiders, reports of AKI after human envenomation with scorpion are scarce (Abdulkader et al., 2008). One species of spider that can cause severe renal injury is the brown spider (*Loxosceles* genus). Spiders of the genus *Loxosceles* have a worldwide distribution, since they can live under variable conditions such as temperature ranging from 8 to 43°C and that they can stay long time intervals living without food or water (Hogan et al., 2004; Swanson and Vetter, 2006). In Brazil, seven species have been described, but some of them are the most frequently implicated in bites in humans, namely *Loxosceles intermedia*, *L. gaucho* and *L. laeta*. These spiders are commonly found inside the residences both in rural and urban areas. They are small, measuring between 8 and 15 mm of body length while their legs measure 8-30 mm. Their colour varies from a pale brown (*L. laeta*) to a dark brown (*L. gaucho*). *Loxosceles* spiders are not aggressive and the bites usually occur when they are pressed against the body, mainly while the victim is sleeping or dressing (da Silva et al., 2004).

The venom has proteolytic, dermonecrotic, hemolytic and nephrotoxic activities (Isbister & Fan, 2011) (Table 2). The accident may have local and systemic manifestations that are exhibited in two different clinical forms: cutaneous and viscerocutaneous loxoscelism (da Silva et al., 2004). Most patients have only the local manifestation or cutaneous loxoscelism. In these cases, the accident may cause mild cutaneous inflammatory reaction or a local injury characterized by pain, edema and erithrema, later developing to dermonecrosis with gravitational spreading. In the minority of cases loxoscelism can cause a systemic injury or the viscerocutaneous loxoscelism. This form occurs

predominantly in children, and patients can develop AKI, which is considered the main cause of death after brown spider envenomation. Viscerocutaneous loxoscelism is characterized by fever, malaise, weakness, nausea and vomiting, hemolysis, hematuria, jaundice, thrombocytopenia and disseminated intravascular coagulation. This severe multisystemic clinical picture can occur as early as 24 hours after the bite (Abdulkader et al., 2008; da Silva et al., 2004; Isbister & Fan, 2011).

Analysis of 267 loxoscelism cases reported in Brazil showed that the viscerocutaneous form was diagnosed in 13.1 % of the cases, where *L. laeta* was the main specie implicated in the accidents. The investigators reported jaundice in 68.6 %, oliguria in 45.7 %, anuria in 8.6 %, dark urine in 28.6 %, hemorrhage in 25.7 %, and shock in 2.9 % of the patients. AKI occurred in 6.4 % of the patients, and most of them were diagnosed more than 24 hours after the bite. Four patients died (1.5 %), all of them were children under 14 years old (Sezerino et al., 1998). The main factors likely associated with AKI development are hemolysis, hypotension/shock, and direct venom nephrotoxicity (Table 2). Pigment-induced acute tubular necrosis was reported in human necropsies of viscerocutaneous loxoscelism (Zambrano et al., 2005). Thus, it was suggested that the pathological effect of the venom on the kidney may reflect hematological disturbances, such as intravascular hemolysis and disseminated intravascular coagulation (Abdulkader et al., 2008). Although only low myotoxic activity has been reported in *Loxosceles* venom, rhabdomyolysis can also occur after envenomation. In this cases, high levels of serum CK and deposits of myoglobin in tubular cells have been observed (França et al., 2002; Lucato-Junior et al., 2011).

### 3.3 Bee and wasp envenomation

Stings of insects from the order Hymenoptera, which includes several species of bees, hornets, wasps and yellow jacks, have also been implicated in cases of human envenomation (Vetter et al., 1999).

In general the victims present only local allergic reactions after one or a few stings. However, after a massive attack with hundreds or thousands of stings, a systemic envenomation may occur (Abdulkader et al., 2008). The majority of envenomation cases with medical importance is caused by the so-called Africanized bees (*Apis* genus). These bees are hybrids between bees of European origin (*Apis mellifera mellifera* and *Apis mellifera ligustica*) and African bees (*Apis mellifera scutellata*) which were originated by the introduction of different species in Brazil since 1957. Currently, due to the migratory behavior and a high reproductive rate they are found throughout South America, Central America and parts of North America. Because of their aggressive behavior and the number of accidents associated with them, the Africanized bees are also known as “killer bees” (Abdulkader et al., 2008; França et al., 1994).

The main venom activities are hemolytic, myotoxic, cardiotoxic and nephrotoxic (Table 2). Clinical manifestations can be divided into allergic and systemic reactions. Allergic reactions usually are observed in patients with a history of previous bee stings or asthma or other hypersensitivity disease. These reactions occur immediately after a single sting and can lead to anaphylaxis and death by laryngeal edema. Systemic reactions usually occur after multiple stings and are characterized by pain, erythema, urticaria, release of histamine,



nausea, vomiting, respiratory failure, hypotension and shock (Abdulkader et al., 2008). Rhabdomyolysis and hemolysis can be detected a few hours after the accident (Chao et al., 2004). Fatalities are typically the result of renal damage or from cardiac arrest due to complications of the venom toxicity (Vetter et al., 1999).

AKI has been observed in cases of massive attacks with 150 stings to more than 1,500 stings. Envenomed patients commonly have anuria or oliguria, high levels of serum creatinine (10-30 mg/dL) and CK (>2,000 U/L), hypotension, tachycardia, myocardial damage and anemia (Daher et al., 2003; Gabriel et al., 2004; França et al., 1994; Xuan et al., 2010). Acute tubular necrosis is the main histologic finding in human beings, domestic dogs, and in experimental animals after bee and wasp envenomations. Allergic interstitial nephritis with concurrent pigment tubulopathy resulting from both hemoglobin and myoglobin has also been described after wasp stings (Chao et al., 2004; Zhang et al., 2001) (Table 2). A direct nephrotoxicity of the venom and/or hypotension caused by anaphylactic reaction are also mechanisms implicated in AKI induced by bees of *Apis* genus (Grisotto et al., 2006). By analyzing five cases of severe envenomation by Africanized bees, França et al. (1994) found high venom concentrations in serum and urine which remain for more than 50 h after the stings in two fatal cases; in one of them the total circulating unbound whole venom components was estimated at 27 mg, one hour after the attack. Despite the treatment with dialysis, antihistamines, corticosteroids, bronchodilators, vasodilators, bicarbonate, mannitol and mechanical ventilation, three out four patients died between 22 and 71 h after the attacks. However, in the majority of cases, the renal damage is usually reversible responding well to the dialysis. Complete recovery may require 3-6 weeks (Vetter et al., 1999).

### 3.4 Caterpillar envenomation

The accidental contact with some lepidopteran caterpillars can also cause human envenomation cases that vary from simple skin irritation and local allergic reactions to a systemic disease characterized by renal damage and hemorrhagic disturbances (Pinto et al., 2010; Veiga et al., 2009). From the medically important Saturniidae family, *Lonomia* genus has been attributed to cause human envenomations since late 1960's in Venezuela (Arocha-Piñango et al., 2000). In Southern Brazil, *Lonomia obliqua* caterpillar is becoming the most important venomous animal responsible for severe injuries, hemorrhagic disorders and often fatal outcome since the 1980's (Duarte et al., 1990). For instance, in the State of Rio Grande do Sul, located in this Brazilian region, more than a thousand accidents have been registered in the period from 1997 to 2005 (Abella et al., 2006). In fact, based on data from the year 2009, the Brazilian Ministry of Health registered an incidence of 7.3 lepidopteran envenomations per 100,000 inhabitants in Southern Brazil (Boletim eletrônico epidemiológico, 2010) (Table 1). Actually, these numbers are greatly underestimated due to the fact that most accidents are occurring in distant rural areas, where the cases are poorly reported. *Lonomia's* accidents usually occur when the victim, leaning against tree trunks containing dozens or hundreds of caterpillars, comes into contact with their bristles. These structures are hard and spiny evaginations of the cuticle, underneath which the toxins are stored. Often, the whole animal is smashed in the accident, the insect's chitinous bristles get broken and the venomous secretions, including hemolymph, penetrate the human skin and enter the circulation (Veiga et al., 2001a).

The venom presents procoagulant, fibrinogenolytic, proteolytic and hemolytic activities (Table 2). Clinical symptoms of *Lonomia* envenomation include local pain (burning sensation) and inflammatory reaction, which starts immediately after contact; systemic reactions such as headache, fever, vomiting and asthenia, which appear a few hours after exposure; and bleeding diathesis characterized by hematomas and ecchymosis, gross hematuria, hematemesis, melena, pulmonary and intracerebral hemorrhage and AKI (Pinto et al., 2010). Intravascular hemolysis has also been described in human envenomation and experimental studies (Malaque et al., 2006; Seibert et al., 2004). The activation of blood coagulation, fibrinolysis and the systemic inhibition of platelet function are mechanisms that seem to contribute to the hemorrhagic syndrome commonly observed in *Lonomia* envenomation (Berger et al., 2010a). In human patients, this hemorrhagic syndrome manifests as a consumptive coagulopathy without thrombocytopenia (Berger et al., 2010a; Zannin et al., 2003).

The incidence of AKI varies from 2 to 5 % of envenomation cases reported in the literature (Duarte et al., 1990; Gamborgi et al., 2006). Of the 2,067 patients evaluated in southern Brazil (period from 1989 to 2003), 39 (1.9 %) developed AKI (serum creatinine levels > 1.5 mg/dL). Eleven (32 %) of these patients were treated with dialysis and four (10.3 %) developed chronic renal injury (CRI). All victims with AKI presented concomitantly coagulation disturbances and hematuria and/or hemoglobinuria. Seven deaths (4%) occurred during the period (Gamborgi et al., 2006). The impossibility of conducting early renal biopsies, due the coagulation disturbances inherent to the envenomation, has made it difficult to analyze the acute anatomopathological alterations. The few reports existing in the literature describe thickening of the Bowman's capsule, focal tubular atrophy and acute tubular necrosis (Burdmann et al., 1996; Fan et al., 1998) (Table 2). Similarly, the contribution of other factors possibly associated with AKI, such as hypotension or glomerular fibrin deposition, remains still obscure in *Lonomia* envenomation.

#### **4. Toxins of snake and arthropod venoms and their role in the pathophysiology of acute kidney injury**

Animal venoms are mixtures of biologically active proteins and peptides, and also non-protein toxins, carbohydrates, lipids, amines, and other small molecules. The clinical features of envenomation reflect the effects of these different venom components and thus, the contribution of the venom toxins to the pathophysiology of renal injury is complex and multifactorial (Sitprija, 2006).

Based on the current knowledge, the hypothesis for pathogenesis of venom-induced AKI include both a direct cytotoxic action of the venom on different renal structures, and a secondary response of the whole organism resulting from systemic envenomation. The secondary response is usually triggered by inflammation, release of cytokines and vasoactive substances that leads to changes in renal function and hemodynamics (Fig. 1). In fact, there is an increase in plasma concentration of different cytokines and vasoactive substances such as TNF- $\alpha$ , interleukins, nitric oxide, histamine, bradykinin and eicosanoids following several types of envenomations (Petricevich et al., 2000). The elevation of cytokines are mainly due to accumulation of pro-inflammatory cells and immune system response. Together, all these mediators can impair renal function ultimately contributing to

a decrease in renal perfusion pressure, renal blood flow and glomerular filtration rate. As a result in association with the systemic hypotension (Table 2), there will be an inadequate tissue and cellular oxygen delivery which can generate an ischemic process. Since the intermediary metabolism and energy production have an absolute dependence on oxygen, and oxygen cannot be stored intracellularly, the inadequate oxygen availability rapidly leads to cellular dysfunction, injury, and cell death by necrosis (Deitch, 1992). Important contribution to venom-induced renal ischemia is also derived from the process of hemolysis, rhabdomyolysis and/or intravascular deposition of platelets and fibrin in the microcirculation (Table 2). The presence of hemoglobin and myoglobin also have a direct cytotoxic effect on renal tubules (Fig.1) (Khan, 2009; Zager, 1996). Thus, it seems that different, but interrelated processes may contribute to the nephrotoxicity and even to other pathological features observed in envenomed patients.

<b>Venomous animals</b>	<b>Main venom activities</b>	<b>General clinical manifestations</b>	<b>Characteristics of AKI and renal pathology</b>
<i>Bothrops</i> snakes	Hemorrhagic, Procoagulant, Proteolytic and Nephrotoxic	Local abscesses and necrosis, Spontaneous bleeding, DIC, Hypotension	Oliguria/anuria, Hemoglobinuria, Hematuria, ATN, AIN, RCN, GFD
<i>Crotalus</i> snakes	Neurotoxic, Myotoxic and Nephrotoxic	Flaccid paralysis, Myalgia, Rhabdomyolysis	Decrease in GFR, Myoglobinuria, ATN, AIN
Brown spiders ( <i>Loxosceles</i> )	Dermonecrotic, Proteolytic, Hemolytic and Nephrotoxic	Local abscesses and necrosis, Hemolysis, Rhabdomyolysis, DIC, Hypotension	Hematuria, Hemoglobinuria, Myoglobinuria, ATN
Africanized Bees ( <i>Apis mellifera</i> )	Hemolytic, Myotoxic, Cardiotoxic and Nephrotoxic	Allergic reaction (anaphylaxis), Hypotension, Hemolysis, Rhabdomyolysis	Oliguria/anuria, ATN, AIN, Hemoglobinuria, Myoglobinuria
<i>Lonomia</i> caterpillars	Procoagulant, Fibrinolytic, Proteolytic and Hemolytic	Ecchymosis, Spontaneous bleeding, DIC, Hemolysis	Hematuria, Hemoglobinuria, ATN

DIC - Disseminated Intravascular Coagulation; ATN - Acute tubular necrosis, AIN - Allergic interstitial nephritis, RCN - Renal Cortical Necrosis, GFD - Glomerular Fibrin Deposition, GFR - Glomerular Filtration Rate.

Table 2. Clinical aspects of venom-induced Acute Kidney Injury (AKI).

Recently, advances in molecular biology, proteomics and transcriptomics, facilitated the isolation of toxins and contributed significantly to the study of their mechanisms of action on renal tissue. In this subsection, we reviewed the renal physiopathological effects of snake and arthropod venoms and their main isolated toxins. Special emphasis was given to

experimental studies with venomous animals highly prevalent in Brazil and other regions of Latin America. As in the previous subsection the following animals were included: *Bothrops* and *Crotalus* snakes, the brown spider *Loxosceles*, africanized bees, wasps and the caterpillars of genus *Lonomia*.

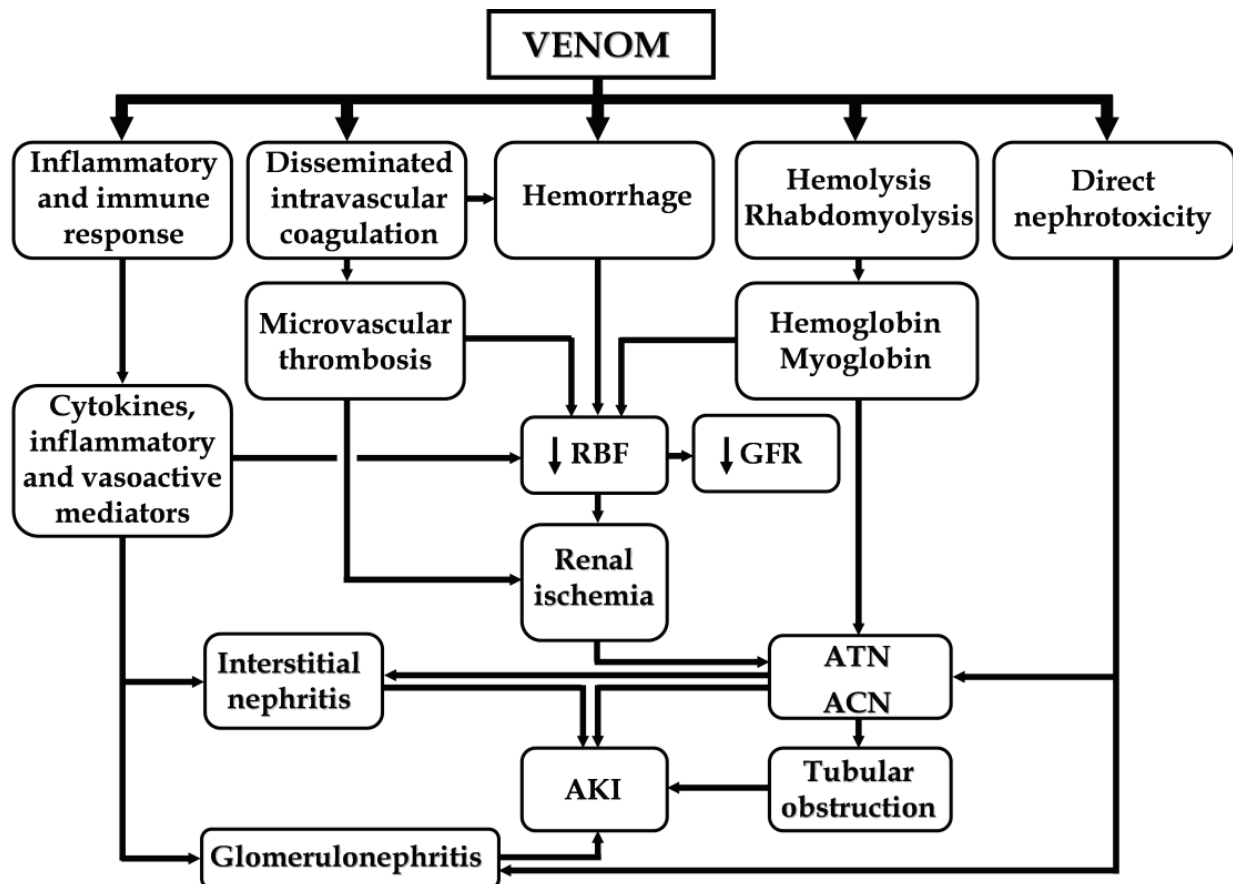


Fig. 1. Schematic summary of pathophysiological phenomena involved in the venom-induced acute kidney injury (AKI). RBF - Renal Blood Flow; GFR - Glomerular Filtration Rate; ATN - Acute Tubular Necrosis; ACN - Acute Cortical Necrosis.

#### 4.1 Snake venoms

##### 4.1.1 *Bothrops* venom

The venom of *bothrops* snakes can cause prominent local tissue damage usually characterized by swelling, blistering, hemorrhage and necrosis of skeletal muscle. Such local pathology is mostly due to the venom proteolytic action (Gutiérrez et al., 2006). Snake venom metalloproteinases (SVMPs), phospholipases A<sub>2</sub>, serine proteinases, esterases, L-amino acid oxidases, hyaluronidases, C-type lectins-like and bradykinin-potentiating peptides (BPPs) are the main venom components that acts inducing cellular injury or releasing inflammatory and vasoactive mediators (Warrell, 2010). Transcriptomic and proteomic studies have showed that SVMPs and serine proteinases are the major toxins in the venom, which explained the high local damage and hemorrhage seen in envenomed patients (Table 2) (Cidade et al., 2006; Zelanis et al., 2010). *Bothrops* toxins are also known for their multiple effects on hemostasis. In fact, the venom have thrombin-like enzymes, factor

X and prothrombin activators that are able to directly convert fibrinogen into fibrin (Berger et al., 2008; White, 2005). These actions produce intravascular coagulation and may lead to blood incoagulability by consumption coagulopathy. Systemic inhibition of platelet aggregation and thrombocytopenia are common (Rucavado et al., 2005; Santoro & Sano-Martins, 2004). Moreover, anti-hemostatic principles, such as thrombin and platelet aggregation inhibitors, are also found in *bothrops* venoms (Kamiguti, 2005; Zingali et al., 2005).

Regarding renal function, Boer-Lima et al. (1999) observed that the intravenous injection of *B. moojeni* venom in rats, produced renal tubular disturbances including an increase in proximal and post-proximal fractional excretion of sodium associated with acute tubular necrosis. The glomerular filtration rate decreased significantly, despite the absence of systemic hypotension. Severe morphologic disturbances in the renal glomeruli also occurred. The changes included mesangiolytic, glomerular microaneurysms, and glomerular basement membrane abnormalities. In addition, there was a reduction in the number and width of podocyte pedicels, which caused a reduction in the number of filtration slits. The morphophysiological changes observed in experimental animals also correlated with the levels of proteinuria (Boer-Lima et al., 2002). Similar renal functional alterations were observed after intravenous injection of *B. jararaca* venom into rats. In these animals, differently of human envenomation, *B. jararaca* venom was not able to induce systemic hypotension but significantly reduced the renal plasma flow and increased renal vascular resistance (Burdmann et al., 1993). There was no increase in CK, indicating that rhabdomyolysis is not an important consequence of *B. jararaca* envenomation. However, the venom caused marked fibrinogen consumption and intravascular hemolysis. Indeed, kidney of rats and rabbits envenomed with *B. jararaca* showed an extensive intraglomerular deposition of fibrin and platelets (Burdmann et al., 1993; Santoro & Sano-Martins, 2004). Contrarily to the findings with *B. jararaca* venom, Boer-Lima et al. (1999) did not observe any glomerular fibrin deposition in the *B. moojeni* envenomation. They suggested that the glomerular injury is more likely to be related to structural disorganization of the glomerular capillary tuft, consequent to a direct action of the venom on the mesangial matrix, glomerular basement membrane and podocytes rather than to fibrin deposition in the capillaries.

Studying the kinetic of renal distribution of injected *B. alternatus* venom in rats, Mello et al. (2010) detected the highest venom concentration in renal tissue 30 min post-venom injection. After this time, venom concentration decreased progressively. Venom components were also detected into urine 3, 6 and 24 h post-venom injection. By immunohistochemistry, venom proteins were detected in glomeruli, proximal and distal tubules, and vascular and perivascular tissue, suggesting that toxins bind to kidney structures where they probably exert a direct nephrotoxic action. In accordance to this observation, it was shown that *B. alternatus* venom is cytotoxic to canine renal epithelial cells (MDCK) in culture and causes extensive cytoskeletal alterations inducing impairment of the cell-matrix interaction (Nascimento et al., 2007). Additionally, it was described that *B. jararaca* venom also causes *in vitro* injury of isolated renal proximal tubules and that the *B. moojeni* venom increases cell release of lactate dehydrogenase and decreased cellular uptake of the vital neutral red in MDCK cells (de Castro et al., 2004; Collares-Buzato et al., 2002). Functionally, *B. alternatus* venom induced oliguria, urine acidification, decreased in glomerular filtration rate and

hematuria. Morphologically, the venom caused lobulation of the capillary tufts, dilation of Bowman's capsular space, disruption of renal tubule brush border, and fibrosis around glomeruli and proximal tubules that persisted 7 days after envenomation (Linardi et al., 2011; Mello et al., 2010).

Some purified *Bothrops* toxins are able to reproduce the renal effects obtained with whole venom. Studies on the isolated perfused rat kidney have shown that L-amino acid oxidase (Braga et al., 2008), C-type lectins (Braga et al., 2006), phospholipase A<sub>2</sub> myotoxins (Barbosa et al., 2005; Evangelista et al., 2010) and thrombin-like enzyme (Braga et al., 2007) from *Bothrops* venoms can alter renal function. The isolated perfused kidney technique also confirmed the direct acute tubular nephrotoxicity of *Bothrops* venoms and showed that platelet activating factor might play a role in some renal functional disturbances such as the decreased in glomerular filtration rate (Monteiro and Fonteles, 1999). However, the systemic injection of baltergin, a purified metalloproteinase from *B. alternatus* venom, only mildly affected the kidney structure. At high doses, baltergin causes congestion, subcapsular hemorrhage and inflammatory infiltrate (Gay et al., 2009). There was no detection of tubular necrosis indicating that different toxins act synergistically to produce the AKI observed in animals treated with whole venom.

#### 4.1.2 *Crotalus* venom

The venom of *Crotalus* rattlesnakes is a complex combination of different enzymes and toxic peptides that mainly display neurotoxic and myotoxic activities (Boldrini-França et al., 2010). Toxins affecting hemostasis, such as thrombin-like enzymes and platelet activators are also found. The main protein families identified by proteomics included phospholipases A<sub>2</sub>, serine proteinases, cysteine-rich secretory proteins (CRISP), vascular endothelial growth factor-like molecules (VEGF), L-amino acid oxidases, C-type lectins-like, and snake venom metalloproteinases (SVMP). Crotoxin, a neurotoxic phospholipase A<sub>2</sub>, represents more than 60 % of the proteins in the whole venom and is the major component responsible for its neurotoxic and myotoxic effects (Boldrini-França et al., 2010). Additionally, crotoxin also exhibits cardiotoxic and direct nephrotoxic activities. Structurally, crotoxin is a heterodimeric  $\beta$ -neurotoxin that consists of a toxic basic phospholipase A<sub>2</sub> and a nonenzymatic, non-toxic acidic component (crotapotin). Crotapotin potentiates the activity of crotoxin, since it prevents the basic phospholipase subunit binding to non-specific sites (Sampaio et al., 2010; Soares et al., 2001). Crotoxin targets neuromuscular junctions and inhibits the release of acetylcholine, which leads to neuromuscular blockade and muscular and respiratory paralysis. In the muscle tissue, crotoxin causes selective injury of skeletal muscle groups composed of type I and IIa fibers, which are extremely vascularized and rich in myoglobin (Sampaio et al., 2010). Other important toxins are crotamine, convulxin and gyroxin. Crotamine is a toxic peptide with myonecrotic activity (Martins et al., 2002). Convulxin is a C-type lectin-like glycoprotein with high affinity to specific receptors in rabbit and human platelets. Convulxin binds to the putative collagen receptor glycoprotein VI (GPVI) and mediates platelet adhesion, aggregation and intracellular calcium mobilization (Francischetti et al., 1997). Gyroxin is a serine proteinase that displays several activities including the induction of blood coagulation (thrombin-like activity), vasodilation and neurotoxicity (Alves da Silva et al., 2011).

Intraperitoneal injection of *C.d. terrificus* venom in mice increased plasma creatinine and uric acid and caused urinary hypoosmolality. When compared to control groups injected with saline, the incidence of hypercreatinemia and hyperuricemia (plasma values higher than 1.8 mg/dL) occurred in 60 % and 100 % of the experimental animals, respectively (Yamasaki et al., 2008). *Crotalus* experimental envenomation was also associated with significant renal blood flow and glomerular filtration rate decreases and ischemia with consequent acute tubular necrosis. In isolated perfused rat kidneys treated with crude venom or crotoxin, a large amount of protein material was observed in the glomeruli, probably due to a direct toxic effect of the venom on the glomeruli and tubules and/or to an increase in vascular permeability (Monteiro et al., 2001). Prostaglandins and TNF- $\alpha$  release seems to be important since the treatment with indomethacin and pentoxifylline (inhibitors of cyclooxygenase and TNF- $\alpha$  synthesis, respectively) were able to blockade the renal effects induced by supernatant of macrophages activated with *Crotalus* venom (Martins et al., 2003; Martins et al., 2004). Among the main venom components, crotoxin was able to induce significant changes in glomerular filtration rate and electrolyte transport in isolated kidney. Gyroxin caused only mild alteration in renal parameters and convulxin had no effects (Martins et al., 2002).

Rhabdomyolysis is a well-known cause of AKI and is commonly observed in envenomed patients and envenomed experimental animals. Myoglobin toxicity has been related to renal vasoconstriction, intraluminal cast formation and direct heme-protein cytotoxicity. Myoglobin can contribute to renal vasoconstriction by directly binding to nitric oxide (NO). Thus, acting as NO scavenging molecules, heme-proteins (including myoglobin or hemoglobin) lead to renal hypoperfusion, reductions in the storage of ATP, ischemia and tissue injury (Zager, 1996). Intraluminal casts are formed due to the precipitation of myoglobin inside the renal tubules, forming obstructive casts. Precipitated myoglobin also can be degraded resulting in the release of free iron and heme. Once released, free iron and heme contribute to renal injury by generate reactive oxygen species (ROS) and lipid peroxidation (Khan, 2009; Zager, 1996). Indeed, Yamasaki et al. (2008), showed an increase of oxidized glutathione/reduced glutathione ratio (GSSG/GSH) in renal tissue during *Crotalus* envenomation. This data indicates a rise in the ROS generation by consumption of reduced glutathione (GSH) and production of oxidized glutathione (GSSH) which are the main antioxidant and oxido-reducing agents, respectively. Confirming the participation of ROS in *Crotalus* induced renal injury, envenomed animals treated with lipoic acid (an antioxidant molecule) had their GSSG/GSH ratios normalized when compared to control groups (Alegre et al., 2010). In addition to deleterious effects of obstructive myoglobin casts formation, the high levels of uric acid found in envenomed animals also contribute to tubular obstruction (Yamasaki et al., 2008). Marked hyperuricemia is known to cause AKI by supersaturation, crystallisation and deposition of crystals inside renal tubules (acute urate nephropathy). Moreover, experimental hyperuricemia causes renal vasoconstriction and soluble uric acid has been shown to inhibit endothelial NO bioavailability (Ejaz et al., 2007). Recently, it was observed that systemic inhibition of uric acid synthesis, by allopurinol treatment, significantly reduced lethality rate, normalized GSSG/GSH ratio and ameliorate the renal histopathological changes. Thus, uric acid also seems to have an important role in renal pathophysiology of *Crotalus* envenomation (Frezza & Silveira, 2011).

#### 4.2 *Loxosceles* venom

The bites of brown spiders (*Loxosceles* genus) led to several clinical manifestations such as necrotic skin degeneration and gravitational spread at the bite site, renal injury and hematological disturbances. Several studies concerning the structural and biological roles of various venom components have shown the complex nature of these venomous secretions. Likewise, the venom of *Loxosceles* spiders is a complex mixture of protein-based toxins with a molecular mass profile ranging from 5 to 40 kDa. The main components belong to the classes of phospholipases D (or dermonecrotic toxins), serine proteinases, venom allergens, hyaluronidases, astacin-like metalloproteinases and insecticidal peptides (Gremski et al., 2010). Dermonecrotic toxins and astacin-like metalloproteinases are considered the major components responsible for the clinical profile observed in envenomed victims (Table 2) (da Silva et al., 2004). In fact, a transcriptomic study indicated that phospholipases D and astacin-like metalloproteinases represent 20.2 % and 22.6 % of total toxin-encoding transcripts, respectively. Other toxins also important to envenomation, such as serine proteinases, venom allergens and hyaluronidases represent the minority of encoding transcripts (Gremski et al., 2010).

Among all the toxins found in *Loxosceles* spider venom, dermonecrotic toxin is undoubtedly the component most investigated and characterized. This toxin is able to reproduce the major biological effects induced by whole venom. It is involved with the development of dermonecrotic lesions and can trigger neutrophil migration, complement system activation, cytokine and chemokine release, platelet aggregation, lysis of red blood cells, among other effects (Abdulkader et al., 2008; da Silva et al., 2004). Dermonecrotic toxin comprises a family of toxins with different related isoforms that have biological, amino acid and immunological similarities which are found in several *Loxosceles* species. Only in *L. intermedia* venom, many isoforms were described being 9 out of them already expressed as recombinant proteins (Gremski et al., 2010). *Loxosceles* dermonecrotic toxins belong to phospholipases D (30–35 kDa) class of enzymes which was primarily designated as sphingomyelinases D due to their ability to convert sphingomyelin to choline and ceramide 1-phosphate (N-acylsphingosine 1-phosphate). As some *Loxosceles* sphingomyelinases D have broad substrate specificity, being able to hydrolyze not only sphingophospholipids but also lysoglycerophospholipids, they are now classified as phospholipases D (Lee and Lynch, 2005). Due to sequence, structural and biochemical differences these toxins are grouped in two classes and their structures and substrate specificities have been recently elucidated (de Giuseppe et al., 2011; Murakami et al., 2005). Other important components of *Loxosceles* venom are the metalloproteinases. The enzymes have molecular weights ranging from 20 to 35 kDa displaying gelatinolytic, fibronectinolytic and fibrinogenolytic activities. They are zinc endopeptidases homologous to the astacin family of metalloproteinases from the crayfish, *Astacus astacus*. The *Loxosceles* astacin-like metalloproteinases possess a digestive function used to initiate the degradation of prey molecules, facilitating the posterior ingestion process (Trevizan-Silva et al., 2010). Furthermore, these enzymes have an important role in the pathogenesis observed in envenomation, particularly inducing hemorrhage into the dermis, injury of blood vessels, imperfect platelet adhesion, and the defective wound healing observed in some cases. Likewise, these metalloproteases can also render tissue structures more permeable, facilitating other noxious toxins to spread throughout the body of victims (Veiga et al., 2000; Veiga et al., 2001b).



The nephrotoxic effect of the *L. intermedia* spider venom was demonstrated experimentally in mice exposed to the whole venom (Luciano et al., 2004). Histopathological analysis showed morphological renal alterations including hyalinization of proximal and distal tubules, erythrocytes in Bowman's space, glomerular collapse, tubule epithelial cell blebs and vacuoles, interstitial edema, and deposition of a protein-rich material inside the Bowman's space and tubule lumen. Morphometric analysis showed that 75–80 % of the kidney area was affected by the venom and no glomerular or tubule leukocyte infiltration was described, suggesting that the involvement of inflammatory process is not important to renal injury in this type of envenomation. Despite the presence of erythrocytes and protein deposits in glomerular and tubular structures, no signs of intravascular hemolysis or hemoglobin were detected in envenomed animals. Supporting the evidence that *L. intermedia* venom has toxins with direct nephrotoxicity, confocal microscopy studies with antibodies against venom proteins were able to show direct binding of toxins to renal structures. Venom proteins were detected in glomerular and tubular epithelial cells and in renal basement membranes. Toxins with molecular weights of 30 kDa were also identified in renal tissue extracts by immunoblotting (Luciano et al., 2004). One of these venom proteins that can bind to the kidney tissue is the dermonecrotic toxin. Chaim et al. (2006), injecting the recombinant dermonecrotic toxin in mice, found glomerular edema and tubular necrosis without signs of inflammatory response. Additionally, the dermonecrotic toxin was detected in kidney tissue and induced changes in renal function such as urine alkalinization, hematuria and elevation of blood urea nitrogen levels. The treatment of renal epithelial cells (MDCK) with recombinant dermonecrotic toxin also caused morphological alterations and reduced the cell viability, confirming its direct cytotoxicity (Chaim et al., 2006). Both effects upon renal structures *in vivo* and renal cells *in vitro* were dependent of the phospholipase D catalytic activity, since a mutated toxin without phospholipase activity showed no nephrotoxic effect (Kusma et al., 2008). Another mechanism involved in AKI induced by *Loxosceles* venom is the renal vasoconstriction and rhabdomyolysis. Recently, it was reported that *L. gaucho* caused a sharp and significant drop in glomerular filtration rate, renal blood flow and urinary output and increased renal vascular resistance in rats (Lucato-Júnior et al., 2011). In this model, the authors also found deposits of myoglobin in tubular cells and degenerative lesions indicative of an ischemic process (Lucato-Júnior et al., 2011).

#### 4.3 Bee and wasp venoms

Bee and wasp venoms are composed of a mixture of proteins, peptides, and small molecules, which are related to different mechanisms of envenomation. In the Africanized bee (*Apis mellifera*) venom the most important components are melittin and phospholipase A2. Melittin is a highly toxic peptide and the most abundant component of bee venom comprising about 50 % of its dry weight. This peptide is able to disrupt biological membranes, producing many effects on living cells (Fletcher et al., 1993). Melittin has antibacterial activity, induces voltage-gated channel formation and can also produce micellization of phospholipids bilayers due to its membrane-interacting effect. This peptide is responsible for the direct hemolytic effect of *Apis* venom (Dempsey, 1990; Terra et al., 2007). The enzyme phospholipase A2 represents approximately 11 % of whole venom and acts synergically with melittin. Once melittin has disrupted the membrane, phospholipase

A2 cleaves bonds in the fatty acid portion of the bilipid membrane layer (Vetter et al., 1999; Lee et al., 2001). In association, melittin and phospholipase A2, can act on erythrocytes, myocytes, hepatocytes, fibroblasts, mast cells, and leukocytes (Abdulkader et al., 2008; Fletcher et al., 1993; Habermann, 1972). Additionally, bee venom also has hyaluronidase (an enzyme that disrupts the hyaluronic acid in connective-tissue matrix), apamin (a neurotoxin), mast cell degranulating peptide (a peptide that releases histamine from mast cells) and other small molecules such as histamine, dopamine, and noradrenaline. Among all *Apis mellifera* venom components the main allergens are melittin, phospholipase A2 and hyaluronidase (Vetter et al., 1999). In wasp venoms the components are active amines (serotonin, histamine, tyramine, catecholamines); wasp kinins (similar in composition to bradykinin), which are mostly responsible for pain; and histamine-releasing peptides, which are responsible for the inflammatory response. The major allergens identified in wasp venoms are phospholipase A1, a hyaluronidase and a serine-protease (Pantera et al., 2003; Vetter et al., 1999).

Despite the current knowledge on the composition of wasp venoms, little is known about the participation of its components, and even the whole venom, on the AKI observed in envenomed patients. On the other hand, the mechanisms of bee venom-induced AKI have been more explored in experimental models *in vivo* and *in vitro*. In the case of bee envenomation, the experimental injection of venom in rats caused a significant and early reduction in glomerular filtration rate and diuresis and an increase in plasma creatinine levels (dos Reis et al., 1997; Grisotto et al., 2006). Tubular alterations such as increased fractional sodium and potassium excretions and a reduced water transport through collecting tubules, were also described (dos Reis et al., 1997). The early glomerular filtration rate reduction was concomitant with marked cortical and medullary renal blood flow decrease (Grisotto et al., 2006). Neither hypertension and hypotension nor intravascular hemolysis were detected in experimental models. Despite of the absence of hemolysis, rhabdomyolysis was present with massive myoglobin deposition in the lumen of the tubules as well as into the tubular cells (dos Reis et al., 1997; Grisotto et al., 2006). The injection of purified melittin or phospholipase A2 also induced rhabdomyolysis, due to their capacity to disrupt the membranes of myocytes (Ownby et al., 1997). Additionally, *in vitro* studies have been demonstrated that bee venom is cytotoxic to cultured isolated proximal tubule cells (Grisotto et al., 2006). Histological analysis showed acute tubular necrosis mainly in cortex and outer medulla, and cast formation in the distal and collecting tubules (dos Reis et al., 1998). These degenerative lesions observed in AKI induced by the bee venom have been associated with the ischemic process induced by melittin, phospholipase A2 and histamine (Abdulkader et al., 2008; Grisotto et al., 2006). Indeed, melittin and phospholipase A2 may be related to impaired renal blood flow by causing direct vasoconstriction, smooth muscle cell contraction, increased renal renin secretion and release of vasoconstrictor eicosanoids and catecholamines. Histamine and the mast cell degranulating peptides present in the venom also play a role in renal blood flow decrease, since histamine can directly induce vascular changes (Cerne et al., 2010; Churchill et al., 1990).

#### 4.4 *Lonomia* venom

Caterpillars of the species *L. obliqua* are well known in Southern Brazil by causing a severe hemorrhagic syndrome characterized by coagulation disorders, AKI and generalized

hemorrhage. The venom is composed of several active principles, including procoagulant and fibrinolytic activities (Pinto et al., 2010). Even though many studies have been performed with toxic secretions from *L. obliqua* aiming a better elucidation of the hemorrhagic syndrome resulting from this envenomation, few active principles have been purified from the venom and fully characterized so far. Thus, most of the molecules identified in this caterpillar have been characterized as putative enzymes and other proteins based solely on cDNA and amino acid sequences obtained by transcriptomic and proteomic methods (Ricci-Silva et al., 2008; Veiga et al., 2005). Through these techniques, the major protein found in *Lonomia* is a biliverdin-binding protein of the lipocalin family, which is mainly concentrated in the bristles and plays an important role in the caterpillar's camouflage behavior. Along with the lipocalin and other housekeeping proteins, *L. obliqua's* integument, hemolymph and bristles produce and store a variety of active principles. Among these proteins, the most abundant ones are serine proteases and their inhibitors (serpins) in the integument, and serine proteases, kininogen and lectins in the bristles. Besides these molecules, cysteine proteinases, phospholipase A2, cystatins, Kazal-type inhibitors and other protease inhibitors are also found. Serine proteases are the most relevant protein family when considering their potential of interfering with blood coagulation. Moreover, serine proteases are an expressive group, representing 16.7 % and 25 % of the clusters derived from tegument and bristle transcriptome, respectively (Veiga et al., 2005). This protein group presents coagulation factors-like activities, so it is expected that these enzymes participate in the generation of thrombin, by activation of factor X and prothrombin (Berger et al., 2010a; Veiga et al., 2003), and in the activation of the fibrinolytic system, contributing directly and indirectly to fibrinogen degradation (Pinto et al., 2006) and resulting in the hemorrhagic disorder. In fact, proteases with fibrinogenolytic, prothrombin and factor X activating activities have been purified and characterized in this venom (Alvarez-Flores et al., 2006; Pinto et al., 2004; Reis et al., 2006). The phospholipase A2 enzyme also has a function in envenomation. This enzyme was isolated and characterized as the major component responsible to the *in vitro* and *in vivo* hemolytic activity of *L. obliqua* venom (Seibert et al., 2004; Seibert et al., 2006). Additionally, the phospholipase A2 seems to be involved in platelet aggregation inducing activity present in the venom (Berger et al., 2010b). Lectins, particularly c-type lectins, are a relatively well-studied group of proteins in snake venoms that may exert an additional function in hemostasis modulation by interacting with coagulations factors and/or platelet receptors. Three lectin clusters were found in the bristle cDNA library with homology to many snake venom lectins being then another important candidate contributing to the hemorrhagic disorder (Veiga et al., 2005).

Although AKI is the leading cause of death in *L. obliqua* envenomation, the mechanisms involved in kidney disorders are poorly understood. In contrast to hemostatic disturbances, to date, there is no experimental studies describing the renal effects of *L. obliqua* venom. Current knowledge is based only on a few case reports in which hematuria, high levels of serum creatinine and acute tubular necrosis are described as the main features of *L. obliqua* induced AKI. Due to this lack of knowledge, nowadays we are focused on the investigation of the effects of *L. obliqua* venom on renal function in rats. Preliminary results, indicate that subcutaneous injection of *L. obliqua* bristle extract caused severe hematuria with the presence of intact erythrocytes and leukocytes in urinary sediment (Berger et al.,

unpublished data). Envenomed animals also show proteinuria and significant changes in glomerular filtration rate and tubular electrolytic transport (Berger et al., unpublished data). Currently, the contribution of intravascular coagulation, deposits of hemoglobin in renal tubules and hemodynamic changes are under investigation.

## **5. Diagnosis and management of acute kidney injury in snake and arthropod envenomation**

The early intravenous administration of animal-derived antivenoms is the only specific treatment against snake and arthropod envenomations. Antivenoms are concentrated of immunoglobulins (usually pepsin-refined F(ab')<sub>2</sub> fragment of whole IgG) purified from the plasma of a horse or sheep that has been immunized with the venoms of one or more species of venomous animal (WHO, 2010a). The preparation of antivenoms is expensive and technically demanding. Around the world different manufacturers, which include public and private laboratories of diverse sizes and strengths, are able to produce the antivenoms (Gutiérrez et al., 2010; Williams et al., 2010). Some of them are small facilities, mostly located in public institutions, which manufacture for the needs of specific countries. Others are larger laboratories that manufacture and distribute antivenoms throughout various countries or regions. Although some countries or regions manufacture enough antivenom for their national and regional needs, as in Europe, USA, Brazil, Central America, Mexico, Australia, Thailand and Japan, in other parts of the world, specially in some regions of Africa, there are very few antivenom producers (Gutiérrez et al., 2010). In Brazil, three main Institutions are responsible for production of antivenoms: Instituto Butantan, Fundação Ezequiel Dias and Hospital Vital Brasil. The manufacture is government-subsidized and the antivenom is usually provided free to the patients. However, failures in the distribution of antivenoms to places where they are needed still contribute to the maintenance of high mortality rates (Table 1). In some instances, antivenoms are held in the main cities, where envenomations are rare, instead of being distributed to peripheral health clinics in rural areas where the accidents are frequent. This reflects defective distribution planning which is associated with a lack of coordination between those who understand the epidemiological pattern of the disease and those responsible for the antivenom distribution. Also, inadequate storage and transportation of antivenoms may result in physical destruction of vials and ampoules (e.g. by freezing of liquid antivenom) (WHO, 2010a). Besides the inadequate supply, distribution and accessibility to safe and effective antivenoms, another major issue is the lack of trained health workers on how to use these products and how to conduct appropriate clinical management of medical emergencies. In fact, it is estimated that in Brazil in 2009, 37% of accidents with scorpions and 9% of accidents with spiders received inadequate treatment with antivenom, mainly because the health authorities are uninformed of the treatment protocols (Boletim eletrônico epidemiológico, 2010).

The treatment with antivenom is indicated in moderate and severe cases when systemic signs of envenomation are observed. In general, patients with hemostatic abnormalities, neurotoxic signs, cardiovascular abnormalities, AKI, hemoglobinuria and myoglobinuria should receive antivenom therapy (WHO, 2010a). In these cases the time elapsed between the occurrence of the accident and administration of a correct dose of antivenom is decisive for a successful therapy. It was demonstrated that the time interval between the accident and

administration of the antivenom of more than 2 hours was associated with the development of AKI, as well as with the risk of death or permanent injuries after *Bothrops* and *Crotalus* envenomations (Otero et al., 2002; Pinho et al., 2005). Although the correct use of antivenom is an effective form of treatment, the sorotherapy is also associated with the occurrence of severe adverse effects. The most serious adverse effect is anaphylactic reactions. Clinical features such as urticaria, itching, fever, tachycardia, vomiting, abdominal colic, headache, bronchospasm, hypotension and angioedema have been described after antivenom treatment (Fan et al., 1999; Ministério da Saúde, 2001). The incidence of adverse effects depends on the quality, dose and speed of intravenous injection or infusion. With antivenoms of good quality profile, there is a low incidence (less than 10%) of generally mild adverse reactions, mostly urticaria and itching. However, for products containing contaminant proteins, the incidence of such reactions may be as high as 85 %, including potentially life-threatening systemic disturbances such as hypotension and bronchospasm (WHO, 2007). Thus the adverse effects are directly associated with lack of good manufacturing practices adopted by laboratories that manufacture antivenoms. Recently, in an attempt to improve the quality of antivenom production the WHO established the guidelines for production, control and regulation of snake antivenom immunoglobulins. These guidelines provide detailed information on the recommended steps for antivenom manufacture and control (WHO, 2010b).

A number of additional interventions besides antivenom may be necessary to restore renal function in patients who developed AKI. Special attention should be given to hypotension, shock, electrolyte balance and maintenance of an adequate state of hydration. An urinary flow of 30 to 40 mL/h/kg is recommended for adults and 1 to 3 mL/h/kg for children to prevent AKI after snake envenomations (Ministério da Saúde, 2001; Pinho et al., 2008). Patients presenting oliguria or anuria, despite of fluid administration, are usually treated with intravenous furosemide or mannitol (WHO, 2010a). In these cases, a higher urinary flow may decrease the exposure of tubular cells to venom components and myoglobin or hemoglobin, which result in injury attenuation and prevention of tubular lumen obstruction (Zager, 1996). Cases that are unresponsive to fluid intake and diuretics are referred to renal units for dialysis (Pinho et al., 2008). Early alkalinization of urine by sodium bicarbonate in patients with myoglobinuria or hemoglobinuria is also recommended, because in the presence of acidic urine, myoglobin and uric acid precipitate and form obstructive cast (Khan, 2009).

## 6. Conclusion

Envenomation by different venomous snakes and arthropods is a neglected disease that afflicts the most impoverished inhabitants of rural areas in tropical developing countries. In this chapter, we reviewed some important aspects related to epidemiology, prevalence, clinical manifestations, pathophysiology and treatment of venom-induced AKI, which is one of the most significant and lethal effect of animal venoms. Despite of actual knowledge discussed here, several aspects involving the renal manifestations remain still unclear. Thus, further research are needed to cover the following key points: (i) biochemical composition of different animal venoms and their individual contribution to renal injury; (ii) renal pathological mechanisms induced by some specific venoms that are still unexplored; (iii)

discovery of new and more specific therapeutic alternatives to treat envenomation cases and (iv) improvement in the production, distribution and availability of the antivenoms currently used.

## 7. Acknowledgments

The authors are grateful to Coordenação de Aperfeiçoamento de Pessoal de Nível Superior, Ministério da Educação, Brasil (CAPES-MEC) and Conselho Nacional de Desenvolvimento Científico e Tecnológico, Ministério da Ciência e Tecnologia, Brasil (CNPq-MCT) for funding and fellowships.

## 8. References

- Abella, H.B.; Marques, M.G.B.; Silva, K.R.L.M.; Rossoni, M.G. & Torres, J.B. (2006). Acidentes com lagartas do gênero *Lonomia* registrados no Centro de Informação Toxicológica do Rio Grande do Sul no período de 1997 a 2005, In: Nicolella, A. (Ed.), *Toxicovigilância - toxicologia clínica: dados e indicadores selecionados*. Secretaria da Saúde. Fundação Estadual de Produção e Pesquisa em Saúde. Centro de Informação Toxicológica, Porto Alegre, pp. 29-34.
- Abdulkader, R.C.; Barbaro, K.C.; Barros, E.J. & Burdmann, E.A. (2008). Nephrotoxicity of insect and spider venoms in Latin America. *Seminars in Nephrology*. Vol.28, No.4, pp. 373-82.
- Alegre, V.S.; Barone, J.M.; Yamasaki, S.C.; Zambotti-Villela, L. & Silveira, P.F. (2010). Lipoic acid effects on renal function, aminopeptidase activities and oxidative stress in *Crotalus durissus terrificus* envenomation in mice. *Toxicon*. Vol.56, No.3, pp.402-10.
- Alvarez-Flores, M.P.; Fritzen, M.; Reis, C.V. & Chudzinski-Tavassi, A.M. (2006). Losac, a factor X activator from *Lonomia obliqua* bristle extract: its role in the pathophysiological mechanisms and cell survival. *Biochemical and Biophysical Research Communications*. Vol. 343, No. 4, pp. 1216-23.
- Alves da Silva, J.A.; Oliveira, K.C. & Camillo, M.A. (2011). Gyroxin increases blood-brain barrier permeability to Evans blue dye in mice. *Toxicon*. Vol.57, No.1, pp.162-7.
- Amaral, C.F.; de Rezende, N.A.; da Silva, O.A.; Ribeiro, M.M.; Magalhães, R.A.; dos Reis, R.J.; Carneiro, J.G. & Castro, J.R. (1986). Acute kidney failure secondary to ophidian bothropic and crotalid accidents. Analysis of 63 cases. *Revista do Instituto de Medicina Tropical de Sao Paulo*. Vol.28, No.4, pp. 220-7.
- Arocha-Piñango, C.L.; Marval, E. & Guerrero, B. (2000). *Lonomia* genus caterpillar toxins: biochemical aspects. *Biochimie*. Vol.82, No.9-10, pp.937-42.
- Azevedo-Marques, M.M.; Cupo, P.; Coimbra, T.M.; Hering, S.E.; Rossi, M.A. & Laure, C.J. (1985). Myonecrosis, myoglobinuria and acute renal failure induced by South American rattlesnake (*Crotalus durissus terrificus*) envenomation in Brazil. *Toxicon*. Vol.23, No.4, pp. 631-6.
- Azevedo-Marques, M.M.; Hering, S.E. & Cupo, P. (1987). Evidence that *Crotalus durissus terrificus* (South American rattlesnake) envenomation in humans causes myolysis rather than hemolysis. *Toxicon*. Vol.25, No.11, pp. 1163-8.
- Barbosa, P.S.; Martins, A.M.; Havt, A.; Toyama, D.O.; Evangelista, J.S.; Ferreira, D.P.; Joazeiro, P.P.; Beriam, L.O.; Toyama, M.H.; Fonteles, M.C. & Monteiro, H.S. (2005).

- Renal and antibacterial effects induced by myotoxin I and II isolated from *Bothrops jararacussu* venom. *Toxicon*. Vol.15, No.4, pp 376-86.
- Berger, M.; Pinto, A.F. & Guimarães, J.A. (2008). Purification and functional characterization of bothrojaractivase, a prothrombin-activating metalloproteinase isolated from *Bothrops jararaca* snake venom. *Toxicon*. Vol.51, No.4, pp. 488-501.
- Berger, M.; Reck-Jr, J.; Terra, R.M.; Pinto, A.F.; Termignoni, C. & Guimarães, J.A. (2010a) *Lonomia obliqua* caterpillar envenomation causes platelet hypoaggregation and blood incoagulability in rats. *Toxicon*. Vol.55, No.1, pp. 33-44.
- Berger, M.; Reck-Jr, J.; Terra, R.M.; Beys da Silva, W.O; Santi, L.; Pinto, A.F.; Vainstein, M.H.; Termignoni, C. & Guimarães, J.A. (2010b). *Lonomia obliqua* venomous secretion induces human platelet adhesion and aggregation. *Journal of Thrombosis and Thrombolysis*. Vol.30, No.3, pp. 300-10.
- Boer-Lima, P.A.; Gontijo, J.A. & da Cruz-Höfling, M.A. (1999). Histologic and functional renal alterations caused by *Bothrops moojeni* snake venom in rats. *American Journal of Tropical Medicine and Hygiene*. Vol.61, No.5, pp. 698-706.
- Boer-Lima, P.A.; Gontijo, J.A. & Cruz-Höfling, M.A. (2002). *Bothrops moojeni* snake venom-induced renal glomeruli changes in rat. *American Journal of Tropical Medicine and Hygiene*. Vol.67, No.2, pp. 217-22.
- Boldrini-França, J.; Corrêa-Netto, C.; Silva, M.M.; Rodrigues, R.S.; De La Torre, P.; Pérez, A.; Soares, A.M.; Zingali, R.B.; Nogueira, R.A.; Rodrigues, V.M.; Sanz, L. & Calvete, J.J. (2010). Snake venomomics and antivenomics of *Crotalus durissus* subspecies from Brazil: assessment of geographic variation and its implication on snakebite management. *Journal of Proteomics*. Vol.73, No.9, pp. 1758-76.
- Boletim eletrônico epidemiológico, 2010. Secretaria de Vigilância em Saúde/Ministério da Saúde (SVS/MS), Brasil. Available from:  
[www.portal.saude.gov.br/portal/arquivos/pdf/ano10\\_n02\\_sit\\_epidemiol\\_zoonoses\\_br.pdf](http://www.portal.saude.gov.br/portal/arquivos/pdf/ano10_n02_sit_epidemiol_zoonoses_br.pdf)
- Braga, M.D.; Martins, A.M.; Amora, D.N.; de Menezes, D.B.; Toyama, M.H.; Toyama, D.O.; Marangoni, S.; Barbosa, P.S.; de Sousa Alves, R.; Fonteles, M.C. & Monteiro, H.S. (2006) Purification and biological effects of C-type lectin isolated from *Bothrops insularis* venom. *Toxicon*. Vol.47, No.8, pp. 859-67.
- Braga, M.D.; Martins, A.M.; de Menezes, D.B.; Barbosa, P.S.; Evangelista, J.S.; Toyama, M.H.; Toyama, D.O.; Fonteles, M.C. & Monteiro, H.S. (2007). Purification and biological activity of the thrombin-like substance isolated from *Bothrops insularis* venom. *Toxicon*. Vol.49, No.3, pp. 329-38.
- Braga, M.D.; Martins, A.M.; Amora, D.N.; de Menezes, D.B.; Toyama, M.H.; Toyama, D.O.; Marangoni, S.; Alves, C.D.; Barbosa, P.S.; de Sousa Alves, R.; Fonteles, M.C. & Monteiro HS. (2008). Purification and biological effects of L-amino acid oxidase isolated from *Bothrops insularis* venom. *Toxicon*. Vol.51, No.2, pp. 199-207.
- Burdmann, E.A.; Woronik, V.; Prado, E.B.; Abdulkader, R.C.; Saldanha, L.B.; Barreto, O.C. & Marcondes, M. (1993). Snakebite-induced acute renal failure: an experimental model. *American Journal of Tropical Medicine and Hygiene*. Vol.48, No.1, pp. 82-8.
- Burdmann, E.A.; Antunes, I.; Saldanha, L.B. & Abdulkader, R.C. (1996). Severe acute renal failure induced by the venom of *Lonomia* caterpillars. *Clinical Nephrology*. Vol.46, No.5, pp. 337-9.

- Cerne, K.; Kristan, K.C.; Budihna, M.V. & Stanovnik, L. (2010). Mechanisms of changes in coronary arterial tone induced by bee venom toxins. *Toxicon*. Vol.56, No.3, pp. 305-12.
- Chaim, O.M.; Sade, Y.B.; da Silveira, R.B.; Toma, L.; Kalapothakis, E.; Chávez-Olórtegui, C.; Mangili, O.C.; Gremski, W.; von Dietrich, C.P.; Nader, H.B. & Veiga S.S. (2006). Brown spider dermonecrotic toxin directly induces nephrotoxicity. *Toxicology and Applied Pharmacology*. Vol.211, No.1, pp. 64-77.
- Chao, Y.W.; Yang, A.H.; Ng, Y.Y. & Yang, W.C. (2004). Acute interstitial nephritis and pigmented tubulopathy in a patient after wasp stings. *American Journal of Kidney Diseases*. Vol.43, No.2, pp. 15-19.
- Chippaux, J.P. (1998). Snake-bites: appraisal of the global situation. *Bulletin of the World Health Organization*. Vol.76, No.5, pp. 515-24.
- Chippaux, J.P. & Goyffon, M. (2008). Epidemiology of scorpionism: a global appraisal. *Acta Tropica*. Vol.107, No.2, pp. 71-9.
- Chippaux, J.P. (2011). Estimate of the burden of snakebites in sub-Saharan Africa: a meta-analytic approach. *Toxicon*. Vol.57, No.4, pp. 586-99.
- Churchill, P.C.; Rossi, N.F.; Churchill, M.C. & Ellis, V.R. (1990). Effect of melittin or renin and prostaglandin E2 release from rat renal cortical slices. *Journal of Physiology*. Vol.428, pp. 233-241.
- Cidade, D.A.; Simão, T.A.; Dávila, A.M.; Wagner, G.; Junqueira-de-Azevedo, I.L.; Ho, P.L.; Bon, C.; Zingali, R.B. & Albano, R.M. (2006). *Bothrops jararaca* venom gland transcriptome: analysis of the gene expression pattern. *Toxicon*. Vol.48, No.4, pp. 437-61.
- Collares-Buzato, C.B.; de Paula Le Sueur, L. & da Cruz-Höfling, M.A. (2002). Impairment of the cell-to-matrix adhesion and cytotoxicity induced by *Bothrops moojeni* snake venom in cultured renal tubular epithelia. *Toxicology and Applied Pharmacology*. Vol.181, No.2, pp. 124-32.
- Cologna, C.T.; Marcussi, S.; Giglio, J.R.; Soares, A.M. & Arantes, E.C. (2009). *Tityus serrulatus* scorpion venom and toxins: an overview. *Protein and Peptide Letters*. Vol.16, No.8, pp. 920-32.
- Daher, E.F.; Silva-Junior, G.B.; Bezerra, G.P.; Pontes, L.B.; Martins, A.M.C. & Guimarães, J.A. (2003). Acute renal failure after massive honeybee stings. *Revista do Instituto de Medicina Tropical de Sao Paulo*. Vol.45, No.1, pp. 45-50.
- da Silva, P.H.; da Silveira, R.B.; Appel, M.H.; Mangili, O.C.; Gremski, W. & Veiga, S.S. (2004). Brown spiders and loxoscelism. *Toxicon*. Vol.44, No.7, pp. 693-709.
- de Castro, I.; Burdmann, E.A.; Seguro, A.C. & Yu, L. (2004). *Bothrops* venom induces direct renal tubular injury: role for lipid peroxidation and prevention by antivenom. *Toxicon*. Vol.43, No.7, pp. 833-9.
- de Giuseppe, P.O.; Ullah, A.; Silva, D.T.; Gremski, L.H.; Wille, A.C.; Chaves-Moreira, D.; Ribeiro, A.S.; Chaim, O.M.; Murakami, M.T.; Veiga, S.S. & Arni, R.K. (2011). Structure of a novel class II phospholipase D: catalytic cleft is modified by a disulphide bridge. *Biochemical and Biophysical Research Communications*. Vol. 409, No.4, pp. 622-7.
- Deitch, E.A. (1992). Multiple organ failure. Pathophysiology and potential future therapy. *Annals of Surgery*. Vol. 216, No. 2, pp. 117-34.



- Dempsey, C.E. (1990). The actions of melittin on membranes. *Biochimica et Biophysica Acta*. Vol.1031, No.2, pp. 143-61.
- dos Reis, M.A.; Costa, R.S.; Coimbra, T.M.; Dantas, M. & Gomes, U.A. (1997). Renal changes induced by envenomation with Africanized bee venom in female Wistar rats. *Kidney and Blood Pressure Research*. Vol. 20, No. 4, pp. 271-7.
- dos Reis MA.; Costa, R.S.; Coimbra, T.M.; Teixeira, V.P. (1998). Acute renal failure in experimental envenomation with Africanized bee venom. *Renal Failure*. Vol.20, No.1, pp. 39-51.
- Duarte, A.C.; Caovilla, J.J.; Lorini, J.D.; Mantovani, G.; Sumida, J.; Manfre, P.C.; Silveira, R.C. & de Moura, S.P. (1990). Insuficiência renal aguda por acidentes com lagartas. *Jornal Brasileiro de Nefrologia*. Vol.12, pp. 184-7.
- Ejaz, A.A.; Mu, W.; Kang, D.H.; Roncal, C.; Sautin, Y.Y.; Henderson, G.; Tabah-Fisch, I.; Keller, B.; Beaver, T.M.; Nakagawa, T. & Johnson, R.J. (2007). Could uric acid have a role in acute renal failure. *Clinical Journal of the American Society of Nephrology*. Vol.2, No.1, pp. 16-21.
- Evangelista, I.L.; Martins, A.M.; Nascimento, N.R.; Havt, A.; Evangelista, J.S.; de Norões, T.B.; Toyama, M.H.; Diz-Filho, E.B.; Toyama, O.; Fonteles, M.C. & Monteiro, H.S. (2010) Renal and cardiovascular effects of *Bothrops marajoensis* venom and phospholipase A2. *Toxicon*. Vol. 55, No. 6, pp. 1061-70.
- Fan, H.W.; Marcopito, L.F.; Cardoso, J.L.; França, F.O.; Malaque, C.M.; Ferrari, R.A.; Theakston, R.D. & Warrell, D.A. (1999). Sequential randomised and double blind trial of promethazine prophylaxis against early anaphylactic reactions to antivenom for *Bothrops* snakebites. *British Medical Journal (BMJ)*. Vol. 318, pp. 1451-1453.
- Fan, H.W.; Cardoso, J.L.; Olmos, R.D.; Almeida, F.J.; Viana, R.P. & Martinez, A.P. (1998). Hemorrhagic syndrome and acute renal failure in a pregnant woman after contact with *Lonomia* caterpillars: a case report. *Revista do Instituto de Medicina Tropical de São Paulo*. Vol. 40, No. 2, pp. 119-20.
- Fletcher, J.E. & Jiang, M.S. (1993). Possible mechanisms of action of cobra snake venom cardiotoxins and bee venom melittin. *Toxicon*. Vol. 31, No. 6, pp. 669-95.
- França, F.O.; Benvenuti, L.A.; Fan, H.W.; dos Santos, D.R.; Hain, S.H.; Picchi-Martins, F.R.; Cardoso, J.L.; Kamiguti, A.S.; Theakston, R.D. & Warrell, D.A. (1994). Severe and fatal mass attacks by 'killer' bees (Africanized honey bees-*Apis mellifera scutellata*) in Brazil: clinicopathological studies with measurement of serum venom concentrations. *The Quarterly Journal of Medicine (Q J Med)*. Vol. 87, No. 5, pp. 269-82.
- França, F.O.; Barbaro, K.C. & Abdulkader, R.C. (2002). Rhabdomyolysis in presumed viscerocutaneous loxoscelism: report of two cases. *Transactions of the Royal Society of Tropical Medicine and Hygiene*. Vol. 96, No. 3, pp. 287-90.
- Francischetti, I.M.; Saliou, B.; Leduc, M.; Carlini, C.R.; Hatmi, M.; Randon, J.; Faili, A. & Bon, C. (1997). Convulxin, a potent platelet-aggregating protein from *Crotalus durissus terrificus* venom, specifically binds to platelets. *Toxicon*. Vol. 35, No. 8, pp. 1217-28.
- Frezzatti, R. & Silveira, P.F. (2011). Allopurinol Reduces the Lethality Associated with Acute Renal Failure Induced by *Crotalus durissus terrificus* Snake Venom: Comparison with Probenecid. *PLoS Neglected Tropical Diseases*. Vol. 5, No. 9, pp. e1312.

- Gabriel, D.P.; Rodrigues, A.G.; Barsante, R.C.; dos Santos-Silva, V.; Caramori, J.T.; Martim, L.C.; Barretti, P. & Balbi, A.L. (2004). Severe acute renal failure after massive attack of Africanized bees. *Nephrology, Dialysis, Transplantation*. Vol. 19, No. 10, pp. 2680.
- Gamborgi, G.P.; Metcalf, E.B. & Barros, E.J. (2006). Acute renal failure provoked by toxin from caterpillars of the species *Lonomia obliqua*. *Toxicon*. Vol. 47, No. 1, pp. 68-74.
- Gay, C.C.; Marunak, S.L.; Teibler, P.; Ruiz, R.; Acosta de Pérez, O.C. & Leiva, L.C. (2009). Systemic alterations induced by a *Bothrops alternatus* hemorrhagic metalloproteinase (baltergin) in mice. *Toxicon*. Vol. 53, No. 1, pp. 53-9.
- Gremski, L.H.; da Silveira, R.B.; Chaim, O.M.; Probst, C.M.; Ferrer, V.P.; Nowatzki, J.; Weinschutz, H.C.; Madeira, H.M.; Gremski, W.; Nader, H.B.; Senff-Ribeiro, A. & Veiga, S.S. (2010). A novel expression profile of the *Loxosceles intermedia* spider venomous gland revealed by transcriptome analysis. *Molecular Biosystems*. Vol. 6, No. 12, pp. 2403-16.
- Grisotto, L.S.; Mendes, G.E.; Castro, I.; Baptista, M.A.; Alves, V.A.; Yu, L. & Burdmann, E.A. (2006). Mechanisms of bee venom-induced acute renal failure. *Toxicon*. Vol. 48, No. 1, pp. 44-54.
- Gutiérrez, J.M.; Theakston, R.D. & Warrell, D.A. (2006). Confronting the neglected problem of snake bite envenoming: the need for a global partnership. *PLoS Medicine*. Vol. 3, No. 6, pp. e150.
- Gutiérrez, J.M.; Williams, D.; Fan, H.W. & Warrell, D.A. (2010). Snakebite envenoming from a global perspective: Towards an integrated approach. *Toxicon*. Vol. 56, No 7, pp. 1223-35.
- Habermann, E. (1972). Bee and wasp venoms. *Science*. Vol. 177, No. 46, pp. 314-22.
- Hogan, C.J.; Barbaro, K.C. & Winkel, K. (2004). Loxoscelism: old obstacles, new directions. *Annals of Emergency Medicine*. Vol. 44, pp. 608-622.
- Isbister, G.K. & Fan, H.W. (2011). Spider bite. *Lancet*. (in press)
- Jorge, M.T. & Ribeiro, L.A. (1992). The epidemiology and clinical picture of an accidental bite by the South American rattlesnake (*Crotalus durissus*). *Revista do Instituto de Medicina Tropical de São Paulo*. Vol. 34, No. 4, pp. 347-54.
- Kamiguti, A.S. (2005). Platelets as targets of snake venom metalloproteinases. *Toxicon*. Vol. 45, No. 8, pp. 1041-9.
- Kasturiratne, A.; Wickremasinghe, A.R.; de Silva, N.; Gunawardena, N.K.; Pathmeswaran, A.; Premaratna, R.; Savioli, L.; Lalloo, D.G. & de Silva, H.J. (2008). The global burden of snakebite: a literature analysis and modelling based on regional estimates of envenoming and deaths. *PLoS Medicine*. Vol. 5, No. 11, pp. e218.
- Khan, F.Y. (2009). Rhabdomyolysis: a review of the literature. *Netherland Journal of Medicine*. Vol. 67, No. 9, pp. 272-83.
- Kusma, J.; Chaim, O.M.; Wille, A.C.; Ferrer, V.P.; Sade, Y.B.; Donatti, L.; Gremski, W.; Mangili, O.C. & Veiga, S.S. (2008). Nephrotoxicity caused by brown spider venom phospholipase-D (dermonecrotic toxin) depends on catalytic activity. *Biochimie*. Vol. 90, No. 11-12, pp. 1722-36.
- Lee, S. & Lynch, K.R. (2005). Brown recluse spider (*Loxosceles reclusa*) venom phospholipase D (PLD) generates lysophosphatidic acid (LPA). *Biochemical Journal*. Vol. 391, No. 2, pp. 317-23.

- Lee, S.Y.; Park, H.S.; Lee, S.J. & Choi, M. (2001). Melittin exerts multiple effects on the release of free fatty acids from L1210 cells: lack of selective activation of phospholipase A2 by melittin. *Archives of Biochemistry and Biophysics*. Vol. 389, pp. 57-67.
- Linardi, A.; Rocha e Silva, T.A.; Miyabara, E.H.; Franco-Penteado, C.F.; Cardoso, K.C.; Boer, P.A.; Moriscot, A.S.; Gontijo, J.A.; Joazeiro, P.P.; Collares-Buzato, C.B. & Hyslop, S. (2011). Histological and functional renal alterations caused by *Bothrops alternatus* snake venom: expression and activity of Na<sup>+</sup>/K<sup>+</sup>-ATPase. *Biochimica et Biophysica Acta*. Vol. 1810, No. 9, pp. 895-906.
- Lucato-Junior, R.V.; Abdulkader, R.C.; Barbaro, K.C.; Mendes, G.E.; Castro, I.; Baptista, M.A.; Cury, P.M.; Malheiros, D.M.; Schor, N.; Yu, L. & Burdmann, E.A. (2011). *Loxosceles gaucho* venom-induced acute kidney injury - *in vivo* and *in vitro* studies. *PLoS Neglected Tropical Diseases*. Vol. 5, No. 5, pp. e1182.
- Luciano, M.N.; da Silva, P.H.; Chaim, O.M.; dos Santos, V.L.; Franco, C.R.; Soares, M.F.; Zanata, S.M.; Mangili, O.C.; Gremski, W. & Veiga, S.S. (2004). Experimental evidence for a direct cytotoxicity of *Loxosceles intermedia* (brown spider) venom in renal tissue. *Journal of Histochemistry and Cytochemistry*. Vol. 52, No. 4, pp. 455-67.
- Malague, C.M.; Andrade, L.; Madalosso, G.; Tomy, S.; Tavares, F.L. & Seguro, A.C. (2006). Short report: A case of hemolysis resulting from contact with a *Lonomia* caterpillar in southern Brazil. *American Journal of Tropical Medicine and Hygiene*. Vol. 74, No. 5, pp. 807-9.
- Martins, A.M.; Toyama, M.H.; Havt, A.; Novello, J.C.; Marangoni, S.; Fonteles, M.C. & Monteiro, H.S. (2002). Determination of *Crotalus durissus cascavella* venom components that induce renal toxicity in isolated rat kidneys. *Toxicon*. Vol. 40, No. 8, pp. 1165-171.
- Martins, A.M.; Lima, A.A.; Toyama, M.H.; Marangoni, S.; Fonteles, M.C. & Monteiro, H.S. (2003). Renal effects of supernatant from macrophages activated by *Crotalus durissus cascavella* venom: the role of phospholipase A2 and cyclooxygenase. *Pharmacology & Toxicology*. Vol. 92, No. 1, pp. 14-20.
- Martins, A.M.; Nobre, A.C.; Almeida, A.C.; Bezerra, G.; Lima, A.A.; Fonteles, M.C. & Monteiro, H.S. (2004). Thalidomide and pentoxifylline block the renal effects of supernatants of macrophages activated with *Crotalus durissus cascavella* venom. *Brazilian Journal of Medical and Biological Research*. Vol. 37, No. 10, pp. 1525-30.
- Mello, S.M.; Linardi, A.; Rennó, A.L.; Tarsitano, C.A.; Pereira, E.M. & Hyslop, S. (2010). Renal kinetics of *Bothrops alternatus* (Urutu) snake venom in rats. *Toxicon*. Vol. 55, No. 2-3, pp. 470-80.
- Ministério da Saúde (2001). Manual de Diagnóstico e Tratamento por Animais Peçonhentos. Fundação Nacional da Saúde, Brasil. Available from: [http://portal.saude.gov.br/portal/saude/visualizar\\_texto.cfm?idtxt=21182](http://portal.saude.gov.br/portal/saude/visualizar_texto.cfm?idtxt=21182).
- Monteiro, H.S. & Fonteles, M.C. (1999). The effect of *Bothrops jararaca* venom on rat kidney after short-term exposure: preliminary results. *Pharmacology & Toxicology*. Vol. 85, No. 4, pp. 198-200.
- Monteiro, H.S.; da Silva, I.M.; Martins, A.M. & Fonteles, M.C. (2001). Actions of *Crotalus durissus terrificus* venom and crotoxin on the isolated rat kidney. *Brazilian Journal of Medical and Biological Research*. Vol. 34, No. 10, pp. 1347-52.


- Murakami, M.T.; Fernandes-Pedrosa, M.F.; Tambourgi, D.V. & Arni, R.K. (2005). Structural basis for metal ion coordination and the catalytic mechanism of sphingomyelinases D. *Journal of Biological Chemistry*. Vol. 280, No. 14, pp. 13658-64.
- Nascimento, J.M.; Franchi, G.C.; Nowill, A.E.; Collares-Buzato, C.B. & Hyslop, S. (2007). Cytoskeletal rearrangement and cell death induced by *Bothrops alternatus* snake venom in cultured Madin-Darby canine kidney cells. *Biochemistry and Cell Biology*. Vol. 85, No. 5, pp. 591-605.
- Ownby, C.L.; Powell, J.R.; Jiang, M.S. & Fletcher, J.E. (1997). Melittin and phospholipase A2 from bee (*Apis mellifera*) venom cause necrosis of murine skeletal muscle *in vivo*. *Toxicon*. Vol. 35, pp. 67-80.
- Otero, R.; Gutiérrez, J.; Beatriz-Mesa, M.; Duque, E.; Rodríguez, O.; Luis-Arango, J.; Gómez, F.; Toro, A.; Cano, F.; María-Rodríguez, L.; Caro, E.; Martínez, J.; Cornejo, W.; Mariano-Gómez, L.; Luis-Urbe, F.; Cárdenas, S.; Núñez, V. & Díaz, A. (2002). Complications of *Bothrops*, *Porthidium*, and *Bothriechis* snakebites in Colombia. A clinical and epidemiological study of 39 cases attended in a university hospital. *Toxicon*. Vol. 40, No. 8, pp. 1107-114.
- Pantera, B.; Hoffman, D.R.; Carresi, L.; Cappugi, G.; Turillazzi, S.; Manao, G.; Severino, M.; Spadolini, I.; Orsomando, G.; Moneti, G. & Pazzagli, L. (2003). Characterization of the major allergens purified from the venom of the paper wasp *Polistes gallicus*. *Biochimica et Biophysica Acta*. Vol. 1623, No. 2-3, pp. 72-81.
- Petricevich, V.L.; Teixeira, C.F.P.; Tambourgi, D.V. & Gutiérrez, J.M. (2000). Increments in serum cytokine and nitric oxide levels in mice injected with *Bothrops asper* and *Bothrops jararaca* snake venoms. *Toxicon*. Vol. 38, No. 9, pp. 1253-66.
- Pinho, F.M.; Zanetta, D.M. & Burdmann, E.A. (2005). Acute renal failure after *Crotalus durissus* snakebite: a prospective survey on 100 patients. *Kidney International*. Vol. 67, No. 2, pp. 659-67.
- Pinho, F.M.; Yu, L. & Burdmann EA. (2008). Snakebite-induced acute kidney injury in Latin America. *Seminars in Nephrology*. Vol. 28, No. 4, pp. 354-62.
- Pinto, A.F.; Dobrovolski, R.; Veiga, A.B. & Guimarães, J.A. (2004). Lonofibrase, a novel alpha-fibrinogenase from *Lonomia obliqua* caterpillars. *Thrombosis Research*. Vol.113, No. 2, pp. 147-54.
- Pinto, A.F.; Silva, K.R. & Guimarães, J.A. (2006). Proteases from *Lonomia obliqua* venomous secretions: comparison of procoagulant, fibrin(ogen)olytic and amidolytic activities. *Toxicon*. Vol. 47, No. 1, pp.113-21.
- Pinto, A.F.; Berger, M.; Reck-Jr, J.; Terra, R.M. & Guimarães, J.A. (2010). *Lonomia obliqua* venom: *In vivo* effects and molecular aspects associated with the hemorrhagic syndrome. *Toxicon*. Vol. 56, No. 7, pp. 1103-12.
- Reis, C.V.; Andrade, S.A.; Ramos, O.H.; Ramos, C.R.; Ho, P.L.; Batista, I.F. & Chudzinski-Tavassi, A.M. (2006). Lopap, a prothrombin activator from *Lonomia obliqua* belonging to the lipocalin family: recombinant production, biochemical characterization and structure-function insights. *Biochemical Journal*. Vol. 398, No. 2, pp. 295-302.
- Ricci-Silva, M.E.; Valente, R.H.; León, I.R.; Tambourgi, D.V.; Ramos, O.H.; Perales, J. & Chudzinski-Tavassi, A.M. (2008). Immunochemical and proteomic technologies as tools for unravelling toxins involved in envenoming by accidental contact with *Lonomia obliqua* caterpillars. *Toxicon*. Vol. 51, No. 6, pp. 1017-28.

- Rodrigues-Sgrignolli, L.; Florido-Mendes, G.E.; Carlos, C.P.; Burdmann, E.A. (2011). Acute kidney injury caused by *Bothrops* snake venom. *Nephron Clinical Practice*. Vol. 119, No. 2 pp. c131-7.
- Rucavado, A.; Soto, M.; Escalante, T.; Loría, G.D.; Arni, R. & Gutiérrez, J.M. (2005). Thrombocytopenia and platelet hypoaggregation induced by *Bothrops asper* snake venom. Toxins involved and their contribution to metalloproteinase-induced pulmonary hemorrhage. *Thrombosis and Haemostasis*. Vol. 94, No. 1, pp. 123-31.
- Sampaio, S.C.; Hyslop, S.; Fontes, M.R.; Prado-Franceschi, J.; Zambelli, V.O.; Magro, A.J.; Brigatte, P.; Gutiérrez, V.P. & Cury, Y. (2010). Crotoxin: novel activities for a classic beta-neurotoxin. *Toxicon*. Vol. 55, No. 6, pp. 1045-60.
- Santoro, M.L. & Sano-Martins, I.S. (2004). Platelet dysfunction during *Bothrops jararaca* snake envenomation in rabbits. *Thrombosis and Haemostasis*. Vol. 92, No. 2, pp.369-83.
- Seibert, C.S.; Oliveira, M.R.; Gonçalves, L.R.; Santoro, M.L. & Sano-Martins, I.S. (2004). Intravascular hemolysis induced by *Lonomia obliqua* caterpillar bristle extract: an experimental model of envenomation in rats. *Toxicon*. Vol. 44, No. 7, pp. 793-9.
- Seibert, C.S.; Tanaka-Azevedo, A.M.; Santoro, M.L.; Mackessy, S.P.; Soares-Torquato, R.J.; Lebrun, I.; Tanaka, A.S. & Sano-Martins, I.S. (2006). Purification of a phospholipase A2 from *Lonomia obliqua* caterpillar bristle extract. *Biochemical and Biophysical Research Communications*. Vol. 342, No. 4, pp. 1027-33.
- Sezerino, U.M.; Zannin, M.; Coelho, L.K.; Gonçalves-Júnior, J.; Grando, M.; Mattosinho, S.G.; Cardoso, J.L.; von Eickstedt, V.R.; França, F.O.; Barbaro, K.C. & Fan, H.W. (1998). A clinical and epidemiological study of *Loxosceles* spider envenoming in Santa Catarina, Brazil. *Transactions of the Royal Society of Tropical Medicine and Hygiene*. Vol. 92, No. 5, pp. 546-8.
- Silveira, P.V. & Nishioka, A. (1992). South American rattlesnake bite in a Brazilian teaching hospital. Clinical and epidemiological study of 87 cases, with analysis of factors predictive of renal failure. *Transactions of the Royal Society of Tropical Medicine and Hygiene*. Vol. 86, No. 5, pp. 562-4.
- Sitprijja, V. (2006). Snakebite nephropathy. *Nephrology (Carlton)*. Vol. 11, No. 5, pp. 442-8.
- Soares, A.M.; Mancin, A.C.; Cecchini, A.L.; Arantes, E.C.; França, S.C.; Gutiérrez, J.M. & Giglio, J.R. (2001). Effects of chemical modifications of crotoxin B, the phospholipase A(2) subunit of crotoxin from *Crotalus durissus terrificus* snake venom, on its enzymatic and pharmacological activities. *International Journal of Biochemistry and Cell Biology*. Vol. 33, No. 9, pp. 877-88.
- Swanson, D.L.; Vetter, R.S. (2006). Loxoscelism. *Clinics in Dermatology*. Vol. 24, pp. 213-221.
- Terra, R.M.; Guimarães, J.A. & Verli, H. (2007). Structural and functional behavior of biologically active monomeric melittin. *Journal of Molecular Graphics and Modelling*. Vol. 25, No. 6, pp. 767-72.
- Trevisan-Silva, D.; Gremski, L.H.; Chaim, O.M.; da Silveira, R.B.; Meissner, G.O.; Mangili, O.C.; Barbaro, K.C.; Gremski, W.; Veiga, S.S. & Senff-Ribeiro, A. (2010). Astacin-like metalloproteases are a gene family of toxins present in the venom of different species of the brown spider (genus *Loxosceles*). *Biochimie*. Vol. 92, No. 1, pp. 21-32.
- Veiga, A.B.; Blochtein, B. & Guimarães, J.A. (2001a). Structures involved in production, secretion and injection of the venom produced by the caterpillar *Lonomia obliqua* (Lepidoptera, Saturniidae). *Toxicon*. Vol. 39, No., 9, pp. 1343-51.

- Veiga, A.B.; Pinto, A.F. & Guimarães, J.A. (2003). Fibrinolytic and procoagulant activities in the hemorrhagic syndrome caused by *Lonomia obliqua* caterpillars. *Thrombosis Research*. Vol. 111, No. 1-2, pp. 95-101.
- Veiga, A.B.; Ribeiro, J.M.; Guimarães, J.A. & Francischetti, I.M. (2005). A catalog for the transcripts from the venomous structures of the caterpillar *Lonomia obliqua*: identification of the proteins potentially involved in the coagulation disorder and hemorrhagic syndrome. *Gene*. Vol. 355, pp. 11-27.
- Veiga, A.B.; Berger, M. & Guimarães, J.A. (2009). *Lonomia obliqua* venom: pharmacotoxicological effects and biotechnological perspectives. In: *Animal toxins: the state of the art. Perspectives on health and biotechnology*. De Lima, M.E.; Pimenta, A.M.; Martin-Eauclaire, M.F.; Zingali, R.B. & Rochat, H. (editors), pp. 371-390, UFMG, ISBN 978-85-7041-735-0, Belo Horizonte, Brazil.
- Veiga, S.S.; Feitosa, L.; dos Santos, V.L.; de Souza, G.A.; Ribeiro, A.S.; Mangili, O.C.; Porcionatto, M.A.; Nader, H.B.; Dietrich, C.P.; Brentani, R.R. & Gremski, W. (2000). Effect of brown spider venom on basement membrane structures. *Histochemical Journal*. Vol. 32, No. 7, pp. 397-408.
- Veiga, S.S.; Zanetti, V.C.; Franco, C.R.; Trindade, E.S.; Porcionatto, M.A.; Mangili, O.C.; Gremski, W.; Dietrich, C.P. & Nader, H.B. (2001b). *In vivo* and *in vitro* cytotoxicity of brown spider venom for blood vessel endothelial cells. *Thrombosis Research*. Vol. 102, No. 3, pp. 229-37.
- Vetter, R.S.; Visscher, P.K. & Camazine, S. (1999). Mass envenomations by honey bees and wasps. *Western Journal of Medicine*. Vol. 170, No. 4, pp. 223-7.
- Warrell, D.A. (2010). Snake bite. *Lancet*. Vol. 375, No. 9708, pp. 77-88.
- White, J. (2005). Snake venoms and coagulopathy. *Toxicon*. Vol. 45, No. 8, pp. 951-67.
- Williams, D.; Gutiérrez, J.M.; Harrison, R.; Warrell, D.A.; White, J.; Winkel, K.D. & Gopalakrishnakone, P. (2010). Global Snake Bite Initiative Working Group; International Society on Toxinology. The Global Snake Bite Initiative: an antidote for snake bite. *Lancet*. Vol. 375, No. 9708, pp. 89-91.
- WHO, 2007. Rabies and Envenomings. A Neglected Public Health Issue. World Health Organization, Geneva. Available from: [www.who.int/rabies/relevant\\_documents/en/index.html](http://www.who.int/rabies/relevant_documents/en/index.html)
- WHO, 2010a. Guidelines for the management of snake-bites. World Health Organization, Geneva. Available from: [apps.who.int/medicinedocs/en/m/abstract/Js17111e/](http://apps.who.int/medicinedocs/en/m/abstract/Js17111e/)
- WHO, 2010b. Guidelines for the Production, Control and Regulation of Snake Antivenom Immunoglobulins. World Health Organization, Geneva. Available from: [www.who.int/bloodproducts/snake\\_antivenoms/snakeantivenomguide/en/index.html](http://www.who.int/bloodproducts/snake_antivenoms/snakeantivenomguide/en/index.html)
- Xuan, B.H.; Mai, H.L.; Thi, T.X.; Thi, M.T.; Nguyen, H.N. & Rabenou, R.A. (2010). Swarming hornet attacks: shock and acute kidney injury - a large case series from Vietnam. *Nephrology, Dialysis, Transplantation*. Vol. 25, No. 4, pp. 1146-50.
- Yamasaki, S.C.; Villarroel, J.S.; Barone, J.M.; Zambotti-Villela, L. & Silveira, P.F. (2008). Aminopeptidase activities, oxidative stress and renal function in *Crotalus durissus terrificus* envenomation in mice. *Toxicon*. Vol. 52, No. 3, pp. 345-54.
- Zager, R.A. (1996). Rhabdomyolysis and myohemoglobinuric acute renal failure. *Kidney International*. Vol. 49, No. 2, pp. 314-26.

- Zambrano, A.; González, J. & Callejas, G. (2005). Severe loxoscelism with lethal outcome. Report of one case. *Revista Médica de Chile*. Vol. 133, No. 2, pp. 219-23.
- Zannin, M.; Lourenço, D.M.; Motta, G.; Dalla Costa, L.R.; Grando, M.; Gamborgi, G.P.; Noguti, M.A. & Chudzinski-Tavassi, A.M. (2003). Blood coagulation and fibrinolytic factors in 105 patients with hemorrhagic syndrome caused by accidental contact with *Lonomia obliqua* caterpillar in Santa Catarina, southern Brazil. *Thrombosis and Haemostasis*. Vol. 89, No. 2, pp. 355-64.
- Zelanis, A.; Tashima, A.K.; Rocha, M.M.; Furtado, M.F.; Camargo, A.C.; Ho, P.L. & Serrano, S.M. (2010). Analysis of the ontogenetic variation in the venom proteome/peptidome of *Bothrops jararaca* reveals different strategies to deal with prey. *Journal of Proteome Research*. Vol. 9, No. 5, pp. 2278-91.
- Zingali, R.B.; Ferreira, M.S.; Assafim, M.; Frattani, F.S. & Monteiro RQ. (2005). Bothrojaracin, a *Bothrops jararaca* snake venom-derived (pro)thrombin inhibitor, as an anti-thrombotic molecule. *Pathophysiology of Haemostasis and Thrombosis*. Vol. 34, No. 4-5, pp. 160-3.
- Zhang, R.; Meleg-Smith, S. & Batuman, V. (2001). Acute tubulointerstitial nephritis after wasp stings. *American Journal of Kidney Diseases*. Vol. 38, No. 6, pp. E33.

IntechOpen



### **Renal Failure - The Facts**

Edited by Dr. Momir Polenakovic

ISBN 978-953-51-0630-2

Hard cover, 270 pages

**Publisher** InTech

**Published online** 23, May, 2012

**Published in print edition** May, 2012

The book "Renal Failure - The Facts" consists of some facts about diagnosis, etiopathogenesis and treatment of acute and chronic renal failure. Acute, as well as chronic renal failure is a great medical problem and their treatment is a burden for the budget of each government. The purpose of the chapters is to present some important issues of diagnosis and causes of AKI, as well as those caused by snakes and arthropods, after cardiac surgery, as well as some therapeutic achievements in AKI. Well presented are the psychological conditions in patients on haemodialysis, as well as the treatment of diabetic uremics. The book is aimed at clinicians with a special interest in nephrology, but it should also prove to be a valuable resource for any generalists who encounter nephrological problems in their day-to-day practice.

#### **How to reference**

In order to correctly reference this scholarly work, feel free to copy and paste the following:

Markus Berger, Maria Aparecida Ribeiro Vieira and Jorge Almeida Guimaraes (2012). Acute Kidney Injury Induced by Snake and Arthropod Venoms, *Renal Failure - The Facts*, Dr. Momir Polenakovic (Ed.), ISBN: 978-953-51-0630-2, InTech, Available from: <http://www.intechopen.com/books/renal-failure-the-facts/acute-kidney-injury-induced-by-snake-and-arthropod-venoms>

**INTECH**  
open science | open minds

#### **InTech Europe**

University Campus STeP Ri  
Slavka Krautzeka 83/A  
51000 Rijeka, Croatia  
Phone: +385 (51) 770 447  
Fax: +385 (51) 686 166  
[www.intechopen.com](http://www.intechopen.com)

#### **InTech China**

Unit 405, Office Block, Hotel Equatorial Shanghai  
No.65, Yan An Road (West), Shanghai, 200040, China  
中国上海市延安西路65号上海国际贵都大饭店办公楼405单元  
Phone: +86-21-62489820  
Fax: +86-21-62489821



© 2012 The Author(s). Licensee IntechOpen. This is an open access article distributed under the terms of the [Creative Commons Attribution 3.0 License](#), which permits unrestricted use, distribution, and reproduction in any medium, provided the original work is properly cited.

IntechOpen

IntechOpen