

# We are IntechOpen, the world's leading publisher of Open Access books Built by scientists, for scientists

**4,800**

Open access books available

**122,000**

International authors and editors

**135M**

Downloads

Our authors are among the

**154**

Countries delivered to

**TOP 1%**

most cited scientists

**12.2%**

Contributors from top 500 universities



**WEB OF SCIENCE™**

Selection of our books indexed in the Book Citation Index  
in Web of Science™ Core Collection (BKCI)

Interested in publishing with us?  
Contact [book.department@intechopen.com](mailto:book.department@intechopen.com)

Numbers displayed above are based on latest data collected.

For more information visit [www.intechopen.com](http://www.intechopen.com)



## Neuroimaging of Single Cases: Benefits and Pitfalls

James Danckert<sup>1</sup> and Seyed M. Mirsattari<sup>2</sup>

<sup>1</sup>*Dept of Psychology, University of Waterloo*

<sup>2</sup>*Depts of CNS, Med Biophys, Med Imaging, & Psychology,  
University of Western Ontario  
Canada*

### 1. Introduction

Single case studies of neurological patients has a long and storied history (Zillmer & Spiers, 2001). First used as a teaching tool (Haas, 2001), the method of thoroughly exploring the cognitive and motor functions of a unique individual patient has led to extraordinary advances in our understanding of structure-function relationships in the human brain. Single cases have led to important advances in many fields, including pioneering work on language (Broca, 1861; see also Ryalls & Lecours, 1996) and visual perception (Poppelreuter, 1917/1990; see also Humphreys & Riddoch, 1996) to more recent work on memory systems (Scoville & Milner, 1957; Milner & Penfield, 1955-1956; see Milner, 2005 for a recent review) where one patient (HM) has arguably done more to advance that field than any other single case study in history. Prior to the advent of x-rays and eventually computerised axial tomography (CT scans), the method of studying single cases was the only way to determine the location of a patient's pathology. The advent of CT scans in the 1970's obviated, to some degree, the need for detailed neuropsychological testing, at least as it was needed to determine the *location* of pathology (Banich, 2004; Lezak, et al., 2004; Kolb & Wishaw, 2009). A few decades later and the advent of functional MRI (fMRI) provides an even more powerful tool for examining the nature of structure-function relationships in humans and in non-human primates (Ogawa et al., 1992; Ford et al., 2009). Indeed, the rapid rise of fMRI studies (Fox, 1997; Raichle, 1994) has outstripped the pace of single case studies in the past few decades (Figure 1).

By 2005 the proportion of neuroimaging abstracts accepted for presentation at the Cognitive Neuroscience Society meeting was around 35% compared to only 15% for patient studies (which included group and single case methods; Chatterjee, 2005<sup>1</sup>).

There are a range of reasons behind the rise of functional neuroimaging studies including the ease and relatively low cost with which these studies can be carried out (Chatterjee, 2005). Although per hour imaging costs seem high to most, the cost of patient research is undoubtedly far higher both in time committed and real costs related to screening and following patients over longer periods of time (Chatterjee, 2005). In addition, each method

---

<sup>1</sup> A search of the 2011 CNS program using "fMRI", "neuroimaging" and "patients" separately showed that neuroimaging references were almost double those of references to patients.

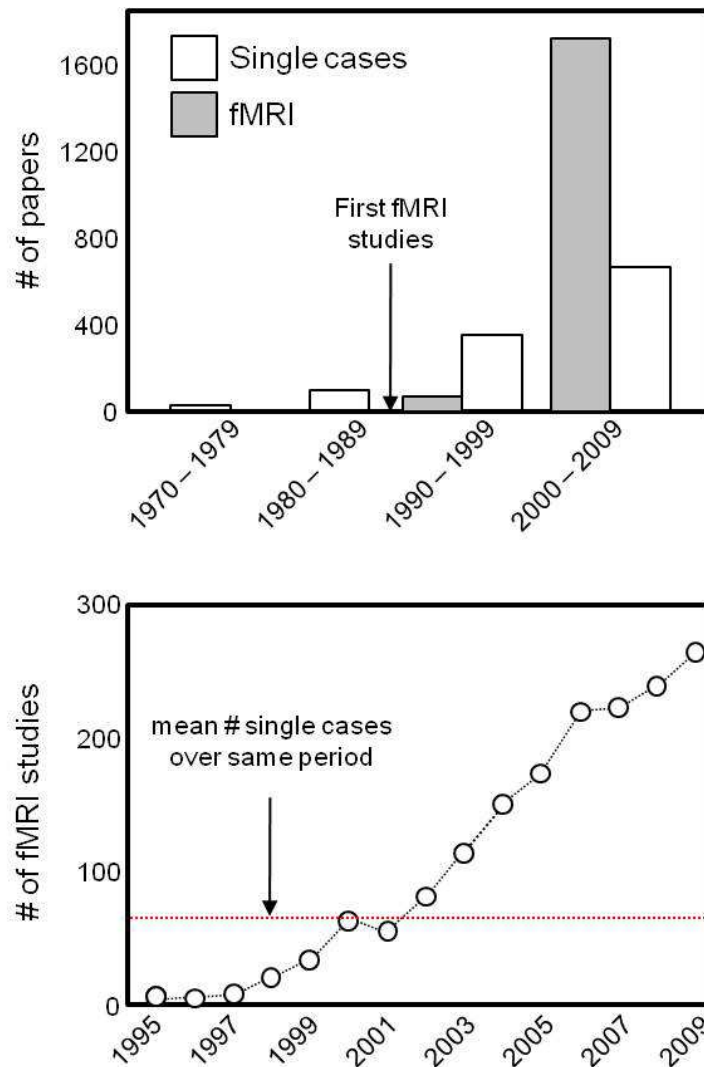


Fig. 1. Proportion of single case and fMRI studies in the past few decades. Upper panel shows the results of two Pubmed searches, the first using the term 'memory' (open bars) and the second using the conjunction search terms 'memory AND fMRI'. The first search included the following constraints: case studies published in English, dating from 1970 onwards (under the 'limits' tab of Pubmed the following criteria were selected: 'English', 'Humans', 'Case Studies', 'dates from 1970.01.01 to 2010.01.01'). The resulting abstracts were inspected to ensure that only single case studies of neurological patients were included. The second search term included the same constraints with the exception that the constraint 'case studies' was removed from the search term. Again, all abstracts were inspected to ensure that only fMRI studies examining memory processes were included.

provides distinct information. By design, human functional neuroimaging studies are necessarily correlational and as such can not address which brain regions are *necessary* for a given function but highlight only those regions or networks that are *sufficient* (Chatterjee, 2005; Friston & Price, 2003). In fact, given that the vast majority of fMRI studies present only group averaged data, it is feasible that much of what we see represents 'cognitively degenerate' neural systems - that is, typical imaging findings may highlight only one of several regions or networks each capable of subserving the same cognitive function (Friston

& Price, 2003). On the other hand, case studies of neurological patients, while capable of demonstrating which brain regions are necessary for a given function, encounter a range of distinct problems (Rorden & Karnath, 2004). Human lesions tend to be large and highly variable and in turn lead to heterogeneous behavioural symptoms. Furthermore, it is not possible to determine the effects of disconnection – the consequences not only of damage to a particular brain region but of removing that 'node' from the network of regions it once participated in (e.g., Bartolomeo, et al., 2007).

Perhaps the best way to compensate for the shortcoming of single case and neuroimaging methods is to combine the two (Friston & Price, 2003; Price et al., 2006, 1999; Chatterjee, 2005). Unfortunately, both methods demonstrate a strong within citation bias (although the bias is stronger in neuroimaging work; Chatterjee, 2005). There have been elegant studies using fMRI in groups of patients to address a wide variety of behaviours from motor control in Parkinson's disease (e.g., Nandhagopal et al., 2008), to strategy selection in social games in psychopathy (Rilling et al., 2007; see also Hoff et al., 2009 for a single case study of psychopathy) and recovery of function in neglect patients – a common disorder typically arising from right hemisphere strokes (Corbetta et al., 2005). Far fewer studies have made use of fMRI to examine single case studies. In this chapter we will first discuss some of the challenges to using fMRI as another tool for exploring single cases before giving some examples of how such an approach could be used to advance our understanding of structure-function relationships in humans.

## 2. Design issues relevant to single case studies in fMRI

Several technical aspects related to collecting the Blood Oxygenated Level Dependent (BOLD) response that forms the basis of fMRI data pose problems for single case studies. First, the shape of the haemodynamic response function (HRF) may vary from one experimental session to another (Aguirre et al., 1998). Within a given subject the shape of the HRF tends to be robust particularly within a single scanning session (Aguirre et al., 1998). More variability is evident within individuals when scanning runs span multiple sessions. This may be related to hardware issues in the scanner itself with some variability in measures of magnetic susceptibility from one session or day to the next (Huettel et al., 2004). Noise may also be introduced from the subject themselves with differing levels of alertness being an important factor in testing neurological patients (Lerdal et al., 2009; see also Tyvaert et al., 2008 for a study of the effects of alertness on BOLD signals). Even factors such as levels of caffeine influence the BOLD signal (Chen & Parrish, 2009). The variability of the HRF and subsequent BOLD measures when testing over multiple sessions is particularly problematic for single case designs as it constrains the number of tasks, and repetition of those tasks, one can expect to complete in a given session. Commonly, fMRI designs require multiple repetitions of the same task within a single session to achieve the appropriate statistical power to demonstrate a robust change in the BOLD signal (Huettel et al., 2004; Monti, 2011). While the same can be said of behavioural studies of single cases, such studies can often extend over days or weeks with an opportunity to replicate findings within the patient and to examine an extensive range of behaviours (e.g., Danckert et al., 2002; Branch-Coslett & Lie, 2008). Issues of fatigue in this instance can be addressed by testing the patient at the same time of day in each instance or collecting a control task as an index of fluctuations in alertness (e.g., a basic information processing task such as the Trails A test

would suffice for this purpose; e.g., Gaudino et al., 1995). In contrast, collecting fMRI data across a range of cognitive functions within one scanning session can be time prohibitive, especially in instances where repetition of each domain specific task is ideal to achieve the appropriate statistical power (Huettel et al., 2004). These limitations can in part be overcome through the choice of tasks to be implemented and the design chosen (i.e., block design vs. the various forms of event-related designs). In general, block designs lead to larger percent signal changes than do event-related designs (Bandettini & Cox, 2000) due to a loss of signal-to-noise ratio for the latter. Tasks exploring basic sensory or motor functions also tend to lead to larger BOLD signal changes than do tasks exploring more complex cognitive functions (Huettel et al., 2004).

A second issue in fMRI scanning impacting upon single case studies using this methodology relates to susceptibility artefacts (Huettel et al., 2004). Susceptibility artefacts can be readily distinguished from true BOLD signal and other artefacts such as motion, using a range of statistical techniques including independent components analysis (e.g., DeMartino et al., 2008). With abnormally developed or injured brains, however, these issues could be compounded. In particular, if one is interested in examining hemispheric differences in activation, it is important to determine that susceptibility artefacts do not impact the damaged and undamaged hemispheres differentially (e.g., Danckert et al., 2007). This can be overcome statistically by contrasting activation for similar regions across each hemisphere (Adcock et al., 2003; Danckert et al., 2007; Shulman et al., 2010). In this instance, however, it is crucial to first determine what one might expect in the healthy brain. For example, basic sensory processes may be expected to lead to symmetrical activations across the two hemispheres (e.g., motion processing and object perception; Dukelow et al., 2001; Kourtzi & Kanwisher, 2000), whereas more complex cognitive processes may be expected to lead to asymmetric activations (e.g., language processing; Price, 2000, 2010). Language functions represent a pertinent case as many individuals may be expected to have bilateral activations during language tasks (Fernandes et al., 2006; Fernandes & Smith, 2000) or even shifted language dominance to the right hemisphere (e.g., Peng & Wang, 2011; Wong et al., 2009). In this instance, fMRI with a single case suffers from the same methodological issues that behavioural studies do – without a baseline measure of performance in some cognitive domains it is difficult if not impossible to determine what has *changed* for the patient. This is particularly problematic for patients suffering from traumatic brain injury (TBI), especially at the mild end of the spectrum, in which subtle changes to executive functions, social functioning and personality are difficult to quantify (e.g., Vaishnavi et al., 2009).

Another issue to consider concerns the nature of damaged or abnormal tissue in neurological patients. More to the point, given that BOLD fMRI depends on changes in oxygenation at the level of capillaries (Huettel et al., 2004; Price et al., 1999), it is possible that damaged or abnormal tissue will also demonstrate abnormal, or at the very least altered, vascularization (Beck & Plate, 2009). Cerebral angiograms are not useful in this circumstance as only gross vascular morphology can be imaged (e.g., obvious abnormalities such as arteriovenous malformations can be detected but the consequences of such malformations for the capillary bed are more complex). This is particularly problematic when faced with null results, an issue we will explore in more detail below. Briefly, any absence of activation could, among other things, be explained due to abnormal vascularization related to the pathology in question. This could be related to abnormally developed tissue (e.g., heterotopias; Guerrini & Barba, 2010) or changes to vascularization due to insults such as stroke (Beck & Plate, 2009). Statistical approaches can in part address this issue (i.e., lowering statistical thresholds should show



some level of activity even in abnormal tissue) and comparisons with similar patients and healthy controls can also partly address these concerns (e.g., Danckert et al., 2007; Danckert & Culham, 2010). These approaches however, never fully remove the concerns surrounding null results and can be seen only as increasing the degree of confidence regarding alternate reasons for an absence of activation. This issue will be revisited with the examples to be discussed in more detail below.

One final vital issue when utilising neuroimaging techniques with neurological patients concerns task design. As already suggested, it is often best to make use of tasks that lead to well documented, robust activation patterns (e.g., tasks known to activate primary sensory and motor cortices). Given that each patient presents with a unique behavioural deficit, however, it is not always possible to stick with the robust, simple tasks. In that sense, task choice and design necessarily feeds off neuropsychological testing – in other words single case methodology. While the temptation may be to choose tasks that fully highlight the patient's particular deficits, this may not be the ideal approach (Price & Friston, 1999). If the patient is completely incapable of performing a given task, interpretation of any neural activity (should any even exist) is limited. Instead, those tasks that the patient can perform either to the same level as healthy controls or to some suboptimal level, should be preferred. In the first instance, when a patient performs to an equivalent level of controls, it is possible to explore the extent to which the same networks are invoked (e.g., Yucel et al., 2002). In many instances, patients will utilise alternate neural networks to achieve the same level of behavioural performance as controls (this may be especially important when investigating disorders such as schizophrenia). The difficulty with this kind of finding comes from interpreting the abnormal neural responses as either *causing* the behavioural syndrome or deficit in question or arising as a *consequence* of the syndrome/deficit (note: in this case the task used may show no deficit per se but tap into a component process known to be impaired in the patient; Price & Friston, 2006). Essentially this arises from the fact that neuroimaging data are correlational in nature and do not allow for conclusions related to the cause of changed patterns of activation. In the second instance, in which the patient performs a task at suboptimal levels, it is possible to correlate performance with the BOLD signal directly (i.e., activations related to correct vs. error trials; Price & Friston, 2006) or to address which parts of the normal neural network are necessary for the task at hand (e.g., Steeves et al., 2004). For example, Steeves and colleagues (2004) examined object processing in a visual form agnostic patient who performed at above chance levels, but well below that of healthy individuals, when asked to recognise visual representations of objects. In their study they were able to examine more precisely which components of object recognition, including colour diagnostics, form outlines and greyscaled images, were most impaired in their patient thereby enabling a more detailed exploration of the variety of processes involved in object perception (Steeves et al., 2004). In instances such as these, however, there remains the possibility that abnormal neural activation patterns arise due to either a loss of function from the damaged region or as a consequence of the fact that the damaged region is disconnected from a broader network (see Price & Friston, 2006 for a detailed review of these and related issues in single case neuroimaging).

Task choice and design are ultimately dictated by the nature of the question being asked. In many instances (including the first two patients to be discussed below) the questions asked are primarily patient focused - that is, the studies represent an attempt to determine the degree of recovery or reorganisation of function in a given patient. In this instance tasks with well-described patterns of activation in the healthy population are essential. In other

instances, the patient serves as a means to understanding normal cognitive processes by virtue of either the demonstrated behavioural deficits or alterations in neural functioning needed to attain normal performance (Price & Friston, 2006). Here one can utilise behavioural performance in conjunction with imaging data (e.g., correlate BOLD with correct vs. incorrect trials) to examine changes in neural function.

In summary, single cases of unique neurological patients provides an opportunity to examine structure-function relationships, with a particular focus on which brain regions may be necessary for a given behaviour. Functional MRI provides another tool that can be used with single cases to examine a broad range of issues. In utilising fMRI with single cases it is important to consider the nature of the pathology for the particular patient, expectations regarding activation in the healthy brain (i.e., is there a demonstrated pattern of activity in healthy individuals related to the task at hand?) and the limitations of the paradigms to be employed (e.g., block designs focussing on well-documented structure-function relationships vs. event-related designs focussing on more complex behaviours). Some of these issues will be explored further below relative to particular examples of fMRI used with single cases.

### **3. Potential uses of fMRI in single case studies**

Below we examine three distinct uses of fMRI in single case studies to illustrate some of the benefits and potential pitfalls of combining the two methodologies. These examples are by no means exhaustive, but represent a disparate range of approaches to combining fMRI and single case studies.

#### **3.1 Examining the consequences of unusual neuropathologies**

We recently examined a range of cognitive functions in two patients with epileptic disorders arising from distinct etiologies (Danckert et al., 2004; 2007). The aims for these studies were varied and so posed distinct challenges. Our first case involved a patient with a large left hemisphere porencaphalic cyst (Figure 2). The remaining left frontal tissue was also the site of seizure onset for the patient and fMRI was employed in the first instance to determine whether or not that residual tissue supported cognitive and motor functions. In this sense then, fMRI becomes an additional tool for the clinician that has the potential to aid in treatment decisions. In fact, fMRI serves another important clinical function in epilepsy research as it has recently begun to surpass traditional methods of determining language lateralisation in epilepsy patients (i.e., the WADA; Abou-Khalil & Schlaggar, 2002; Jones et al., 2011; Woermann et al., 2003). A secondary aim in this case, was to use fMRI to determine the extent to which normal structure-function relationships had been distorted in this patient. In other words, to what extent had his pathology led to a reorganisation of function? Our approach in this instance was to examine basic motor and somatosensory functions and language functions that would all be expected to activate left frontal regions (i.e., when using the right hand for the motor and somatosensory tasks; Toma & Nakai, 2002; Price, 2000). The motor and somatosensory tasks have the added benefit of being robust, simple tasks with predictable activation patterns expected in the unaffected hemisphere, thereby enabling comparisons between the intact and affected cortex. Results showed that the remaining tissue in the left frontal region of this patient did in fact support a range of cognitive and motor functions (Figure 2). Importantly, this indicated that tissue that was demonstrated to be the focus of seizure activity was also capable of supporting normal functioning.

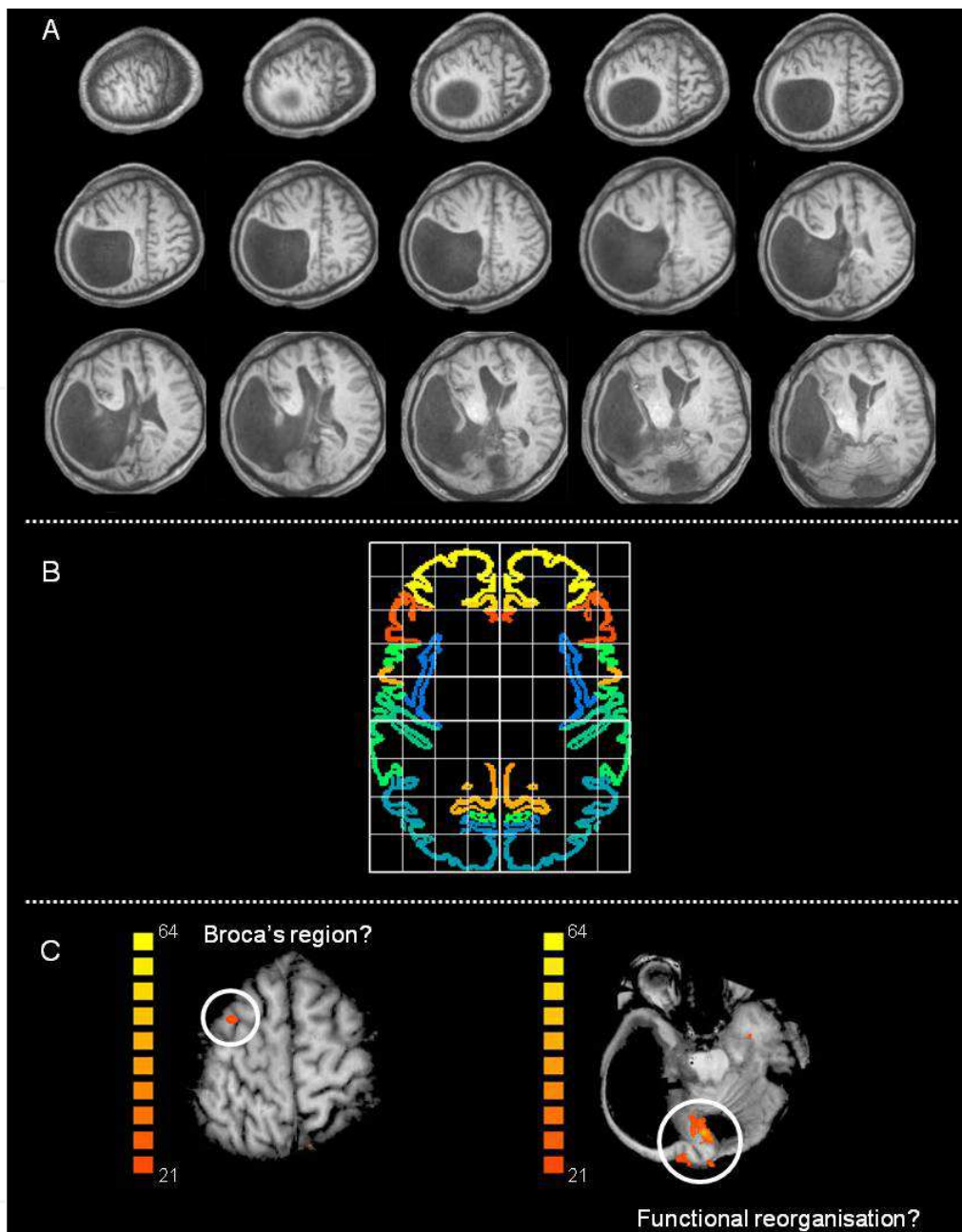


Fig. 2. Selected results from the first case study discussed. Panel A shows anatomical images showing that the patient's skull had been deformed by his porencephalic cyst making it difficult to align the patient's images to a standardised space (indicated in the Panel B using the Talairach template from BrainVoyager software). Panel C shows two data points from this patient. To the left is activity during a silent word naming task in which a left frontal region was activated. Given the distortions evident in the patient's brain and skull it is impossible to know whether this region represents Broca's area. Similarly, the data to the right shows activity in a remaining portion of occipital cortex during silent word naming. This region would not normally be activated in this task (and the undamaged hemisphere showed no occipital activity) and the patient was hemianopic suggesting that the remaining occipital cortex was unlikely to support visual functioning. Nevertheless, caution should be employed when interpreting data of this sort in terms of functional reorganisation. Data adapted from Danckert et al., 2004.



Challenges arising from the case described above that are pertinent to studies of this kind included alignment of the patient's structural scan to a standardised space and a lack of exhaustive testing, especially for unusual activations. As can be seen in Figure 2, the patient's skull had been deformed by the cyst making it difficult to find the landmarks normally used to align structural scans to a normalised space (e.g., Talairach & Tournoux, 1988; see Price & Friston, 2006 for further discussion of this issue). In instances such as this estimates of missing or distorted landmarks are required. This is relatively trivial given that the patient's data will stand alone (i.e., there is no 'group average' to worry about). Where it does pose a problem is in localising activations one would normally expect to see. For example, we found a region of frontal cortex that was active for silent word production that may have been analogous to Broca's region (Danckert et al., 2004). However, given the obvious distortion in gross morphology and without appropriate landmarks, this kind of association was at best speculative.

Perhaps more difficult to address was the fact that it was simply not possible to perform the full range of tasks we would have liked to have collected on this patient. This is likely a problem for all single case studies using fMRI for all of the reasons noted above. For our patient, silent word naming activated a small region of remaining occipital cortex. Given that the patient was hemianopic, any activation in this region is difficult to interpret without further testing. For example, visual perceptual tasks (e.g., object recognition protocols; even retinotopy; Kourtzi & Kanwisher, 2000; Sereno et al., 1995; Tootell et al., 1995) may have been informative regarding the role this remaining region of occipital cortex played in the patient's behaviour (e.g., would the patient have shown residual functions akin to blindsight, or would visual imagery evoke activity in this region even though it receives no afferent input?). Unfortunately, we had been guided in the first instance by other aspects of his presentation (e.g., some mild apraxia) and the fact that his seizures originated not in the sliver of remaining occipital tissue, but in the frontal cortex. This merely serves to highlight some of the restrictions one encounters when addressing unusual single cases in fMRI. Perhaps more important to highlight is the fact that this work was able to demonstrate that a range of functions were subserved by the compromised left hemisphere which in turn guided treatment decisions to some extent. That is, surgery to remove the remaining left frontal tissue had been considered a treatment option, with the fMRI demonstrating just how devastating this approach would have been for the patient's daily functioning.

In our second case, we examined a patient with heterotopic tissue in the anterior temporal cortex (Danckert et al., 2007). In contrast to our first patient, this patient's pathology was not the site of the origin of his seizures, which was more posterior in normally differentiated tissue. Here we wanted to know whether the heterotopic tissue supported any normal cognitive functioning. In addition, what if any, were the consequences to expected structure-function relationships in the tissue where seizures originated? Here we were able to take advantage of imaging results in healthy individuals to examine laterality effects in our patient. Using tasks that would normally activate brain regions identified as the origin of his seizures or tasks that would activate neighbouring regions (i.e., object recognition and motion processing tasks) we were able to demonstrate that our patient had asymmetrical activations where symmetrical activation patterns would have been expected (Figure 3). Taken together with results from our first case, this highlights an important finding in

epilepsy research such that tissue that supports epileptic activity is also likely to support normal function. In the current case we were able to demonstrate an asymmetry of processing such that the epileptic hemisphere showed less activity than the unaffected hemisphere (Figure 3).

The challenges in this case were more substantial than in our first case for several reasons. First, we were unable to demonstrate activation in the heterotopic tissue for any of the tasks we used (Danckert et al., 2007). This raises the spectre of null results briefly mentioned above with the obvious caveat that an absence of evidence is not evidence of absence. This issue would be particularly important if fMRI results of this kind were to be used to guide surgery. Although there was no gross distortion of the patient's brain, the heterotopic tissue also raises concerns regarding abnormal vascularization (see D'Esposito, et al., 2003 for a review of this issue). Any such abnormalities may well have been the root cause of the failure to find significant activations. In addition, task choice may well determine whether or not activation is observed. Without the right task, one would not expect to see activation in a given region. Two approaches can be utilised to address these concerns although it should be noted that what is provided here is some degree of corroborating evidence and not certainty. First, data from healthy individuals using the same tasks/protocols used in the patient can demonstrate what would normally be expected with respect to a given brain region (note, we were unable to do this for all tasks in our case). If the same task that fails to activate a brain region in the patient nevertheless leads to robust and reliable (i.e., evident in all subjects) activity in healthy individuals, one can have more confidence that the patient's pathology has disrupted normal function.

A second approach to dealing with null results involves lowering the threshold for significant activation to determine whether changes in the BOLD response will be evident with less stringent statistical approaches (Figure 3; Danckert et al., 2007; Danckert & Culham, 2010). In our case, even at the lowest statistical thresholds there was no evidence of activity within the heterotopic tissue. Even instances where lowering the statistical threshold does show changes in BOLD signal that were not evident at more conventional thresholds can be informative (Danckert & Culham, 2010). Changes in BOLD signal seen at lower statistical thresholds that fail to modulate with task manipulations (i.e., no difference between BOLD in the task vs. baseline conditions) should be considered meaningless (Danckert & Culham, 2010).

In both cases described above, careful neuropsychological testing was also carried out to compliment the imaging findings. Where possible, such clinical and/or experimental testing is vital as it can cover more ground than imaging alone. In our first case, neuropsychological results (i.e., mild apraxia) directed us towards tasks that would examine basic and more complex (i.e., praxic) motor skills. Similarly, our second case exhibited some mild object naming deficits on neuropsychological testing that guided our choice of tasks (i.e., both language and object naming tasks were used; Danckert et al., 2007). Not only do neuropsychological findings of this kind help guide the choice of tasks for imaging, they can corroborate certain imaging findings. For example, our patient with heterotopic tissue showed asymmetric activation of the lateral occipital complex when naming objects, which could be interpreted in the context of both his pathology (i.e., LOC was proximal to the region of cortex deemed to be the origin of his seizures) and his neuropsychological profile (i.e., mild naming deficits).

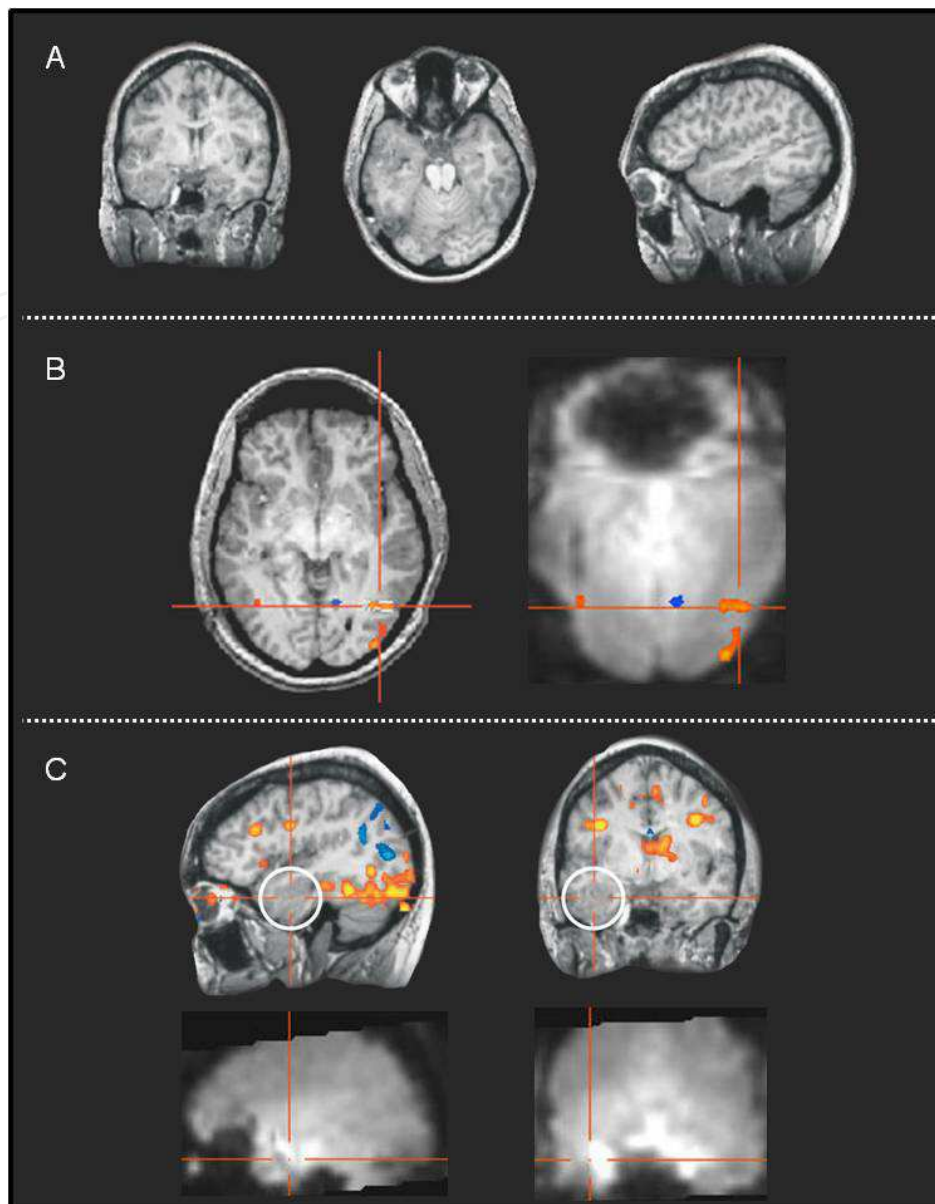


Fig. 3. Selected results from the second case study discussed. Panel A shows anatomical images highlighting the region of heterotopic tissue in the left anterior temporal cortex. Panel B shows activity in response to expanding and contracting concentric circles in area MT bilaterally. Both area and peak BOLD signal were weaker in the damaged hemisphere. Importantly, the raw fMRI data shows no drop-off in signal-to-noise ratio in the damaged hemisphere. Panel C shows activity (both raw and overlaid data) from an object naming task in which the statistical thresholds have been lowered to determine whether heterotopic tissue supported activity. This shows that a failure to detect activity in this region was not due to a lack of statistical power. Nevertheless, caution should be exercised in this instance as other explanations (e.g., abnormal vascularization) can not be ruled out. Data adapted from Dankert et al., 2007.

In both instances discussed above tasks were chosen that would lead to robust, predictable activations with a limited number of experimental runs to maximise the range of behaviours that could be addressed within a single scanning session. This allowed us to explore issues of

symmetry, reorganisation of function and the association between epileptiform activity and function across a reasonably large range of tasks. In other instances, the *range* of tasks to be explored is less relevant as specific hypotheses regarding particular functions allow the focus to be narrowed. For instance, recent investigations into memory functioning in an epilepsy patient who underwent resective surgery of anterior temporal cortex, focused only on specific component processes of memory – namely, familiarity vs. recollection, to determine the role played in each process by the region surgically removed (Bowles et al., 2007). Another instance in which the fMRI approach to single cases can be more narrowly focussed – that of blindsight – is discussed in more detail below.

### 3.2 Residual visual pathways in blindsight

Patients presenting with visual field defects, such as hemianopias, arising from lesions of primary occipital cortex (area V1) can nevertheless respond to blind field stimuli at better than chance levels (Pöppel et al., 1973; Weiskrantz et al., 1974). The term 'blindsight' was first coined by Weiskrantz and colleagues (1974) to refer to these residual visual abilities. Initial demonstrations of above chance responding to blind field stimuli showed that some patients were surprisingly accurate when reaching to, or making a saccade to target locations that had been briefly flashed in their 'blind' field (Weiskrantz et al., 1974; Zihl & Werth, 1984). Note, that the patients were "guessing" at these locations as they had no conscious experience of the targets themselves. Research on blindsight has demonstrated a myriad of residual abilities including motion discrimination, colour and form interference effects, wavelength discrimination and even semantic priming (Danckert et al., 1998; Magnussen & Mathiesen, 1989; Marcel, 1998; Morland et al., 1999; Stoerig & Cowey, 1989).

The demonstration of a broad range of residual abilities in blindsight patients indicates that secondary visual pathways carry information to extrastriate cortex in the absence of input from V1 (Cowey, 2004; Danckert & Goodale, 2000; Danckert & Rossetti, 2005; Stoerig & Cowey, 1997; Weiskrantz et al., 1974). The most prominent of these pathways spared following damage to V1 connects the superior colliculus directly to the pulvinar nucleus of the thalamus, which in turn has direct connections with extrastriate visual cortex (Cowey, 2004; Stoerig & Cowey, 1997; see Sincich et al., 2004 for demonstration of another pathway in the monkey from koniocellular layers of the LGN directly to motion-selective regions of extrastriate cortex).

One key issue in blindsight research involves demonstrating conclusively that the residual visual functions demonstrated are not in fact explained by factors not related to secondary visual pathways. Light scattering from blind to sighted portions of the retina (intraocular scatter) or from blind to sighted portions of the visual field (extraocular scatter) represent a major challenge to blindsight research (Campion et al., 1983). Masking off regions of the blind field and modifying the physical properties of the target stimuli can address these issues to some extent (King et al., 1996; Danckert et al., 2003; Danckert & Culham, 2010). A second challenge can be addressed through both anatomical and functional MRI. Some have suggested that blindsight does not rely on residual pathways bypassing V1, but instead reflects subthreshold activation in residual 'islands' of cortex within V1 (Campion et al., 1983; Fendrich et al., 1992; Gazzaniga et al., 1994). Anatomical scans in this case can conclusively address whether such islands even exist in a given patient. Functional scans have suggested that, in at least one blindsight patient, despite evidence of anatomical sparing of V1, there was no evidence that the spared region supported any functions (Stoerig et al., 1998). Although this work suffers from the absence of evidence argument



discussed above, activation in the undamaged hemisphere can act as a 'control' site for the patient. In other words, if stimuli presented to the sighted field leads to robust activation in the undamaged hemisphere one can be reasonably confident that the task, equipment and statistics are not responsible for a lack of activation when the same stimuli are presented to the blind field (Stoerig et al., 1998). Furthermore, the fact that extrastriate regions *did* show activity in this patient goes a long way towards dismissing the hypothesis that residual visual capacities are in fact reliant on spared islands of cortex in V1.

Functional neuroimaging can also provide insights into the neural structures and potentially the pathways connecting those structures, that would support the range of blindsight phenomena observed. One of the more robust activation paradigms in fMRI makes use of simple flickering checkerboard stimuli to highlight retinotopic maps in striate and extrastriate cortex (e.g., Tootell et al., 1998). For example, various neuroimaging techniques, including fMRI, positron emission tomography (PET) and visual evoked potentials, have been used in the most extensively tested blindsight patient, GY, to demonstrate that, although V1 has been almost completely destroyed in this patient's left hemisphere, spared processing occurs in the visual motion complex, MT+/V5 (Barbur et al., 1993; ffytche et al., 1996; Zeki & ffytche, 1998; Bridge et al., 2008; Goebel, Muckli et al., 2001), in dorsal extrastriate cortex (Baseler et al., 1999; Goebel, et al., 2001), and even in the amygdala, colliculus and prefrontal cortex within the damaged hemisphere in response to blind field stimuli (Morris et al., 2001; Sahraie et al., 1997). Finally, diffusion tensor imaging has the potential to illuminate the white matter pathways that until recently were merely hypothesised to support the range of blindsight phenomena discussed (Leh et al., 2006).

We recently used fMRI to determine the veracity of an unusual case of responding to blind field stimuli (Danckert & Culham, 2010). Our patient had surgery to remove V1 as treatment for medication resistant epilepsy. The patient presented with unusual responses to blind field stimuli in that she consistently localised targets presented in the periphery of her blind field to locations closer to the midline of her field defect and vice versa (Figure 4).

We used fMRI to determine whether we would see residual activation in MT to blind field motion stimuli – a phenomenon evident in other blindsight patients (Magnussen & Mathiesen, 1989). We were also able to contrast our patient's performance with that of GY on similar tasks. Results showed there was no residual activation in the extrastriate cortex of the damaged hemisphere in response to blind field motion stimuli in our patient (Danckert & Culham, 2010). Again, this result suffers from the 'absence of evidence' argument. Here we were able to show reliable activity to blind field motion stimuli in GY's damaged hemisphere and were then able to show that this activity was evident in only one experimental run (Figure 4). That is, responses to blind field stimuli were reliable and robust in patient GY with only minimal exposure. The same could not be said of our patient who showed no reliable activity on any single experimental run even at lowered statistical thresholds (Figure 4). Just as in our case of heterotopic tissue discussed above (Figure 3), this kind of evidence provides additional support to the notion that the absence of activity is not simply due to a lack of statistical power. In contrast to that patient, lowering statistical thresholds in this case did show some level of signal in the voxels of the damaged hemisphere that would be expected to support blindsight motion processing (Figure 4). In this case, however, we were able to show that the 'activity' in these voxels did not show any reliable modulation with the experimental paradigm (Figure 4). Again, caution is still needed with respect to evidence of this kind as it does not rule out other potential explanations for the lack of activation.



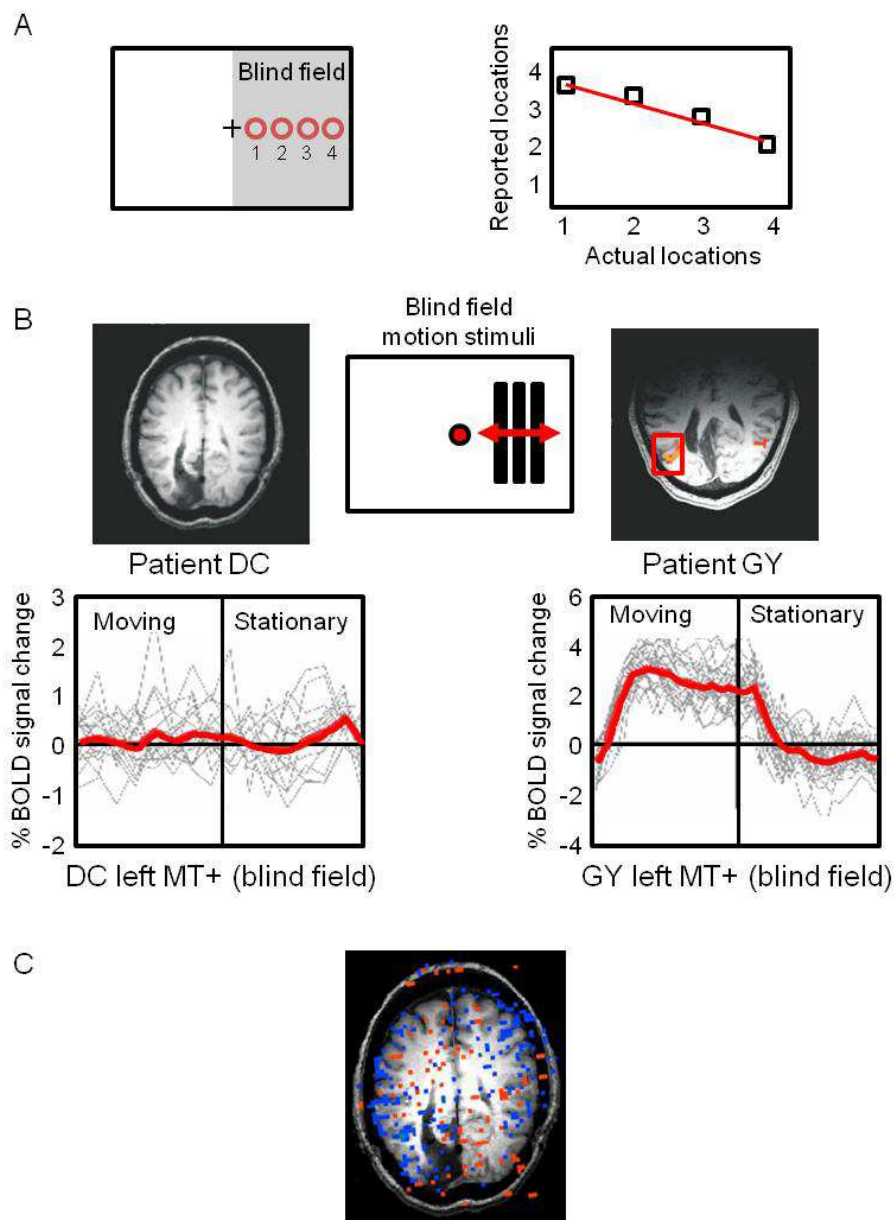


Fig. 4. Panel A shows behavioural data from a hemianopic patient (DC) who showed unusual residual behaviour. To the left is the stimulus setup in which targets could be flashed to either her sighted or blind fields (only blind field targets are shown). When asked to guess blind field target locations DC consistently mislocalised targets - that is, she consistently guessed that targets presented at location 1 in her blind field had instead appeared at location 4 and vice versa. Panel B shows fMRI data from DC and GY, a well tested blindsight patient, when motion stimuli were presented to their blind fields. For GY (to the right) blind field motion stimuli reliably activated MT bilaterally despite a lack of awareness of the stimuli (the red line below represents mean activation across a number of runs for the region highlighted on the anatomical scan show above). This response was evident even in single experimental runs (indicated by the grey lines in the event-related average). In contrast, DC showed no reliable activation to blind field motion stimuli. Panel C shows activity for DC when statistical thresholds were lowered which failed to show any reliable activation suggesting that statistical power was not responsible for the lack of activity to blind field stimuli. Data adapted from Danckert & Culham, 2010

The approaches to examining residual vision in hemianopic patients discussed above highlight many of the issues facing single case studies with fMRI. In most instances robust paradigms (e.g., retinotopy, motion processing) with known activation patterns localised to specific brain regions in the healthy brain (Serenio et al., 1995) were utilised. This enables the testing of specific and directed hypotheses concerning what one would expect to see in the patient. In contrast to the cases of epilepsy discussed above, these cases did not require an extensive range of behaviours to be tested (or accompanying neuropsychological profiling) and instead could focus on particular aspects of residual visual processing in more detail. Finally, utilising fMRI in single cases of residual vision (suspected or demonstrated) can inform not only the neural pathways necessary for supporting residual vision but also the neural signatures of conscious experience. For example, it is possible to contrast activations to stimuli that the patient does report some degree of awareness of with those instances in which they responded to stimuli without any conscious perceptual experience. The final use of fMRI in single cases to be discussed below – synaesthesia – has similar potential to inform our understanding of the neural correlates of consciousness.

### 3.3 Synaesthesia and the neural bases of consciousness

Synaesthesia represents an unusual perceptual phenomenon in which the subject perceives multiple percepts in response to a single sensory stimulus (Rich & Mattingley, 2002, Ward & Mattingley, 2006). Perhaps the most common synaesthetic experience is grapheme-colour associations in which a digit presented in black ink is perceived by the synaesthete to have an additional, consistent colour associated with it (e.g., 7 is always red; Rich & Mattingley, 2002, Ward & Mattingley, 2006; Ramachandran & Hubbard, 2001; Dixon et al., 2000). The study of this unusual phenomenon has the potential to offer new insights into two key issues in cognitive neuroscience: first, how are different perceptual characteristics bound to the same object? That is, colour-grapheme synaesthesia may represent an unusual form of binding in the absence of an external percept (Robertson, 2003). Second, given that synaesthetes experience conscious percepts in the absence of external stimuli, they present an interesting avenue for exploring the neural bases of consciousness and in particular, in discriminating between preconscious and conscious processes (i.e., a synaesthetic experience is by definition not preconscious; Gray 2003; Gray et al., 2006). Functional neuroimaging represents another tool through which these and other questions related to synaesthesia (e.g., is attention necessary for a synaesthetic experience?) can be addressed (Rich et al., 2005).

A key issue in synaesthesia research is the idiosyncratic nature of the individual's experience (see Hochel & Milán, 2008 and Ward & Mattingley, 2006 for review). The authenticity of the particular experience must first be verified through behavioural testing. In essence then, functional imaging approaches to synaesthesia largely *require* single case methodology. That is, given the idiosyncratic experiences of individual synaesthetes, any imaging study will need to tailor tasks to the individual's experience making group comparisons problematic (although see van Leeuwen et al., 2010). A key issue highlighted by fMRI in synaesthetes is the need for appropriate control tasks and participants. For example, Blakemore and colleagues (2005) tested a synaesthete who experienced touch sensations when observing others being touched. They first demonstrated that the synaesthete and controls showed similar patterns of activity for somatosensory stimuli of the self before examining the potential differences in activation when observing others being touched. In the latter case the intention was to determine whether the synaesthete would

show differential activation to the observation of touch in the form of either *increased* activity in regions also shown to be active in controls or *additional* regions not normally activated. Results showed that the synaesthete demonstrated both kinds of activation patterns, with higher activation relative to controls in somatosensory cortex when observing others being touched and additional regions of activity in the anterior insular cortex bilaterally.

One problem with interpreting activations in synaesthetes (or indeed in neurological patients) not evident in controls is that it remains possible that statistical power or other analysis variables may have led to the failure to see those same regions in controls (Friston & Price, 2003). Essentially, additional activations seen in the synaesthete may be evidence of a cognitively degenerate system. That is, there may be more than one brain region or network capable of performing a given cognitive task with only a subset of those regions evident in the analysis of the control group (Friston & Price, 2003; Price & Friston, 2006). One approach to address this concern is to match the synaesthete (or patient, as in the blindsight example above) with a control subject with similar behavioural competencies or idiosyncracies (or similar deficits in the case of neurological patients). Elias and colleagues (2003) did this by contrasting a grapheme-colour synaesthete with a cross-stitch expert. Cross-stitching involves consistent, overlearned associations between colours and numbers. Both the synaesthete and the cross-stitch expert showed Stroop-like interference effects for incongruently coloured numbers (i.e., for the synaesthete this means presenting a number in a colour inconsistent with her perceptual experience, whereas for the cross-stitch expert this meant presenting a number in an incorrectly associated colour with respect to the standards used in cross-stitching). Despite similar behavioural effects, the synaesthete showed distinct neural activations (Elias et al., 2003). The power of this design is that the two individuals (who were also contrasted with a healthy control group) demonstrated comparable behaviours. Some would argue that this is an essential component of using fMRI to explore neurological cases (Price & Friston, 2006) although it is far more challenging to find tasks that patients and controls perform at a similar level. Regardless, the advantage is that with identical behavioural performance, differences in neural activation are less ambiguous. In the example discussed above, the cross-stitch expert represents an 'over-trained' normal control individual, whereas the synaesthete, by virtue of the distinct neural activations observed, clearly invokes different neural patterns to support her unique perceptual experience. Without such a control participant (and beyond the most commonly experienced form of synaesthesia it is hard to see how one would obtain such controls; Smilek et al., 2007) additional activations evident in synaesthesia are difficult to interpret.

As already mentioned in the other examples presented in this chapter, choosing tasks with well documented activation patterns in the healthy brain represents an important component of the approach to investigating the neural basis of synaesthesia. For example, retinotopic mapping demonstrates the borders of visual areas in the healthy brain including those regions most responsive to colour – areas V4 and V8 (Sereno, et al., 1995; Tootell, et al., 1998). Sperling and colleagues (2006) tested four grapheme-colour synaesthetes using retinotopic mapping to first delineate areas V4/V8. Subsequent tests then presented graphemes that did and did not have associated synaesthetic colour experiences (idiosyncratic to the individual synaesthete) in regions corresponding to the retinotopically mapped V4/V8. For the synaesthetes, graphemes with associated colours led to higher activity in V4/V8 than did graphemes with no colour association (Sperling et al., 2006). In contrast, van Leeuwen and colleagues (2010) used another fMRI technique – MR adaptation, in which repeated presentation of a stimulus leads to reduced BOLD signal – to demonstrate

that adaptation occurred not in colour responsive cortex but in the left superior parietal lobule. This result was taken to suggest that synaesthetic experiences depend on feedback from higher cortical regions. Nevertheless, in both instances conclusions regarding the neural basis of synaesthetic experiences benefited from the use of robust paradigms with well documented activation patterns.

Perhaps the primary concern in fMRI with synaesthetes involves the interpretation of additional activations not seen in the healthy brain (Price & Friston, 2003). Closely matched controls, robust tasks with predictable activation patterns and closely matching BOLD signal with behaviour (e.g., dissociating BOLD signal to graphemes that do vs. do not lead to synaesthetic percepts) represent important considerations that can at least partly assist with interpretations of additional activations.

#### 4. Conclusion

Neuroimaging techniques, including functional MRI, are necessarily correlational in nature. From neuroimaging then, we can make conclusions regarding which regions are *sufficient* for a particular function (Friston & Price, 2003; Price & Friston, 2006). In addition, activity may reflect one or many regions/systems capable of subserving the function under consideration (i.e., cognitive degeneracy; Friston & Price, 2003). In contrast, single case studies of neurological patients can demonstrate which brain regions are *necessary* for a given behaviour. The combination of the two methodologies has the potential to provide insights into brain-behaviour relationships that each technique alone can not address, with both clinical and basic science implications. Issues concerning changes to vascularisation as a consequence of neural insult or abnormal neural development, altered signal-to-noise ratios in those regions and consistency of the haemodynamic response function across sessions all represent challenges to implementing single case fMRI studies. In addition, task choice and design involve a number of important considerations: can the patient perform the task? Can performance be correlated with changes in BOLD signal (e.g., differences related to errors vs. correct trials, conscious vs. unconscious percepts, etc.)? Are there precedents in the healthy population (i.e., does the task lead to robust, reliable patterns of activation)? Contrasting activation with similar patients (e.g., Danckert & Culham, 2010) also represents an important strategy with the potential to bolster interpretations of either additional activations or a lack of activation. Nevertheless, the absence of activations in expected regions represents a significant challenge in applying fMRI to single case methods. One approach might be to conduct large scale normative fMRI studies or meta-analyses to provide robust expectations regarding patterns of activation for a range of behaviours that could then be applied to single case studies with either a basic or clinical focus (see Vigneau et al., 2006 for an example of this with respect to language tasks). Given appropriate consideration, the combination of fMRI and single case methodologies has the potential to lead to insights into a wide range of important issues in clinical and cognitive neuroscience.

#### 5. References

- Abou-Khalil, B., & Schlaggar, B.L. (2002). Is it time to replace the Wada test? *Neurology*, 59, 160–161.
- Adcock, J.E., Wise, R.G., Oxbury, J.M., Oxbury, S.M., & Matthews, P.M. (2003). Quantitative fMRI assessment of the differences in lateralization of language-related brain activation in patients with temporal lobe epilepsy. *Neuroimage*, 18, 423–438.



- Aguirre, G.K., Zarahn, E., & D'Esposito, M. (1998). The variability of human, BOLD hemodynamic responses. *Neuroimage*, 8, 360–369.
- Bandettini, P.A., & Cox, R.W. (2000) Event-related fMRI contrast when using constant interstimulus interval: theory and experiment. *Magnetic Resonance Medicine*, 43, 540–548.
- Banich, M.T. (2004). *Cognitive Neuroscience and Neuropsychology*, 2nd Edition. Houghton, Mifflin, Boston, USA.
- Barbur, J.L., Watson, J.D.G., Frackowiak, R.S.J., & Zeki, S. (1993). Conscious visual perception without V1. *Brain*, 116, 1293–1302.
- Bartolomeo, P., Thiebaut de Schotten, M., & Doricchi, F. (2007) Left unilateral neglect as a disconnection syndrome. *Cerebral Cortex*, 17, 2479–2490.
- Baseler, H.A., Morland, A.B., & Wandell, B.A. (1999). Topographic organisation of human visual areas in the absence of input from primary cortex. *Journal of Neuroscience*, 19, 2619–2627.
- Beck, H., & Plate, K.H. (2009) Angiogenesis after cerebral ischemia. *Acta Neuropathologica*, 117, 481–496.
- Bittar, R.G., Ptito, M., Faubert, J., Dumoulin, S.O., & Ptito, A. (1999). Activation of the remaining hemisphere following stimulation of the blind hemifield in hemispherectomized subjects. *Neuroimage*, 10, 339–346.
- Bowles, B., Crupi, C., Mirsattari, S.M., Pigott, S.E., Parrent, A.G., Pruessner, J.C., Yonelinas, A.P., & Köhler, S. (2007). Impaired familiarity with preserved recollection after anterior temporal-lobe resection that spares the hippocampus. *Proceedings of the National Academy of Science, U S A*, 104, 16382–16387.
- Bridge, H., Thomas, O., Jbabdi, S., & Cowey, A. (2008). Changes in connectivity after visual cortical brain damage underlie altered visual function. *Brain*, 131, 1433–1444.
- Broca, P. (1861). Nouvelle observation d'aphémie produite par une lésion de la moitié postérieure des deuxième et troisième circonvolutions frontales. *Bulletins de la Société Anatomique de Paris*, 36, 398–407.
- Campion, J., Latto, R., & Smith, Y.M. (1983). Is blindsight an effect of scattered light, spared cortex, and near-threshold vision? *The Behavioural and Brain Sciences*, 6, 423–486.
- Chatterjee, A. (2005). A madness to the methods in cognitive neuroscience? *Journal of Cognitive Neuroscience*, 17, 847–849.
- Chen, Y., & Parrish, T.B. (2009) Caffeine dose effect on activation-induced BOLD and CBF responses. *Neuroimage*, 46, 577–583.
- Corbetta, M., Kincade, M.J., Lewis, C., Snyder, A.Z., & Sapir, A. (2005) Neural basis and recovery of spatial attention deficits in spatial neglect. *Nature Neuroscience*, 8, 1603–1610.
- Coslett, H.B., & Lie, G. (2008) Simultanagnosia: when a rose is not red. *Journal of Cognitive Neuroscience*, 20, 36–48.
- Cowey, A. (2004). The 30<sup>th</sup> Sir Frederick Bartlett lecture: Fact, artefact, and myth about blindsight. *The Quarterly Journal of Experimental Psychology*, 57A, 577–609.
- Danckert, J., & Rossetti, Y. (2005). Blindsight in action: What can the different subtypes of blindsight tell us about the control of visually guided actions? *Neuroscience and Biobehavioural Reviews*, 29, 1035–1046.
- Danckert, J., Revol, P., Pisella, L., Krolak-Salmon, P., Vighetto, A., Goodale, M.A., & Rossetti, Y. (2003). Measuring unconscious actions in action-blindsight: exploring the



- kinematics of pointing movements to targets in the blind field of two patients with cortical hemianopia. *Neuropsychologia*, 41, 1068–1081.
- Danckert, J., & Goodale, M.A. (2000). Blindsight: A conscious route to unconscious vision. *Current Biology*, 10, R64–R67.
- Danckert, J., Maruff, P., Kinsella, G., de Graff, S., & Currie, J. (1998). Investigating form and colour perception in blindsight using an interference task. *NeuroReport*, 9, 2919–2925.
- Danckert, J., Ferber, S., Doherty, T., Steinmetz, H., Nicolle, D., & Goodale, M.A. (2002). Selective, non-lateralized impairment of motor imagery following right parietal damage. *Neurocase*, 8, 194–204.
- Danckert, J., Mirsattari, S.M., Danckert, S., Wiebe, S., Blume, W.T., Carey, D., Menon, R., & Goodale, M.A. (2004). Spared somatomotor and cognitive functions in a patient with a large porencephalic cyst revealed by fMRI. *Neuropsychologia*, 42, 405–418.
- Danckert, J., Mirsattari, S.M., Bihari, F., Danckert, S., Allman, A-A., Janzen, L. (2007). Functional MRI characteristics of a focal region of cortical malformation not associated with seizure onset. *Epilepsy & Behaviour*, 10, 615–625.
- Danckert, J., & Culham, J.C. (2010). Reflections on blindsight: neuroimaging and behavioural explorations clarify a case of reversed localisation in the blind field of a patient with hemianopia. *Canadian Journal of Experimental Psychology*, 64, 86–101.
- De Martino, F., Valente, G., Staeren, N., Ashburner, J., Goebel, R., & Formisano, E. (2008). Combining multivariate voxel selection and support vector machines for mapping and classification of fMRI spatial patterns. *Neuroimage*, 43, 44–58.
- D'Esposito, M., Deouell, L.Y., & Gazzaley, A. (2003). Alterations in the BOLD fMRI signal with ageing and disease: A challenge for neuroimaging. *Nature Reviews Neuroscience*, 4, 863–872.
- Dixon, M.J., Smilek, D., Cudahy, C., & Merikle, P.M. (2000). Five plus two equals yellow. *Nature*, 406, 365.
- Dukelow, S.P., DeSouza, J.F., Culham, J.C., van den Berg, A.V., Menon, R.S., & Vilis, T. (2001). Distinguishing subregions of the human MT+ complex using visual fields and pursuit eye movements. *Journal of Neurophysiology*, 86, 1991–2000.
- Fendrich, R., Wessinger, C.M., & Gazzaniga, M.S. (1992). Residual vision in a scotoma: Implications for blindsight. *Science*, 258, 1489–1491.
- Fernandes, M.A., Smith, M.L., Logan, W., Crawley, A., & McAndrews, M.P. (2006). Comparing language lateralization determined by dichotic listening and fMRI activation in frontal and temporal lobes in children with epilepsy. *Brain and Language*, 96, 106–114.
- Fernandes, M.A., & Smith, M.L. (2000). Comparing the Fused Dichotic Words Test and the Intracarotid Amobarbital Procedure in children with epilepsy. *Neuropsychologia*, 38, 1216–1228.
- ffytche, D.H., Guy, C.N., & Zeki, S. (1996). Motion specific responses from a blind hemifield. *Brain*, 119, 1971–1982.
- Ford, K.A., Gati, J.S., Menon, R.S., & Everling, S. (2009). BOLD fMRI activation for anti-saccades in nonhuman primates. *Neuroimage*, 45, 470–476.
- Fox, P.T. (1997). The growth of human brain mapping. *Human Brain Mapping*, 5, 1–2.
- Friston, K.J., & Price, C.J. (2003). Degeneracy and redundancy in cognitive anatomy. *Trends in Cognitive Science*, 7, 151–152.

- Gaudino, E.A., Geisler, M.W., & Squires, N.K. (1995) Construct validity in the Trail Making Test: What makes Part B harder? *Journal of Clinical and Experimental Neuropsychology*, 17, 529–535.
- Gazzaniga, M.S., Fendrich, R., & Wessinger, C.M. (1994). Blindsight reconsidered. *Current Directions in Psychological Science*, 3, 93–96.
- Goebel, R., Muckli, L., Zanella, F.E., Singer, W., & Stoerig, P. (2001). Sustained extrastriate cortical activation without visual awareness revealed by fMRI studies of hemianopic patients. *Vision Research*, 41, 1459–1474.
- Gray, J.A. (2003). How are qualia coupled to functions? *Trends in Cognitive Sciences*, 7, 192–194.
- Gray, J.A., Parslow, D.M., Brammer, M.J., Chopping, S., Vythelingum, G.N., & ffytche, D.H. (2006). Evidence against functionalism from neuroimaging of the alien colour effect in synaesthesia. *Cortex*, 42, 309–318.
- Guerrini, R., & Barba, C. (2010) Malformations of cortical development and aberrant cortical networks: epileptogenesis and functional organization. *Journal of Clinical Neurophysiology*, 27, 372–379.
- Haas, L.F. (2001) Jean Martin Charcot (1825-93) and Jean Baptiste Charcot (1867-1936). *Journal of Neurology, Neurosurgery & Psychiatry*, 71, 524.
- Hochel, M. & Milán, E.G. (2008). Synaesthesia: The existing state of affairs. *Cognitive Neuropsychology*, 25, 93–117.
- Huettel, S.A., Song, A.W., & McCarthy, G. (2004). Functional Magnetic Resonance Imaging. Sinauer Associates, Massachusetts, USA.
- Humphreys, G.W., & Riddoch, M.J. (1996). Poppelreuter's case of Merk: The analysis of visual disturbances following a gunshot wound to the brain. In C. Code, C-W. Wallesch, Y. Joannette & A. Roch Lecours (Eds.) *Classic Cases in Neuropsychology*. Psychology Press, Erlbaum, East Sussex, UK.
- Jones, S.E., Mahmoud, S.Y., & Phillips, M.D. (2011). A practical clinical method to quantify language lateralization in fMRI using whole-brain analysis. *Neuroimage*, 54, 2937–2949.
- King, S.M., Azzopardi, P., Cowey, A., Oxbury, J., & Oxbury, S. (1996). The role of light scatter in the residual visual sensitivity of patients with complete cerebral hemispherectomy. *Vision Neuroscience*, 13, 1–13.
- Kolb, B., & Wishaw, I.Q. (2009). *Fundamentals of Human Neuropsychology*, 6th Edition. Worth Publishers, USA.
- Kourtzi, Z., & Kanwisher, N. (2000) Cortical regions involved in perceiving object shape. *Journal of Neuroscience*, 20, 3310–3318.
- Leh, S.E., Johansen-Berg, H., & Ptito, A. (2006). Unconscious vision: new insights into the neuronal correlate of blindsight using diffusion tractography. *Brain*, 129, 1822–1832.
- Lerdal, A., Bakken, L.N., Kouwenhoven, S.E., Pedersen, G., Kirkevold, M., Finset, A., & Kim, H.S. (2009) Poststroke fatigue--a review. *Journal of Pain Symptom Management*, 38, 928–949.
- Lezak, M.D., Howieson, D.B., & Loring, D.W. (2004). *Neuropsychological Assessment*, 4th Edition. Oxford, New York.
- Magnussen, S., & Mathiesen, T. (1989). Detection of moving and stationary gratings in the absence of striate cortex. *Neuropsychologia*, 27, 725–728.


- Marcel, A.J. (1998). Blindsight and shape perception: Deficit of visual consciousness or of visual function? *Brain*, 121, 1565–1588.
- Milner, B. (2005) The medial temporal-lobe amnesic syndrome. *Psychiatry Clin North America*, 28, 599–611.
- Milner, B., & Penfield, W. (1955-1956) The effect of hippocampal lesions on recent memory. *Transactions of the American Neurological Association*, (80th Meeting), 42–48.
- Monti, M.M. (2011). Statistical Analysis of fMRI Time-Series: A Critical Review of the GLM Approach. *Frontiers in Human Neuroscience*, 5, 28.
- Morland, A.B., Jones, S.R., Finlay, A.L., Deyzac, E., Le, S., & Kemp, S. (1999). Visual perception of motion, luminance and colour in a human hemianope. *Brain*, 122, 1183–1196.
- Morris, J.S., de Gelder, B., Weiskrantz, L., & Dolan, R.J. (2001). Differential extrageniculostriate and amygdala responses to presentation of emotional faces in a cortically blind field. *Brain*, 124, 1241–1252.
- Nandhagopal, R., McKeown, M.J., & Stoessl, A.J. (2008) Functional imaging in Parkinson disease. *Neurology*, 70, 1478–1488.
- Ogawa, S., Tank, D.W., Menon, R., Ellermann, J.M., Kim, S.G., Merkle, H., & Ugurbil, K. (1992) Intrinsic signal changes accompanying sensory stimulation: functional brain mapping with magnetic resonance imaging. *Proceedings of the National Academy of Sciences, U S A*, 89, 5951–5955.
- Peng, G., & Wang, W.S. (in press) Hemisphere lateralization is influenced by bilingual status and composition of words. *Neuropsychologia*.
- Pöppel, E., Held, R., & Frost, D. (1973). Residual visual function after brain wounds involving the central visual pathways in man. *Nature*, 243, 295–296.
- Poppelreuter, W. (1917/1990). Disturbances of lower and higher visual capacities caused by occipital damage. (J. Zihl with L. Weiskrantz, Translation). Clarendon Press, Oxford, UK.
- Price, C.J. (2010) The anatomy of language: a review of 100 fMRI studies published in 2009. *Annals of the New York Academy of Science*, 1191, 62–88.
- Price, C.J. (2000) The anatomy of language: contributions from functional neuroimaging. *Journal of Anatomy*, 197, 335–359.
- Price, C.J., & Friston, K.J. (1999) Scanning patients with tasks they can perform. *Human Brain Mapping*, 8, 102–108.
- Price, C.J., Crinion, J., & Friston, K.J. (2006) Design and analysis of fMRI studies with neurologically impaired patients. *Journal of Magnetic Resonance Imaging*, 23, 816–826.
- Ptito, M., Johannsen, P., Faubert, J., & Gjedde, A. (1999). Activation of human extrageniculostriate pathways after damage to area V1. *Neuroimage*, 9, 97–107.
- Raichle, M.E. (1994) Images of the mind: studies with modern imaging techniques. *Annual Reviews in Psychology*, 45, 333–356.
- Ramachandran, V.S., & Hubbard, E.M. (2001). Psychophysical investigations into the neural basis of synaesthesia. *Proceedings of Biological Sciences*, 268, 979–983.
- Rich, A.N., Bradshaw, J.L., & Mattingley, J.B. (2005). A systematic, largescale study of synaesthesia: Implications for the role of early experience in lexical-colour associations. *Cognition*, 98, 53–84.
- Rich, A.N., & Mattingley, J.B. (2002). Anomalous perception in synaesthesia: a cognitive neuroscience perspective. *Nature Reviews Neuroscience*, 3, 43–52.

- Rilling, J.K., Glenn, A.L., Jairam, M.R., Pagnoni, G., Goldsmith, D.R., Elfenbein, H.A., & Lilienfeld, S.O. (2007) Neural correlates of social cooperation and non-cooperation as a function of psychopathy. *Biological Psychiatry*, 61, 1260–1271.
- Robertson, L.C. (2003). Binding, spatial attention and perceptual awareness. *Nature Reviews Neuroscience*, 4, 93–102.
- Rorden, C., & Karnath, H-O. (2004) Using human brain lesions to infer function: a relic from a past era in the fMRI age? *Nature Reviews Neuroscience*, 5, 813–819.
- Ryalls, J., & Lecours, A.R. (1996). Broca's first two cases: from bumps on the head to cortical convolutions. In C. Code, C-W. Wallesch, Y. Joanette & A. Roch Lecours (Eds.) *Classic Cases in Neuropsychology*. Psychology Press, Erlbaum, East Sussex, UK.
- Sahraie, A., Weiskrantz, L., Barbur, J.L., Simmons, A., Williams, S.C.R., & Brammer, M.J. (1997). Pattern of neuronal activity associated with conscious and unconscious processing of visual signals. *Proceedings of the National Academy of Sciences, USA*, 94, 9406–9411.
- Scoville, W.B., & Milner, B. (1957). Loss of recent memory after bilateral hippocampal lesions. *Journal of Neurology, Neurosurgery, & Psychiatry*, 20, 11–21.
- Sereno, M.I., Dale, A.M., Reppas, J.B., Kwong, K.K., Belliveau, J.W., Brady, T.J., Rosen, B.R., & Tootell, R.B. (1995) Borders of multiple visual areas in humans revealed by functional magnetic resonance imaging. *Science*, 268, 889–893.
- Shulman, G.L., Pope, D.L.W., Astafiev, S.V., McAvoy, M.P., Snyder, A.Z., & Corbetta, M. (2010). Right hemisphere dominance during spatial selective attention and target detection occurs outside the dorsal frontoparietal network. *The Journal of Neuroscience*, 30, 3640–3651.
- Sincich, L.C., Park, K.F., Wohlgenuth, M.J., & Horton, J.C. (2004). Bypassing V1: a direct geniculate input to area MT. *Nature Neuroscience*, 7, 1123–1128.
- Smilek, D., Malcolmson, K.A., Carriere, J.S., Eller, M., Kwan, D., & Reynolds. M. (2007). When "3" is a jerk and "E" is a king: personifying inanimate objects in synesthesia. *Journal of Cognitive Neuroscience*, 19, 981–992.
- Steeves, J.K., Humphrey, G.K., Culham, J.C., Menon, R.S., Milner, A.D., & Goodale, M.A. (2004). Behavioral and neuroimaging evidence for a contribution of color and texture information to scene classification in a patient with visual form agnosia. *Journal of Cognitive Neuroscience*, 16, 955–965.
- Stoerig, P., & Cowey, A. (1989). Wavelength sensitivity in blindsight. *Nature*, 342, 916–918.
- Stoerig, P., & Cowey, A. (1997). Blindsight in man and monkey. *Brain*, 120, 535–559.
- Stoerig, P., Kleinschmidt, A., & Frahm, J. (1998). No visual responses in denervated V1: high-resolution functional magnetic resonance imaging of a blindsight patient. *Neuroreport*, 9, 21–25.
- Toma, K., & Nakai, T. (2002) Functional MRI in human motor control studies and clinical applications. *Magnetic Resonance Medical Science*, 1, 109–120.
- Tootell, R.B., Hadjikhani, N., Mendola, J.D., Marrett, S., & Dale, A.M. (1998). From retinotopy to recognition: fMRI in visual cortex. *Trends in Cognitive Science*, 2, 174–183.
- Tootell, R.B., Reppas, J.B., Kwong, K.K., Malach, R., Born, R.T., Brady, T.J., Rosen, B.R., & Belliveau, J.W. (1995) Functional analysis of human MT and related visual cortical areas using magnetic resonance imaging. *Journal of Neuroscience*, 15, 3215–3230.



- Tyvaert, L., Levan, P., Grova, C., Dubeau, F., & Gotman, J. (2008). Effects of fluctuating physiological rhythms during prolonged EEG-fMRI studies. *Clinical Neurophysiology*, *119*, 2762–2774.
- Vaishnavi, S., Rao, V., & Fann, J.R. (2009) Neuropsychiatric problems after traumatic brain injury: unraveling the silent epidemic. *Psychosomatics*, *50*, 198–205.
- van Leeuwen, T.M., Petersson, K.M., & Hagoort, P. (2010). Synaesthetic colour in the brain: Beyond colour areas. A functional magnetic resonance imaging study of synaesthetes and matched controls. *PLoS One*, *5*, 1–12.
- Vigneau, M., Beaucousin, V., Hervé, P.Y., Duffau, H., Crivello, F., Houdé, O., Mazoyer, B., & Tzourio-Mazoyer, N. (2006). Meta-analyzing left hemisphere language areas: phonology, semantics, and sentence processing. *Neuroimage*, *30*, 1414–1432.
- Ward, J., & Mattingley, J.B. (2006). Synaesthesia: an overview of contemporary findings and controversies. *Cortex*, *42*, 129–136.
- Weiskrantz, L., Warrington, E.K., Sanders, M.D., & Marshall, J. (1974). Visual capacity in the hemianopic field following a restricted occipital ablation. *Brain*, *97*, 709–728.
- Woermann, F.G., Jokeit, H., Luerding, R., Freitag, H., Schulz, R., Guertler, S., Okujava, M., Wolf, P., Tuxhorn, I., & Ebner, A. (2003). Language lateralisation by Wada test and fMRI in 100 patients with epilepsy. *Neurology*, *61*, 699–701.
- Wong, S.W.H., Jong, L., Bandur, D., Bihari, F., Yen, Y.F., Takahashi, A.M., Lee, D.H., Steven, D.A., Parrent, A.G., Pigott, S.E., & Mirsattari, S.M. (2009). Cortical reorganization in temporal lobe epilepsy patients following anterior temporal lobectomy. *Neurology*, *73*, 518–525.
- Yücel, M., Pantelis, C., Stuart, G.W., Wood, S.J., Maruff, P., Velakoulis, D., Pipingas, A., Crowe, S.F., Tochon-Danguy, H.J., & Egan, G.F. (2002). Anterior cingulate activation during Stroop task performance: a PET to MRI coregistration study of individual patients with schizophrenia. *American Journal of Psychiatry*, *159*, 251–254.
- Zeki, S., & ffytche, D.H. (1998). The Riddoch syndrome: insights into the neurobiology of conscious vision. *Brain*, *121*, 25–45.
- Zihl, J., & Werth, R. (1984). Contributions to the study of “blindsight” - I. Can stray light account for saccadic localisation in patients with postgeniculate field defects? *Neuropsychologia*, *22*, 1–11.
- Zilmer, E.A., & Spiers, M.V. (2001). Principles of Neuropsychology. Wadsworth, Belmont, USA.





## **Neuroimaging - Cognitive and Clinical Neuroscience**

Edited by Prof. Peter Bright

ISBN 978-953-51-0606-7

Hard cover, 462 pages

**Publisher** InTech

**Published online** 16, May, 2012

**Published in print edition** May, 2012

The rate of technological progress is encouraging increasingly sophisticated lines of enquiry in cognitive neuroscience and shows no sign of slowing down in the foreseeable future. Nevertheless, it is unlikely that even the strongest advocates of the cognitive neuroscience approach would maintain that advances in cognitive theory have kept in step with methods-based developments. There are several candidate reasons for the failure of neuroimaging studies to convincingly resolve many of the most important theoretical debates in the literature. For example, a significant proportion of published functional magnetic resonance imaging (fMRI) studies are not well grounded in cognitive theory, and this represents a step away from the traditional approach in experimental psychology of methodically and systematically building on (or chipping away at) existing theoretical models using tried and tested methods. Unless the experimental study design is set up within a clearly defined theoretical framework, any inferences that are drawn are unlikely to be accepted as anything other than speculative. A second, more fundamental issue is whether neuroimaging data alone can address how cognitive functions operate (far more interesting to the cognitive scientist than establishing the neuroanatomical coordinates of a given function - the where question).

### **How to reference**

In order to correctly reference this scholarly work, feel free to copy and paste the following:

James Danckert and Seyed M. Mirsattari (2012). Neuroimaging of Single Cases: Benefits and Pitfalls, Neuroimaging - Cognitive and Clinical Neuroscience, Prof. Peter Bright (Ed.), ISBN: 978-953-51-0606-7, InTech, Available from: <http://www.intechopen.com/books/neuroimaging-cognitive-and-clinical-neuroscience/neuroimaging-of-single-cases-benefits-and-pitfalls>

**INTECH**  
open science | open minds

### **InTech Europe**

University Campus STeP Ri  
Slavka Krautzeka 83/A  
51000 Rijeka, Croatia  
Phone: +385 (51) 770 447  
Fax: +385 (51) 686 166  
[www.intechopen.com](http://www.intechopen.com)

### **InTech China**

Unit 405, Office Block, Hotel Equatorial Shanghai  
No.65, Yan An Road (West), Shanghai, 200040, China  
中国上海市延安西路65号上海国际贵都大饭店办公楼405单元  
Phone: +86-21-62489820  
Fax: +86-21-62489821

© 2012 The Author(s). Licensee IntechOpen. This is an open access article distributed under the terms of the [Creative Commons Attribution 3.0 License](#), which permits unrestricted use, distribution, and reproduction in any medium, provided the original work is properly cited.

IntechOpen

IntechOpen