

# We are IntechOpen, the world's leading publisher of Open Access books Built by scientists, for scientists

**4,800**

Open access books available

**122,000**

International authors and editors

**135M**

Downloads

Our authors are among the

**154**

Countries delivered to

**TOP 1%**

most cited scientists

**12.2%**

Contributors from top 500 universities



**WEB OF SCIENCE™**

Selection of our books indexed in the Book Citation Index  
in Web of Science™ Core Collection (BKCI)

Interested in publishing with us?  
Contact [book.department@intechopen.com](mailto:book.department@intechopen.com)

Numbers displayed above are based on latest data collected.

For more information visit [www.intechopen.com](http://www.intechopen.com)



# Sequential Management with Gonadotropin-Releasing Hormone Agonist and Dienogest of Endometriosis-Associated Uterine Myoma and Adenomyosis

Atsushi Imai\*, Hiroshi Takagi, Kazutoshi Matsunami and Satoshi Ichigo  
*Institute of Endocrine-Related Cancer, Matsunami General Hospital,  
Japan*

## 1. Introduction

Uterine leiomyoma and adenomyosis represent the most common benign tumors of the female reproductive system (Levy, 2008; Parker, 2007; Sankaran & Manyonda, 2008). These tumors are estrogen dependent, develop during the reproductive period, and are suppressed with menopause. Traditional treatments for myomas and adenomyosis have been various types of surgical techniques. Medical management of these tumors is an approach that has been used recently and is attractive for many gynecologists because of its relative ease and lack of complications (pelvic organ adhesion) compared with surgery. Indications for therapy are similar to those for surgical removal of these tumors and focus on preserving fertility and/or the patient's desire to maintain her uterus. Medications used include androgens, antiprogestogens (mifepristone), raloxifen, and gonadotropin-releasing hormone agonist (GnRHa) (Levy, 2008; Parker, 2007; Sankaran & Manyonda, 2008; Schweppe, 1999). At present, considering efficiency and safety issues, none of the above agents obtained adequate popularity except for GnRHa. However, GnRHa also have disadvantages including bone loss and menopausal symptoms. The effect of GnRHa is transient and reversal of estrogen deprivation occurs soon after discontinuation of the GnRHa and most myoma and adenomyosis returns to their initial size within several months after discontinuation.

Dienogest is a selective progestin that combines the pharmacologic properties of 19-norprogesterins and progesterone derivatives, offering potent progestogenic effects without androgenic, mineral corticoid, or glucocorticoid activity (Harada & Taniguchi, 2010; Sasagawa *et al*, 2008; Sitruk-Ware, 2006). Previous trials demonstrated that dienogest provides effective reductions in endometriosis-associated pelvic pain and laparoscopic measures of pathology (Harada *et al*, 2009; Köhler *et al*, 2010; Schindler *et al*, 2006; Strowitzki *et al*, 2010b). Recently, the new progesterone 2 mg daily demonstrated equivalent efficacy to GnRHa (e.g. buserelin acetate and leuprolide acetate) for relieving the pain of endometriosis in two 24-week, randomized studies (Harada *et al*, 2009; Strowitzki *et al*, 2010a; Strowitzki *et al*, 2010b). Because uterine myoma/adenomyosis and endometriosis have many common

---

\* Corresponding author: Institute of Endocrine-Related Cancer, Matsunami General Hospital, Kasamatsu, Japan.

features (Huang *et al*, 2010), these successful trials on endometriosis support that the use of dienogest inhibits myoma and adenomyosis growth. While evaluating superiority of dienogest in women with endometriosis, we have found significant shrinkage of myoma nodes coexisted with endometriosis over several months during an administration of dienogest (Ichigo *et al*, 2011). In this paper, we attempted to prevent their regrowth after discontinuation of GnRHa using dienogest. This retrospective study may be the first study that examined the efficacy and safety of dienogest following GnRHa therapy in perimenopausal women until leading to a natural menopause.

## 2. Materials and methods

### 2.1 Reproductive chart review

The data were collected from 13 perimenopausal patients sequentially treated with leuprolide acetate (1.88mg monthly, Takeda Pharmaceutical, Japan) for 6 months and dienogest (2mg/day, Mochida Pharmaceutical, Japan) for 6 months against endometriosis in our patient clinic from January 2008 to May 2011. In this retrospective chart review, we included all perimenopausal patients complicated with a myoma node measuring > 4cm or with adenomyosis measuring >10 cm at the age 46-52 years. Measurements of nodes or total uterine volume using MRI were performed at baseline and during treatment at months 6 and 12. For technical reasons, leuprolide acetate was supplied in vials and dienogest in tablets.

Size of myoma or overall uterine was measured at three diameters (transverse, vertical and anterior-posterior) with MRI. Half of multiplied three diameters was accepted as size of myomas and uterus. These measurements were repeated 6 and 12 months after starting the therapy.

### 2.2 Statistics

Pared t-tests were used to analyze in each size change from baseline. Statistical significance was defined as  $P < 0.05$ .

Case No.	Age (years)	Myoma type	Total myoma volume (cm <sup>3</sup> ) (% of baseline)			
			Baseline	After GnRHa treatment	After dienogest treatment	
1	48	Intramural	108.6	78.6 (72.2)	80.6 (74.0)	
2	49	Intramural	72.8	61.9 (85.0)	58.6 (80.5)	
3	46	Intramural (multiple)	45.6	33.6 (73.7)	36.9 (80.9)	
4	52	Intramural (multiple)	89.3	42.7 (47.8)	50.9 (57.0)	
5#	52	Adenomyosis	117.5	56.3 (47.8)	50.3 (42.8)	
6	50	Subserosal	88.7	85.6 (96.5)	81.7 (92.1)	
7##	52	Subserosal (multiple)	87.2	43.6 (50.0)	45.2 (51.8)	
Average			49.9 ± 2.3	87.1 ± 23.5	57.5 ± 19.3* (67.6 ± 19.5)	57.7 ± 17.3* (68.4 ± 18.1)

Table 1. Myoma volume change during sequential treatment with GnRHa and dienogest

The patients were sequentially treated with leuprolide acetate (1.88mg monthly) for 6 months and dienogest (2mg daily) for 6months. Measurements of nodes using MRI were performed at baseline, during treatment at months 6 (after GnRHa therapy) and 12 (after dienogest therapy).

# MRI changes of case 5 are presented as a representative profile in Fig.1.

## Case 7 was submitted to laparotomy at month 8 because of bilateral ovarian abscess. See Fig. 2.

\*  $P < 0.01$  versus baseline.

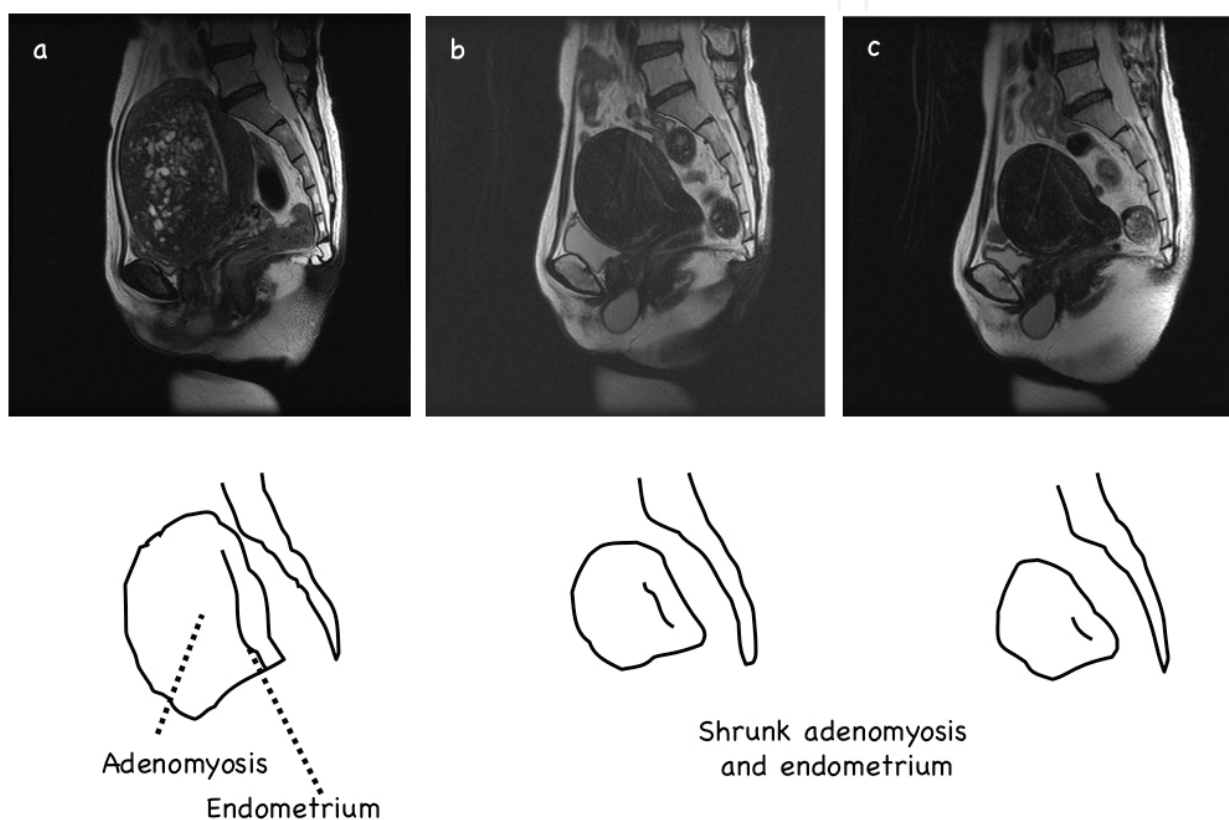


Fig. 1. Total uterine volume change in the patient with myoma during sequential treatment with GnRHa and dienogest (case 6 of Table 1).

The patient was sequentially treated with leuprolide acetate (1.88mg monthly) for 6 months and dienogest (2mg daily) for 6months. Sagittal T2-weighted MR imagings before (a), months 6 (after GnRHa therapy) (b) and 12 (after dienogest therapy)(c)

### 3. Results

Of 13 endometriosis patients sequentially treated with GnRHa and dienogest, 7 were associated with coexistent myoma node and adenomyosis; 4 intramural and 2 subserosal types and 1 of adenomyosis. Mean age was  $49.9 \pm 2.3$  (46-52)(Table 1). Volume changes of total myoma and adenomyosis are presented as the percentage change from baseline in Table 1. A remarkable reduction in myoma /adenomyosis volume from baseline was noted:

the total volume of myoma/adenomyosis declined to  $67.6 \pm 19.5$  % after GnRHa treatment (table 1). During the dienogest-period, myoma volume remained as they shrunk; no regrowth occurred. Fig. 1 showed as a representative profile (case 6 of Table 1). One patient (case 7) discontinued therapy because of an unexpected event, onset on ovarian abscess developed in the endometrioma (see Fig.2).

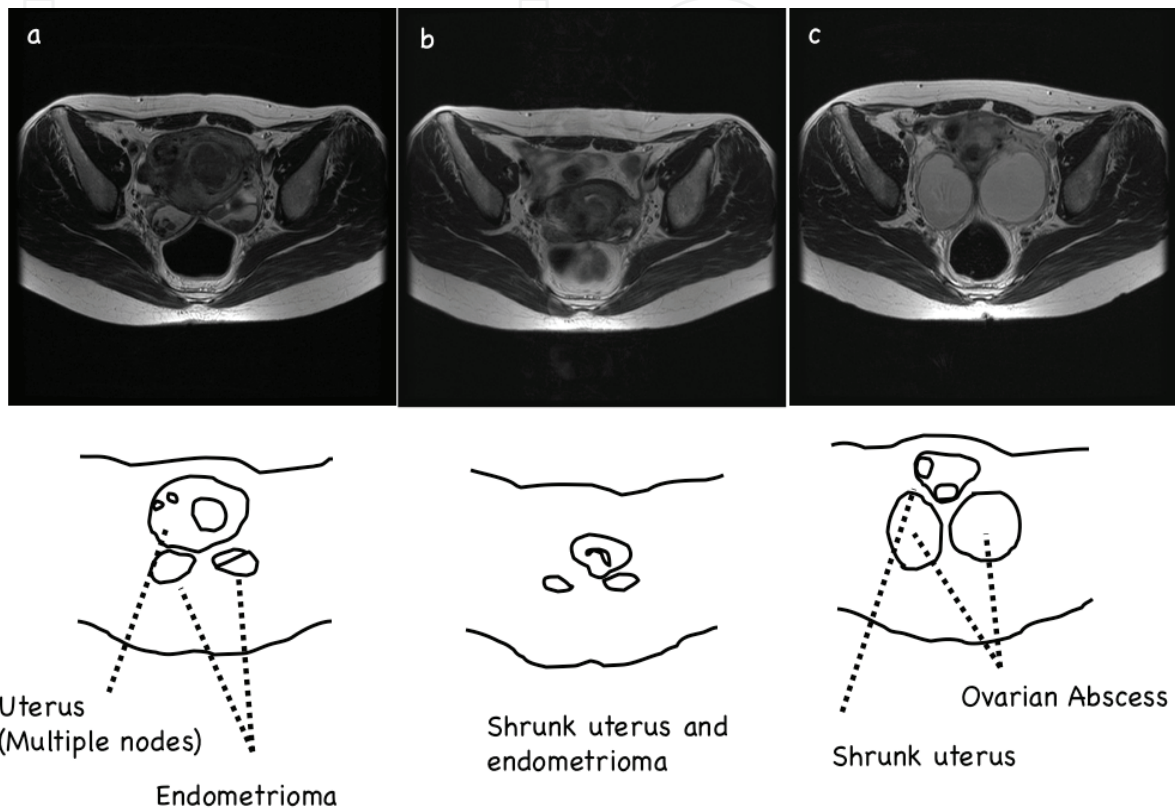


Fig. 2. Bilateral *de novo* ovarian abscesses in a 52-year-old woman with multilobular uterine myoma and bilateral ovarian endometriomas (case 7, table 1).

The patient was treated with leuprolide acetate (1.88mg monthly, Takeda Pharmaceutical, Japan) for 6 months. Axial T2-weighted MR imagings before (a) and after (b) GnRHa treatment showed remarkable shrinkage of uterine myoma and bilateral endometriomas. An attempt to prevent the recurrence submitted the patient to dienogest therapy (2mg daily, Mochida Pharmaceutical, Japan). After two months, she complaint a one-week history of increasing abdominal girth and a two-day history of fever. Axial T2-weighted MR imaging (c) showed two enlarged cystic lesions, one in the left adnexa and the other in the right adnexa. Both lesions were superimposed on the endometrioma with inhomogenous content and the thick wall, while shrunk uterine myoma was detected. There was no history of gynecological interventions including endometrioma aspiration, no had she ever used an intra-uterine device. The clinical and imaging findings and unresponsive to antibiotic therapy proposed the ovarian abscess developed in the endometriomas. At laparotomy, both ovarian cysts were markedly distended and filled with yellow-brown pus, and both ovaries were destroyed by multiple abscess pockets. Histology of the abscess wall confirmed endometriotic nature of the cyst.

#### 4. Discussion

Uterine myoma/adenomyosis and endometriosis have many common features. Both are estrogen-dependent conditions that can often be the source of pelvic pain and menstrual abnormalities. In addition, both have range of symptom severity that is often poorly correlated to preoperative or operative findings, making surgical planning a challenge (Huang et al, 2010). Recently we found significant shrinkage of myoma nodes coexisted with endometriosis over several months during an administration of dienogest (Ichigo et al, 2011). To our knowledge this retrospective study may be the first study that examined the efficacy and safety of sequential management with dienogest following GnRHa therapy in perimenopausal women until leading to a natural menopause.

Many studies have reported the potential usefulness of the hypoestrogenic state induced by GnRHa for treatment of uterine myoma (Levy, 2008; Parker, 2007; Sankaran & Manyonda, 2008). A GnRHa down-regulates the pituitary-ovarian-gonadal axis, leading to suppression of ovarian steroidogenesis. In the present study our patients revealed an average reduction of 57.5 % in myoma volume in response to leuprolide acetate (1.8mg/month). The results are in agreement with those of previous studies (Levy, 2008; Parker, 2007; Parsanezhad *et al*, 2010; Sankaran & Manyonda, 2008). The GnRHa treatment is often associated with so-called ovarian defect symptoms, including vasomotor instability, vaginal dryness, and significant bone loss, which preclude the long-term use of this compound (Levy, 2008; Parker, 2007; Sankaran & Manyonda, 2008). These limit the standard use of GnRHa to 6 months. The regression of uterine or endometriosis volume is not permanent, with returning to their original size or even enlarging more rapidly upon cessation of GnRHa administration. GnRHa, therefore, can only be used in the short term, as temporizing measures in the perimenopausal woman, or pre-operatively to reduce myoma size, influence the type of surgery, restore hemoglobin levels and apparently reduce blood loss at operation (Sankaran & Manyonda, 2008).

There may be profound differences among the available progestins according to their structure, metabolites and pharmacodynamic actions (Harada & Taniguchi, 2010; Sasagawa *et al*, 2008; Sitruk-Ware, 2006). It is therefore inappropriate to consider the various effects of the older and newer progestins as class effects. While it has long been established that estrogen promotes myoma growth, many biochemical and clinical studies suggested that older progestins, without an estrogen component, may be effective in the treatment of endometriosis, but not adenomyosis or myomas (Levy, 2008; Parker, 2007; Sankaran & Manyonda, 2008). The newer progestin dienogest demonstrates a modest suppression of estradiol, representing a potential advantage over other therapies, such as GnRHa, which require estrogen add-back if used longer than 6 months (Harada & Taniguchi, 2010; Strowitzki *et al*, 2010a). Also in contrast to GnRHa, dienogest is not associated with an increased incidence of hot flashes (Strowitzki *et al*, 2010a; Strowitzki *et al*, 2010b). More recently the efficacy and safety of long-term usage of dienogest have been demonstrated in previous controlled studies in a large number of patients with endometriosis (Endrikat *et al*, 2007; Momoeda *et al*, 2009; Schindler *et al*, 2010; Sitruk-Ware, 2006). Our previous paper demonstrated that the use of dienogest have several advantages over GnRHa therapy to manage uterine myoma (Ichigo *et al*, 2011). Management of uterine myoma using dienogest is useful in women for whom temporary reduction in myoma volume is aimed and no surgical intervention is planned for any reason. Women with uterine myoma who have pain, pressure effect, hypermenorrhea, or other types of abnormal uterine bleeding who wish to retain the option of childbirth; women who wish to save their uterus; women who are not fit for surgical intervention; and young

women with infertility can take advantage of this type of treatment. However, the total decline in myoma volume and controlling symptoms are greater in GnRHa protocol (Ichigo *et al*, 2011). The benefit of dienogest in controlling symptoms may persist after therapy of GnRHa in perimenopausal women.

In the previous study (Imai *et al*, 2003), because rapid regrowth frequently occurs after the therapy is stopped, we attempted to determine whether GnRHa therapy could lead perimenopausal women carrying symptomatic myomas to the natural onset of the menopause. A retrospective analysis of 145 patients who received GnRHa for 24 weeks demonstrated that after cessation of therapy no menstruation occurred over 25 weeks in women aged over 45 years, with elevated levels of follicle-stimulating hormone (FSH) and luteinising hormone (LH). To extend this observation, we studied prospectively 21 women, aged 45 years and older who had regular menstruation with symptoms attributed to myomas and elevated days 3 - 5 FSH and days 3 - 5 LH levels ( $> 25$  mIU/ml). After discontinuation of GnRHa (leuprorelin acetate, 1.88 mg) therapy for 6 months, menstruation occurred in only two of 21 individuals but the remaining 19 cases had no menstrual bleeding. It is suggested that the rise in early follicular phase serum gonadotrophins, in particular FSH ( $> 25$  mIU/ml), may precede the natural menopause following (or during) GnRHa therapy in older women. Measuring days 3 to 5 serum FSH concentrations may make it easier to decide on the optimal duration of therapy for symptomatic uterine fibroids in perimenopausal women aged  $> 45$  years. However, in other words, approximately 10 % of women failed to become natural menopause.

Regarding an unexpected event of case 7 of table 1, she has no known previous history of pelvic inflammatory disease, IUD, or any surgical intervention, so she was very unlikely to present with ovarian abscess. It shows that an isolated ovarian abscess can develop in an endometrioma without any recognized risk factor. There are different theories about developing an abscess in the endometrioma (Hameed *et al*, 2010; Kavoussi *et al*, 2006). It may be due to an altered immune environment within endometrial glands and stroma. Recent studies have shown that progesterone-like substances enhance the sexual transmission of various pathogens, including bacteria (Huber & Gruber, 2001; Vassiliadou *et al*, 1999). Collection of altered menstrual type of blood in a cystic space in the ovary and can be a suitable culture medium for pathogens. Cystic wall of endometrioma is theoretically weak as compared to normal ovarian epithelium, so it is susceptible to bacterial invasion.

Lastly, we reported successful management of a series of patients with uterine myoma associated with endometriosis by sequential therapy with GnRHa and a progestine dienogest, although based on the finding in patients associated with endometriosis. The follow-up period of our study was too short to consider the recurrence rate of myomas after discontinuation of treatment in all subjects. Although prospective controlled study should be addressed, the use of dienogest treatment following GnRHa discontinuation for perimenopausal women with symptomatic uterine myoma or adenomyosis should be considered before choosing a more invasive interventions.

## 5. Conclusion

High recurrence rate rapidly after finishing GnRHa leads us to examine the efficacy of sequential management with GnRHa and dienogest in perimenopausal women with endometriosis-associated uterine myoma. Consideration of GnRHa advantages on myoma

shrinkage and low incidence of dienogest-induced adverse events may lead to long-term management of perimenopausal women with myoma and adenomyosis.

## 6. Conflict of interest


The authors declare that they have no conflict of interest.

## 7. References

- Endrikat, J.; Graeser, T., Mellinger, U., Ertan, K. & Holz, C. (2007) A multicenter, prospective, randomized, double-blind, placebo-controlled study to investigate the efficacy of a continuous-combined hormone therapy preparation containing 1mg estradiol valerate/2mg dienogest on hot flushes in postmenopausal women. *Maturitas* Vol.58, pp. 201-201, ISSN 0378-5122
- Hameed, A.; Mehta, V. & Sinha, P. (2010) A rare case of de novo gigantic ovarian abscess within an endometrioma. *Yale Journal of Biology and Medicine* Vol.83, pp. 73-75, ISSN 0044-0086
- Harada, T.; Momoeda, M., Taketani, Y., Aso, T., Fukunaga, M., Hagino, H. & Terakawa, N. (2009) Dienogest is as effective as intranasal buserelin acetate for the relief of pain symptoms associated with endometriosis--a randomized, double-blind, multicenter, controlled trial. *Fertility and Sterility* Vol.91, pp. 675-681, ISSN 0015-0282
- Harada, T. & Taniguchi, F. (2010) Dienogest: a new therapeutic agent for the treatment of endometriosis. *Women's Health* Vol.6, pp. 27-35, ISSN 1745-5057
- Huang, J.; Lathi, R., Lemyre, M., Rodriguez, H., Nezhat, C. & Nezhat, C. (2010) Coexistence of endometriosis in women with symptomatic leiomyomas. *Fertility and Sterility* Vol.94, pp. 720-723, ISSN 0015-0282
- Huber, J. & Gruber, C. (2001) Immunological and dermatological impact of progesterone. *Gynecological Endocrinology* Vol.15 (Suppl 6), pp. 18-212, ISSN 0951-3590
- Ichigo, S.; Takagi, H., Matsunami, K., Suzuki, N. & Imai, A. (2011) Beneficial effects of dienogest on uterine myoma volume: a retrospective controlled study comparing with gonadotropin-releasing hormone agonist. *Archives of Gynecology and Obstetrics* Vol.Epub ahead of print, ISSN 0932-0067
- Imai, A.; Sugiyama, M., Furui, T. & Tamaya, T. (2003) Treatment of perimenopausal women with uterine myoma: successful use of a depot GnRH agonist leading to a natural menopause. *Journal of Obstetrics and Gynaecology* Vol.23, pp 518-520, ISSN 0144-3615
- Kavoussi, S.; Pearlman, M., Burke, W. & Lebovic, D. (2006) Endometrioma complicated by tubo-ovarian abscess in a woman with bacterial vaginosis. *Infectious Disease in Obstetrics and Gynecology* Vol.2006, pp. 1-3,
- Köhler, G.; Faustmann, T., Gerlinger, C., Seitz, C. & Mueck, A. (2010) A dose-ranging study to determine the efficacy and safety of 1, 2, and 4mg of dienogest daily for endometriosis. *International Journal of Gynaecology and Obstetrics* Vol.108, pp. 21-25, ISSN: 0020-7292
- Levy, B. (2008) Modern management of uterine fibroids. *Acta Obstetrica et Gynecologica Scandinavica* Vol.87, pp. 812-823, ISSN 1600-0412



- Momoeda, M.; Harada, T., Terakawa, N., Aso, T., Fukunaga, M., Hagino, H. & Taketani, Y. (2009) Long-term use of dienogest for the treatment of endometriosis. *Journal of Obstetric and Gynaecological Research* Vol.35, pp. 1069-1076, ISSN 13418076
- Parker, W. (2007) Uterine myomas: management. *Fertility and Sterility* Vol.88, pp. 255-271, ISSN 0015-0282
- Parsanezhad, M.; Azmoon, M., Alborzi, S., Rajaeefard, A., Zarei, A., Kazerooni, T., Frank, V. & Schmidt, E. (2010) A randomized, controlled clinical trial comparing the effects of aromatase inhibitor (letrozole) and gonadotropin-releasing hormone agonist (triptorelin) on uterine leiomyoma volume and hormonal status. *Fertility and Sterility* Vol.93, pp. 192-198, ISSN 0015-0282
- Sankaran, S. & Manyonda, I. (2008) Medical management of fibroids. *Best Practice & Research Clinical Obstetrics & Gynaecology* Vol.22, pp. 655-676, ISSN 1521-6934
- Sasagawa, S.; Shimizu, Y., Kami, H., Takeuchi, T., Mita, S., Imada, K., Kato, S. & Mizuguchi, K. (2008) Dienogest is a selective progesterone receptor agonist in transactivation analysis with potent oral endometrial activity due to its efficient pharmacokinetic profile. *Steroids* Vol.73, pp. 222-231, ISSN 0039-128X
- Schindler, A.; Christensen, B., Henkel, A., Oettel, M. & Moore, C. (2006) High-dose pilot study with the novel progestogen dienogest in patients with endometriosis. *Gynecological Endocrinology* Vol.22, pp. 9-17, ISSN 0951-3590
- Schindler, A.; Henkel, A., Moore, C. & Oettel, M. (2010) Effect and safety of high-dose dienogest (20 mg/day) in the treatment of women with endometriosis. *Archives of Gynecology and Obstetrics* Vol.282, pp. 507-514, ISSN 0932-0067
- Schweppe, K. (1999) Progestins and uterine leiomyoma. *Gynecological Endocrinology* Vol.13 Suppl 4, pp. 21-24, ISSN 0951-3590
- Sitruk-Ware, R. (2006) New progestagens for contraceptive use. *Human Reproduction Update* Vol.12, pp. 169-178, ISSN 1355-4786
- Strowitzki, T.; Faustmann, T., Gerlinger, C. & Seitz, C. (2010a) Dienogest in the treatment of endometriosis-associated pelvic pain: a 12-week, randomized, double-blind, placebo-controlled study. *European Journal of Obstetrics & Gynecology and Reproductive Biology* Vol.151, pp. 193-198, ISSN 0301-2115
- Strowitzki, T.; Marr, J., Gerlinger, C., Faustmann, T. & Seitz, C. (2010b) Dienogest is as effective as leuprolide acetate in treating the painful symptoms of endometriosis: a 24-week, randomized, multicentre, open-label trial. *Human Reproduction Update* Vol.25, pp. 633-641, ISSN 1355-4786
- Vassiliadou, N.; Tucker, L. & Anderson, D. (1999) Progesterone-induced inhibition of chemokine receptor expression on peripheral blood mononuclear cells correlates with reduced HIV-1 infectability in vitro. *Journal of Immunology* Vol.162, pp. 7510-7518, ISSN 0022-1767



## **Endometriosis - Basic Concepts and Current Research Trends**

Edited by Prof. Koel Chaudhury

ISBN 978-953-51-0524-4

Hard cover, 490 pages

**Publisher** InTech

**Published online** 09, May, 2012

**Published in print edition** May, 2012

This book provides an insight into the emerging trends in pathogenesis, diagnosis and management of endometriosis. Key features of the book include overviews of endometriosis; endometrial angiogenesis, stem cells involvement, immunological and hormonal aspects related to the disease pathogenesis; recent research reports on infertility, endometrial receptivity, ovarian cancer and altered gene expression associated with endometriosis; various predictive markers, and imaging modalities including MRI and ultrasound for efficient diagnosis; as well as current non-hormonal and hormonal treatment strategies. This book is expected to be a valuable resource for clinicians, scientists and students who would like to have an improved understanding of endometriosis and also appreciate recent research trends associated with this disease.

### **How to reference**

In order to correctly reference this scholarly work, feel free to copy and paste the following:

Atsushi Imai, Hiroshi Takagi, Kazutoshi Matsunami and Satoshi Ichigo (2012). Sequential Management with Gonadotropin-Releasing Hormone Agonist and Dienogest of Endometriosis-Associated Uterine Myoma and Adenomyosis, *Endometriosis - Basic Concepts and Current Research Trends*, Prof. Koel Chaudhury (Ed.), ISBN: 978-953-51-0524-4, InTech, Available from: <http://www.intechopen.com/books/endometriosis-basic-concepts-and-current-research-trends/sequential-management-with-gonadotropin-releasing-hormone-agonist-and-dienogest-of-endometriosis-ass>

**INTECH**  
open science | open minds

#### **InTech Europe**

University Campus STeP Ri  
Slavka Krautzeka 83/A  
51000 Rijeka, Croatia  
Phone: +385 (51) 770 447  
Fax: +385 (51) 686 166  
[www.intechopen.com](http://www.intechopen.com)

#### **InTech China**

Unit 405, Office Block, Hotel Equatorial Shanghai  
No.65, Yan An Road (West), Shanghai, 200040, China  
中国上海市延安西路65号上海国际贵都大饭店办公楼405单元  
Phone: +86-21-62489820  
Fax: +86-21-62489821

© 2012 The Author(s). Licensee IntechOpen. This is an open access article distributed under the terms of the [Creative Commons Attribution 3.0 License](#), which permits unrestricted use, distribution, and reproduction in any medium, provided the original work is properly cited.

IntechOpen

IntechOpen